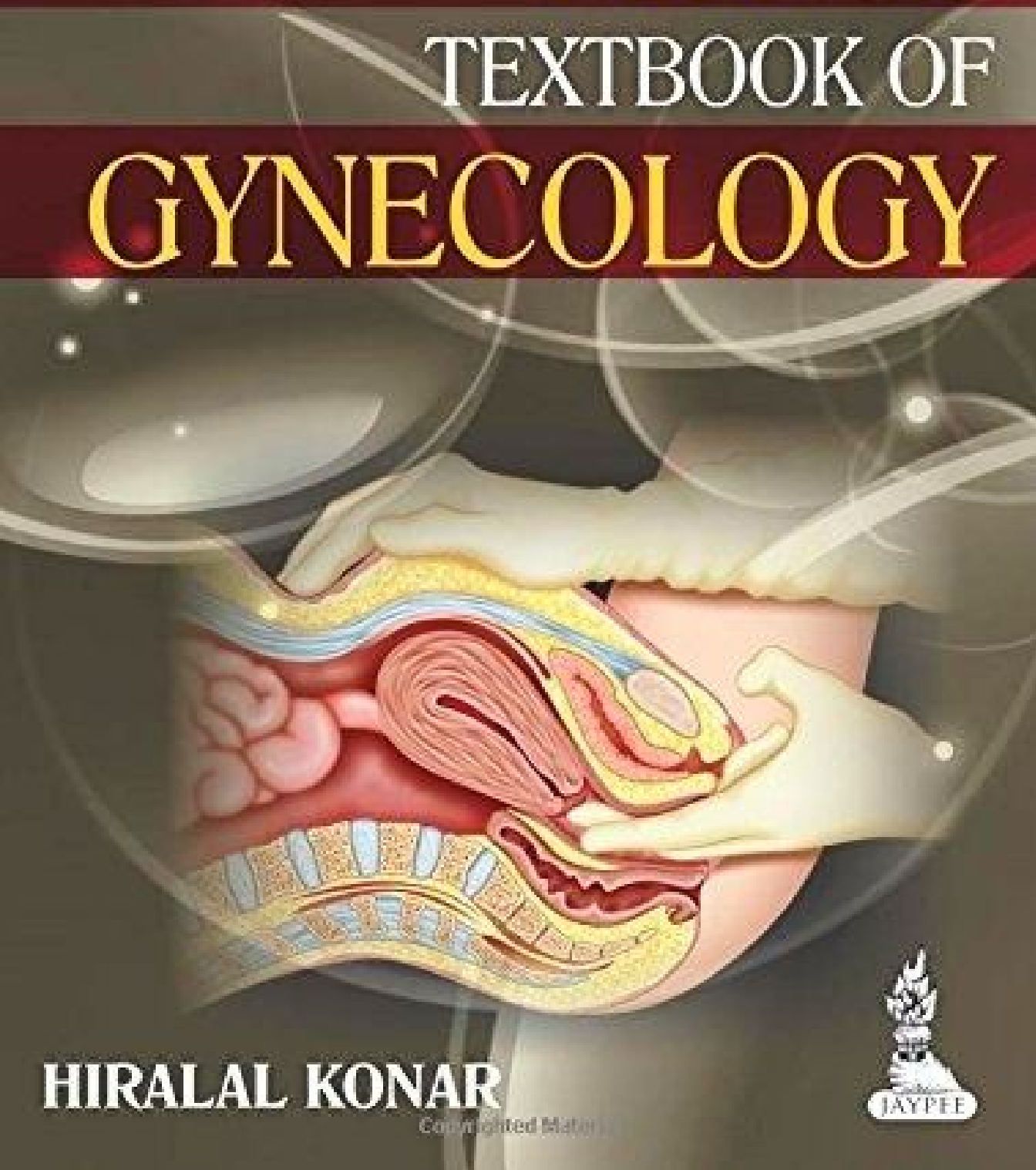




Includes Interactive  
DVD-ROM

# D C DUTTA'S TEXTBOOK OF GYNECOLOGY



**HIRALAL KONAR**

Copyrighted Material





DC DUTTA'S  
TEXTBOOK OF  
GYNECOLOGY

---

*including*  
*Contraception*

## **OTHER BOOKS BY THE SAME AUTHOR**

---

- Textbook of Obstetrics
- A guide to Clinical Obstetrics and Gynecology
- Bedside Clinics & Viva-voce in Obstetrics and Gynecology
- Master Pass in Obstetrics and Gynecology
- Emergencies in Manipulative and Operative Obstetrics

# DC DUTTA'S TEXTBOOK OF GYNECOLOGY

---

*including*  
*Contraception*

*Enlarged & Revised Reprint of Sixth Edition*

## **DC DUTTA**

MBBS, DGO, MO(CAL)

Professor and Head, Department of Obstetrics and Gynecology  
Nilratan Sircar Medical College and Hospital, Kolkata, India

*Edited by*

## **HIRALAL KONAR**

(HONS; GOLD MEDALLIST)

MBBS (CAL), MD (PGI), DNB (INDIA)

MNAMS, FACS (USA), FRCOG (LONDON)

Chairman, Indian College of Obstetricians and Gynecologists

Professor, Department of Obstetrics and Gynecology

Calcutta National Medical College and C.R. Hospital, Kolkata, India

*One time Professor & Head, Dept. Obst. & Gyne.,*

*Midnapore Medical College & Hospital, West Bengal University of Health Sciences, Kolkata, India;*

*Rotation Registrar in Obstetrics, Gynecology and Oncology*

*Northern and Yorkshire Region, Newcastle-upon-Tyne, UK*

Examiner of MBBS, DGO, MD and PhD of different Indian Universities  
and National Board of Examination, New Delhi, India



---

**JAYPEE BROTHERS MEDICAL PUBLISHERS (P) LTD**

**New Delhi • London • Philadelphia • Panama**



**Jaypee Brothers Medical Publishers (P) Ltd**

### Headquarters

Jaypee Brothers Medical Publishers (P) Ltd  
4838/24, Ansari Road, Daryaganj  
New Delhi 110 002, India  
Phone: +91-11-43574357  
Fax: +91-11-43574314  
Email: [jaypee@jaypeebrothers.com](mailto:jaypee@jaypeebrothers.com)

### Overseas Offices

J.P. Medical Ltd  
83 Victoria Street, London  
SW1H 0HW (UK)  
Phone: +44-2031708910  
Fax: +02-03-0086180  
Email: [info@jpmedpub.com](mailto:info@jpmedpub.com)

Jaypee Medical Inc  
The Bourse  
111 South Independence Mall East  
Suite 835, Philadelphia, PA 19106, USA  
Phone: +1 267-519-9789  
Email: [joe.rusko@jaypeebrothers.com](mailto:joe.rusko@jaypeebrothers.com)

Jaypee Brothers Medical Publishers (P) Ltd  
Bhotahity, Kathmandu, Nepal  
Phone: +977-9741283608  
Email: [kathmandu@jaypeebrothers.com](mailto:kathmandu@jaypeebrothers.com)

Website: [www.jaypeebrothers.com](http://www.jaypeebrothers.com)  
Website: [www.jaypeedigital.com](http://www.jaypeedigital.com)

© Copyright reserved by Mrs Madhusri Konar

The views and opinions expressed in this book are solely those of the original contributor(s)/author(s) and do not necessarily represent those of editor(s) of the book.

All rights reserved. No part of this publication may be reproduced, stored or transmitted in any form or by any means, electronic, mechanical, photocopying, recording or otherwise, without the prior permission in writing of the publishers.

All brand names and product names used in this book are trade names, service marks, trademarks or registered trademarks of their respective owners.

Information contained in this book is up to date, believed to be reliable when checked with the sources and is in accordance with the accepted standard, at the time of publication. However, with ongoing research and passage of time, new knowledge may modify some of it. The reader should, therefore, approach the book with a realistic attitude (particularly the drugs and doses) and should carry the professional responsibility. The readers are asked to verify the information contained herein from other sources. Neither the publisher nor the author(s)/editor(s) assume any liability for any injury and/or damage to persons or property arising from or related to use of material in this book.

This book is sold on the understanding that the publisher is not engaged in providing professional medical services. If such advice or services are required, the services of a competent medical professional should be sought.

Every effort has been made where necessary to contact holders of copyright to obtain permission to reproduce copyright material. If any have been inadvertently overlooked, the publisher will be pleased to make the necessary arrangements at the first opportunity.

**Inquiries for bulk sales may be solicited at:** [jaypee@jaypeebrothers.com](mailto:jaypee@jaypeebrothers.com)

### **Textbook of Gynecology**

*Enlarged & Revised Reprint of Sixth Edition: November 2013*

ISBN 978-93-5152-068-9

Printed at

**Dedicated to**

*The students of gynecology  
past and present*





# Preface to the sixth edition

This widely acclaimed *Dutta's Textbook of Gynecology* has stepped into its sixth edition within a span of twenty three years. Since its predecessor, each area of gynecology has evolved substantially due to the concurrent progress in the field of molecular biology, technology and imaging. The amount of knowledge to acquire and skill to develop by the students, residents and clinicians are enormous. Retaining the basic objectives of *Dutta*, for his textbook, this edition has been revised extensively in the light of current wealth of information and for the need of our targeted readers. Each chapter of this book is authoritative. *Consistency and uniformity with updated information in all the chapters is a special feature of this text.*

This edition has been made more user-friendly in terms of presentation of text matters, graphics, design and use of different color codes. Color code helps to highlight the core knowledge (must-know area) and also to present the high quality photographs, anatomical drawings, and imaging studies. The text has been enriched with tables, diagrams, boxes, charts, and algorithms which could be reproduced easily. Key points at the end of each chapter are for quick and easy revision. The *state-of-the art* in Dutta's text lies in the presentation which is simple, lucid, clear, and concise. Above all, it provides a balanced distillation of evidence-based information upon which a student, trainee resident, a practitioner, and a nurse can fully depend.

Chapters on basic areas (chapters 1, 2, 3, 4, 9), reproductive endocrinology (chapters 5, 6, 7, 8, 16, 28, 31, 33), menopause (chapter 6), diagnostic and imaging technologies (chapter 9), pelvic infections (chapters 10, 11, 12), oncology (chapters 22, 23, 30), urogynecology (chapters 24 and 25), contraception (chapter 29) have either been thoroughly revised or exhaustively rewritten. New topics, for example, adolescent gynecology (chapter 32), sexual dysfunction (chapter 33), gene therapy (chapter 30) have been incorporated. Chapters in general gynecology 17, 18, 19, 20, 21 have been extensively updated. The chapter on pelvic organ prolapse (chapter 15) has been rewritten, based upon the latest concept of pelvic anatomy and the 'new' concepts of repair. Operative gynecology (chapter 34) is meant to provide the basic principles of commonly performed gynecologic surgery so as to guide an apprentice. More emphasis has been given on case selection (indications), principal steps of operation and the complications. The chapter on endoscopic (laparoscopic and hysteroscopic) surgery (Chapter 35) has been rewritten, as it has gained its place to a large extent.

The chapter on practical gynecology (chapter 37) consists of several hundreds of questions along with answers, explanations and high quality photographs and plates of imaging studies. This chapter is designed to help the students in their preparations for the clinical and oral parts of the examination. The self-assessment questionnaire having objective structured clinical examination (OSCE) format is to improve the clinical competence of the students. The total information given in chapter 37 amounts to a "*mini-textbook-cum-color atlas*" of gynecology.

More than 470 figures, photographs, sketches and drawings have been incorporated.

Considering the vast amount of scientific information and the progressive research, it is practically impossible to limit the subject matter within the few pages of this book. Arrangements have been made, through electronic media (website, e-mails) for the readers who wish to know more [highlighted in the text '*more information*'; '*ask the author*']. Informations regarding examination situation (theory, viva-voce and multiple choice questions and answers, clinical examination procedures, operation video clips) have been provided through these electronic resources ([www.dcdutta.com](http://www.dcdutta.com)/[www.hiralalkonar.com](http://www.hiralalkonar.com)).

My aim in this book has always been to help the students, residents, and the clinicians to remain with updated the knowledge that has passed the test of clinical relevancy.

The editor has many distinguished persons to thank for their efforts in updating the book. I have consulted many outstanding teachers in the profession, a multitude of eminent authors and many current evidence-L studies-the legacy is gratefully acknowledged. I expresses my sincere thanks to many of my esteemed colleagues throughout the country and abroad for their valued suggestions, criticisms, and contribution of photographs (duly acknowledged). I acknowledge sincerely the support of all the students (undergraduate and postgraduate) of different medical institutions in this country for their opinion and criticisms that have helped to improve the text. As before, I welcome the views of students and teachers who regularly write to me offering their suggestions and ideas on my e-mails: h.kondr@gmail.com; h.kon@vsnl.net.

I am specially grateful to Dr K M Gun, MD, FRCOG, FRCS, Prof (Retd) for his contribution on the topic “Amenorrhea”, Dr B N Chakravorty, MD, FRCOG, DSc, Prof (Retd), Director, Institute of Reproductive Medicine, Kolkata, for his contribution on the topics “Reproductive endocrinology”, “Infertility”, “Intersex”, and “Hormones in gynecology” and Dr A Mazumdar, MD, Prof and Head, Dept Radiotherapy, IPGME & R, Kolkata, for his support in revising the chapter “Radiotherapy Chemotherapy” in gynecology. The editor wishes to express his sincere thanks to Dr Subir Kumar Dutta, MD, Professor (Retd), Dept of Pathology and Bacteriology, University College of Medicine, Kolkata, for the microphotographs depicted throughout the text.

Dr A Roy, PhD, Professor (Retd), Dr (Mrs) S Ganguly, MD, RMO-Clinical tutor, Dept of Obst-Gyne and Dr Chandrachur Konar, MBBS, deserve special appreciation for their sincere help throughout.

I am extremely grateful to Mrs Madhusri Konar, MA, BEd, for all her insightful secretarial accomplishments in support of the book through six editions.

Lastly, I am grateful to all who have taught me, most of all the patients and my beloved students.

I do hope this comprehensive textbook will continue to be an immense educational resource to the readers as ever. According to the author’s desire, the book is, therefore, dedicated once again to the *students of gynecology —past and present.*

### Preface to the Enlarged and Revised Reprint of Sixth Edition

To keep pace with the continued research, development of technology and knowledge, *Dutta’s Textbook of Gynecology* has come up with an intrim revision. Many chapters have been revised and updated depending upon the information available and the need of current clinical practice. Keeping in view the recent advances, a new chapter, Current Topics in Gynecology has been added dealing with stem cells and therapies. Contents and the index have been expanded for easy text reference. Information regarding different areas of examination situation (theory, viva-voce, clinical and practical examination including video-clips) have been provided through our electronic sources ([www.dcdutta.com](http://www.dcdutta.com)/[www.hiralalkonar.com](http://www.hiralalkonar.com)).

I gratefully acknowledge the help of Shri Jitendar P. Vij (Group Chairman), Mr Ankit Vij (Managing Director) and Dr Sakshi Arora (Chief Development Editor) along with entire team of M/s Jaypee Brothers Medical Publishers (P) Ltd, New Delhi, for their professional guidance, suggestion and support in bringing out the enlarged and revised reprint of sixth edition.

I do hope this comprehensive textbook of Dutta’s Gynaecology will continue to be an essential educational resource to the readers as ever.

# Preface to the first edition

Since my publication of Textbook of Obstetrics about 5 years back, I have been pressed hard by my esteemed colleagues and the students all over the country and abroad to write a textbook on gynecology of similar style to fill up the deficit. Initially, I was hesitant to proceed with the stupendous task but considering the fact that a compact, comprehensive and practical-oriented fundamental book in gynecology is not available to the undergraduates, I have decided to comply with their request.

The book has been written in a lucid language in author's own style. Extensive diagrams, photographs, and flow-charts (schemes) have been depicted throughout the text to give clarity of the subject. Due attention has been paid to project the fundamental principles and practice of gynecology. As such, more emphasis has been given on medical gynecology. But for that, indications, limitations, and principles of techniques of operations have received adequate consideration. The book is thus made invaluable not only to the medical students but also the practising physicians and students of nursing.

The author wishes to acknowledge gratitude to his esteemed colleague Dr N Chowdhury, MBBS, DGO, MO (Cal), for his contribution to the topic "Hormone Therapy in Gynecological practice". Dr Santosh Kr. Paul, MBBS, DGO, MO(Cal), Prof Dept of Obst and Gyne, NRS Medical College, Calcutta, deserves full appreciation for his contribution in a lucid way to the topic "Radiotherapy and Chemotherapy in Gynecology". The author has much pleasure in expressing grateful thanks to Dr B N Chakrabarty, MBBS, DGO, MO(Cal), FRCOG (Eng) and Dr K M Gun, MBBS, DGO, MO (Cal), FRCOG (Eng), FRCS (Edin), FACS (USA), for their valued suggestions as and when required and their contribution of photographs to enrich the text. I gratefully record my thanks to Dr Subir Kumar Dutta, MBBS, DCP, MD (Path & Bact), Prof, Dept of Pathology and Bacteriology, University College of Medicine, Calcutta, for the microphotographs depicted throughout the text. The author records his thanks to Dr SM Dali, Prof of Obst and Gyne and Dr Bhola Rijal, Associate Prof of Obst and Gyne of Teaching Hospital and Dr (Mrs) Dibya S Malia, Director, Maternity Hospital, Kathmandu, Nepal, for their contribution of few outstanding photographs to enrich the text.

The author expressed much pleasure all the time to the House Surgeons, Internees and students of Nilratan Sircar Medical College, Calcutta, for the help they have rendered in preparation of the final drafts of the manuscripts, check up of the proofs and compiling the index. Their help is invaluable and unforgettable and without which the book could never have been published.

The author wishes to thank Mr Biren Das for his exhaustive number of drawings and flow-charts which enrich the lucidity of the book. The author also thanks Mr Ranjit Sen for preparation of photographs (black and white) depicted throughout the text. The author has much pleasure in expressing his appreciation to Mr Bimal Bhattacharya, MSc, LLB(Cal), DSW, DHE, Lecturer, Health Education and Family Welfare, Post-partum Unit, NRS Medical College, Calcutta, for the patience shown in dealing with correction of manuscripts and proofs.

In preparing the textbook, the author has utilized the knowledge of number of stalwarts in his profession and consulted many books and publications. The author wishes to express his appreciation and gratitude to all of them including the related authors and publishers.

The author still confesses that as a teacher he has learnt a lot from the students and more so while writing this book and as such he could not think to dedicate the book to anyone else than the *students of gynecology, past and present.*


**DC DUTTA**

# Guide to use the special symbols

(1) Ask the author = [www.dcdutta.com](http://www.dcdutta.com)



(2) More information = [www.dcdutta.com](http://www.dcdutta.com)



# Contents

PREFACE.....	vii–ix	
<b>Chapter 1</b>	<b>Anatomy of the Female Pelvic Organs</b>	<b>1–25</b>
External Genitalia.....	1	
Internal Genitalia.....	3	
Female Urethra.....	13	
Urinary Bladder.....	14	
Pelvic Ureter.....	15	
Rectum and Anal Canal.....	16	
Pelvic Muscles, Pelvic Floor.....	17	
Pelvic Fascia, Cellular Tissue, Ligaments.....	21	
Applied Anatomy.....	24	
<b>Chapter 2</b>	<b>Blood Vessels, Lymphatic Drainage and Innervation of Pelvic Organs</b>	<b>26–33</b>
Pelvic Blood Vessels.....	26	
Pelvic Lymphatics.....	28	
Pelvic Nerves.....	31	
<b>Chapter 3</b>	<b>Development of Genital Organs and Gonads</b>	<b>34–40</b>
External Genital Organs.....	34	
Internal Genital Organs.....	35	
Gonads.....	37	
<b>Chapter 4</b>	<b>Congenital Malformation of Female Genital Organs</b>	<b>41–48</b>
<b>Chapter 5</b>	<b>Puberty Normal and Abnormal</b>	<b>49–56</b>
<b>Chapter 6</b>	<b>Menopause</b>	<b>57–65</b>
<b>Chapter 7</b>	<b>Neuroendocrinology in Relation to Reproduction — Dr B N Chakravorty</b>	<b>66–81</b>
<b>Chapter 8</b>	<b>Menstruation — Dr B N Chakravorty</b>	<b>82–98</b>
<b>Chapter 9</b>	<b>Examination of a Gynecological Patient</b>	<b>99–125</b>
History.....	99	
Examination.....	100	
Diagnostic Procedures.....	108–123	
Exfoliative Cytology.....	110	

	Creviceal Mucus .....	114
	Colposcopy.....	115
	Imaging Techniques in Gynecology.....	116
	Ultrasound–113; Computed Tomography–114; Magnetic Resonance Imaging–114; Positron Emission Tomography–115	
	Endometrial Sampling .....	120
	Culdocentesis .....	120
	Endoscopy in Gynecology .....	121
	Laser in Gynecology .....	123
<b>Chapter 10</b>	<b>Pelvic Infection</b>	<b>126–145</b>
	Defence of the Genital Tract .....	126
	Acute Pelvic Infection .....	127
	Chronic Pelvic Infection.....	136
	Genital Tuberculosis.....	137
<b>Chapter 11</b>	<b>Sexually Transmitted Infections</b>	<b>146–159</b>
<b>Chapter 12</b>	<b>Infections of the Individual Pelvic Organs</b>	<b>160–177</b>
	Vulva .....	160
	Bartholin's Gland .....	161
	Vagina .....	163
	Cervix.....	167
	Endometrium.....	168
	Fallopian Tube .....	169
	Ovary.....	173
	Parametrium.....	173
	Pelvic Abscess.....	175
<b>Chapter 13</b>	<b>Dysmenorrhea and Other Disorders of Menstrual Cycles</b>	<b>178–184</b>
	Dysmenorrhea.....	178
	Premenstrual Syndrome .....	182
<b>Chapter 14</b>	<b>Abnormal Uterine Bleeding</b>	<b>185–197</b>
	Menorrhagia.....	185
	Dysfunctional Uterine Bleeding .....	187
<b>Chapter 15</b>	<b>Displacement of the Uterus</b>	<b>198–226</b>
	Retroversion .....	198
	Pelvic Organ Prolapse .....	201
	Chronic Inversion .....	223

<b>Chapter 16</b>	<b>Infertility — Dr B N Chakravorty</b>	<b>227–258</b>
	Causes .....	227
	Investigations .....	231
	Treatment .....	241
	Assisted Reproductive Techniques .....	251
<b>Chapter 17</b>	<b>Benign Lesions of the Vulva and Vagina</b>	<b>259–266</b>
	Vulval Epithelial Disorders .....	259
	Vulval Ulcers .....	262
	Benign Tumors .....	264
	Vaginal Cysts .....	264
	Vulval Pain .....	264
<b>Chapter 18</b>	<b>Benign Lesions of the Cervix</b>	<b>267–271</b>
<b>Chapter 19</b>	<b>Benign Lesions of the Uterus</b>	<b>272–288</b>
	Fibroid .....	272
	Polyps .....	285
<b>Chapter 20</b>	<b>Benign Lesions of the Ovary</b>	<b>289–303</b>
	Non-neoplastic Enlargement .....	289
	Benign Ovarian Neoplasm .....	290
<b>Chapter 21</b>	<b>Endometriosis and Adenomyosis</b>	<b>304–317</b>
	Endometriosis .....	304
	Adenomyosis .....	314
	Stromal Endometriosis .....	316
<b>Chapter 22</b>	<b>Premalignant Lesions</b>	<b>318–332</b>
	Vulva .....	318
	Vagina .....	319
	Cervix .....	320
	Endometrium .....	329
<b>Chapter 23</b>	<b>Genital Malignancy</b>	<b>333–392</b>
	Vulval .....	333
	Bartholin's Gland .....	337
	Vaginal .....	337
	Endometrial .....	354
	Gestational Trophoblastic Disease .....	361

	Sarcoma Uterus.....	367
	Fallopian Tube .....	369
	Ovarian .....	370
<b>Chapter 24</b>	<b>Urinary Problems in Gynecology</b>	<b>393–416</b>
	Anatomy of Vesico-urethral Unit .....	393
	Genuine Stress Incontinence .....	398
	Urge Incontinence .....	405
	Painful Bladder Syndrome .....	408
	Overflow Incontinence .....	409
	Voiding Disorder .....	409
	Retention of Urine .....	409
	Urinary Tract Infections.....	410
	Dysuria.....	413
	Urethral Caruncle.....	413
<b>Chapter 25</b>	<b>Genital Fistulae</b>	<b>417–429</b>
	Genitourinary .....	417
	Ureteric Injury .....	425
	Rectovaginal .....	427
<b>Chapter 26</b>	<b>Genital Tract Injuries</b>	<b>430–438</b>
	Old Complete Perineal Tear .....	430
	Rape Victims .....	434
<b>Chapter 27</b>	<b>Intersex — Dr B N Chakravorty</b>	<b>439–448</b>
	Embryological Considerations.....	439
	Female Intersex .....	440
	Male Intersex.....	443
	Management .....	445
<b>Chapter 28</b>	<b>Amenorrhea — Dr K M Gun</b>	<b>449–474</b>
	Physiological .....	449
	Primary .....	450
	Secondary .....	457
<b>Chapter 29</b>	<b>Contraception</b>	<b>475–504</b>
	Methods .....	475
	Temporary.....	476
	Barrier Methods .....	476



	IUCD .....	479
	Steroidal .....	485
	Emergency .....	492
	Sterilisation .....	494
<b>Chapter 30</b>	<b>Radiotherapy, Chemotherapy, Immunotherapy and Genethery in Gynecology</b>	<b>505–523</b>
	Radiotherapy .....	505
	Chemotherapy .....	511
	Immunotherapy .....	519
	Gene Therapy .....	520
	Tumor Markers .....	521
<b>Chapter 31</b>	<b>Hormones in Gynecological Practice — Dr B N Chakravorty</b>	<b>524–541</b>
<b>Chapter 32</b>	<b>Gynecologic Problems from Birth to Adolescence</b>	<b>542–550</b>
	Neonates, Toddlers and Infants .....	542
	Premenarchal .....	544
	Postmenarchal to Adolescence .....	546
<b>Chapter 33</b>	<b>Special Topics</b>	<b>551–579</b>
	Abnormal Vaginal Discharge .....	551
	Pruritus Vulvae .....	553
	Pelvic Pain .....	555
	Postmenopausal Bleeding .....	559
	Low Backache .....	561
	Breast in Gynecology .....	561
	Breast Carcinoma .....	564
	Psychosexual Problems .....	567
	Vaginismus .....	567
	Dyspareunia .....	568
	Abdomino-pelvic Lump .....	568
	Adnexal Mass .....	570
	Hirsutism .....	571
	Galactorrhea .....	576
<b>Chapter 34</b>	<b>Operative Gynecology</b>	<b>580–610</b>
	Preoperative Preparations .....	580
	Day Surgery .....	582
	Postoperative Care .....	583
	Gynecological Operations .....	585

<b>Chapter 35</b>	<b>Endoscopic Surgery in Gynecology</b> (Syn: Minimally invasive surgery, Minimal access surgery)	<b>611–624</b>
	Laparoscopy .....	611
	Hysteroscopy .....	619
<b>Chapter 36</b>	<b>Current Topics in Gynecology</b>	<b>625–626</b>
	Stem Cells and Therapies in Gynecology .....	625
<b>Chapter 37</b>	<b>Practical Gynecology</b>	<b>627–666</b>
	Instruments .....	627
	Sutures .....	644
	Specimens .....	645
	Imaging Studies (plates): Skiagraphy, Ultrasonography, Computed Tomography (CT), and Magnetic Resonance Imaging (MRI) .....	657
<b>Index</b> .....		<b>667–686</b>

# Anatomy of the Female Pelvic Organs

## EXTERNAL GENITALIA

(SYN: VULVA, PUDENDUM)

The vulva includes mons veneris, labia majora, labia minora, clitoris, vestibule and conventionally the perineum. These are all visible on external examination. It is, therefore, bounded anteriorly by the mons veneris, laterally by the labia majora and posteriorly by the perineum (Fig. 1.1).

### MONS VENERIS (MONS PUBIS)

It is the pad of subcutaneous adipose connective tissue lying in front of the pubis and, in the adult female, is covered by hair.

### LABIA MAJORA

The vulva is bounded on each side by the elevation of skin and subcutaneous tissue, which form the labia majora. They are continuous where they join medially to form the posterior commissure in front of the anus. The inner surface of the labia majora are hairless. The labia majora are covered with squamous epithelium and contain sebaceous glands, sweat glands and hair follicles. Beneath the skin, there are dense connective tissue and adipose tissue. The adipose tissue is richly supplied by venous plexus, which may produce hematoma, if injured during childbirth. **The labia majora are homologous with the scrotum in the male.** The round ligaments terminate at its anterior third.

### LABIA MINORA

Labia minora are two thick folds of skin, devoid of fat, on either side just within the labia majora. Except in the parous women, they are only exposed when the labia majora are separated. Anteriorly, they

are divided to enclose the clitoris and unite with each other in front and behind the clitoris to form the prepuce and frenulum, respectively. The lower portion of the labia minora fuses across the midline to form a fold of skin known as fourchette. It is usually injured during childbirth. **Between the fourchette and the vaginal orifice is the fossa navicularis. The labia minora do not contain hair follicle.** The folds contain connective tissues, numerous sebaceous glands, erectile muscle fibers and numerous vessels and nerve endings. **It is homologous to the ventral aspect of the penis.**

### CLITORIS

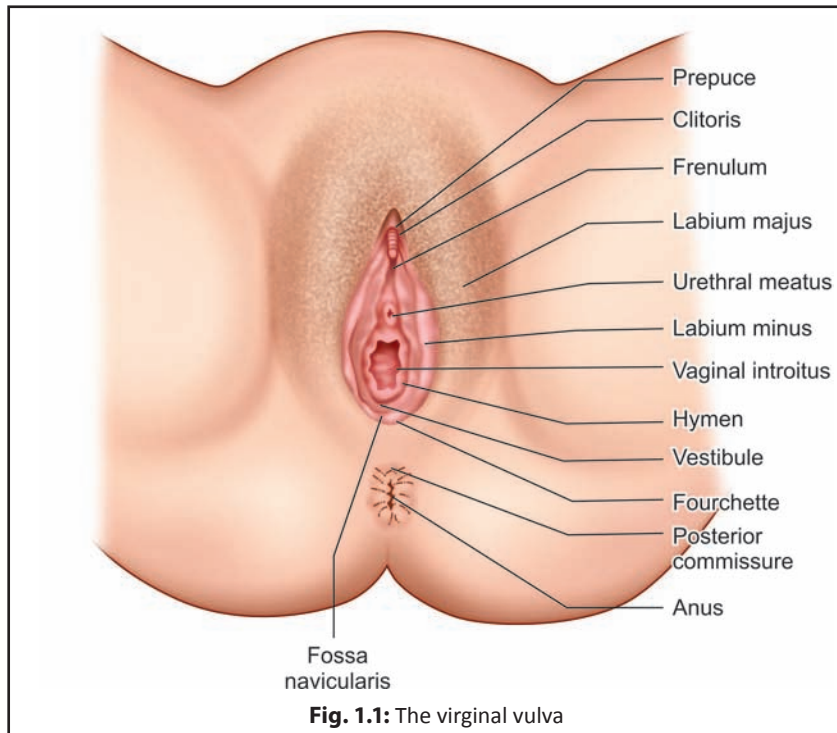
Clitoris is a small cylindrical erectile body, measuring about 2.5 cm situated in the most anterior part of the vulva. It consists of glans, a body and two crura. The glans is covered by squamous epithelium and is richly supplied with nerves. The vessels of the clitoris are connected with the vestibular bulb and are liable to be injured during childbirth. **Clitoris is an analogue to the penis in the male,** but it differs basically in being entirely separate from the urethra. It is attached to the undersurface of the symphysis pubis by the suspensory ligament.

### VESTIBULE

Vestibule is a triangular space bounded anteriorly by the clitoris, posteriorly by the fourchette and on either side by labium minus. **There are four openings into the vestibule (Fig. 1.1).**

### URETHRAL OPENING

The opening is situated in the midline, just in front of the vaginal orifice about 1–1.5 cm below the



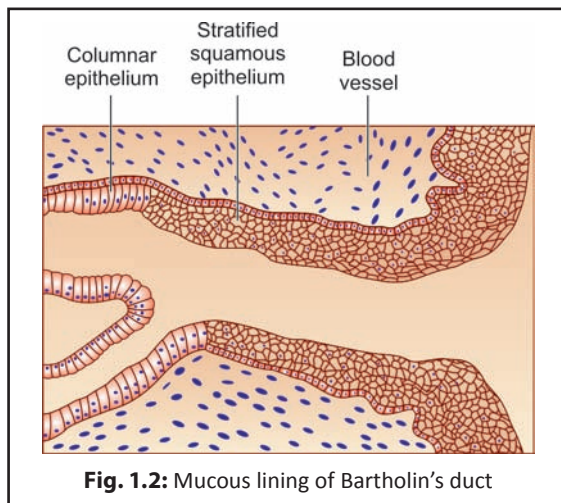
**Fig. 1.1:** The virginal vulva

pubic arch. The paraurethral ducts open either on the posterior wall of the urethral orifice or directly into the vestibule.

### VAGINAL ORIFICE AND HYMEN

The vaginal orifice lies in the posterior end of the vestibule and is of varying size and shape. In

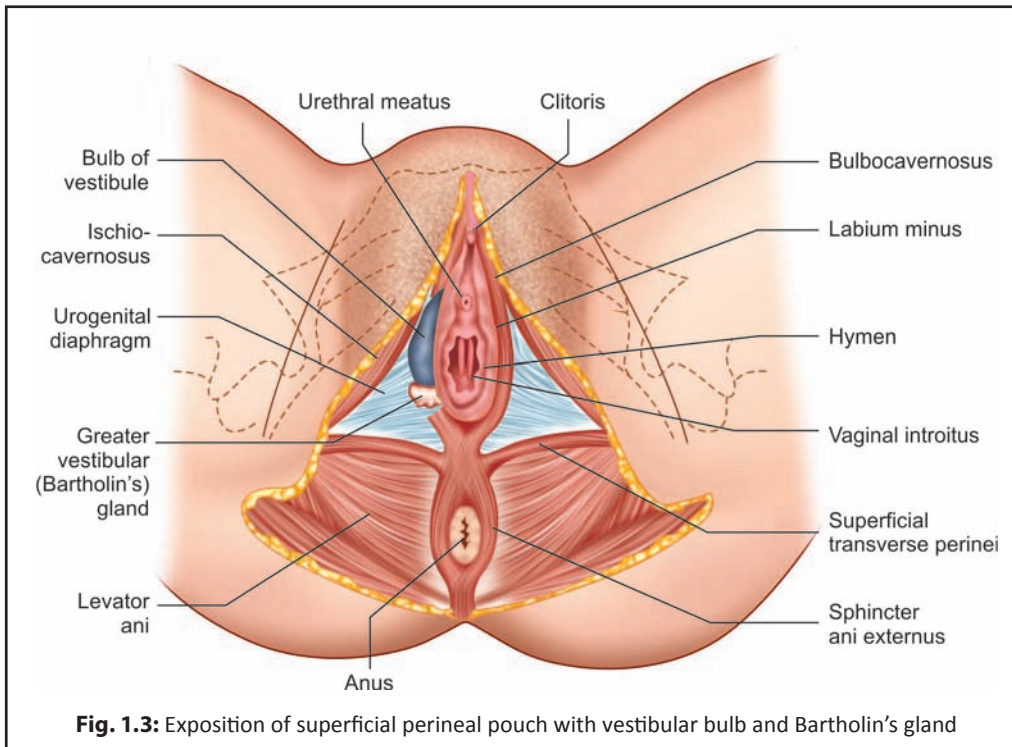
virgins and nulliparae, the opening is closed by the labia minora but in parous, it may be exposed. It is incompletely closed by a septum of mucous membrane, called hymen. The membrane varies in shape but is usually circular or crescentic in virgins. The hymen is usually ruptured at the consummation of marriage. During childbirth, the hymen is extremely lacerated and is later represented by cicatrized nodules of varying sizes, called the **carunculae myrtiformes**. On both sides, it is lined by stratified squamous epithelium.



**Fig. 1.2:** Mucous lining of Bartholin's duct

### BARTHOLIN'S GLAND

The Bartholin's glands are situated in the superficial perineal pouch, close to the posterior end of the vestibular bulb. They are pea-sized, of about 0.5 cm and yellowish-white in color. During sexual excitement, it secretes abundant alkaline mucus which helps in lubrication. Contraction of bulbocavernosus helps squeeze the secretion. The glands are compound racemose variety and are lined by columnar epithelium. **Each gland has got a duct which measures about 2 cm** and opens into



the vestibule, outside the hymen at the junction of the anterior two-third and posterior one-third in the groove between the hymen and the labium minus. **The duct is lined by columnar epithelium but near its opening by stratified squamous epithelium** (Fig. 1.2). **The Bartholin's gland corresponds to the bulbourethral gland of male.**

**Vestibular Bulbs:** These are bilateral elongated masses of erectile tissues situated beneath the mucous membrane of the vestibule. Each bulb lies on either side of the vaginal orifice in front of the Bartholin's gland and is incorporated within the bulbocavernosus muscles. **They are homologous to the single bulb of the penis and corpus spongiosum in the male.** They are likely to be injured during childbirth with brisk hemorrhage (Fig. 1.3).

### PERINEUM

The details of the anatomy of perineum are described later in this chapter (see p. 20).

### BLOOD SUPPLY OF THE VULVA

**Arteries:** (a) Branches of internal pudendal artery—the chief being labial, transverse perineal, artery to

the vestibular bulb and deep and dorsal arteries to the clitoris. (b) Branches of femoral artery—superficial and deep pudendal.

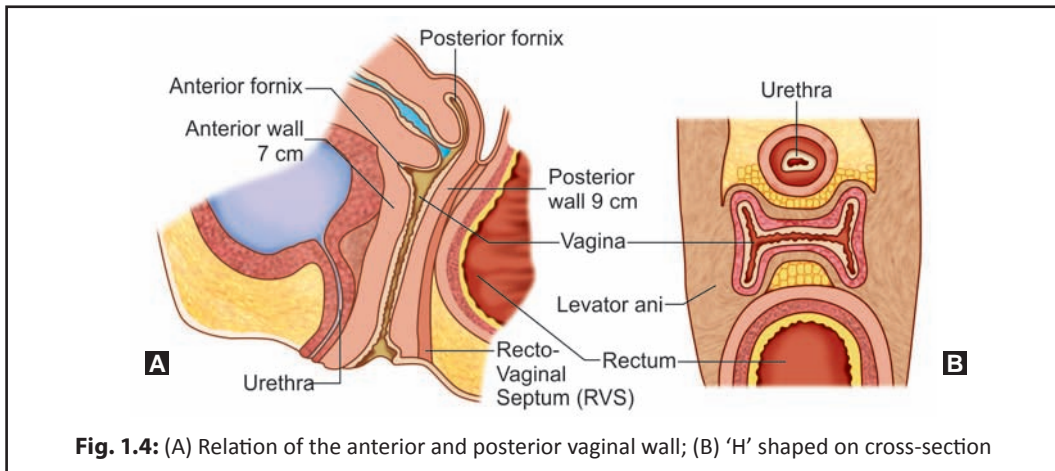
**Veins:** The veins form plexuses and drain into—(a) internal pudendal vein, (b) vesical or vaginal venous plexus, and (c) long saphenous vein. Varicosities during pregnancy are not uncommon and may rupture spontaneously causing visible bleeding or hematoma formation.

### NERVE SUPPLY OF THE VULVA

The supply is through bilateral spinal somatic nerves. Anterosuperior part is supplied by the cutaneous branches from the ilioinguinal and genital branch of genitofemoral nerve ( $L_1$  and  $L_2$ ) and the posteroinferior part by the pudendal branches from the posterior cutaneous nerve of thigh ( $S_{2,3,4}$ ). Between these two groups, the vulva is supplied by the labial and perineal branches of the pudendal nerve ( $S_{2,3,4}$ ).

### INTERNAL GENITAL ORGANS

The internal genital organs in female include vagina, uterus, fallopian tubes, and the ovaries. These organs



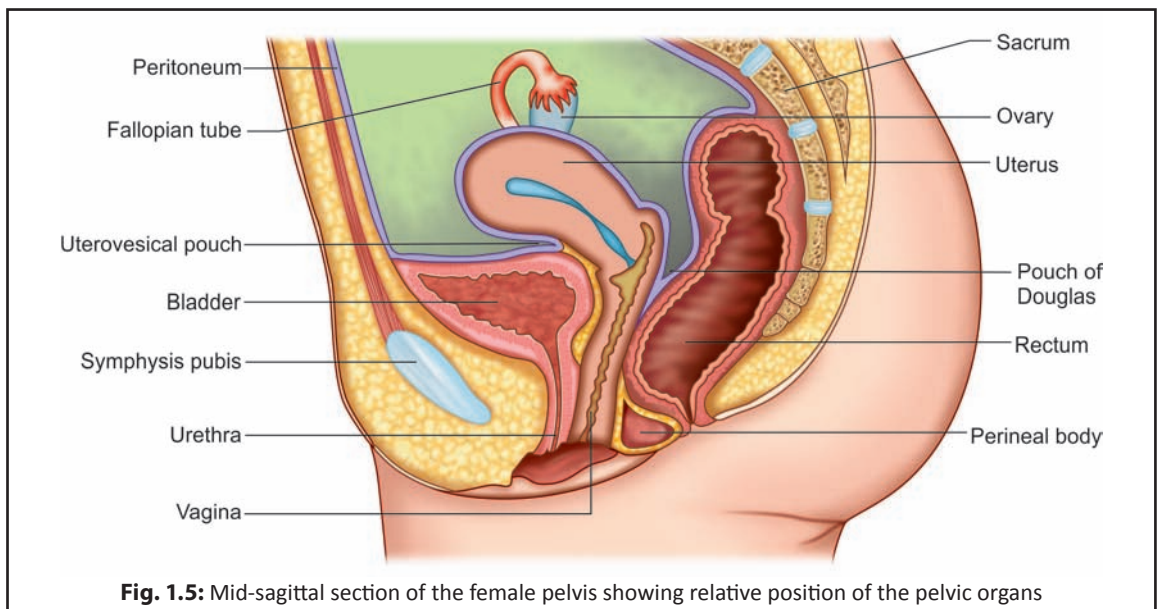
are placed internally and require special instruments for inspection.

## VAGINA

The vagina is a fibromusculomembranous sheath communicating the uterine cavity with the exterior at the vulva. It constitutes the excretory channel for the uterine secretion and menstrual blood. It is the organ of copulation and forms the birth canal of parturition. The canal is directed upwards and backwards forming an angle of  $45^\circ$  with the horizontal in erect posture.

The long axis of the vagina almost lies parallel to the plane of the pelvic inlet and at right angles to that of the uterus. The diameter of the canal is about 2.5 cm, being widest in the upper part and narrowest at its introitus. It has got enough power of distensibility as evident during childbirth.

**Walls:** Vagina has got an anterior, a posterior, and two lateral walls. The anterior and posterior walls are apposed together but the lateral walls are comparatively stiffer especially at its middle, as such it looks 'H' shaped on transverse section. **The length**



of the anterior wall is about 7 cm and that of the posterior wall is about 9 cm (Fig. 1.4). The upper end of vaginal is above the pelvic floor.

### Fornices

The fornices are the clefts formed at the top of vagina (vault) due to the projection of the uterine cervix through the anterior vaginal wall, where it is blended inseparably with its wall. There are four fornices—one anterior, one posterior, and two lateral; the posterior one being deeper and the anterior, most shallow one.

### Relations

#### Anterior

The upper one-third is related with base of the bladder and the lower two-thirds are with the urethra, the lower half of which is firmly embedded with its wall (Fig. 1.4).

#### Posterior

The upper one-third is related with the pouch of Douglas, the middle-third with the anterior rectal wall separated by rectovaginal septum, and the lower-third is separated from the anal canal by the perineal body (Fig. 1.5).

#### Lateral walls

The upper one-third is related with the pelvic cellular tissue at the base of broad ligament in which the ureter and the uterine artery lie approximately 2 cm

from the lateral fornices. The middle-third is blended with the levator ani and the lower-third is related with the bulbocavernosus muscles, vestibular bulbs, and Bartholin's glands (Fig. 1.6).

### Structures

#### Layers from within outwards are

- (1) mucous coat which is lined by stratified squamous epithelium without any secreting glands;
- (2) submucous layer of loose areolar vascular tissues;
- (3) muscular layer consisting of indistinct inner circular and outer longitudinal and;
- (4) fibrous coat derived from the endopelvic fascia which is tough and highly vascular (Fig. 1.7).

### Epithelium

The vaginal epithelium is under the action of sex hormones (Fig. 1.8). **At birth and up to 10–14 days**, the epithelium is stratified squamous under the influence of maternal estrogen circulating in the newborn. Thereafter, up to prepuberty and in postmenopause, the epithelium becomes thin, consisting of few layers only.

**From puberty till menopause**, the vaginal epithelium is stratified squamous and devoid of any gland. Three distinct layers are defined—basal cells, intermediate cells, and superficial cornified cells. The intermediate and superficial cells contain glycogen

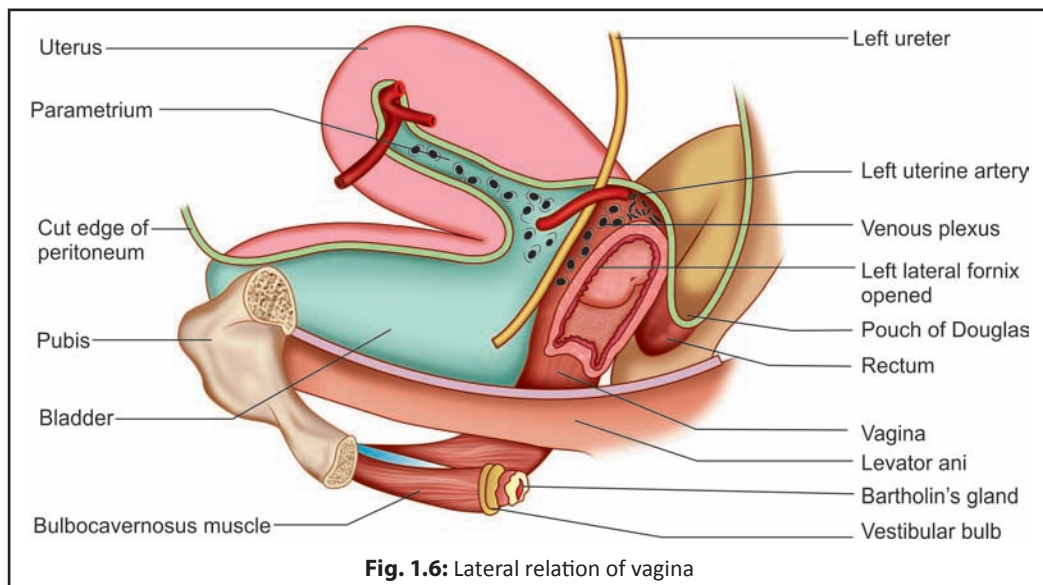
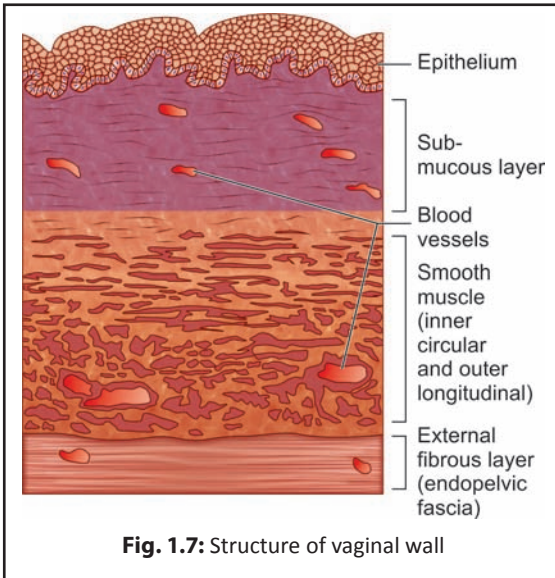


Fig. 1.6: Lateral relation of vagina



**Fig. 1.7:** Structure of vaginal wall

under the influence of estrogen. These cells become continuous with those covering the vaginal portion of the cervix and extend up to the squamocolumnar junction at the external os. The superficial cells exfoliate constantly and more so in inflammatory or neoplastic condition. Replacement of the superficial cells occurs from the basal cells. When the epithelium is exposed to the dry external atmosphere, keratinization occurs. **Unlike skin, it does not contain hair follicle, sweat, and sebaceous gland.**

**Secretion:** The vaginal secretion is very small in amount sufficient to make the surface moist. Normally, it may be little excess in mid-menstrual or just prior to menstruation, during pregnancy and during sexual excitement. **The secretion is mainly derived from the glands of the cervix, uterus, transudation of the vaginal epithelium, and Bartholin's glands (during sexual excitement).**

	ESTROGEN	EPITHELIUM	GLYCOGEN	pH	FLORA
BIRTH TO 2 WEEKS	+		+	ACID 4 - 5	STERILE ↓ DODERLEIN'S BACILLI SECRETION ABUNDANT
2 WEEKS TO PREPUBERTY	-		-	ALKALINE > 7	DODERLEIN'S BACILLI ABSENT  SECRETION SCANT
PREPUBERTY	APPEARS		- → +	ALKALINE ↓ ACID	SPARSE, COCCAL ↓ RICH BACILLARY
REPRODUCTIVE PERIOD	++		+	ACID 4 - 5	DODERLEIN'S BACILLI APPEAR  SECRETION ABUNDANT
POST MENOPAUSE	+ → -		-	NEUTRAL OR ALKALINE 6 - > 7	DODERLEIN'S BACILLI ABSENT  SECRETION SCANT

**Fig. 1.8:** Estrogenic effect on vaginal epithelium and flora at different ages



The pH is acidic and varies during different phases of life and menstrual cycle. Conversion of glycogen in the exfoliated squamous cells to lactic acid by the **Doderlein's bacilli** is dependent on estrogen. As such, the pH is more towards acidic during child-bearing period and ranges **between 4 and 5.5 with average of 4.5**. The pH is highest in upper vagina because of contaminated cervical secretion (alkaline). The **vaginal secretion consists** of tissue fluid, epithelial debris, some leukocytes (never contains more than an occasional pus cell), electrolytes, proteins, and lactic acid (in a concentration of 0.75%). Apart from Doderlein's bacilli, it contains many a pathogenic organism including *Cl. welchii*. **The glycogen content is highest** in the vaginal fornix to the extent of 2.5–3 mg% and is lowest in the lower-third being 0.6–0.9 mg%.

**Doderlein's bacillus:** It is a rod-shaped gram-positive bacillus which grows anaerobically on acid media. It appears in the vagina 3–4 days after birth and disappears after 10–14 days. It appears again at puberty and disappears after menopause. It probably comes from the intestine. Its presence is dependent to estrogen, and its function is to convert the glycogen present in the vaginal mucosa into lactic acid so that the vaginal pH is maintained towards acidic side. This acid pH prevents growth of the other pathogenic organisms (Fig. 1.8).

### Blood Supply

**The arteries involved are:** (1) cervicovaginal branch of the uterine artery, (2) vaginal artery—a branch of anterior division of internal iliac or in common origin with the uterine, (3) middle rectal, and (4) internal pudendal. These anastomose with one another and form two azygos arteries—anterior and posterior.

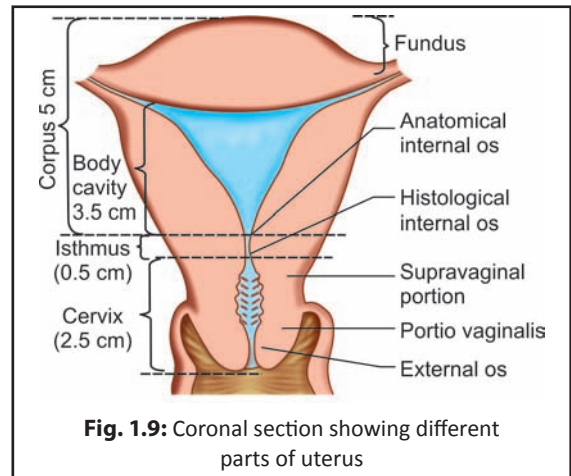
Veins drain into internal iliac and internal pudendal veins.

**Nerve Supply:** The vagina is supplied by sympathetic and parasympathetic from the pelvic plexus. The lower part is supplied by the pudendal nerve.

## THE UTERUS

The uterus is a hollow pyriform muscular organ situated in the pelvis between the bladder in front and the rectum behind (Fig. 1.5).

**Position:** Its normal position is one of the **anteversion** and **anteflexion**. The uterus usually inclines to the



**Fig. 1.9:** Coronal section showing different parts of uterus

right (dextrorotation) so that the **cervix is directed to the left (levorotation)** and comes in close relation with the left ureter.

**Measurements and parts:** The uterus measures about 8 cm long, 5 cm wide at the fundus and its walls are about 1.25 cm thick. Its weight varies from 50–80 g. It has got the following parts (Fig. 1.9).

### • Body or corpus • Isthmus • Cervix

**Body or corpus:** The body is further divided into **fundus**—the part which lies above the openings of the uterine tubes. The **body** properly is triangular and lies between the openings of the tubes and the isthmus. The superolateral angles of the body of the uterus project outwards from the junction of the fundus and body and are called the cornua of the uterus. The uterine tube, round ligament, and ligament of the ovary are attached to each cornu.

**Isthmus:** The isthmus is a constricted part measuring about 0.5 cm situated between the body and the cervix. It is limited above by the anatomical internal os and below by the histological internal os (Aschoff). Some consider isthmus as a part of the lower portion of the body of the uterus.

**Cervix:** The cervix is the lowermost part of the uterus. It extends from the histological internal os and ends at external os which opens into the vagina after perforating the anterior vaginal wall. It is almost cylindrical in shape and measures about 2.5 cm in length and diameter. It is divided into a supravaginal part—the part lying above the vagina and a vaginal

part which lies within the vagina, each measuring 1.25 cm. In **nulliparous**, the vaginal part of the cervix is conical with the external os looking circular, whereas in **parous**, it is cylindrical with the external os having bilateral slits. The slit is due to invariable tear of the circular muscles surrounding the external os and gives rise to anterior and posterior lips of the cervix.

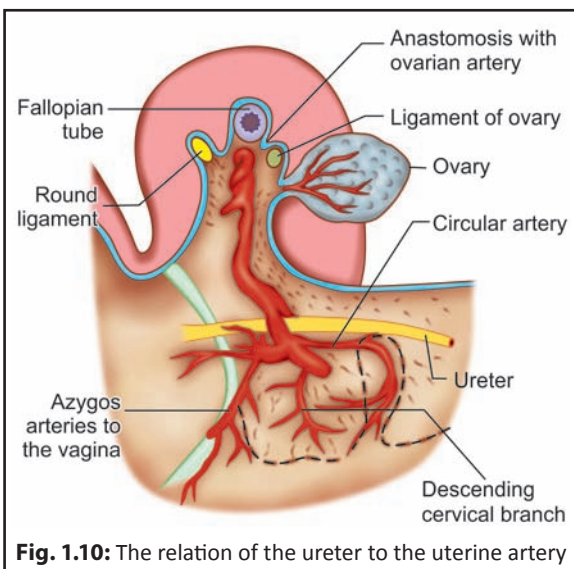
**Cavity:** The cavity of the uterine body is triangular on coronal section with the base above and the apex below. It measures about 3.5 cm. There is no cavity in the fundus. The cervical canal is fusiform and measures about 2.5 cm. Thus, the normal length of the uterine cavity including the cervical canal is usually 6–7 cm (Fig. 1.9).

### Relations

**Anteriorly:** Above the internal os, the body forms the posterior wall of the uterovesical pouch. Below the internal os, it is separated from the base of the bladder by loose areolar tissue.

**Posteriorly:** It is covered by peritoneum and forms the anterior wall of the pouch of Douglas containing coils of intestine.

**Laterally:** The double folds of peritoneum of the broad ligament are attached laterally between which the uterine artery ascends up. Attachment of the Mackenrodt's ligament extends from the internal os



**Fig. 1.10:** The relation of the ureter to the uterine artery

down to the supravaginal cervix and lateral vaginal wall. About 1.5 cm away at the level of internal os, a little nearer on the left side is the crossing of the uterine artery and the ureter. **The uterine artery crosses from above and in front of the ureter**, soon before the ureter enters the ureteric tunnel (Fig. 1.10).

### Structures

**Body—**The wall consists of 3 layers from outside inwards:

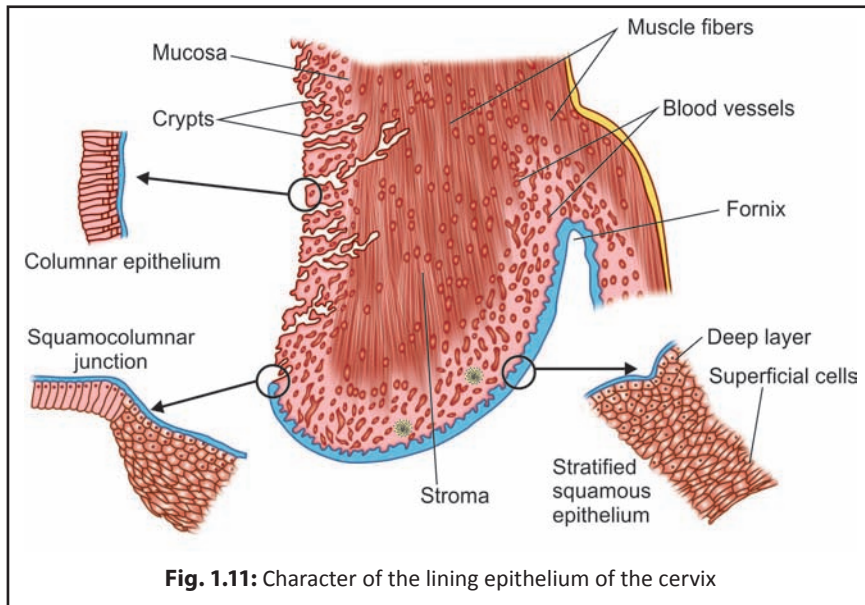
- ◆ **Perimetrium**—It is the serous coat which invests the entire organ except on the lateral borders. The peritoneum is intimately adherent to the underlying muscles.
- ◆ **Myometrium**—It consists of thick bundles of smooth muscle fibers held by connective tissues and are arranged in various directions. During pregnancy, however, three distinct layers can be identified—outer longitudinal, middle interlacing and the inner circular.
- ◆ **Endometrium**—The mucous lining of the cavity is called endometrium. As there is no submucous layer, the endometrium is directly apposed to the muscle coat. It consists of lamina propria and surface epithelium. The surface epithelium is a single layer of ciliated columnar epithelium. The lamina propria contains stromal cells, endometrial glands, vessels and nerves. The glands are simple tubular and lined by mucus secreting non-ciliated columnar epithelium which penetrate the stroma and sometimes even enter the muscle coat. All the components are changed during menstrual cycles (see Ch. 8). The endometrium is changed to decidua during pregnancy.

**CERVIX:** The cervix is composed mainly of fibrous connective tissues. The smooth muscle fibers average 10–15%. Only the posterior surface has got peritoneal coat (see Fig. 1.5).

### Epithelial Lining of the cervix

#### Endocervical canal and glands

There is a median ridge on both the anterior and posterior surface of the canal from which transverse folds radiate. This arrangement is called arbor vitae uteri. The canal is lined by single layer of tall columnar epithelium with basal nuclei. Those placed



**Fig. 1.11:** Character of the lining epithelium of the cervix

over the top of the folds are ciliated. There are patches of cubical basal or reserve cells underneath the columnar epithelium. These cells may undergo squamous metaplasia or may replace the superficial cells (see p. 321).

The glands which dip into the stroma are of complex racemose type and are lined by secretory columnar epithelium. There is no stroma unlike the corpus and the lining epithelium rests on a thin basement membrane. The change in the epithelium and the glands during menstrual cycle and pregnancy are not so much as those in the endometrium.

### Portio vaginalis

It is covered by stratified squamous epithelium and extends right up to the external os where there is abrupt change to columnar type.

**The transitional zone (transformation zone)** may be of 1–10 mm width with variable histological features. The zone consists of endocervical stroma and glands covered by squamous epithelium. **The zone is not static but changes with hormone level of estrogen.** The site is constantly irritated not only by hormones but also by infection and trauma. Thus, **there is more chance of severe dysplasia, carcinoma in situ or even invasive carcinoma at this zone (Fig. 1.11)** (see p. 322).

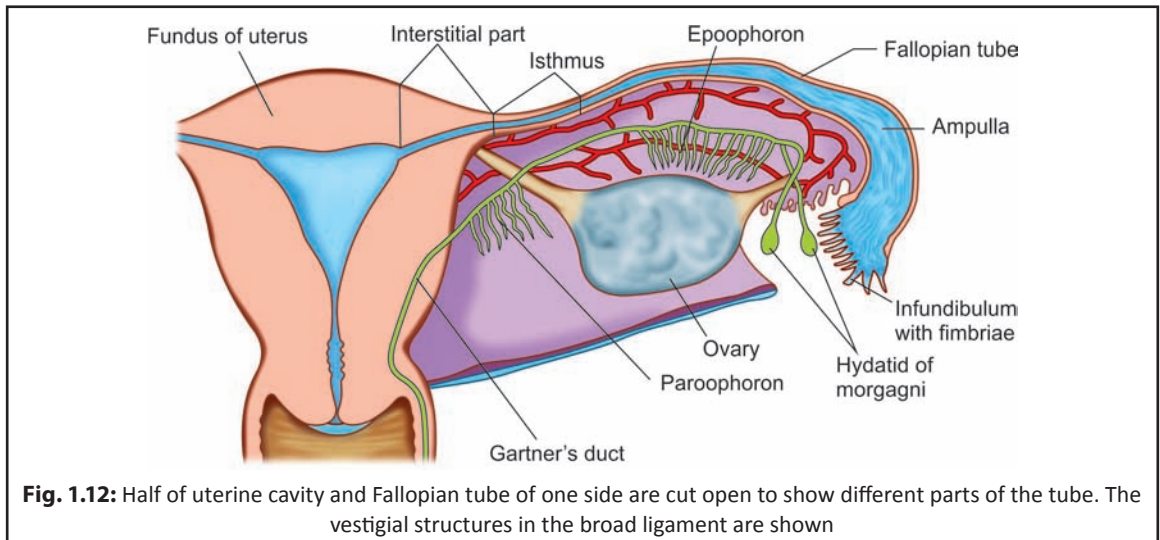
**Secretion:** The endometrial secretion is scanty and watery. The physical and chemical properties of the cervical secretion change with menstrual cycles and with pregnancy. The cervical glands secrete an alkaline mucus with **pH 7.8**. The mucus is rich in fructose, glycoprotein and mucopolysaccharides. It also contains sodium chloride. The fructose has got nutritive function to the spermatozoa. Under estrogenic stimulation, glycoprotein network is arranged parallel to each other thus facilitating sperm ascent. Progesterone produces interlacing bridges thereby preventing sperm penetration. Cervical mucus contributes significantly to the normal vaginal discharge. A part forms the mucus plug which functionally closes the cervical canal and has got bacteriolytic property.

### Pelvic peritoneum in relation to the uterus

This is described later in the chapter.

### Blood Supply

**Arterial supply:** The arterial supply is from the uterine artery—one on each side. The artery arises directly from the anterior division of the internal iliac or in common with superior vesical artery. The other sources are ovarian and vaginal arteries to which the uterine arteries anastomose. **The uterine artery crosses the ureter anteriorly about 1.5 cm away**



**Fig. 1.12:** Half of uterine cavity and Fallopian tube of one side are cut open to show different parts of the tube. The vestigial structures in the broad ligament are shown

at the level of internal os before it ascends up along the lateral border of the uterus in between the leaves of broad ligament. The internal supply of the uterus is shown in Figure 2.1.

**Veins:** The venous channels correspond to the arterial course and drain into internal iliac veins.

### Nerve Supply

The nerve supply of the uterus is derived principally from the sympathetic system and partly from the parasympathetic system. Sympathetic components are from T<sub>5</sub> and T<sub>6</sub> (motor) and T<sub>10</sub> to L<sub>1</sub> spinal segments (sensory). The somatic distribution of uterine pain is that area of the abdomen supplied by T<sub>10</sub> to L<sub>1</sub>. The parasympathetic system is represented on either side by the pelvic nerve which consists of both motor and sensory fibers from S<sub>2</sub>, S<sub>3</sub>, S<sub>4</sub> and ends in the ganglia of Frankenhauser which lies on either sides of the cervix.

**The cervix is insensitive to touch,** heat and also when it is grasped by any instrument. The uterus, too is insensitive to handling and even to incision over its wall.

### Changes of Uterus with Age

At birth, the uterus lies in the false pelvis; the cervix is much longer than the body. **In childhood,** the proportion is maintained but reduced to 2:1. **At puberty,** the body is growing faster under the action of ovarian steroids (estrogens) and the proportion is

reversed to 1:2 and following childbirth, it becomes even 1:3. **After menopause** the uterus atrophies; the overall length is reduced; the walls become thinner, less muscular but more fibrous (Fig. 5.1).

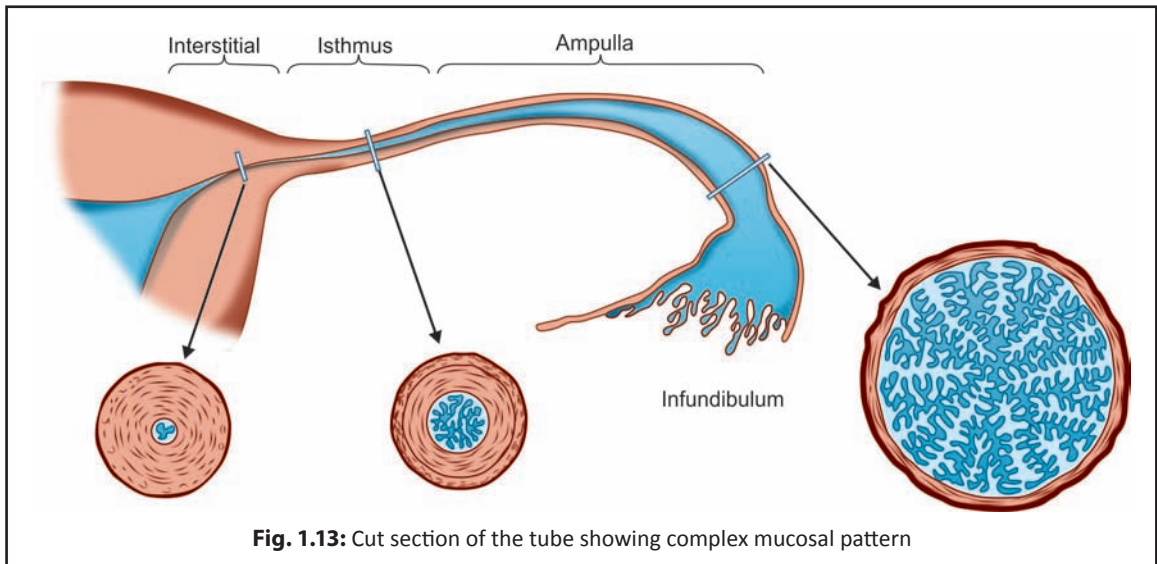
### Position of the Uterus

The normal position of the uterus is anteversion and anteflexion. **Anteversion relates** the long axis of the cervix to the long axis of vagina which is about 90°. **Anteflexion relates** the long axis of the body to the long axis of the cervix and is about 120°. In about 15–20%, normally the uterus remains in retroverted position. In erect posture, the internal os lies on the upper border of the symphysis pubis and the external os lies at the level of ischial spines.

### FALLOPIAN TUBE (SYN: UTERINE TUBE)

The uterine tubes are paired structures, measuring about 10 cm (4") and are situated in the medial three-fourth of the upper free margin of the broad ligaments. Each tube has got two openings, one communicating with the lateral angle of the uterine cavity, called uterine opening and measures 1 mm in diameter, the other is on the lateral end of the tube, called pelvic opening or abdominal ostium and measures about 2 mm in diameter (Fig. 1.12).

**Parts:** There are four parts, from medial to lateral, they are—(1) intramural or interstitial lying in the uterine wall and measures 1.25 cm (1/2") in length and 1 mm in diameter; (2) isthmus almost straight and



**Fig. 1.13:** Cut section of the tube showing complex mucosal pattern

measures about 2.5 cm (1") in length and 2.5 mm in diameter; (3) ampulla—tortuous part and measures about 5 cm (2") in length which ends in wide; (4) infundibulum measuring about 1.25 cm (1/2") long with a maximum diameter of 6 mm. The abdominal ostium is surrounded by a number of radiating fimbriae, one of these is longer than the rest and is attached to the outer pole of the ovary called ovarian fimbria (Fig. 1.13).

**Structures—It consists of 3 layers:**

1. *Serous*—consists of peritoneum on all sides except along the line of attachment of mesosalpinx.
2. *Muscular*—arranged in two layers—outer longitudinal and inner circular.
3. *Mucous membrane* is thrown into longitudinal folds. It is lined by columnar epithelium, partly ciliated, others secretory nonciliated and 'Peg cells'. The epithelium rests on delicate vascular reticulum of connective tissue. There is no submucous layer nor any glands. Changes occur in the tubal epithelium during menstrual cycle but are less pronounced and there is no shedding (Fig. 1.13).

**Functions:** The important functions of the tubes are—(1) transport of gametes, (2) to facilitate fertilization, and (3) survival of zygote through its secretion.

**Blood supply:** Arterial supply is from the uterine and ovarian. Venous drainage is through the pampiniform plexus into the ovarian veins.

**Nerve supply:** The nerve supply is derived from the uterine and ovarian nerves. The tube is very much sensitive to handling.

## THE OVARY

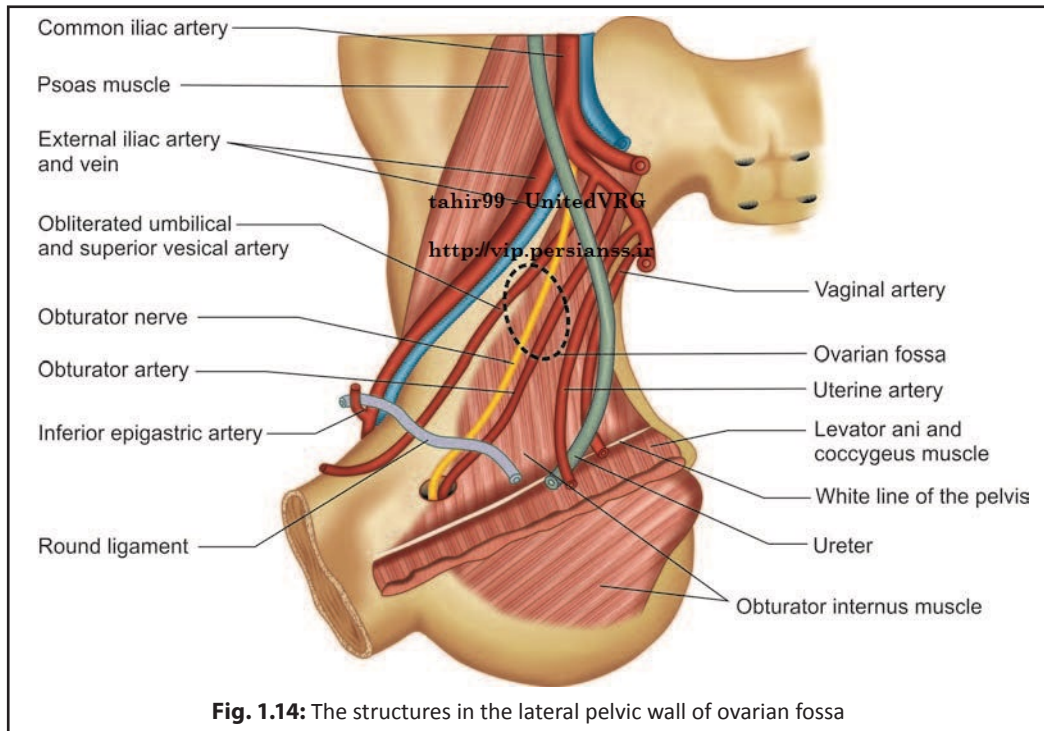
The ovaries are paired sex glands or gonads in female which **are concerned with:**

- i. Germ cell maturation, storage and its release.
- ii. Steroidogenesis.

Each gland is oval in shape and pinkish grey in color and the surface is scarred during reproductive period. It measures about 3 cm in length, 2 cm in breadth and 1 cm in thickness. Each ovary presents two ends—tubal and uterine, two borders—mesovarium and free posterior and two surfaces—medial and lateral.

The ovaries are intraperitoneal structures. In nulliparae, the ovary lies in the ovarian fossa on the lateral pelvic wall. **The ovary is attached** to the posterior layer of the broad ligament by the mesovarium, to the lateral pelvic wall by infundibulopelvic ligament and to the uterus by the ovarian ligament.

**Relations: Mesovarium or anterior border**—A fold of peritoneum from the posterior leaf of the broad ligament is attached to the anterior border through which the ovarian vessels and nerves enter the hilum of the gland. **Posterior border** is free and is related with tubal ampulla. It is separated by the peritoneum



**Fig. 1.14:** The structures in the lateral pelvic wall of ovarian fossa

from the ureter and the internal iliac artery. **Medial surface** is related to fimbrial part of the tube. **Lateral surface** is in contact with the **ovarian fossa** on the lateral pelvic wall.

**The ovarian fossa is related** superiorly to the external iliac vein, posteriorly to ureter and internal iliac vessels and laterally to the peritoneum separating the obturator vessels and nerves (Fig. 1.14).

**Structures:** The ovary is covered by a single layer of cubical cell known as germinal epithelium. It is a misnomer as germ cells are not derived from this layer. The substance of the gland consists of outer cortex and inner medulla (Fig. 1.15).

**Cortex:** It consists of stromal cells which are thickened beneath the germinal epithelium to form tunica albuginea. During reproductive period (i.e. from puberty to menopause), the cortex is studded with numerous follicular structures, called the functional units of the ovary in various phases of their development. These are related to sex hormone production and ovulation. **The structures include** primordial follicles, maturing follicles, Graafian

follicles and corpus luteum. Atresia of the structures results in formation of atretic follicles or corpus albicans (Fig. 1.15). The structural changes during ovular cycle are described in the Chapter 8 (see p. 84).

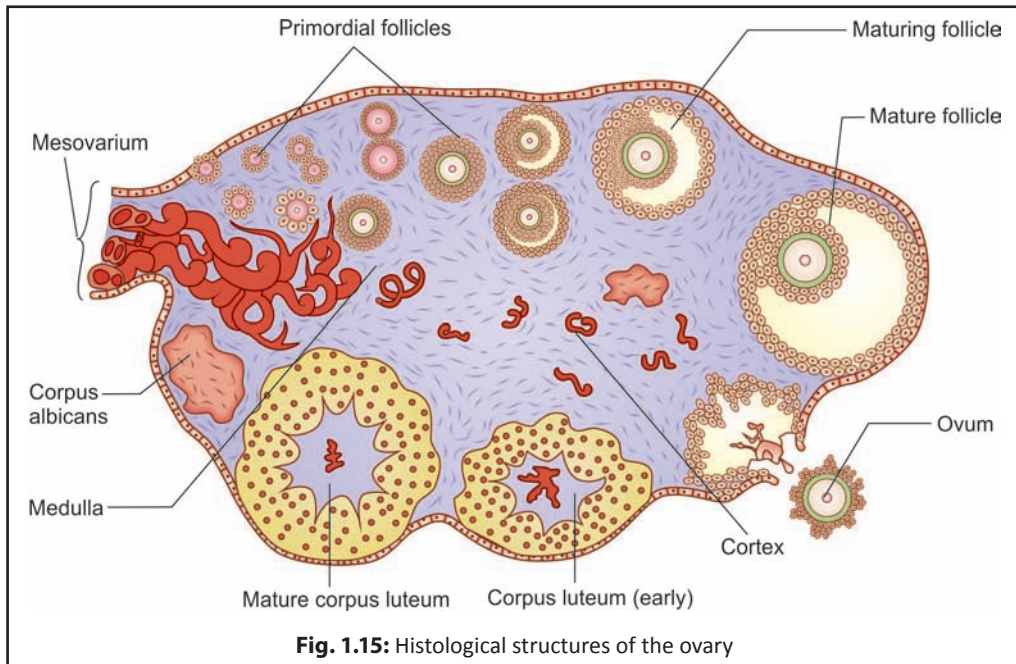
**Medulla:** It consists of loose connective tissues, few unstriated muscles, blood vessels and nerves. There are small collection of cells called "**hilus cells**" which are homologous to the interstitial cells of the testes.

### Blood Supply

**Arterial supply** is from the ovarian artery, a branch of the abdominal aorta.

**Venous drainage** is through pampiniform plexus, to form the ovarian veins which drain into inferior vena cava on the right side and left renal vein on the left side. Part of the venous blood from the placental site drains into the ovarian and thus may become the site of thrombophlebitis in puerperium.

**Nerve Supply:** Sympathetic supply comes down along the ovarian artery from T<sub>10</sub> segment. Ovaries are sensitive to manual squeezing.



**Fig. 1.15:** Histological structures of the ovary

## FEMALE URETHRA

The female urethra extends from the neck of the bladder to the external urethral meatus. **It measures about 4 cm and has a diameter of about 6 mm.**

The bladder base forms an angle with the posterior wall of the urethra called posterior urethrovesical angle (PUV) which normally measures 100°. The urethra runs downwards and forwards in close proximity of the anterior vaginal wall. About 1 cm from the lower end, it pierces the triangular ligament. It ultimately opens into the vestibule about 2.5 cm below the clitoris.

### Relations

**Posteriorly:** It is related to the anterior vaginal wall to which it is loosely separated in the upper two-third but firmly adherent in the lower-third.

**Anteriorly:** It is related to the posterior aspect of symphysis pubis. The upper two-third is separated by loose areolar tissue; the lower one-third is attached on each side of the pubic rami by fibrous tissue called—pubourethral ligament.

### Laterally

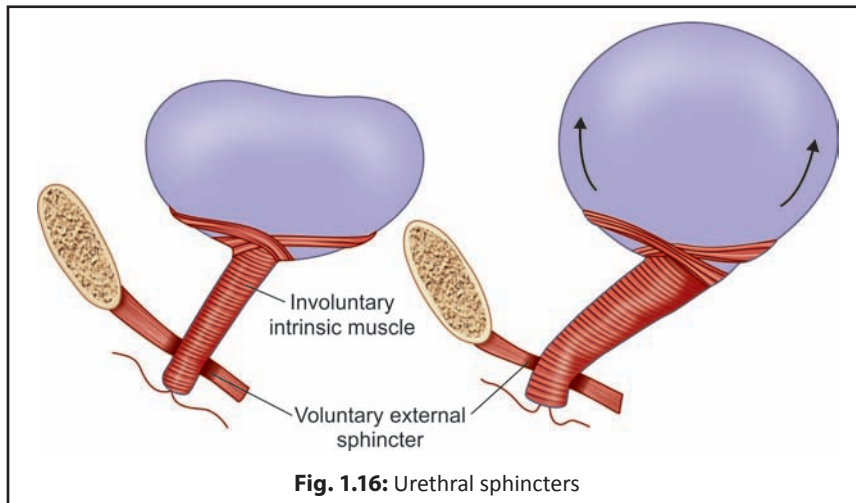
- i. As it passes through the triangular ligament, it is surrounded by compressor urethra.

- ii. Whether the medial fibers of puborectalis get attached to the urethra while passing by its sides to get attached to lateral vaginal walls is debatable.
- iii. Bulbocavernosus and vestibular bulb.

**Glands:** Numerous tubular glands called paraurethral glands open into the lumen through ducts. Of these, two are longer and called Skene's ducts which open either on the posterior wall just inside the external meatus or into the vestibule. **Skene's glands are homologous to the prostate in the male.**

**Sphincters:** The following are the sphincters:

1. At the urethrovesical junction, there is intricate decussation of the involuntary muscles. This has the effect of forming anterior and posterior slings which function as an involuntary internal sphincter. This is the lissosphincter. When the detrusor muscle actively contracts, the slings relax → funneling of the bladder neck → urine flows into the urethra (Fig. 1.16).
2. The wall of the urethra is composed of involuntary muscles and the fibers are arranged in the form of crossed spirals. The fibers are continuous with those of the bladder detrusor. The tone and elasticity of these muscles keep it close except during micturition.



3. Sphincter urethra in the urogenital diaphragm. This sphincter allows the voluntary arrest of urine flow.
4. Although debatable, puborectalis part of levator ani which surrounds the lower-third of the urethra acts as an external sphincter.
5. Superficial perineal muscles, bulbocavernosus and ischiocavernosus form an accessory external sphincter.

**Structures:** Mucous membrane is lined by transitional epithelium except at the external urethral meatus where it becomes stratified squamous. Submucous coat is vascular. Muscle coat is composed of involuntary muscles and the fibers are arranged in the form of crossed spirals.

### Blood Supply

**Arterial supply:** Proximal part is supplied by the inferior vesical branch and the distal part by a branch of internal pudendal artery.

**The veins** drain into vesical plexus and into internal pudendal veins.

**Lymphatics** (see p. 31).

**Nerves:** The urethra is supplied by the pudendal nerve.

**Development:** The urethra is developed from the vesicourethral portion of the cloaca.

### Applied Anatomy

- (i) Because of shortness and its close proximity to the vagina and anus, the infection is likely which commonly spreads upwards to involve the bladder.
- (ii) Because of close proximity of the anterior vaginal wall, the urethra may be injured during the process of childbirth.
- (iii) The paraurethral glands are the sites of infection and occasional development of benign adenoma or malignant changes.

## THE URINARY BLADDER

The bladder is a hollow muscular organ with considerable power of distension. Its capacity is about 450 mL (15 oz) but can retain as much as 3–4 liters of urine. When distended, it is ovoid in shape. It has got: (1) an apex, (2) superior surface, (3) base, (4) two inferolateral surfaces and (5) neck, which is continuous with the urethra. **The base and the neck remain fixed even when the bladder is distended.**

**Relations:** The superior surface is related with the peritoneum of the uterovesical pouch (Fig. 1.5). The base is related with the supravaginal cervix and the anterior fornix. The ureters, after crossing the pelvic floor at the sides of the cervix, enter the bladder on its lateral angles. In the interior of bladder, the triangular area marked by three openings—two ureteric and



one urethral, is called the trigone. The **inferolateral surfaces are related with the space of Retzius**. The neck rests on the superior layer of the urogenital diaphragm.

**Structures : From outside inwards—**

1. Outer visceral layer of the pelvic fascia.
2. Muscle layer composed of muscles running in various directions. Near the internal urethral opening, the circular muscle fibers provide involuntary sphincter.
3. Mucous coat is lined by transitional epithelium with no gland. **There is no submucous coat.**

**Blood Supply:**

**The arterial supply** is through superior and inferior vesical arteries. The veins drain into vesical and vaginal plexus and thence to internal iliac veins.

**Lymphatics:** Lymphatics drain into external and internal iliac lymph nodes.

**Nerve supply:**

**The sympathetic supply** is from the pelvic plexus and the parasympathetic via the pelvic plexus from the nervi erigentes (S<sub>2,3,4</sub>). **The parasympathetic** produces contraction of the detrusor muscles and relaxation of the internal sphincter (nerve of evacuation). Sympathetic conveys afferent painful stimuli of overdistension.

**Development:** The urinary bladder is developed from the upper part of the urogenital sinus.

## PELVIC URETER

The pelvic ureter extends from its crossing over the pelvic brim up to its opening into the bladder. **It measures about 13 cm in length and has a diameter of 5 mm.**

**Course and Relations**

The ureter enters the pelvis in front of the bifurcation of the common iliac artery over the sacroiliac joint behind the root of the mesentery on the right side and the apex of the mesosigmoid on the left side. As it courses downwards in contact with the peritoneum, it lies anterior to the internal iliac artery and behind

the ovary and forms the posterior boundary of ovarian fossa (see Fig. 1.14). On reaching the ischial spine, it lies over the pelvic floor and as it courses forwards and medially on the base of the broad ligament, **it is crossed by the uterine artery anteriorly (Fig. 1.10)**. Soon, it enters into the ureteric tunnel and lies close to the supravaginal part of the cervix, about 1.5 cm lateral to it. After traversing a short distance on the anterior fornix of the vagina, it courses into the wall of the bladder obliquely for about 2 cm by piercing the lateral angle before it opens into the base of the trigone. **In the pelvic portion, the ureter is comparatively constricted:**

- a. Where it crosses the pelvic brim.
- b. Where crossed by the uterine artery.
- c. In the intravesical part.

**Structures: From outside inwards—**(1) Fibers derived from the visceral layer of the pelvic fascia. (2) Muscle coat consisting of three layers—outer and inner longitudinal and intermediate circular. (3) Mucous layer lined by transitional epithelium.

**Blood supply:** The ureter has got segmental supply from nearly all the visceral branches of the anterior division of the internal iliac artery. The venous drainage corresponds to the arteries (uterine, vaginal, vesical, middle rectal, and superior gluteal).

**Lymphatics:** The lymphatics from the lower part drain into the external and internal iliac lymph nodes and the upper part into the lumbar lymph nodes.

**Nerve supply:** Sympathetic supply is from the hypogastric and pelvic plexus; parasympathetic from the sacral plexus.

**Development:** The ureter is developed as an ureteric bud from the caudal end of the mesonephric duct.

### Applied Anatomy

**The ureter is recognized by the following features:**

- i. Pale glistening appearance.
- ii. Longitudinal vessels on the surface.
- iii. Peristalsis.

### Applied Anatomy *Contd...*

The ureter is likely to be damaged during pelvic surgery (see p. 425).

**Abdominal hysterectomy: The common sites of ureteric injury are**—(i) infundibulopelvic ligament; (ii) by the side of the cervix (clamping the cardinal ligament along with descending cervical artery); (iii) vaginal angle as the ureter traverses along the anterior fornix; (iv) during pelvic peritonization (ureter lies in the posterior leaf of the peritoneum).

**The chances of injury are more** in cases of endometriosis, pelvic inflammation or broad ligament tumor. Injury is more common during reclamping than primary clamping.

**Radical hysterectomy:** Direct injury is not common. Sloughing necrosis may occur due to stripping the ureter off the peritoneum → devitalization → sloughing.

## RECTUM

The rectum commences at the level of the third piece of the sacrum in continuation of pelvic colon and ends in anal canal. It measures 12–15 cm. The rectum follows the curve of the sacrum. It curves twice to the left and once to the right before it passes down to continue as anal canal.

**Peritoneal coverings:** Rectum is covered anteriorly and laterally in its upper-third, only anteriorly in the middle-third. Whole of the posterior surface and the entire lower-third remain uncovered.

### Relations

#### Anteriorly:

- i. The part of the rectum covered by peritoneum is related to the posterior wall of the pouch of Douglas.
- ii. The ampulla is related to the posterior vaginal wall separated by rectovaginal septum.
- iii. The lower part is related to the perineal body.

**Posteriorly:** Rectum is related to the sacrum and coccyx from which intervened by loose areolar tissue, sacral nerve trunks and middle sacral vessels.

**Laterally:** Rectum is related to uterosacral ligament, pelvic plexus of nerves and ureter. Near the anorectal

junction, it is related to puborectalis part of levator ani. Below the muscle, it is related to ischiorectal fossa.

### Structures

Rectum is surrounded by rectal fascia. Muscle coat consists of outer longitudinal and inner circular fibers. Submucous layer is loose and contains venous plexuses. Mucous membrane is lined by columnar epithelium.

## ANAL CANAL

The anal canal measures about 2.5 cm. It is directed backwards almost at right angles to the ampulla and at the site of insertion of puborectalis part of levator ani. It ends at the anal orifice. At the junction of the upper two-third and lower one-third is the white line (Hilton's line).

**Relations:** Anteriorly, it is related to perineal body and posteriorly to the anococcygeal body.

### Anal Sphincters

The anal canal has got two sphincters:

- ♦ Involuntary internal sphincter is formed by thickening of circular layer of the upper two-third of the anal canal.
- ♦ Voluntary sphincter ani externus which surrounds the entire length of the canal, **consists of three parts:**
  1. *Subcutaneous part*—It is attached to the skin.
  2. *Superficial part*—It starts from the perineal body and is inserted posteriorly to the tip of the coccyx.
  3. *Deep part*—It is separated from the sphincter ani internus by levator ani (Fig. 1.17).

### Lining Epithelium

The upper two-third is lined by columnar epithelium but the lower-third with stratified squamous epithelium.

### Blood Supply of Rectum and Anal Canal

**Arterial supply** is from:

- i. *Superior rectal*—branch of inferior mesenteric artery.
- ii. *Middle rectal*—branch of internal iliac artery.
- iii. *Inferior rectal*—branch of the internal iliac artery.

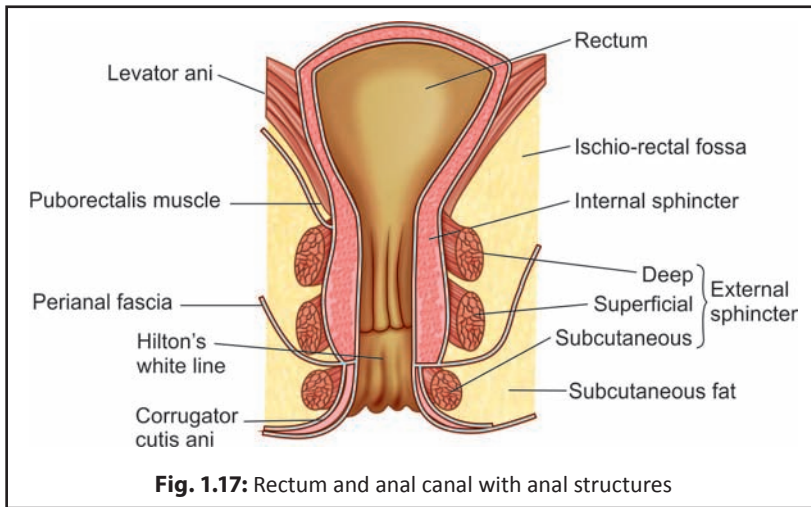


Fig. 1.17: Rectum and anal canal with anal structures

### Venous drainage

The rectum and upper-third of the anal canal drain via superior rectal veins to portal circulation. The lower-third of the anal canal drains on both sides into inferior rectal veins (systemic system).

### Lymphatics of Rectum and Anal Canal

The lymphatics from the rectum and upper-third of the anal canal drain into internal iliac and preaortic nodes, while the lower-third of the anal canal drains into the superficial inguinal nodes.

### Nerve Supply of Rectum and Anal Canal

The rectum and the upper two-third of the anal canal are supplied by autonomic through pelvic plexuses. The lower-third of the anal canal is supplied by inferior hemorrhoidal nerve.

### Development of Rectum and Anal Canal

The rectum and the upper two-third of the anal canal are developed from the dorsal part of cloaca (endoderm). The lower one-third of the anal canal is developed from the anal pit (ectoderm).

## PELVIC MUSCLES

The most important muscle supporting the pelvic organs is the levator ani which forms the pelvic floor. The small muscles of the perineum also have got some contribution in the support.

## PELVIC FLOOR

(SYN: PELVIC DIAPHRAGM)

Pelvic floor is a muscular partition which separates the pelvic cavity from the anatomical perineum. It consists of three sets of muscles on either side—**pubococcygeus, iliococcygeus and ischiococcygeus. These are collectively called levator ani.** Its upper surface is concave and slopes downwards, backwards and medially and is covered by parietal layer of pelvic fascia. The inferior surface is convex and is covered by anal fascia. The muscle with the covering fascia is called the **pelvic diaphragm. Levator ani** is a strong and fatigue resistant striated muscle. It is slug like a hammock around the midline pelvic effluents — (urethra, vagina and anal canal: Fig. 1.18).

### Origin

Each levator ani arises from the back of the pubic rami, from the condensed fascia covering the obturator internus (**white line**) and from the inner surface of the ischial spine.

### Insertion

**The pubococcygeus**—The fibers pass backwards and medially and are inserted as follows : **(a)** The posterior fibers are inserted into the anococcygeal raphe and tip of the coccyx. **(b) Puborectalis**—these fibers wind round the anorectal junction and are continuous with the

similar fibers of the opposite side forming a 'U' shaped loop known as *Puborectal sling*. **(c) Puboanalis**—these fibers run between the sphincter and externus and internus and are inserted in the wall of the anal canal along the longitudinal fibers. **(d) Pubovaginalis**—these anterior fibers pass by the side of vagina and are inserted into the perineal body (Fig. 1.18).

**Coccygeus** (Ischiococcygeus) is triangular in shape. It arises from the apex of the ischial spine and the sacrospinous ligament and is inserted by its base into the sides of the upper two pieces of the coccyx and the last piece of sacrum (Fig. 1.18).

**Anococcygeal raphe** also known as **levator plate**, is a layered musculofibrous tissue. It extends from the anorectal junction to the tip of the coccyx. It comprises from above downwards: (i) presacral fascia, (ii) tendinous plate of pubococcygeus, (iii) muscular raphe of iliococcygeus and (iv) superficial fibers of sphincter ani externus muscles (Fig. 1.18).

**Gaps:** There are two gaps in the midline—(1) The anterior one is called **hiatus urogenitalis** which is bridged by the muscles and fascia of urogenital triangle and pierced by the urethra and vagina. (2) The posterior one is called **hiatus rectalis**, transmitting the rectum.

### Structure in Relation to Pelvic Floor

The superior surface is related with the following:

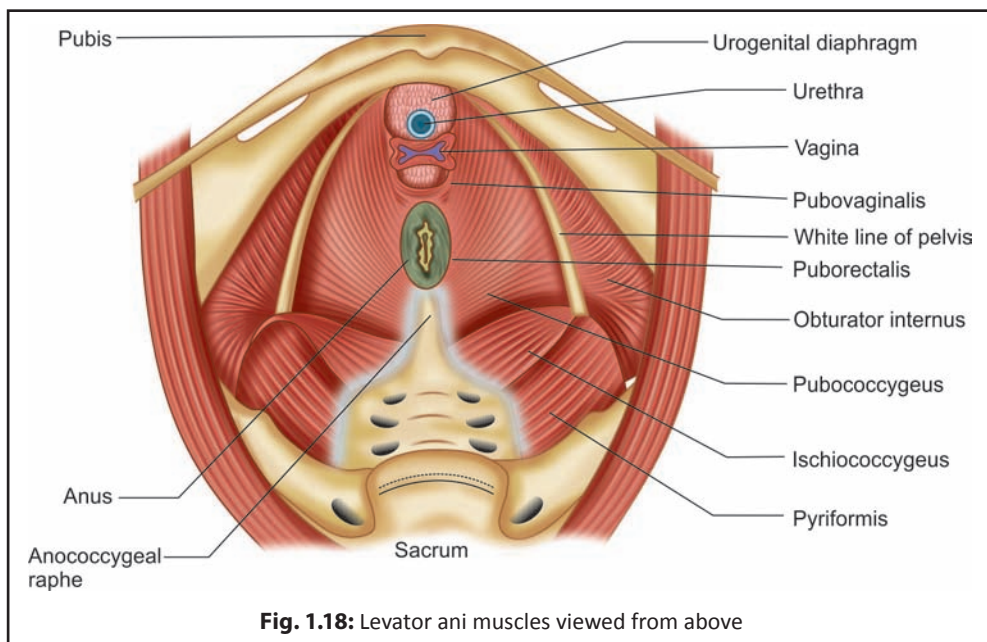
1. Pelvic organs from anterior to posterior are bladder, vagina and rectum.
2. Pelvic cellular tissues between the pelvic peritoneum and upper surface of the levator ani which fill all the available spaces.
3. Ureter lies on the floor in relation to the lateral vaginal fornix. **The uterine artery lies above and the vaginal artery lies below it.**
4. Pelvic nerves.

**The inferior surface** is related to the anatomical perineum.

**Nerve supply:** The muscle is supplied by the 3rd and 4th sacral nerve, inferior rectal nerve and a perineal branch of pudendal nerve ( $S_{2,3,4}$ ).

### Functions

1. To support the pelvic organs (Table 1.1)—The pubovaginalis which forms a 'U' shaped sling, supports the vagina which in turn supports the other pelvic organs—bladder and uterus. Weakness or tear of this sling during parturition is responsible for prolapse of the organs concerned.



**Fig. 1.18:** Levator ani muscles viewed from above

2. Counteracts the downward thrust of increased intra-abdominal pressure and guards the hiatus urogenitalis.
3. Facilitates anterior internal rotation of the presenting part when it presses on the (puborectal sling) pelvic floor.
4. Puborectalis plays an ancillary role to the action of the external anal sphincter.
5. Ischiococcygeus helps to stabilize the sacroiliac and sacrococcygeal joints.
6. To steady the perineal body.

### Pelvic Floor during Pregnancy and Parturition

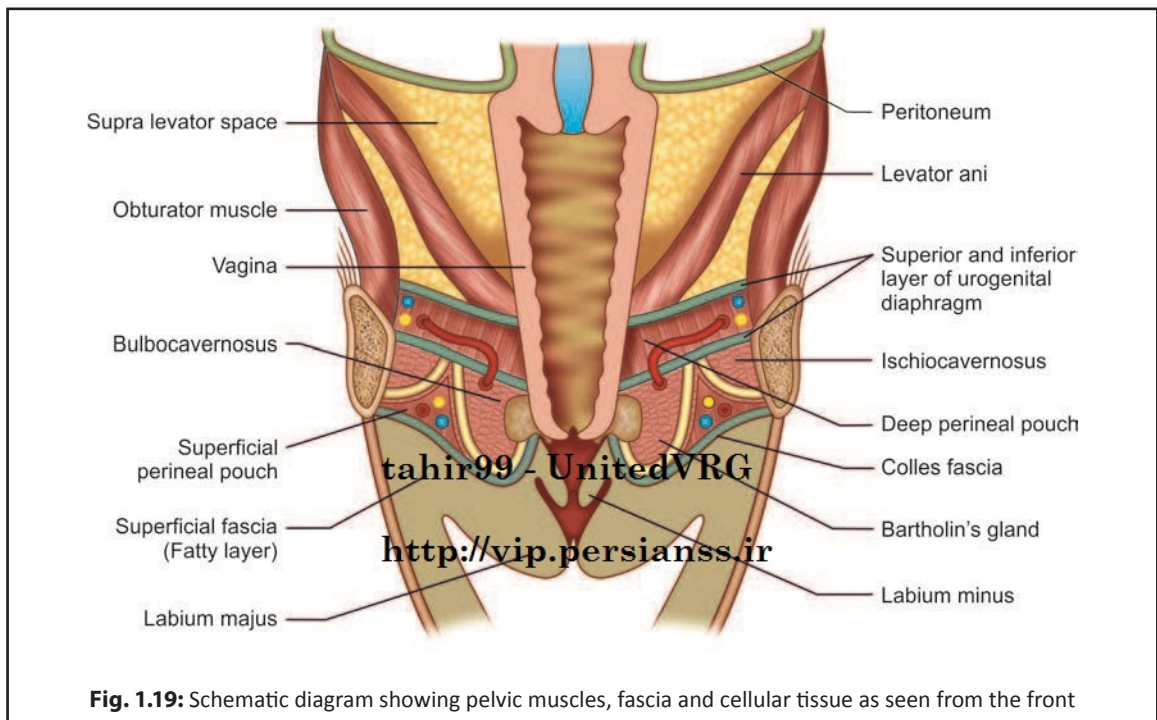
During pregnancy, levator muscles hypertrophy, become less rigid and more distensible. Due to water retention, it swells up and sags down. In the second stage, the pubovaginalis and puborectalis relax and the levator ani is drawn up over the advancing presenting part in the second stage. Failure of the levator ani to relax at the crucial moment may lead to extensive damage of the pelvic structures. The effect of such a displacement is to elongate the birth canal, which is

composed solely of soft parts below the bony outlet. The soft canal has got deep lateral and posterior walls and its axis is in continuation with the axis of the bony pelvis.

## PERINEUM

### ANATOMICAL PERINEUM

Anatomically, the perineum is bounded above by the inferior surface of the pelvic floor, below by the skin between the buttocks and thighs. Laterally, it is bounded by the ischiopubic rami, ischial tuberosities and sacrotuberous ligaments and posteriorly, by the coccyx. The diamond-shaped space of the bony pelvic outlet is divided into two triangular spaces with the common base formed by the free border of the urogenital diaphragm. The anterior triangle is called the urogenital triangle which fills up the gap of the hiatus urogenitalis and is important from the obstetric point of view. The posterior one is called the anal triangle.



**Fig. 1.19:** Schematic diagram showing pelvic muscles, fascia and cellular tissue as seen from the front

### Urogenital Triangle

It is pierced by the terminal part of the vagina and the urethra. The small perineal muscles are situated in two compartments formed by the ill-defined fascia. The compartments are superficial and deep perineal pouch. **The superficial pouch** is formed by the deep layer of the superficial perineal fascia (Colles fascia) and inferior layer of the urogenital diaphragm (perineal membrane). **The contents are** (Figs 1.3 and 1.19) superficial transverse perinei (paired), bulbocavernosus covering the bulb of the vestibule, ischiocavernosus (paired) covering the crura of the clitoris and the Bartholin's gland (paired). **The deep perineal pouch** is formed by the inferior and superior layer of the urogenital diaphragm—together called urogenital diaphragm or triangular ligament. Between the layers, there is a potential space of about 1.25 cm. **The contents are** the following muscles—deep transverse perinei (paired) and sphincter urethrae membranaceae. Both the pouches contain vessels and nerves (Fig. 1.19).

### Anal Triangle

The triangle has got no obstetric importance. It contains the terminal part of the anal canal with sphincter ani externus, anococcygeal body, ischio-rectal fossa, blood vessels, nerves, and lymphatics.

## OBSTETRICAL PERINEUM

(SYN: PERINEAL BODY, CENTRAL POINT OF PERINEUM)

The pyramidal-shaped tissue where the pelvic floor and the perineal muscles and fascia meet in between the vaginal and the anal canal is called the obstetrical perineum. It measures about 4 cm × 4 cm (1 1/2") with the (see Fig. 15.5A) base covered by the perineal skin and the apex is pointed and is continuous with the rectovaginal septum.

### The musculofascial structures involved are:

- ◆ **Fascia**—(1) Two layers of superficial perineal fascia—superficial fatty layer and deeper layer called Colles fascia. (2) Inferior and superior layers of urogenital diaphragm, together called triangular ligament.
- ◆ **Muscles**—(1) Superficial and deep transverse perinei (paired). (2) Bulbospongiosus. (3) Levator

ani—pubococcygeus part (paired) situated at the junction of the upper two-third and lower one-third of the vagina. (4) Sphincter ani externus (few fibers).

### Importance

1. It helps support the levator ani which is placed above it.
2. By supporting the posterior vaginal wall, it indirectly supports the anterior vaginal wall, bladder and the uterus.
3. It is vulnerable to injury during childbirth.
4. Deliberate cutting of the structures during delivery is called episiotomy.

## PELVIC PERITONEUM

Traced anteriorly, the peritoneum covering the superior surface of the bladder reflects over the anterior surface of the uterus at the level of the internal os. The pouch, so formed, is called **utero-vesical pouch**. The peritoneum, thereafter, is firmly attached to the anterior and posterior walls of the uterus and upper one-third of the posterior vaginal wall where from it is reflected over the rectum. The pouch, so formed, is called **pouch of Douglas** (Fig. 1.6).

## POUCH OF DOUGLAS

This is a narrow peritoneal cul-de-sac in the pelvis situated in the rectouterine space. It is continuous with the pararectal fossa of either side.

**Anteriorly**, it is bounded by the peritoneal covering of the cervix, posterior vaginal fornix and upper-third of the posterior vaginal wall.

**Posteriorly**, it is bounded by the peritoneal covering on the anterior surface of the rectum.

**Laterally**, it is limited by the uterosacral folds of peritoneum covering the uterosacral ligaments.

**The floor** is formed by the reflection of the anterior peritoneum onto the anterior surface of the rectum. It is about 6–7 cm above the anal orifice. Below the floor, there is a thin fibrous tissue septum (rectovaginal).

**Contents:** It may remain empty but may contain coils of intestine or omentum.

### Surgical Importance

- ◆ As it is the most dependent part of the peritoneal cavity, intraperitoneal blood or pus usually settles down to the pouch to produce either pelvic hematocele or pelvic abscess.
- ◆ Herniation of the pouch through the posterior fornix may occur producing the clinical entity of enterocele.
- ◆ Vaginal ligation is done through opening the pouch.
- ◆ Culdoscopy, culdocentesis or at time pneumoperitoneum may be done through the pouch.
- ◆ Nodules deposited in the pouch can help in the clinical diagnosis of pelvic malignancy, endometriosis or genital tuberculosis.

### BROAD LIGAMENT

The double fold of peritoneum which extends from the lateral border of the uterus to the lateral pelvic wall of pelvis is called broad ligament. These are two, one on each side. These, truly are not ligaments (Fig. 1.12).

Each broad ligament consists of two layers, anterior and posterior. The layers are continuous at its upper free border embracing the Fallopian tube. The lower part of the broad ligament is wider from before backwards and the layers are reflected above the pelvic diaphragm. The anterior leaf is reflected forwards at the level of the internal os as uterovesical pouch. The posterior leaf descends a little down to cover the upper-third of the posterior vaginal wall to form the posterior layer of the pouch of Douglas.

### PARTS OF BROAD LIGAMENT

**Infundibulopelvic Ligament (Syn: Suspensory ligament of the ovary):** It includes the portion of the broad ligament which extends from the infundibulum of the Fallopian tube to the lateral pelvic wall. It contains ovarian vessels and nerves and lymphatics from the ovary, Fallopian tube and body of the uterus.

**Mesovarium:** The ovary is attached to the posterior layer of the broad ligament by a fold of peritoneum called mesovarium (ovarian mesentery). Through this fold, ovarian vessels, nerves and lymphatics enter and leave the hilum. The ovary is not enclosed within the broad ligament (Fig. 1.10).

**Mesosalpinx:** The part of the broad ligament between the fallopian tube and the level of attachment of the ovary is the mesosalpinx. It contains utero-ovarian anastomotic vessels and vestigial remnants (Fig. 1.12).

**Mesometrium:** The part of the broad ligament below the mesosalpinx is called mesometrium. It is the longest portion which is related with the lateral border of the uterus.

### CONTENTS

#### Each broad ligament contains:

- ◆ Fallopian tube.
- ◆ Uterine and ovarian arteries with their branches, including the anastomotic branches between them and corresponding veins.
- ◆ Nerves and lymphatics from the uterus, Fallopian tube and ovary.
- ◆ Proximal part of the round ligament which raises a peritoneal fold on the anterior leaf.
- ◆ Ovarian ligament which raises a peritoneal fold on the posterior leaf.
- ◆ Parametrium containing loose areolar tissue and fat. The terminal part of the ureter, uterine artery, paracervical nerve and lymphatic plexus are lying at the base of the broad ligament.
- ◆ Vestigial structures, such as duct of Gartner, epoophoron, and paroophoron.

### DEVELOPMENT

The broad transverse fold which is established as the two Müllerian ducts approach each other is developed into broad ligament.

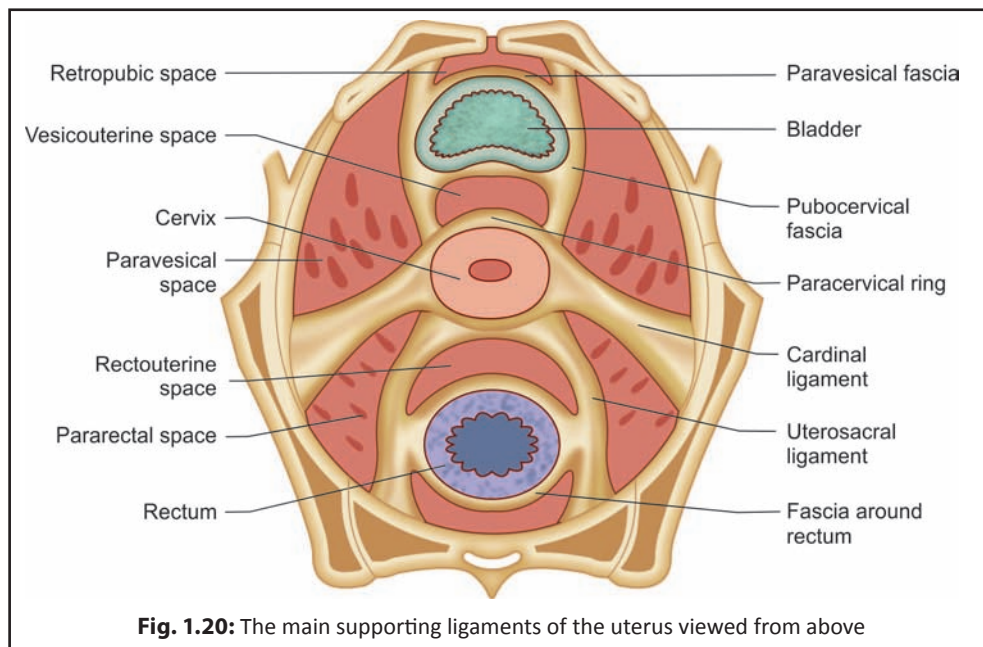
### FUNCTION

Along with the loose areolar tissue (packing material), it has got steady effect to maintain the uterus in position.

## PELVIC FASCIA AND CELLULAR TISSUE

### PELVIC FASCIA

For descriptive purpose, the pelvic fascia is grouped under the heading that covers the pelvic wall, the pelvic floor and the pelvic viscera.



### Fascia on the Pelvic Wall

The fascia is very tough and membranous. It covers the obturator internus and pyriformis and gets attached to the margins of the bone. The pelvic nerves lie external to the fascia but the vessels lie internal to it.

### Fascia on the Pelvic Floor

The fascia is not tough but loose. The superior and the inferior surfaces are covered by the parietal layer of the pelvic fascia which runs down from the white line to merge with the visceral layer of the pelvic fascia covering the anal canal (Fig. 1.19).

### Fascia Covering the Pelvic Viscera

The fascia is not condensed and often contains loose areolar tissue to allow distension of the organs.

## PELVIC CELLULAR TISSUE

The cellular tissue lies between the pelvic peritoneum and the pelvic floor, and fills up all the available empty spaces. It contains fatty and connective tissues and unstripped muscle fibers. **Collectively, it is known as endopelvic fascia.** Its distribution round the vaginal vault, supravaginal part of the cervix and into the layers of the broad ligament is

called **parametrium**. Condensation occurs especially near the cervicovaginal junction to form ligaments, which extend from the viscera to the pelvic walls on either side. **The deep endopelvic connective tissue condenses to form** (i) Uterosacral ligaments. (ii) Cardinal ligaments. (iii) Pubocervical ligament. (iv) Rectovaginal septum. (v) Pubovesical fascia.

### MACKENRODT'S LIGAMENTS

(**SYN: CARDINAL LIGAMENT, TRANSVERSE CERVICAL**)

**Origin:** Condensation of parietal fascia covering the obturator internus.

**Insertion:** Lateral supravaginal cervix and upper part of lateral vaginal wall in a fan-shaped manner. This insertion is continuous with the endopelvic and paricervical fascial ring (see Fig. 15.6).

**Content:** Uterosacral plexus of autonomic nerves, uterine artery and vein, smooth muscle fiber. **Distal part of ureter passes under the uterine artery within the upper part of the cardinal ligament.** It is situated inferior to the uterosacral ligament with which it is blended (Fig. 1.20).

**Function:** (i) Lateral stabilization to the cervix at the level of ischial spine. (ii) Primary vascular conduits of the uterus and vagina.



## UTEROSACRAL LIGAMENTS

**Origin:** Periosteum of sacral vertebra 2, 3 and 4.

**Insertion:** Posterolateral surface of the cervix at the level of internal os. Here it blends with the endopelvic fascial ring. These are formed by condensation of peritoneum.

**Content:** Uterosacral plexus of autonomic nerves. Smooth muscle and minimal vessels.

**Function:** These are the primary proximal suspensory ligaments of the uterovaginal complex. They hold the cervix posteriorly at the level of the ischial spines. Uterus is thus maintained anteflexed and the vagina is suspended over the levator plate.

## PUBOCERVICAL FASCIA (BLADDER PILLAR)

**Origin:** Back of the pubic bone and the arcus tendinous fascia laterally.

**Insertion:** Anterolateral supravaginal cervix and blends with the pericervical ring of endopelvic fascia and the cardinal ligaments.

**Content:** Artery and veins of the bladder pillar.

**Function:** These ligaments are poorly developed. They serve mainly as vascular conduit and provide less cervical stabilization force.

**Vesicovaginal septum:** It is a fibroelastic connective tissue with some smooth muscle fibers.

**Extension:** Laterally, it extends from pubic tubercles, pubic arch. Arcus tendinous fascia (white line) and centrally to the pubocervical ring, blending with the pubocervical and cardinal ligaments and pelvic visceral fascia.

**Function:** It supports the bladder and the anterior vaginal wall.

**Rectovaginal septum (RVS)** (Fascia of Denonvilliers'). It is also a fibroelastic connective tissue with few smooth muscle fibers.

**Extension:** It is an extension of endopelvic fascia. It extends between the posterior vaginal wall and anterior wall of the rectum. This fibroelastic connective tissue fuses **below** with the perineal body, **centrally** with the pericervical ring, **laterally** to the arcus tendineus fascia, Mackenrodt's ligament and **posteriorly** with the uterosacral ligaments.

**Function:** It supports the posterior vaginal wall, stabilizes the rectum and the perineum.

**Pericervical ring (see Fig. 1.20):** It is a circular band of fibromuscular connective tissue that encircles the supravaginal part of the cervix.

**Extension: Anteriorly,** it lies between the base of the bladder and the anterior cervix. It is continuous with the pubocervical ligaments.

**Laterally:** It is continuous with the Mackenrodt's ligaments.

**Posteriorly:** It is located between the posterior surface of the cervix and the rectum behind. It extends posteriorly as the uterosacral ligaments.

**Function:** It stabilizes the cervix at the level of inschial spines.

### Clinical significance of the pelvic cellular tissues and their condensation

- ◆ To support the pelvic organs.
- ◆ To form protective sheath for the blood vessels and the terminal part of the ureter.
- ◆ Infection spreads along the track, so from outside the pelvis to the perinephric region along the ureter, to the buttock along the gluteal vessels, to the thigh along the external iliac vessels and to the groin along the round ligament.
- ◆ Marked hypertrophy occurs during pregnancy to widen up the spaces.

## ROUND LIGAMENTS

These are paired, one on each side. Each measures about 10–12 cm. It is attached at the cornu of the uterus below and in front of the fallopian tube. It courses beneath the anterior leaf of the broad ligament to reach the internal abdominal ring (Figs 1.10 and 1.14). After traversing through the inguinal canal, it fuses with the subcutaneous tissue of the anterior third of the labium majus. During its course, it runs anterior to obturator artery and lateral to the inferior epigastric artery (Fig. 1.14). It contains plain muscles and connective tissue. It is hypertrophied during pregnancy and in association with fibroid.

Near the uterus, it is flat but more distally, it becomes round. It corresponds developmentally to the gubernaculum testis and is morphologically continuous with the ovarian ligament. The blood supply is from the utero-ovarian anastomotic vessels. The lymphatics from the body of the uterus pass along it to reach the inguinal group of nodes. While it is not related to maintain the uterus in anteverted position, but its shortening by operation is utilized to make the uterus anteverted.

**Embryologically**, it corresponds with gubernaculum testis. In the fetus, there is a tubular process of peritoneum continuing with the round ligament into the inguinal region. This process is called canal of Nuck. It is analogous to the processus vaginalis which precedes to descent of the testis.

### OVARIAN LIGAMENTS

These are paired, one on each side. Each one is a fibromuscular cord-like structure which attaches to the inner pole of the ovary and to the cornu of the uterus posteriorly below the level of the attachment of the fallopian tube (Fig. 1.12). It lies beneath the posterior

leaf of the broad ligament and measures about 2.5 cm in length. **Morphologically, it is continuous with the round ligament and together are the homologous to the gubernaculum testis.**

**TABLE 1.1**

#### BIOMECHANICAL BASIS OF UTERO VAGINAL SUPPORT

Level	Site of vagina	Structures involved	Type of defects
I	Upper	<ul style="list-style-type: none"> <li>◆ Ligaments               <ul style="list-style-type: none"> <li>• Uterosacral</li> <li>• Mackenrodt</li> </ul> </li> </ul>	<ul style="list-style-type: none"> <li>◆ Prolapse               <ul style="list-style-type: none"> <li>• Uterovaginal</li> <li>• Enterocele</li> <li>• Vaginal vault</li> </ul> </li> </ul>
II	Middle	<ul style="list-style-type: none"> <li>◆ Fascia               <ul style="list-style-type: none"> <li>• Arcus tendineus</li> <li>• Pubocervical</li> </ul> </li> </ul>	<ul style="list-style-type: none"> <li>◆ Defects               <ul style="list-style-type: none"> <li>• Paravaginal</li> <li>• Pararectal</li> </ul> </li> </ul>
III	Lower	<ul style="list-style-type: none"> <li>◆ Urogenital diaphragm</li> <li>◆ Perineal muscles</li> <li>◆ Perineal body</li> <li>◆ Levator plate</li> </ul>	<ul style="list-style-type: none"> <li>• Cystocele</li> <li>• Rectocele</li> <li>• Urinary incontinence</li> </ul>

### Applied Anatomy

#### SUPPORTS OF THE UTERUS AND PELVIC ORGAN PROLAPSE (see p. 204)

##### Paravaginal defect (see p. 213)

Normally, the pubocervical fascia is attached laterally to the arcus tendineus fascia (white line) of the pelvis. Paravaginal defect may be due to:

- ◆ Complete detachment of pubocervical fascia from the arcus tendineus fascia.
- ◆ Detachment of arcus tendineus fascia from the pelvic side wall. However, pubocervical fascia remains attached to it.
- ◆ The arcus tendineus fascia may split. One part remains attachment to the pelvic side wall while the other part sags down with the attached pubocervical fascia.

##### Defect in the Posterior Compartment (see p. 205)

Posterior compartment defect (see Fig. 1.4A) may be due to any one or a combination of the following five defects combination:

- ◆ Detachment of the rectovaginal septum (RVS) from the pericervical ring and from the uterosacral ligaments (Figs 1.4 and 1.20).
- ◆ Break or tear of the RVS in its central or lateral part at the level of midvagina (Fig. 1.4A).
- ◆ Detachment of the RVS from the perineal body (Fig. 1.4A and 1.5).
- ◆ Disruption of the perineal body (Fig. 1.5) and
- ◆ Disruption or attenuation of the sphincter anus externus (Fig. 1.17).

**KEY POINTS**

- The labia majora contain sebaceous, sweat glands and hair follicles. The labia minora are devoid of fat and do not contain hair follicle.
- There are four openings in the vestibule—vaginal orifice, urethral opening, opening of paired Bartholin's ducts. Rarely, paraurethral ducts open into the vestibule.
- Bartholin's gland is situated in the superficial perineal pouch and measures about 0.5 cm. The duct measures 2 cm. The gland is compound racemose and lined by columnar epithelium. The duct is lined by columnar epithelium except near the opening, where it is lined by stratified squamous epithelium.
- The length of the anterior vaginal wall is 7 cm and that of posterior wall is 9 cm. Ureter lies about 2 cm from the lateral fornix. Vagina is lined by stratified squamous epithelium. It has no glands. The pH ranges between 4 and 5.5. Doderlein bacillus is gram-positive anaerobic organism. The glycogen content is highest in the vaginal fornix being 2.5–3 mg%.
- Uterus measures 8 cm and weighs 50–80 g. Isthmus is bounded above by the anatomical internal os and below by the histological internal os. Isthmus measures 0.5 cm. Normal length of uterine cavity is 6–7 cm. Uterine artery crosses the ureter anteriorly from above. The epithelium, called endometrium is ciliated columnar type. The glands are simple tubular. There is no submucous layer. Cervical canal is lined by tall columnar epithelium. The cervical glands are compound racemose type.
- Fallopian tube has got 4 parts—interstitial (1 mm diameter), isthmus, ampullary (fertilization takes place) and infundibulum (6 mm diameter). It is lined by ciliated columnar epithelium, secretory nonciliated epithelium and 'peg' cells. The tube measures 10 cm.
- Ovary is attached to the posterior leaf of the broad ligament by the mesovarium. The ovarian fossa is related posteriorly to ureter. The cortex is studded with follicular structures and the medulla contains hilus cells which are homologous to the interstitial cells of the testes.
- Female urethra measures 4 cm with a diameter of 6 mm. Posterior urethrovesical angle measures 100°. Mucous coat is lined by transitional epithelium. There is no submucous coat.
- Pelvic part of the female ureter measures 13 cm with a diameter of 5 mm. It lies close to the supravaginal part of the cervix (1.5 cm). It is comparatively constricted (i) where it crosses the brim, (ii) where crossed by the uterine artery, and (iii) in the intravesical part. The ureter is likely to be damaged during hysterectomy at the infundibulopelvic ligament, by the side of the cervix, at the vaginal angle and during posterior peritonization.
- Superficial perineal pouch is formed by the deep layer of the superficial perineal fascia and inferior layer of the urogenital diaphragm. The deep perineal pouch is formed by the inferior and superior layer of the urogenital diaphragm. Obstetrical perineum is the fibromuscular structure, pyramidal-shaped with the base covered by the perineal skin and situated in between the vaginal and anal canal. It measures 4 cm × 4 cm.
- Pelvic cellular tissues (endopelvic fascia), ligaments, perineal body, pelvic floor muscles (levator ani), support the pelvic organs and counter acts the downward thrust of increased intra-abdominal pressure (see p. 24, 207). This prevent pelvic organ prolapse (see Table 15.1).
- Broad ligament has got four parts — infundibulopelvic ligament, mesovarium, mesosalpinx and mesometrium. Broad ligament contains Fallopian tube, round ligament, ovarian ligament, parametrium, utero-ovarian anastomotic vessels, nerves, lymphatics of the uterus, tubes and ovaries and vestigial structures—duct of Gartner, epoophoron and paroophoron.
- Round ligament measures 10–12 cm. One end is attached to cornu of the uterus and the other end terminates in the anterior third of the labium majus.

# Blood Vessels, Lymphatic Drainage and Innervation of Pelvic Organs

## THE PELVIC BLOOD VESSELS

■ Arterial supply ■ Venous drainage

### ARTERIAL SUPPLY

#### Sources

- ◆ Anterior division of internal iliac artery
- ◆ Ovarian artery
- ◆ Superior rectal artery.

#### INTERNAL ILIAC ARTERY

Internal iliac artery is one of the bifurcations of the common iliac artery. The bifurcation occurs over the sacroiliac articulation. It measures about 2 cm. Ureter lies anteriorly and the internal iliac vein posteriorly. It soon divides into anterior and posterior divisions. Only the anterior division supplies the pelvic viscera. The branches are schematically mentioned overleaf.

#### Uterine artery

**Origin:** The uterine artery arises either directly from the internal iliac artery or in common with the obliterated umbilical artery.

**Course:** It runs downwards and forwards along the lateral pelvic wall almost in the same direction as the ureter until it reaches the base of the broad ligament. It then turns medially and crosses the ureter anteriorly from above and at right angle to it; about 1.5–2 cm lateral to, at the level of internal os. On reaching the side of the uterus, it runs upwards and takes a spiral course along the lateral uterine wall between the layers of broad ligament. It ultimately anastomoses end on with the tubal branch of the ovarian artery in the mesosalpinx.

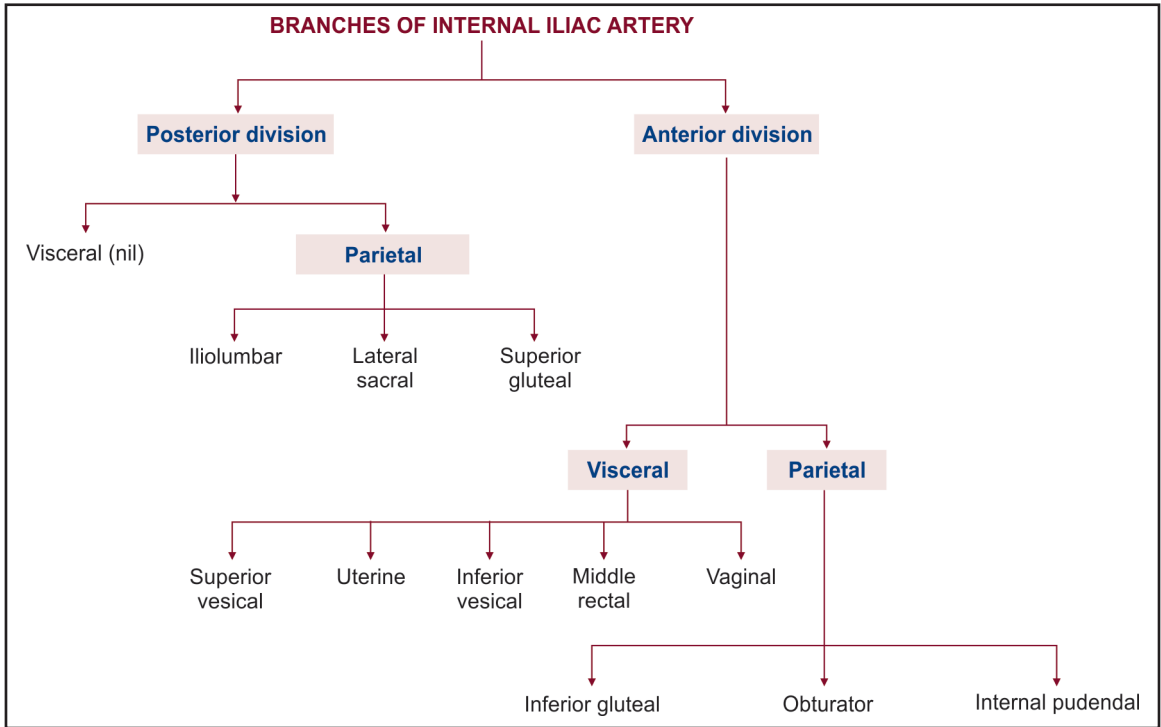
#### Branches

The following branches are given off:

- ◆ Ureteric—as it crosses it
- ◆ Descending cervical
- ◆ Circular artery to the cervix: This is formed by anterior and posterior branches of the artery to the cervix of both sides
- ◆ Segmental arcuate arteries: These are the branches from the ascending part. These pierce about one-third of the myometrium and then divide into anterior and posterior branches. These anastomose with the corresponding branches of the opposite side in the midline. Thus, the middle of the uterus is comparatively avascular. From the arcuate arteries, a series of radial arteries arise almost at right angles, which stretch through the entire length of the myometrium. Near the myoendometrial junction, the radial arteries are divided into:
  - (a) Short basal artery—supplies the basal endometrium.
  - (b) Spiral artery which proceeds as far as superficial portion of the endometrium and ends finally in extensive capillary plexuses (Figs 2.1A and B).
- ◆ Fundal branch
- ◆ Twigs to round ligament
- ◆ Tubal branch
- ◆ Ovarian anastomotic branch.

#### Vaginal artery

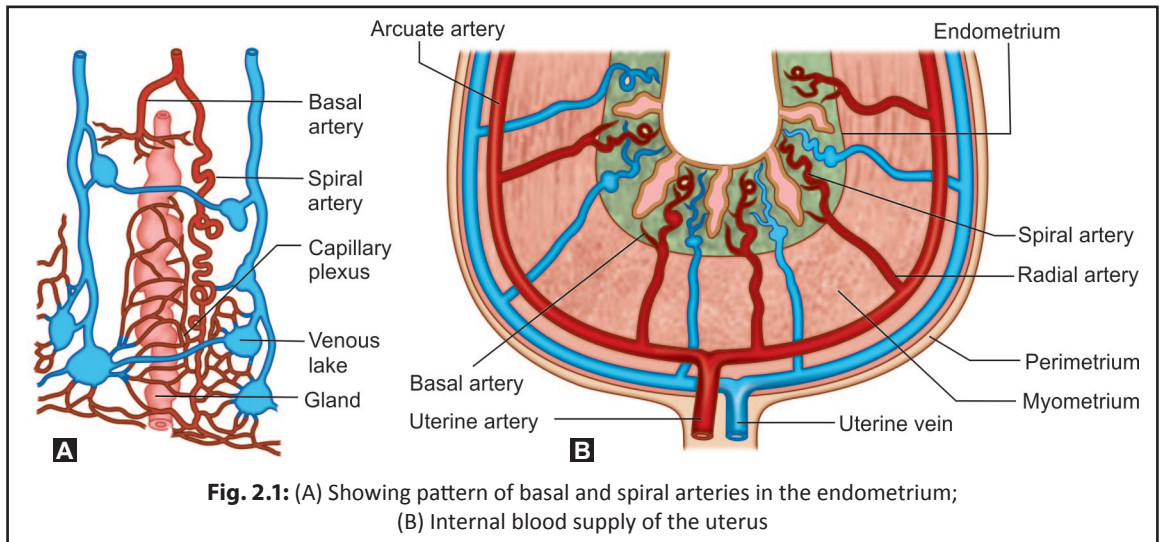
**Origin:** The vaginal artery arises either from the uterine artery or directly from the anterior division of



the internal iliac artery. It is in relation to the lateral fornx and then runs down along the lateral wall of the vagina. Numerous transverse branches are sent off anteriorly and posteriorly, which anastomose with the similar branches of the other side to form azygos arteries of the vagina—one anterior and one posterior.

**Other arteries contributing to azygos arteries are:** (i) Descending cervical, (ii) Circular artery to the cervix, (iii) Inferior vesical, and (iv) Internal pudendal.

**Vesical arteries:** These are variable in number. They supply the bladder and the terminal part of the ureter.



**Fig. 2.1:** (A) Showing pattern of basal and spiral arteries in the endometrium; (B) Internal blood supply of the uterus

Inferior vesical artery supplies the middle-third of vagina and urethra.

**Middle rectal:** It arises either directly from the anterior division of the internal iliac or in common with inferior vesical artery. It supplies the lower-third of the vagina.

**Internal pudendal artery:** It is one of the parietal branches of the anterior division of the internal iliac artery. It leaves the pelvic cavity along with its vein and pudendal nerve through the greater sciatic foramen and reenters the ischioanal fossa to lie in the pudendal canal (Alcock's canal) after winding round the ischial spine. Here, it gives off inferior rectal artery. Thereafter, it sends numerous branches to supply the perineal and vulval structures, including the vestibular bulb and clitoris. The terminal branches of the artery anastomose with superficial and deep pudendal arteries—branches of the femoral artery. This will help in maintaining the blood supply of the bladder when the vesical branch of the internal iliac artery is ligated.

### Ovarian artery

Each ovarian artery arises from the front of the aorta, a little below the renal artery. It enters the pelvic cavity after crossing the external iliac vessels. It then runs medially along the infundibulopelvic ligament to enter the mesovarium. As it enters the hilum of the ovary, it breaks up into numerous branches to supply the organ. Branches given to structures other than the ovary are:

- Ureter
- Uterine tube
- Round ligament
- Uterine anastomotic.

### Superior rectal artery

This artery is a continuation of the inferior mesenteric artery and descends down to the base of pelvic mesocolon. It then divides into two and each courses down on either side of the rectum to supply it by numerous branches.

## PELVIC VEINS

The peculiarities of the pelvic veins are:

- ◆ There is a tendency to form plexuses
- ◆ The plexuses anastomose freely with each other

- ◆ The veins may not follow the course of the artery
- ◆ They have no valves.

### OVARIAN VEINS

The ovarian veins on each side begin from the pampiniform plexus, which lies in between the layers of broad ligament near the mesovarium. Beyond the infundibulopelvic ligament, there are two ovarian veins on each side, which ascend up along the course of the corresponding artery. Higher up, the veins become one and ultimately drains into left renal vein on the left side and inferior vena cava on the right side.

### UTERUS, VAGINA, AND BLADDER

Venous drainage from the uterine, vaginal and vesical plexuses chiefly drain into internal iliac vein.

### RECTUM

Venous drainage from the rectal plexus drains via superior rectal vein into the inferior mesenteric vein. The middle and inferior rectal veins drain into the internal pudendal vein and thence to the internal iliac vein.

### Applied Anatomy

- ◆ The free anastomosis between the superior rectal veins of the portal, the middle and inferior rectal veins of the systemic system explains the liver metastases from the genital organ.
- ◆ The uterine veins communicate with the vaginal plexus; thus, accounting for vaginal metastases in endometrial carcinoma or choriocarcinoma.
- ◆ A free communication between pelvic plexuses with the sacral and lumbar channels of the vertebral venous plexus explains not only the development of vertebral metastases but also explains the intracranial malignant metastases bypassing the lungs through jugular vein. This collateral pathway is also related with supine hypotension syndrome in late pregnancy.

## PELVIC LYMPHATICS

The knowledge of the lymphatic channels and the draining lymph nodes from the genital organs is of paramount importance either in inflammatory or

specially in malignant diseases. The following groups of nodes are involved.

### INGUINAL NODES (FIG. 2.2)

**Superficial:** There are two groups. One lying horizontally and parallel to the inguinal ligament and the other is placed vertically along the long saphenous vein.

**Superficial group** receive afferents from gluteal region, anterior abdominal wall below the umbilicus, vulva, perineum, vagina below the hymen, anal canal below the Hilton's line and cornu of the uterus (along the round ligament). The efferents from the superficial inguinal lymph nodes drain into the deep inguinal nodes and external iliac lymph nodes passing through the inguinal canal.

**Deep inguinal lymph nodes:** These nodes receive afferents from deep femoral vessels, glans clitoris and few from superficial inguinal nodes. They are 5–6 in number and lie on the medial side of the femoral vein. The uppermost gland of this group is called the **gland of Cloquet or the gland of Rosenmüller**, which lies beneath the inguinal ligament in the femoral canal.

Efferents from the deep nodes pass through the femoral canal and drain to the **external iliac nodes**.

### PARAMETRIAL NODE

It is of small size, inconsistently present in the parametrium near the crossing of the ureter with the uterine artery.

**Internal iliac nodes** receive afferents from all the pelvic viscera, deeper perineum, muscles of the thigh and buttock. These glands receive the afferents from the obturator (obturator canal) and the sacral nodes (along the median and lateral sacral vessels).

### EXTERNAL ILIAC NODES

There are three groups: (i) Lateral—lateral to external iliac artery, (ii) Middle (anterior)—in between the artery and vein, and (iii) Medial—medial to the vein. These glands receive drainage from the cervix, upper vagina, bladder, lower abdominal wall and from the inguinal nodes. Afferents are from internal iliac, inferior epigastric, circumflex iliac and obturator nodes. The efferents ultimately drain into the **common iliac group**. **In carcinoma cervix, the medial and middle groups are involved.**

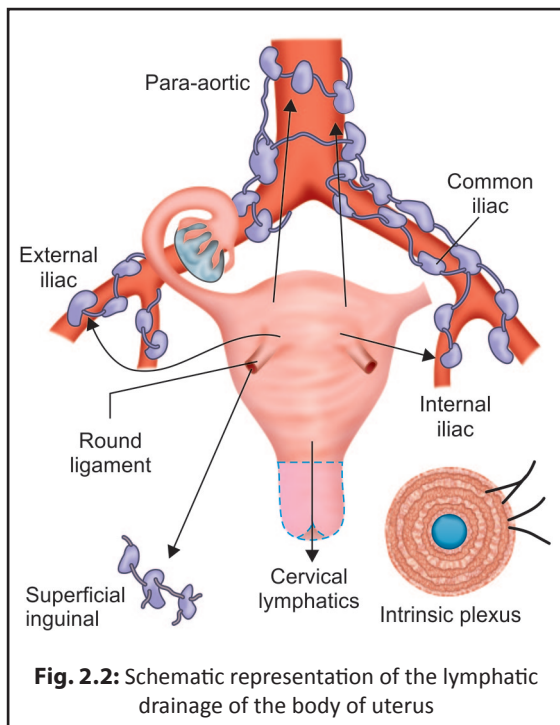
**Common iliac lymph nodes** are arranged in three groups: (i) Lateral, (ii) Intermediate and (iii) Medial. They receive **afferents** from external and internal iliac nodes and send **efferents** to the lateral aortic nodes.

### SACRAL GROUP

It consists of two sets of glands; one lateral group, which lies lateral to the rectum and a medial group lying in front of the sacral promontory. The lymphatics from these groups pass on either to the inferior lumbar group or to the common iliac group.

### LUMBAR GROUP

It consists of two sets of glands—(1) Inferior group, which lies in front of the aorta below the origin of inferior mesenteric artery. (2) Superior group, which lies near the origin of the ovarian artery. These two groups receive all the lymph from the pelvic organs. Thereafter, it passes up to cisterna chyli situated over the body of 12th thoracic vertebra. The lymph is finally carried upwards via the **thoracic duct which opens into the left subclavian vein at its junction with left internal jugular vein.**



**Fig. 2.2:** Schematic representation of the lymphatic drainage of the body of uterus

## LYMPHATICS OF THE CORPUS (FIG. 2.2)

### INTRINSIC PLEXUS

Two plexuses are demonstrated: (i) Basal layer of the endometrium and (ii) Subserosal layer. The lymphatics from the basal layer run through the myometrium in close relation to the blood vessels to reach the subserosal plexus.

### EXTRINSIC DRAINAGE

- (i) From the fundus and the adjoining part of the body → along ovarian lymphatics → superior lumbar (para-aortic) group of glands.
- (ii) From the cornu → along the round ligament → superficial inguinal (horizontal group).
- (iii) Rest of the body of uterus → external iliac group.
- (iv) Adjacent to cervix → into cervical lymphatics.

## LYMPHATICS OF THE CERVIX (FIG. 2.3)

The lymphatics from the cervix drain into the following lymph nodes coursing along the uterine veins.

### Primary groups

1. Parametrial group—inconsistent.
2. Internal iliac group.
3. Obturator group.
4. External iliac—anterior and medial group.
5. Sacral group.

### Secondary group

The lymphatics from all the primary groups drain into common iliac and superior lumbar group.

## LYMPHATICS FROM THE FALLOPIAN TUBE AND OVARY

The intrinsic plexuses of the fallopian tube are situated in the mucosal and subperitoneal layers. The afferents from these plexuses pass up along with ovarian lymphatics to superior lumbar group. There is free anastomosis between the ovarian lymphatics of each side across the uterosacral ligament or via the subperitoneal lymphatic plexus of the fundus of the uterus.

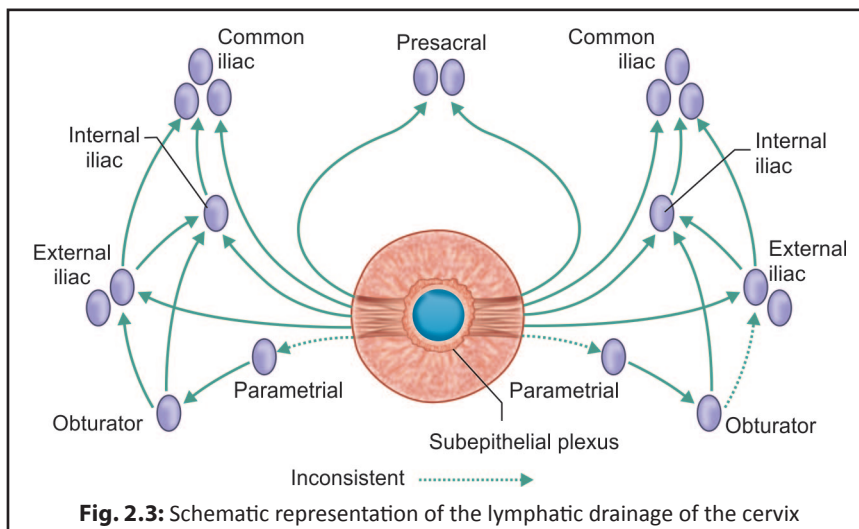
## LYMPHATICS OF THE VAGINA

The intrinsic plexuses are situated in the mucosal and muscle layers. (i) Upper two-thirds drain into the glands like those of the cervix. (ii) Lower one-third drains into inguinal and at times into external iliac nodes.

## LYMPHATICS OF THE VULVA (FIG. 2.4)

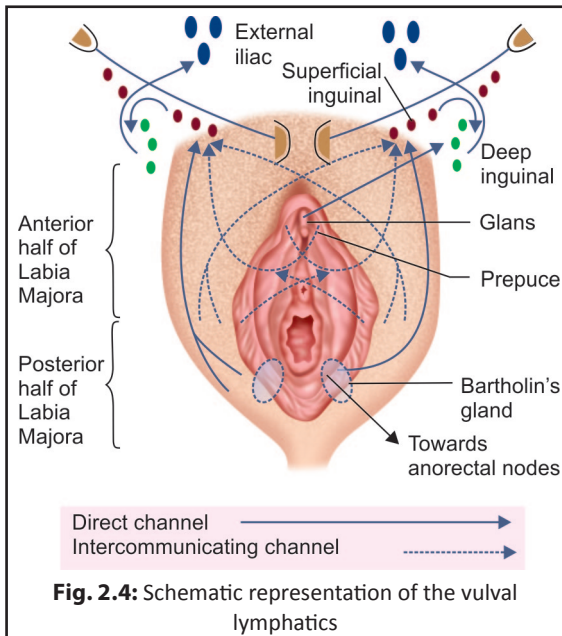
There are dense lymphatic plexuses in the dermis of the vulva, which intercommunicate with those of subcutaneous tissue (see p. 335).

- The lymphatics of each side freely communicate with each of them
- The lymphatics hardly cross beyond the labiocrural fold



**Fig. 2.3:** Schematic representation of the lymphatic drainage of the cervix





- ▶ The vulval lymphatics also anastomose with the lymphatics of the lower-third of the vagina and drain into external iliac nodes
- ▶ Lymphatics from the deep tissues of the vulva accompany the internal pudendal vessels to the internal iliac nodes
- ▶ Superficial inguinal lymph nodes are the primary lymph nodes that act as the sentinel nodes of the vulva. Deep inguinal lymph nodes are secondarily involved. It is unusual to find positive pelvic glands without metastatic disease in the inguinal nodes
- ▶ Gland of Cloquet or Rosenmüller, which is the upper most deep femoral nodes is absent in about 50 percent of cases.

### Labia Majora (Anterior Half)

Lymphatics intercommunicate with the opposite side in the region of mons veneris → Superficial inguinal nodes.

Thus, there is bilateral and contralateral spread of metastasis in malignancy affecting the areas.

### Labia Majora (Posterior Half)

Drains into → Superficial inguinal → Deep inguinal → External iliac.

### Labia Minora and Prepuce of Clitoris

Intercommunicating with the lymphatics of the opposite side in the vestibule and drains into superficial inguinal nodes.

**Glans of clitoris:** Drains directly into the deep inguinal and external iliac glands.

**Bartholin's glands:** The lymphatics drain into superficial inguinal and anorectal nodes.

**Node of Cloquet:** It was previously thought to be the main relay node through which the efferents from the superficial inguinal nodes pass to the external iliac nodes. Recent study shows its insignificant involvement in vulval malignancy, and thus, it is not considered to be the relay node. The efferents from the superficial inguinal may reach the external iliac group bypassing the node of Cloquet.

## LYMPHATICS OF BLADDER AND URETHRA

**Bladder:** The lymphatics drain into hypogastric group of glands → external iliac.

**Urethra:** Upper half drains like that of bladder; lower half drains into superficial inguinal node.

## PELVIC NERVES

- Somatic
- Autonomic

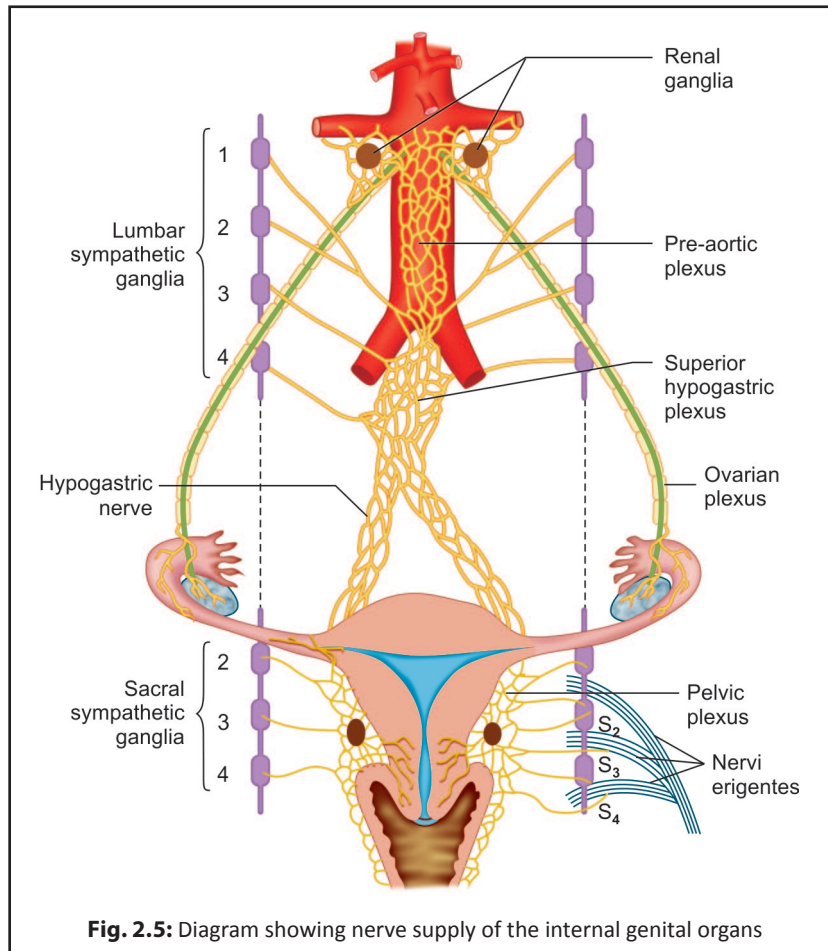
### SOMATIC

Both the motor and sensory part of the somatic supply to the pelvic organs are through:

- (i) Pudendal nerve— $S_2, S_3, S_4$ .
- (ii) Ilio-inguinal nerve— $L_1, L_2$ .
- (iii) Genital branch of genitofemoral nerve— $L_1, L_2$ .
- (iv) Posterior cutaneous nerve of thigh.

### PUDENDAL NERVE

The sensory component supplies the skin of the vulva, external urethral meatus, clitoris, perineum and lower vagina. The motor fibers supply all the voluntary muscles of the perineal body, levator ani and sphincter ani externus. Levator ani, in addition, receives direct supply from  $S_3$  and  $S_4$  roots.



**Fig. 2.5:** Diagram showing nerve supply of the internal genital organs

While the anterior half of vulval skin is supplied by the ilioinguinal and genital branch of genitofemoral nerves, the posterior part of the vulva, including the perineum is supplied by the posterior cutaneous nerve of thigh.

### AUTONOMIC

The autonomic supply is principally from the sympathetic and partly from the parasympathetic systems.

#### SYMPATHETIC

The sympathetic system carries both the sensory and motor fibers. The motor fibers arise from the segments D<sub>5</sub> and D<sub>6</sub> and the sensory fibers from the segments D<sub>10</sub> to L<sub>1</sub>. The fibers from the preaortic plexus of the sympathetic system are continuous with those of the superior hypogastric plexus. This plexus lies in front

of 5th lumbar vertebra and more often wrongly called presacral nerve. While passing over the bifurcation of aorta, it divides into right and left hypogastric nerves. The hypogastric nerve joins the pelvic parasympathetic nerve of the corresponding side and forms the pelvic plexus (right and left) or inferior hypogastric plexus or Frankenhauser plexus. This plexus lies in the loose cellular tissue, posterolateral to the cervix below the uterosacral folds of peritoneum. The pelvic plexus then continues along the course of the uterine artery as paracervical plexus (Fig. 2.5).

#### PARASYMPATHETIC

The parasympathetic fibers (nervi erigentes) are derived from the S<sub>2</sub>, S<sub>3</sub>, and S<sub>4</sub> nerves and join the hypogastric nerve of the corresponding side to form the pelvic plexus. The fibers are mainly sensory to the cervix. Thus, from the vaginal plexus, the nerve fibers

### Applied Anatomy

- ◆ Epidural analgesia or paracervical block during labor is effective due to blocking of the sensory impulses carried via sympathetic or parasympathetic fibers.
- ◆ Presacral neurectomy, although rarely done, either for intractable dysmenorrhea or endometriosis is to divide the sensory impulses carried from the uterus (see p. 180).
- ◆ While simple hysterectomy rarely disturbs the paracervical plexus, but the radical hysterectomy does and, in such cases, there may be marked atonicity of the bladder because of the division of the sacral connection of the uterovaginal plexus (see p. 349).
- ◆ Myometrium contains both alpha and beta adrenergic and cholinergic receptors. Strong stimulation of the receptors with beta mimetic drugs, such as isoxsuprine will inhibit myometrial activity.

pass on to the uterus, upper-third of vagina, urinary bladder, ureter and rectum.

### OVARIAN PLEXUS

Ovarian plexus is derived from the coeliac and renal ganglia. The fibers accompany the ovarian vessels to supply to ovary, Fallopian tube and the fundus of the uterus. The sensory supply of the tube and ovary is from  $D_{10}$  to  $D_{12}$ .

#### APPLIED ANATOMY

##### Ligation of Internal Iliac Artery and Development of Collateral Circulation

Systemic artery		Internal iliac artery
1. Lumbar (aorta) →	with	← Iliolumbar
2. Middle sacral (aorta) →	with	← Lateral sacral
3. Superior rectal (inferior mesenteric) →	with	← Middle rectal
4. Ovarian (aorta) →	with	← Uterine

### KEY POINTS

- Only the anterior division of the internal iliac artery supplies the pelvic viscera.
- The uterine artery arises either directly from the internal iliac artery or in common with obliterated umbilical artery.
- Vaginal artery arises either from the uterine artery or directly from the anterior division of internal iliac artery. The azygos arteries (two) are formed by vaginal, descending cervical, inferior vesical, and internal pudendal arteries.
- The ovarian artery arises from the aorta below the renal artery. The ovarian veins drain into inferior vena cava on the right side and into the left renal vein on the left side.
- The free anastomosis between the superior rectal veins of the portal, the middle and inferior rectal veins of the systemic system explains the liver metastases from the genital organs.
- The gland of Cloquet lies beneath the inguinal ligament in the femoral canal.
- From the cornu of the uterus, the lymphatics course along the round ligament to superficial inguinal group of glands.
- Levator ani is supplied by pudendal nerve and receives direct supply from  $S_3$  and  $S_4$  nerve roots. Levator ani muscle supports the pelvic viscera and prevents pelvic organ prolapse (see p. 198).
- The motor fibers of the sympathetic arise from the segments  $D_5$  and  $D_6$  and the sensory fibers from the segments  $D_{10}$  to  $L_1$ . The parasympathetic fibres are derived from the  $S_{2,3}$  and  $S_4$  nerves. The sensory supply of the tube and ovary is from  $D_{10}$  to  $D_{12}$ .
- Myometrium contains both alpha and beta adrenergic and cholinergic receptors.

# Development of Genital Organs and Gonads

## DEVELOPMENT OF EXTERNAL GENITAL ORGANS

The external genital organs start developing almost simultaneously with the development of the internal genital organs. The site of origin is from the **urogenital sinus** (Fig. 3.1). The endodermal cloaca is divided by a coronally oriented vertical partition, known as **urorectal septum**. The urorectal septum contains a pair of **paramesonephric ducts** close to the midline and a pair of **mesonephric ducts** laterally. The dorsal part of the endodermal cloaca, thus formed, differentiates to form the **rectum and anal canal**. The ventral portion, known as **urogenital sinus**, differentiates into three parts (Fig. 3.4).

- Upper vesicourethral part** forms the **mucous membrane of the bladder except the trigonal area**. It also contributes to the major part of **female urethra**.
- Middle pelvic part of urogenital sinus:** It receives the united caudal end of the two para-

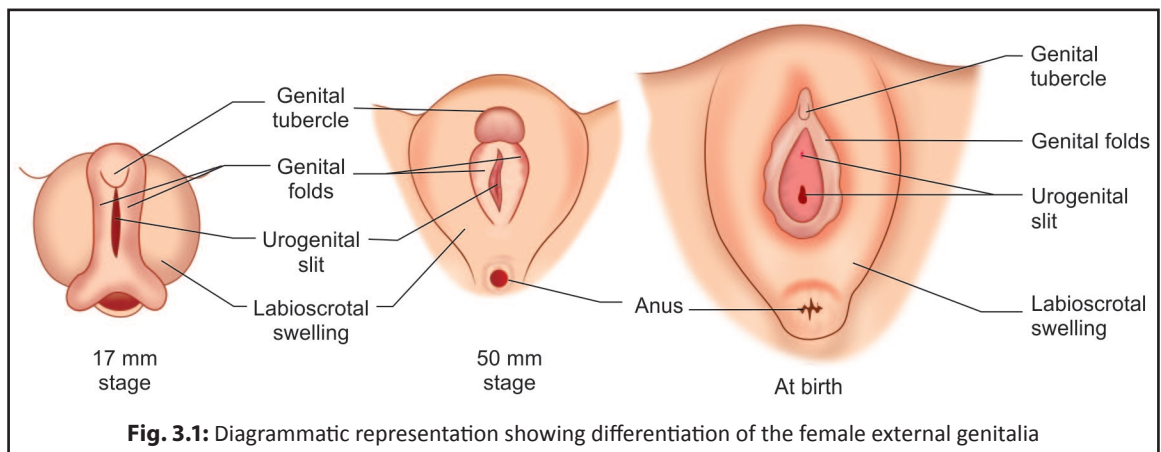
mesonephric ducts in the midline. Derivatives of this part differentiates into the epithelium of the vagina, Bartholin's gland, and the hymen.

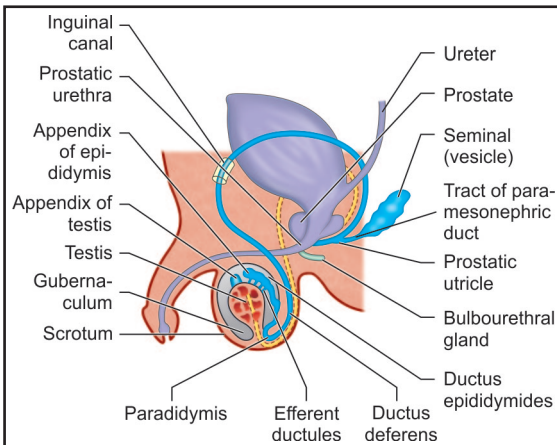
- The lower phallic part of the urogenital sinus:** It is lined by the bilaminar urogenital membrane (see below). It contributes to **vestibule of vagina**.

The site of fusion between the urorectal septum and the cloacal membrane is the **primitive perineal body**.

The part of the cloacal membrane in front of the primitive perineal body is called **urogenital membrane** and the part behind is called **anal membrane**. When the urogenital membrane ruptures, the genital folds do not reunite in female (e.f. male). They persist as **labia minora**. The perineal cleft persists as **vestibule**, into which the urethra and the vagina open. The ectodermal swelling, one on either side and lateral to the genital fold is called **labioscrotal swelling**. Eventually they form the **labia majora**.

The genital folds meet at the cephalic end of the cloacal membrane to form an elevation. This eleva-





**Fig. 3.2:** Diagrammatic representation showing development of male reproductive systems from the primitive genital ducts. Vestigial structures are also shown (see p. 39)

tion is known as **genital tubercle**, which ultimately differentiates into the **clitoris**.

Development up to this stage is the same in the male and the female (50 mm CR length, 10 weeks).

If the gonads become ovaries, the external genitalia will attain the female characteristics (Table 3.1).

- ❖ **Clitoris** is developed from the genital tubercle.
- ❖ **Labia minora** are developed from the genital folds.
- ❖ **Labia majora** are developed from the genital swellings.

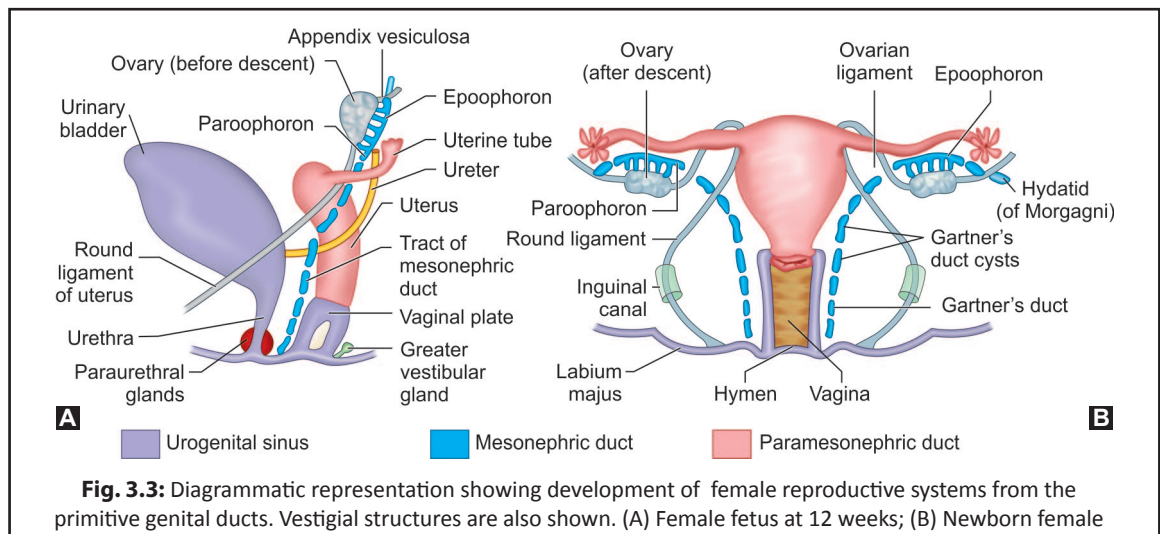
- ❖ **The Bartholin's glands** are developed as outgrowths from the caudal part of the urogenital sinus and correspond to the bulbourethral glands of male.

- ❖ **The vestibule:** The inferior portion of the pelvic part (Fig. 3.4D) and whole of the phallic part of the urogenital sinus expand to form the **vestibule** of the vagina (at about 5th month). It receives the openings of urethra, the vagina and Bartholin's ducts (Fig. 3.1).

## DEVELOPMENT OF INTERNAL GENITAL ORGANS

- Fallopian tubes
- Uterus
- Broad ligaments
- Vagina

The major part of the female genital tract develops from the **Müllerian ducts**. The duct forms one on each side as an ingrowth of coelomic epithelium in the lateral aspect of mesonephros at about 5–6 weeks (10 mm CR length). The ingrowth forms a groove and then a tube, which goes beneath the surface. While it grows downwards, it has developed three parts—(1) cranial vertical, (2) middle horizontal, and (3) caudal vertical after crossing the Wolffian duct anteriorly. In the absence of **androgen** (testosterone) and **anti-Müllerian hormone (AMH)**, as in a normal female, there is further growth and development of the Müllerian duct system with regression of the Wolffian ducts (Figs 3.3 and 3.6).



**Fig. 3.3:** Diagrammatic representation showing development of female reproductive systems from the primitive genital ducts. Vestigial structures are also shown. (A) Female fetus at 12 weeks; (B) Newborn female

## FALLOPIAN TUBES

Fallopian tube is developed from **upper vertical part and the adjoining horizontal part of the Müllerian duct**. The coelomic opening of the duct becomes the **abdominal ostium**.

## UTERUS

Uterus is developed by the fusion of the **intermediate horizontal and the adjoining vertical part of the Müllerian ducts**, which begins at 7–8 weeks (22 mm CR length) and completes by 12th week. Cervix is developed from the fused lower vertical parts of the two paramesonephric ducts. The cervix is differentiated from the corpus by 10th week. **The intervening septum disappears during the 5th month of intrauterine life**. The lining epithelium and the glands of the uterus and cervix are developed from the coelomic epithelium. Myometrium and endometrial stroma are developed from the **mesoderm of the paramesonephric ducts**.

## BROAD LIGAMENT

When the Müllerian ducts approach each other in the midline, a broad transverse fold is established. It extends from the lateral side of the fused Müllerian ducts up to the lateral pelvic walls, which is named as Broad ligament. All the vestigial remnants of mesonephric tubules, i.e. **epoophoron** (situated above

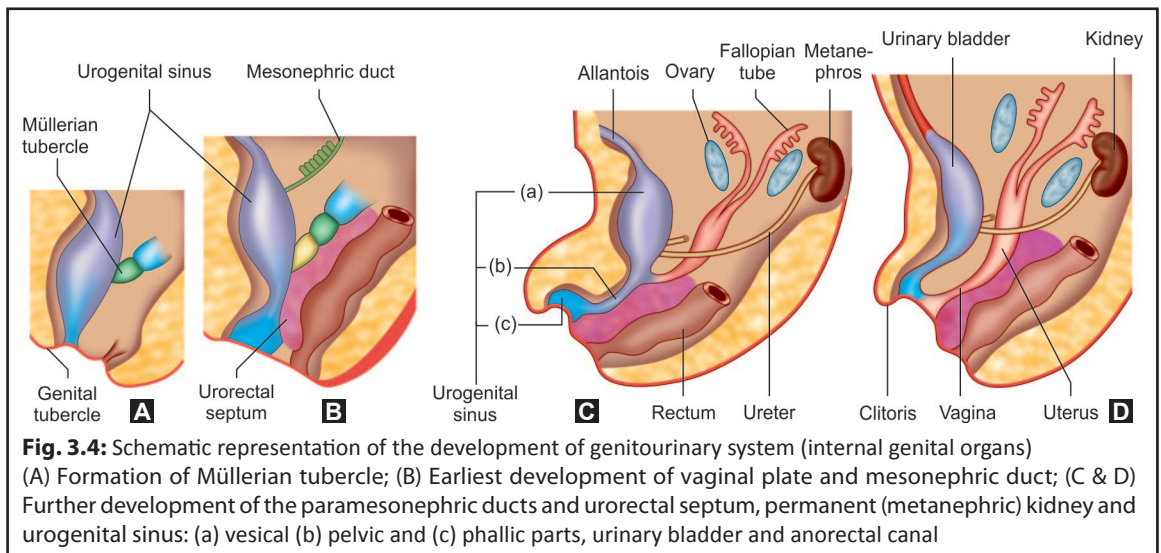
the ovary), **paroophoron** (between ovary and uterus) and the duct, remnant as **Gartner's duct** are found in the broad ligament in the mesosalpinx (Fig. 3.3). **Kobelt's tubules** on the outer set are said to be of pronephric origin (Fig. 1.12).

## VAGINA

**Development of vagina is composite, partly from the Müllerian (paramesonephric) ducts and partly from the urogenital sinus.**

The **paramesonephric ducts** develop at about **sixth week**, as an invagination of coelomic epithelium lateral to each mesonephric (Wolffian) duct. Each paramesonephric duct passes ventral to the corresponding mesonephric duct and then meets its counterpart from the opposite side in the midline (Fig. 3.4). The lower vertical parts of the two paramesonephric (Müllerian) ducts pass caudal wards in the urorectal septum and meet each other. Around 9th week, the solid caudal tip of the fused vertical parts of the Müllerian ducts project blindly into the dorsal wall of the urogenital sinus as **Müllerian tubercles** (Fig. 3.4A).

The paramesonephric ducts shortly undergo fusion with each other and the partition between them disappears. The united lower vertical parts form the **utero vaginal canal** and the fused Müllerian tubercles form the **Müllerian eminence**. The **unfused cranial part** of each paramesonephric duct



forms the uterine tube and the **distal open end forms the abdominal ostium**.

The endodermal cells from the dorsal wall of the urogenital sinus proliferate and form the **sinovaginal bulb** (Fig. 3.4B). These endodermal cells further proliferate and extend cranially into the central axis to form a solid plate, called **vaginal plate**. This vaginal plate elongates thereby increasing the distance between the urogenital sinus (below) at the cervix (above).

At about 20 weeks the vaginal plate undergoes canalization with the disintegration of the central cells. The upper end of the canal forms the vaginal fornices and communicates with the cervical canal and uterine cavity.

Central cells of the Müllerian eminence disintegrate, so that the vaginal canal now opens into the urogenital sinus (Fig. 3.4C). The tissue at the periphery persists as **hymen**. It is lined by sinus epithelium (endodermal origin) on either side with a thin mesoderm in between. Thus, whole of the vagina is lined by endoderm of the urogenital sinus and the muscle in the wall is derived from the mesoderm of the Müllerian ducts.

Finally, the urogenital membrane ruptures and the genital folds persist as the labia minora.

Eventually, the vaginal segment grows and is extended between the paramesonephric derived cervix at the top and the sinus derived vestibule at the bottom.

## SUMMARY

**Vagina is developed mainly from the Müllerian ducts and partly from the urogenital sinus.**

**Upper three-fifth above the hymen** develop from the fused uterovaginal canal of the Müllerian ducts.

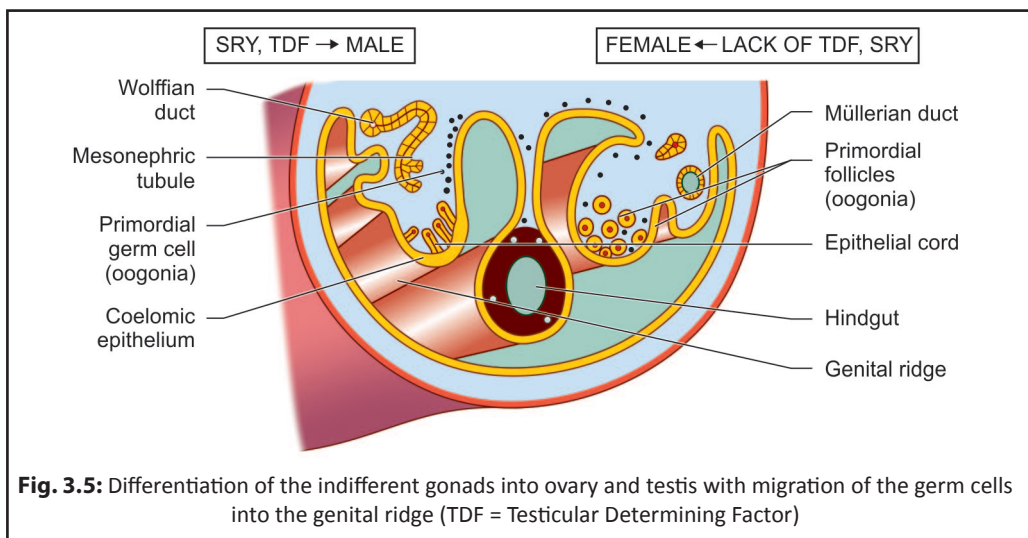
- ◆ Mucous membrane is developed from the endoderm of the canalized (vaginal plate) sinovaginal bulb (urogenital sinus).
- ◆ The musculature is developed from the mesoderm of the fused caudal vertical part of the Müllerian ducts.
- ◆ The hymen is developed from the junction of the Müllerian tubercle (mesodermal) and the urogenital sinus (endodermal).

**Lower one-fifth below the hymen** is developed entirely from the endoderm of the urogenital sinus.

**Vaginal introitus** is developed from the ectoderm of the genital folds after rupture of the bilaminar urogenital membrane.

## DEVELOPMENT OF THE OVARY

- ◆ **Site**
- ◆ **Sources**
- ◆ **Indifferent or primitive gonad**
- ◆ **Definitive gonad**
- ◆ **Descent of the ovary**



**Fig. 3.5:** Differentiation of the indifferent gonads into ovary and testis with migration of the germ cells into the genital ridge (TDF = Testicular Determining Factor)

### Site

The ovary is developed on either side from the genital or gonadal ridge. This ridge is formed in a four-week embryo between the dorsal mesentery (medially) and the mesonephric ridge (laterally) by the multiplication of the coelomic epithelium along with condensation of the underlying mesenchyme (Fig. 3.5).

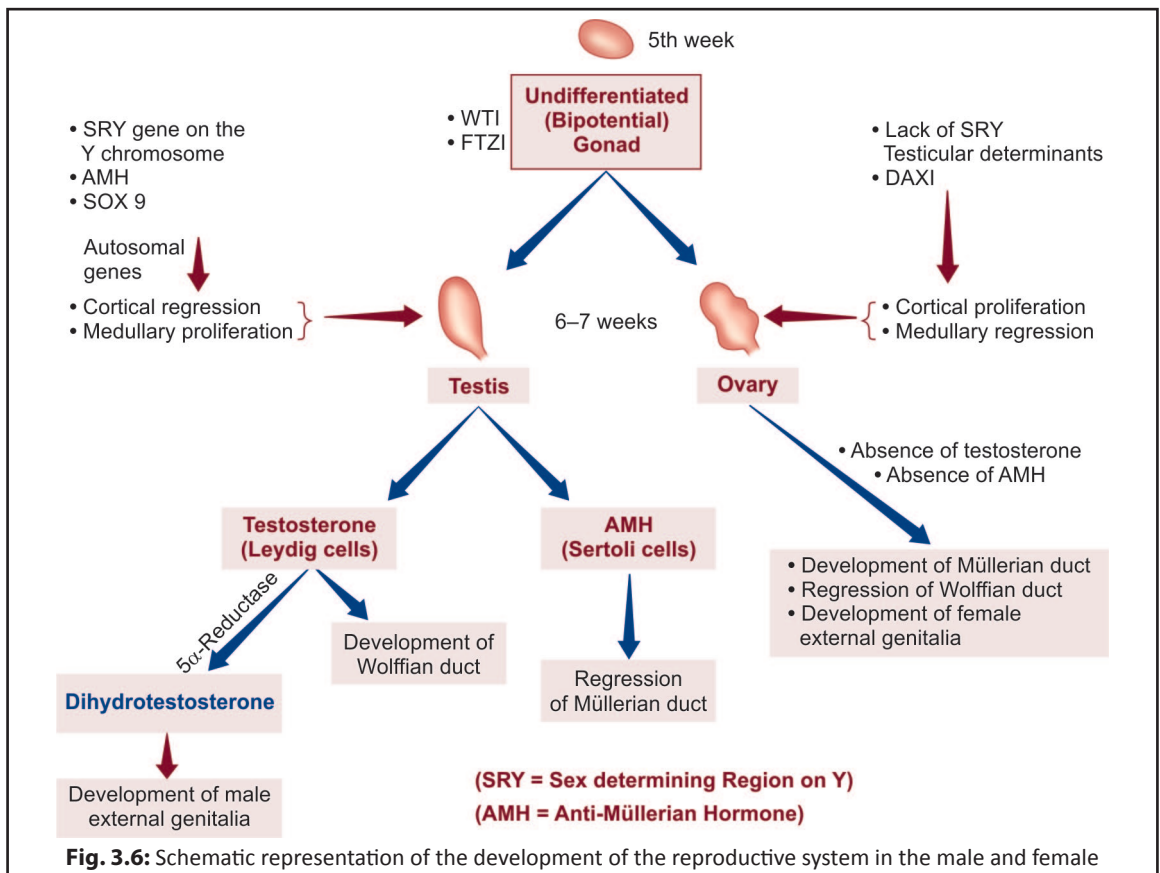
### Sources

The cortex and the covering epithelium are developed from the coelomic epithelium and the medulla from the mesenchyme. **The germ cells are of endodermal origin.** They migrate from the **yolk sac** to the genital ridge along the dorsal mesentery by amoeboid movement between 20 and 30 days. The germ cells undergo a number of rapid mitotic divisions and differentiate into oogonia. **The number of oogonia reaches its maximum at 20th week numbering about 7 million.** The mitotic division gradually ceases

and the majority enter into the prophase of the first meiotic division and are called **primary oocytes.** These are surrounded by flat cells (granulosa cells) and are called primordial follicles. At birth, there is no more mitotic division and all the oogonia are replaced by primary oocytes. **The estimated number at birth is about 2 million (details p. 82).**

### Indifferent or Primitive Gonad

Initially, the gonads do not acquire male or female morphological characteristics until the **seventh week of development.** Around the time of arrival of germ cells, the coelomic epithelium of the genital ridge proliferates. The irregular cords of cells (primitive sex cords) invaginate the underlying mesenchyme. These cords of cells surround the primordial germ cells and still have connection with the surface epithelium. It is difficult at this stage to differentiate between an ovary and testis.





**TABLE 3.1 MALE AND FEMALE DERIVATIVES OF EMBRYONIC UROGENITAL STRUCTURES**

Embryonic structure	Derivatives	
	Male (Fig. 3.2)	Female (Fig. 3.3)
Labioscrotal swelling	Scrotum	Labia majora
Urogenital folds	Ventral aspect of penis	Labia minora
Genital tubercle	Penis	Clitoris
Urogenital sinus	Urinary bladder Urethra except navicular fossa Prostate gland Prostatic utricle Bulbourethral glands	Urinary bladder, urethra Urethral and paraurethral glands  Vagina Bartholin's glands
Paramesonephric duct	Appendix of testes	Hydatid of Morgagni, uterus, cervix fallopian tubes, vagina (muscular wall)
Mesonephric duct	Ductus epididymis Ductus deferens and seminal vesicles	Duct of epoophoron Gartner's duct
Mesonephric tubules	Ductuli efferentes Paradidymis	Epoophoron Paroophoron
Undifferentiated gonad Cortex Medulla	Testis Seminiferous tubules Rete testis	Ovary Ovarian follicles Rete ovarii
Gubernaculum	Gubernaculum testis	Ovarian ligament Round ligament
Müllerian tubercle	Seminal colliculus	Hymen

### Definitive Gonad

In a XX individual, without the active influence of Y chromosome, **the bipotential gonad develops into an ovary about two weeks later than testicular development. SRY gene located on the short arm of Y chromosome directly controls the differentiation of testis from the bipotential gonad.** Apart from SRY, autosomal genes are also essential for differentiation of the gonads. Absence of SRY gene leads to female sex differentiation (Fig. 3.6).

**Genetic control** is of prime importance for differentiation of bipotential gonad. Genes that regulate the process are: Wilms' tumor gene (WTI), FTZI and SRY.

**Second gene** involved in development of testis is SOX9 and anti-Müllerian hormone (produced by Sertoli cells). DAXI gene expression is involved in ovarian differentiation. DAXI antagonizes the action of SRY gene.

The surface becomes thicker and continues to proliferate extensively. It sends down secondary

cords of cells into the mesenchyme (cortical cords), but unlike testis, maintains connection with the surface epithelium. In the fourth month, these cords split into clusters of cells, which surround the germ cells.

The germ cells will be the future oogonia and the epithelial cells will be the future **granulosa cells**. From 20th week, the oocytes that are not surrounded by the granulosa cell envelope, are destroyed. The stromal mesenchymal cells also surround the follicular structure to form the future theca cells. Thus, a basic unit of a follicle is completed. By 28th week, number of these follicles are exposed to maternal gonadotropin and undergo various degrees of maturation (little short of antrum formation) and atresia.

### Descent of the Ovary

The cranial part of the genital ridge becomes the infundibulopelvic ligament (Fig. 3.3). From the lower pole of the ovary, genital ligament (gubernaculum)

is formed, which is attached to the genital swelling (labial). Gubernaculum is a fibromuscular band. The genital ligament gets an intermediate attachment as it comes close to Müllerian ducts (angle of the developing uterus). The part between **the ovary and**

**the Müllerian attachment is the ovarian ligament and the part between the cornu of the uterus to the end is the round ligament. The ovaries descend during the seventh to ninth months, and at birth, they are situated at the pelvic brim.**

## KEY POINTS

- ▶ The external genital organs start developing almost simultaneously with the development of the internal genital organs.
- ▶ Clitoris is developed from the genital tubercle, labia minora from the genital folds and labia majora from the genital swellings.
- ▶ Bartholin's glands are developed from the caudal part of the urogenital sinus.
- ▶ Major part of the vagina is developed from urogenital sinus.
- ▶ SRY (sex-determining region of the Y chromosome) gene directly controls the testicular differentiation from the bipotential gonad. SRY gene encodes the testicular determining factor (TDF), which induces the differentiation. Testicular development is an active event whereas ovarian development is a default pathway due to absent SRY gene.
- ▶ An individual with absent SRY gene, though the chromosomal complement is 46, XY, the gonadoductal development is towards female (XY gonadal dysgenesis).
- ▶ The ovary is developed from the gonadal ridge. The cortex and the covering epithelium are developed from the coelomic epithelium and the medulla from the mesenchyme. The germ cells are endodermal in origin and migrate from the yolk sac to the genital ridge. The number of oogonia reaches its maximum at 20th week numbering about 7 million. The estimated number at birth is about 2 million.
- ▶ The bipotential gonad develops into an ovary about two weeks later than the testicular development.
- ▶ The cranial end of the genital ridge becomes the infundibulopelvic ligament.
- ▶ The ovary is developed from the middle part of the genital ridge.
- ▶ The part of the gubernaculum (genital ligament) between the lower pole of the ovary and the Müllerian attachment is the ovarian ligament. The part between the cornu of the uterus (Müllerian attachment) to the end (external genitalia) is the round ligament.
- ▶ The ovaries descend during seventh to ninth months, and at birth, they are situated at the pelvic brim.
- ▶ The paramesonephric duct in female differentiates into fallopian tube, uterus and cervix. The mesonephric duct in male gives rise to epididymis, vas deferens and seminal vesicles. The sinovaginal bulbs, which grow out from the posterior aspect of the urogenital sinus, differentiates into vagina. The genital tubercle differentiates into clitoris (female) or penis (male). The urinary bladder develops from the urogenital sinus.
- ▶ Urinary bladder develops from the upper vesicourethral part of the urogenital sinus except the trigone.
- ▶ A cyst of the vagina, especially on the anterolateral vaginal wall, is usually Gartner's duct cyst (embryonic cyst).

# Congenital Malformation of Female Genital Organs

## INTRODUCTION

From the embryological considerations, the following facts can be deduced.

- ◆ Developmental anomalies of the external genitalia along with ambiguity of sex are **usually genetic in origin**
- ◆ Major anatomic defect of the genital tract is usually associated with **urinary tract abnormality (40%), skeletal malformation (12%),** and normal gonadal function
- ◆ While minor abnormality escapes attention, it is the moderate or severe form, which will produce gynecologic and obstetric problem.

## DEVELOPMENTAL ANOMALIES OF THE EXTERNAL GENITALIA

### PERINEAL OR VESTIBULAR ANUS

The entity is detected at birth. The usual anal opening site is evidenced by anal pit. The anal opening is situated either close to the posterior end of the vestibule or in the vestibule. Rarely, it is situated in the vagina (congenital rectovaginal fistula). The opening is usually sufficiently big and continence is present. There is no problem in future reproduction. The delivery should be by cesarean section (see p. 47).

If there are features of obstruction or the opening is situated high in the vagina, pull through operation is to be done bringing the anal end to the anal pit with prior colostomy.

### ECTOPIC URETER

The additional ureteric opening is usually in the vestibule close to the urethra or in the vagina. The

main symptom is uncontrollable wetness. Partial nephrectomy and ureterectomy may be indicated or implantation of the ectopic ureter into the bladder may be done.

## VAGINAL ABNORMALITIES

The significant abnormalities include:

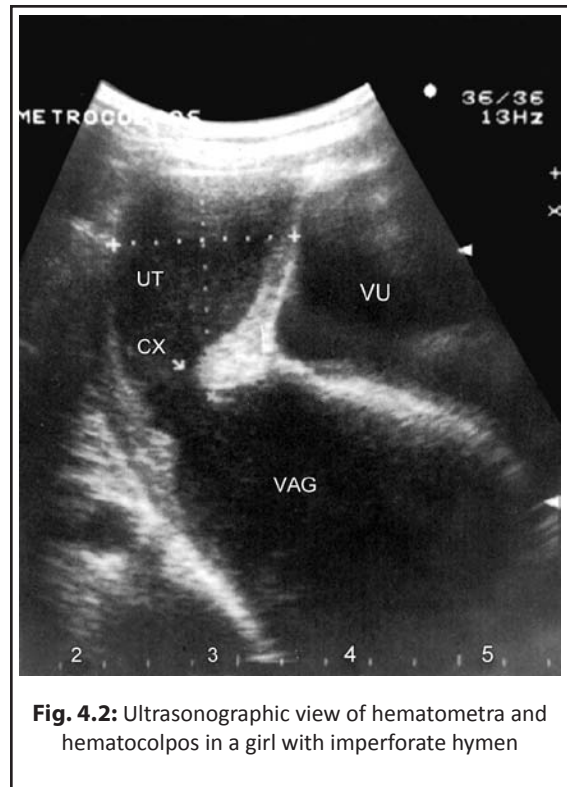
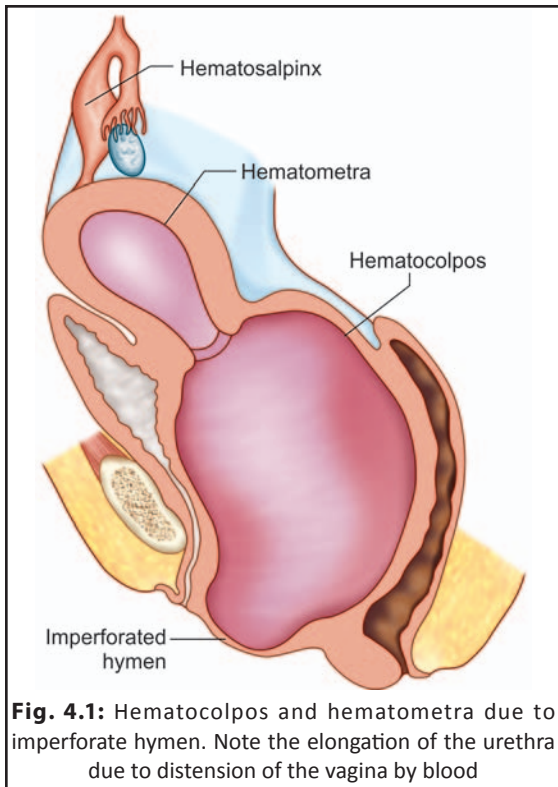
- **Narrow introitus** ▪ **Hymen abnormality**
- **Septum** ▪ **Agenesis** ▪ **Associated abnormalities**

### NARROW INTROITUS

The existence is revealed after marriage. Dyspareunia may be the first complaint, or it may be detected during investigation of infertility. Treatment is effective by manual stretching under general anesthesia or by surgical enlargement (Perineoplasty/Fenton's operation, see p. 592).

### HYMEN ABNORMALITY

Gross hymenal abnormality of significance is **imperforate hymen**. It is due to failure of disintegration of the central cells of the **Müllerian eminence** that projects into the **urogenital sinus** (see p. 36). The existence is almost always unnoticed until the girl attains the age of 14–16 years. As the uterus is functioning normally, the menstrual blood is pent up inside the vagina behind the hymen (cryptomenorrhea). Depending upon the amount of blood so accumulated, it first distends the vagina (hematocolpos). The uterus is next involved and the cavity is dilated (hematometra). In the late and neglected cases, the tubes may also be distended after the fimbrial ends are closed by adhesions (**Hematosalpinx**) (Fig. 4.1).



**Clinical features:** The girl is aged about 14–16 years. The chief complaints are periodic lower abdominal pain, which may be continuous, primary amenorrhea and urinary symptoms, such as frequency, dysuria or even retention of urine. In fact, in significant cases the presenting feature may be the retention of urine. **The cause of retention is due to elongation of the urethra** (Fig. 4.1).

Abdominal examination reveals a suprapubic swelling, which may be uterine or full bladder. Prior catheterization reveals the true state.

Vulval inspection reveals a tense bulging membrane of bluish coloration (Fig. 4.3). In majority, however, it is not the true hymen but the obstructing membrane is a transverse vaginal septum close to the inner aspect of the hymen. Rectal examination reveals the bulged vagina. **Ultrasonography** can make the diagnosis of **hematometra and hematocolpos** (Fig. 4.2).

In newborn (usually within one week of birth), accumulated mucus behind the imperforate membrane gives the clinical entity of mucocolpos. The secretion

is either from the desquamated vaginal epithelial cells or from the cervical glands.

### Treatment

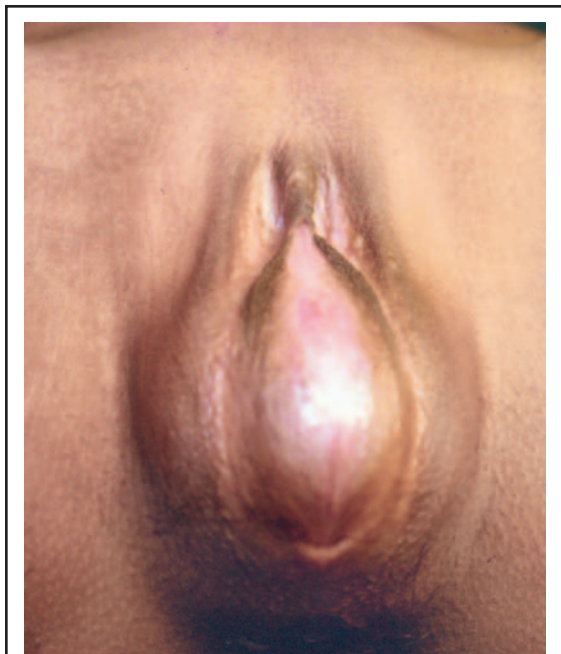Cruciate incision is made in the hymen. The quadrants of the hymen are partially excised not too close to the vaginal mucosa. Spontaneous escape of dark tarry colored blood is allowed (Fig. 4.4).

**Pressure from above should not be given. Internal examination should not be done.** The patient is put to bed with the head end raised. Antibiotic should be given. The residual pathology, if any, may be detected by internal examination after the next period is over.

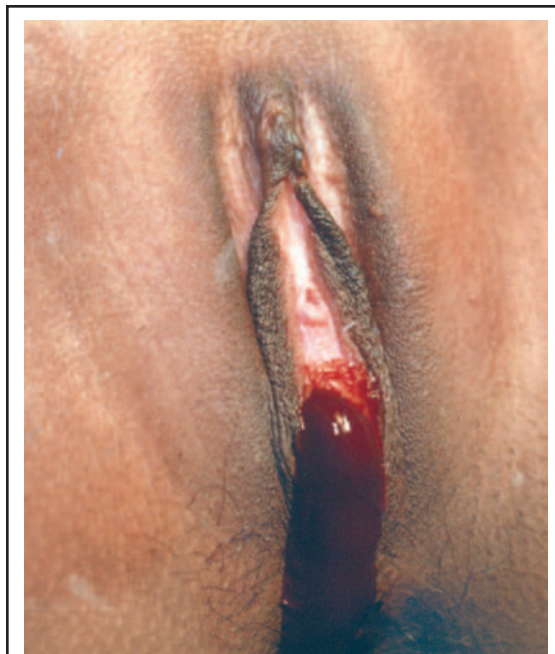## VAGINAL MALDEVELOPMENTS

### Common variations of vaginal maldevelopments

- ◆ Agenesis of vagina
- ◆ Failure of vertical fusion
- ◆ Failure of lateral fusion



**Fig. 4.3:** Tense bulging of the hymen in hematocolpos



**Fig. 4.4:** Spontaneous escape of dark tarry blood following incision

**Etiological factors** for Müllerian malformations are not clearly understood. The probable causes are: polygenic, multifactorial, teratogens, or environmental.

**Pathology of Müllerian malformation:** It may be due to failure of formation of the vaginal plate or due to its failure of canalization or cavitation.

**Vertical fusion defects** result in failure of fusion of the Müllerian system with urogenital sinus. It may also be due to incomplete or segmental canalization of the vagina.

**Disorders of lateral fusion** are also due to failure of the two Müllerian ducts to unite. This results in double uterovaginal canals. Such malformation may be obstructive or nonobstructive.

**Transverse vaginal septa** are due to faulty fusion or canalization of the urogenital sinus and the Müllerian ducts. **About 45% occur in the upper vagina, 40% in mid vagina and 15% in the lower vagina.** Septum located in the lower vagina is often complete and the signs and symptoms are similar to that of imperforate hymen. **Ultrasonography** is a useful investigation to

detect hematometra, hematocolpos, and also urinary tract malformations. **The principles of surgical treatment** are the same. Septum in the upper vagina is often perforated. Incision of a complete (imperforate) septum becomes easy when the upper vagina is distended. This reduces the risk of injury to adjacent organs. Otherwise abdominovaginal approach (see p. 44) is made.

**Longitudinal septum** of the vagina may be present when the distal parts of the **Müllerian ducts fail to fuse** (fusion failure). It may be associated with double uterus and double cervix. It may be asymptomatic and needs no treatment. But it may cause dyspareunia or may obstruct delivery. In such circumstances, the septum is to be excised. Results of surgery are good in terms of achieving pregnancy.

#### **PARTIAL AGENESIS OF UPPER VAGINA**

A segment of vagina may be atretic in the upper-third. It is often associated with hypoplasia or even absence of cervix. Uterus may be normal and functioning or malformed. Primary amenorrhoea (cryptomenorrhoea),

hematometra, hematocolpos, cyclic lower abdominal pain and presence of lower abdominal mass (as felt per abdomen or per rectum) point to the diagnosis. Conventional treatment is hysterectomy. Currently, abdominovaginal approach is made to establish communication between the uterovaginal canal above and the newly created vagina below. Prosthesis is used to prevent restenosis. The result is, however, not always satisfactory though successful pregnancy and live birth have been reported. When hysterectomy is considered, ovaries should be conserved. This gives the benefit of endogenous estrogen. Assisted reproductive technology would be the option, when desired, using a surrogate uterus.

### COMPLETE AGENESIS

Complete agenesis of the vagina is almost always associated with absence of uterus. There is, however, presence of healthy gonads and fallopian tubes. The patient is phenotypically female, with normal female karyotype pattern. **The entity is often associated with urinary tract (40%) and skeletal (12%) malformation.** This is called **Mayer-Rokitansky-Küster-Hauser syndrome**. The patient usually seeks advice for primary amenorrhea and dyspareunia.

**Treatment** of such patients needs repeated psychological counseling. Often they are depressed concerning their sexual and reproductive life. Treatment options are: (1) Nonsurgical, (2) Surgical.

1. **Nonsurgical method:** Repeated use of graduated vaginal dilators for a period of 6–12 months. Presence of a vaginal dimple (1 cm) is often seen. This method (Frank, 1938) is a simple and effective one.
2. **Surgical methods** various procedures of vaginal reconstruction (vaginoplasty) are done.
  - a. **McIndoe-Reed procedure (1938):** A space is created digitally between the bladder and the rectum. Split thickness skin graft is used over a mould. This mould is kept in this neovaginal space.
  - b. **Williams Vulvovaginoplasty (1976):** A vaginal pouch is created from skin flaps of labia majora in the midline. This is not done these days.
  - c. **Vaginoplasty with amnion graft** (Chakraborty, Konar, 2004) see p. 456.



**Complications of vaginoplasty:** During surgery VVF, RVF, infection and bleeding are the important ones. Dyspareunia, restenosis are common late complications.

### ASSOCIATED ABNORMALITIES

#### Associated abnormalities with:

- a. **Vesicovaginal fistula** is formed when the Müllerian eminence ruptures into the vesicourethral part of the cloaca instead of the pelvic part of the urogenital sinus (see Fig. 3.4D).
- b. **Rectovaginal fistula** when the Müllerian eminence opens in the dorsal segment of the endodermal cloaca.
- c. **Persistent urogenital sinus** with various irregularities of urethral and vaginal orifices in the sinus.

### UTERINE ANOMALIES

Uterine anomalies are often associated with vaginal maldevelopment.

*American Fertility Society (AFS) Classification of Müllerian Anomalies (1988) are (Figs 4.5A to F):*

**Class I:** Müllerian agenesis/Hypoplasia—segmental, **Class II:** Unicornuate uterus, **Class III:** Didelphys uterus, **Class IV:** Bicornuate uterus, **Class V:** Septate uterus, **Class VI:** Arcuate uterus, and **Class VII:** Diethylstilbestrol (DES)-related abnormality.

**Incidence of Müllerian abnormalities:** It varies between 3 and 4%. The incidence is found to be high in women suffering from recurrent miscarriage or preterm deliveries (5–20%).

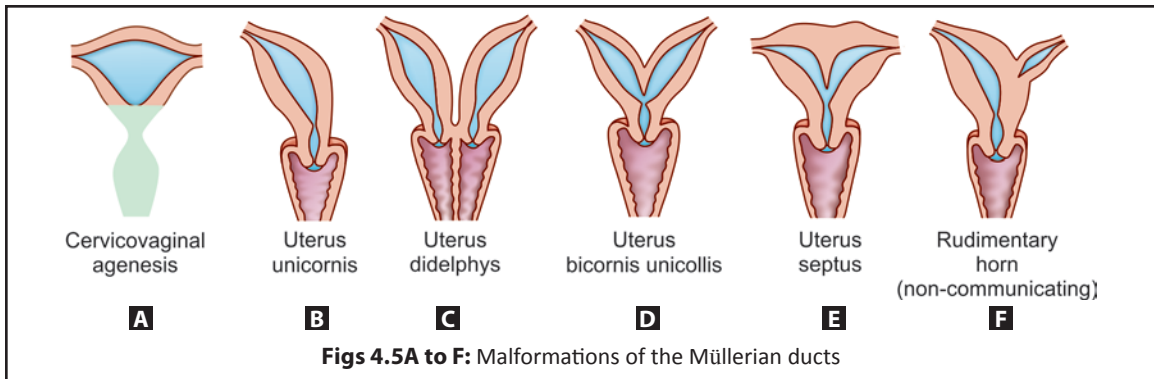
#### ■ Failure of development of one or both Müllerian ducts

The absence of both ducts leads to absence of uterus, including oviducts. There is absence of vagina as well. Primary amenorrhea is the chief complaint.

The absence of one duct leads to a unicornuate uterus with a single oviduct.

#### ■ Failure of recanalization of the Müllerian ducts

Agenesis of the upper vagina or of the cervix—This may lead to hematometra as the uterus is functioning (discussed above).



**Figs 4.5A to F:** Malformations of the Müllerian ducts

### ■ Failure of fusion of Müllerian ducts

In majority, the presence of deformity escapes attention. In some, the detection is made accidentally during investigation of infertility or repeated pregnancy wastage. In others, the diagnosis is made during D + E operation, manual removal of placenta or during cesarean section.

### Types of fusion anomalies (Figs 4.5A to F)

- ▶ **Arcuate (18%):** The cornual parts of the uterus remains separated. The uterine fundus looks concave with heart-shaped cavity outline (Fig. 4.6D).
- ▶ **Uterus didelphys (8%):** There is complete lack of fusion of the Müllerian ducts with a double uterus, double cervix and a double vagina (Fig. 4.5C).
- ▶ **Uterus bicornis (26%):** There is varying degrees of fusion of the muscle walls of the two ducts.
  - *Uterus bicornis bicollis:* There are two uterine cavities with double cervix with or without vaginal septum.
  - *Uterus bicornis unicollis:* There are two uterine cavities with one cervix. The horns may be equal or one horn may be rudimentary and have no communication with the developed horn (Figs 4.5D and 4.6F).
- ▶ **Septate uterus (35%):** The two Müllerian ducts are fused together but there is persistence of septum in between the two either partially (sub septate) or completely (Figs 4.5E and 4.6A and B).
- ▶ **Uterus unicornis (10%):** Failure of development of one Müllerian duct (Figs 4.5B and 4.6E).

- ▶ **DES-related abnormality (Fig. 4.6C):** It is due to DES exposure during intrauterine life. Varieties of malformations are included, e.g. **Vagina:** Adenosis, adenocarcinoma. **Cervix:** Cockscomb cervix, cervical collar. **Uterus:** Hypoplasia, T-shaped cavity, uterine synechiae. **Fallopian tube:** Cornual budding, abnormal fimbriae. Such cases are not seen now.

### Clinical features

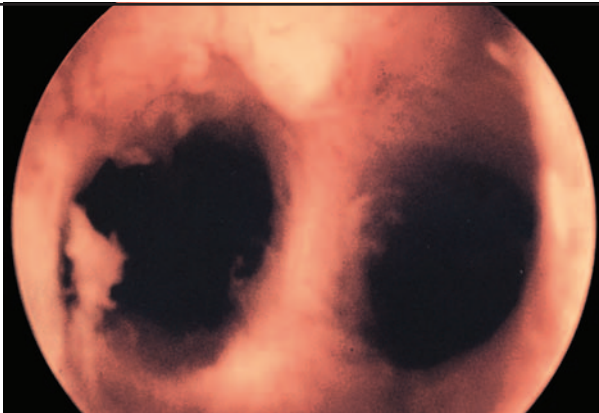
As previously mentioned, the condition may not produce any clinical manifestation.

### Gynecological

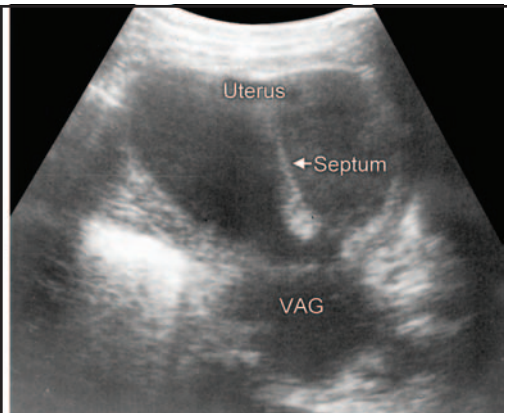
- i. **Infertility and dyspareunia** are often related in association with vaginal septum.
- ii. Dysmenorrhea in bicornuate uterus or due to cryptomenorrhea (pent up menstrual blood in rudimentary horn).
- iii. Menstrual disorders (menorrhagia, cryptomenorrhea) are seen. Menorrhagia is due to increased surface area in bicornuate uterus.

### Obstetrical

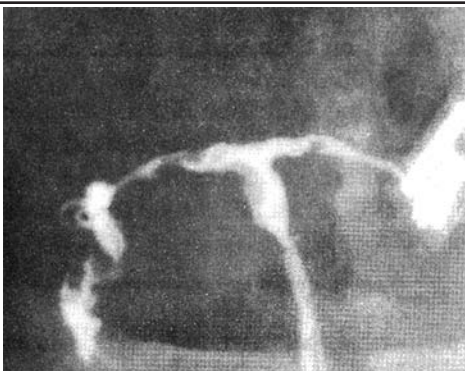
- i. Midtrimester abortion which may be recurrent.
- ii. Rudimentary horn pregnancy may occur due to transperitoneal migration of sperm or ovum from the opposite side. Cornual pregnancy (ectopic) inevitably ends in rupture around 16th week.
- iii. Cervical incompetence.
- iv. Increased incidence of malpresentation—transverse lie in arcuate or subseptate, breech in bicornuate, unicornuate or complete septate uterus.
- v. Preterm labor, IUGR, IUD.



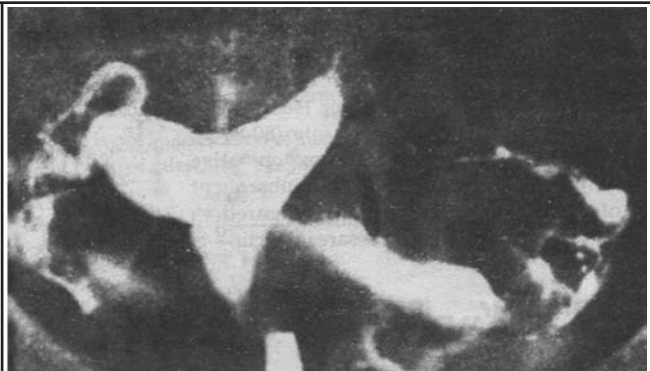**Fig. 4.6A:** Hysteroscopic view of a septate uterus



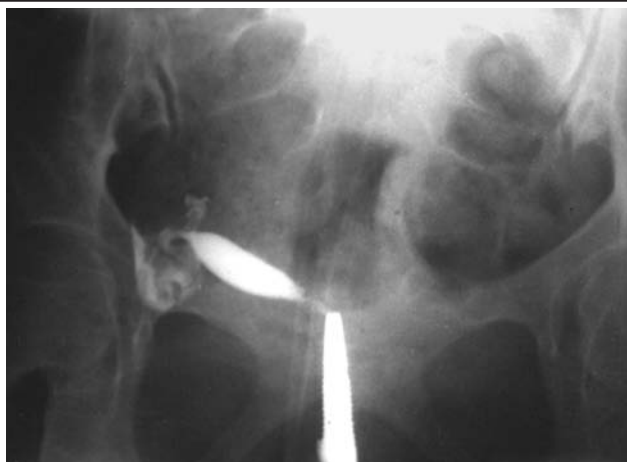**Fig. 4.6B:** Ultrasonographic view of a septate uterus



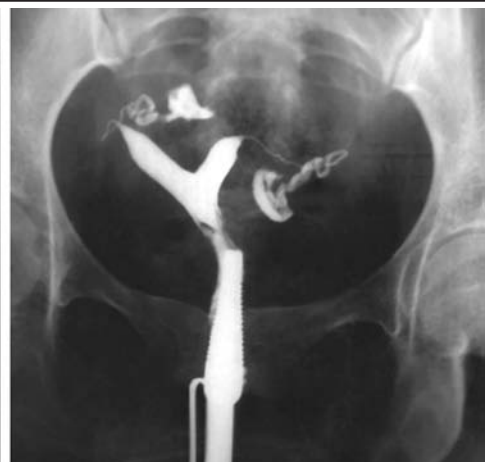**Fig. 4.6C:** Hystero-graphic view of T-shaped hypoplastic uterus—consistent with in utero-exposure to DES (p. 44)



**Fig. 4.6D:** Hystero-graphic view of an arcuate uterus confirmed by laparoscopy



**Fig. 4.6E:** Unicornuate uterus



**Fig. 4.6F:** Bicornuate uterus confirmed by laparoscopy

**Fig. 4.6:** Hysteroscopic (A); Ultrasonographic (B); Hystero-graphic diagnosis of congenital malformations of uterus (C, D, E and F)



- vi. Prolonged labor—due to incoordinate uterine action.
- vii. Obstructed labor—obstruction by the nongravid horn of the bicornuate uterus or rudimentary horn.
- viii. Retained placenta and postpartum hemorrhage where the placenta is implanted over the uterine septum.

**Diagnosis:** Internal examination reveals septate vagina and two cervixes. Passage of a sound can diagnose two separate cavities. In fact in significant number of cases, the clinical diagnosis is made during uterine curettage, manual removal of placenta or cesarean section. For exact diagnosis of the malformation, internal as well as external architecture of the uterus must be visualized. For this reason several investigations in **different combinations** are done, such as **hystero-graphy (see p. 588)**, **hysteroscopy (see p. 619)**, **laparoscopy (see p. 121)**, **ultrasonography (vaginal probe) (Fig. 4.6B)** and **magnetic resonance imaging (MRI)**. Ultrasonography and MRI are noninvasive procedures. Urological tract is also evaluated at the same time. **The renal tract abnormality in association with Müllerian abnormality is about 40%. Skeletal system anomaly (12%) is also associated.**

**Treatment:** Mere presence of any uterine malformation *per se* is not an indication of surgical intervention.

**Reproductive outcome:** Better obstetric outcome in **septate uterus (86%)**, **bicornuate uterus (50%)** has been mentioned. **Unicornuate uterus has very poor (40%) pregnancy outcome.** No treatment is generally effective. **Uterus didelphys** has best possibility of successful pregnancy (64%). Unification operation is generally not needed. Other causes of infertility or recurrent fetal loss must be excluded.

- **Rudimentary horn** should be excised to reduce the risk of ectopic pregnancy (8%)
- **Unification operation (bicornuate/septate uterus)** is, therefore, indicated in otherwise unexplained cases with uterine malformation. Abdominal metroplasty could be done either by excising the septum (Strassman, Jones, and Jones) or by incising the septum (Tompkins). Success rate

of abdominal metroplasty in terms of live birth is high (5–75%).

**Hysteroscopic metroplasty** is more commonly done. Resection of the septum can be done either by a resectoscope or by laser (see p. 622). **Advantages are:** (a) High success rate (80–89%), (b) Short hospital stay, (c) Reduced postoperative morbidity (infection or adhesions), and (d) Subsequent chance of vaginal delivery is high compared to abdominal metroplasty where cesarean section is mandatory.

## ABNORMALITIES OF THE FALLOPIAN TUBES

The tubes may be unduly elongated; may have accessory ostia or diverticula. Rarely, the tube may be absent on one side. These conditions may lower the fertility or favor ectopic pregnancy.

## ANOMALIES OF THE OVARIES

There may be **streak gonads** or gonadal dysgenesis, which are usually associated with errors of sex chromosomal pattern. No treatment is of any help. **Accessory ovary** (division of the original ovary into two) may be rarely (1 in 93,000) present. Rarely, **supernumerary ovaries** may be found (1 in 29,000) in the broad ligament or elsewhere. This can explain a rare event where menstruation continues even after removal of two ovaries.

## WOLFFIAN REMNANT ABNORMALITIES

The outer end of the Wolffian (Gartner) duct may be cystic, size of pea, often pedunculated (hydatid of Morgagni) and attached near the outer end of the tube. The tubules of the Gartner's duct may be cystic, the outer ones are Kobelt's tubules, the middle set, the epoophoron and the proximal set, the paroophoron. Small cyst may arise from any of the tubules. **A cystic swelling from the Gartner duct** may appear in the anterolateral wall of the vagina, which may be confused with cystocele.

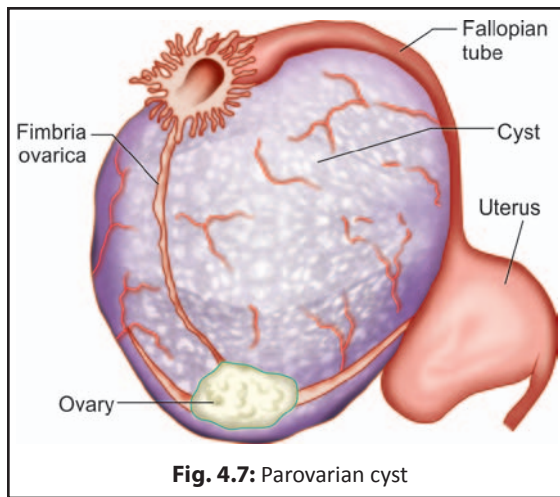


Fig. 4.7: Parovarian cyst

### PAROVARIAN CYST

It arises from the vestigial remnants of Wolffian tissue situated in the mesosalpinx between the tube and the ovary. This can attain a big size. The cyst is unilocular; the wall is thin and contains clear translucent fluid. The ovarian fimbria with the ovary is stretched over the cyst (Fig. 4.7). The wall consists of connective tissue lined by single layer of low columnar epithelium.

### OTHER ABNORMALITIES

1. **LABIA MINORA: Labial fusion:** (a) True due to developmental defect (b) Inflammatory (see p. 543).
2. **LABIA MAJORA:** (a) Hyperplastic or hypoplastic labia. (b) Abnormal fusion in adrenogenital syndrome (see p. 440).
3. **CLITORIS: Clitoral hypertrophy**—often associated with various intersex problems (see p. 440).
4. **PERINEUM:** Perineum differentiates from the area of contact between the urorectal septum (mesoderm) and the dorsal wall of cloaca (endoderm) at about 7th week. This site of contact between the two is the perineal body. Malformations of the perineum are rare. Imperforate anus, anal stenosis or fistula are the result of abnormal development of the urorectal septum (see p. 41). This is due to the posterior deviation of the septum as it approaches the cloacal membrane. Anal agenesis and fistula are rare. **The anal fistula may open into the posterior aspect of the vestibule of the vagina** (anovestibular fistula see p. 41).

### KEY POINTS

- Developmental anomalies of the external genitalia along with ambiguity of sex are usually genetic in origin.
- The clinical features with imperforate hymen usually appear at 14–16 years. Retention of urine may be the first symptom. Cruciate incision of the hymen is the treatment. Major anatomic defect of the genital tract is usually associated with normal gonadal function and urinary tract abnormalities.
- While minor abnormality escapes attention, it is the moderate or severe form which will produce gynecologic and obstetric problems (see p. 45). For exact diagnosis of malformation both the internal and external architecture of the uterus must be viewed. Failure of fusion of Müllerian ducts may lead to arcuate, bicornuate, septate or didelphys uterus.
- While gynecological symptoms are far and few but at times, they may produce infertility or obstetric problems such as recurrent miscarriage, cornual pregnancy, preterm labor or even obstructed labor (see p. 45).
- Presence of uterine malformation per se is not an indication of surgical correction. Unification operation is indicated in otherwise unexplained cases of infertility or repeated pregnancy wastage. Hysteroscopic metroplasty has got many advantages (see p. 47).
- Vaginal agenesis is most commonly due to Mayer-Rokitansky Kuster-Hauser Syndrome. In such a case urologic (40%) and skeletal (12%) anomalies are associated. Treatment may be nonsurgical or surgical (see p. 44).
- Nearly 15–20% of women with recurrent miscarriage are associated with malformation of the uterus.

# Puberty Normal and Abnormal

## PUBERTY

### Definition

**Puberty in girls is the period, which links childhood to adulthood.** It is the **period of gradual development of secondary sexual characters.** There are profound biological, morphological, and psychological changes that lead to full sexual maturity and eventually fertility.

### Morphological Changes

As described by Tanner and Marshall, **five** important physical changes are evident during puberty. **These are breast, pubic and axillary hair growth, growth in height, and menstruation.** Most of the changes occur gradually but only the menarche can be dated. Moreover, there is a lot of variations in the timing of the events. **The most common order is beginning of the growth spurt → breast budding (thelarche) → pubic and axillary hair growth (adrenarche) → peak growth in height → menstruation (menarche).** All these changes are usually completed between the age of 10 and 16 years.

Important controlling factors for onset of puberty are genetic, nutrition, body weight, psychologic state, social and cultural background, exposure to light and others. A girl, living in urban areas with good nutrition, adequate body weight and whose mother and sisters have early menarche, starts puberty early. Blind girls start menarche early.

## ENDOCRINOLOGY IN PUBERTY

The levels of gonadal steroids and gonadotropins are low until the age of 6–8 years. This is mainly due to the negative feedback effect of estrogen to

the hypothalamic pituitary system (Gonadostat). The gonadostat remains very sensitive (6–15 times) to the negative feedback effect, even though the level of estradiol is very low (10 pg/mL) during that time. As puberty approaches this negative feedback effect of estrogen is gradually lost (see p. 77). This results in some significant changes in the endocrine function of the girl.

### ◆ Hypothalamopituitary gonadal axis

The GnRH pulses from hypothalamus results in pulsatile gonadotropin secretion (first during the night then by the day time).

GnRH → FSH, LH → Estradiol

The tonic and episodic secretion of gonadotropins in prepubertal period is gradually changed to one of cyclic release in postpubertal period (details in p. 77, Fig. 7.6).

- ◆ **Thyroid gland** plays an active role in the hypothalamopituitary-gonadal axis.
- ◆ **Adrenal glands** (Adrenarche) increase their activity of sex steroid synthesis (androstenedione, DHA, DHAS) from about 7 years of age. Increased sebum formation, pubic and axillary hair and change in voice are primarily due to adrenal androgen production.
- ◆ **Gonadarche:** Increased amplitude and frequency of GnRH → ↑ secretion of FSH and LH → ovarian follicular development → ↑ estrogen. Gonadal estrogen is responsible for the development of uterus, vagina, vulva and also the breasts (see p. 50).
- ◆ **Leptin**, a peptide, secreted in the adipose tissue is also involved in pubertal changes and menarche (see p. 460).

## Menarche

The onset of first menstruation in life is called **menarche**. It may occur anywhere between 10 and 16 years, the **peak time being 13 years**. There is endometrial proliferation due to ovarian estrogen but when the level drops temporarily, the endometrium sheds and bleeding is visible. It denotes an intact hypothalamo-pituitary-ovarian axis, functioning ovaries, presence of responsive endometrium to the endogenous ovarian steroids and the presence of a patent uterovaginal canal. The **first period is usually anovular**. The ovulation may be irregular for a variable period following menarche and may take about 2 years for regular ovulation to occur. The menses may be irregular to start with.

## Growth

Growth in height in an adolescent girl is mainly due to hormones. The important hormones are growth hormone, estrogen and insulin like growth factor-1 (IGF-1). The bone or skeletal age is determined by X-ray of hand or knee.

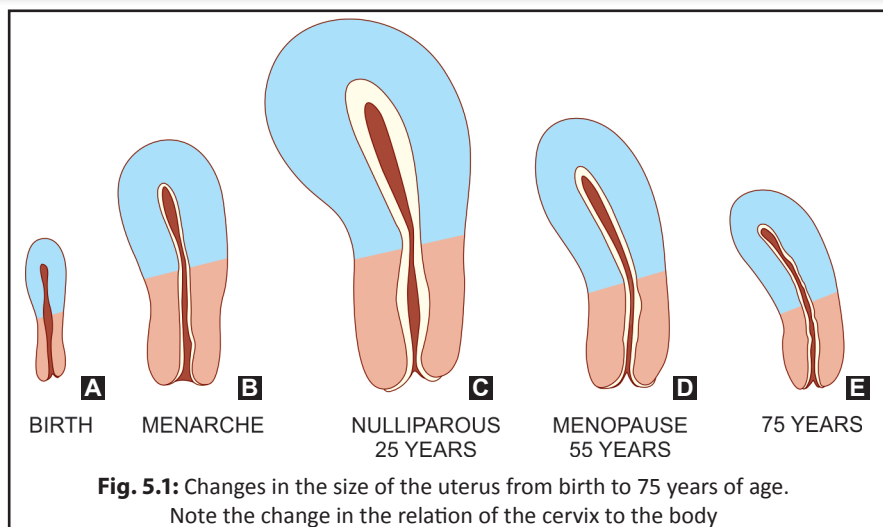
## Genital Organ Changes

**Ovaries** change their shape, the elongated shape becomes bulky and oval. The ovarian bulk is due to follicular enlargement at various stages of development and proliferation of stromal cells.

**The uterine body and the cervix ratio at birth is** about 1 : 2, the ratio becomes 1 : 1 when menarche occurs. Thereafter, the enlargement of the body occurs rapidly, so that the ratio soon becomes 2 : 1 (Fig. 5.1).

**TABLE 5.1 TANNER STAGES OF PUBERTAL DEVELOPMENT IN GIRLS**

Stage	Breast	Pubic hair
<b>Stage I</b>	Prepubertal state, elevation of papilla only	No pubic hair present
<b>Stage II</b>	Breast buds and papilla slightly elevated, and side of labia areola begins to enlarge. (Median age: 9.8 years)	Sparse, long hair on either majora. (Median age: 10.5 years)
<b>Stage III</b>	Further enlargement of entire breast tissue	Darker, coarser and curly hair over the mons pubis
<b>Stage IV</b>	Secondary mound of areola and papilla projecting above the breast tissue. (Median age: 12.1 years)	Adult type hair covering the mons only. (Median age: 12.0 years)
<b>Stage V</b>	Areola recessed to general contour of breast. (Median age : 14.6 years)	Adult hair with an inverse triangle distribution (female escutcheon) covering the medial thighs. (Median age: 13.7 years)



**The vaginal changes** are more pronounced. A few layers of thin epithelium in a child become stratified epithelium of many layers. The cells are rich in glycogen due to estrogen. Doderlein's bacilli appear which convert glycogen into lactic acid; the vaginal pH becomes acidic, ranging between 4 and 5.

**The vulva** is more reactive to steroid hormones.

**The mons pubis and the labia minora** increase in size.

**Breast changes** are pronounced. Under the influence of estrogen, there is marked proliferation of duct systems and deposition of fat. The breast becomes prominent and round. Under the influence of progesterone, the development of acini increases considerably.

**Tanner staging:** According to Tanner, breast and pubic hair development at puberty are divided into five stages (Table 5.1).

### COMMON DISORDERS OF PUBERTY

- ▶ Precocious puberty
- ▶ Delayed puberty
- ▶ Menstrual abnormalities (amenorrhea, menorrhagia, dysmenorrhea)
- ▶ Others (infection, neoplasm, hirsutism, etc.) see Ch. 32.

## PRECOCIOUS PUBERTY

### DEFINITION

The term precocious puberty is reserved for girls who exhibit any secondary sex characteristics before the age of 8 or menstruate before the age of 10.

Precocious puberty may be isosexual where the features are due to excess production of estrogen. It may be heterosexual where features are due to excess production of androgen (from ovarian and adrenal neoplasm).

### TYPES OR CAUSES

The causes are tabulated in the Table 5.2.

### ETIOPATHOLOGY

#### Constitutional

**It is due to premature activation of hypothalamo-pituitary ovarian axis.** There is secretion of

**TABLE 5.2 CAUSES OF PRECOCIOUS PUBERTY**

#### **GnRH dependent—80% (complete, central, isosexual or true)**

- Constitutional—most common
- Juvenile primary hypothyroidism
- Intracranial lesions—trauma, tumor or infection

#### **Incomplete**

- Premature thelarche
- Premature puberche
- Premature menarche

#### **GnRH independent (precocious pseudopuberty or peripheral)**

(Excess estrogen or androgen)

#### **Ovary**

- Granulosa cell tumor
- Theca cell tumor
- Leydig cell tumor
- Chorionic epithelioma
- Androblastoma
- McCune-Albright syndrome

#### **Adrenal**

- Hyperplasia
- Tumor

#### **Liver**

- Hepatoblastoma

#### **Iatrogenic**

- Estrogen or androgen intake

gonadotropins and gonadal steroids due to premature release of GnRH. Bone maturation is accelerated, leading to premature closure of the epiphysis and curtailed stature. If menstruation occurs, they may be ovulatory. The changes in puberty progress in an orderly sequence.

#### **Intracranial lesions**

Meningitis, encephalitis, craniopharyngioma, neurofibroma or any tumor—hypothalamic or pineal gland.

**McCune-Albright syndrome** is characterized by sexual precocity, multiple cystic bone lesions (polyostotic fibrous dysplasia), endocrinopathies and café-au-lait spots on the skin. Sexual precocity is due to early and excessive estrogen production from

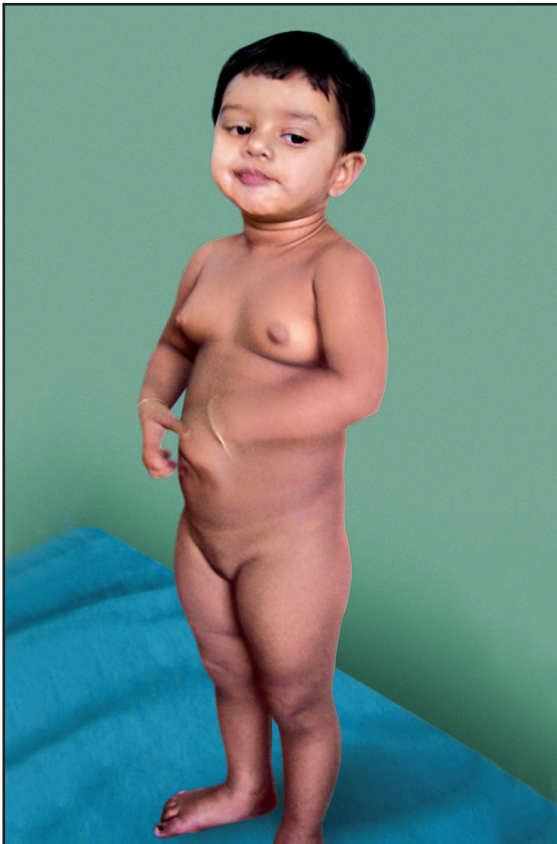the ovaries. FSH, LH levels are low. There may be associated hyperthyroidism, hyperparathyroidism, and acromegaly.

### Premature thelarche

**It is the isolated development of breast tissue before the age of 8** and commonly between 2 and 4 years of age. Either one or both the breasts may be enlarged (Fig. 5.2). There is no other feature of precocious puberty. It generally requires no treatment.

### Premature pubarche

**Premature pubarche is isolated development of axillary and or pubic hair prior to the age of 8 without other signs of precocious puberty.** The premature hair growth may be due to unusual sensitivity of endorgans to the usual low level of hormones in the blood during childhood. Rarely, there may be signs of excess androgen production



**Fig. 5.2:** Precocious puberty in a girl aged 2 years and 3 months

due to adrenal hyperplasia or tumor or androgenic ovarian tumor (Leydig cell tumor, androblastoma, etc.).

### Premature menarche

**Premature menarche is an isolated event of cyclic vaginal bleeding without any other signs of secondary sexual development.** The cause remains unclear but may be related to unusual endocrine sensitivity of the endometrium to the low level of estrogens.

Chorionic epithelioma, hepatoblastoma are the ectopic sources of human chorionic gonadotropin and may cause sexual precocity.

## DIAGNOSIS

### True precocious

**Constitutional type is the commonest one** but the rare one is to be kept in mind. The diagnosis is made by:

- ◆ History of early menarche of mother and sisters
- ◆ The pubertal changes occur in orderly sequence
- ◆ Tanner stages
- ◆ No cause could be detected.

The basic investigations, to confirm or to exclude some pathologic lesions, include:

- ◆ X-ray hand and wrist (non-dominant) for bone age. Acceleration of growth is one of the earliest clinical features of precocious puberty
- ◆ Pelvic sonography to exclude ovarian pathology
- ◆ Skull X-ray, CT scan, or MRI brain—to exclude intracranial lesion
- ◆ Serum hCG, FSH, LH
- ◆ Thyroid profile (TSH, T4)
- ◆ Serum estradiol, testosterone, 17 OH progesterone, dehydroepiandrosterone (DHEA).
- ◆ Electroencephalogram.

### Premature thelarche

- ◆ Somatic growth pattern is not accelerated
- ◆ Bone age is not advanced
- ◆ Nipple development is absent
- ◆ Vaginal smear shows negative estrogen effect.

### Premature pubarche

It may be due to adrenal or ovarian mischief. As such, the investigations are directed accordingly.

- ◆ An ovarian enlargement may not be palpable clinically. Examination under anesthesia or sonography is helpful
- ◆ IVP or CT scan is required to detect adrenal tumor.
- ◆ Estimations of serum 17  $\alpha$ -hydroxyprogesterone, DHEA-S and serum testosterone are to be done in suspected cases of adrenal mischief—hyperplasia or tumor.

If nothing abnormal is detected, then the diagnosis of idiopathic pubarche is made.

### Premature menarche

The other causes of vaginal bleeding, such as foreign body or injury has to be excluded. If the bleeding is cyclic, the diagnosis is confirmed.

### Remarks

Investigations must be carried out to rule out any pathology in the CNS, ovary, and adrenal. It should be borne in mind that even in cases when no cause can be detected in any of the types mentioned, the periodic evaluation at 6 monthly intervals is to be made to detect any life-threatening pathology at the earliest.

### TREATMENT

The treatment depends upon the cause. The exogenous estrogen therapy or its inadvertent intake should be stopped forthwith. Cortisone therapy for adrenal hyperplasia and surgery to remove the adrenal or ovarian tumor eliminate the excess source of either androgen or estrogen. The intracranial tumor requires neurosurgery or radiotherapy. Primary hypothyroidism needs thyroid replacement therapy.

### CONSTITUTIONAL OR IDIOPATHIC TYPE

#### The goals are:

- ◆ To reduce gonadotropin secretions.
- ◆ To suppress gonadal steroidogenesis or counteract the peripheral action of sex steroids.
- ◆ To decrease the growth rate to normal and slowing the skeletal maturation.
- ◆ To protect the girl from sex abuse.

### The drugs used are:

- ◆ **GnRH agonist therapy** arrests the pubertal precocity and growth velocity significantly. The agonists suppress the premature activation of hypothalamopituitary axis due to down regulation and thereby diminished estrogen secretion. **GnRH agonist therapy is the drug of choice in cases with GnRH dependent precocious puberty.** Therapy should be started as soon as the diagnosis is established. GnRH agonist therapy suppresses FSH, LH secretion, reverses the ovarian cycle, establishes amenorrhea, causes regression of breast, pubic hair changes, and other secondary sexual characteristics. This drug should be continued till the median age of puberty (see p. 49).

**Dose:** Buserelin nasal spray 100  $\mu$ g daily. It can slow down the process of skeletal maturation. Depot forms (goserelin or leuprolide) once a month can be used (see p. 525). Dose is adjusted to maintain the serum estradiol below 10 pg/mL.

- ◆ **Medroxyprogesterone acetate**—30 mg daily orally or 100–200 mg. IM weekly to suppress gonadal steroids. It can suppress menstruation and breast development but cannot change the skeletal growth rate.
- ◆ **Cyproterone acetate**—It acts as a potent progestogen, having agonist effects on progesterone receptors.

**Dose**—70–100 mg/m<sup>2</sup>/day orally for 10 days starting from 5th day of cycle.

- ◆ **Danazol**—It produces amenorrhea and arrest breast development. But there is no effect on growth rate or skeletal maturation.

### Duration of therapy

The drugs should be used up to the age of 11 years. However, individualization is to be done.

### PROGNOSIS

Prognosis varies considerably depending on the etiology. Overall prognosis is good with primary hypothyroidism, adrenal or ovarian tumors following treatment. For the CNS group, prognosis depends on neurological involvement and treatment outcome. Apart from the short stature due to accelerated bone

maturation, **the idiopathic group** have got a normal menstrual pattern in future. The fertility rate is also expected to be normal.

### DELAYED PUBERTY

**Puberty is said to be delayed when the breast tissue and/or pubic hair have not appeared by 13–14 years or menarche appears as late as 16 years.** The normal upper age limit of menarche is 15 years.

**TABLE 5.3 CAUSES OF DELAYED PUBERTY**

- ◆ **Hypergonadotropic hypogonadism** (see p. 453)
  - Gonadal dysgenesis, 45 XO
  - Pure gonadal dysgenesis 46 XX, 46 XY
  - Ovarian failure 46 XX
- ◆ **Hypogonadotropic hypogonadism** (see p. 451)
  - Constitutional delay
  - Chronic illness, malnutrition
  - Primary hypothyroidism
  - Isolated gonadotropin deficiency (Kallmann's syndrome)
  - Intracranial lesions—tumors: craniopharyngioma, pituitary adenomas
- ◆ **Eugonadism**
  - Anatomical causes (see Ch. 4)
    - Müllerian agenesis
    - Imperforate hymen
    - Transverse vaginal septum
  - Androgen insensitivity syndrome

### Treatment

Treatment is directed according to the etiology. Assurance, improvement of general health and treatment of any illness may be of help in non-endocrinal causes. Cases with hypogonadism may be treated with cyclic estrogen. Unopposed estrogen 0.3 mg (conjugated estrogen) daily is given for first 6 months. Then combined estrogen and progestin, sequential regimen is started (see Ch. 6). Cases of hypergonadotropic hypogonadism should have chromosomal study to exclude intersexuality (see p. 439).

### PUBERTY MENORRHAGIA

**Menstrual abnormality in adolescents are common.** The periods may be heavy, irregular or scanty initially.

Eventually the majority of these teenaged girls establish a normal cycle and are fertile.

### The important causes of menorrhagia are:

- i. **Dysfunctional uterine bleeding** (95%). Anovulatory cycles → unopposed estrogen → endometrial hyperplasia → prolonged and heavy periods (see p. 189).
- ii. **Endocrine dysfunction:**
  - ◆ Polycystic ovary syndrome (PCOS, see p. 459).
  - ◆ Hypo- or hyperthyroidism.
- iii. **Hematological:**
  - ◆ Idiopathic thrombocytopenic purpura (see p. 185).
  - ◆ Von-Willebrand's disease (see p. 185).
  - ◆ Leukaemia.
- iv. **Pelvic tumors:**
  - ◆ Fibroid uterus (see p. 272).
  - ◆ Sarcoma botryoides (see p. 369).
  - ◆ Estrogen producing ovarian tumor (see p. 384, 385).
- v. **Pregnancy complications** (abortion).

**Diagnosis** is made by careful history taking and thorough clinical examination.

Evaluation is especially indicated if the menstrual interval is < 22 days or > 44 days, lasts longer than one week or the bleeding is too heavy that anemia develops.

**Investigations** are planned according to the clinical diagnosis. Investigations include, routine hematological examination, including bleeding time, clotting time, platelet count. Thyroid profile (TSH, T<sub>3</sub>, T<sub>4</sub>), clotting profile, and imaging study of the pelvis by ultrasonography may be needed. EUA and uterine curettage are rarely needed to exclude any pelvic pathology (pregnancy complications). The curetted material is sent for histopathological study.

**Management:** The girl needs adequate explanation, reassurance and psychological support. Rest and correction of anemia are helpful in majority of the cases.

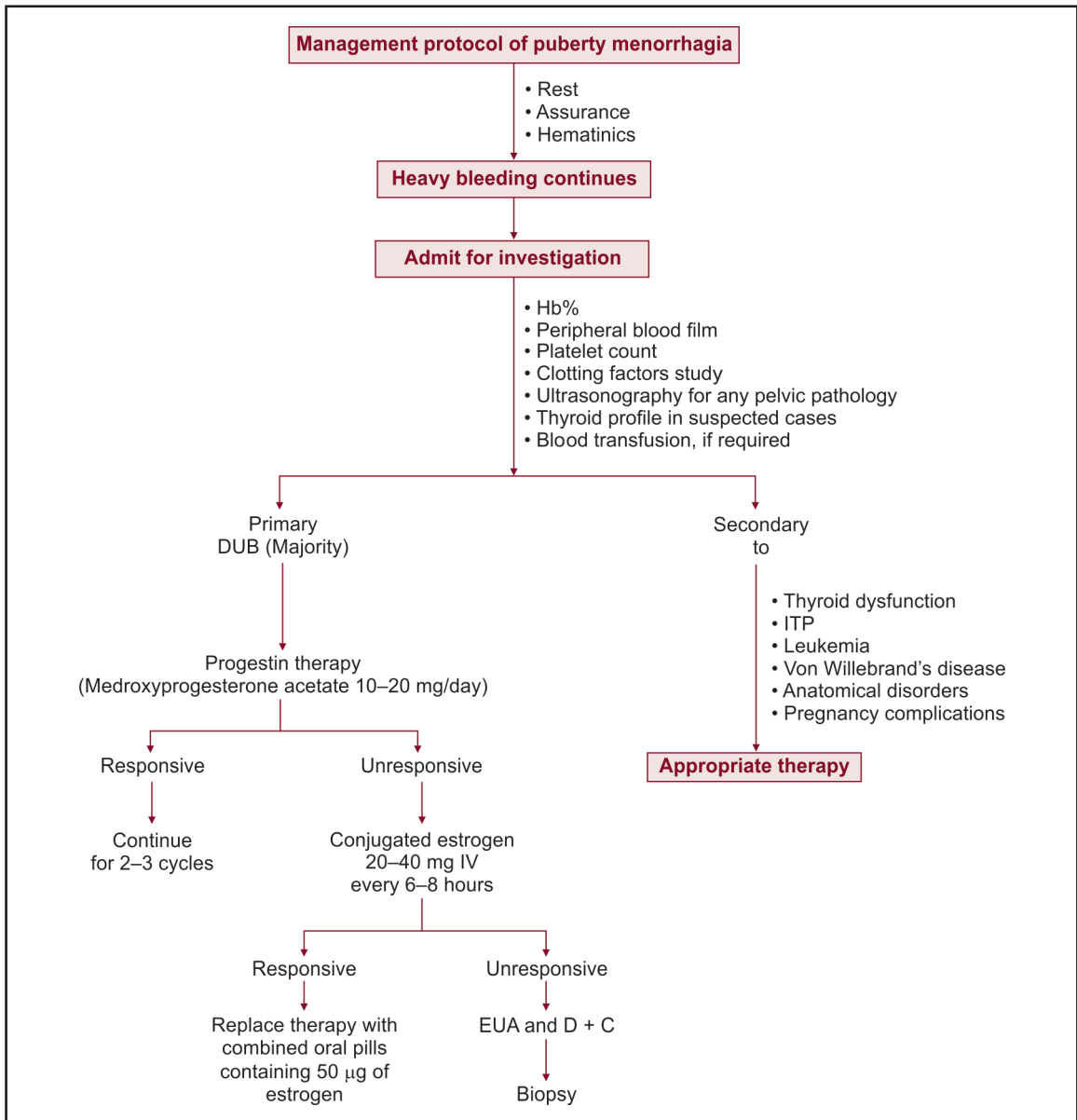
Therapy with hematinics or even blood transfusion may be needed. In refractory cases, proge-



strogens, such as medroxyprogesterone acetate or norethisterone 5 mg thrice daily is given till bleeding stops. Usually, the bleeding is controlled within 3–7 days. Medication is continued for 21 days. The condition usually becomes normal following 2–3 courses and then normal cycles resume. In

emergency, conjugated equine estrogen 20–40 mg IV is given every 6–8 hours. Once the bleeding is controlled, combined oral pills are started (Flowchart 5.1).

Regular menstrual cycle will be established once the hypothalamo-pituitary-ovarian axis is matured.



**KEY POINTS**

- ▶ Puberty in girls is the period that binds childhood to adulthood.

The most common order of changes is beginning of growth spurt → Enlargement of the breast buds → Appearance of pubic hair → Axillary hair → Peak growth in height → Menstruation (menarche).

Uterine body and cervix ratio becomes 1 : 1 at menarche from 1 : 2 at birth. The ratio is 2 : 1 in adult.

- ▶ The term precocious puberty is reserved to those who exhibit any secondary sex characteristic before the age of 8 or menstruate before the age of 10. The common cause being constitutional.

The exact etiology of GnRH dependent (true) precocious puberty is not known. Central nervous system disease may be present in nearly 30% of cases. GnRH independent (pseudo) precocious puberty is mostly related to an ovarian or adrenal pathology.

- ▶ Life-threatening neoplasms (ovary, adrenal or CNS system) must be ruled out when a girl with precocious puberty is seen.

- ▶ The basic investigations include X-ray hand and wrist for bone age, pelvic sonography, skull X-ray, CT or MRI brain and electroencephalogram. Serum levels of FSH, LH, hCG, thyroid profile, 17 OH progesterone and testosterone are measured.

- ▶ The primary aim of management for a girl with precocious puberty is to (i) reduce the secretion of gonadotropins. (ii) block the peripheral action of sex steroids and (iii) slow down the growth rate, including skeletal maturation.

- ▶ GnRH agonist is the drug of choice. It suppresses FSH, LH secretion, reverses ovarian cycle, establishes amenorrhea, causes regression of breast, pubic hair changes and other secondary sexual characteristics (see p. 53).

The other drugs used for constitutional type to suppress the premature activation of hypothalamo-pituitary-gonadal axis are—medroxyprogesterone acetate, cyproterone acetate, and danazol.

- ▶ Delayed puberty is said to occur when the breast tissues and/or pubic hair have not appeared by 13–14 years or menarche as late as 17 years.

- ▶ Ovarian failure and chromosomal anomalies are the common causes of delayed puberty. Estimation of serum gonadotropins is important to differentiate hypogonadotropic from hypergonadotropic causes (Table 5.3).

- ▶ Initial periods may be excessive due to anovulation.

- ▶ Menstruation just after puberty and just before menopause are mostly anovulatory and often irregular in frequency.

- ▶ The important cases of puberty menorrhagia are: DUB, PCOS, thyroid disorders, hematological, pelvic tumors or pregnancy complications (see p. 54).

- ▶ Pubertal menorrhagia should be treated with rest, assurance, hematinics and blood transfusions. Hypothyroidism and thrombocytopenic purpura are to be excluded. Pelvic ultrasonography is needed to exclude any organic lesion. In refractory cases, progestins or conjugated estrogen are effective failing which, EUA and uterine curettage are to be done. The materials should be histologically examined.

# Menopause

## DEFINITION

Menopause means *permanent cessation of menstruation at the end of reproductive life due to loss of ovarian follicular activity. It is the point of time when last and final menstruation occurs.*

The clinical diagnosis is confirmed following stoppage of menstruation (amenorrhea) for twelve consecutive months without any other pathology. As such, a woman is declared to have attained menopause only retrospectively. Premenopause refers to the period prior to menopause, postmenopause to the period after menopause and perimenopause to the period around menopause (40–55 years).

**Climacteric** is the period of time during which a woman passes from the reproductive to the non-reproductive stage. This phase covers 5–10 years on either side of menopause.

**Perimenopause** is the part of the climacteric when the menstrual cycle is likely to be irregular.

**Postmenopause** is the phase of life that comes after the menopause.

## AGE OF MENOPAUSE

**Age at which menopause occurs is genetically predetermined. The age of menopause is not related** to age of menarche or age at last pregnancy. It is also not related to number of pregnancy, lactation, use of oral pill, socioeconomic condition, race, height or weight. Thinner women have early menopause. However, cigarette smoking and severe malnutrition may cause early menopause. The age of menopause ranges between 45–55 years, average being 50 years.

## CLINICAL IMPORTANCE

Due to increased life expectancy, specially in affluent society, about one-third of life span will be spent during the period of estrogen deprivation stage with long-term symptomatic and metabolic complications.

## ENDOCRINOLOGY OF CLIMACTERIC AND MENOPAUSE

### Hypothalamopituitary Gonadal Axis

Few years prior to menopause, along with depletion of the ovarian follicles, the follicles become resistant to pituitary gonadotropins. As a result, effective folliculogenesis is impaired with diminished estradiol production. There is a significant fall in the level of serum estradiol from 50–300 pg/mL before menopause to 10–20 pg/mL after menopause. **This decreases the negative feedback effect on hypothalamopituitary axis resulting in increase in FSH. The increase in FSH is also due to diminished inhibin.** Inhibin, a peptide, is secreted by the granulosa cells of the ovarian follicle. The increase of LH occurs subsequently.

Disturbed folliculogenesis during this period may result in anovulation, oligo-ovulation, premature corpus luteum or corpus luteal insufficiency. The sustained level of estrogens may even cause endometrial hyperplasia and clinical manifestation of menstrual abnormalities prior to menopause.

The mean cycle length is significantly shorter. This is due to shortening of the follicular phase of the cycle. Luteal phase length remaining constant.

Ultimately, no more follicles are available and even some exist, they are resistant to gonadotropins.

Estradiol production drops down to the optimal level of 20 pg/mL → no endometrial growth → absence of menstruation.

### Estrogens

Following menopause, the predominant estrogen is estrone and to a lesser extent estradiol. Serum level of estrone (30–70 pg/mL) is higher than that of estradiol (10–20 pg/mL). The major source of estrone is peripheral conversion (aromatization) of androgens from adrenals (mainly) and ovaries. The aromatization occurs at the level of muscle and adipose tissue. The trace amount of estradiol is derived from peripheral conversion of estrone and androgens. Compared to estradiol, estrone is biologically less (about one-tenth) potent.

With times, the sources fail to supply the precursors of estrogen and about 5–10 years after menopause, there is a sharp fall in estrogen and also the trophic hormones. The woman is said to be in a state of true menopause.

**Androgens:** After menopause, the stromal cells of the ovary continue to produce androgens because of increase in LH. The main androgens are androstenedione and testosterone. Though the secretion of androgens from postmenopausal ovary are more, their peripheral levels are reduced due to conversion of androgens to estrone in adipose tissue. However, the cumulative effect is a decrease in estrogen: androgen ratio. This results in increased facial hair growth and change in voice.

As the obese patient converts more androgens into estrone, they are less likely to develop symptoms of estrogen deficiency and osteoporosis. But, they are vulnerable to endometrial hyperplasia and endometrial carcinoma.

**Progesterone:** A trace amount of progesterone detected is probably adrenal in origin.

### Gonadotropins

The secretions of both FSH and LH are increased due to **absent negative feedback effect of estradiol and inhibin** or due to enhanced responsiveness of pituitary to GnRH. Rise in FSH is about 10–20 fold whereas that of LH is about 3-fold. GnRH pulse secretion is increased both in frequency and amplitude. During menopause, there is fall in the

level of prolactin and inhibin. Fall in the level of inhibin (see ch. 7), lead to increase in the level of FSH from the pituitary. Ultimately, due to physiologic aging GnRH and both FSH, LH decline along with decline of estrogens.

### ORGAN CHANGES

**Ovaries** shrink in size, become wrinkled and white. There is thinning of the cortex with increase in medullary components. There is abundance of stromal cells which have got secretory activity.

**Fallopian tubes** show feature of atrophy. The muscle coat becomes thinner, the cilia disappear and the plicae become less prominent.

**The uterus** becomes smaller and the ratio between the body and the cervix reverts to the 1:1 ratio. The endometrium becomes thin and atrophic. In some women, however, with high endogenous estrogens, the endometrium may be proliferative or even hyperplastic. The cervical secretion becomes scanty.

**The vagina** becomes narrower due to gradual loss of elasticity. The vaginal epithelium becomes thin. The rugae progressively flatten. There is no glycogen. Doderlein's bacillus is absent. The vaginal pH becomes alkaline. Maturation index (parabasal, intermediate and superficial cells) is 10/85/5.

**The vulva** shows features of atrophy. The labia becomes flattened and the pubic hair becomes scantier. The end result is a narrow introitus.

**Breast fat** is reabsorbed and the glands atrophy. The nipples decrease in size. Ultimately, the breasts become flat and pendulous.

**Bladder and urethra** undergo similar changes to those of the vagina. The epithelium becomes thin and is more prone to damage and infection. There may be dysuria, frequency, urge or even stress incontinence.

**Loss of muscle tone** leads to pelvic relaxation, uterine descent and anatomic changes in the urethra and neck of the bladder. The pelvic cellular tissues become scanty and the ligaments supporting the uterus and vagina lose their tone. As such preexisting weakness gets aggravated.

### BONE METABOLISM

Normally, bone formation (osteoblastic activity) and bone resorption (osteoclastic activity) are in balance depending on many factors (age, endocrine, nutrition,

and genetic). Following menopause, there is loss of bone mass by about 3–5% per year. This is due to deficiency of estrogen. **Osteoporosis** is a condition where there is reduction in bone mass but bone mineral to matrix ratio is normal.

**Osteopenia** (WHO) refers to bone mineral density (BMD) that is  $>1.0$  to  $<2.5$  standard deviation (SD) below the young adult mean bone mass (“T” score). **Osteoporosis** is  $\geq 2.5$  SD below the young adult mean. A “Z” score is the BMD of the patient compared to average bone mass for same age sex and weight. A “Z” score  $>1SD$  below the mean is abnormal. Postmenopausal woman runs a high risk for fracture of bones due to osteoporosis. Parathyroid hormone (PTH) and IL-1 are involved in osteoporosis. Estrogen prevents osteoporosis by several mechanisms. It inhibits osteoclastic activity and inhibits release of IL-1 by monocytes. Estrogen increases absorption of calcium from the gut, stimulates calcitonin secretion from the C cells of the thyroid and increases 1, 25 dihydroxy vitamin D. All these lead to increased bone mineralization.

### CARDIOVASCULAR SYSTEM

Risk of cardiovascular disease is high in postmenopausal women **due to deficiency of estrogen**. **Estrogen prevents cardiovascular disease by several ways**. It increases HDL (particularly HDL 2) and decreases LDL and total cholesterol. It inhibits platelet and macrophage (foam cell) aggregation at the vascular intima. It stimulates the release of nitric oxide (NO) and prostacycline from vascular endothelium to dilate the blood vessels. It prevents atherosclerosis by its **antioxidant property**.

### MENSTRUATION PATTERN PRIOR TO MENOPAUSE

Any of the following patterns are observed:

- i. Abrupt cessation of menstruation (rare).
- ii. Gradual decrease in both amount and duration. It may be spotting or delayed and ultimately lead to cessation.
- iii. Irregular with or without excessive bleeding. One should exclude genital malignancy prior to declare it as the usual premenopausal pattern.

### MENOPAUSAL SYMPTOMS

In majority, apart from cessation of menstruation, no more symptoms are evident. In some women

symptoms appear. **The important symptoms and the health concerns of menopause are:**

- ♦ Vasomotor symptoms
- ♦ Urogenital atrophy
- ♦ Osteoporosis and fracture
- ♦ Cardiovascular disease
- ♦ Cerebrovascular disease
- ♦ Psychological changes
- ♦ Skin and Hair
- ♦ Sexual dysfunction
- ♦ Dementia and cognitive decline.

**Vasomotor symptoms:** The characteristic symptom of menopause is “hot flush”. **Hot flush is characterized by sudden feeling of heat followed by profuse sweating**. There may also be the symptoms of palpitation, fatigue and weakness. The physiologic changes with hot flushes are **perspiration** and **cutaneous vasodilatation**. Both these two functions are under central thermoregulatory control. Low estrogen level is a prerequisite for hot flush. Hot flush coincides with GnRH pulse secretion with increase in serum LH level. It may last for 1–10 minutes, and may be at times unbearable. Sleep may be disturbed due to night sweats. The **thermoregulatory center in association with GnRH center in the hypothalamus is involved in the etiology of hot flush**. Gonadotropins (LH) are thought to be involved.

**Genital and urinary system:** Steroid receptors have been identified in the mucous membrane of urethra, bladder, vagina and the pelvic floor muscles. Estrogen plays an important role to maintain the epithelium of vagina, urinary bladder and the urethra. Estrogen deficiency produces atrophic epithelial changes in these organs. This may cause dyspareunia and dysuria.

**Vagina:** Minimal trauma may cause vaginal bleeding. Dyspareunia, vaginal infections, dryness, pruritus and leucorrhea are also common. **The urinary symptoms are:** urgency, dysuria and recurrent urinary tract infection and stress incontinence.

**Sexual dysfunction:** Estrogen deficiency is often associated with decreased sexual desire. This may be due psychological changes (depression anxiety) as well as atrophic changes of the genitourinary system.

**Skin and hair:** There is thinning, loss of elasticity and wrinkling of the skin. Skin collagen content and thickness decrease by 1–2% per year. “Purse string” wrinkling around the mouth and “crow feet” around the eyes are the characteristics. Estrogen receptors are present in the skin and maximum are present in the facial skin. Estrogen replacement can prevent this skin loss during menopause. After menopause, there is some loss of pubic and axillary hair and slight balding. This may be due to low level of estrogen with normal level of testosterone.

**Psychological changes:** There is increased frequency of anxiety, headache, insomnia, irritability dysphasia and depression. They also suffer from dementia, mood swing and inability to concentrate. Estrogen increases opioid (neurotransmitter) activity in the brain and is known to be important for memory.

**Dementia:** Estrogen is thought to protect the function of central nervous system. Dementia and mainly Alzheimer disease are more common in postmenopausal women.

**Osteoporosis and fracture:** Following menopause there is decline in collagenous bone matrix resulting in osteoporotic changes. Bone mass loss and microarchitectural deterioration of bone tissue occurs primarily in trabecular bone (vertebra, distal radius) and in cortical bones. Bone loss increases to 5% per year during menopause. **Osteoporosis** may be **primary (Type 1)** due to estrogen loss, age, deficient nutrition (calcium, vit. D) or hereditary. It may be **secondary (Type 2)** to endocrine abnormalities (parathyroid, diabetes) or medication (see p. 62). Osteoporosis may lead to back pain, loss of height and kyphosis. Fracture of bones is a major health problem. Fracture may involve the vertebral body, femoral neck, or distal forearm (Colles’ fracture). Morbidity and mortality in elderly women following fracture is high.

**Detection of osteoporosis:** Computed tomography (CT) and specially the dual-energy X-ray absorptiometry (DEXA) are reliable methods to assess the bone-mineral density. Total radiation exposure is high with CT than DEXA.

Biochemical parameters to detect bone loss are measurement of urinary calcium/creatinine and hydroxyproline/creatinine ratios.

**Cardiovascular and cerebrovascular effects:** Oxidation of LDL and foam cell formation cause vascular endothelial injury, cell death and smooth muscle proliferation. All these lead to vascular atherosclerotic changes, vasoconstriction and thrombus formation (see p. 59).

Risks of ischemic heart disease, coronary artery disease and strokes are increased.

## DIAGNOSIS OF MENOPAUSE

1. Cessation of menstruation for consecutive 12 months during climacteric.
2. Appearance of menopausal symptoms ‘hot flush’ and ‘night sweats’.
3. Vaginal cytology – showing maturation index of at least 10/85/5 (Features of low estrogen).
4. Serum estradiol : < 20 pg/mL.
5. Serum FSH and LH : >40 mIU/mL (three values at weeks interval required).

## MANAGEMENT

### PREVENTION

**Spontaneous menopause** is unavoidable. However, **artificial menopause** induced by surgery (bilateral oophorectomy) or by radiation (gonadal) during reproductive period can to some extent be preventable or delayed.

**Counseling:** Every woman with postmenopausal symptoms should be adequately explained about the physiologic events. This will remove her fears, and minimize or dispel the symptoms of anxiety, depression and insomnia. Reassurance is essential.

## TREATMENT

### NONHORMONAL TREATMENT

- ♦ Lifestyle modification includes: Physical activity (weight bearing), reducing high coffee intake, smoking and excessive alcohol. There should be adequate calcium intake (300 mL of milk), reducing medications that causes bone loss (corticosteroids)
- ♦ Nutritious diet—balanced with calcium and protein is helpful

- ◆ Supplementary calcium—daily intake of 1–1.5 g can reduce osteoporosis and fracture
- ◆ Exercise—weight bearing exercises, walking, jogging
- ◆ Vitamin D—supplementation of vitamin D<sub>3</sub> (1500–2000 IU/day) along with calcium can reduce osteoporosis and fractures. Exposure to sunlight enhances synthesis of cholecalciferol (vitamin D<sub>3</sub>) in the skin
- ◆ Cessation of smoking and alcohol
- ◆ **Bisphosphonates** prevent osteoclastic bone resorption. It improves bone density and prevents fracture. It is preferred for older women. Women should be monitored with bone density measurement. Drug should be stopped when there is severe pain at any site. Commonly used drugs are etidronate and alendronate. Alendronate is more potent. Ibandronate and zoledronic acid are also effective and have less side effects. Bisphosphonates when used alone cannot prevent hot flushes, atrophic changes and cardiovascular disease. It is taken in empty stomach. Nothing should be taken by mouth for at least 30 minutes after oral dosing. Patient should remain upright for 30 minutes. **Side effects** include gastric and esophageal ulceration, osteomyelitis and osteonecrosis of the jaw
- ◆ **Fluoride** prevents osteoporosis and increases bone matrix. It is given at a dose of 1 mg/kg for short-term only. Calcium supplementation should be continued. Long-term therapy induces **side effects** (brittle bones)
- ◆ **Calcitonin** inhibits bone resorption. Simultaneous therapy with calcium and vitamin D should be given. It is given either by nasal spray (200 IU daily) or by injection (SC) (50–100 IU daily). It is used when estrogen therapy is contraindicated.
- ◆ **Selective estrogen receptor modulators (SERMs)** are tissue specific in action. Of the many SERMs, **raloxifene** has shown to increase bone mineral density, reduce serum LDL and to raise HDL<sub>2</sub> level. Raloxifene inhibits the estrogen receptors at the breast and endometrial tissues. **Risks of breast cancer and endometrial cancer are therefore reduced. Raloxifene does not improve hot flushes or urogenital atrophy.**

Evaluation of bone density (hip) should be done periodically. Risks of venous thromboembolism is increased

- ◆ **Clonidine**, an alpha adrenergic agonist may be used to reduce the severity and duration of hot flushes. It is helpful where estrogen is contraindicated (hypertension)
- ◆ **Thiazides** reduce urinary calcium excretion. It increases bone density specially when combined with estrogen.
- ◆ **Paroxetine**, a selective serotonin reuptake inhibitor, is effective to reduce hot flushes (both the frequency and severity).
- ◆ **Gabapentin** is an analog of gamma-aminobutyric acid. It is effective to control hot flushes.
- ◆ **Phytoestrogens** containing isoflavones are found to lower the incidence of vasomotor symptoms, osteoporosis and cardiovascular disease. It reduces the risk of breast and endometrial cancer.
- ◆ **Soy protein** is also found effective to reduce vasomotor symptoms. Soy protein acts as SERMS.

## HORMONE REPLACEMENT THERAPY (HRT)

The HRT is indicated in menopausal women to overcome the short-term and long-term consequences of estrogen deficiency.

### Indication of Hormone Replacement Therapy

- i. Relief of menopausal symptoms (see p. 59).
- ii. Prevention of osteoporosis (see p. 60).
- iii. To maintain the quality of life in menopausal years.

Special group of women to whom HRT should be prescribed:

- ▶ Premature ovarian failure
- ▶ Gonadal dysgenesis
- ▶ Surgical or radiation menopause

**HRT and Osteoporosis:** HRT prevents bone loss and stimulate new bone formation. HRT increases BMD by 2–5% and reduces the risk of vertebral and hip fracture (25–50%). Estrogen is found to play a direct role, as

### BENEFITS OF HORMONE REPLACEMENT THERAPY (HRT)

- ◆ Improvement of vasomotor symptoms (70–80%)
- ◆ Improvement urogenital atrophy
- ◆ Increase in bone mineral density (2–5%)
- ◆ Decreased risk in vertebral and hip fractures (25–50%)
- ◆ Reduction in colorectal cancer (20%)
- ◆ Possibly cardioprotection

TABLE 6.1

### RISK FACTORS FOR OSTEOPOROSIS IN A WOMAN

- Family history
- Age—Elderly
- Race—Asian, White race
- Lack of estrogen
- Body weight—Low BMI
- Early menopause—Surgical, radiation
- Dietary—↓ Calcium and ↓ Vitamin D, ↑ Caffeine, ↑ Smoking
- Sedentary habit
- Drugs—Heparin, corticosteroids, GnRH analogue
- Diseases—Thyroid disorders, hyperparathyroidism malabsorption, multiple myeloma.

receptors have been found in the osteoblasts. Women receiving HRT should supplement their diet with an extra 500 mg of calcium daily. **Total daily requirement of calcium in postmenopausal women is 1.5 g.**

**HRT is thought to be cardiovascular protective.** LDL on oxidation produces vascular endothelial injury and foam cell (macrophage) formation. These endothelial changes ultimately lead to intimal smooth muscle proliferation and atherosclerosis. Estrogen prevents oxidation of LDL, as it has got **antioxidant properties.**

TABLE 6.2

### RISK FACTORS FOR CARDIOVASCULAR DISEASE

- |                           |                              |
|---------------------------|------------------------------|
| • Hypertension            | • Smoking habit              |
| • Familial hyperlipidemia | • Impaired glucose tolerance |

In postmenopausal women, there is some amount of insulin resistance and hyperinsulinemia.

Hyperinsulinemia induces atherogenesis. Estrogen improve glucose metabolism.

### RISKS OF HORMONE REPLACEMENT THERAPY

- a. **Endometrial cancer:** When estrogen is given alone to a woman with intact uterus, it causes endometrial proliferation, hyperplasia and carcinoma. It is therefore advised that a progestogen should be added to ERT to counter balance such risks.
- b. **Breast cancer:** Combined estrogen and progestin replacement therapy, increases the risk of breast cancer slightly (RR 1.26). Adverse effects of hormone therapy are related to the dose and duration of therapy.
- c. **Venous thromboembolic (VTE) disease** has been found to be increased with the use of combined oral estrogen and progestin (Table 6.3). Transdermal estrogen use does not have the same risk compared to oral estrogen.
- d. **Coronary heart disease (CHD):** Combined HRT therapy shows a relative hazard (RR, 1.29) of CHD. Hypertension has not been observed to be a risk of HRT.
- e. **Lipid metabolism:** An increased incidence of gallbladder disease has been observed following ERT due to rise in cholesterol (in bile).
- f. **Dementia, Alzheimer** disease are increased.

TABLE 6.3

### CONTRAINDICATIONS TO HRT

- ◆ Undiagnosed genital tract bleeding
- ◆ Estrogen dependent neoplasm in the body
- ◆ History of venous thromboembolism
- ◆ Active liver disease
- ◆ Gallbladder disease

### AVAILABLE PREPARATIONS FOR HORMONE REPLACEMENT THERAPY

The principal hormone used in HRT is estrogen. This is ideal for a woman who had her uterus removed (hysterectomy) already. But in a woman with an intact uterus, only estrogen therapy leads to endometrial hyperplasia and even endometrial carcinoma. Addition of progestins for last 12–14 days each month can



prevent this problem. **Commonly used estrogens** are conjugated estrogen (0.625–1.25 mg/day) or micronized estradiol (1–2 mg/day). **Progestins** used are medroxyprogesterone acetate (2.5–5 mg/day), micronized progesterone (100–300 mg/day) or dydrogesterone (5–10 mg/day).

**Considering the risks, hormone therapy should be used with the lowest effective dose and for a short period of time.** Low dose oral conjugated estrogen 0.3 mg daily is effective and has got minimal side effects. Dose interval may be modified as daily for initial 2–3 months then it may be changed to every other day for another 2–3 months and then every third day for the next 2–3 months. It may be stopped thereafter if symptoms are controlled.

**Oral estrogen regime:** Estrogen—conjugated equine estrogen 0.3 mg or 0.625 mg is given daily for woman who had hysterectomy.

**Estrogen and cyclic progestin:** For a woman with intact uterus estrogen is given continuously for 25 days and progestin is added for last 12–14 days.

### Continuous estrogen and progestin therapy

Continued combined therapy can prevent endometrial hyperplasia. There may be irregular bleeding with this regimen.

- ♦ **Subdermal implants:** Implants are inserted subcutaneously over the anterior abdominal wall using local anesthesia. 17  $\beta$  estradiol implants 25 mg, 50 mg or 100 mg are available and can be kept for 6 months. This method is suitable in patients after hysterectomy. Implants maintain physiological  $E_2$  to  $E_1$  ratio.
- ♦ **Percutaneous estrogen gel:** 1 g applicator of gel, delivering 1 mg of estradiol daily, is to be applied onto the skin over the anterior abdominal wall or thighs. Effective blood level of oestradiol (90–120 pg/mL) can be maintained.
- ♦ **Transdermal patch:** It contains 3.2 mg of 17  $\beta$  estradiol, releasing about 50  $\mu$ g of estradiol in 24 hours. Physiological level of  $E_2$  to  $E_1$  is maintained. It should be applied below the waist line and **changed twice a week.** Skin reaction, irritation and itching have been noted with their use.
- ♦ **Vaginal cream:** Conjugated equine vaginal estrogen cream 1.25 mg daily is very effective specially when associated with atrophic vaginitis.

It also reduces urinary frequency, urgency and recurrent infection. Women with symptoms of urogenital atrophy and urinary symptoms and who do not like to have systemic HRT, are suitable for such treatment.

- ♦ **Progestins:** In patients with history of breast carcinoma, or endometrial carcinoma, progestins may be used. It may be effective in suppressing hot flushes and it prevents osteoporosis. Medroxyprogesterone acetate 2.5–5 mg/day can be used.

**LNG-IUS** (see p. 480) with daily release of 10 microgram (see below) of levonorgestrel per 24 hours, it protects the endometrium from hyperplasia and cancer. At the same time it has got no systemic progestin side effects. Estrogen can be given by any route. It can serve as contraception and HRT when given in a perimenopausal women.

- ♦ **Tibolone:** Tibolone is a steroid (19-nortestosterone derivative) having weakly estrogenic, progestogenic and androgenic properties. It prevents osteoporosis, atrophic changes of vagina and hot flushes. It increases libido. Endometrium is atrophic. A dose of 2.5 mg per day is given.

TABLE 6.4

### MONITORING PRIOR TO AND DURING HRT

A base level parameter of the following and their subsequent check up (at least annually) are mandatory.

- ♦ Physical examination including pelvic examination.
- ♦ Blood pressure recording.
- ♦ Breast examination (see p. 565) and Mammography (see p. 565).
- ♦ Cervical cytology (see p. 110).
- ♦ Pelvic ultrasonography (TVS) to measure endometrial thickness (normal <5 mm).

Any irregular bleeding should be investigated thoroughly (endometrial biopsy, hysteroscopy).

Ideal serum level of estradiol should be 100 pg/mL during HRT therapy. Serum level of estradiol is useful to monitor the HRT therapy rather than that of serum FSH.

### Duration of HRT Use

Generally, use of HRT for a short period of 3–5 years have been advised. Reduction of dosage should be done as soon as possible. Menopausal women should maintain optimum nutrition, ideal body weight and perform regular exercise.

**Individual woman should be given informed choice as regard the relative merits and possible risks of continuing HRT.**

### PROGRESS IN HORMONE REPLACEMENT THERAPY

**Low Dose HRT**—Women with intact uterus with 0.3 mg conjugated equine estrogen (CEE) and Medroxy Progesterone acetate (MPA) 1.5 mg is found effective to control the vasomotor symptoms. Similarly 1 mg of estradiol and norethisterone acetate 0.5 mg orally, are also effective and have significant bone sparing effect. Progestogen is added in the HRT to minimize the adverse effects of estrogen. **Hormone therapy should be used with lowest effective dose and for the short period of time as possible.** Dose interval may be modified (see above) before stopping the therapy. To minimize the systemic adverse effects of progestogen, Levonorgestrel intrauterine delivery system (LNG-IUS) is being used. It is primarily used as a contraceptive (see p. 480). Estrogen component is delivered by oral or by transdermal route or as an implant. A small size LNG-IUS has been developed that releases 10 µg LNG per day. This reduced size LNG-IUS is suitable for the postmenopausal women as the size of the uterus is also small (p. 501).

### ABNORMAL MENOPAUSE

**Premature Menopause:** If the menopause occurs at or below the age of 40, it is said to be premature (details in p. 463). Often, there is familial diathesis.

Treatment by substitution therapy is of value (details in p. 531).

**Delayed Menopause:** If the menopause fails to occur even beyond 55 years, it is called delayed menopause.

The common causes are constitutional, uterine fibroids, diabetes mellitus and estrogenic tumor of the ovary. The cases should not be neglected. In the absence of palpable pelvic pathology, diagnostic curettage should be done and an early decision of hysterectomy should be taken in the face of increased incidence of endometrial carcinoma.

**Artificial Menopause:** Permanent cessation of ovarian function done by artificial means, e.g. surgical removal of ovaries or by radiation is called artificial menopause.

**Surgical Menopause:** Menstruating women who have bilateral oophorectomy, experience menopausal symptoms (see p. 59). It is sometimes more troublesome than natural menopause.

**Radiation Menopause:** The ovarian function may be suppressed by external gamma radiation in women below the age of 40. The castration is not permanent. The menstruation may resume after 2 years and even conception is possible. Intracavity introduction of radium can cause castration effect by destroying the endometrium and also by depressing the ovarian function. The menopausal symptoms are not so intense as found in surgical menopause or menopause following external radiation.

### KEY POINTS

- Menopause means permanent cessation of menstruation at the end of reproductive life due to ovarian follicular inactivity. The average age being 50 years. Menopause is genetically predetermined. It is not related to the number of pregnancies, race, socioeconomic conditions, education, height, weight, age at menarche or age of last childbirth.
- The initial endocrine change with the onset of menopause is decreased ovarian inhibin production and increase in pituitary FSH release. The amount of estrogen replacement in menopause is not dependent upon the level of FSH.
- There is gradual elevated levels of first the FSH and then LH. Simultaneously, estradiol levels fall to optimal 20 pg/mL when menopause sets in. There is increased androgen secretion from the ovarian stroma and from the adrenal. A trace amount of progesterone is adrenal in origin.

Contd...

Contd...

- Diagnosis is from the classic symptom of 'hot flush' (50%) and confirmed by elevated FSH levels to >100 mIU/mL and serum estradiol <20 pg/mL.
- In menopause, there is depletion of ovarian follicles with degeneration of granulosa and theca cells. Stromal cells produce androgens, which are converted to estrogens in peripheral body fat. Obese postmenopausal women, have higher levels of estrone, less hot flushes and osteoporosis. But risk of developing endometrial cancer is high for them.
- **Benefits of HRT are:** Improvement in vasomotor symptoms, urogenital atrophy, increase in BMD, reduced risk of vertebral and hip fractures, reduction colorectal cancer and possibly cardioprotection (see p. 62). Estrogen reduces the risk of late onset Alzheimer's disease. It is beneficial in symptomatic women.
- **Risks of HRT are:** Endometrial cancer, breast cancer, VTE and coronary heart disease (see p. 62).
- For a woman with intact uterus, progestin (for last 12–14 days) must be combined with estrogen. Otherwise unopposed estrogen therapy will increase the risk of endometrial hyperplasia and adenocarcinoma. Estrogen without a progestin is recommended for a postmenopausal women who had hysterectomy.
- **Contraindications** to HRT include undiagnosed genital tract bleeding, estrogen dependent neoplasm in the body, history of venous thromboembolism, active liver disease and gallbladder disease (see p. 62).
- **Estrogen may be administered** orally, subdermal implants, vaginal cream, percutaneous gel or by transdermal patch. Provided the women is monitored during the period of therapy (see Table 6.4), HRT can be continued as long as the benefits are desired. However, low dose and short period of therapy (3–5 years) is currently recommended.
- Dual energy X-ray absorptiometry (DEXA) is the most accurate method to measure bone density.
- **Indications of estrogen therapy in menopause are:** Presence of vasomotor symptoms, prevention of atrophic vaginitis, urethritis and osteoporosis. Estrogen increases calcium absorption and reduces bone reabsorption.
- LDL cholesterol increases the risk of coronary artery disease (CAD) while HDL protects CAD. Estrogen therapy decreases LDL cholesterol and increases HDL.
- **Premature menopause** is one when the menstruation stops at or below the age of 40. **Delayed menopause** is one when menopause fails to occur even beyond 55 years.

# Neuroendocrinology in Relation to Reproduction

The neuroendocrine mechanisms are the basic factors in the reproductive cycle. A transducer concept has been evolved in which the specialized neural cells of the hypothalamus function as the final common pathway to guide the appropriate anterior pituitary hormonal response.

## HYPOTHALAMUS

Hypothalamus plays an important role in the neuroendocrine regulation. Three well-defined areas are demarked—(i) supraoptic area; (ii) tuberal region; and (iii) mamillary region. Each region is further subdivided into areas, or nuclei (Fig. 7.1). Both a tonic and a cyclic center are located within

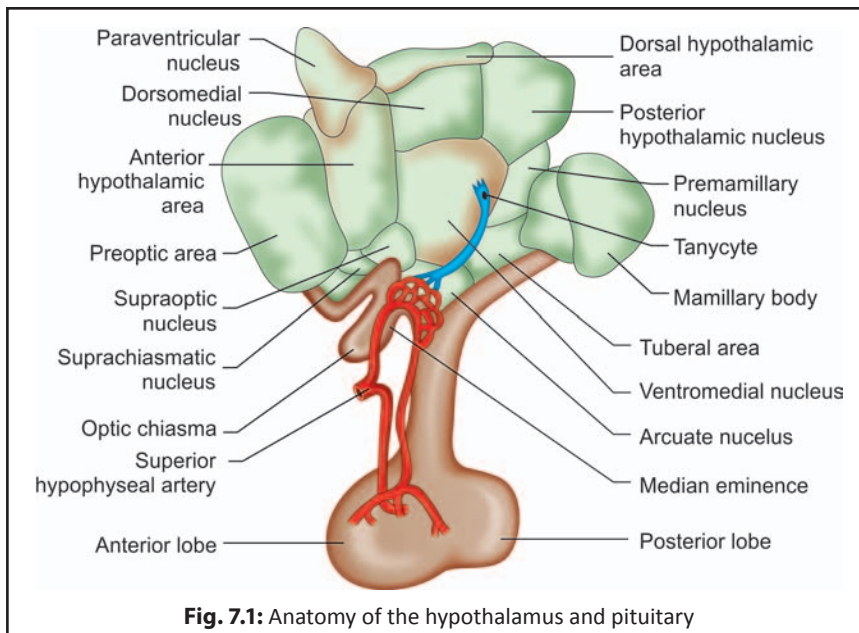
the hypothalamus resulting in changes in GnRH production.

## CONNECTIONS

- Cortical
- Pituitary

### Cortical

During recent years, the neural connection between the higher cortical centers and the hypothalamus has been well established. Apart from this, there are numerous output connections to pituitary gland as well other areas of the CNS, e.g. amygdala, hippocampus (limbic system), the thalamus and the pons (Fig. 7.6). Through this system, the ovarian and consequently the menstrual cycle are affected by various emotional and environmental factors.



**Fig. 7.1:** Anatomy of the hypothalamus and pituitary

## Pituitary

The hypothalamus is connected with the anterior lobe of the pituitary (adenohypophysis) through a special hypothalamopituitary portal system of vessels. However, it is directly connected with the posterior lobe of the pituitary (neurohypophysis) by the supraoptic and paraventricular nuclei (Fig. 7.1).

## SECRETIONS

The hypothalamus produces a series of specific releasing and inhibiting hormones which have got effect on the production of the specific pituitary hormones. These hormones are synthesized by the hypothalamic neurons and are released at the nerve endings around the tuber cinereum. Thereafter, these are drained to the pituitary through the hypothalamo-pituitary portal system of vessels.

### 1. Gonadotropin releasing hormone (GnRH)

The GnRH is also named as *luteinizing hormone releasing hormone* (LHRH). **GnRH is a decapeptide** and is concerned with the release, synthesis and storage of both the gonadotropins (FSH and LH) from the anterior pituitary. The divergent patterns of FSH and LH in response to a single GnRH are due to modulating influence of the endocrine environment specially the feedback effects of steroids on anterior pituitary gland. **GnRH is secreted by the arcuate nucleus of the hypothalamus (Fig. 7.1) in a pulsatile fashion.** Developmentally, these neurons originated from the olfactory area (see p. 464). The half-life of GnRH is very short (2–4 minutes). This is due to the cleavage of amino acid bonds between 5–6, 6–7 and 9–10 in circulation (Fig. 7.1A). GnRH is secreted into the portal circulation in **pulsatile fashion**. This pulse secretion varies in **frequency and amplitude** at different phases of menstrual cycle (see below). **GnRH stimulates anterior pituitary** for synthesis, storage and secretion of gonadotropins. There is decrease in receptor sensitivity when

gonadotroph cells (adenohypophysis) are exposed to GnRH stimulation continually. This is called '**down regulation**'. On the contrary, intermittent exposure of GnRH to gonadotrophs, increase the receptor sensitivity. This is called '**up-regulation**'. This variable response of anterior pituitary gonadotrophs to GnRH have been utilized in different clinical situation to get therapeutic benefits (see p. 525).

### 2. Prolactin inhibitory factor (PIF)

Prolactin secretion from the anterior pituitary seems to be under chronic inhibition by PIF. **Dopamine is the physiological inhibitor.**

### 3. Thyrotropin releasing hormone (TRH)

**The hormone TRH, a tripeptide** stimulates the release of not only the thyrotropin but also prolactin from the pituitary.

### 4. Corticotropin releasing hormone (CRH)

It is a tetradecapeptide.

### 5. Other secretions are—growth hormone releasing hormone (GHRH) and melanocytic releasing factor.

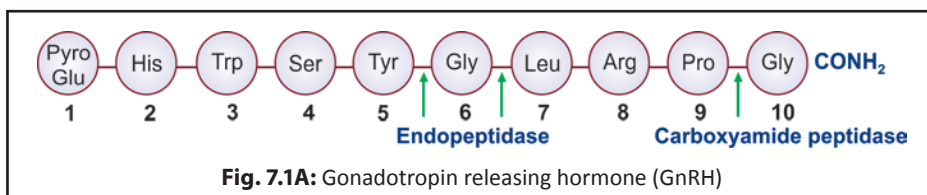
## CONTROL OF GnRH SECRETION

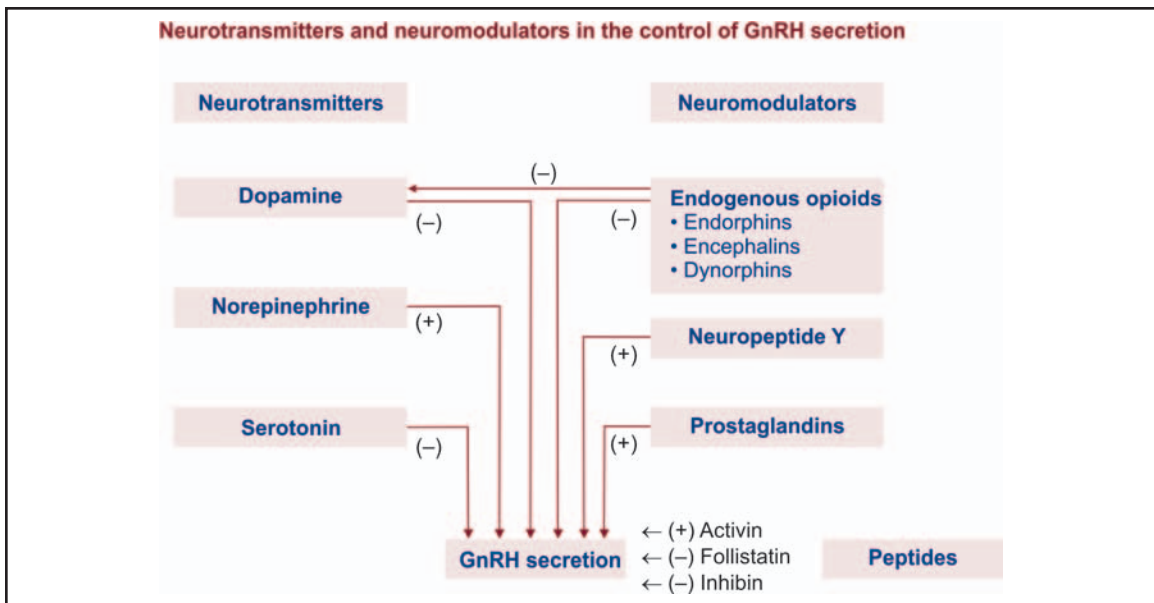
The neurohormonal control of GnRH secretion is modulated by four ways:

- ◆ Neurotransmitters and neuromodulators.
- ◆ Peptides.
- ◆ Ultrashort feedback loop.
- ◆ Short feedback loop.
- ◆ Long feedback loop.

### Neurotransmitters and neuromodulators

The control of GnRH secretion is highly complex and dependent on a number of inhibitory or excitatory pathways involving neurotransmitters and neuromodulators with interaction of ovarian steroids. The neurotransmitters and neuromodulators within the brain act through a neural input.





**The important neurotransmitters are** catecholamines—dopamine, norepinephrine (noradrenaline) and serotonin.

**Norepinephrine** exerts a stimulatory effect on the release of GnRH, while **dopamine** exerts its inhibitory effect. **Serotonin** plays an inhibitory role in GnRH release.

Catecholamines are capable of changing the frequency of GnRH pulse. Thus, pharmacological agents, psychological factors which affect the brain catecholamines, are likely to affect the pulsatile release of GnRH.

**The principal neuromodulators are** endogenous opioids, peptides and prostaglandins.

**Endogenous opioids:** The important endogenous opioids are endorphins, enkephalins and dynorphins. They inhibit GnRH release and thereby inhibit gonadotropin secretion.

The endorphins may suppress both the dopamine and GnRH pathway leading to increase in prolactin secretions. Increased endogenous opioids has been actively implicated in hypothalamic amenorrhea and elevated prolactin levels observed in association with stress and exercise. **Prostaglandin E** produced locally, increases the release of GnRH.

**Role of peptides**—a number of peptides like activin, inhibin and follistatin are produced by GnRH from

pituitary cells as well as from the granulosa cells of the ovary. Activin stimulates but follistatin inhibits GnRH secretion. Inhibin blocks GnRH receptors. LH secretion is regulated by GnRH. Inhibin, activin or follistatin has no effect on it.

### Ultrashort feedback loop

It refers to autoregulation of the releasing hormone of the hypothalamus on its own synthesis. If the GnRH production is more, it will suppress and if it is less, it will stimulate its own production.

GnRH can regulate the concentration of its own pituitary receptors.

### Short feedback loop (gonadotropins)

It relates to the secretion of the GnRH by the interplay between the neurotransmitters and the pituitary gonadotropins. FSH and LH are believed to exert negative feedback effect on hypothalamic production of GnRH.

### Long feedback loop (sex steroid hormones)

The secretion of the hypothalamus (GnRH) and pituitary (FSH, LH) are influenced by the sex steroids. Sex steroids exert their inhibitory effect throughout except in preovulatory period, when a high and sustained level of estradiol exerts a stimulatory effect in the release of GnRH through catechol estrogen.

### Nature of secretion

The secretion and release of GnRH are tonic, cyclic and pulsatile.

**The tonic center** is controlled primarily by the negative feedback of sex steroids, probably via dopaminergic activity.

**The cyclic center** is stimulated by the positive feedback effect of preovulatory sustained and high rise of estradiol resulting in increased GnRH secretion.

**The pulsatile release** (i.e. secretion of GnRH into portal circulation) is presumably regulated by the neurotransmitters and neuromodulators. The pulse secretion of GnRH has an amplitude and frequency.

**Amplitude signifies** the amount of GnRH delivered into portal circulation. **Frequency means** at what interval the GnRH is delivered into portal circulation. The frequency is rapid in the follicular phase, about one pulse per hour and lower in the luteal phase about one pulse every 2–3 hours. In the follicular phase the amplitude is low but it is high in luteal phase.

### GnRH action on anterior pituitary (self-priming of gonadotrophs)

GnRH, on reaching the anterior lobe of the pituitary, stimulates the synthesis and release of both LH and FSH from the same cell (gonadotrophs) in the pituitary gland.

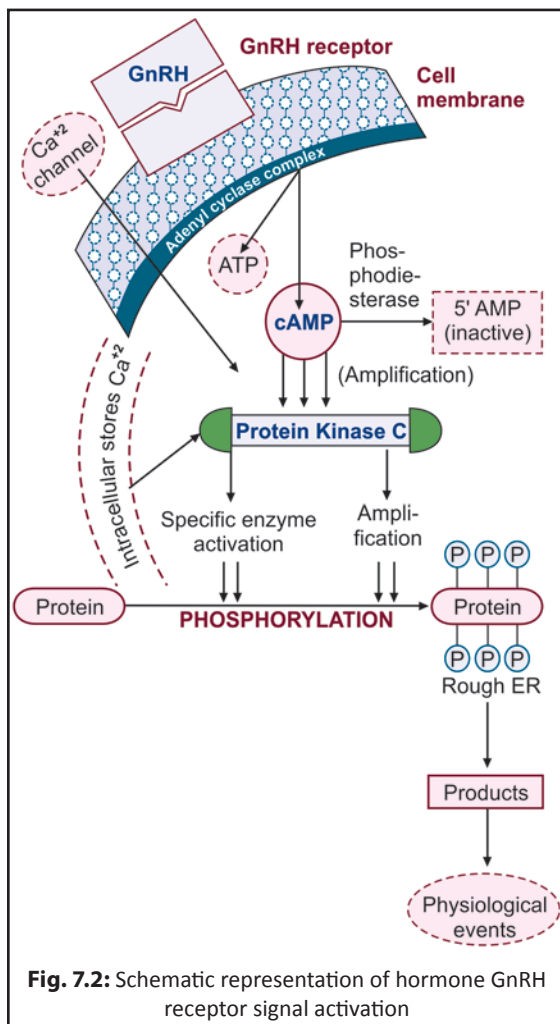
GnRH is involved not only in release of stored LH and FSH but it is of importance in maintaining the synthesis of gonadotropins. It has been demonstrated that repeated exposure of the gonadotrophs to GnRH seems essential for the adequate pituitary stores. Lower GnRH pulse frequencies favor FSH secretion and the higher frequencies favor LH secretion. This response has been termed ‘self-priming’. It has got a cyclic relationship and is greatest with the higher levels of estrogen. Estrogen preferentially induces more LH than FSH release.

### Physiological control mechanism of gonadotropin release

There are two pools of gonadotropins. One is readily releasable by the initial exposure to GnRH (primary pool) and a second one—called reserve pool (secondary pool). GnRH makes this larger reserve pool to be more readily released by a subsequent repeated exposure. Thus, this is suggestive of a transfer of gonadotropins from one pool to the other.

### Mechanism of action of GnRH on pituitary cell (Fig. 7.2)

GnRH binds to the specific receptors on the cell membrane of the gonadotrophs. Within a second, there is activation of the enzyme, adenylyl cyclase which catalyzes the conversion of ATP to cyclic AMP (cAMP). cAMP-receptor protein complex then activates protein kinase C. Intracellular free  $Ca^{++}$  concentration increases. Protein kinase C causes phosphorylation and activation of specific enzymes.  $Ca^{++}$ , protein kinase C and cAMP then interact to



**Fig. 7.2:** Schematic representation of hormone GnRH receptor signal activation

stimulate the release of stored FSH and LH and their subsequent biosynthesis.

However, if GnRH continues to be infused, gonadotropin secretion is inhibited, probably because the receptors are saturated and are unable to stimulate the release of second messenger. This is known as **desensitization or down regulation**.

## PITUITARY

The pituitary gland lies in a bony cavity called sella turcica. The gland, principally consists of two parts—the anterior pituitary (adenohypophysis) and the posterior pituitary (neurohypophysis).

### ANTERIOR PITUITARY

The anterior pituitary is a large, compact and highly vascular gland. It consists of cells arranged in nests or columns. The cells are of two types:

- a. Chromophobes or parent cells—these are small cells without affinity for any dye.
- b. Chromophils—these are larger cells which stain easily.
  - i. Acidophils or eosinophils or alpha cells which stain red with eosin. These cells produce growth hormone and lactogenic hormone (prolactin).
  - ii. Basophils or beta cells which stain blue with hematoxylin.

These beta cells are of three types. **The oval ones produce gonadotropins**; the angular ones produce thyrotropin and the lightly granulated ones produce corticotropin.

### SECRETIONS FROM ANTERIOR PITUITARY

#### I. GONADOTROPINS

There are two gonadotropic hormones secreted from the anterior pituitary—(a) Follicle stimulating hormone (FSH) and (b) Luteinizing hormone (LH).

#### Site of secretion and chemical nature

The mechanisms of hormone synthesis, storage and release of the anterior pituitary hormones are poorly understood. While pulsatile stimulation of hypothalamic GnRH is required by the pituitary for the synthesis and release of gonadotropins, ovarian

hormones determine the cyclic pattern of FSH and LH as they occur in normal cycle. FSH and LH are secreted from the beta cells in a pulsatile fashion in response to pulsatile GnRH. **These are water-soluble glycoproteins** of high molecular weight. They have got two subunits. The amino acid composition of the  $\alpha$  subunits of FSH, LH and human chorionic gonadotropins (hCG) are similar. The hormone specificity being determined by the difference between the  $\beta$  subunits.

#### Functions of FSH

The function of FSH is predominantly morphogenic, related to the growth and maturation of the Graafian follicle. In conjunction with LH, it is also involved in maturation of oocyte, ovulation and steroidogenesis.

#### ◆ Morphological effects ◆ Biochemical effects

#### Morphological effects of FSH

- FSH rescues follicles from apoptosis.
- Stimulates formation of follicular vesicles (antral follicle).
- Stimulates proliferation of granulosa cells.
- Helps full maturation of the Graafian follicle (dominant follicle) as it converts the follicular microenvironment from androgen dominated to estrogen dominated (see p. 85).

#### Biochemical effects of FSH

- Synthesizes its own receptors in the granulosa cells.
- Synthesizes LH receptors in the theca cells.
- Synthesizes LH receptors in the granulosa cells.
- Induces aromatization to convert androgens to estrogens in granulosa cells (see p. 72).
- Enhances autocrine and paracrine function (IGF-II, IGF-I) in the follicle.
- Stimulates granulosa cells to produce activin and inhibin.
- Stimulates plasminogen activator necessary for ovulation.

The FSH level tends to rise soon following the onset of menstruation and attains its peak at the twelfth day of the cycle (preovulatory) and gradually declines to attain the base level at about the eighteenth day (Fig. 7.5).



### Functions of LH

The main function of LH is steroidogenic but along with FSH, it is responsible for full maturation of the Graafian follicle and oocyte and ovulation.

- **Biochemical effects**
- **Morphological effects**

#### Biochemical effects (steroidogenic) of LH

- ◆ Activation of LH receptors in the theca cells which stimulates the enzymes necessary for androgen production → diffuse into the granulosa cells → estrogens
- ◆ Luteinization of the granulosa cells → to secrete progesterone.
- ◆ Synthesizes prostaglandins.

#### Morphological effects of LH

- ◆ Stimulates resumption of meiosis with extrusion of first polar body (see p. 82).
- ◆ Helps in the physical act of ovulation (see p. 83).
- ◆ Formation and maintenance of corpus luteum.

LH levels remain almost static throughout the cycle except at least 12 hours prior to ovulation, when it attains its peak, called LH surge (Fig. 7.5).

### II. PROLACTIN

Prolactin is secreted from the alpha cells and **is a polypeptide**.

Its role in the human reproductive physiology is not clearly understood. Its role in the maintenance of corpus luteum in human is not well-documented, but the fact remains that there is high incidence of anovulation in women with elevated plasma prolactin levels (see p. 464 and 576).

### III. THYROTROPIC HORMONE

Thyroid stimulating hormone (TSH) is produced by the beta cells. It acts on the thyroid gland and regulate the production of thyroxine. It has got  $\alpha$  and  $\beta$  subunits like those of FSH and LH, with functions of  $\beta$  subunits being different. Abnormal TSH secretion is associated with menstrual and ovulatory dysfunction.

### IV. ADRENOCORTICOTROPIC HORMONE (ACTH)

ACTH is also secreted by the beta cells. It stimulates the production of corticosteroids in the adrenal cortex.

### V. SOMATOTROPIN OR GROWTH PRODUCING HORMONE

It is secreted from the alpha cells of the pituitary and acts directly on the skeletal system.

### VI. MELANOCYTE STIMULATING HORMONE (MSH)

It is clearly linked with ACTH. The hormone is increased during puberty and in pregnancy. It is probably responsible for the pigmentary changes during those periods.

### POSTERIOR PITUITARY

The hormones oxytocin and vasopressin are formed in the hypothalamus and transported within the neurons in the hypothalamo-hypophyseal tract. Both the hormones are bound to polypeptides called neurophysins. **Oxytocin** is a nonapeptide. It is produced by the paraventricular nucleus of the hypothalamus. Oxytocin acts on the myometrial contractile system, specially during labor and also causes contraction of the myoepithelial cells in the breast ductules during lactation.

**Arginine-vasopressin** is also a nonapeptide, with two amino acid composition different from that of oxytocin. It is produced by the supraoptic nucleus. It regulates plasma osmolality and circulating blood volume.

### OVARY

The gross anatomy (ch. 1) and the structure of the functional unit of the ovary (ch. 8) are described in the appropriate chapters. **The functions of the ovary** are ovulation and production of hormones (steroidogenesis). The ovulation is dealt in the Chapter 8.

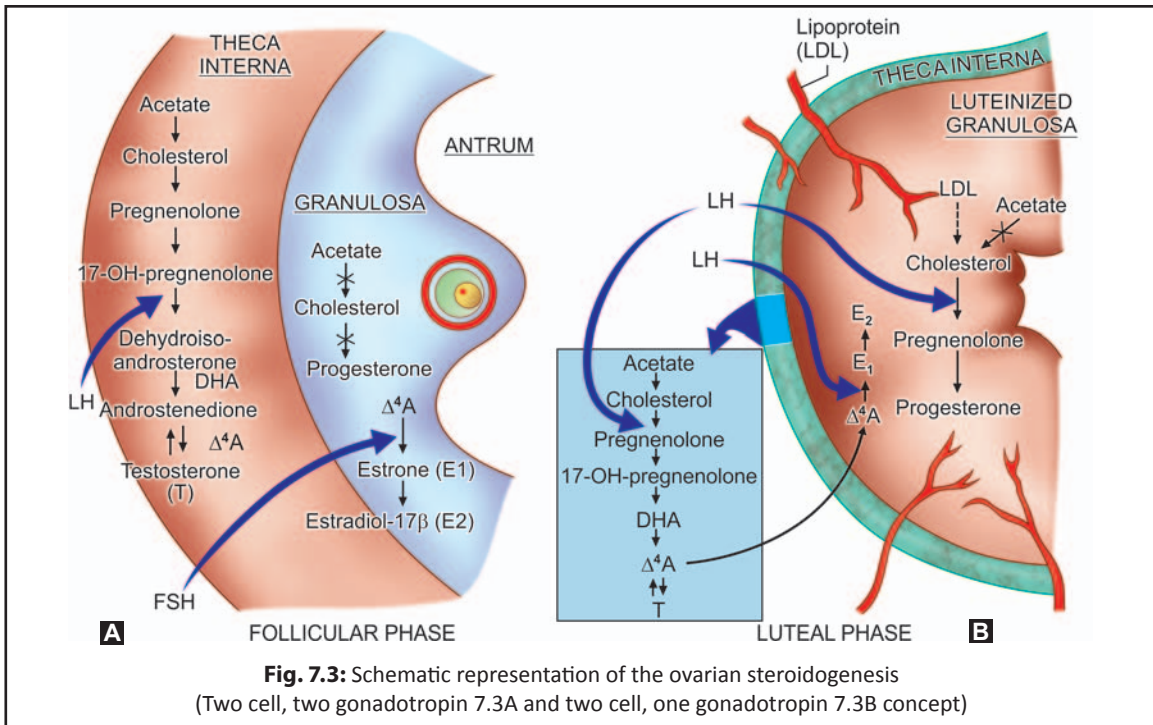
### OVARIAN STEROIDOGENESIS

The principal hormones secreted from the ovaries are—(i) Estrogens; (ii) Progesterone; (iii) Androgens; and (iv) Inhibin.

### ESTROGENS

#### Site of production

The estrogen is predominantly estradiol ( $E_2$ ) and to a lesser extent estrone.



**Fig. 7.3:** Schematic representation of the ovarian steroidogenesis (Two cell, two gonadotropin 7.3A and two cell, one gonadotropin 7.3B concept)

The sites of production in the ovary are:

- ◆ Predominant sites are granulosa cells of the follicles and from the same cells after luteinization to form corpus luteum.
- ◆ Small quantity is also produced from the theca cells and ovarian stroma.

### Mechanism of steroid hormone production (Figs 7.3 and 7.4A)

**Two cell, two gonadotropin, concept of ovarian steroidogenesis** establishes the fact that two cells (**theca cells and granulosa cells**) produce different hormones under the influence of **two gonadotropins (LH and FSH)**.

During the **follicular phase**, under the influence of LH, androgens (androstenedione and testosterone) are produced in the theca cells. These androgens diffuse into the granulosa cells where they are aromatized under the influence of FSH to estrogens—estradiol predominantly and to lesser extent estrone (Figs 7.3, 7.4 and 7.4A).

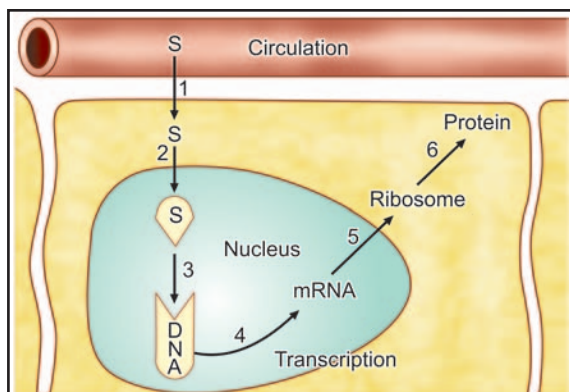
**After ovulation**, progesterone is synthesized in the luteinized granulosa cells under the influence of LH. The precursor-LDL is available to the site

after vascularization of the granulosa cells following ovulation. During luteal phase, androstenedione produced by the theca luteal cells diffuses into the granulosa luteal cells (Fig. 7.3B) to be converted into estradiol by LH. During follicular phase, it is the FSH that enhances aromatase activity in the granulosa cells. Whereas during the luteal phase it is the LH that enhances the aromatase activity in the luteinized granulosa cells for the conversion of androstenedione to estradiol. Therefore, during luteal phase, a two cell (theca luteal and granulosa luteal)—one gonadotropin (LH) system works for estradiol biosynthesis.

### Metabolism

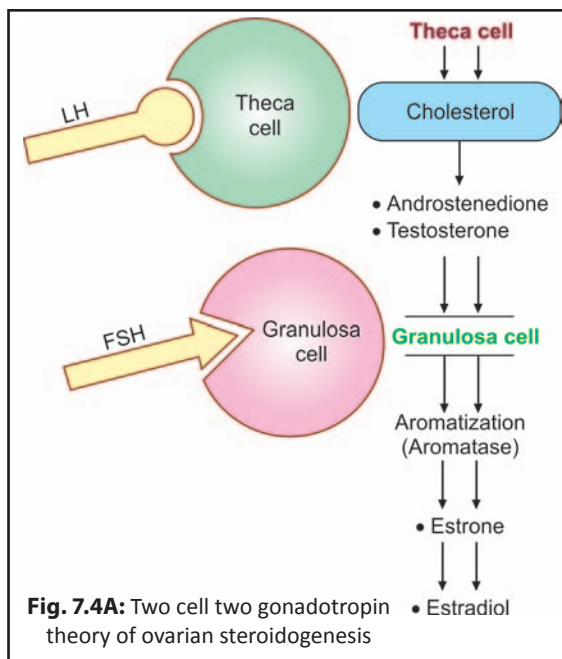
The estrogens are bound to albumin (30%) and sex hormone binding globulin (SHBG) in 69% and the remaining free 1% is biologically active. Unlike trophic hormones, steroid hormones enter the cell and mediate action via receptors within the nucleus as shown diagrammatically in Figure 7.5A to produce specific response.

Following this, the estrogens are quickly inactivated by converting to estriol. Of the three classic estrogens, **estradiol is the most potent**, being ten times as potent as estrone which is ten times as potent as estriol.



**Fig. 7.4: Mechanism of action of steroid hormone:**

The precise mechanism of action of steroid hormones includes: (1) Diffusion of steroid hormone through the cell membrane; (2) Steroid hormone receptor complex within the nucleus; (3) Interaction of this complex with nuclear DNA; (4) Synthesis of messenger RNA (mRNA); (5) mRNA combines with ribosome in the cytoplasm; (6) Synthesis of protein and desired activity



**Fig. 7.4A: Two cell two gonadotropin theory of ovarian steroidogenesis**

The estrone is conjugated in the liver with glucuronic acid. The conjugated estrogen is excreted partly in the bile and partly in the urine. The bile fractions on reaching the intestine are broken down by microorganisms and then reabsorbed as active hormones (enterohepatic circulation). The disturbances of liver function or of the intestinal flora can thus alter this mechanism with consequent disturbances of menstrual cycles.

### AMOUNT OF ESTROGEN PRODUCTION AND BLOOD LEVEL (See Table 7.2)

**Total daily production** of estradiol is estimated to be about 50 µg during the early follicular phase reaching 150–300 µg at ovulation.

**The blood level** rises to about 300–600 pg/mL at ovulation. After a sharp fall, it rises again to about 150–200 pg/mL in the luteal phase (Fig. 7.5).

**Total quantity of estradiol** production during a cycle from ovulatory ovary is estimated to be 10 mg.

### Physiological action

**Secondary sex characters**—Estrogen tends to induce feminine characteristics. The hormone is responsible for feminine body configuration and feminine mental make up including shyness. There

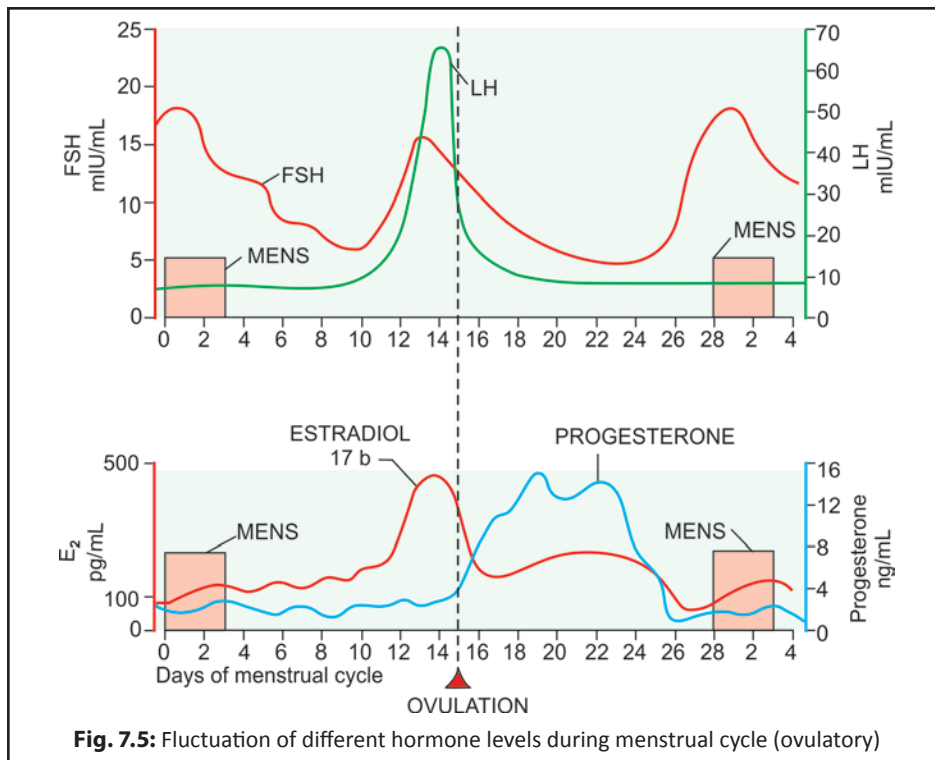
is secretion in apocrine glands, change in voice and deposition of fat on the breasts, thighs and hips. **The growth of axillary and pubic hair is dependent predominantly on androgens of adrenal origin.**

**Action on the genital organs**—Under the action of estrogen, the genital organs not only develop into maturity but induce cyclic changes for reproduction. After menopause, with the fall in the estrogen level, atrophic changes of the organs occur.

**Vulva and vagina**—All the structures are influenced by the estrogens. The vaginal vascularity and epithelial activity are related to estrogen. Estrogen induces thickening of the lining epithelium, cornification of the superficial cells and deposition of glycogen which is converted into lactic acid by the Doderlein's bacilli. **As such, the vaginal flora is maintained by estrogen.**

**Uterus**—There is increased vascularity with hyperplasia of the muscles. It changes the uterus from the infantile to adult form. Cyclic changes in the endometrium includes regeneration and proliferation of the endometrium. **It produces receptors for progesterone.** Withdrawal of estrogen causes shedding of the endometrium and menstruation.

**Cervix**—Estrogen causes hypertrophy of the cervix and increases the cervical gland secretion. The secretion is more watery, alkaline with less protein



and more electrolytes. These favor penetration of the sperm.

**Fallopian tubes**—There is increased vascularity with increased motility of the tubes.

**Breasts**—There is increased proliferation of the ducts and stromal tissues. There is also increased vascularity and pigmentation of the areola. Accumulation of fat also occurs. Breast secretion, however, cannot occur.

**Blood**—Estrogen increases the coagulability of blood by increasing many procoagulants, chiefly fibrinogen. The platelets become more adhesive.

**Locomotor system**—Estrogen conserves calcium and phosphorus and encourages bone formation.

**General**—Estrogen increases sodium, nitrogen and fluid retention of the body. It lowers the blood cholesterol and lowers the incidence of coronary heart disease in women prior to menopause. It has got widespread capillary vasodilatation effect.

### Endocrine system

◆ *Hypothalamopituitary axis.*

### Negative Feedback

Estrogen exerts a negative feedback effect on the release of FSH. This is by:

- (i) Direct action on pituitary, decreasing the sensitivity of the gonadotroph to GnRH
- (ii) Direct action on the hypothalamus with a decrease in GnRH secretion, possibly via increased inhibitory dopaminergic activity.

### Positive Feedback

High levels of estrogen (>200 pg/mL) exert a positive feedback effect on LH (mid cycle LH surge). Sustained (24–48 hours) elevated levels of estrogen lead to sustained and elevated LH secretion. It may be due to:

- i. Increasing pituitary responsiveness to GnRH.
- ii. Stimulating the hypothalamus in secreting GnRH.

The positive feedback effect cannot occur in the postovulatory phase because of the presence of progesterone.

◆ *Ovary:* The presence of  $E_2$  and FSH in the antral fluid is essential for sustained proliferation of granulosa cells and continued follicular growth.

- ◆ It increases the binding globulin in circulation and raises the blood levels of protein bound iodine and protein bound cortisol.

## PROGESTERONE

### Site of secretion

The progesterone is secreted from the luteinized theca granulosa cells of the corpus luteum. A trace amount is however, secreted from the theca granulosa cells of the follicle and also from the ovarian stroma.

### Metabolism

Progesterone is bound mainly to albumin (79%) and corticosteroid binding globulin (17.7%).

It is metabolized in the liver and excreted as sodium pregnanediol glucuronide (pregnanediol) in the urine. This metabolite has no progestational activity. Only 20% of secreted progesterone is conjugated and appears in the urine as pregnanediol. The fate of the remainder is not clear.

17- $\alpha$ -hydroxy progesterone is an important product of the ovary. It is metabolized in the liver and reduced to pregnanetriol.

### Amount of production and blood level (Table 7.2)

Daily production of progesterone is 2–3 mg in follicular phase and 20–30 mg in luteal phase.

Daily excretion of pregnanediol in the urine is less than 1 mg in follicular phase and 3–6 mg in luteal phase.

Serum value of progesterone is less than 1 ng/mL in follicular phase and 5–15 ng/mL in midluteal phase (Fig. 7.5).

**Physiological action:** Progesterone acts on all the organs of the genital tract and on the breasts provided they are sensitized by estrogen.

**Uterus**—Progesterone produces myohyperplasia and diminishes the contractility of the myometrium. It however, increases the tone of the circular muscle fibers at the isthmus. It produces secretory activity in the endometrium; enhances secretion of the glands rich in glycogen. The character of the cervical mucus is changed and become more thick and viscid preventing sperm penetration.

**Vagina**—The maturation of the vaginal epithelium is hindered. There is more shedding of the intermediate cells with folded edges and a tendency to clump.

**Fallopian tubes**—The epithelial cells are stimulated to secrete clear mucus which helps in migration of the ovum. Tubal motility is however, decreased which may predispose to tubal pregnancy.

**Breasts**—Along with estrogen, it produces hypertrophy and growth of the acinar structures.

**General**—Progesterone is thermogenic, raises the basal body temperature by 0.2–0.5°C. There may be enhanced deposition of fat in the tissues. It relaxes smooth muscles and ligaments—specially during pregnancy. It promotes the secretion of sebum by the skin. Like other steroids, it causes fluid retention.

### Endocrinal system

#### ■ Hypothalamopituitary axis

The principal negative feedback action of progesterone is upon the midcycle gonadotropin surge and it may be responsible for its short duration.

Progesterone by itself does not appear to exert a positive feedback effect. However, its rise during preovulatory period is related with the FSH surge by its positive feedback action. The positive feedback effect of estradiol in the secretory phase is inhibited by progesterone.

#### ■ GnRH secretion

Progesterone first (low level) stimulates, then (high level) inhibits the production of GnRH.

#### ■ Ovary

Progesterone acts through both intraovarian and central negative feedback mechanisms to suppress new follicular growth. It is postulated that increased intraovarian progesterone concentration prevents follicular maturation in that ovary in the subsequent cycle.

## ANDROGENS

The androgens are produced in the ovary by all three types of cells—stroma, theca and granulosa, but mainly by the theca interna of the follicles. The production of androgens is primarily under the control of LH. **The principal androgens secreted are**—dehydroepiandrosterone, androstenedione and testosterone.

The principal site of metabolism is liver. The androgens are reduced to androsterone and etiocholanolone. These can be measured in the urine as 11 deoxy-17 ketosteroids.

Total daily production of androstenedione is 3 mg and of testosterone 0.2–0.3 mg.

Plasma level of androstenedione is 1.3–1.5 ng/mL, that of testosterone 0.3–0.6 ng/mL and of SHBG 38–103 nmol/L.

### PEPTIDES AND THEIR ROLE

**Inhibin, Activin and Follistatin** are the peptides, secreted by the granulosa cells in response to FSH. Inhibin, inhibits FSH secretion. Activin is produced by the pituitary and granulosa cells. **Activin** stimulates FSH release from the pituitary. It also enhance FSH action in the ovary. Follistatin, suppresses FSH activity by inhibiting activin.

**Inhibin:** Inhibin is secreted by the granulosa cells of the ovarian follicle in response to FSH. It has got a preferential negative feedback effect on FSH release. FSH and inhibin bear a reciprocal relationship. Inhibin A and inhibin B block the synthesis and secretion of FSH.

### ANTI-MÜLLERIAN HORMONE (AMH)

- ◆ It is a peptide produced by the granulosa cells of primordial follicles (< 6 mm).
- ◆ It causes Müllerian duct regression during male sexual differentiation.
- ◆ AMH levels reflect the number of growing follicles in the ovary and it helps oocyte maturation and follicular development.
- ◆ Low levels of AMH is observed with rise of FSH and E<sub>2</sub> levels and also with increasing age of the women (as the follicle number declines).
- ◆ Estimation of serum AMH is used as a screening test of ovarian reserve (see p. 529).



### RELAXIN

Relaxin is secreted from the preovulatory follicle and corpus luteum. It probably facilitates follicular rupture during ovulation.

**Growth factors** are polypeptides and they act locally through paracrine and autocrine way. Important growth factors are: Insulin-like growth factors (IGF), Epidermal growth factor, Tumor necrosis factor  $\alpha$  (TNF $\alpha$ ) and Interleukin-1 system.

**Insulin-like growth factors (IGF)**—are most abundant. IGF-II is produced in theca cells, granulosa cells and luteinized granulosa cells. IGF-II enhances gonadotropin (FSH and LH) actions to stimulate granulosa cell proliferation, aromatase activity, and progesterone synthesis.

### THYROID

The thyroid gland consists of numerous acini and follicles. Between the follicles, there are parafollicular or 'C' cells. The follicular cells synthesize iodine containing thyroxine (T<sub>4</sub>) and triiodothyronine (T<sub>3</sub>) under the influence of TSH of the anterior pituitary (Table 7.1). These hormones are related to body growth and metabolic needs. Ovarian function is markedly related to the thyroid activity. Normal enlargement of the gland occurs during puberty, pregnancy and menopause. Menstrual function may be significantly disturbed in thyroid dysfunction. Calcitonin is secreted from the parafollicular cells in response to elevated blood calcium.

TABLE 7.1

NORMAL SERUM VALUES OF THYROID PROFILE

TSH	0.4–5 mmol/L	(3 $\mu$ U/mL)
T <sub>3</sub>	1.1–2.3 nmol/L	(70–190 ng/100 mL)
T <sub>4</sub>	10–25 pmol/L	(5–12 $\mu$ g/100 mL)

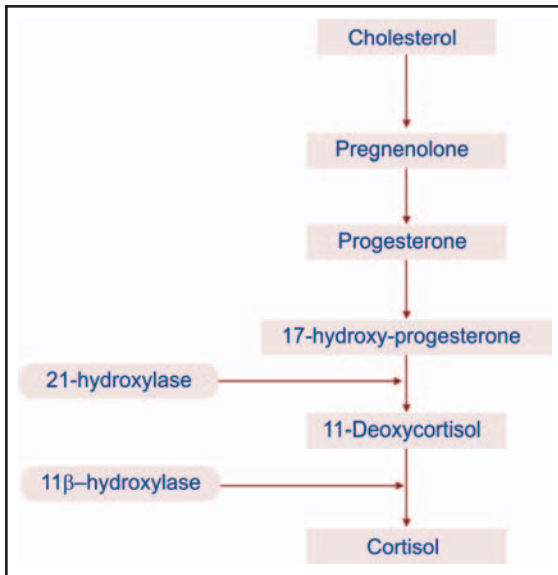
### ADRENAL GLANDS

Adrenal gland consists of two zones—outer cortex and inner medulla. The medulla secretes adrenaline and noradrenaline.

#### Control of cortical secretions

**Zona glomerulosa:** Aldosterone is secreted from this zone. The secretion is principally controlled by the renin–angiotensin mechanism and is not markedly affected by ACTH. It produces retention of sodium and increased excretion of potassium through the renal tubules.

**Zona reticularis and fasciculata:** They act as a single unit. The principal hormones that are secreted are cortisol, corticosterone (gluco-corticoids); androstenedione, androsterone and dehydroepiandrosterone (collectively called androgens) and to some extent estrogen and progesterone. These constitute the extraovarian sources of steroids.



The control of cortisol synthesis through ACTH is regulated by the negative feedback, diurnal rhythm and stress. Stress can override the negative feedback mechanism and diurnal rhythm. A rise of plasma cortisol causes a rapid suppression of ACTH. A fall in cortisol level leads to increased production of ACTH probably through release of CRH from the hypothalamus.

**The biosynthetic pathway in the secretion of cortisol** through series of enzymatic action (predominantly 21-hydroxylase) is as follows:

**(a) Action of glucocorticoids**

The main action of cortisol is anabolic.

- (i) Antagonistic to insulin and tends to raise the blood sugar.
- (ii) Suppression of inflammatory reaction.
- (iii) Lipogenic effect.

**(b) The action of androgens and adrenal steroids** is anabolic to antagonize the catabolic effects of the glucocorticoids.

## HYPOTHALAMOPITUITARY OVARIAN AXIS

The hormones liberated from the hypothalamus, pituitary and ovary are dependent to one another. A well-coordinated axis is formed called hypothalamo-

pituitary ovarian axis (Fig. 7.6). The secretion of hormones from these glands is modified through feedback mechanism operating through this axis. The axis may also be modified by hormones liberated from the thyroid or adrenal glands.

### FEEDBACK LOOP

- ◆ The long feedback loop refers to the feedback effects of the ovarian steroids on both the hypothalamus and pituitary. It is usually inhibitory (negative) but may be stimulatory (positive-preovulatory).
- ◆ The short feedback loop relates the secretion of GnRH by gonadotropins by interplay between the neurotransmitters and the pituitary gonadotropins. FSH and LH exert negative feedback effect on the hypothalamic production of GnRH.
- ◆ Ultrashort feedback loop refers to autoregulation of the releasing hormones of the hypothalamus on its own synthesis (Fig. 7.6).

### FETAL LIFE

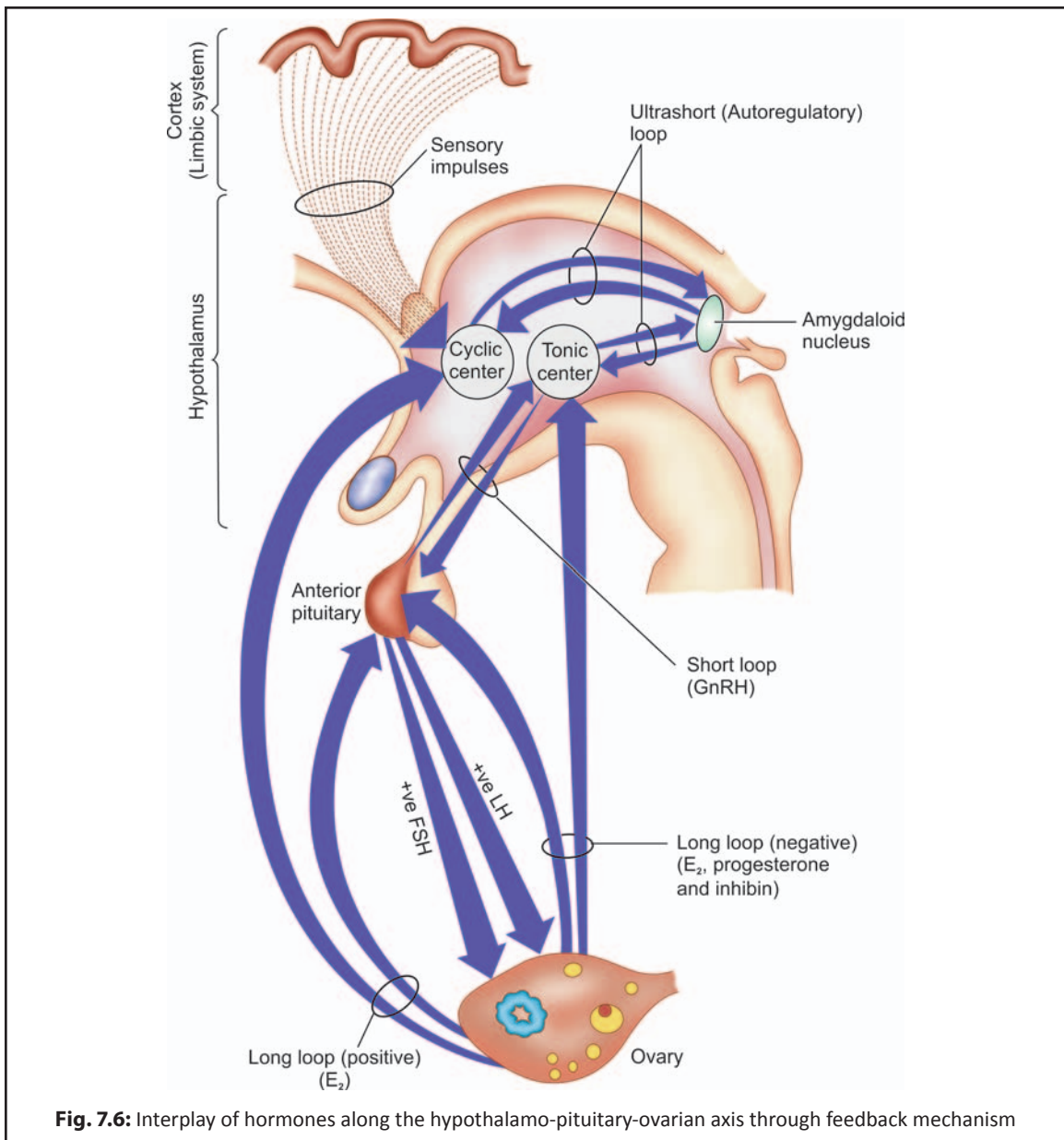
In terms of hormone production, the hypothalamopituitary ovarian axis is active and functional from approximately 20 weeks of fetal life. In fact, the circulatory gonadotropin levels remain at a higher level in fetal life than during neonatal period. The development of ovarian follicles in the fetus depends upon the gonadotropins released from the fetal pituitary.

### INFANCY AND CHILDHOOD

The high level of FSH and to a lesser degree of LH at birth gradually decline and the minimum levels are achieved by two years of age. The FSH levels are highly sensitive to exogenous estrogen.

### PREPUBERTY AND PUBERTY

The hypothalamopituitary-gonadal feedback system is in operation for many years prior to puberty. Prior to puberty, the hypothalamus is very much sensitive to the negative feedback by even a small amount of extragonadal steroids (estrogens produced by peripheral conversion of androgens from adrenals). As a result, the release of gonadotropin releasing hormone (GnRH) from the hypothalamus and that of



**Fig. 7.6:** Interplay of hormones along the hypothalamo-pituitary-ovarian axis through feedback mechanism

FSH and LH from the anterior pituitary are kept in abeyance. As puberty approaches, the hypothalamic centers involved in the release of GnRH become more and more sensitive to the positive feedback of ovarian steroids. This may be related to increasing androgens from adrenals. There is augmented GnRH pulse release. This results in gradually increasing gonadotropin secretion (LH > FSH) → increasing

ovarian stimulation → increasing estrogen levels → tonic and pulsatile discharge of gonadotropins.

This increasing level of estrogen is responsible for the growth and initiation of thelarche and finally menarche. The development of the positive feedback response to estrogen resulting in cyclic release of gonadotropins occurs after a variable period following menarche. As such, the first few cycles are expected



to be anovulatory. The growth of pubic and axillary hair is related to increase in the secretion of adrenal androgens. The onset of this increase is called adrenarche which occurs at age 8–10 years.

### OVARIAN AND MENSTRUAL CYCLE (p. 84)

**Pregnancy and during 'Pill' intake**—As the estrogen level is high in both the conditions, the pituitary gonadotropins remain static at low levels by the negative feedback mechanism.

#### Following Delivery

During pregnancy, there is hypofunction of the axis induced by high level of estrogen. The hypothalamic hypofunction results in low levels of GnRH. In the immediate postpartum period, there is pituitary refractoriness to GnRH resulting in low FSH and LH levels. High prolactin levels render the ovary less sensitive to the already low gonadotropin stimulation resulting in ovarian inactivity, low estrogen status and anovulation. Even when ovarian activity resumes, raised levels of prolactin give rise to short luteal phase and reduced fertility.

Thus, the picture of the first three weeks postpartum is one of hypothalamopituitary ovarian inactivity which is prolonged by lactation under the influence of prolactin secretion.

#### Perimenopausal Period

Few years prior to menopause, the ovarian follicles become gradually resistant to the pituitary gonadotropins. As a result of impaired folliculogenesis, less estrogen is secreted. There is decrease in

TABLE 7.2

#### DAILY PRODUCTION, SERUM VALUES AND URINARY EXCRETION OF HORMONES

Hormones	Follicular phase	At ovulation	Luteal phase
<i>Daily production</i>			
Estradiol (µg)	50	150–300	100
Progesterone (mg)	2–3		20–30
<i>Serum values</i>			
Estradiol (pg/mL)	50	300–600	150–200
Progesterone (ng/mL)	< 1		> 5
FSH (mIU/mL)	10	15–20	10
LH (mIU/mL)	5	60	5
<i>Daily excretion</i>			
Total estrogen (µg)	10–25	35–100	25–75
Pregnanediol (mg)	< 1		3–6

the negative feedback effect of estrogen on the hypothalamic pituitary axis, resulting in increase of FSH. The increase of FSH may also be due to diminished follicular inhibin (see p. 74).

When menopause sets in, the estradiol level comes down to basal 20 pg/mL and cannot have any negative feedback effect on hypothalamo-pituitary axis (see p. 76).

As a result, GnRH release is enhanced resulting in increased synthesis and release of gonadotropins. The pulsatile pattern is maintained and while the frequency remains unaltered, the amplitude is markedly increased.

Gradually with senescence, the GnRH secretion is diminished and so also the gonadotropins and estrogens, when the true menopause sets in.

## KEY POINTS

- Hypothalamus has got neural connection with the cortex and through hypothalamo-portal system of vessels, connected with the anterior pituitary.
- Among the specific releasing hormones, the important ones are GnRH, TRH, CRH and the prolactin secretion is inhibited by PIF. Dopamine is a physiological inhibitor.
- GnRH is a decapeptide with a very short half-life (see p. 67).
- GnRH is secreted in a pulsatile manner. The amplitude and frequency vary in the menstrual cycle. The frequency is rapid (one pulse/hr) in the follicular phase but slower (1 pulse/2-3 hours) in the luteal phase (see p. 67).

GnRH stimulates the release and synthesis of both LH and FSH from the same cells of the anterior pituitary in pulsatile manner.

Contd...

Contd...

GnRH binds to the specific receptor on the surface membrane of the gonadotrophs. A second messenger is activated combining  $Ca^{++}$ , protein kinase C and cAMP together to stimulate the release of stored LH and FSH and their subsequent synthesis (Fig. 7.2).

- The neurohormonal control of GnRH secretion is very complex. A number of neurotransmitters and neuromodulators (see p. 67) are involved to play their inhibitory (endogenous opioids, dopamine, inhibin) and stimulatory (norepinephrine, prostaglandin, activin) roles (see p. 68).
- Gonadotropins are secreted from the beta cells of anterior pituitary. These are glycoproteins. The hormone specificity is ascertained by  $\beta$  subunits.

Down regulation is the decrease in sensitivity of the gonadotroph (adenohypophysis) receptors, due to continued stimulation of GnRH. Upregulation is the increase in receptor sensitivity due to intermittent exposure to GnRH (see p. 67).

GnRH analogues are produced by substitution of amino acids in the parent molecule (see p. 67) at the 6 and 10 positions. The agonists have greater potencies and longer half-lives than the parent GnRH.

- Ovarian hormones determine the cyclic pattern of FSH and LH release (Fig. 7.6).
- The half-life of LH is 30 minutes and that of FSH is 3.9 hours. LH acts primarily on the theca cells to produce androgens. Granulosa cells convert androgens to estrogen by the enzyme aromatase.
- FSH is predominantly morphogenic but in conjunction with LH, it is involved in maturation of oocyte, ovulation and steroidogenesis. LH is predominantly steroidogenic. It also stimulates resumption of meiosis, helps in ovulation and formation and maintenance of corpus luteum (see p. 70).
- LH acts primarily on theca cells to produce androgens, whereas FSH acts primarily on the granulosa cells to produce estrogens by aromatization of androgens (see p. 71). The ovary secretes three principal steroid hormones : estradiol from the follicle, progesterone from the corpus luteum and androstenedione from the stroma (see p. 71).
- Prolactin is secreted from the alpha cells and is a polypeptide. Thyrotrophic hormone is produced by the beta cells.
- The  $\alpha$  subunits of LH, FSH, TSH and hCG are similar. It is due to the different  $\beta$  subunits which provide specific biologic activity for each hormone.
- A number of peptides like activin, inhibin and follistatin are produced by GnRH from pituitary cells as well as from the granulosa cells of the ovary. Inhibin inhibits FSH. Follistatin inhibits GnRH secretion (see p. 76).
- Two cell, two gonadotropin concept of ovarian steroidogenesis states that LH stimulates the theca cells to produce androgens, which are subsequently aromatized in the granulosa cells by FSH to produce estrogens (see Fig 7.3A p. 72; Fig. 7.4A p. 73).
- LH acts upon the luteinized granulosa cells to produce progesterone. Estrogen is also produced in luteal phase under the influence of FSH and LH.
- The midcycle LH surge initiates the resumption of meiosis-I. The primary oocyte undergoes first meiotic division giving rise to secondary oocyte and first polar body (see p. 86).
- The second meiotic division is completed only after fertilization by a sperm. The ovum and second polar body is then developed (see p. 86).
- The sites of production of estrogens, predominantly the estradiol, are granulosa cells, luteinized granulosa cells, theca cells and stroma of the ovary. The estrogens are produced by two-cell two gonadotropin concept (Fig. 7.3A and 7.4A).

Contd...

Contd...

- Androstenedione is converted to estrone in the adipose tissue. Estradiol and estrone are interconvertible. Estrone sulfate is the major circulating estrogen and has a long half-life.
- Estradiol exerts a negative feedback effect on the hypothalamopituitary axis. However, when the level is raised to more than 200 pg/mL and sustained for 24–48 hours, it has got positive feedback effects. The positive feedback effect cannot occur in the luteal phase because of progesterone.
- Progesterone has 21 carbon atoms, androgens have 19 carbon atoms and estrogens have 18 carbon atoms. The progesterone is secreted from the luteinized thecagranulosa cells of the corpus luteum, theca granulosa cells of the follicle and from the stroma. Trace amount of 17- $\alpha$ -hydroxy progesterone in the preovulatory period is essential for final maturation of the oocyte and involved in LH surge.
- Serum progesterone levels are <1 ng/mL before ovulation and reach 10–20 ng/mL at the mid luteal phase.
- Progesterone has got negative feedback on the hypothalamopituitary axis; principally upon the midcycle gonadotropin surge and is responsible for its short duration.
- Estrogen stimulates the synthesis of both estrogen and progesterone receptors in target tissues. Progestins inhibit the synthesis of both the receptors. Progesterone has antimitotic and antiproliferative action (see p. 75).
- Normal enlargement of thyroid gland occurs during puberty, pregnancy and menopause.
- Menstrual function is significantly disturbed in thyroid dysfunction.
- The biosynthetic pathway in the secretion of cortisol is through series of enzymatic action from cholesterol via 17- $\alpha$ -hydroxy progesterone.
- The hypothalamopituitary axis is active and functional from 20 weeks of fetal life (see p. 77).
- At puberty, increasing estrogen levels result in pulsatile release of gonadotropins. The development of positive feedback effect occurs 2–3 years following menarche (see p. 77).
- During pregnancy and 'pill' taking period, gonadotropins remain static at low levels (see p. 79).
- During first three weeks postpartum, there is hypothalam-opituitary-ovarian inactivity due to high level of prolactin. As menopause approaches, there is less production of estrogens and the remaining ovarian follicles become resistant to gonadotropins. There is decrease in follicular inhibin. The combined effects result in increase in FSH and later on LH also. When the estradiol level falls below 20 pg/mL, menopause sets in (see p. 57).  
GnRH release is also enhanced because of decrease in negative feedback effect of estrogen. This results also in increased release and synthesis of gonadotropins (p. 58).
- Dominant follicle is selected by days 5 and 7. The dominant follicle on ultrasonography has a maximum diameter of about 20 mm and a volume of 3.8 mL. The dominant follicle secretes more estradiol which in turn induces more FSH receptors (see p. 85, Fig. 8.3A, 8.4)
- FSH induces LH receptors on granulosa cells.
- The actions of FSH and LH on the follicles are modulated by a group of peptides and growth factors by autocrine and paracrine nodes. Inhibin, secreted in the granulosa cells by FSH, directly suppresses FSH. Activin augments FSH secretion and action (see p. 76).
- Successful development of a follicle depends on the FSH induced aromatase activity in the granulosa cells to convert the follicular microenvironment from androgen dominated to an estrogen dominated one (see p. 70, 85).

# Menstruation

## DEFINITION

**Menstruation is the visible manifestation of cyclic physiologic uterine bleeding due to shedding of the endometrium** following invisible interplay of hormones mainly through hypothalamo-pituitary-ovarian axis. **For the menstruation to occur**, the axis must be actively coordinated, endometrium must be responsive to the ovarian hormones (estrogen and progesterone) and the outflow tract must be patent.

## ANATOMICAL ASPECT

The period extending from the beginning of a period (mens) to the beginning of the next one is called menstrual cycle. The first menstruation (menarche) occurs between 11–15 years **with a mean of 13 years**. It is more closely related to bone age than to chronological age. For the past couple of decades, the age of menarche is gradually declining with improvement of nutrition and environmental condition. Once the menstruation starts, it continues cyclically at intervals of 21–35 days with a mean of 28 days. Physiologically, it is kept in abeyance due to pregnancy and lactation. Ultimately, it ceases between the ages 45–50 when menopause sets in. **The duration of menstruation (mens) is about 4–5 days and the amount of blood loss is estimated to be 20 to 80 mL with an average of 35 mL. Nearly 70 percent of total menstrual blood loss occurs in the first 2 days. The menstrual discharge consists** mainly of dark altered blood, mucus, vaginal epithelial cells, fragments of endometrium, prostaglandins, enzymes and bacteria.

## FOLLICULAR GROWTH AND ATRESIA

- ♦ Germ cells
- ♦ Primordial follicle

- ♦ Cyclic maturation of the follicle (ovarian cycle)
  - Ovulation
  - Corpus luteum
- ♦ Follicular atresia.

## GERM CELLS

**ORIGIN: The germ cells migrate from the endoderm of the yolk sac in the region of hindgut.** From there, they migrate into the genital ridge (between 5 and 6 weeks of gestation) passing through the dorsal mesentery of the hindgut. A peptide, called, telopheron directs this anatomic migration. The migration is probably through amoeboid activity or by chemotactic mechanism between 4 and 6 weeks gestation. In the gonadal ridge, the oogonia are surrounded by clumps of epithelial cells (see Fig. 3.5).

## MULTIPLICATION

The germ cells undergo rapid mitotic division and **by 20 weeks, the number reaches about 7 million.** While majority of the oogonia continue to divide until 7th month of gestation, some enter into the prophase of first meiotic division and **are called primary oocytes.** These are surrounded by flat cells from the stroma (pregranulosa cells) and are called **primordial follicles.** The primary oocytes continue to grow through various stages of prophase (leptotene, zygotene, pachytene and diplotene) and ultimately reach to the stage of diplotene or else become atretic. Primary oocytes are then arrested in the diplotene stage of prophase of first meiotic division, until ovulation.

**Total number of oocytes at 20 weeks of intra-uterine life is about 6–7 million. At birth, the total number of primordial follicles is estimated to be about 2 million.** The primary oocytes do not finish

the first meiotic division until puberty is reached. **At puberty, some 400,000 primary oocytes are left behind, the rest become atretic. During the entire reproductive period, some 400 are likely to ovulate.** Thus, the important feature is the tendency of the sex cells to undergo degeneration. **The degeneration starts in the intrauterine life** and continues throughout childhood and the childbearing period. As a result, no more follicles with ova can be detected in menopausal women.

### MATURATION

The essence of maturation is reduction of the number of chromosomes to half. The primary oocyte remains in diplotene phase until shortly before ovulation unless it undergoes atresia. **It is the midcycle LH surge that initiates the resumption of meiosis-1.** The primary oocyte undergoes **first meiotic division** giving rise to secondary oocyte and **one polar body**. The two are of unequal size, the secondary oocyte contains haploid number of chromosomes (23, X) but nearly all the cytoplasm. The small polar body also contains haploid number of chromosome (23, X) but with scanty cytoplasm. **The formation of secondary oocyte occurs** with full maturation of Graafian follicle just prior to ovulation.

The secondary oocyte immediately begins the **second meiotic division** but stops at metaphase. **The secondary oocyte completes the second meiotic division (homotypical) only after fertilization by**

**a sperm in the fallopian tube.** The division results in the formation of the two unequal daughter cells each possessing 23 chromosomes (23, X). The larger one is called the ovum (female pronucleus) and the smaller one is the **second polar body**. **In the absence of fertilization, the secondary oocyte, does not complete the second meiotic division and degenerates as such.** Thus, the first stage of maturation of the oocyte occurs within the follicle but the final stage is achieved only after fertilization in the fallopian tube.

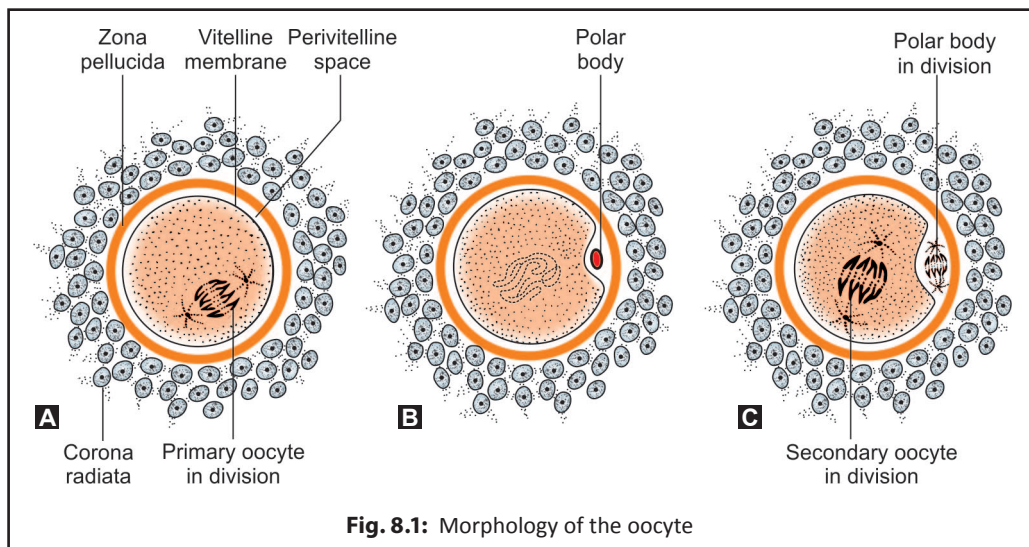
The arrested meiotic division of the oocyte prior to ovulation is probably due to oocyte maturation inhibition (OMI) factor present in the follicular fluid. OMI is secreted by the granulosa cells. The resumption of meiosis occurs due to the midcycle LH surge.

### PRIMORDIAL FOLLICLE

**The primordial follicle** consists of an oocyte, which is surrounded by a single layer of flattened granulosa cells. The follicle measures about 0.03–0.05 mm. The oocyte (primitive ovum) measures about 18–24  $\mu$  in diameter, nucleus 12  $\mu$  and nucleolus 6  $\mu$ . Throughout childhood, the primordial follicles grow very slowly. Thin growth is not dependent on gonadotropins.

### MORPHOLOGY OF THE OOCYTE

With the maturation of the follicle, there is simultaneous enlargement of the oocyte although at a lesser pace. While the follicle continues to enlarge



**Fig. 8.1:** Morphology of the oocyte

until just prior to ovulation, the oocyte ceases to enlarge around the time of antrum formation. **The morphological features of the primary oocyte just prior to ovulation (often erroneously called mature ovum) are as follows:**

It measures about 130 microns and the nucleus measures 20–25 microns. This is in contrast with 20 microns and 10 microns, respectively in the primordial follicle. The radially arranged granulosa cells surrounding the oocyte is called **corona radiata**. The oocyte is surrounded by an outer envelope called **zona pellucida**, a glycoprotein layer, secreted by the growing oocyte (Fig 8.1). The cytoplasm, also called vitellus contains nutritive yolk granules and is limited by a definite membrane called **vitelline membrane**. The space between the vitelline membrane and the zona pellucida is called **perivitelline space**. The spherical nucleus is located near the center of the cytoplasm. The nucleolus is large with sparsely distributed chromatin. Shortly before ovulation, meiosis is reinitiated. At the completion of the first and second meiotic division, the number of chromosomes in the oocyte is halved (23, X) and the two polar bodies which are formed are pushed to the perivitelline space. **The first polar body is formed just prior to**

**ovulation and the second one just after fertilization (Figs 8.1 and 8.2).**

## MENSTRUAL CYCLE

### OVARIAN CYCLE

#### Definition

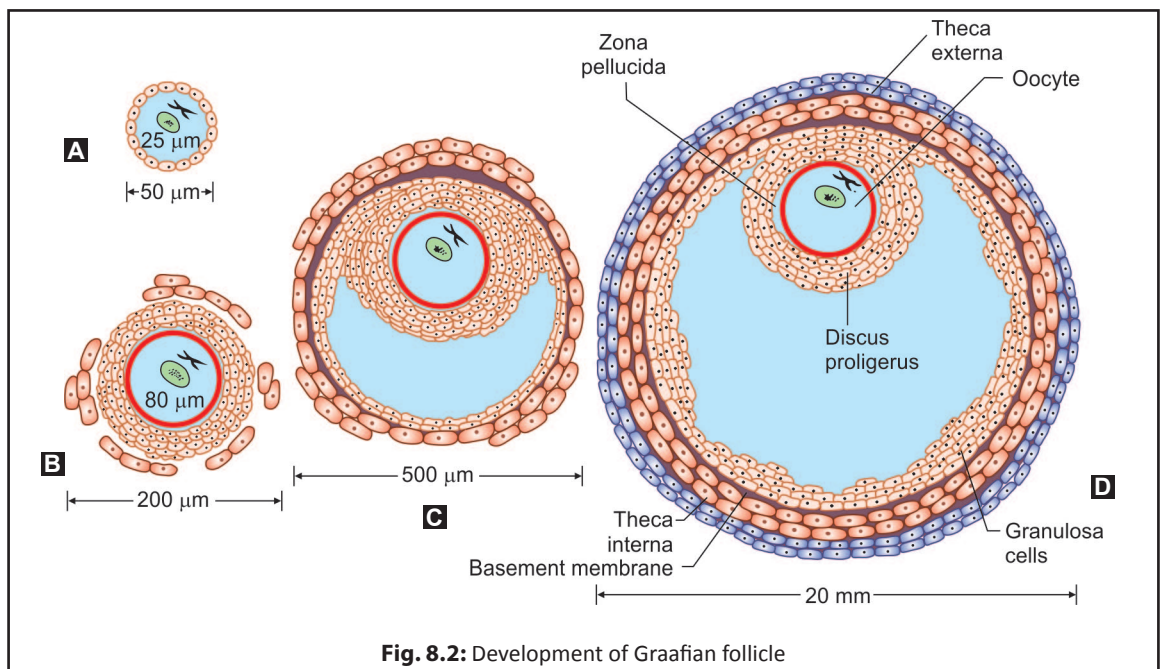
The development and maturation of a follicle, ovulation and formation of corpus luteum and its degeneration constitute an ovarian cycle. All these events occur within 4 weeks.

#### Thus, the ovarian cycle consists of:

- ◆ Recruitment of groups of follicles
- ◆ Selection of dominant follicle and its maturation.
- ◆ Ovulation
- ◆ Corpus luteum formation
- ◆ Demise of the corpus luteum.

#### Recruitment of groups of follicles (Preantral phase)

The cohort of the growing follicles undergoes a process of development and differentiation which takes about **85 days and spreads over 3 ovarian cycles.**



**Fig. 8.2:** Development of Graafian follicle

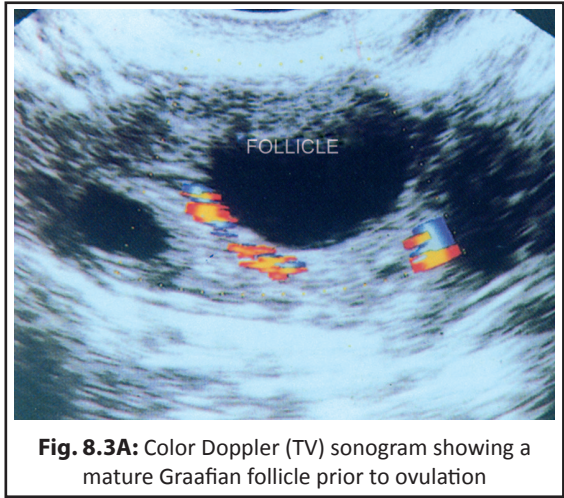
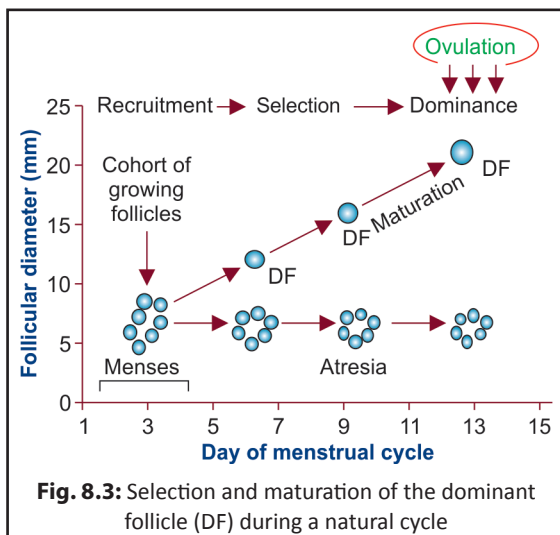
It is not clear as to how many and which of the primordial follicles amidst several thousands are recruited for a particular cycle. It is presumed that about 20 antral follicles (about 5–10 per ovary) proceed to develop in each cycle.

The initial recruitment and growth of primordial follicles are not under the control of any hormone. After a certain stage (2–5 mm in size) the growth and differentiation of primordial follicles are under the control of FSH. **Unless the follicles are rescued by FSH at this stage, they undergo atresia.**

There is predominant change is in the oocyte which is enlarged out of proportion to the size of the follicle. The oocyte is now surrounded by an acellular barrier of glycoprotein produced by the follicular cells and is called **zona pellucida**. The flattened outer single layer pregranulosa cells become cuboidal and multilayered—now called granulosa cells. There is appearance of channels (gap junctions) between the granulosa cells and the oocyte. Through these gap junctions nutrition to the oocyte is maintained. There is noticeable beginning of differentiation of the theca interna layer of ovarian stroma surrounding the follicle. The granulosa cells now acquire FSH receptors.

### Selection of a dominant follicle and its maturation

The Graafian follicle is named after the **Dutch physician and anatomist Reijnier de Graaf (1641–1673)**. The development of antrum containing secondary or vesicular follicle from the solid primary follicle depends on FSH.



There is accelerated growth of all the components of the follicles of the preantral phase. The granulosa cells grow faster than the theca cells. There is production of follicular fluid which is primarily an ultrafiltrate of blood from the vessels within theca interna. The fluid-filled space is formed amidst the granulosa cells. The spaces coalesce to form an antrum.

### Dominant Follicle

As early as day 5–7, one of the follicles out of so many becomes dominant and undergoes further maturation. It seems probable that the **one with highest antral concentration of estrogen and lowest androgen: estrogen ratio (estrogenic microenvironment) and whose granulosa cells contain the maximum receptors for FSH, becomes the dominant follicle.** The rest of the follicles become atretic by day 8 (Fig. 8.3).

There is marked enlargement of the granulosa cells with lipid inclusion. The granulosa cells surround the ovum to form cumulus oophorus or discus proligerus which infact anchors the ovum to the wall of the follicle. The cells adjacent to the ovum are arranged radially and is called corona radiata (Figs 8.2 and 8.4). At this stage, **FSH induces LH receptors on the granulosa cells of the dominant follicle.** LH receptor induction is essential for the midcycle LH surge to induce ovulation, luteinization of the granulosa cells to form corpus luteum and secretion of progesterone (two cell, two gonadotropin therapy—see p. 72).

Theca cells becomes vacuolated and more vascular than those of other antral follicles. The theca cells are

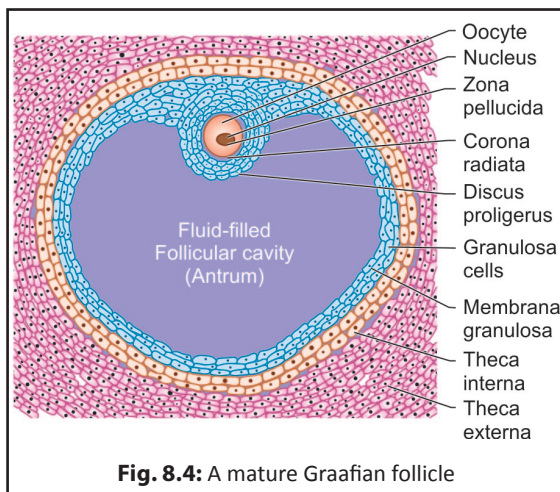
separated from the granulosa cells by a polymerized membrane called membrana granulosa. Just prior to ovulation, LH may act to depolymerize this membrane to facilitate vascularization of the granulosa cells.

The follicular fluid is increased in amount. **The fluid contains** estrogens, FSH, trace amount of androgen, prolactin, OMI (oocyte maturation inhibitor), LI (luteinization inhibitor), inhibin—which acts centrally to inhibit FSH, proteolytic enzymes, plasmin, etc.

**The fully mature Graafian follicle just prior to ovulation measures about 20 mm**, and is composed of the following structures from outside inward (Fig. 8.4).

- a. Theca externa.
- b. Theca interna.
- c. Membrana granulosa (limitans).
- d. Granulosa cell layer.
- e. Discus proligerus in which the ovum is incorporated with cells arranged radially (corona radiata).
- f. Antrum containing vesicular fluid.

As previously mentioned, it takes 3 months for the follicle to grow and mature to ovulation—2 months to reach an antral stage measuring 1 mm; 2 weeks to reach 5 mm and another 2 weeks to reach 20 mm before ovulation.



**Fig. 8.4:** A mature Graafian follicle

## Ovulation

The dominant follicle, shortly before ovulation reaches the surface of the ovary. The cumulus becomes detached from the wall, so that the ovum with the surrounding cells (corona radiata) floats freely in the liquor folliculi. The oocyte completes the first meiotic division with extrusion of the first polar body which is pushed to the perivitelline space. The follicular wall near the ovarian surface becomes thinner. The stigma develops as a conical projection which penetrates the outer surface layer of the ovary and persists for a while (30–120 seconds) as a thin membrane. The cumulus escapes out of the follicle by a slow oozing process, taking about 60–120 seconds along with varying amount of follicular fluid. The stigma is soon closed by a plug of plasma.

## Causes

The following are the possible explanations which may operate singly or in combination.

### 1. Endocrinal

#### ◆ LH surge

Sustained peak level of estrogen for 24–48 hours in the late follicular phase results in LH surge from the anterior pituitary (positive feedback effect). Effective LH surge persists for about 24 hours. The **LH surge stimulates** completion of retraction division of the oocyte and initiates luteinization of the granulosa cells, synthesis of progesterone and prostaglandins.

#### ◆ FSH rise

Preovulatory rise of 17- $\alpha$ -hydroxy progesterone facilitates the positive feedback action of estrogen to induce FSH surge  $\rightarrow$  increase in plasminogen activator  $\rightarrow$  plasminogen  $\rightarrow$  plasmin  $\rightarrow$  helps lysis of the wall of the follicle.

Thus, the combined LH/FSH midcycle surge is responsible for the final stage of maturation, rupture of the follicle and expulsion of the oocyte.

### 2. Stretching factor

It is more a passive stretching causing necrobiosis of the overlying tissue rather than rise in intrafollicular pressure which remains static at about 10–15 mm Hg.



3. **Contraction of the micromuscles** in the theca externa and ovular stroma due to increased local prostaglandin secretion.

### Effects of Ovulation

Following ovulation, the follicle is changed to corpus luteum. The ovum is picked up into the fallopian tube and undergoes either degeneration or further maturation, if fertilization occurs. **Menstruation is unrelated to ovulation and anovular menstruation is quite common during** adolescence, following childbirth and in women approaching menopause.

### Corpus Luteum

After ovulation, the ruptured Graafian follicle develops into corpus luteum. The life cycle is divided into four stages:

- **Proliferation**
- **Vascularization**
- **Maturation**
- **Regression**

### Stage of Proliferation

The collapsed walls of the empty follicle form convolutions. The opening through which the ovum escapes soon becomes plugged with fibrin. The granulosa cells undergo hypertrophy without multiplication. The cells become larger, polyhedral with pale vesicular nuclei and frothy cytoplasm. The cells are called granulosa lutein cells. The color of the

corpus luteum at this stage is greyish yellow due to presence of lipids (Fig. 8.5).

### Stage of Vascularization

Within 24 hours of rupture of the follicle, small capillaries grow into granulosa layer towards the lumen accompanied by lymphatics and fibroblasts. The sprouting vessels may rupture and bleed in the cavity.

### Stage of Maturation

By 4th day, the luteal cells have attained the maximum size. Approximately about 7–8 days following ovulation, the corpus luteum attains a size of about 1–2 cm and reaches its secretory peak. There is hypertrophy of the theca interna cells. The cells persist in the periphery and in the septa and are called paralutein cells. Some theca lutein cells called ‘K’ cells invade the granulosa layer. The lutein cells become greatly enlarged and develop lipid inclusion, giving the cells a distinctive yellowish color. **The color is due to the pigment carotene.** The cavity may be small containing scanty fluid.

### Stage of Regression

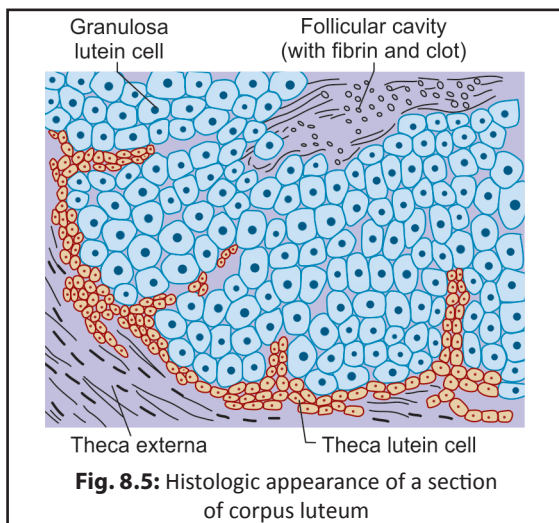
**On the day 22–23 of cycle, retrogression starts.**

The first evidence of degeneration is appearance of vacuolation in the cells. There is deposition of fat in the lutein cells and appearance of hyaline tissue between them. The lutein cells atrophy and the corpus luteum becomes corpus albicans. Regression of corpus luteum is due to withdrawal of tonic LH support.

If, however, fertilization occurs in the particular cycle, regression fails to occur, instead it is converted into corpus luteum of pregnancy.

### Hormones in Relation to Formation and Maintenance of Corpus Luteum

1. FSH in presence of high level of estrogen induces LH receptors in the granulosa cells of the dominant follicle. Thereafter midcycle LH surge causes luteinization of the granulosa cells and progesterone secretion. LH secretion must be continued for the function of corpus luteum, failing which the corpus luteum will regress.
2. Adequate folliculogenesis in the preovulatory phase with increased secretion of estradiol and of 17- $\alpha$ -hydroxy progesterone is a prerequisite for adequate corpus luteum formation.



3. Low level of prolactin: Corpus luteum has a life span of about 12–14 days. The cause of degeneration of corpus luteum in an infertile cycle is not clear. It has been suggested that prostaglandin F<sub>2</sub>  $\alpha$  liberated from the ovary is luteolytic. Estradiol is also considered to have luteolytic effect. The role of prolactin is not clear.

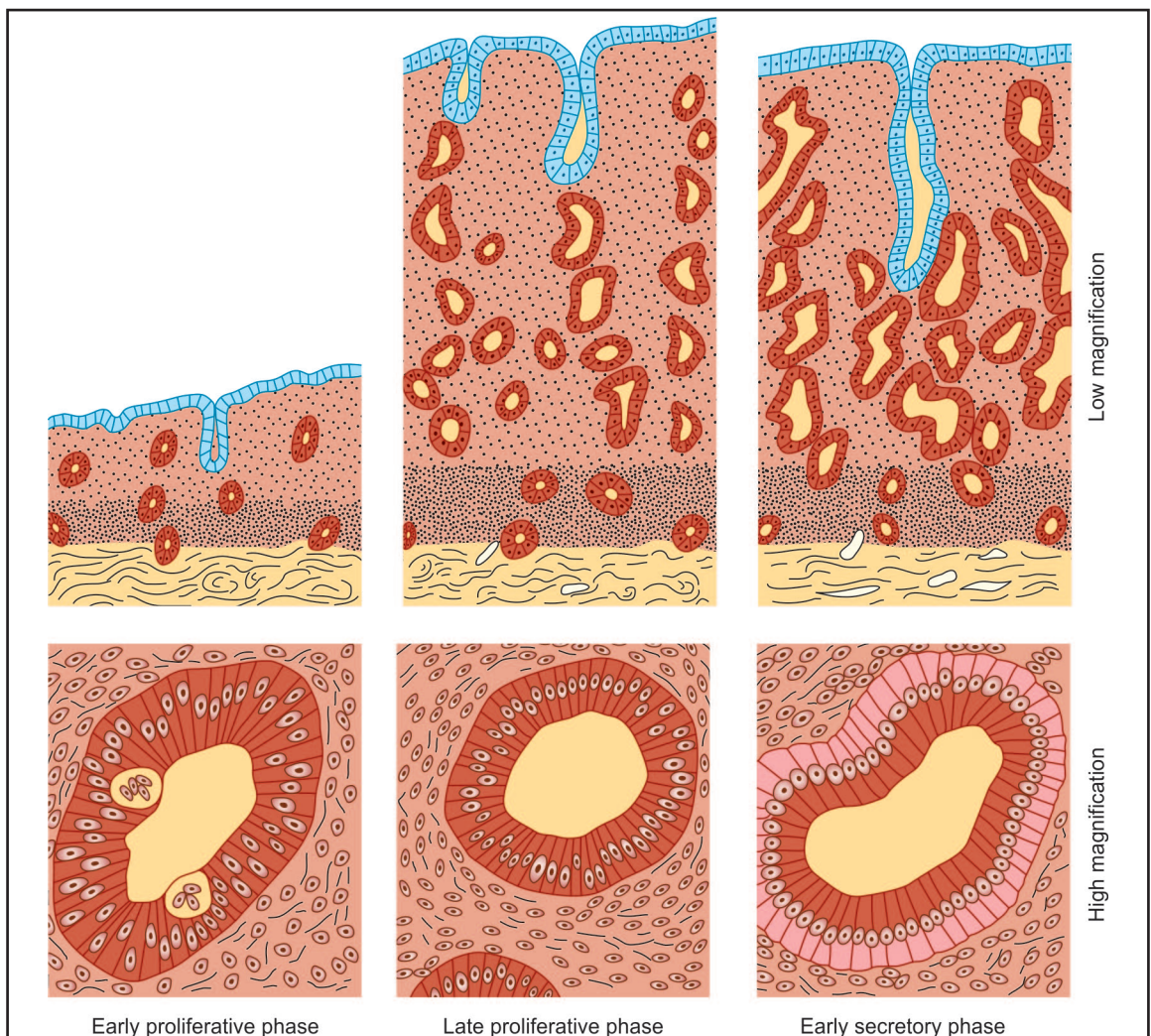
### Corpus Luteum of Pregnancy

There is a surge of hyperplasia of all the layers between 23rd to 28th day due to chorionic gonadotropin. hCG, like LH will stimulate the corpus luteum to secrete

progesterone. The 'K' cells are also increased in number. The growth reaches its peak at about 8th week when it measures about 2–3 cm. It looks bright orange, later on becomes yellow and finally pale. Regression occurs following low levels of chorionic gonadotropin and the degenerative changes take place most frequently at about 6 months of gestation.

### Hormone Secretion

Hormones—predominantly progesterone is secreted by the corpus luteum to support the endometrium of the luteal phase. There is also secretion of estrogen,



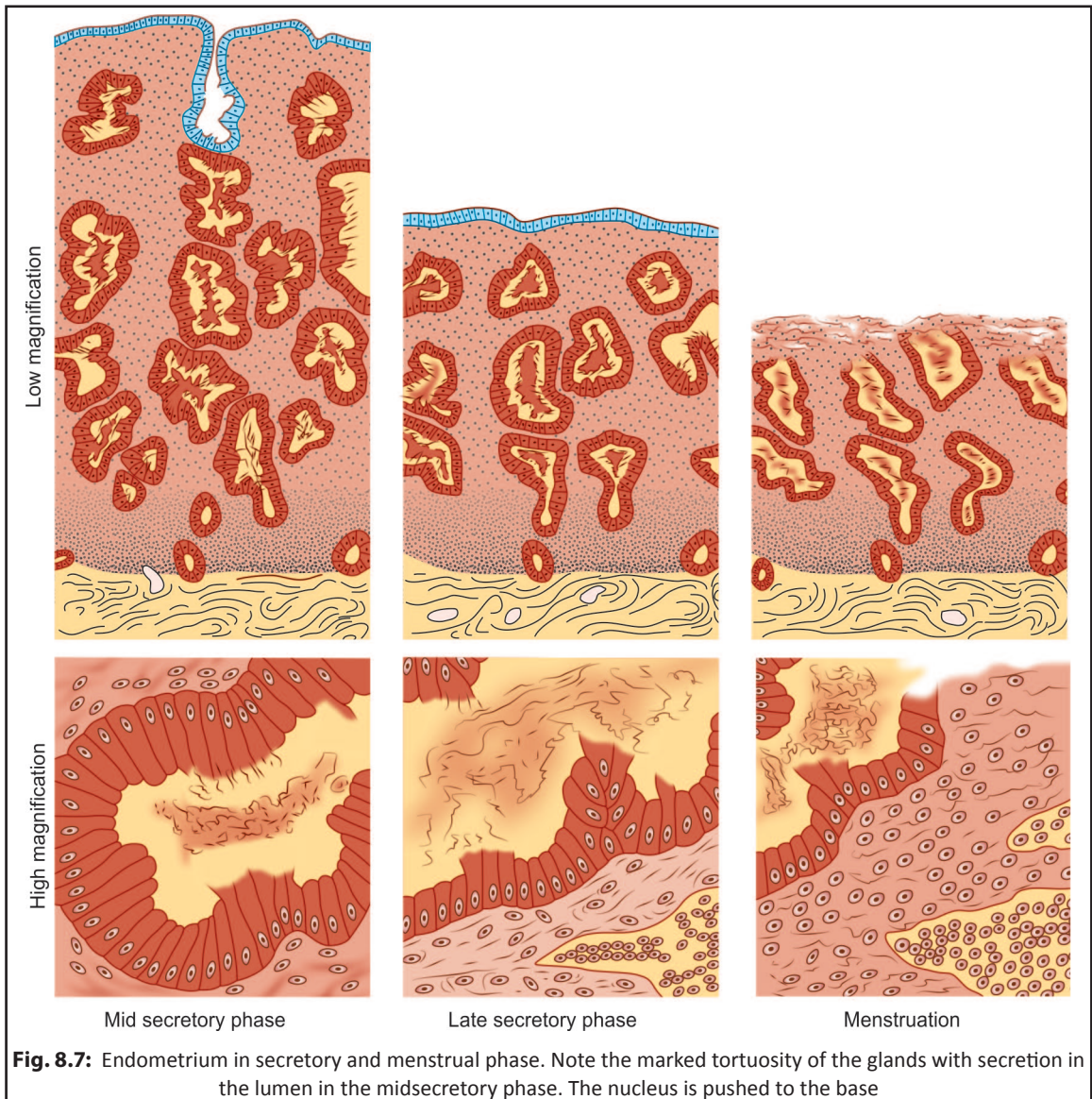
**Fig. 8.6:** Endometrium in proliferative and early secretory phase. Note the tendency of tortuosity of the glands and the characteristic subnuclear vacuolation in early secretory phase (cf compare with those of proliferative phase)

inhibin and relaxin. Progesterone along with estrogen from corpus luteum maintain the growth of the fertilized ovum. This is essential till the luteal function is taken over by the placenta. **This turn over of function from corpus luteum of pregnancy to placenta is called luteal-placental shift. This transition period continues from seven weeks to ten weeks.** In the absence of pregnancy, there is fall in the levels of **serum estradiol, progesterone and inhibin.** This removes the inhibitory control of GnRH and FSH. Gradual increase in FSH is

responsible for fresh recruitment of follicles for the next cycle.

### FOLLICULAR ATRESIA

Atresia is a continued process which actually starts at 20th week of intrauterine life and ends at menopause. It may affect a follicle at any stage of development. However, the following descriptions are related to atretic changes of a maturing follicle which is ultimately left out in the race of a dominant follicle.



**Changes in the ovum occur first.** The ovum swells and undergoes hyaline and fatty degeneration. Granulosa cells then regress at a faster rate than the cells of theca interna. Hyaline tissue is deposited beneath the membrana granulosa to form the glass membrane which is the classic feature of follicular degeneration. Liquor folliculi is gradually absorbed with increasing formation of hyaline tissue in the glass membrane. Eventually, the follicle collapses; its cavity is obliterated when the opposing surfaces of the glass membranes come in contact. In the periphery, deep staining theca interna cells persist and are called interstitial cells of the ovary. These cells atrophy after menopause.

### CAUSES OF GERM CELL LOSS AND FOLLICULAR ATRESIA

Exact factors are unknown. The following are the possible explanations for follicular degeneration and atresia:

- ▶ Oogonia having no granulosa cell layer envelope.
- ▶ Follicles that do not enter the germ cell meiotic division
- ▶ Follicles not rescued by FSH
- ▶ Follicles not having estrogen induced FSH receptors
- ▶ Follicles losing FSH receptors due to negative feedback effect of estrogen secreted by the dominant follicle
- ▶ Follicles losing FSH receptors due to high androgen: estrogen ratio (androgenic follicular microenvironment)
- ▶ Genetic influence—as in 45, X individual
- ▶ Apoptosis—programmed cell death.

Under the action of LH, more **androgens** are formed from these thecal cells which perhaps have got two functions: (i) **to enhance the process of atresia** of the small follicles; and (ii) **to stimulate libido** specially noticed in midmenstrual period.

## ENDOMETRIAL CYCLE

The endometrium is the lining epithelium of the uterine cavity above the level of internal os. It consists of **surface epithelium, glands, stroma and blood vessels**. Two distinct divisions are established—**basal zone (stratum basalis) and the superficial functional zone**.

### BASAL ZONE

It is about one-third of the total depth of the endometrium and lies in contact with the myometrium. It consists of stromal cells which stain deeply and are compactly placed. The base of the endometrial glands extends into the layer. The zone is supplied by the basal arteries. The zone is uninfluenced by hormone and as such, no cyclic changes are observed. After shedding of the superficial part during menstruation, the regeneration of all the components occurs from this zone. **It measures about 1 mm.**

### FUNCTIONAL ZONE

This zone is under the influence of fluctuating cyclic ovarian hormones, estrogen and progesterone. The changes in different components during an ovulatory cycle has been traditionally divided into four stages (Figs 8.6 to 8.9).

- ◆ Regenerative phase.
- ◆ Proliferative phase.
- ◆ Secretory phase.
- ◆ Menstruation.

### STAGE OF REGENERATION

Regeneration of the endometrium starts even before the menstruation ceases and is completed 2–3 days after the end of menstruation. The cubical surface epithelium is derived from the gland lumina and stromal cells. New blood vessels grow from the stumps of the old one. The glands and the stromal cells are regenerated from the remnants left in the basal zone. The glands are lined by the cubical epithelium and lie parallel to the surface. The stromal ground substance re-expands. **The thickness averages 2 mm.**

### STAGE OF PROLIFERATION

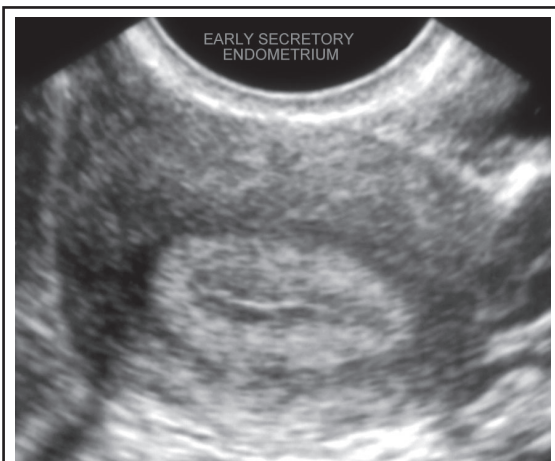
This stage extends from 5th or 6th day to 14th day (till ovulation). The proliferative changes occurs due to rise in level of ovarian estrogens. There is proliferation of all the elements—at first slowly but later on at a rapid pace. **The glands** become tubular and lie perpendicular to the surface. **The epithelium** becomes columnar with the nuclei placed at the base. The epithelium of one gland becomes continuous with the neighboring gland. Mitosis is evident in the epithelial cells. **The stromal cells** become spindle-shaped with evidences of mitosis and are compact. **The spiral vessels** extend unbranched to a region

below the epithelium where they form loose capillary network. There may be evidences of subepithelial congestion. **The thickness measures about 3–4 mm.**

### SECRETORY PHASE

The changes of the components are due to the combined effects of estrogen and progesterone liberated from the corpus luteum after ovulation. The endometrium contains receptors for progesterone which are induced by estrogen. **Thus, the progesterone can only act on the endometrium previously primed by estrogen.**

All the components display their growth. It begins on day 15 and ceases 5–6 days prior to menstruation. **The surface epithelium** becomes more columnar and ciliated at places. The glands show predominant changes. **The glands** increase in size. The lining epithelium become taller. There is appearance of vacuoles due to secretion of glycogen between the nuclei and the basement membrane. This is called **subnuclear vacuolation**, which is the **earliest (36–48 hours) evidence of progesterone effect (ovulation)**. **The subnuclear vacuolation persists until about 21st day of cycle.** The intracellular secretion then enters the gland lumina on the way to the uterine cavity pushing the nuclei back towards the basement membrane. The effect is a saw-toothed glandular epithelium. The fluid has got nutritive value for any fertilized ovum reaching the uterus during that time. **The glands become corkscrew-shaped. The blood vessels undergo marked spiraling.**



**Fig. 8.8:** Transvaginal scan demonstrating thickened, triple line endometrium (preovulatory phase)

**The stromal cells** become swollen, large and polyhedral and after the 21st day tend to collect more superficially around the neck of the glands. The deeper spongy layer is composed of convoluted glands, coiled arterioles and comparatively few stromal cells in edematous stroma. Histochemical studies show increase in glycogen and acid phosphatase. Histological staining is eosinophilic **The thickness of the endometrium reaches its highest (6–8 mm) (Fig. 8.8).**

The endometrial growth ceases 5–6 days prior to menstruation (22nd or 23rd day of cycle) in an infertile cycle. This is due to dehydration of the glands. The subepithelial capillaries and the spiral vessels are engorged. **The regressive changes in the endometrium are pronounced 24–48 hours prior to menstruation.** There is marked spiralling of the arteries and the withdrawal of hormones estrogen and progesterone causes intense spasm of the spiral arterioles at the basal part. These two lead to stasis and tissue anoxemia. There are evidences of infiltration of leucocytes and monocytes in the stroma.

### MENSTRUAL PHASE

It is essentially degeneration and casting off an endometrium prepared for a pregnancy. **Regression of corpus luteum with fall in the level of estrogen and progesterone is an invariable preceding feature.** As a result of withdrawal of hormone support, there is retrogressive changes in the endometrium as mentioned earlier.

### MECHANISM OF MENSTRUAL BLEEDING

The degenerative changes are predominantly of vascular origin. **Stasis** of blood and **spasm** of the arterioles lead to damage of the arteriolar walls. Phase of relaxation leads to escape of blood out of the vessels through the damaged walls. The degenerative process is rapid and involves all the components of the functional damaged layer. There is local tissue destruction by release of **proteolytic enzymes** from the breakdown of lysosomes. **So there is enzymatic autodigestion of the functional zone.** **The bleeding occurs** from the broken arteries, veins and capillaries and also from the stromal hematoma. The blood along with the superficial functional layer is shed into the uterine cavity. The blood **coagulates** in the uterine cavity but soon liquefies by **plasmin**

unless the bleeding is very brisk and rapid. **The menstrual flow** stops as a result of combined effect of prolonged vasoconstriction, myometrial contraction and local aggregation of platelets with deposition of fibrin around them. Endothelin and platelet activating factor present in the endometrium are potent vasoconstrictors. Resumption of estrogen secretion leads to clot formation over the decapitated stumps of endometrial vessels. There is simultaneous repair of endometrium. This is under control of estrogen and different growth factors.

### ROLE OF PROSTAGLANDINS

It is likely that the arteriolar constriction and endometrial necrosis are caused by prostaglandins. The endometrium and partly the myometrium, synthesize the prostaglandins from arachidonic acid by the enzyme cyclo-oxygenase. Different prostaglandins have got different action.  $PGF_2\alpha$  causes myometrial contraction and vasoconstriction. It seems to play a dominant role in normal cycle.  $PGE_2$  produces myometrial contraction but causes vasodilatation.  $PGI_2$  (Prostacyclin) causes myometrial relaxation and vasodilatation. It also inhibits platelet activity. Thus, the menstrual pain and blood flow are probably related to the relative proportion of different prostaglandins present in the endometrium.

### HORMONES IN RELATION TO OVARIAN AND MENSTRUAL CYCLE

The outcome in relation to hormonal interplay in normally menstruating women includes:

- Growth and development of the Graafian follicle.
- Ovulation.
- Maintenance and demise of corpus luteum.
- Endometrial growth and shedding.

### GROWTH AND DEVELOPMENT OF THE FOLLICLE (FIG. 8.9)

At the **beginning of a menstrual** cycle, a low level of estrogen and inhibin secreted from the previous weaning corpus luteum maintains a high FSH level through release of negative feedback of estrogen. The FSH increases not only its own receptors in the granulosa cells but also LH receptors in theca cells. Initial sustained low level of LH stimulates the

production of estrogen. Under the synergistic effect of FSH and estrogen, multiplication of the granulosa cells, formation of the follicular fluid and synthesis of more LH receptors in the theca cells occur.

With increased secretion of estrogen, the FSH level is lowered through a negative feedback mechanism. Thus, the initial high level of FSH comes down to a static base level by day 5. Paradoxically, the increasing LH level with the rising estrogen level stimulates androgen production in the theca cells. Granulosa cells now utilize the increased androgen produced from the theca cells for the synthesis of estrogen.

The falling FSH level with peak rise of estrogen in the late follicular phase increases the LH receptors in the granulosa cells. Final maturation of the follicle is thus achieved by the combined effect of FSH and LH.

### ROLE OF PEPTIDES AND GROWTH FACTORS (P. 76)

**Peptides**—FSH stimulates the granulosa cells to produce a number of peptides like inhibin, activin and follistatin. Activin is also secreted by the pituitary gland. Inhibin directly inhibits FSH, where as activin stimulates FSH.

**Growth factors**—Insulin like growth factors (IGF), epidermal growth factors and others, modulate the action of FSH, LH and the peptides. IGF-11, is produced in the theca cells. It stimulates aromatase activity and progesterone synthesis in the granulosa cells.

## OVULATION

LH surge initiates luteinization acting through its receptors about 24–48 hours. prior to ovulation. A trace amount of  $17\text{-}\alpha$ -hydroxy progesterone is formed which is probably responsible for completion of the first meiotic division of the oocyte and compounds the effect of estrogen for LH surge. Progesterone also facilitates the positive feedback action to induce FSH surge → increase in plasminogen activator → plasminogen → plasmin → helps lysis of the follicular wall.

After the estradiol reaches beyond the critical level of 200 pg/mL and is sustained for about 48 hours, it exerts a positive feedback action to LH

from the anterior pituitary (LH surge). **Ovulation occurs approximately 10–12 hours after the LH peak or 32–36 hours after the onset of LH surge.** A threshold of LH surge generally persists for 24 hours. **Ovulation coincides approximately 24–36 hours after the peak estradiol level. LH surge stimulates completion of the reduction division of the oocyte and initiates luteinization of the granulosa cells and synthesis of progesterone and prostaglandins.**

Thus, the **combined LH/FSH midcycle surge** is responsible for the final stage of maturation of the follicle, completion of the first meiotic division of the oocyte with extrusion of the first polar body and expulsion of the oocyte (ovulation).

The drop in LH level following its peak may be due to desensitization of LH receptors or due to negative feedback effect of progesterone. This down regulation results in a refractory state during which there is diminished steroidogenesis.

Events	Hours
Estradiol rise	83
Onset of LH surge	34–36
Estradiol peak	24–36
LH peak	10–12
Progesterone rise	8

### MAINTENANCE AND DEMISE OF CORPUS LUTEUM

Soon following the LH surge, the level of estrogen drops down within an hour and the LH peak after 24 hours. LH initiates and maintains the corpus luteum from which both progesterone and estrogen are secreted. The estrogen attains a lower level and maintains a plateau curve as against a peak rise in follicular phase. **17- $\alpha$ -hydroxy progesterone** parallels with the estradiol level in the luteal phase. **Progesterone attains its highest peak about 8 days after the LH peak.** Through intraovarian and central negative feedback mechanisms, **progesterone acts to suppress new follicular growth.** As the estrogen and progesterone attain their highest peak, they

exert a negative feedback effect on LH and FSH in an infertile cycle and the level of LH and FSH drops down to a minimum. The lysis of the corpus luteum occurs and so the secretion of progesterone and estrogen falls. **The life span of corpus luteum is about 12–14 days.** With the fall of estrogen and progesterone, FSH level again rises under the influence of GnRH to exert its effect on follicular growth and maturation for the next cycle (Figs 8.9 and 8.10).

### ENDOMETRIAL GROWTH AND SHEDDING

Estrogen secreted in the follicular phase produces proliferative changes in the endometrium and induces receptors for progesterone. In the luteal phase, progesterone acts on the estrogen primed endometrium having sufficient number of receptors and produces secretory changes. In the infertile cycle, with the fall of estrogen and progesterone, the endometrium becomes unsupported to the hormones and degeneration occurs → menstruation (Fig. 8.10).

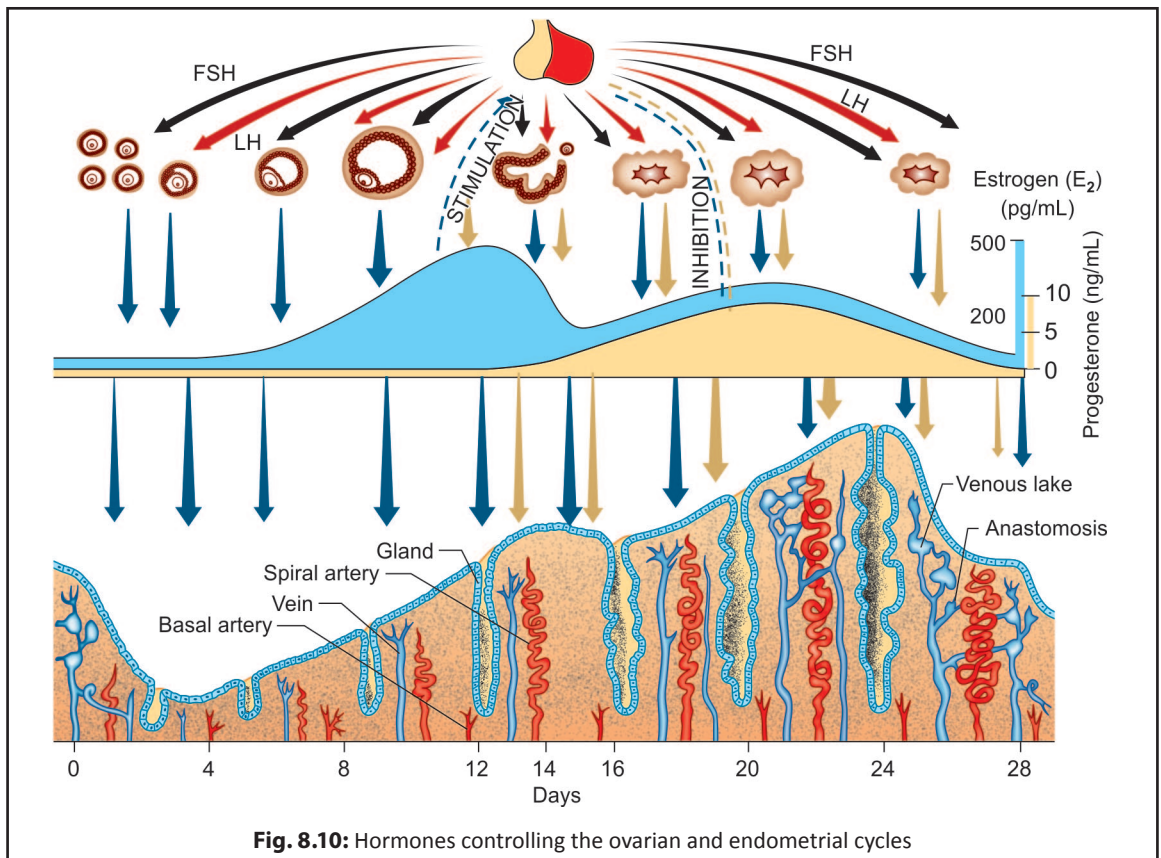
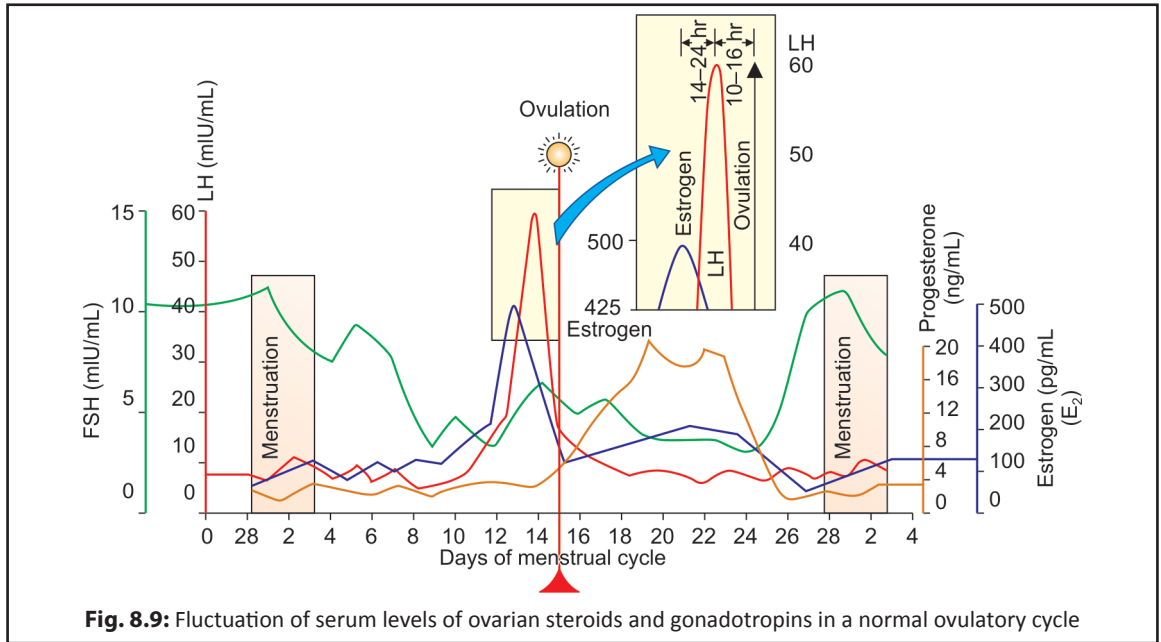
Endometrial sample biopsy and histology can precisely determine the date of menstrual cycle. Any discrepancy of **more than two days** when examined in the post ovulatory phase is called **luteal phase defect.** This method of endometrial examination is called **dating of endometrium.**

### LUTEAL-FOLLICULAR SHIFT

**This period extends from the demise of corpus luteum (fall of serum estradiol, inhibin and progesterone level) to the selection of a dominant follicle for the next cycle.** The recruitment of follicles is done by FSH. The decrease in inhibin level removes its suppressive effect of FSH secretion in the pituitary. FSH level starts rising about 2 days before the onset of menses. Fall in the level of estradiol and progesterone allows pulsatile secretion of GnRH. Rising FSH level rescues the follicles from atresia and selects the dominant follicle.

### MENSTRUAL SYMPTOMS

In majority, apart from bleeding per vaginum there is no symptom. Initially, it begins as pink discharge but





on day 2 and 3 it becomes dark red. In teenagers or nulliparous, there may be associated tolerable colicky pain at the beginning due to uterine contraction. If the pain is of sufficient magnitude so as to incapacitate the day-to-day activities, it is called dysmenorrhea (see Ch 14). There may be premonitory symptoms such as pelvic discomfort, backache, fullness of the breasts or mastalgia just prior to menstruation. Headache or depression may be present. If these premonitory symptoms are predominant, these are grouped into a syndrome called “premenstrual syndrome” and is dealt separately in a later chapter.

### MENSTRUAL HYGIENE

Sympathetic and careful handling of the young girls experiencing first menstruation is of paramount importance. This should be done by the mother explaining the physiological and other associated changes during period. The girls should continue with their normal activities. The daily bath should not be suspended. During initial few periods, the girl may use sanitary pads comfortably but with experience may be changed to tampon, if so desired.

### ANOVULAR MENSTRUATION

In an anovulatory cycle, the follicles grow without any selection of dominant follicle. The estrogen is secreted in increasing amount. There may be imbalance

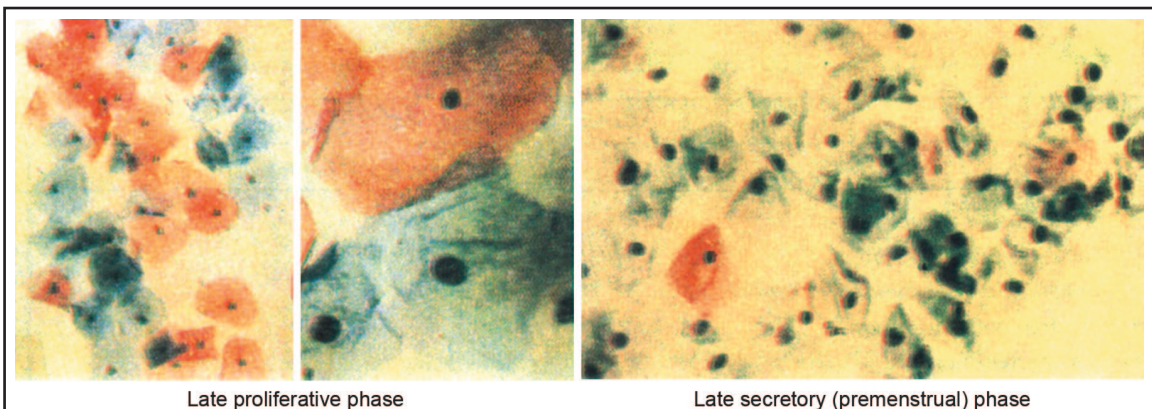
between estrogen and FSH or because of temporary unresponsiveness of the hypothalamus to the rising estrogen, GnRH is suppressed → no ovulation. The net effect is unopposed secretion of estrogen till the follicles exist. The endometrium remains in either proliferative or at times hyperplastic state. There is inadequate structural stromal support and the endometrium remains fragile. When the estrogen level falls, there is asynchronus shedding of the endometrium and menstruation. The bleeding may be heavy or prolonged and irregular.

**This type of bleeding is mostly found** during adolescence, following childbirth and abortion and in premenopausal period.

### ARTIFICIAL POSTPONEMENT

Artificial alteration of the date of menstrual flow should be judiciously comply with. It should not be taken lightly. **It is preferable to defer than to advance the date** as the artificial withdrawal bleeding may be continued for a variable period which may spoil the purpose.

The hormones used for deferment of the period are—combined oral pill, 2 tablets daily or progestogen such as norethisterone 5 mg twice daily. The drug should be taken at least 3–6 days before the expected date of the period and continued until the crisis is over. The period is expected 2–3 days after the drug is suspended.



**Fig. 8.11:** Vaginal cytology—In the late proliferative phase, there are preponderance of superficial large cornified cells with pyknotic nuclei. The background is clear. In the premenstrual phase, there is preponderance of navicular cells. The background is dirty

**TABLE 8.2** CERVICAL CYCLE, VAGINAL CYCLE AND GENERAL CHANGES IN FOLLICULAR AND LUTEAL PHASE

<i>Cervical Cycle</i>		
Follicular phase	Luteal phase	
<ul style="list-style-type: none"> <li>◆ Internal os — funnel-shaped</li> <li>◆ Mucus — thin and watery</li> <li>◆ Stretchability — increased to beyond 10 cm</li> <li>◆ Fern tree pattern present</li> <li>◆ Glycoprotein network — parallel, thus facilitating sperm penetration</li> <li>◆ Glandular epithelium — taller</li> </ul>	<ul style="list-style-type: none"> <li>◆ Tightly closed</li> <li>◆ Thick and viscid</li> <li>◆ Lost</li> <li>◆ Lost</li> <li>◆ Interlacing bridges, preventing sperm penetration</li> <li>◆ Glands — more branched</li> </ul>	
<i>Vaginal Cycle (Fig. 8.11)</i>		
Follicular phase	Luteal phase	
<ul style="list-style-type: none"> <li>✦ Cytology — showing preponderance of superficial large cornified cells with pyknotic nuclei</li> <li>✦ Background of the smear — clear</li> </ul>	<ul style="list-style-type: none"> <li>✦ Preponderance of intermediate cells with folded edges (navicular cells)</li> <li>✦ Dirty due to presence of leucocytes and bacilli</li> </ul>	
<i>General Changes</i>		
Preovulatory	Ovulatory	Premenstrual
<ul style="list-style-type: none"> <li>✦ No symptom</li> </ul>	<ul style="list-style-type: none"> <li>✦ Pain abdomen on either iliac fossa</li> <li>✦ Slight vaginal bleeding</li> <li>✦ Mucoid vaginal discharge</li> </ul>	<ul style="list-style-type: none"> <li>✦ Irritability, lethargy, constipation</li> <li>✦ Acne</li> <li>✦ Pelvic discomfort</li> <li>✦ Abnormal gain in weight</li> <li>✦ Mastalgia</li> </ul>

## KEY POINTS

- Menstruation is the visible manifestation of cyclical physiologic uterine bleeding due to shedding of the endometrium as a result of invisible interplay of hormones mainly through hypothalamo pituitary ovarian axis.
- Average age of menarche is 13 years. The average menstrual blood loss is 35 mL (may be upto 80 mL). Average loss of iron in each menses is 13 mg and about 70 percent of total menstrual blood loss (MBL) occurs in the first 2 days (see p. 82). Alkali hematin method is most precise to measure the MBL.
- The primordial follicle measures 0.03–0.05 mm. Primitive ovum measures 18–24 microns in diameter.
- The primary oocyte undergoes first meiotic division giving rise to secondary oocyte and one polar body just prior to ovulation. The measurement of a primary oocyte just prior to ovulation (mature ovum) is 130 microns.
- The secondary oocyte completes the second meiotic division only after fertilization by a sperm in the fallopian tube.
- It is presumed that those follicles which are less exposed to progesterone environment are likely to run in the race for dominance in the next cycle.
- One follicle with highest antral concentration of estrogen and lowest androgen : estrogen ratio and the granulosa cells containing the maximum receptors for FSH becomes the dominant follicle. The fully mature Graafian follicle measures about 20 mm with a volume of 3.5 mL.

*Contd...*

*Contd...*

- With ultrasound the dominant follicle mean diameter is about 19.5 mm.
- LH surge stimulates the completion of first meiotic division, luteinization of granulosa cells, synthesis of progesterone and prostaglandins. Subnuclear vacuole is the first histologic evidence of progesterone effect. Preovulatory FSH surge (which is progesterone dependent) enhances conversion of plasminogen to plasmin for the lysis of follicular wall. Estradiol ( $E_2$ ) exerts negative feedback effect to FSH but bears a positive feedback effect to LH. Both FSH and LH regulates follicular development through a number of growth factors and peptides by autocrine and paracrine mechanism (see p. 70). Insulin growth factor II (IGF-II) is produced by theca and granulosa cells. IGF-II stimulates granulosa cell proliferation and aromatase activity (see p. 70). Inhibin is a peptide, secreted by the granulosa cells in response to FSH. Inhibin is a potent inhibitor of FSH. Activin, another peptide secreted by the granulosa cells and by the pituitary, stimulates FSH.
- Sustained peak level of estradiol for about 24 hours beyond 200 pg/mL in late follicular phase results in LH surge (positive feedback effect). Ovulation occurs about 32–36 hours after the onset of LH surge and about 10–12 hours of the LH peak levels. The mean duration of LH surge is about 24 hours. The peak LH levels plateau for about 14 hours. The cause of LH decline is probably due to acute down regulation or due to negative feedback effect of progesterone (p. 93, Table 8.1).
- After ovulation, the ruptured Graafian follicle becomes corpus luteum.
- The yellowish color is due to lipid and pigment carotene. Regression starts on day 22–23 of infertile cycle.
- LH hormone, with adequate number of LH receptors in the granulosa cells, as induced during folliculogenesis with increased secretion of estradiol, is the key factor of adequate corpus luteum formation (p. 85).
- The hormones—estrogen and progesterone are secreted from the corpus luteum.
- The follicles containing high androgen : estrogen ratio are destined to undergo atresia. Under the action of LH, more androgens are produced from the active thecal compartments (p. 85).
- The functional zone of the endometrium is under the influence of fluctuating cyclic ovarian hormones, estrogen and progesterone. Progesterone can only act on the endometrium previously primed by estrogen. Subnuclear vacuolation is the earliest evidence of ovulation and appears on 18th day and persists up to 21st day. The mechanism of menstrual bleeding is due to degenerative changes predominantly of vascular origin. The menstrual flow stops as a result of combined effect of prolonged vasoconstriction, myometrial contraction and local aggregation of platelets.
- $PGF_2\alpha$  causes myometrial contraction and vasoconstriction,  $PGE_2$  produces myometrial contraction but causes vasodilatation,  $PGI_2$  (prostacyclin) causes myometrial relaxation and vasodilatation.
- Under the synergistic effect of FSH and estrogen, multiplication of the granulosa cells, formation of the follicular fluid and synthesis of more LH receptors in the theca cells occur. The falling FSH level with peak rise of estrogen in the late follicular phase increases the LH receptors in the granulosa cells. Final maturation of the follicle is achieved by the combined effect of FSH and LH.
- Preovulatory FSH surge increases the plasmin which helps lysis of the follicular wall. LH surge stimulates completion of reduction division of the oocyte and initiates luteinization of the granulosa cells and synthesis of progesterone and prostaglandins.

*Contd...*

Contd...

- Progesterone attains its highest peak about 8 days after the LH peak. Through intraovarian and central negative feedback mechanisms, progesterone acts to suppress new follicular growth.
- When the endometrium becomes unsupported by the fall of estrogen and progesterone, degeneration occurs resulting in menstruation. The regressive changes in the endometrium are pronounced 24–48 hours prior to menstruation (p. 91).
- LH stimulates granulosa cell proliferation and luteinization and production of progesterone.
- Theca cells and the stroma of atretic follicles produce more androgens in the midcycle. This raised androgen level enhances further atresia of the small follicles. This also increases libido.
- Demise of corpus luteum is due to the luteolytic action of estrogen, prostaglandin  $F_{2\alpha}$ , nitric oxide, endothelin, TNF $\alpha$  and the proteolytic enzymes. hCG rescues the corpus luteum.
- **Luteal–Placental shift** is the turnover of function from corpus luteum of pregnancy to placenta. This transition period continues from seven weeks to ten weeks. This is essential for the growth of the fertilized ovum (p. 88).
- **Luteal–Follicular shift** is the period that extends from the demise of corpus luteum to the selection of a new dominant follicle for the next cycle. It is due to fall in the levels of estradiol, progesterone and inhibin. There is simultaneous rise in the levels of GnRH and FSH (p. 93).
- Rising in FSH level rescues follicles from apoptosis and selects the dominant follicle (p. 85 and 90).
- Menstrual cycle is associated with other changes like cervical, vaginal and general (Table 8.2). The cervical cycle includes changes in the cervix and cervical mucus. Vaginal cytology varies with the phases of menstruation. General changes includes the different symptoms (Table 8.2).

# Examination of a Gynecological Patient

**The clinical examination should be thorough and meticulous.** These include **in-depth history taking and examinations**—general, abdominal and internal. It should be emphasized that a meticulous history taking alone can give a positive diagnosis in majority of cases without any physical examination. The examination should, in fact, proceed with the provisional diagnosis in mind. On occasion, ancillary aids are required to confirm the diagnosis. For a careful history taking, the following outlines are of help:

- Name ..... Age .....
- Address .....
- Marital status ..... Parity .....
- Social status .....
- Chief complaint .....

A patient hearing should be given about the complaints made by the patient in her own words. In order to substantiate the guess made out of her complaints, some pertinent questions (open-ended or specific) may be asked tactfully and judiciously. Looking at the patient (direct observation) before speaking may give many clues (nonverbal) to the diagnosis, e.g. fear, sadness, apathy or anger.

## HISTORY

This should be taken in details. If multiple symptoms are present, their chronologic appearances are to be noted. Integration of the symptomatology to one pathology is to be tried first before embarking on the diagnosis of multiple pathology. Enquiry should be made about the bowel habits and urinary trouble, if any.

**Menstrual History:** Enquiry should be made about:

- ◆ Age of onset of the first period (menarche).
- ◆ Regularity of the cycle
- ◆ Duration of period
- ◆ Length of the cycle
- ◆ Amount of bleeding—Excess is indicated by the passage of clots or number of pads used
- ◆ First day of the last menstrual period (LMP).

The menstrual history can be reproduced as 13/4/28, representing that the onset of period was at the age of 13, bleeding lasts for 4 days and occurs every 28 days.

**Obstetric History:** If the patient had been previously pregnant, details are to be enquired as per tabulation below. Many a times, the complaints may be related to the pregnancy complications or lactation.

No. date	Year and events	Pregnancy events	Labor delivery	Method of delivery	Puer-perium	Baby weight and sex. Birth asphyxia. Duration of breastfeeding, contraception
1.						
2.						

The obstetric history is to be summed up as—

No. of living children .....Boys.....Girls.....  
 Health status of the baby .....  
 Immunization ..... Last child birth .....

### Past Medical History

Relevant medical disorders—systemic, metabolic or endocrinal (diabetes, hypertension, hepatitis) should be enquired. Their presence requires care during operative procedure. Next pertinent point is the interrogation about sexually transmitted diseases.

### Past Surgical History

This includes general, obstetrical or gynecological surgery. The nature of the operation, anesthetic procedures, bleeding or clotting complication if any, postoperative convalescence are to be enquired. Any histopathological report or relevant investigation related to the previous surgery is most often helpful.

### Family History

It is of occasional value. Malignancy of the breast, colon, ovary or endometrium is often related. Tubercular affection of any family member can give a clue in diagnosis of pelvic tuberculosis.

### Personal History

Occupation, marital status—married, widow, divorced or separated should be enquired. If married—details of sexual history should be taken, especially in case of infertility. Sexual history includes any sexual dysfunction, or dyspareunia. Contraceptive practice, if any should be enquired—especially relevant in pill users or cases having IUCD, as these methods often produce some adverse symptoms. History of taking drugs for a long time or allergy to certain drugs is to be noted.

## EXAMINATION

The examination includes:

- General and systemic examination
- Gynecological examination
  - ◆ Breast examination
  - ◆ Abdominal examination
  - ◆ Pelvic examination.

### GENERAL AND SYSTEMIC EXAMINATION

The general and systemic examination should be thorough and meticulous.

- ◆ *Built*—Too obese or too thin—May be the result of endocrinopathy and related to menstrual abnormalities
- ◆ *Nutrition*—Average/Poor
- ◆ *Stature*—Including development of secondary sex characters
- ◆ Pallor
- ◆ Jaundice
- ◆ Edema of legs
- ◆ *Teeth, gums and tonsils*—For any septic foci
- ◆ *Neck*—Palpation of thyroid gland and lymph nodes, especially the left supraclavicular glands
- ◆ Cardiovascular and respiratory systems—Any abnormality may modify the surgical procedure, if it deems necessary
- ◆ Pulse ◆ Blood pressure.

## GYNECOLOGICAL EXAMINATION

### Breast Examination (Fig. 9.1)

This should be a routine especially in women above the age of 30 to detect any breast pathology, the important being carcinoma. In India, **breast carcinoma is the second most common** malignancy in female, next to carcinoma cervix.

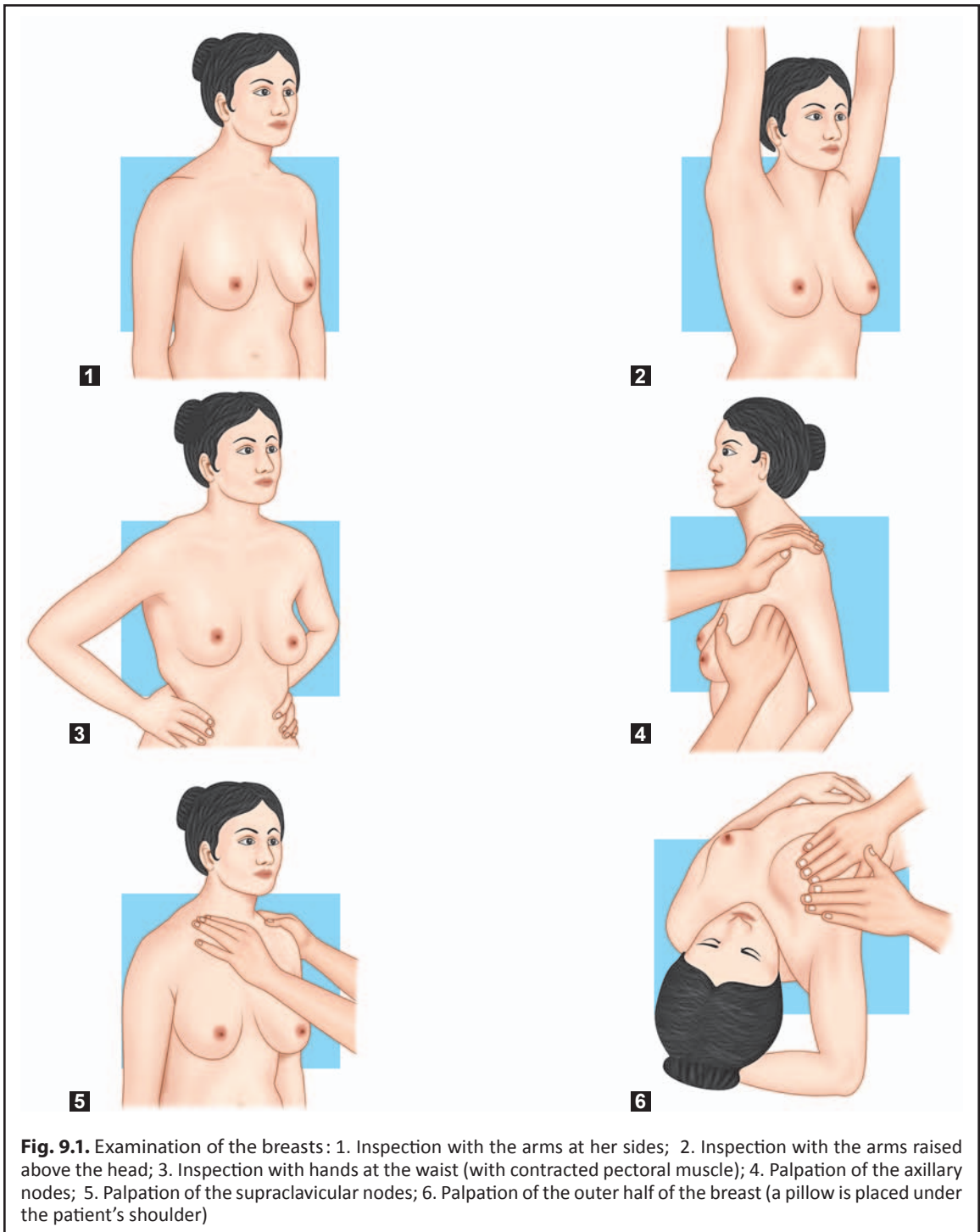
### Abdominal examination

#### Prerequisites

- **Bladder should be empty.** The only exception to the procedure is the presence of history suggestive of stress incontinence. If history is suggestive of chronic retention of urine, catheterization should be done taking aseptic precautions, using sterile simple rubber catheter
- The patient is to lie flat on the table with the thighs slightly flexed and abducted to make the abdominal muscles relaxed (see Fig. 9.3B)
- The physician usually prefers to stand on the right side
- Presence of a chaperone (a female) for the support of the patient and the physician.

#### Actual steps:

- ◆ Inspection ◆ Palpation
- ◆ Percussion ◆ Auscultation



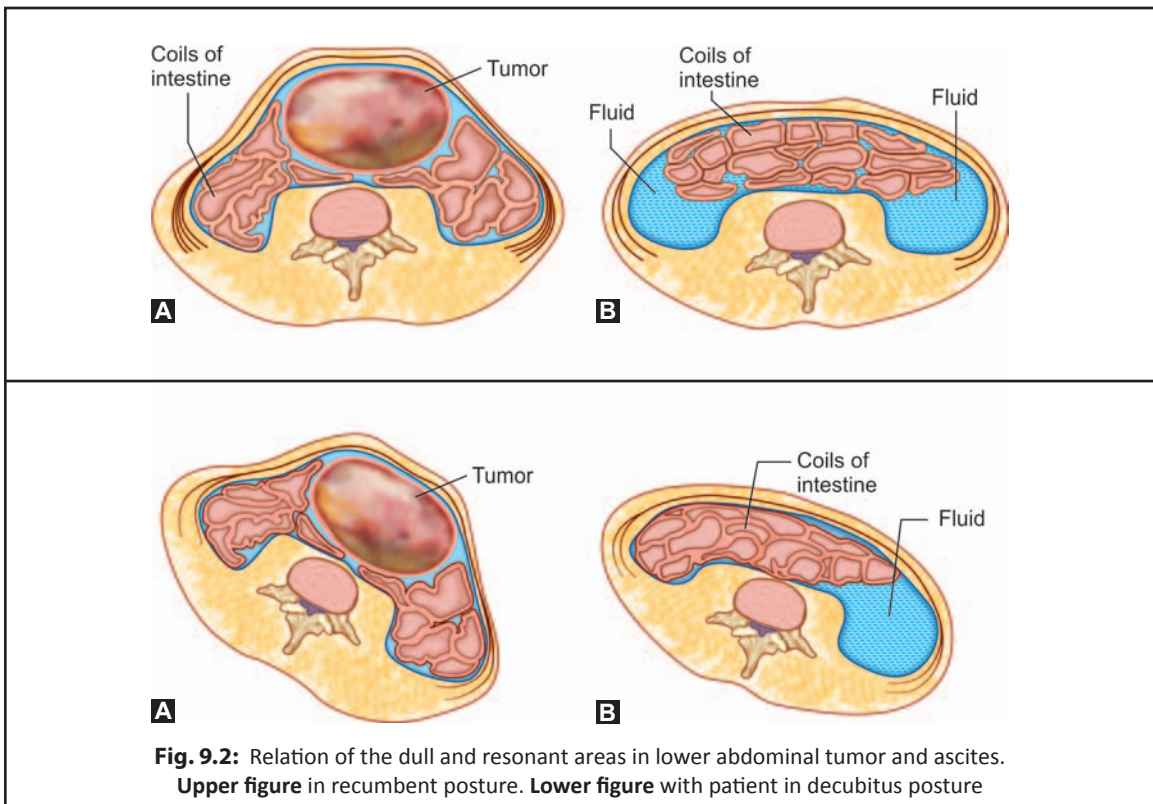
**Fig. 9.1.** Examination of the breasts: 1. Inspection with the arms at her sides; 2. Inspection with the arms raised above the head; 3. Inspection with hands at the waist (with contracted pectoral muscle); 4. Palpation of the axillary nodes; 5. Palpation of the supraclavicular nodes; 6. Palpation of the outer half of the breast (a pillow is placed under the patient's shoulder)

**Inspection:** The skin condition of the abdomen—presence of old scar, striae, prominent veins or eversion of the umbilicus is to be noted. By asking the patient to strain, one can elicit either incisional hernia or divarication of the rectus abdominis muscles. In intestinal obstruction, the abdomen is uniformly distended and the respiration is of thoracic type. In pelvic peritonitis, the lower abdomen is only distended with diminished inspiratory movements. In ascites, one can find fullness only in the flanks with the center remaining flat. A huge pelvic tumor is more prominent in the hypogastrium situated either centrally or to one side. Female escutcheon over the mons pubis is noted.

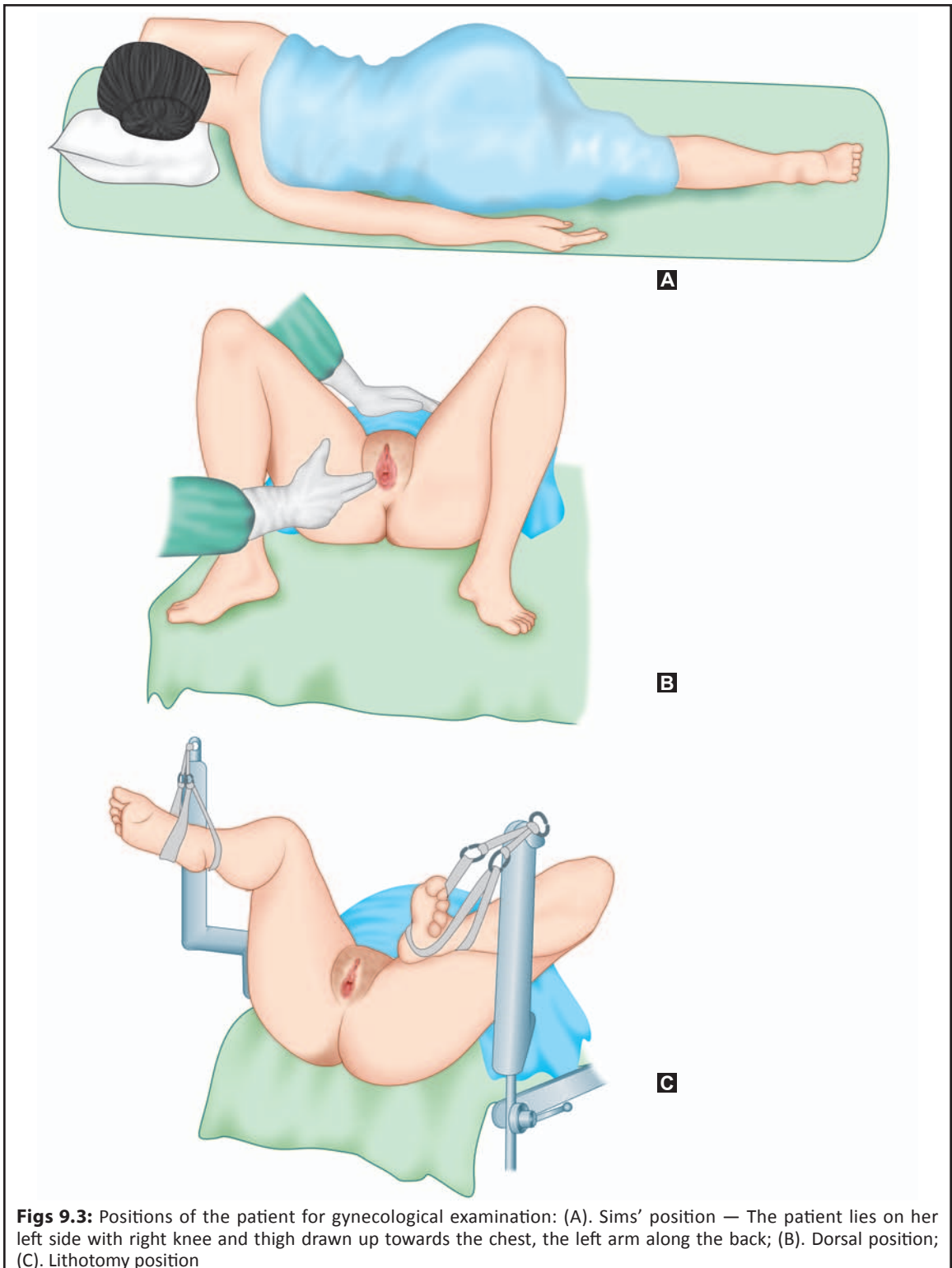
**Palpation:** The palpation should be done with the flat of the hand gently rather than the tips of the fingers. If **rigidity** of the abdominal muscles is encountered, it may be due to high tension or due to **muscle guard**. If **a mass is felt** in the lower abdomen, its location, size above the symphysis pubis, consistency, feel, surface, mobility from side to side and from above to down, and margins are to be noted. Whether the lower border

of the mass can be reached or not should be elicited. In general, lower border cannot be reached in pelvic tumor, but in ovarian tumor with a long pedicle one can go below the lower pole. If the tumor is cystic and huge, one can exhibit a fluid thrill felt with a flat hand placed on one side of the tumor when the cyst is tapped on the other side of the tumor with the other hand. Whether a mass is felt or not, routine palpation of the viscera (for any organomegaly) includes—liver, spleen, cecum and appendix, pelvic colon, gallbladder and kidneys.

**Percussion:** A pelvic tumor is usually dull on percussion with resonance on the flanks. However, if there are intestinal adhesions or the tumor is retroperitoneal, it will be resonant. In presence of ascites, the flanks will be dull on percussion and the shifting dullness, if elicited, confirms the diagnosis of free fluid in the peritoneal cavity. It is, however, mandatory to elicit presence of free fluid in the peritoneal cavity in every cases of pelvic tumor (Fig. 9.2).







**Figs 9.3:** Positions of the patient for gynecological examination: (A). Sims' position — The patient lies on her left side with right knee and thigh drawn up towards the chest, the left arm along the back; (B). Dorsal position; (C). Lithotomy position

**Auscultation:** Ordinarily, auscultation reveals only the intestinal sounds. Hypoactive bowel sounds are found in paralytic ileus, hyperactive bowel sounds may be due to intestinal obstruction. The uterine souffle may be heard over a pregnant uterus or vascular fibroid, which is synchronous with the patient's pulse. If the tumor is of pregnant uterine origin, fetal heart sound can be heard beyond 24 weeks.

## PELVIC EXAMINATION

Pelvic examination includes:

- ◆ Inspection of the external genitalia
- ◆ Vaginal examination
  - Inspection of the cervix and vaginal walls
  - Palpation of the vagina and vaginal cervix by digital examination
  - Bimanual examination of the pelvic organs
- ◆ Rectal examination
- ◆ Rectovaginal examination.

## PREREQUISITES

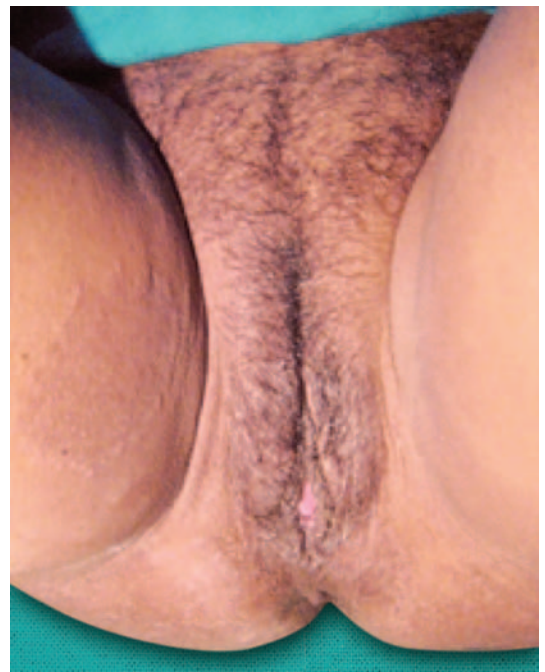- ◆ The patient's bladder must be empty—the exception being a case of stress incontinence
- ◆ A female attendant (nurse or relative of the patient) should be present by the side
- ◆ To examine a minor or unmarried, a consent from the parent or guardian is required
- ◆ Lower bowel (rectum and pelvic colon) should preferably be empty
- ◆ A light source should be available
- ◆ Sterile gloves, sterile lubricant (preferably colorless without any antiseptics), speculum, sponge holding forceps and swabs are required.

## POSITION OF THE PATIENT (FIG. 9.3)

The patient is commonly examined in **dorsal position** with the knees flexed and thighs abducted. The physician usually stands on the right side. This position gives better view of the external genitalia and the bimanual pelvic examination can be effectively performed.

However, the patient can be examined, in any position of the physician's choice. **Lateral or Sims' position** seems ideal for inspecting any lesion in anterior vaginal wall as the vagina balloons with

air as soon as the introitus is opened by a speculum. **Lithotomy position** (patient lying supine with her legs on stirrups) is ideal for examination under anesthesia.



**Fig. 9.4:** Inspection of vulva in dorsal position

## INSPECTION OF THE VULVA (FIG. 9.4)

- ◆ To note any anatomical abnormality starting from the pubic hair, clitoris, labia and perineum
- ◆ To note any palpable pathology over the areas
- ◆ To note the character of the visible vaginal discharge, if any
- ◆ To separate the labia using fingers of the left hand to note external urethral meatus, visible openings of the Bartholin's ducts (normally not visible unless inflamed) and character of the hymen.
- ◆ To ask the patient to strain to elicit:
  - Stress incontinence—urine comes out through urethral meatus (see p. 399).
  - Genital prolapse and the structures involved— anterior vaginal wall, uterus alone or posterior vaginal wall or all the three (see p. 204).
- ◆ Lastly, to look for hemorrhoids, anal fissure, anal fistula or perineal tear.

## VAGINAL EXAMINATION

### Inspection of the vagina and cervix

Which one is to be done first—inspection or palpation?

**Speculum examination** should preferably be done prior to bimanual examination. **The advantages are:**

- Cervical scrape cytology and endocervical sampling can be taken as ‘screening’ in the same sitting
- Cervical or vaginal discharge can be taken for bacteriological examination
- The cervical lesion may bleed during bimanual examination, which makes the lesion difficult to visualize.

Two types of speculum are commonly used—Sims’ or Cusco’s bivalve. **While in dorsal position, Cusco is widely used** but in lateral position, Sims’ variety has got advantages (Figs 9.5A and B).

The cervix is best visualized with the Cusco’s variety. But while the vaginal fornices are only

visualized by Cusco, **the anterior vaginal wall is to be visualized by Sims’ variety**. Sims’ speculum is advantageous in cases of genital prolapse.

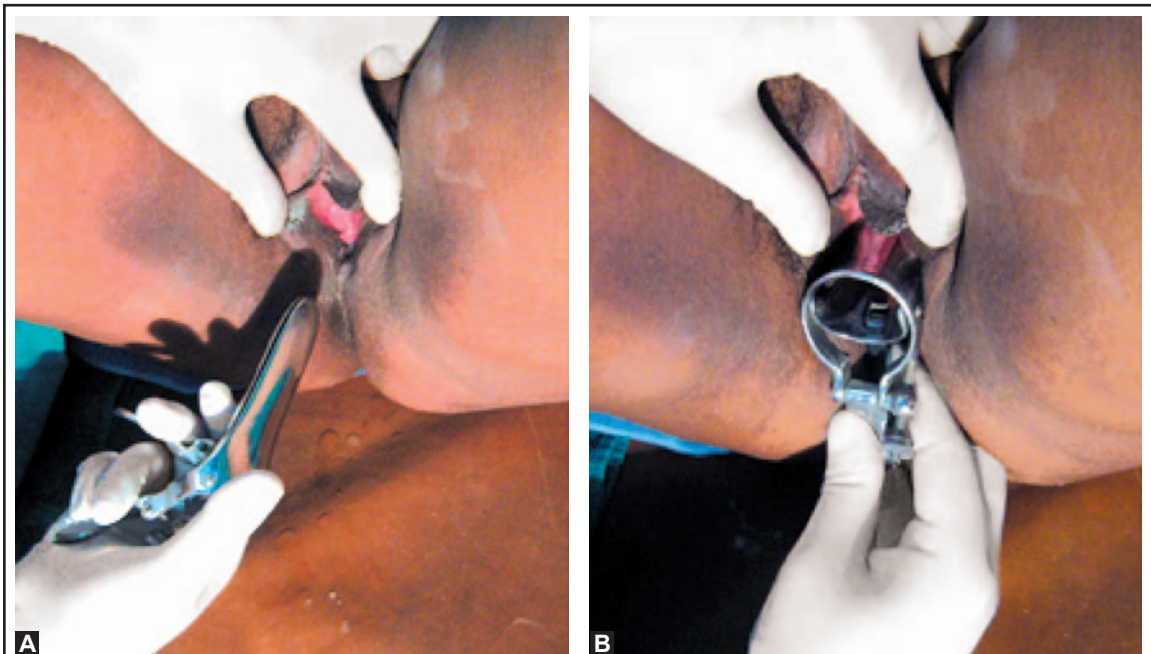
Apart from inspection, collection of the discharge from the cervix or from the vaginal fornices or from the external urethral meatus is taken for bacteriological examination.

It is a routine practice to take **cervical scrape cytology and endocervical sampling for cytological examination in all patients** as a screening procedure, if not done recently.

### Digital examination

Digital examination is done using a gloved index finger lubricated with sterile lubricant. In virgins with intact hymen, this examination is withheld but can be employed under anesthesia.

**Palpation of any labial swelling** (commonly Bartholin’s cyst or abscess) is made with the finger placed internally and thumb placed externally (Fig. 9.6). The **urethra** is now pressed from above down for any discharge escaping out through the meatus.



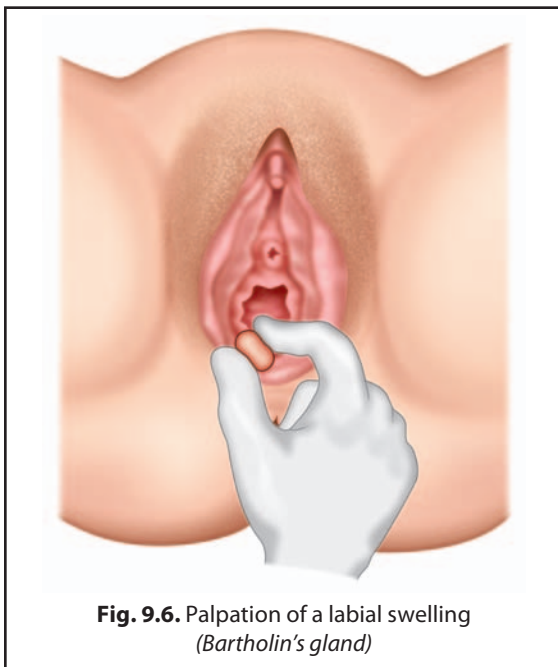
**Figs 9.5A and B:** Introduction of Cusco’s speculum: (A) The transverse diameter of the closed blades are placed in the anteroposterior position and inserted slightly obliquely to minimize pressure on the urethra; (B) Blades are inserted in a downward motion and then rotated. Rotate to 90° and then to open up the blades. Inspection is then made using a good light

**Palpation of the vaginal walls** is to be done from below upwards to detect any abnormality either in the wall or in the adjacent structures.

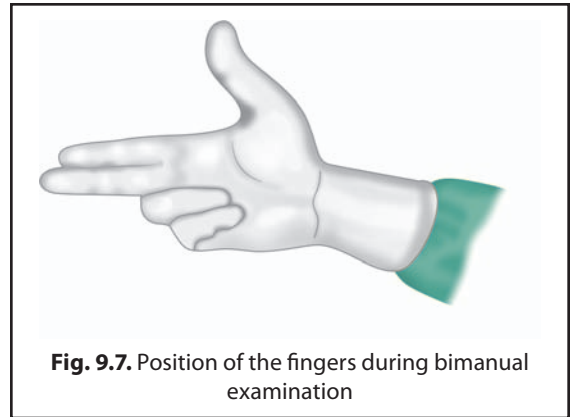
**The vaginal portion of cervix is next palpated to note:**

- ◆ *Direction*—In anteverted uterus, the anterior lip is felt first and in retroverted position either the external os or the posterior lip is felt first
- ◆ *Station*—Normally the external os is at the level of ischial spines
- ◆ *Texture*—In nonpregnant state, it feels firm like tip of the nose
- ◆ *Shape*—It is conical with smooth surface in nulliparae but cylindrical in parous women
- ◆ *External os*—It is smooth and round in nulliparae but may be dilated with evidence of tear in parous women
- ◆ *Movement*—Painful or not
- ◆ Whether it bleeds to touch.

**Integrity and tone of the perineal body** are to be elicited by flexing the internal finger posteriorly and palpating the perineal body between the internal finger and the thumb placed externally. The finger



**Fig. 9.6.** Palpation of a labial swelling (Bartholin's gland)



**Fig. 9.7.** Position of the fingers during bimanual examination

is now turned laterally above the level of levator ani muscles. The muscles can be palpated between the vaginal finger and the thumb placed externally over the labium majus.

### **Bimanual examination**

The techniques are difficult to describe in words but perfectness will be achieved only through experience.

The gloved right index and middle fingers smeared with lubricants are inserted into the vagina. If the introitus is narrow or tender, one finger may be used. The relative position of the fingers during introduction is shown in Figure 9.7. The left hand is placed on the hypogastrium well above the symphysis pubis so that the pelvic organs can be palpated between them. **The examination should be methodical, gentle but purposeful.** To be more informative, abdominal hand is to be used more than the vaginal fingers and the patient is asked to breathe through the mouth for better relaxation of the abdominal muscles.

The information obtained by bimanual examination includes:

- ◆ Palpation of the uterus
- ◆ Palpation of the uterine appendages
- ◆ Pouch of Douglas.

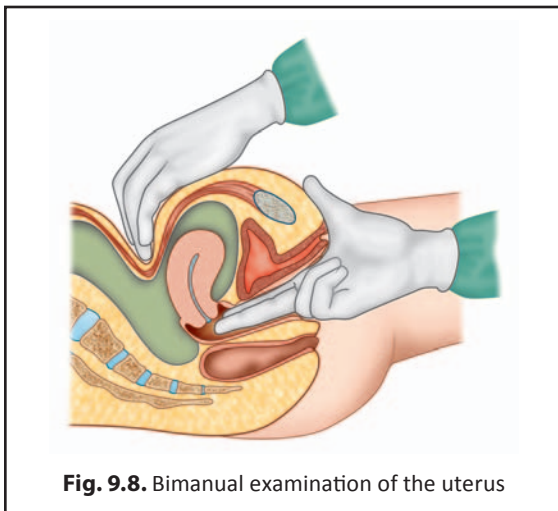
### ■ **Palpation of the uterus**

The two internal fingers, which are placed in the anterior fornix exert a pushing force at the uterocervical junction in an upward direction towards the lumbar vertebrae and not towards the symphysis pubis. The pressure exerted by the left hand should be not only downwards but from behind forwards

(Fig. 9.8). The uterine outline between the two hands can thus be palpated clearly as anteverted. If the uterus is retroverted, it will not be so felt but can be felt if the internal fingers push up the uterus through the posterior fornix. After the uterine outline is defined, one should note its position, size, shape, consistency and mobility. **Normally**, the uterus is anteverted, pearshaped, firm and freely mobile in all directions.

#### ■ Palpation of the uterine appendages

For palpation of the adnexa, the vaginal fingers are placed in the lateral fornix and are pushed backwards



**Fig. 9.8.** Bimanual examination of the uterus

and upwards. The counter pressure is applied by the abdominal hand placed to one side of the uterus in a backward direction. **The normal uterine tube cannot be palpated.** A normal ovary may not be felt. If it is palpable, it is mobile and sensitive to manual pressure.

#### The pouch of Douglas

The pouch of Douglas can be examined effectively through the posterior fornix. Normally, the fecal mass in the rectosigmoid or else the body of a retroverted uterus is only felt. Some pathology detected in the pouch of Douglas should be supplemented by rectal examination.

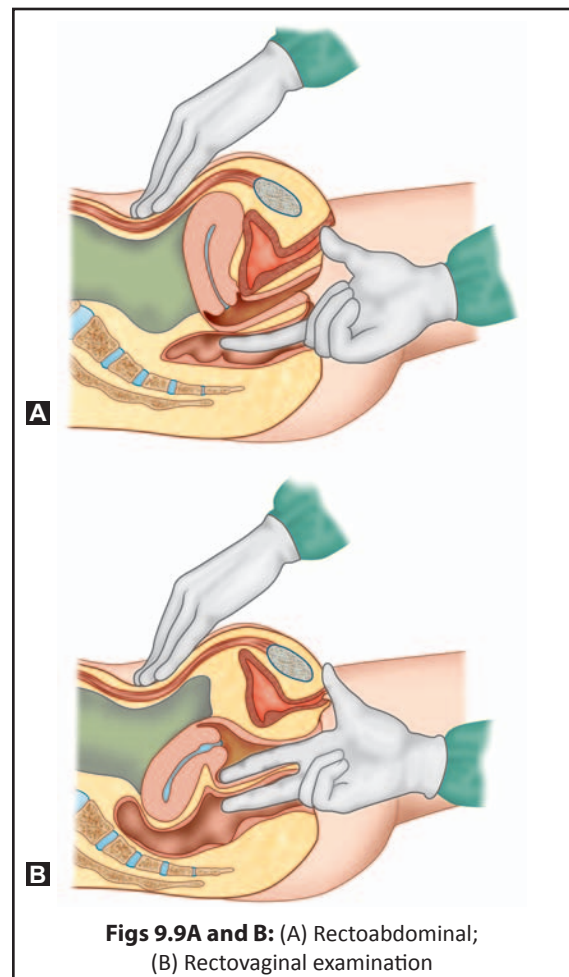
#### RECTAL OR RECTOABDOMINAL EXAMINATION

Rectal examination can be done in isolation or as an adjunct to vaginal examination.

#### Indications of Rectal Examination

- ◆ Children or in adult virgins
- ◆ Painful vaginal examination
- ◆ Carcinoma cervix—to note the parametrial involvement (base of the broad ligament and the uterosacral ligament can only be felt rectally) or involvement of the rectum
- ◆ To corroborate the findings felt in the pouch of Douglas by bimanual vaginal examination
- ◆ Atresia (agenesis) of vagina
- ◆ Patients having rectal symptoms
- ◆ To diagnose rectocele and differentiate it from enterocele.

The lower bowel should preferably be empty. The rectoabdominal procedure is almost the same as that



**Figs 9.9A and B:** (A) Rectoabdominal; (B) Rectovaginal examination

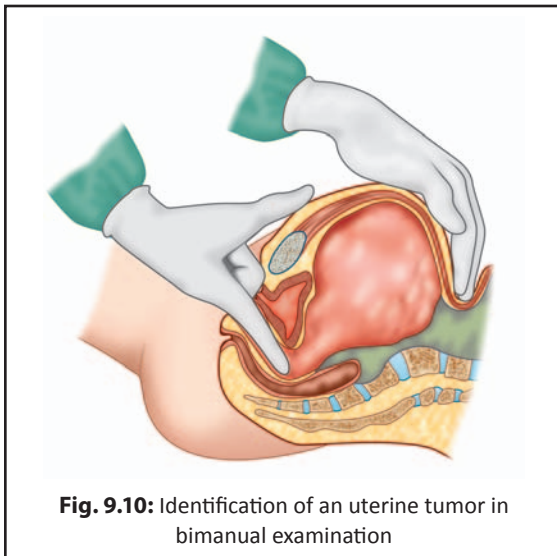
of vaginal examination except that only the gloved index finger smeared with vaseline is to be introduced into the rectum (Fig. 9.9A).

**RECTOVAGINAL EXAMINATION:** The procedure consists of introducing the index finger in the vagina and the middle finger in the rectum. This examination may help to determine whether the lesion is in the bowel or between the rectum and vagina. Any thickening or beadiness of uterosacral ligaments or presence of endometriotic nodules are noted. **This is of special help** to differentiate a growth arising from the ovary or rectum (Fig. 9.9B).

### Identification of a mass felt on bimanual examination

#### Uterine tumor (Fig. 9.10)

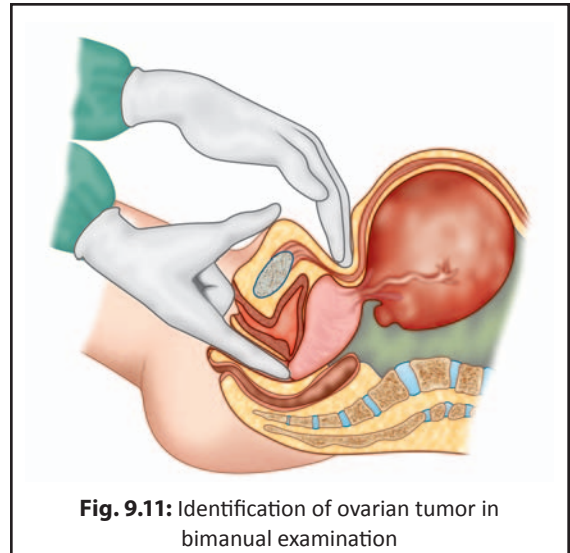
- Uterus is not separated from the mass.
- Movements of the mass felt per abdomen are transmitted to the cervix and vice versa, the exception being one of subserous pedunculated fibroid.



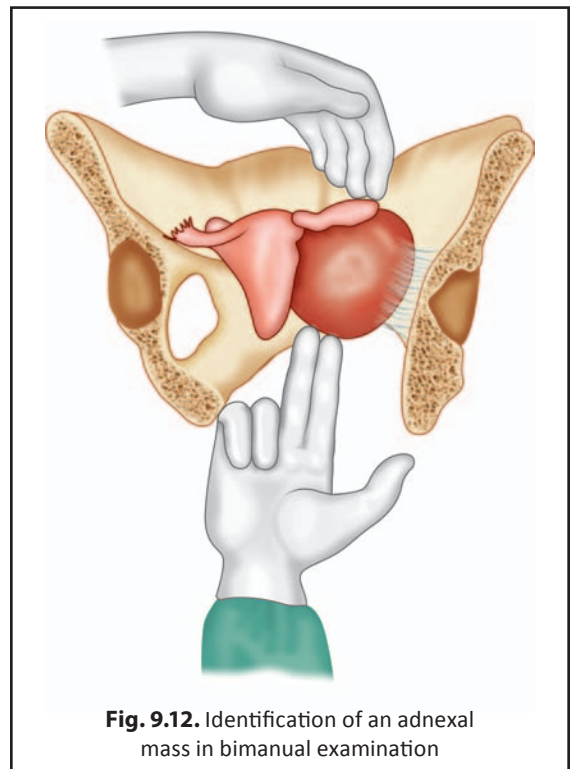
**Fig. 9.10:** Identification of an uterine tumor in bimanual examination

#### Adnexal mass

- The uterus is separated from the mass (Figs 9.11 and 9.12)
- Movements of the mass (tumor) are not transmitted to the cervix, the exception being one if the mass is fixed with uterus.



**Fig. 9.11:** Identification of ovarian tumor in bimanual examination



**Fig. 9.12.** Identification of an adnexal mass in bimanual examination

### DIAGNOSTIC PROCEDURES

For confirmation of diagnosis or rarely in cases with diagnostic difficulty, ancillary aids are required.

- **Blood Values:** Hemoglobin estimation should be done in all cases of excessive bleeding. Total and differential count of white blood cells and ESR are helpful in diagnosis of pelvic inflammation. Serological investigation includes blood for VDRL to be done in selected cases of HIV. Platelet count and bleeding and coagulation time are helpful in pubertal menorrhagia.
- **Urine: Routine and Microscopic Examination** for the presence of protein, sugar, pus cells and casts are done. In the presence of excessive vaginal discharge, it is preferable to collect the midstream urine (vide infra).

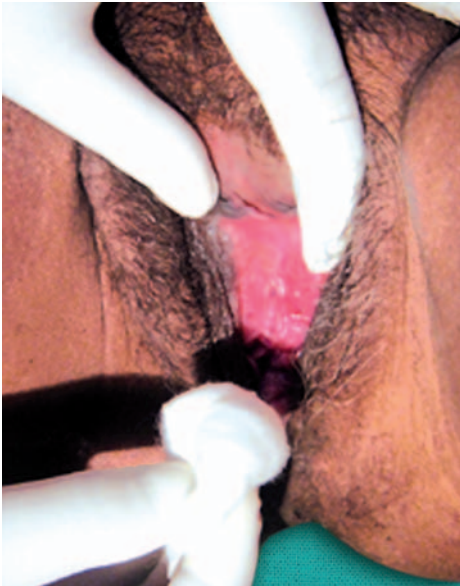**Culture and drug sensitivity** is done in suspected cases of urinary tract infection. Any of the following methods are used to collect the urine for the purpose.

- (i) **Midstream collection:** The patient herself should separate the labia with the fingers of left hand. A sterile cotton swab moistened with sterile water is passed over the external urethral meatus from above down and is then discarded. With the vulva still separated the patient is to pass urine. During the middle of the act of micturition, a part of urine is collected in a sterile wide mouth container.

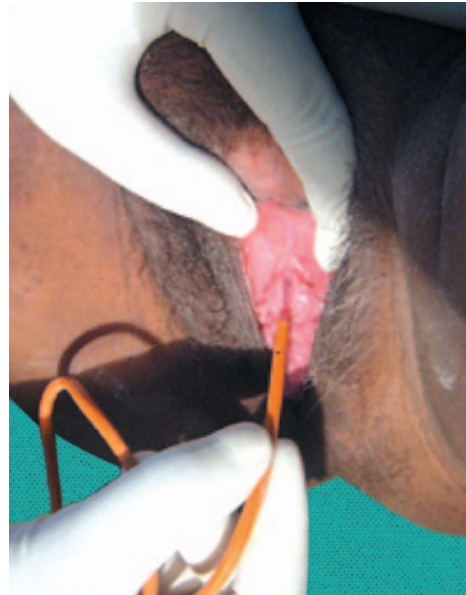- (ii) **Catheter collection:** This should be collected by a doctor or a nurse. This is especially indicated when the patient is not ambulant or having chronic retention. **Meticulous washing of the hands with soap and wearing sterile gloves are mandatory.** The patient is in dorsal position with the thighs apart. The labia are separated using the fingers of left hand. A sterile cotton swab moistened with sterile water is passed from above down over the external urethral meatus. The sterile autoclaved rubber catheter or a disposable plastic catheter is to be introduced with the proximal 4 cm remaining untouched by the fingers. With meticulous asepsis, the technique does not increase urinary tract infection (Figs 9.13A and B).

- (iii) **Suprapubic bladder puncture:** The result is more reliable and bladder infection is minimum. The patient is asked not to void urine to make the bladder full. A fine needle fitted with a syringe is passed through the abdominal wall just above the symphysis pubis into the bladder. About 5–10 mL of urine is collected. **The patient is asked to void the urine immediately.**

Whatever method employed in the collection of urine, **the sample should be sent immediately to**



**Fig. 9.13A:** Methods of catheterization by rubber catheter. Cleansing of the vestibule from above down by a moist swab



**Fig. 9.13B:** Note the use of left fingers for disposition of the external urethral meatus and holding the catheter well away from the tip by the right hand


**the laboratory.** There may be multiplication of the organisms with time.

- **Urethral discharge:** With a sterile gloved finger, the urethra is squeezed against the symphysis pubis from behind forwards. The discharge through the external urethral meatus is collected with sterile swabs. One swab may be sent for culture and the other to be spread on to a slide, stained and examined under microscope.
- **Vaginal or cervical discharge:** The patient is advised not to have vaginal douche at least in previous 24 hours. **Cusco's bivalve speculum is introduced without lubricant and prior to internal examination.** The material collected in the posterior blade or from the cervical canal as the case may be, is taken either by a platinum loop or swab stick.

**For Culture:** The cotton swab stick is put in a sterile container with a stopper and to be sent immediately to the laboratory. The culture is usually unnecessary in vaginal infection. For trichomoniasis, Kupferberg's media or Feinberg Whittington media; for *Candida albicans*—Nickerson's or Sabouraud's media is used.

#### Identification of Organism in Slide

- a. **Trichomonas vaginalis:** The material is dropped over a slide and then mixed with one drop of normal saline. It is then covered with a coverslip. Actively motile trichomonads can be seen under microscope easily (see Fig. 12.2). It can be effectively visualized after staining with 1 per-



**Fig. 9.14:** Rocket endocervical brush

cent brilliant cresyl violet; leukocytes and other bacteria will not take up the dye.

- b. **Monilia:** One drop of the discharge is mixed with one drop of 10% potassium hydroxide and is covered with a coverslip. The mycelia of the fungus can be seen under microscope. Alternatively, the discharge is spread over a slide, dried and stained with methylene blue to demonstrate the mycelia (see Fig. 12.4).

### CERVICAL AND VAGINAL SMEAR FOR EXFOLIATIVE CYTOLOGY

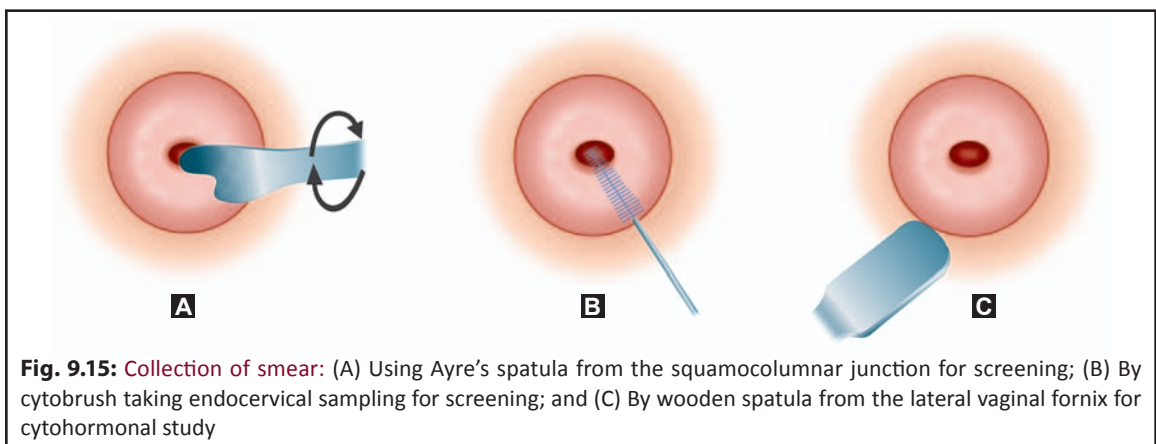
The indications are:

- ◆ As a screening procedure
- ◆ For cyto hormonal study
- ◆ Others

#### SCREENING PROCEDURE

**Collection of material:** The cervix is exposed **with a Cusco's vaginal speculum without lubricant and prior to bimanual examination.** Lubricants tend to distort cell morphology.

**Cervical scraping:** The material from the cervix is best collected using Ayre's spatula made of wood or plastic. Whole of the squamocolumnar junction has to be scrapped to obtain good material (Fig. 9.15).



**Fig. 9.15:** Collection of smear: (A) Using Ayre's spatula from the squamocolumnar junction for screening; (B) By cytobrush taking endocervical sampling for screening; and (C) By wooden spatula from the lateral vaginal fornix for cyto hormonal study



**Vaginal pool aspiration:** The exfoliated cells accumulated in the vaginal pool in the posterior fornix is collected either using a glass pipette about 15 cm long and 0.5 cm in diameter with a strong rubber bulb at one end or by a swab stick. This is not much reliable.

Collection by any one of the methods should be combined with endocervical sampling either by cytobrush or with moist cotton tip applicator (Figs 9.14 and 9.15).

### Fixation and Staining

The principle of the staining is to achieve clear nuclear definition and to define cytoplasmic coloration.

TABLE 9.1		WOMEN SUBJECTED TO CERVICAL CANCER SCREENING PROGRAM
<p>■ <b>Low risk</b></p> <ul style="list-style-type: none"> <li>– Women who had never been sexually active</li> <li>– Women aged 70, who had three negative smears in the past 10 years</li> <li>– Women who had hysterectomy for benign lesion</li> </ul>	<p><i>Screening schedule (ACOG-2009)</i></p> <p>Nil</p>	
<p>■ <b>At risk</b></p> <ul style="list-style-type: none"> <li>– Women aged 21 years or having sex for last 3 years up to the age of 70 who are or have been sexually active</li> </ul>	<p>Every 2–3 years after age 30 with 3 negative yearly smears</p>	
<p>■ <b>High risk</b></p> <ul style="list-style-type: none"> <li>– Early marriage</li> <li>– Early intercourse</li> <li>– Early pregnancy</li> <li>– Smoking habits</li> <li>– Oral pill users</li> <li>– Multiple sexual partners</li> <li>– Human papilloma virus (see p. 322, 323) infection</li> <li>– Women who are immunosuppressed (HIV positive)</li> </ul>	<p>Every 2–3 years after age 30 with 3 negative yearly smears</p>	

The material so collected should be immediately spread over a microscopic slide and at once put into the fixative ethyl alcohol (95%) before drying. After fixing for about 30 minutes, the slide is taken out, air dried and sent to the laboratory with proper identification. The slide so sent is stained either with Papanicolaou's or Sorr's method and examined by a trained cytologist. Indeed, **trained cytopathologist and cytotechnologist are vital for the success of any screening program (Table 9.1).**

**BENEFITS:** The objective of screening is to reduce the incidence and mortality from cervical cancer. Even a single smear in a life time, if appropriately timed, will produce some benefits. If extended only to high-risk group, the mortality from the cancer deaths will still be reduced to 60 percent.

**Pap smear test has been effective reducing the incidence of cervical cancer by 80% and the mortality by 70%.** As a result of Pap test, more and more preinvasive carcinoma is detected. Opportunistic screening done by a trained staff is effective when follow-up (call and recall) is maintained. Pap testing after total hysterectomy, done for benign lesion is not recommended.

**INTERVALS:** All sexually active women should be screened starting from the age of 21 years or after 3 years of vaginal sex with no upper age limits. Screening should be yearly till the age of 30. Thereafter, it should be done at an interval of every 2–3 years after three consecutive yearly negative smears (ACOG 2009). The high risk group should be screened with **HPV DNA testing combined with cytology (p. 324). The negative predictive value of one negative HPV DNA test and two negative cytology tests are almost 100%.** When both the tests are negative, the screening interval may be increased to 6 years.

### MORPHOLOGICAL ABNORMALITIES OF THE NUCLEUS (DYSKARYOSIS)

- ▶ Disproportionate nuclear enlargement
- ▶ Irregularity of the nuclear outline
- ▶ Abnormalities of the nucleus—in number, size and shape
- ▶ Hyperchromasia
- ▶ Condensation of chromatin material
- ▶ Multinucleation.

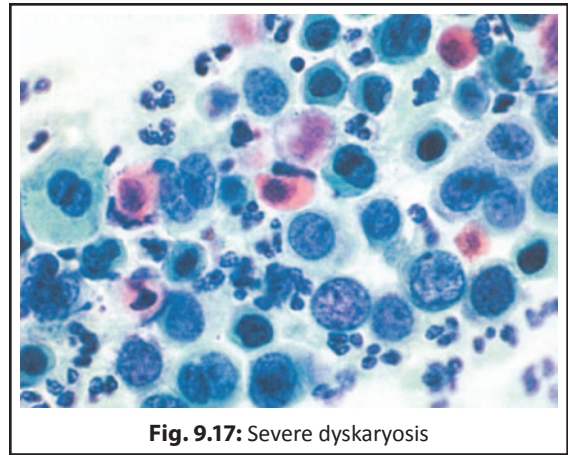
**Abnormal cells are:**

**Mild dyskaryosis**—Cells are of superficial or intermediate type squamous cells. Cells have angular borders with translucent cytoplasm. The nucleus occupies less than half of the total area of cytoplasm. Binucleation is common. Mild dyskaryosis correlates with cells from surface of CIN I (see p. 320).

**Moderate dyskaryosis**—The cells are of intermediate, parabasal or superficial type squamous cells. Cells have more disproportionate nuclear enlargement and hyperchromasia compared to mildly dyskaryotic cells. The nucleus occupies one half to two-thirds of the total area of the cytoplasm.

**Severe dyskaryosis (Fig. 9.17)**—Cells are of basal type, looking round, oval, polygonal or elongated in shape. The abnormal cells may occur in clumps or singly. The abnormal nucleus either practically fills the cell or there may be a thick, dense and narrow rim of cytoplasm around it. The nucleus is irregular with coarse chromatin pattern. The cells may be different in size and shape. Severely dyskaryotic cells when elongated, are sometimes called **fiber cells**. A severely dyskaryotic cell with an elongated tail of cytoplasm is described as a **tadpole cell**. Severely dyskaryotic cells correlate with CIN 3.

**Koilocytosis** is the nuclear abnormalities associated with human papilloma virus infection. Cells show typical central clearing (perinuclear halo) with peripheral condensation of cytoplasm. The nucleus is irregularly enlarged and shows hyperchromasia with



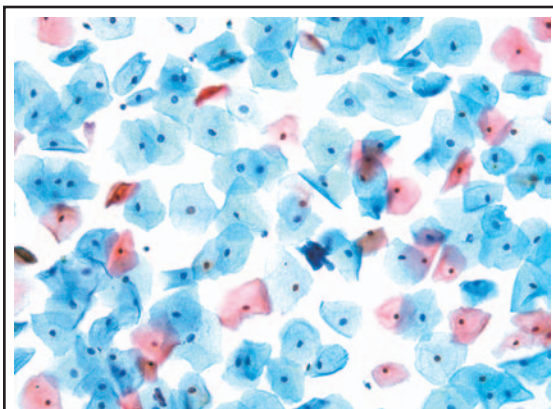
**Fig. 9.17:** Severe dyskaryosis

multinucleation. Patients with koilocytosis on repeated smear, need colposcopic evaluation (see p. 115).

**Carcinoma in situ (Fig. 9.18)**—Cells are parabasal type with increased nuclear cytoplasmic ratio. The nucleus may be irregular sometimes multiple. The chromatin pattern is granular. Cytoplasm is scanty.

**Invasive carcinoma**—Cells are single or grouped in clusters. The cells show irregular nuclei and clumping of nuclear chromatin, which is also coarse. **Large tadpole cells are seen.**

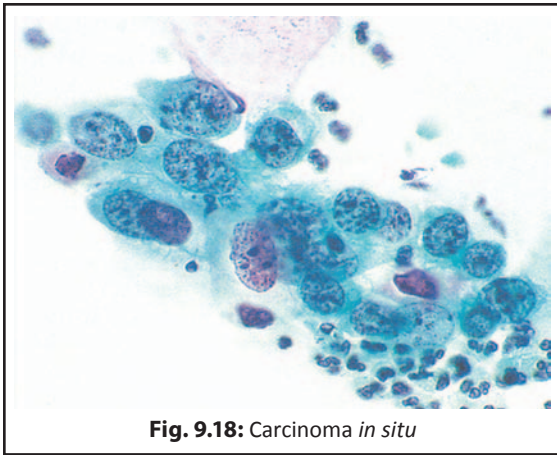
**Reporting system:** Reporting system on the grading basis (Papanicolaou's) is replaced by some with two remarks only—normal or abnormal (Table 9.2). An abnormal smear indicates the presence of lesion either CIN and/or papilloma virus infection or invasive malignancy. A doubtful or inconclusive smear dictates repeat smear.



**Fig. 9.16:** Liquid-based cytology—normal squamous cells and endocervical cells

TABLE 9.2 PAPANICOLAOU'S GRADING	
<b>Group – I</b>	Normal
<b>Group – II</b>	Presence of borderline atypical cells—probably due to infection. No evidence of malignancy
<b>Group – III</b>	Cells suspicious of malignancy
<b>Group – IV</b>	Presence of few malignant cells
<b>Group – V</b>	Presence of large number of malignant cells

**Accuracy:** A single Pap smear has a diagnostic sensitivity of about 60 percent. False negative results



**Fig. 9.18:** Carcinoma *in situ*

may be up to 25%. **False negative rate of Pap smear after three consecutive negative tests is less than 1 percent.** There are several reasons for false-negative smear. This may be due to technical error where smear is too scanty, too thick, too bloody, poorly stained or due to misinterpretation by the cytologist. Error in cytology could be reduced further by liquid-based thin layer slide preparation and automated (computer) screening methods. **Abnormal cytology is an indication of colposcopic evaluation and directed biopsy.** If colposcopy is not available, biopsy is to be taken from the unstained areas following **application of Schiller's or Lugol's iodine** (see Ch. 22). In the presence of infection, repeat cytology has to be done after the infection is controlled (Table 9.3).

**LIQUID-BASED CYTOLOGY (LBC):** Cervical smear is taken using a plastic spatula. The spatula is rinsed in a liquid media. Cells are separated by centrifugation. Thin layer smears are made. National Institute of Clinical Excellence (NICE) has recommended to replace the conventional smear with LBC. LBC avoids the risk of false-positive, false-negative or unsatisfactory smears (Fig. 9.16).

**CYTOHORMONAL STUDY:** The vaginal epithelium is highly sensitive to the hormones estrogen and progesterone. The non-invasive study of the epithelium for hormonal status is steadily increasing owing to the speed, cheapness and accuracy.

**TABLE 9.3**

**THE BETHESDA CLASSIFICATION SYSTEM FOR CYTOLOGY**

■ Adequacy of sample	◆ Satisfactory	◆ Unsatisfactory
■ Squamous cell abnormalities	<ul style="list-style-type: none"> <li>◆ Atypical squamous cells (ASC)</li> <li>◆ ASC of undetermined significance (ASC-US)</li> <li>◆ ASC, cannot exclude high grade lesion (ASC-H)</li> <li>◆ Low-grade squamous intraepithelial lesion (L SIL)</li> <li>◆ High-grade squamous intraepithelial lesion (H SIL)</li> <li>◆ Squamous cell carcinoma</li> </ul>	
■ Glandular cell abnormalities	<ul style="list-style-type: none"> <li>◆ Atypical glandular cells, specify site of origin, if possible</li> <li>◆ Atypical glandular cells, favor neoplastic</li> <li>◆ Adenocarcinoma <i>in situ</i></li> <li>◆ Adenocarcinoma</li> </ul>	
■ Other cancers (e.g. lymphoma, metastasis, sarcoma)		

**Instructions to the patient**

- ◆ To avoid intercourse for about 48 hours
- ◆ Not to use vaginal douche for 24 hours
- ◆ To withhold use of hormonal drugs.

**Procedures:** The lateral wall of the upper-third of the vagina (most sensitive to hormonal influence) is lightly scraped with a wooden spatula after taking due precautions mentioned earlier. The material so collected is to be fixed and stained as mentioned earlier. **The physician should mention the following information,** such as age, first day of the last period, menstrual pattern and any hormone therapy.

**Inferences:** The exfoliated vaginal epithelial cells normally include parabasal, intermediate and superficial cells. The **parabasal** cells are small, round and basophilic; the **intermediate cells** are transparent and basophilic while the **superficial cells** are large, thin acidophilic with pyknotic nuclei. The estrogen produces superficial cell maturation; progesterone, androgen, corticosteroids, 'pill' and pregnancy produce intermediate cell maturation, whereas lack of any hormonal activity produces parabasal cell dominance (Table 9.4).

**TABLE 9.4** MATURATION INDEX FROM BIRTH TO MENOPAUSE

	MI	Smear features	Inference
<i>At birth</i>	0/95/5	—	Combined effect of circulating maternal hormones—estrogen, progesterone and corticoids
<i>Childhood</i>	80/20/0	—	MI shifting to left because of diminished steroid hormones
<i>Reproductive period:</i>			
– Preovulatory	0/40/60	Smear clear, cells are discrete	Estrogen ++
– Mild secretory	0/70/30	Smear dirty, cells in clusters	Estrogen +; Progesterone ++
– During pregnancy	0/95/5	Marked folding of the intermediate cells—‘navicular cells’	Estrogen ++; Progesterone ++; Corticosteroids +
– Postpartum	100/0/0	—	Parabasal maturation
<i>Postmenopausal</i>	0/100/0 or 100/0/0	—	Lack of estrogen

The estrogenic smear is suggested by preponderance of large eosinophilic cells with pyknotic nuclei (cornified cells). The background remains clear (see Fig. 8.11).

The progesterone smear is of predominantly basophilic cells with vesicular nuclei. The background looks dirty (see Fig. 8.11).

**Interpretations:** The number of cornified cells per 100 cells counted is expressed as **cornification or karyopyknotic index**. It is mostly replaced by a more appropriate expressive method—called **maturation index (MI)**. The maturation index relates to the relative percentage of parabasal, intermediate and superficial cells per 100 cells counted. It is expressed in three numbers, the left one parabasal percentage, the intermediate in the centre and on the right, the percentage of the superficial cells (Table 9.4).

#### Other Indications of Cytology Study are

- ◆ **The exfoliative cell cytology is used** in follow-up cases of carcinoma cervix treated either by surgery or radiotherapy
- ◆ **Sex chromatin study**—The materials are from scraping of buccal mucosa and to be stained with Papanicolaou stain. The presence of Barr body in more than 25% cells is diagnostic of female sex

- ◆ **Aspirated** ascitic, cystic or pleural fluid is subjected to Papanicolaou stain for evidences of malignant cells.

## EXAMINATION OF CERVICAL MUCUS

- **Bacteriological study**
- **Hormonal status**
- **Infertility investigation**

**BACTERIOLOGICAL STUDY:** Cusco’s bivalve speculum is introduced without lubricant. With the help of a sterile cotton swab, the cervical canal is swabbed. The material is either sent for culture or spread over a microscopic slide for Gram staining.

**HORMONAL STATUS:** The physical, chemical and cellular components of the cervical secretion are dependent on hormones—Estrogen and progesterone. Estrogen increases the water and electrolyte content with decrease in protein. As such, the mucus becomes copious, clear and thin. Progesterone, on the other hand, decreases the water and electrolytes but increases the protein. As a result, the mucus becomes scanty, thick and tenacious. The influence of the hormones on the cervical mucus is utilized in detection of ovulation in clinical practice.

- pH around the time of ovulation is about 6.8–7.4.
- **Spinnbarkeit** (stretchability or elasticity)—During the midcycle, the cervical secretion is collected with a pipette and placed over a glass slide. Another glass slide is placed over it. Because of increased elasticity due to high estrogen level during this period, the mucus placed between the slides **can withstand stretching up to a distance of over 10 cm**. After ovulation when corpus luteum forms, progesterone is secreted. Under its action, the cervical mucus loses its property of elasticity and while attempting the above procedure, the mucus fractures when put under tension much earlier. **This loss of elasticity after its presence in the midcycle is the indirect evidence of ovulation.**
- **Fern test**—During the midcycle, the cervical mucus is obtained by a platinum loop or pipette and spread on a clean glass slide and dried. When seen under low power microscope, it shows characteristic pattern of fern formation. **It is due to high sodium chloride** and low protein content in the mucus due to high estrogen in the midmenstrual phase prior to ovulation. After

ovulation with increasing progesterone, the ferning disappears completely after 21st day. **Thus, the presence of ferning even after 21st day suggests anovulation and its disappearance is presumptive evidence of ovulation (Fig. 9.19).**

The cervical scoring system of Insler (1979) takes into the account the amount, spinnbarkeit, ferning of the mucus along with state of the external os of the cervix. A score of 10–12 indicates complete follicular maturation.

### INFERTILITY INVESTIGATIONS

**Postcoital test (PCT)—Marion Sims (1866) and Max Huhner (1913)**

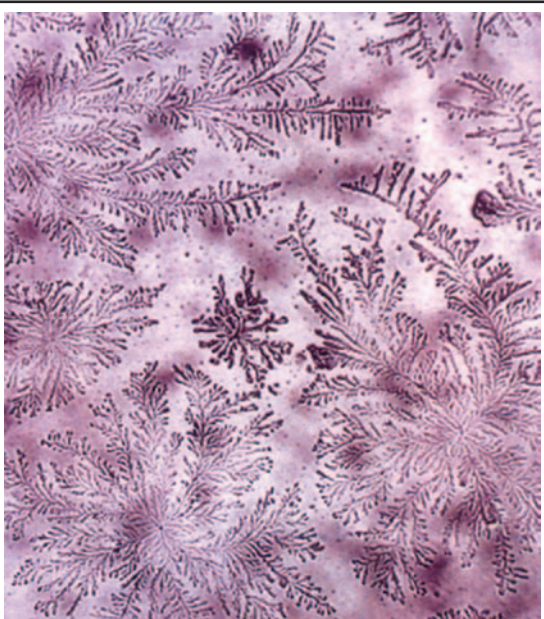
**Cervical mucus** is a glycoprotein gel with interstitial channel between mucin strands. These strands expand and contract in response to steroid hormones. This helps sperm transport upwards (see Fig. 16.4).

**Principle:** It is the examination of the cervical mucus to evaluate the presence of progressively motile sperm in it. This test is done several hours after (within 8–12 hours) sexual intercourse. Presence of at least 10 progressively motile sperm per high power field signifies the test is normal. PCT has got poor predictive value. Moreover, the test procedure is inconvenient and embarrassing. Routine postcoital test is not recommended.

### COLPOSCOPY

The instrument was devised by Hinselmann in 1925. **Colposcope and colpomicroscope are the low-power binocular microscope, mounted on a stand.** It is designed to magnify the surface epithelium of the vaginal part of the cervix including entire transformation zone. The magnification is to the extent of 15–40 times in colposcopy and about 100–300 times in colpomicroscopy (Fig. 9.20).

**Procedure:** The patient is placed in lithotomy position. The cervix is visualized using a Cusco's speculum (Fig. 9.5). Colposcopic examination of the cervix and vagina is done using low power magnification (6–16 fold). Cervix is then cleared of any mucus discharge using a swab soaked with normal saline. Green filter and high magnification can be used now. Next, the cervix is wiped gently with 3 percent acetic acid and examination repeated. Acetic acid causes coagulation of nuclear protein



**Fig. 9.19:** Typical fern pattern appearance of cervical mucus

which is high in CIN. This prevents transmission of light through the epithelium, which is visible as white (acetowhite) areas (see Fig 22.6A).



**Fig. 9.20:** Colposcope

Technique of colposcopy needs ease of maneuver (frontal distance of 225 to 250 mm), magnification (6–16 times), adequate light source (30,000 lux), the stand to permit mobility and the examination table for patient's comfort

**TABLE 9.5**

**ABNORMAL CYTOLOGY AND PLACE OF COLPOSCOPY**

Cervical cytology	Procedure
<ul style="list-style-type: none"> <li>■ <b>Squamous cells:</b></li> <li>◆ <b>ASC-US</b></li> <li>◆ <b>ASC-H</b></li> <li>◆ <b>L SIL</b></li> <li>◆ <b>H SIL</b></li> <li>■ <b>Glandular lesions</b></li> </ul>	<ul style="list-style-type: none"> <li>• HPV-DNA testing for HR types (see p. 323)</li> <li>• Repeat Pap in 6 months</li> <li>• Colposcopy (any method)</li> </ul> <p>: Colposcopy</p> <p>: Colposcopy</p> <p>: Colposcopy</p> <p>: Colposcopy and further evaluation</p>

**TABLE 9.6**

**COLPOSCOPIC TERMINOLOGY**

I.	Normal colposcopic findings
	A — Normal squamous epithelium
	B — Columnar epithelium
	C — Transformation zone
II.	Abnormal colposcopic findings (see p. 325)
	A — Atypical transformation zone
	(a) Mosaic (b) Punctuation
	(c) Acetowhite epithelium
	(d) Keratosis
	(e) Atypical vessels (f) Iodine negativity
	B — Suspected frank invasive cancer— The cancer is evident only colposcopically
III.	Unsatisfactory —
	Transformation zone not seen (see p. 324)
IV.	Other findings —
	Condyloma, ectopy and papilloma are of importance

## IMAGING TECHNIQUES IN GYNECOLOGY

■ X-ray ■ Ultrasound ■ CT Scan ■ MRI ■ PET

### X-RAY

A chest X-ray and intravenous urogram are essential for investigation in pelvic malignancy, cervical cancer in particular, prior to staging. Plain X-ray of the pelvis is helpful to locate an IUCD (see Fig. 29.7) or to look for shadows of teeth or bone in benign cystic teratoma (see Fig. 20.10). Special X-ray using contrast media are:

- ◆ HSG (details in p. 588).
- ◆ Lymphangiography—to locate the lymph nodes involved in pelvic malignancy.

### ULTRASOUND

Ultrasound is a noninvasive imaging procedure that utilizes high frequency sound waves. It was first introduced by Ian Donald (Glasgow – 1950) in the field of medicine. Sonography is used widely in Gynecology either with the transabdominal (TAS) or with the transvaginal (TVS) probe. Because of safety, high patient acceptance and relatively low cost,

ultrasonography has become a common diagnostic modality in gynecology, these days.

**Transabdominal Sonography (TAS)** is done with a linear or curvilinear array transducer operating at 2.5–3.5 MHz. TAS requires full bladder to displace the bowel out of pelvis. Full bladder serves as an acoustic window for the high-frequency sound waves. Ultrasound is very accurate (>90%) in recognizing a pelvic mass but cannot stabilize a tissue diagnosis. Tissue resolution of <0.2 mm can be obtained with sonography. **TAS is best used** for large masses like fibroid or ovarian tumor. Higher is the frequency of ultrasound wave, better is the image resolution but lesser is the depth of tissue penetration.

**Transvaginal Sonography (TVS)** is done with a probe, which is placed close to the target organ. There is no need of a full bladder. It also avoids the difficulties due to obesity, faced in TAS. TVS operates at a high frequency (5–8 MHz). **Therefore, detailed evaluation of the pelvic organs (within 10 cm of the field) is possible with TVS.** But the drawbacks of TVS are mainly due to narrow vagina as in virgins, postmenopausal women or post-radiation vaginal stenosis.

**Transvaginal Color Doppler Sonography (TV–CDS)**—Provides additional information of blood flow to, from or within an organ (uterus or adnexae). This flow can be measured by analysis of the waveform using the pulsatility index.

### Use of Ultrasound in Gynecology

#### ■ Infertility workup

- ◆ Serial measurement of ovarian follicular diameter (folliculometry) and endometrial thickness are done using TVS. **Mature follicle** should measure between 18 and 20 mm in diameter. The favorable periovulatory endometrium should be between 7 and 11 mm thick (see Chapter 16)
- ◆ Ultrasound can provide presumptive evidence of ovulation. **Following ovulation**, internal echoes appear within ruptured follicle and free fluid is observed in pouch of Douglas
- ◆ To detect **correct timing of ovulation** by folliculometry in conjunction with plasma estradiol. This helps in induction of ovulation,

artificial insemination and ovum retrieval in IVF

- ◆ Sonographic guided **oocyte retrieval** in IVF and GIFT programs, is now accepted as the best method
- **Ectopic pregnancy** can be detected on TVS as a “**tubal ring**”, separate from the ovary in a patient with empty uterine cavity. **TV–CDS** is of more help to detect the vascularity of “tubal ring” when it is unruptured
- **Pelvic mass** can be evaluated as regard to its location and consistency. Uterine fibroid, ovarian mass, endometrioma, tubo-ovarian mass, etc. can be delineated when there is confusion in clinical diagnosis. However, major limitation is due to its lack of specificity
- **Oncology:** TV–CDS can assess the vascularity of the mass. Low flow impedance with high flow velocity raises the suspicion of a malignant tumor.
 

Presence of papillary excrescences, mural nodules, septations, cystic lesion with solid components, snow storm appearance (hydatidiform mole) and ascites are the other sonographic features of malignancy.
- **Endometrial disease:** Women with unexplained uterine bleeding, or postmenopausal bleeding are better studied with TVS. An endometrial thickness of less than 5 mm is considered atrophic. Endometrial biopsy is needed for postmenopausal women with thicker endometrium (see p. 356).
- **Sonohysterography** involves instillation of saline in the uterine cavity and study with TVS. Submucous fibroid or polyp is better diagnosed with this method.
- **To locate missing IUD (see p. 483).**
- **Sonohysterosalpingography (see p. 239).**
- **Sonographically guided procedures.**

A needle guide is attached to the shaft of the vaginal probe. With the use of real time, TVS can guide the needle course in a safe path. This technique can be utilized for many diagnostic and therapeutic purposes:

  - ◆ Aspiration of cystic masses, e.g. chocolate cyst (see p. 312)

- ◆ Follicular aspiration, e.g. ovum retrieval in IVF (see p. 253)
- ◆ Aspiration of tubo-ovarian abscess.
- ◆ Biopsies
- **Transrectal sonography** can be used where TVS cannot be used due to vaginal narrowing
- **Saline infusion sonography (SIS):**

Infusion of normal saline into the uterine cavity and doing transvaginal (high resolution) sonography is helpful for the diagnosis of many uterine pathology. SIS catheter is inserted through the cervical os. Normal saline is infused slowly (5–10 mL) when the uterus is imaged with vaginal ultrasound.

#### Common indications of SIS are:

- ▶ Postmenopausal bleeding.
- ▶ Abnormal uterine bleeding.
- ▶ Recurrent miscarriage.
- ▶ Infertility.

### COMPUTED TOMOGRAPHY (CT SCAN)

The CT scan provides high resolution two-dimensional images. Cross-sectional images of the body are taken at very close intervals (few millimeters thick) in the form of multiple slices. CT can differentiate tissue densities and this gray-scale pictures can be read on an X-ray film or a television monitor. **Pelvic organs** could be differentiated from gastrointestinal

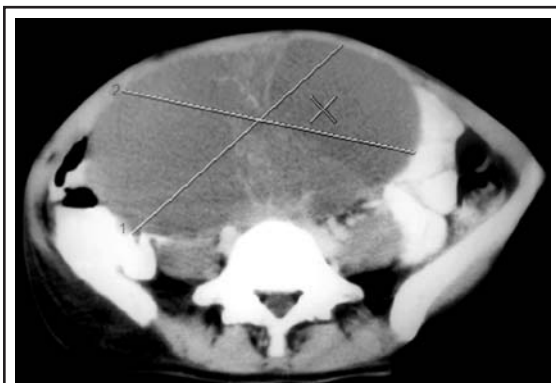and urinary systems using contrast media. Contrast media can be given orally, IV or rectally. CT is most useful in the **diagnosis of lymph node metastases**, depth of **myometrial invasion** in endometrial cancer, ovarian mass and myomas. CT can detect enlarged lymph nodes but cannot differentiate between benign hyperplasia or metastatic carcinoma. **However, lymph nodes must be enlarged at least by 2 cm to be detected by CT. Cerebral metastases of choriocarcinoma or microadenoma of the pituitary** can best be detected by CT procedure. CT scan also facilitates the percutaneous **needle biopsy** of suspicious lymph nodes. In obese or in cases of distended stomach or gut, it is an ideal alternative to sonar (see Fig. 37.81). CT is useful in assessing tumor extent and detecting metastases (Fig. 9.21). CT has its role in staging of ovarian cancer as it can detect peritoneal, omental and serosal deposits in addition to liver and nodal (retroperitoneal and intraperitoneal) metastasis (see p. 662). It is superior to ultrasound. Lower limit of detectable **intra-peritoneal implants** is between 1 and 5 mm. CT scans are useful in evaluating **pituitary tumors**. The best images from CT are obtained when there are significant differences in tissue densities. Helical CT is a current modification and has many advantages. Helical CT has replaced pulmonary angiography and ventilation-perfusion scans for the diagnosis of **pulmonary embolism**.

However, it is more costly and there is chance of surface radiation. Surface radiation dose of CT scan of the abdomen and pelvis is between 2 and 10 cGY. However, value of CT in the assessment of pelvic organs is limited. MRI is preferred where available.

### MAGNETIC RESONANCE IMAGING (MRI)

The phenomenon of nuclear magnetic resonance was first described by Felix Bloch and Edward Purcell in 1946. MR as a basis for an imaging technique was employed in practice about 30 years later by Lauterbur.

The MRI creates cross-sectional images of the body using a combination of radiowaves (nonionizing radiation) and magnetic fields. Biologic tissue nuclei with protons or neutrons have got magnetic properties. When a pulse of radiowaves is imposed on the nuclei a strong resonance will occur and the energy is absorbed by the nuclei. A signal is detected in a receiver coil,



**Fig. 9.21:** CT scan of the pelvis showing an ovarian mass



situated close to the tissue, when the energy is emitted by the nuclei. The strength of the emitted signal varies directly with the proton density. In gynecology, resolution is 0.5 to 1 mm. The radiowaves penetrate bone and air without attenuation. Respiratory movements have got little effect on the pelvic organs. Sagittal and coronal views can be obtained without moving the patient. Patients with implants (pacemakers) cannot undergo MRI. Gadolinium is used as IV contrast for better visualization of organs and their abnormalities.

### Uses of MRI

- ◆ MRI can differentiate the different zones (endometrium, inner and outer myometrium) of the uterus clearly (see Fig. 37.84). It can measure the depth of myometrial penetration of endometrial cancer preoperatively
- ◆ MRI can detect accurately the parametrial invasion of cervical cancer but cannot identify lymphatic metastases reliably. It is more reliable in distinguishing post-treatment fibrosis and recurrence
- ◆ MRI is superior to CT or ultrasound in diagnosing adenomyosis, myomas and endometrial cancer (including myometrial invasion)
- ◆ Endovaginal or endorectal coils produce high resolution images of the cervix and parametrium. Tumor volume can be measured with 3D imaging system. Coronal and axial planes are used to determine the invasion of the bladder, rectum, parametrium and uterine body
- ◆ MRI does not require the use of radio-opaque contrast agents. MRI uses gadolinium, a magnetically opaque contrast agent and it is not nephrotoxic
- ◆ MRI is found to be safe in pregnancy and is not mutagenic
- ◆ Leiomyomas are better diagnosed with MRI.
- ◆ MRI is a noninvasive tool in the diagnosis of endometriosis. It can measure the depth of penetration, which is responsible for pelvic pain.
- ◆ MRI is superior to CT in the evaluation of metastatic lymph nodes or recurrent pelvic tumor. However, neither CT nor MRI can detect microscopic malignant disease (see p. 664).

MRI is twice more expensive than CT.

### Hazards

**Main hazards** are electroconvulsions and atrial fibrillation. This is due to rapidly changing magnetic field. Hence, caution should be exercised with epileptic patients and who had recent myocardial infarction. Other limitation of MRI is patient acceptance. Many patient feel 'trapped' in the machine (psychological distress).

### POSITRON EMISSION TOMOGRAPHY (PET)

The PET is based on the tissue uptake of <sup>18</sup>F-fluoro-2 deoxyglucose (FDG). FDG-PET can measure the difference between the normal tissue and cancerous tissue. Cancer tissues process this glucose analogue differently compared to that of normal tissues. This glucose analogue is given IV. FDG-PET scan is then done and the images are interpreted.

FDG-PET scan is more sensitive for detection of metastatic disease and recurrence of ovarian or cervical malignancy. It is also useful to assess the response following tumor therapy. FDG-PET scan is found to be more sensitive and specific compared to CT or MRI.

Sensitivity of PET in detecting pelvic node metastasis is 80% compared to MRI (70%) and CT (48%).

### CONCLUSIONS

All the imaging systems have got their role in gynecological practice.

**X-ray**, either plain or using contrast media, has got its place. It is cheaper and quite informative with minimal risks of irradiation.

**Ultrasound** establishes a definite place in diagnostic evaluation. Ultrasound guided procedures are used for both the diagnostic and therapeutic purposes.

**CT** is useful in the diagnosis of lymph node metastasis and depth of myometrial invasion in endometrial cancer. It may be employed in selected cases to detect microadenoma of pituitary or metastatic lesions in the brain or liver.

**MRI:** Superior to CT or ultrasound. It is especially helpful to differentiate post-treatment fibrosis and tumor. It is safe in pregnancy.

- ◆ PET is helpful to differentiate normal tissues from cancerous one.

## ENDOMETRIAL SAMPLING

Endometrial sampling is one of the diagnostic tests, most frequently performed as an outdoor procedure. This rapid, safe and inexpensive test is employed in the clinical work up of women with infertility or abnormal uterine bleeding or for periodic screening during HRT. The instrument commonly used is either a Vabra aspirator or a Sharman curette. **Currently endometrial sampler (Pipelle) is used as an outpatient procedure** (Fig. 9.22). A thin plastic cannula (2–4 mm diameter), with a plunger within, is negotiated within the uterus. **It is done as an outpatient procedure.** When the plunger is withdrawn, adequate endometrium is obtained due to suction action. This procedure is reliable and is accepted by the patient. **Indications of endometrial sampling are:** (a) Dysfunctional uterine bleeding; (b) Abnormal bleeding following the use of hormone replacement therapy; (c) Abnormal perimenopausal or menopausal bleeding. Pipelle is the instrument of first choice for endometrial sampling. The failure rate of the procedure is < 8%. To study the hormonal effect, material from the fundus and upper part of the body is to be taken. However, additional diagnostic procedures, such as hysteroscopy should be done when needed. When a large tissue mass is needed for histological studies, a thorough endometrial curettage is to be done under anesthesia as in endometrial tuberculosis or postmenopausal bleeding.

**ENDOMETRIAL BIOPSY:** The most reliable method to study the endometrium is by obtaining the material by curettage after dilatation of the cervix usually under general anesthesia. Its clinical application is described in appropriate chapters (see p. 194, 558).

**TESTS FOR TUBAL PATENCY:** These are described in the Chapter 16 (see p. 238).

**CERVICAL BIOPSY:** To confirm the clinical diagnosis of the cervical pathology, biopsy is mandatory. It can be done in the outpatient department or in indoor. Biopsy can be taken safely at the outpatient department, if the pathology is detectable, but for wider tissue excision as in cone biopsy, it should be done as an inpatient procedure. The details are described in page 589.

## CULDOCENTESIS

### Definition

Culdocentesis is the transvaginal aspiration of peritoneal fluid from the cul-de-sac or pouch of Douglas.

### Indications

- ◆ In suspected disturbed ectopic pregnancy or other causes producing hemoperitoneum
- ◆ In suspected cases of pelvic abscess.

### Steps

- ◆ The procedure is done under sedation
- ◆ The patient is put in lithotomy position
- ◆ Vagina is cleaned with Betadine
- ◆ A posterior vaginal speculum is inserted
- ◆ An 18 gauge spinal needle fitted with a syringe is inserted at a point 1 cm below the cervicovaginal junction in the posterior fornix (Fig. 9.23)
- ◆ After inserting the needle to a depth of about 2 cm, suction is applied as the needle is withdrawn.
- ◆ **If unclotted blood is obtained, the diagnosis of intraperitoneal bleeding is established.** If no blood or fluid is obtained, the needle is withdrawn slowly while intermittent suction should be maintained. If the tap is found dry, another attempt is to be made.


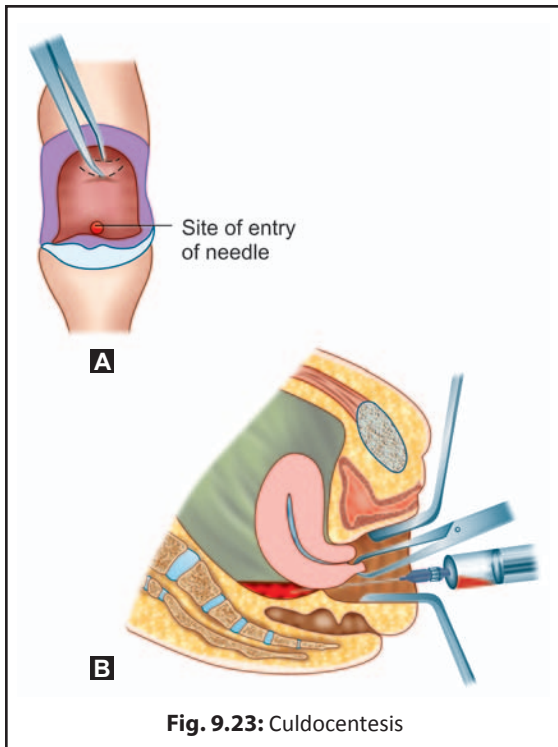


Fig. 9.22: Endometrial sampler



## ENDOSCOPY IN GYNECOLOGY

(See Chapter 35)

Endoscopy has become an essential armamentarium in the diagnostic evaluation of gynecologic lesions as well as for operative procedures. Gynecological endoscopy includes the procedures as mentioned in Table 9.7.

**TABLE 9.7** GYNECOLOGICAL ENDOSCOPY

• Laparoscopy	• Hysteroscopy	• Salpingoscopy
• Falloposcopy	• Cystoscopy	• Culdoscopy
• Sigmoidoscopy and proctoscopy		

## LAPAROSCOPY

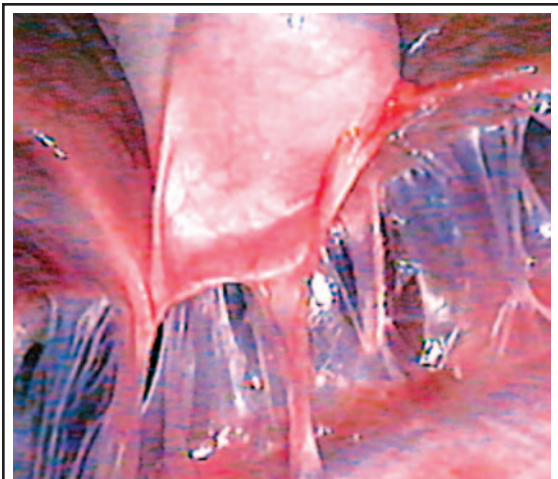
Laparoscopy is a technique of visualization of peritoneal cavity by means of a fiberoptic endoscope introduced through the abdominal wall. Prior pneumoperitoneum is achieved by introduction of carbon dioxide or air. For diagnostic purposes, either local or general anesthesia may be used. Its use is gradually widening both in diagnostic and therapeutic field in gynecology. The details are in Chapter 35 (Fig. 9.24).

## Indications

- ◆ **Diagnostic**
- ◆ **Operative (see Chapter 35)**

## Diagnostic

- ◆ Infertility work up (see Chapter 16)
  - Peritubal adhesions.
  - Chromopertubation (see p. 238).
  - Minimal endometriosis (see p. 308).
  - Ovulation stigma of the ovary.
  - Before reversal of sterilization operation (see p. 247).
- ◆ Chronic pelvic pain (see p. 555)
- ◆ Nature of a pelvic mass: Fibroid, ovarian cyst
- ◆ To diagnose an acute pelvic lesion
  - Ectopic pregnancy (see p. 555).
  - Acute appendicitis.
  - Acute salpingitis—diagnosis and collection of pus for culture.
- ◆ Follow-up of pelvic surgery (second look)
  - Tuboplasty
  - Ovarian malignancy
  - Evaluation of therapy in endometriosis.



**Fig. 9.24:** Chlamydial infection causing perihepatic adhesions (Fitz-Hugh-Curtis syndrome) diagnosed by laparoscopy

- ◆ Investigation protocol of amenorrhea
- ◆ Diagnosis of suspected Müllerian abnormalities (see p. 45)
- ◆ Uterine perforation.

**Timing of laparoscopy:** In infertility work up, it may be done in the periovulatory period to facilitate chromopertubation and also diagnosis of ovulation. However, in endometriosis, it is preferably done in the premenstrual period when the ectopic endometrial implants increase in size.

**Operative**—(see Chapter 35).

**Complications**—(see p. 619).

### HYSTEROSCOPY (See P. 587)

Hysteroscopy is an operative procedure whereby the endometrial cavity can be visualized with the aid of fiberoptic telescope. **The uterine distension is achieved by** carbon dioxide, normal saline or glycine. The instrument is to pass transcervically, usually without dilatation of the cervix or local anesthesia. However, for operative hysteroscopy, either paracervical block or general anesthesia is required. **Diagnostic hysteroscopy should be performed in the postmenstrual period** for better view without bleeding. The chance of conception disturbance is absent (Fig. 9.25).

Recently, contact hysteroscopy has become more popular since a distending medium is not needed. The interpretation of endometrial pathology is similar to colposcopy in that it depends on color, contour and vascular pattern.

**Indications:**     ■ **Diagnostic**     ■ **Operative**

The technical details and operative hysteroscopy are dealt in Chapter 35.

#### Diagnostic

- ◆ Unresponsive irregular uterine bleeding to exclude uterine polyp, submucous fibroid or products of conception
- ◆ Congenital uterine septum in recurrent abortion
- ◆ Missing threads of IUD
- ◆ Intrauterine adhesions (uterine synechiae)

- ◆ To visualize transformation zone with colpomicrohysteroscopy when colposcopic finding is unsatisfactory.

**Operative**—(see p. 622).

**Complications**—(see p. 623).

**Conclusion:** The instruments for endoscopic procedures are costly and require a great deal of expertise for diagnostic and especially for operative procedures.

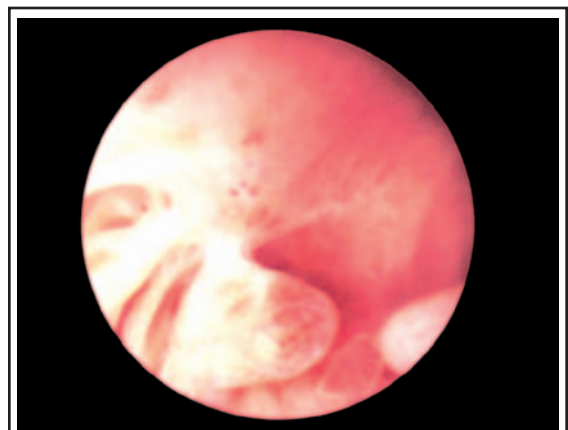
**SALPINGOSCOPY:** In salpingoscopy, a firm telescope is inserted through the abdominal ostium of the uterine tube so that the tubal mucosa can be visualized by distending the lumen with saline infusion. The telescope is to be introduced through laparoscope.

Salpingoscopy allows study of the physiology and anatomy of the tubal epithelium and **permits more accurate selection of patients for IVF rather than the tubal surgery.**

**FALLOPOSCOPY**—see p. 239.

**CYSTOSCOPY:** The main use of cystoscopy in gynecology is to evaluate cervical cancer prior to staging and, to investigate the urinary symptoms including hematuria, incontinence and fistulae.

**CULDOSCOPY:** Culdoscopy is an optical instrument designed to visualize the pelvic structures through an



**Fig. 9.25:** Hysteroscopic view of a submucous fibroid polyp

incision in the pouch of Douglas. Its use has almost been replaced by laparoscopy.

**PROCTOSCOPY AND SIGMOIDOSCOPY:** For rectal involvement of genital malignancy, a digital examination or at best proctoscopy is usually adequate.

**EXAMINATION UNDER ANESTHESIA (EUA):** EUA is indicated where bimanual examination cannot be conducted properly either because of extreme tenderness or inadequate relaxation of abdominopelvic muscles or non-cooperative patient. It should be done routinely in all cases of uterine malignancy for clinical staging. It is extended freely to examine virgins or in cases with pediatric gynecological problems.

### LASER IN GYNECOLOGY

The word 'Laser' is an acronym for *light amplification by Stimulated Emission of Radiation*:

#### Physics of Laser

The important physical properties of laser are:

- (i) Monochromaticity—Light beams of a particular laser have got the same wavelength.
- (ii) Coherent—The light waves are all perfectly aligned and unidirectional.
- (iii) Collimated—The light beams run parallel and do not diverge.
- (iv) The laser beam can be converged by a convex lens to a sharp focus, called **spot size**.
- (v) Power density is the measure of laser effects upon tissue. It is expressed as watts/cm<sup>2</sup>.
- (vi) Smaller the spot size, greater is the power density.
- (vii) Laser-tissue interaction—The water in the cells (80% by volume) boils instantly at the temperature of 100°C. The cell explodes and vaporizes. The cell protein and minerals are incinerated and look charred.
- (viii) The depth of tissue destruction is very precise and there is very little lateral effect.
- (ix) Laser effect depends on power (watts), spot size, power density, and laser-tissue contact time.
- (x) Beams of CO<sub>2</sub> and Nd: YAG laser are invisible. There is preferential absorption of laser by one tissue from another.

Common laser systems used in gynecology are carbon dioxide, Nd : YAG, KTP and Argon (Table 9.8).

Fiberoptic laser laparoscopy (KTP 532 and Argon) has the following advantages: Accurate targetting, better hemostasis, contact modes of cutting, vaporization, coagulation and less laser plume production.

#### USES OF LASER IN GYNECOLOGY

Principal use of laser in gynecology is for the purpose of tissue cutting, coagulation or vaporization. It is used widely in genital tract surgery and with endoscopic surgery. It is commonly used in the management of:

- (i) Cervical intraepithelial neoplasia (CIN) (see p. 320).
- (ii) Conization of the cervix (see p. 589).
- (iii) Vulvar intraepithelial neoplasia (VIN) (see p. 318).
- (iv) Vaginal intraepithelial neoplasia (VAIN) (see p. 319).
- (v) Vaporization of pelvic endometriosis (see p. 312).
- (vi) Laser laparoscopy for ovarian cystectomy, adhesiolysis, removal of ectopic pregnancy and presacral neurectomy.
- (vii) Laser laparoscopy assisted hysteroscopy, for dividing large pedicles that have been coagulated or suture ligated.

**TABLE 9.8** COMMON LASER SYSTEMS USED IN GYNECOLOGY

Laser type	Wavelength	Tissue penetration
Carbon dioxide	10.6 μm	0.1 mm
Neodymium : yttrium-aluminium garnate (Nd : YAG)	1.06 μm	0.6–4.2 mm
Potassium titanyl-phosphate (KTP 532)	0.532 μm	0.4–0.8 mm
Argon	0.5 μm	0.2 mm

(viii) Hysteroscopic surgery—Laser ablation of endometrium (see p. 193), resection of uterine septum (metroplasty) and submucous fibroids (see p. 283).

### Limitations of Laser

- ◆ The equipment is expensive
- ◆ Technical complexity—requires sufficient training.

### HAZARDS OF LASER SYSTEMS

Laser must be used by a trained person. Laser protection guidelines must be strictly followed to protect the operator, assistant, the theatre staff and the patient from the accidental hazards. A laser controlled area

(LCA) must have warning signs when laser is in use. Special spectacles are used to protect the eyes. Common hazards are :

**A**—(i) Eyes—visual loss due to corneal or retinal damage, (ii) Skin damage, and (iii) Damage from laser smoke.

**B**—General: (i) Burn injury (use of spirit and paper drapes must be avoided in theatre), (ii) Inflammable anesthetic gases are to be used with great care, (iii) Reflections of laser beam is dangerous. Shining instruments are not to be used, (iv) Fire extinguisher should always be available (v) Plume of smoke should be extracted.

## KEY POINTS

- The clinical examination should be thorough and meticulous. The examination should in fact proceed with the provisional diagnosis in mind. A patient hearing should be given about the complaints made by the patient in her own words.
- Menstrual history includes age of menarche, cycle length, regularity, duration of period, amount of flow and the first day of the last menstrual period.
- Integration of the symptomatology to a single pathology is to be tried first before embarking on the diagnosis of multiple pathology.
- The general and systemic examination should be thorough and meticulous.
- Clinical breast examination (CBE) should be a routine part of the gynecologic examination (Fig. 9.1). Annual CBE of women with age > 40 years is recommended (ACOG).
- CBE begins with inspection and then a thorough palpation (see p. 565). The examiner should check for nipple discharge (see p. 566) as well as the axillary lymph nodes (see p. 565).
- Bladder should be empty prior to examination.
- Abdominal palpation should be done with the flat of the hand rather than the tips of the fingers. Whether a mass is felt or not, routine palpation of the viscera includes liver, spleen, cecum, pelvic colon, gallbladder and kidneys.
- It is mandatory to elicit presence of free fluid in the peritoneal cavity in all cases of pelvic tumors.
- Pelvic examination includes inspection of external genitalia, vaginal examination (inspection with a speculum, palpation and bimanual examination), rectal examination and rectovaginal examination.
- Rectovaginal examination is of special help to differentiate a growth arising from the ovary or rectum.
- Dyskaryosis is the morphological abnormality of the nucleus. It may be mild, moderate or severe. Koilocytosis is associated with human papilloma virus infection.
- As a screening procedure, the material from the cervix is best collected using Ayre's spatula. About 5 cases of cervical intraepithelial neoplasia are diagnosed per 1000 patients and invasive carcinoma of the cervix in order of 1 in 1000. The Pap smear screening should best be done at interval of 3 years after 2 yearly negative smears from 18 years to 60 years. However, screening interval depends on patient's risk level (Table 9.1).
- Diagnostic accuracy of Pap smear after three consecutive negative tests is about 99 percent.
- For cytohormonal study, the smear is taken from the lateral wall of the upper-third of the vagina. The estrogenic smear is suggested by preponderance of large eosinophilic cells with pyknotic nuclei. The progesterone smear is predominantly basophilic with vesicular nuclei. The background is dirty.

Contd...

- Power density is the most important determinant of the laser effects. Greater the power density, the less the thermal effect and less is the hemostatic property.
- Maturation index (MI), is expressed by three numbers as the percentage of parabasal, intermediate and superficial cells written from left to the right. There is significant shift in maturation index from birth to menopause.
- Examination of cervical mucus is done for bacteriological study, to know the hormonal status and in infertility investigation.  
 Estrogenic mucus is clear, abundant and has got the power of elasticity and shows pattern of fern tree formation. Progesterone smear is thick and viscid, loses its property of elasticity and ferning disappears.
- Postcoital test (PCT) is done on day 12 or 13. The reporting time is within 8-12 hours following intercourse. Presence of at least 10 progressively motile sperm per high power field signifies the test to be normal. Routine postcoital test is not recommended.
- Menstrual cycles after puberty and before menopause are frequently anovulatory and irregular.
- Pap smears should be performed every 1-3 years depending upon **patients' risk** factors.
- Ultrasonography (TAS, TVS or TV-CDS) has become a common diagnostic modality in gynecology. It is widely used in infertility work up (sonohysterosalpingography, folliculometry, detection of ovulation and oocyte retrieval in IVF programme), evaluation of pelvic mass, ectopic pregnancy and endometrial disease. Sonographically guided procedures provide added information.  
 CT is useful in detection of enlarged pelvic lymph nodes and microadenoma of pituitary. Helical CT is a modification that uses movement of the patient combined with rotation of several radiographic registers in a spiralling fashion. Vascular images are so high quality that it has replaced pulmonary angiography and ventilation-perfusion scans. Surface radiation dose from CT is between 2 and 10 rads.
- MRI uses radiowaves (nonionising) and magnetic fields. It accurately shows parametrial invasion of cervical cancer but cannot reliably identify the lymph node metastases. It can measure the depth of myometrial penetration in endometrial carcinoma preoperatively. High resolution images in multiple planes are obtained. Tumour volume can be measured with 3D imaging system.
- MRI should not be used in patients with cochlear implants or pacemakers. It is safe in women with pregnancy or IUDs.
- Endometrial sampling is useful in the clinical **work-up** of women with infertility or abnormal perimenopausal bleeding. It can be performed in the OPD using a narrow plastic cannula (pipette).
- Culdocentesis is indicated in suspected cases of haemoperitoneum or pelvic abscess.
- Pap test (cervical smear test) is the most effective cancer screening procedure. It reduces the incidence of cancer cervix by 80% when used regularly.
- Cervical cancer is caused by HPV (see p. 323) infection. Virtually most HPV infections regress spontaneously. An HPV-DNA test can be used to triage women with ASC-US cytology reports.
- Colposcope is a lower power binocular microscope. It is employed in cases with abnormal cervical smear and with clinically suspicious cervixes, especially with history of contact bleeding even if the smear is negative. Colposcopy directed biopsy is the best one when the lesion is not clinically detected. Colposcope is used to evaluate women with abnormal cytology (p. 115, 324).
- The use of laparoscopy is gradually widening. The major diagnostic uses are infertility, chronic pelvic pain and to exclude pelvic lesion (see Ch. 35).
- Hysteroscopy is gaining popularity as a diagnostic aid in unresponsive uterine bleeding, uterine synechiae, congenital uterine septum or missing threads of IUD (see Ch. 35).
- **Salpingoscopy** is the evaluation of tubal mucosa with a telescope, introduced through the abdominal ostium of the tube.
- Principal use of laser in gynecology is for tissue cutting, coagulation or vaporisation. Laser effects depend on power (watts), spot size, power density and laser-tissue contact time. Commonly used laser systems in gynecology are CO<sub>2</sub>, Nd:YAG, KTP 532 and Argon (Table 9.8).

# Pelvic Infection

## DEFENCE OF THE GENITAL TRACT

As there is free anastomosis between the lymphatics and blood vessels, the infection of one pelvic organ usually spreads to the other more frequently. There is direct communication of the peritoneal cavity to the exterior through the vagina. In spite of these, the frequency and intensity of pelvic infection is kept lowered by the defence mechanism.

### Vulval Defence

*Anatomic:* (i) Apposition of the cleft by labia; (ii) Compound racemose type of Bartholin's glands.

*Physiologic:* (i) Fungicidal action of the secretion (undecylenic acid) of the apocrine glands; (ii) Natural high resistance to infection of the vulval and perineal skin.

### Vaginal Defence

*Anatomic:* (i) Apposition of the anterior and posterior walls with its transverse rugae; (ii) Stratified epithelium devoid of glands.

*Physiologic:* This is maintained by the hormone oestrogen (Table 10.1).

**At Birth**, under the influence of maternal estrogen circulating into the newborn, the vaginal epithelium becomes multilayered. The desquamated epithelium containing glycogen is converted into lactic acid probably by enzymatic action for the first 48 hours. Subsequently, the Doderlein's bacilli appear probably from the gut and convert the glycogen into lactic acid. As a result, **for about 10-12 days following birth, the vaginal defence is good and infection is unlikely.**

**Thereafter and upto puberty**, there is no circulatory estrogen. The vaginal epithelium is reduced to few layers; glycogen is absent and so also the Doderlein's bacillus. The vaginal pH becomes neutral or alkaline. **During the reproductive period** with highoestrogen, the vaginal defence is fully restored. But again in **postmenopause**, after the withdrawal of estrogen, the vaginal defence is lost.

It should be emphasized that only the **Doderlein's bacilli can grow in the acidic media with pH 4–4.5**. But when the pH increases, the other organisms normally present in the vagina will grow.

### Phases of Life when Defence is lost:

(i) Following 10 days of birth till puberty is reached.

**TABLE 10.1 DEFENCE OF THE VAGINA IN RELATION TO AGE**

	<b>Newborn (0-10 days)</b>	<b>Up to puberty</b>	<b>Childbearing period</b>	<b>Postmenopause</b>
Epithelium	Multilayered	Thin	Multilayered	Thin
Glycogen	++	(-)	++	(-)
Doderlein's bacillus	+	(-)	++	(-)
pH	Acidic (4-5)	Neutral or alkaline (6-8)	Acidic (4-5)	Neutral (6-7)



(ii) During reproductive period—in the following situation:

- ◆ **During menstruation:** The vaginal pH becomes increased due to contaminated blood and fall of oestrogen. The protective cervical mucus disappears and the endometrium sheds.
- ◆ **Following abortion and childbirth:** The contaminated lochia increases the pH. The raw placental site, inevitable tear of the cervix, bruising of the vagina and presence of blood clots or remnants of decidua favor nidation of the bacterial growth.

(iii) During menopause.

**Cervical defence:** *Anatomic*—(i) Racemose type of glands, (ii) mucus plug.

*Physiologic*—Bactericidal effect of the mucus.

**Uterine defence:** (i) Cyclic shedding of the endometrium (ii) Closure of the uterine ostium of the fallopian tube with slightest inflammatory reaction in the endometrium.

**Tubal defence:** *Anatomic*—Integrated mucus plicae and epithelial cilia.

*Physiologic*—Peristalsis of the tube and also the movement of the cilia are towards the uterus.

**Causative organisms:** The bacterial pathogens involved in upper genital tract infections are principally derived from the normal flora of the vagina and endocervix. Exogenous sources are sexually transmitted or following induced or unsafe abortion or during delivery in unhygienic surroundings.

## ORGANISMS

1. **Pyogenic (50%):** This is the commonest type – the organisms responsible are:

### Aerobes

The gram-positive organisms are *Staphylococcus*.

The gram-negatives are *E. coli*, *Pseudomonas*, *Klebsiella*, *N. gonorrhoeae*, etc.

### Anaerobes

The gram-positives are anaerobic *Streptococcus*, *Clostridium welchii*, *Cl. tetani*, etc. The gram-negatives are mainly bacteroides group of which *Bacteroides fragilis* is the commonest.

2. **Sexually transmitted disease (STD):** The organisms are *N. gonorrhoeae*, *Chlamydia trachomatis*, *Treponema pallidum*, *Herpes simplex virus type II*, *Human papilloma virus*, *Gardnerella vaginalis* (*Haemophilus vaginalis*), *Haemophilus ducreyi*, *Donovan bodies*, *HIV I or II*, etc.
3. **Parasitic:** *Trichomonas vaginalis*
4. **Fungal:** *Candida albicans*
5. **Viral:** Herpes simplex virus type II, Human papilloma virus, HIV, Condylomata accuminata, etc.
6. **Tubercular:** *Mycobacterium tuberculosis*.

## MODES OF SPREAD OF INFECTIONS

The route of infection is most commonly ascending in nature. However, the classic modes of infection of some specific organisms are:

- **Through continuity and contiguity**—gonococcal infection (Fig. 10.1).
- **Through lymphatics and pelvic veins**—post-abortal and puerperal infection—by pyogenic organisms other than gonococcus (Fig. 10.2).
- **Through blood stream**—tubercular
- **From adjacent infected extra-genital organs** like intestine.

## ACUTE PELVIC INFECTION

- Pelvic inflammatory disease (PID).
- Following delivery and abortion.
- Following gynecological procedures.
- Following IUD.
- Secondary to other infections—appendicitis.

## PELVIC INFLAMMATORY DISEASE (PID)

### DEFINITION

PID is a disease of the upper genital tract. It is a spectrum of infection and inflammation of the upper genital tract organs typically involving the uterus (endometrium), fallopian tubes, ovaries, pelvic peritoneum and surrounding structures. It

is attributed to the ascending spread of microorganisms from the cervicovaginal canal to the contiguous pelvic structures. **The clinical syndrome is not related to pregnancy and surgery.**

But, as the terminology fails to pinpoint the precise organ or organisms involved, it is better to use the anatomical terminology in relation to which organ is involved in the infectious process. Thus, **the better terminology should be** either endometritis, salpingitis, pelvic peritonitis or tuboovarian abscess. **The cervicitis is not included in the list.**

Many, however, prefer the term salpingitis as because it ultimately bears the brunt of acute infection.

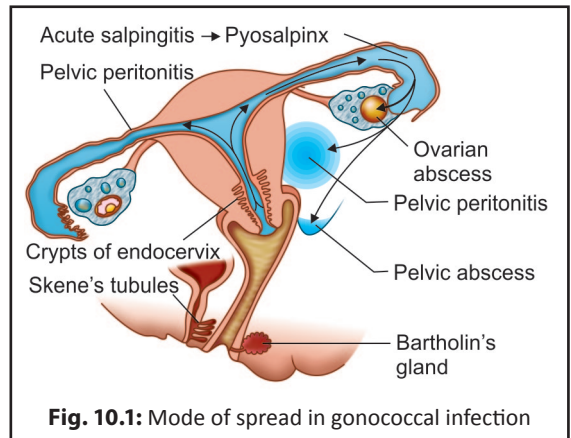
From a clinical perspective, it is more pragmatic to describe acute salpingitis as sexually transmitted or not.

**Epidemiology:** Despite better understanding of the etiology, pathogenesis, improved diagnostic tools such as sonar or laparoscopy and advent of wide range of antimicrobials, it still constitutes a health hazard both in the developed and more so in the developing countries. The incidence of pelvic infection is on the rise due to the rise in sexually transmitted diseases.

**The ready availability of contraception together with increased permissive sexual attitude** has resulted in increased incidence of sexually transmitted diseases and, correspondingly, acute PID (more in p. 147).

The incidence varies from 1–2 per cent per year among sexually active women. About 85 per cent are spontaneous infection in sexually active females of reproductive age. The remaining 15 per cent follow procedures, which favors the organisms to ascend up. Such iatrogenic procedures include endometrial biopsy, uterine curettage, insertion of IUD and hysterosalpingography. Two-thirds are restricted to young women of less than 25 years and the remaining one-third limited among 30 years or older.

**Pelvic inflammatory disease is a major problem to the reproductive health of young women.** PID may be asymptomatic or subclinical. Currently there is **certain changes in the epidemiology of PID.** (A) Shift from *inpatient PID to outpatient PID.* (B) Change in clinical presentation. Less severe disease is commonly seen. (C) Shift in the microbial etiology of more *Chlamydia trachomatis* than gonococcus and others.



**Fig. 10.1:** Mode of spread in gonococcal infection

## RISK FACTORS

- Menstruating teenagers.
- Multiple sexual partners.
- Absence of contraceptive pill use.
- Previous history of acute PID.
- IUD users.
- Area with high prevalence of sexually transmitted diseases.

Teenagers have got low hormonal defence in response to genital tract infection. Wider area of cervical epithelium allows colonisation of *Chlamydia trachomatis* and *N. gonorrhoeae* (See p. 147).

## PROTECTIVE FACTORS

### ■ Contraceptive practice

- ◆ Barrier methods, specially condom, diaphragm with spermicides (see p. 476).
- ◆ Oral steroidal contraceptives have got two preventive aspects.
  - Produce thick mucus plug preventing ascent of sperm and bacterial penetration (see p. 485).
  - Decrease in duration of menstruation, creates a shorter interval of bacterial colonization of the upper tract.

- ◆ Monogamy or having a partner who had vasectomy.

### ■ Others

- ◆ Pregnancy

- ◆ Menopause
- ◆ Vaccines: hepatitis B, HPV (p. 326).

## MICROBIOLOGY

Acute PID is usually a **polymicrobial** infection caused by organisms ascending upstairs from downstairs.

**The primary organisms are** sexually transmitted and limited approximately to *N. gonorrhoeae* in 30 per cent, *Chlamydia trachomatis* in 30 per cent and *Mycoplasma hominis* in 10 per cent.

**The secondary organisms** normally found in the vagina are almost always associated sooner or later. These are:

**Aerobic organisms**—non-hemolytic *Streptococcus*.

*E. coli*, group B *Streptococcus* and *Staphylococcus*.

**Anaerobic organisms**—*Bacteroides* species—*fragilis* and *bivius*, *Peptostreptococcus* and *Peptococcus*.

## MODE OF AFFECTION

- The classic concept is that the gonococcus ascends up to affect the tubes through mucosal **continuity and contiguity**. This ascent is facilitated by the sexually transmitted vectors such as sperm and trichomonads.
- **Reflux of** menstrual blood along with gonococci into the fallopian tubes is the other possibility.
- *Mycoplasma hominis* probably spreads across the **parametrium** to affect the tube.
- The secondary organisms probably affect the tube through **lymphatics**.
- Rarely, organisms from the gut may affect the tube **directly**.

## PATHOLOGY

The involvement of the tube is almost always bilateral and usually following menses due to loss of genital defence.

**The pathological process is initiated primarily in the endosalpinx.** There is gross destruction of the epithelial cells, cilia and microvilli. In severe infection, it invades all the layers of the tube and produces acute inflammatory reaction; becomes edematous and hyperemic. The exfoliated cells

along with the exudate pour into the lumen of the tube and agglutinate the mucosal folds. **The abdominal ostium is closed** by the indrawing of the edematous fimbriae and by inflammatory adhesions. The uterine end is closed by congestion. The closure of both the ostia results in pent up of the exudate inside the tube. **Depending upon the virulence, the exudate may be watery producing hydrosalpinx or purulent producing pyosalpinx.** The purulent exudate then changes the microenvironment of the tube which favors growth of other pyogenic and anaerobic organisms resulting in deeper penetration and more tissue destruction. The organisms spontaneously die within 2–3 weeks. As the serous coat is not much affected, **the resulting adhesions of the tube with the surrounding structures are not so dense**, in fact flimsy, unlike pyogenic or tubercular infection.

On occasions, the exudate pours through the abdominal ostium to produce pelvic peritonitis and pelvic abscess or may affect the ovary (the organisms gain access through the ovulation rent) producing ovarian abscess. A tubo-ovarian abscess is thus formed (Fig. 10.1).

## CLINICAL FEATURES

### SYMPTOMS

Patients with acute PID present with a wide range of non-specific clinical symptoms. Symptoms usually appear at the time and immediately after the menstruation.

- ◆ Bilateral lower abdominal and pelvic pain which is dull in nature. The onset of pain is more rapid and acute in gonococcal infection (3 days) than in chlamydial infection (5–7 days).
- ◆ There is fever, lassitude and headache.
- ◆ Irregular and excessive vaginal bleeding is usually due to associated endometritis.
- ◆ Abnormal vaginal discharge which becomes purulent and or copious.
- ◆ Nausea and vomiting.
- ◆ Dyspareunia.
- ◆ Pain and discomfort in the right hypochondrium due to concomitant perihepatitis (**Fitz-Hugh-**

**Curtis syndrome**) may occur in 5–10 per cent of cases of acute salpingitis. **The liver is involved** due to transperitoneal or vascular dissemination of either gonococcal or chlamydial infection.

### SIGNS

- ▶ The temperature is elevated to beyond 38.3°C.
- ▶ Abdominal palpation reveals tenderness on both the quadrants of lower abdomen. The liver may be enlarged and tender.
- ▶ Vaginal examination reveals: (1) Abnormal vaginal discharge which may be of purulent. (2) Congested external urethral meatus or openings of Bartholin's ducts through which pus may be seen escaping out on pressure. (3) Speculum examination shows congested cervix with purulent discharge from the canal. (4) Bimanual examination reveals bilateral tenderness on fornix palpation, which increases more with movement of the cervix. There may be thickening or a definite mass felt through the fornices.

### CLINICAL DIAGNOSTIC CRITERIA OF PID (CDC-2006)

#### ▶ Minimum Criteria

- ◆ Lower abdominal tenderness.
- ◆ Adnexal tenderness.
- ◆ Cervical motion tenderness.

#### ▶ Additional Criteria

- ◆ Oral temperature > 38.3°C.
- ◆ Mucopurulent cervical or vaginal discharge.
- ◆ Raised C-reactive protein and/or ESR.
- ◆ Laboratory documentation of positive cervical infection with Gonorrhoea or *C. trachomatis*.

#### • Definitive Criteria

- ◆ Histopathologic evidence of endometritis on biopsy.
- ◆ Imaging study (TVS/MRI) evidence of thickened fluid filled tubes ± tubo-ovarian complex.
- ◆ Laparoscopic evidence of PID (see below).

### INVESTIGATIONS

**Identification of organisms:** For identification of organisms, the materials are collected from the following available sources:

1. Discharge from the urethra or Bartholin's gland.
2. Cervical canal.
3. Collected pus from the fallopian tubes during laparoscopy or laparotomy.

The material so collected is subjected to Gram stain and culture (aerobic and anaerobic). The findings of gram-negative diplococci is very much suggestive of gonococcal infection. Except in highly sophisticated centers, the detection of *Cl. trachomatis* is difficult (for diagnosis see p. 150). As the process of investigation is not specific and is time consuming, treatment for *Cl. trachomatis* should be started from the clinical diagnosis. A positive Gram stain smear from endocervical mucus is non-specific and a negative smear does not rule out upper genital tract infection.

**Blood:** Leucocyte count shows leucocytosis to more than 10,000 per cu mm and an elevated ESR value of more than 15 mm per hour. The results correlate with the severity of the inflammatory reactions of the fallopian tubes as seen on laparoscopy. **Serological test for syphilis should be carried out for both the partners in all cases.**

**Laparoscopy:** Laparoscopy is considered the "**gold standard**". While it is the **most reliable aid** to support the clinical diagnosis but it may not be feasible to do in all cases. It is reserved only in those cases in which differential diagnosis includes salpingitis, appendicitis or ectopic pregnancy. Nonresponding pelvic mass needs laparoscopic clarification (also see p. 141).

#### Laparoscopic findings and severity of PID:

- ◆ **Mild:** Tubes: Edema, erythema, no purulent exudates and mobile.
- ◆ **Mod:** Purulent exudates from the fimbrial ends, tubes not freely movable.
- ◆ **Severe:** Pyosalpinx, inflammatory complex, abscess.
- ◆ **'Violin string'** like adhesions in the pelvis and around the liver suggests chlamydial infection.

**TABLE 10.2** CLINICAL FEATURES OF ACUTE PID

◆ Fever > 38°C.	
◆ Bilateral lower abdominal tenderness with radiation to the legs.	
◆ Abnormal vaginal discharge.	
◆ Abnormal uterine bleeding.	
◆ Deep dyspareunia.	
◆ Cervical motion tenderness	] On bimanual examination
◆ Adnexal tenderness	

Laparoscopy helps to aspirate fluid or pus for microbiological study from the fallopian tube, ovary or pouch of Douglas.

**Sonography:** It is of limited value. Dilated and fluid-filled tubes, fluid in the pouch of Douglas or adnexal mass are suggestive of PID. It may be employed where clinical examination is difficult or is not informative because of acute tenderness or obesity.

**Culdocentesis:** Aspiration of peritoneal fluid and its white cell count, if exceeds 30,000 per mL, is significant in acute PID. Bacterial culture from the fluid is not informative because of vaginal contamination.

**Investigations are also to be extended to male partner** and smear and culture are made from urethral secretion.

## DIAGNOSIS

**The anatomic diagnosis** of infection to the upper genital tract is made from the following clinical features (Table 10.2).

**Microbial diagnosis** is difficult. But as already emphasized, one should not wait for the report, instead treatment should be started empirically. **The materials for identification of organisms are** from the cervical and urethral discharge and secretion from the Bartholin's gland, and laparoscopic or laparotomy collection of pus from the fallopian tubes. The materials are to be subjected to Gram stain and culture (aerobic and anaerobic).

Gram stain of the discharge may be positive for gram-negative intracellular diplococci of *N. gonorrhoeae*. Bacteriologic diagnosis of *Chlamydia trachomatis* is difficult. However, the status of the sexual partner is the single most important clue to the diagnosis of chlamydial infection. **If the woman has a stable sexual relationship with asymptomatic man, the clinical manifestations are unlikely to be due to chlamydial infection.**

## DIFFERENTIAL DIAGNOSIS

The clinical condition may be confused with: (1) Appendicitis, (2) Disturbed ectopic pregnancy,

**TABLE 10.3** CLINICAL FEATURES OF ACUTE SALPINGITIS, ACUTE APPENDICITIS AND DISTURBED ECTOPIC

Symptoms and signs	Acute salpingitis (Table 12.3)	Acute appendicitis	Disturbed ectopic
◆ Pain	Acute lower abdominal on both sides	Starts near umbilicus but settles to right iliac fossa	Acute lower abdomen on one side
◆ Amenorrhea and bleeding PV	Unrelated	Unrelated	Usually present
◆ GI symptoms such as nausea, vomiting	Inconsistently present	Usual	Absent
◆ General look	Face-flushed	Toxic	Pale
◆ Tongue	No significant change	Furred	Pale
◆ Pulse	Rapid but proportionate with temperature	Rapid, out of proportion to temperature	Persistent rise even with normal temperature
◆ Temperature	More raised	Slightly raised	Not raised
◆ Tenderness	Lower abdomen on both sides	On McBurney's point may have muscle guard	Lower abdomen more on one side
◆ Per vaginum	Tenderness on both fornices. A mass may be felt	Tenderness on right fornix and high up	Mass may be felt through one fornix extending up to pouch of Douglas

(3) Torsion of ovarian pedicle, haemorrhage or rupture of ovarian cyst, (4) Endometriosis, (5) Diverticulitis and (6) Urinary tract infection (Table 10.3).

**The two conditions—acute appendicitis and disturbed ectopic pregnancy must be ruled out**, because both the conditions require urgent laparotomy whereas acute salpingitis is to be treated conservatively.

### COMPLICATIONS OF PID

**Immediate:** (1) Pelvic peritonitis or even generalized peritonitis. (2) Septicemia—producing arthritis or myocarditis.

**Late:** (1) Dyspareunia. (2) Infertility rate is 12 per cent, after two episodes increases to 25 per cent and after three raises to 50 per cent. It is due to tubal damage or tubo-ovarian mass. (3) Chronic pelvic inflammation is due to recurrent or associated pyogenic infection. (4) Formation of adhesions or hydrosalpinx or pyosalpinx and tubo-ovarian abscess. (5) Chronic pelvic pain and ill health. (6) Increased risk of ectopic pregnancy (6-10 fold).

### TREATMENT

#### Essential steps in the prevention are:

- ◆ Community based approach to increase public health awareness.
- ◆ Prevention of sexually transmitted diseases with the knowledge of healthy and safer sex.
- ◆ Liberal use of contraceptives.
- ◆ Routine screening of high-risk population.

#### The principles of therapy are:

- ◆ To control the infection energetically.
- ◆ To prevent infertility and late sequelae.
- ◆ To prevent reinfection.

**Outpatient therapy:** Apart from adequate rest and analgesic, antibiotics are to be prescribed even before the microbiological report is available. As because the infection is polymicrobial in nature, instead of single, combination of antibiotics should be prescribed. Outpatients antibiotic therapy for acute PID is given in the Table 10.4.

**TABLE 10.4**

#### AMBULATORY MANAGEMENT OF ACUTE PID (CDC-2006)

##### ■ Patient should have oral therapy for 14 days

##### ■ Regimen A

- Levofloxacin 500 mg (or, ofloxacin 400 mg) PO once daily with or without
- Metronidazole 500 PO bid

##### ■ Regimen B

- Ceftriaxone 250 mg IM single dose PLUS
- Doxycycline 100 mg PO bid with or without
- Metronidazole 500 mg PO bid for 14 days

Broad spectrum antibiotic coverage (cefotaxime/cefodoxitin) is indicated as most PIDs are polymicrobial (gram-negative and positive aerobes as well as anaerobic rods and cocci)

All patients treated in the outpatients are **evaluated after 48 hours and if no response, are to be hospitalised.**

**Inpatient therapy:** The patients are to be hospitalized for antibiotic therapy in the conditions as mentioned in Table 10.5.

Bed rest is imposed. Oral feeding is restricted. Dehydration and acidosis are to be corrected by intravenous fluid.

Intravenous antibiotic therapy is recommended for at least 48 hours but may be extended to 4 days, if necessary (Table 10.6).

Improvement of the patient is evidenced by remission of temperature, improvement of pelvic tenderness, normal white blood cell count and negative report on bacteriological study.

**TABLE 10.5**

#### INDICATIONS FOR HOSPITALIZATION (CDC-2006)

- ◆ Suspected tubo-ovarian abscess
- ◆ Severe illness, vomiting, temperature > 38°C
- ◆ Uncertain diagnosis—where surgical emergencies, (e.g. appendicitis) cannot be excluded
- ◆ Unresponsive to outpatient therapy for 48 hours
- ◆ Intolerance to oral antibiotics
- ◆ Co-existing pregnancy
- ◆ Patient is known to have HIV infection

TABLE 10.6

INPATIENT ANTIBIOTIC THERAPY  
(CDC-2006)

- ◆ **Regimen A**
  - Cefoxitin 2 gm IV every 6 hours for 2-4 days  
PLUS
  - Doxycycline 100 mg PO for 14 days
- ◆ **Regimen B**
  - Clindamycin 900 mg IV every 8 hours  
PLUS
  - Gentamicin 2 mg/kg IV (loading dose), followed  
by 1.5 mg/kg IV (maintenance dose) every 8 hours
- ◆ **Alternative Regimen**
  - Levofloxacin 500 mg IV once daily with or without
  - Metronidazole 500 mg IV every 8 hours

Regimen B is preferred for cases with pelvic abscess as it has anaerobic coverage. **Alternative regimen** is dosed once a day

**Indications of surgery:** The indications of surgery are comparatively less. The unequivocal indications are:

- ◆ Generalized peritonitis.
- ◆ Pelvic abscess.
- ◆ Tubo-ovarian abscess which does not respond (48–72 hours) to antimicrobial therapy.

**To prevent reinfection:** The following formalities are to be rigidly followed to prevent reinfection:

- ◆ Educating the patient to avoid reinfection and the potential hazards of it.
- ◆ The patient should be warned against multiple sexual partners.
- ◆ To use condom.
- ◆ The sexual partner or partners are to be traced and properly investigated to find out the organism(s) and treated effectively. If they have got non-gonococcal urethritis, they should be treated with tetracycline 500 mg 6 hourly or doxycycline 100 mg twice daily for 7 days.

## FOLLOW UP

Repeat smears and cultures from the discharge are to be done after 7 days following the full course of treatment. The tests are to be repeated following each menstrual period until it becomes **negative for three consecutive reports when the patient is declared cured**. Until she is cured and her sexual partner(s)

have been treated and cured, the patient must be prohibited from intercourse.

The only unequivocal proof of successful treatment after salpingitis is an intrauterine pregnancy.

## PELVIC INFECTION FOLLOWING DELIVERY AND ABORTION

**The common organisms producing acute infection following delivery** are anaerobic *Streptococcus*, *Staphylococcus pyogenes*, non-hemolytic streptococcus, *E. coli* and *Bacteroides group*. Too often, multiple organisms are present and it is difficult to pinpoint a particular organism responsible for a particular type of infection.

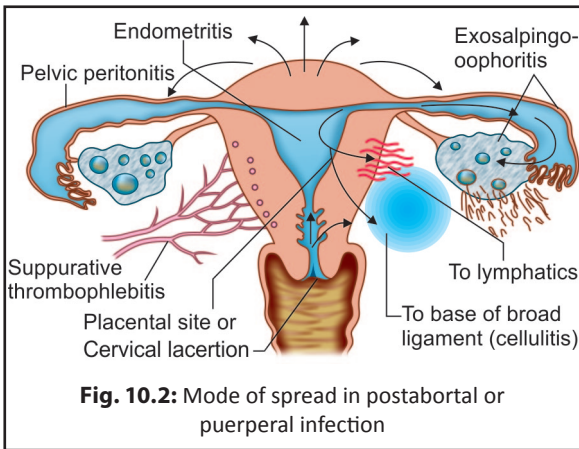
As previously mentioned, the defence is lost following childbirth and abortion. Malnutrition, unhygienic environment during delivery, dehydration and ketoacidosis during labor are the additional factors in underprivileged women. Infections are common following cesarean section. Following abortion, specially when induced criminally, exogenous infection is quite likely and potentially virulent.

### Pathology

The infection is either localized to the cervix, producing acute cervicitis or may affect the placental site producing endometritis. The infection may spread to the myometrium producing endomyometritis which is limited by a leucocytic barrier. On occasion, the infection spreads to the parametrium, usually to one side, through lymphatics or directly through the tear of the cervix; thereby gaining access to the base of the broad ligament. The infection may also spread upwards through the tubal openings into the tubal lumen producing endosalpingitis. **Thus, the fallopian tube is affected** either from outside following parametritis, through lymphatics producing perisalpingitis or through endosalpingitis. The ovary may be affected through involvement of the tube or following pelvic peritonitis. Thus, an acute tubo-ovarian mass is formed (Fig. 10.2).

**Spread of infection:** Depending upon the virulence of the organisms and resistance of the host, the following events may occur.

**The infection is localized** principally to the cervix and subsequently develops into chronic cervicitis. **The parametrial exudate** may resolute completely leaving behind scarring or fibrosis or may undergo suppuration. The abscess so formed usually points above the inguinal ligament. **The tubal affection results in cornual block**, hydro-salpinx or pyosalpinx following blockage of the fimbrial end. **There**



may be peritonitis either localized or at times generalized. In others, the tube may be adherent with the ovary, intestine and omentum producing tubo-ovarian mass, the abdominal ostium usually remaining patent. **The pelvic veins may be involved producing thrombophlebitis**, which is either confined to the pelvis or spreads upwards along the ovarian veins or downwards along the iliofemoral veins. The systemic effect varies from minimal to a fatal one, specially with gram-negative organisms following criminal abortion. **The serious complications include** septic shock, acute renal failure and disseminated intravascular coagulopathy.

### Clinical features

The onset may be acute or insidious and the clinical picture varies widely depending upon the severity and spread of infection. But the **chief complaints** of varying magnitude are fever, lower abdominal and pelvic pain and offensive vaginal discharge following delivery or abortion.

**On examination, the patient looks ill and may be restless.** She likes to lie on her back with the legs flexed. Pulse rate is rapid and is out of proportion to the temperature. Abdominal examination reveals tenderness or even rigidity on lower abdomen.

**Vaginal examination** is painful. The discharge is offensive. The uterus is tender, more with movement of the cervix. The fornices are tender. Depending upon the spread, there may be unilateral or bilateral mass (tubo-ovarian), an unilateral tender indurated mass pushing the uterus to the contralateral side (parametritis) or a bulging fluctuating mass felt through the posterior fornix (pelvic abscess). Rectal examination is useful to corroborate the pelvic findings.

### Complications of Acute PID following Delivery or Abortion

(1) Endotoxic shock. (2) Oliguria or anuria. (3) Disseminated intravascular coagulopathy. These are predominantly due to gram-negative organisms and are too often associated with unsafe abortion. (4) Tubo-ovarian abscess. (5) Peritonitis. (6) Parametritis. (7) Thrombophlebitis—features usually appear 7-10 days following the initial events. (8) Pulmonary embolism.

### TREATMENT

**Prevention:** (1) To maintain asepsis and antiseptic measures during labor. (2) To avoid traumatic and difficult vaginal deliveries. (3) To use prophylactic antibiotic when labor is delayed following rupture of the membranes or when there are intrauterine manipulations like forceps or manual removal of placenta. (4) To encourage family planning acceptance to prevent the unwanted pregnancies.

### Curative

- ◆ **Hospitalization:** The patient may be admitted if clinically indicated (p. 132).
- ◆ **Triple swabs** are to be taken—one from high vagina, one from the endocervix and the third from the urethra. These are to be sent for aerobic and anaerobic culture, drug sensitivity test and Gram stain. **The swabs are to be taken prior to bimanual examination.**
- ◆ Vaginal and rectal examinations are then made to note the extent of pelvic infection.

### Investigations

**ROUTINE:** (a) **Blood** is sent for hemoglobin estimation, total and differential count of white cells, depending on severity of infection blood culture and serum electrolytes are done. (b) Urine analysis including culture.

**Special investigations** are to be done as required: (a) Ultrasonography of abdomen and pelvis to detect physometra or presence of any foreign body left behind in the uterus or in the abdominal cavity used for criminal interference.

### Definitive treatment

- ◆ **Antibiotics:** Pending sensitivity report, potent bactericidal drugs such as gentamicin 2 mg/kg



body weight and clindamycin IV 600 mg daily with IV metronidazole 500 mg are to be administered at every 6–8 hours interval. If the temperature does not subside by 48 hours, the antibiotic should be changed according to microbiology and sensitivity report.

### Supportive therapy

- ◆ Blood transfusion for anemia.
- ◆ Treatment for endotoxic shock, renal failure or disseminated intravascular coagulopathy need intensive care management.

### Indications of surgery in septic abortion are:

(1) Injury to the uterus. (2) Suspected injury to the gut. (3) Presence of foreign body in the abdomen as evidenced by the USG or felt through the fornix on bimanual examination. (4) Unresponsive peritonitis suggestive of collection of pus. (5) Patient's clinical condition not responding to the conservative treatment.

### Active surgery includes:

- ◆ Evacuation of uterus
- ◆ Posterior colpotomy
- ◆ Laparotomy—in a suspected case of acute appendicitis or ruptured tubo-ovarian abscess.

## LATE SEQUELAE OF PID

- ◆ Infertility either due to cornual block, or damage to the wall of the tube.
- ◆ Chronic infection
- ◆ Chronic pelvic pain, dysmenorrhea
- ◆ Pelvic adhesive disease
- ◆ Ectopic pregnancy
- ◆ Residual infection with periodic acute exacerbation.
- ◆ Intestinal obstruction.
- ◆ Chronic ill health.
- ◆ Dyspareunia and marital disharmony.

## PELVIC INFECTION FOLLOWING GYNECOLOGICAL PROCEDURES

Infection of the residual pelvic organs or cellular tissues is not uncommon following hysterectomy,

more in vaginal than abdominal one. It is more common in infected or potentially infected cases than in 'elective' non-infective cases.

**Organisms:** *Escherichia coli* and *Bacteroides fragilis* are the predominant organisms.

**Pathology:** The vaginal cuff may be indurated due to infected hematoma → cellulitis → abscess. The infection may spread to produce pelvic cellulitis, thrombophlebitis or tubo-ovarian mass.

**Clinical features:** Fever and lower abdominal or pelvic pain of varying degrees appear few days (3–4) following surgery.

**Per vaginam:** Discharge is offensive and the vaginal vault is indurated and tender. Speculum examination may reveal exposed vaginal cuff with purulent discharge coming through the gaping vault. Rectal examination reveals induration on the vault or its extension to one side (parametritis). Rarely, a fluctuant mass may be felt (pelvic abscess).

### TREATMENT: Prophylactic

Preoperative cleaning of the vagina with antiseptic lotion, perfect hemostasis during surgery and leaving behind the vault open in infected cases could reduce the postoperative infection. **Chemoprophylaxis** in potentially or actually infected cases using **intravenous metronidazole 500 mg 8 hourly for 3 such and intravenous ceftriaxone 1 g, given during the operation and 1–2 doses after the operation is quite effective to lower the risk of infection.**

**Definitive treatment:** Appropriate antibiotic and drainage of pus through the vault are enough to arrest the infection. However, in parametritis and thrombophlebitis, the response is poor. Adnexal abscess requires urgent exploration and removal of the infected mass.

## IUD AND PELVIC INFECTION

IUD is one of the iatrogenic causes of pelvic infection in gynecology (see ch. 29). All types of IUDs are responsible. The incidence ranges from 2–10 per cent. **The risk is, however, more in nulliparae.** It may flare up pre-existing pelvic infection. IUD tail may be implicated in ascent of the organisms from the vagina in infections long after insertion. The bacteria may be carried from the cervix into the endometrium during insertion. Actinomycosis has been found rarely

in association with the use of copper devices. Risk of PID is highest in the first month after insertion. Again risk of PID is highest when the patient has multiple sexual partners.

As a preventive measure, **it is better not to insert in nulliparae or in cases with previous history of pelvic inflammatory disease.** Insertion should be carried out under strict aseptic condition. Once the pelvic infection occurs, the device should be removed in addition to antibiotic and supportive therapy. Actinomyces responds well with penicillin.

## CHRONIC PELVIC INFECTION

Chronic pelvic infection is a distressing clinical entity not only to the patients but also to the physicians. Its results:

- ◆ Following acute pelvic infection—the initial treatment was delayed or inadequate.
- ◆ Following low grade recurrent infection.
- ◆ Tubercular infection.

The first two types are predominantly due to pyogenic organisms. There is often history of previous acute pelvic infection. Tubercular infection is chronic from the beginning and is described as a separate entity.

### PYOGENIC

#### Pathology

The pathology in the uterus is most often spared because of periodic shedding of the endometrium. The tubal changes are secondary to the changes induced by previous acute salpingitis. The tubal epithelium is usually lost, specially in gonococcal infection; the wall gets thickened with plasma cell infiltration and the openings are blocked. These result in hydrosalpinx, with loss of the lining mucosa with its plicae. The peritoneal surface is involved in recurrent infection producing **either flimsy (gonococcal) or dense (non-gonococcal pyogenic) adhesions.** The tubes are thus kinked and may get adherent to the ovaries, uterus, intestine, omentum and pelvic peritoneum. A tubo-ovarian mass or a frozen pelvis results. The serum and lymphatic exudate in the parametrium of acute

infection coagulates, which later either completely resolves or becomes fibrotic. The fibrosis pulls the uterus, the cervix in particular to the same side.

#### Clinical features

- ◆ The entity may remain asymptomatic.
- ◆ There may be previous history of acute pelvic infection following childbirth or abortion. Recurrent episodes of reinfection is often present. The use of IUCD is highly corroborative.

#### Symptoms

- ◆ Chronic pelvic pain of varying magnitude and the pain aggravates prior to menstruation due to congestion.
- ◆ Dyspareunia, which is deep and may be located unilaterally or bilaterally.
- ◆ Congestive dysmenorrhea.
- ◆ Lower abdominal pain.
- ◆ Menorrhagia or polymenorrhagia are due to congestion.
- ◆ Vaginal discharge is almost a constant manifestation and may be mucoid or mucopurulent.
- ◆ Infertility, which may be primary or more commonly secondary.

**Important factors for infertility are**—cornual block (Fig. 37.69), loss of cilia, loss of peristalsis due to thickening of the tubal wall, closure of the abdominal ostium and distortion of the tube due to peritubal adhesions.

#### On examination

**Per abdomen:** There may be tenderness on one or both iliac fossa. An irregular tender pelvic mass may be felt.

**Per vaginam:** The findings are as mentioned in page 130.

**Rectal examination** corroborates the findings of vaginal examination and should not be omitted (p. 108). The involvement of the parametrium and uterosacral ligaments are better assessed rectally.



## Investigations

- ◆ Blood examination for evidences of leucocytosis, Hb estimation and ESR. Urine examination—routine and, if necessary, culture sensitivity.

**Laparoscopy:** This is helpful to confirm the diagnosis and to know the extent of the lesion specially in cases of infertility. However, in cases where too much adhesions are anticipated, diagnostic laparotomy is a safer substitute.

## Management: • General • Specific • Surgery

### ■ General

- ▶ Improvement of general health and anemia.
- ▶ Analgesics as required, may be prescribed. Pelvic heat application by short wave diathermy is comforting to the patient.

### ■ Specific

- ▶ The IUCD is to be removed, if it is still inside.
- ▶ Antibiotic therapy has got little benefit unless there is recent acute exacerbation. The long-term broad spectrum antibiotics to be administered include doxycycline or tetracycline or cephalosporin for three weeks. In proved cases of gonococcal infection, specific therapy is directed as outlined in acute infection (p. 148).

- **Surgery:** Surgery may be needed either by laparoscopy or by laparotomy in a few selected cases.

## Indications:

- **Persistence** of symptoms in spite of adequate conservative treatment.
- **Recurrence** of acute attacks.
- **Increase in size** of the pelvic mass despite treatment.
- **Infertility** for restorative tubal surgery or for adhesiolysis.

**Nature of surgery:** Due consideration should be given to age, parity and extent of the lesion.

**Laparoscopic** adhesiolysis, tubal restorative and reconstructive surgery are commonly done. Few cases may need salpingectomy or salpingo-oophorectomy.

*In general, the ideal surgery should be total hysterectomy with bilateral salpingo-oophorectomy for women that they have completed their family.*

## GENITAL TUBERCULOSIS

### INCIDENCE

The incidence of genital tuberculosis varies widely with the social status of the patient and her environment. The incidence is about 1 per cent amongst the gynecological patients attending the outpatient department in the developing countries. Incidence is high (5–10%) amongst the patients with infertility. With the prevalence of HIV infection incidence of genital tuberculosis is rising. About 10 per cent of women with pelvic tuberculosis, have urinary tract tuberculosis.

### PATHOGENESIS

The causative organism is *Mycobacterium tuberculosis* of human type. Very rarely the bovine type may affect the vulva. **Genital tuberculosis is almost always secondary to primary infection** elsewhere in the extragenital sites such as lungs (50%), lymph nodes, urinary tract, bones and joints. **The fallopian tubes are invariably the primary sites** of pelvic tuberculosis from where secondary spread occurs to other genital organs.

### MODE OF SPREAD

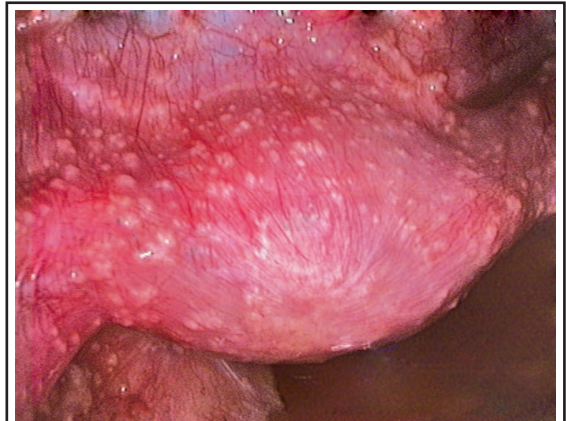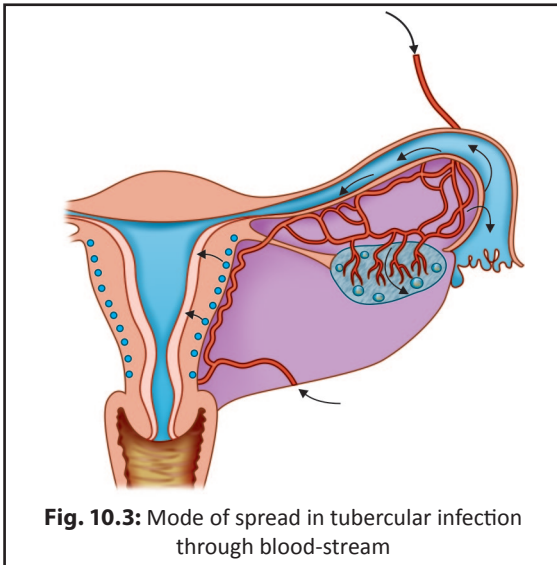
**Hematogenous:** From any of the primary sites, the pelvic organs are involved by hematogenous spread in about 90 per cent cases. If the post-primary hematogenous spread coincides with the growth spurt of the pelvic vessels, the genital organs, the tubes in particular, are likely to be affected. Thus, the pelvic organs are infected during puberty. If the spread precedes the growth phase, the genital organs are spared. The infection remains dormant for a variable period of time (4–6 years) until clinical manifestations appear (Fig. 10.3).

**Lymphatic or direct:** The pelvic organs are involved directly or by lymphatics from the infected organs such as peritoneum, bowel or mesenteric nodes.

**Ascending:** Although difficult to prove but sexual transmission from a male with urogenital tuberculosis is possible in vulval, vaginal or cervical lesion.

### PATHOLOGY OF PELVIC ORGANS

**Fallopian tube:** **The commonest site of affection is the fallopian tubes (100%). Both the tubes are**



**affected simultaneously. The initial site of infection** is in the submucosal layer (interstitial salpingitis) of the ampullary part of the tube.

The infection may spread medially along the wall causing destruction of the muscles which are replaced by fibrous tissue. The walls get thickened, become calcified or even ossified. The thickening may at time become segmented. The infection may spread inwards; the mucosa gets swollen and destroyed. The fimbria are everted and **the abdominal ostium usually remains patent**. The elongated and distended distal tube with the patent abdominal ostium gives the appearance of **“tobacco-pouch”**. Occlusion of the ostium may however occur due to adhesions. The tubercles burst pouring the caseous material inside the lumen producing tubercular pyosalpinx, which may adhere to the ovaries and the surrounding structures. Often the infection spreads outwards producing perisalpingitis with exudation, causing dense adhesions with the surrounding structures—tubercular tubo-ovarian mass. Rarely, miliary tubercles may be found on the serosal surface of the tubes, uterus, peritoneum or intestines. These are often associated with tubercular peritonitis (Fig. 10.4).

However, not infrequently the tubes may look absolutely normal or nodular at places. If the nodules happen to be present in the isthmus near the uterine cornu, it constitutes salpingitis isthmica nodosa.

**Salpingitis isthmica nodosa** is the nodular thickening of the tube due to proliferation of tubal epithelium within the hypertrophied myosalpinx (muscle layer). Exact aetiology is unknown. It is diagnosed radiologically as a small diverticulum (Fig. 10.7). It is however not specific to tubercular infection only (see p. 172). It is also observed in pelvic endometriosis.

**Uterus: The endometrium is involved in 60 per cent of cases. The infection is from** the tubes either by lymphatics or by direct spread through continuity. Cornual ends are commonly affected due to their dual blood supply, as well as their anatomical proximity to tubes. The tubercle is situated in the basal layer of the endometrium only to come to the surface premenstrually. After the endometrium is shed at each menstruation, reinfection occurs from the lesions in the basal layer or from the tubes. Endometrial ulceration may lead to **adhesion or synechiae formation (Asherman’s syndrome)**. This may cause infertility, secondary amenorrhoea or recurrent abortion (p. 459). Rarely, the infection spreads to the myometrium (2.5%) and if caseation occurs, a pyometra results, specially in postmenopausal women.

**Cervix: The cervical affection is not so uncommon (5–15%).** Primary infection of the cervix by sexual intercourse though rare, has been recorded. It may be ulcerative or may be bright nodular in type. Both

may bleed to touch, thereby causing confusion with carcinoma. Histologically genital tuberculosis is associated with marked epithelial hyperplasia with some degree of atypia. This may lead to erroneous diagnosis of carcinoma (Fig. 10.8).

**Vulva and vagina:** The affection of these sites is **very rare (1%)**. The lesion may be ulcerative with undermined edges. Rarely the lesions may be of hypertrophic variety. The diagnosis is made only by histology.

**Ovary:** The ovaries are involved in **about 30 per cent of tubercular salpingitis**. The manifestation may be surface tubercles, adhesions, thickening of the capsule or even caseating abscess in the substance of the ovary.

### PELVIC PERITONEUM

**Pelvic peritonitis is present in about 40–50 per cent of cases.** Tuberculous peritonitis may be ‘wet’ (exudative type) or ‘dry’ (adhesive type).

In the ‘**wet**’ variety there is ascites with straw colored fluid in the peritoneal cavity. The parietal and visceral peritoneum are covered with numerous small tubercles (Fig. 10.4).

In the ‘**dry**’ variety there is dense adhesion with bowel loops. The adhesion is due to fibrosis when the ‘wet’ variety heals.

### Microscopic appearance of the lesion

Microscopic picture of the lesion is very characteristic irrespective of the organ involved. **Typical granuloma consists of infiltration of multinucleated giant cells (Langhans), chronic inflammatory cells and epithelioid cells, surrounding a central area of caseation necrosis (Fig. 10.5)**. Caseation may not be a constant feature.

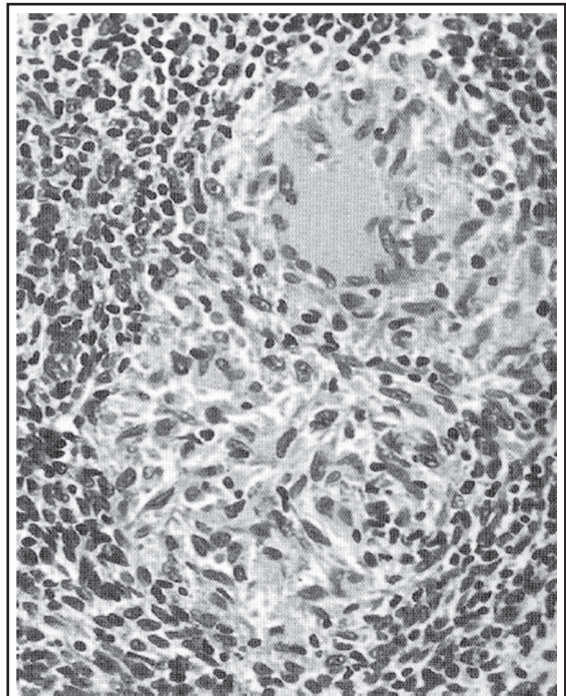
### CLINICAL FEATURES

**Patient profile:** The infection is restricted mostly (80%) to childbearing period (20–40 years). There may be past history of tubercular affection of the lungs or lymph glands. **Genital tuberculosis occurs in 10–20 per cent of patients who have pulmonary tuberculosis in adolescence.** A family history of contact may be available. Onset is mostly insidious. A flare up of the infection may occur acutely either spontaneously or following diagnostic endometrial curettage or hysterosalpingography.

**Symptoms:** Symptoms vary considerably with the severity and stage of the disease. At one extreme, there is neither any symptom nor any palpable pelvic pathology. **Sometimes symptoms like** weakness, low grade fever, anorexia, anemia or night sweats may be present. The lesion is accidentally diagnosed during investigation for infertility or dysfunctional uterine bleeding. These cases are often designated as “silent tuberculosis”. **In others, the clinical manifestations appear.** These are:

**Infertility:** It may be primary or secondary and is present in about 70–80 per cent cases of pelvic tuberculosis. In India, about 10 per cent infertile women have got genital tuberculosis. The causes are predominantly due to tubal blockage, adhesions in the endometrial cavity (uterine synechiae) or associated ovulatory dysfunction.

**Menstrual abnormality:** In about 50 per cent, the menstrual function is normal.



**Fig. 10.5:** A typical tubercular granuloma formed by lymphocytes, epithelioid cells and Langhans giant cells. Central area of caseation necrosis is seen

**The menstrual abnormalities include:**

- ▶ Menorrhagia or irregular bleeding is probably due to ovarian involvement, pelvic congestion or endometrial proliferative lesion. It is the early manifestation. These patients fail to respond with hormone therapy. Endometrial tuberculosis is a rare cause of puberty menorrhagia and postmenopausal bleeding.
- ▶ Amenorrhoea or oligomenorrhoea: Secondary amenorrhoea is more common and may be the only presenting symptom that makes the patient seek medical advice. It may be due to suppression of the ovarian function probably by tubercular toxin (oophoritis). Else it may be result of endometrial destruction and uterine synechiae formation. It may be due to general debility also. As such, it is a late manifestation.

**Others: Chronic pelvic pain** is present in about 20–30 percent cases. It is often associated with tuboovarian mass and may be precipitated by tubal patency test. Secondary infection may aggravate the chronic pain to an acute one. **Vaginal discharge**—cervical or vaginal tuberculosis may be associated with postcoital bleeding or blood stained discharge. **Constitutional symptoms** such as loss of weight, malaise, anorexia, pyrexia and anaemia are present in the acute phase of the disease.

**SIGNS**

**Health status:** The general health usually remains unaffected. There may be constitutional symptoms like weakness, low grade fever, anorexia, anemia and night sweats. There may be evidences of active or healed extra-genital tubercular lesion.

**Per abdomen:** Abdominal findings may be negative or rarely one may find an irregular tender mass in lower abdomen arising out of the pelvis. Abdomen may **feel doughy due to matted intestines**. Evidences of free peritoneal fluid are rare. **Tubercular ascites when encysted mimics an ovarian cyst**.

**Per vaginam:** The pelvic findings may be negative in 50 per cent cases. Vulval or vaginal ulcer presents with undermined edges. There may be thickening of the tubes which are felt through the lateral fornices or nodules, felt through posterior fornix. At times, there is bilateral pelvic mass of varying sizes quite

indistinguishable from that due to pyogenic infection. Per rectum, one may confirm the vaginal findings.

**INVESTIGATIONS**

The aims of investigations are:

- ◆ To identify the primary lesion.
- ◆ To confirm the genital lesion.

**Blood:** The leucocyte count and ESR values may be raised. Periodic examination is of value to evaluate the progress of the lesion.

**Mantoux test:** Positive test with high dilution is suggestive that the patient is sensitized to tuberculo-protein. A negative test excludes tuberculosis.

**Chest X-ray** is taken for evidence of healed or active pulmonary lesion.

**Diagnostic uterine curettage:** This is to be done during the week preceding menstruation. The tubercles are likely to come to the surface during this period. **The material should be sent to the laboratory in two portions.**

- a. One part in formol-saline for histopathological examination to detect the giant cell system. Histology could detect tuberculosis in about 10 per cent of cases only. False-positive histology may be due to the presence of chronic lesions (like talc or catgut granuloma) or sarcoidosis. False-negative result is due to improper timing of uterine curettage or due to less incidence of uterine infection.
- b. One part in normal saline for:
  - i. Culture in Löwenstein-Jensen media.
  - ii. Identification of the acid-fast bacilli by Ziehl-Neelsen's stain (AFB-Microscopy).
  - iii. Nucleic acid amplification.
  - iv. Guineapig inoculation.

A positive culture is suggestive while a positive guineapig inoculation test is diagnostic. Bacteriological test, if positive, should be able to type the bacilli and report on their drug sensitivity.

**Nucleic acid amplification (16S ribosomal DNA)** techniques with Polymerase Chain Reaction (PCR), **can identify *M. tuberculosis* from endometrium or menstrual blood (clinical specimens)**. PCR is more sensitive (85–95%) than microscopy and bacterio-

logical culture. **This method can detect fewer than 10 organisms in clinical specimens compared to 10,000 necessary for smear positivity. Genital TB is usually paucibacillary.**

**First day menstrual discharge:** This is to be collected by a pipette and the material subjected to **mycobacterial** nucleic acid amplification, culture and guineapig inoculation. **It should be emphasized that while a positive report on AFB-microscopy, PCR, culture and histology gives the diagnosis, a negative report does not rule out tuberculosis.**

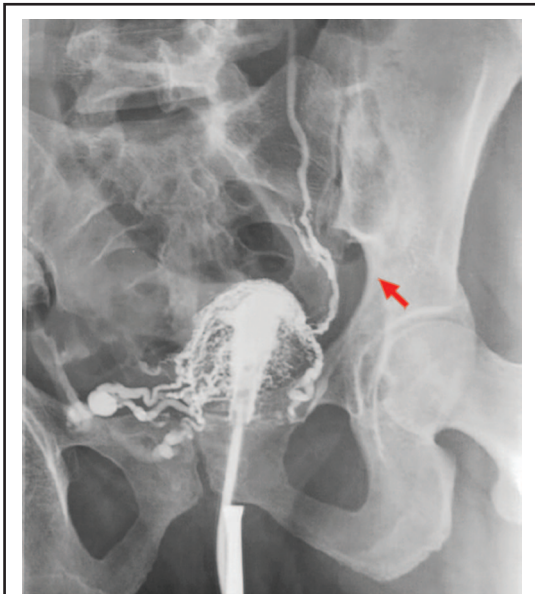
**Sputum and urine** are to be cultured for tubercle bacillus.

**Lymph node biopsy** is to be done, specially from the neck in lymphadenitis.

**Biopsy** from the lesion in cervix, vagina or vulva.

**Hysterosalpingography (HSG):** In a proved case, HSG is contraindicated for the risk of reactivation of the lesion. HSG done as a routine work up in the investigation of infertility may reveal the following suggestive features:

- ◆ Vascular or lymphatic extravasation of dye (Fig. 10.6).



**Fig. 10.6:** Hysterosalpingogram showing marked extravasation of dye in venous and lymphatic channels. It was proved to be a case of tubercular endometritis [By courtesy Dr. H. Roy, Patna]

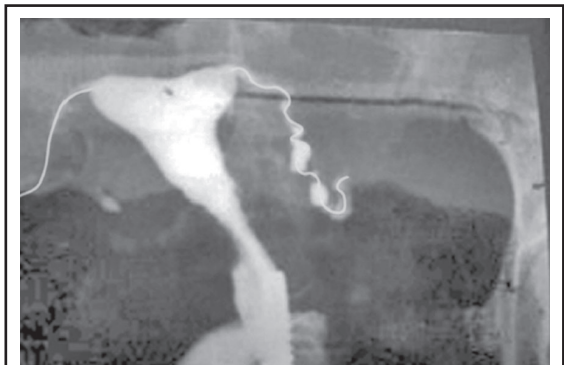- ◆ Rigid (lead-pipe) tubes with nodulations at places.
- ◆ ‘Tobacco pouch’ appearance with blocked fimbrial end (Fig. 10.4).
- ◆ Beaded appearance of the tube with variable filling density (Fig. 10.7).
- ◆ Distal tube obstruction.
- ◆ Coiling of the tubes or calcified shadow at places.
- ◆ Bilateral cornual block (Fig. 37.69).
- ◆ Tubal diverticula and/or fluffiness of tubal outline.
- ◆ Uterine cavity—irregular outline, honeycomb appearance or presence of uterine synechiae.

**Imaging:** Abdominal and pelvic ultrasound, CT or MRI is helpful where a mass and/or ascites is present. However, it cannot confirm the diagnosis.

**Laparoscopy:** In the absence of endometrial evidence, one may take the advantage of laparoscope for identification of tubercles in the pelvic organs or characteristic segmented nodular appearance of the tubes. Biopsy may be taken from peritoneal tubercles for histology. Aspiration of fluid is done for culture. This may be accidentally discovered during diagnostic laparoscopy for infertility work up or for chronic pelvic pain.

## DIAGNOSIS

Considering the high prevalence of extragenital tuberculosis, pulmonary in particular, the physicians of the Third World Countries should look out for



**Fig. 10.7:** Hysterosalpingogram showing beaded appearance of the tube with variable filling density. Pelvic tuberculosis was later confirmed

(By courtesy: Dr P Panigrahi, Consultant Gynecologist, JLN Hospital, Bhilai)

the presence of genital tuberculosis. For this, **the following guidelines may be prescribed:**

- The physician should be conscious of the entity.
- One should suspect and exclude genital tuberculosis in the following conditions:
  - ◆ Unexplained infertility or amenorrhea.
  - ◆ Recurrent episodes of pelvic infections, not responding with usual course of antibiotics.
- Presence of pelvic mass with nodules in the pouch of Douglas.

**Differential diagnosis:** The pelvic mass is often confused with: (i) Pyogenic tubo-ovarian mass. (ii) Pelvic endometriosis. (iii) Adherent ovarian cyst. (iv) Chronic disturbed ectopic pregnancy.

**TREATMENT: | General | Chemotherapy | Surgery**

**General:** In the presence of active pulmonary tuberculosis, hospital admission is preferred. Otherwise, pelvic tuberculosis *per se* need not require hospitalization or bed rest except in acute exacerbation.

To improve the body resistance, due attention is to be paid as regards diet and to correct anemia. Until the infection is controlled, the husband should use condom during intercourse to prevent possibility of contracting urogenital tuberculosis.

**Chemotherapy:** Antitubercular chemotherapy is the treatment of first choice.

**Initial phase:** Four drugs are used for 2 months to reduce the bacterial population and to prevent emergence of drug-resistance. The drugs used are isoniazid, rifampicin, pyrazinamide and ethambutol. Ethambutol is essential to those who have been treated previously or are immunocompromised (HIV positive individual).

**Continuation phase:** Treatment is continued for a period of further 4 months with isoniazid and rifampicin.

This standard regimen may be used **during pregnancy and lactation (Table 10.7).**

After about a year of treatment, diagnostic endometrial curettage is to be done. If the histological and/or bacteriological examination becomes posi-

**TABLE 10.7 ANTITUBERCULAR CHEMOTHERAPY FOR INITIAL TREATMENT**

Drug	Daily oral dosage (adult)	Nature	Toxicity	Comments
Isoniazid	5 mg/kg: max. 300 mg	Bactericidal	Hepatitis, Peripheral neuropathy	<ul style="list-style-type: none"> <li>• Check liver function</li> <li>• Combine pyridoxin 50 mg daily</li> </ul>
Rifampicin	10 mg/kg: max. 600 mg.	Bactericidal	Hepatic dysfunction, orange discolouration of urine. Febrile reaction	<ul style="list-style-type: none"> <li>• Drug interaction (p. 487)</li> <li>• Oral contraceptives to be avoided (p. 487)</li> <li>• Monitor Liver enzymes (AST)</li> </ul>
Pyrazinamide	20–25 mg/kg: max. 2 gm	Bactericidal	Hepatitis, Hyperuricemia, GI upset and Arthralgia	<ul style="list-style-type: none"> <li>• Active against intracellular dividing forms of <i>Mycobacterium</i>.</li> <li>• Monitor (AST)</li> </ul>
Ethambutol	15–20 mg/kg: max. 2.5 gm.	Bacteriostatic	Visual disturbances, Optic neuritis, Loss of visual acuity.	<ul style="list-style-type: none"> <li>• Ophthalmoscopic examination prior to therapy.</li> </ul>

Intermittent dose schedule is also recommended. Treatment should be supervised by the DOTS provider. Revised National TB Control Program (RNTCP) 1993 and Directly Observed Treatment by Short Course Chemotherapy (DOTS).

- ◆ Isoniazid: 15 mg/kg, 3 times a week for 6 months.
- ◆ Rifampicin: 600 mg, 3 times a week for 6 months.
- ◆ Pyrazinamide: 30 mg/kg, 3 times a week for first 2 months only.
- ◆ Ethambutol: 30 mg/kg, 3 times a week for first 2 months only.



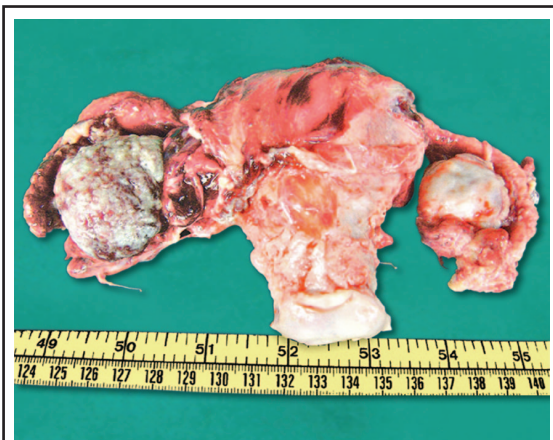
tive, the treatment must be continued further. If these are negative, the endometrium is examined at interval of 6 months. **A patient may be considered cured**, if at least two reports including histological and bacteriological examination become negative. Majority of the patients (90–95 %) respond well to chemotherapy.

**Multidrug resistant (MDR) tuberculosis** is defined as infection with *M. tuberculosis* that is resistant to two or more agents including isoniazid. HIV negative patients who are MDR have high mortality rate (80%). Such patients are treated with five drug regimens (CDC).

**Surgery—Indications:** (i) Unresponsiveness of active disease in spite of adequate anti-tubercular chemotherapy. (ii) Tubercular pyosalpinx, ovarian abscess or pyometra (iii) Persistent menorrhagia and/or chronic pelvic pain causing deteriorating health status.

**Contraindications:** (i) Presence of active tuberculosis in extragenital site. (ii) Favorable response to antimicrobial therapy with diminishing size of the pelvic mass. (iii) Accidental discovery of tubercular tubo-ovarian mass on laparotomy in young patient. The abdomen is to be closed after taking tissue for biopsy.

**Precautions:** Antitubercular drug therapy in full dosage should be instituted at least 6 weeks prior to surgery and similar treatment should be continued following surgery.



**Fig. 10.8:** Bilateral tubo-ovarian mass (calcification on the right) due to genital tuberculosis. TAH with BSO done following antitubercular drug therapy

**Type of surgery:** The ideal surgery should be total hysterectomy with bilateral salpingo-oophorectomy. In young women at least one ovary, if found apparently healthy, should be preserved. Isolated excision of tubo-ovarian mass, drainage of pyometra or repair of fistula may be done in selected cases.

### Results of Treatment

In terms of future reproduction, the prognosis is most unfavorable. Pregnancy is rare (5–10 %), and if occurs, chance of ectopic pregnancy is more (40 %). In uterine pregnancy, abortion is likely and a pregnancy going upto term is a rare event.

With the help of assisted reproductive technology (ART) higher pregnancy rate is observed following successful chemotherapy.

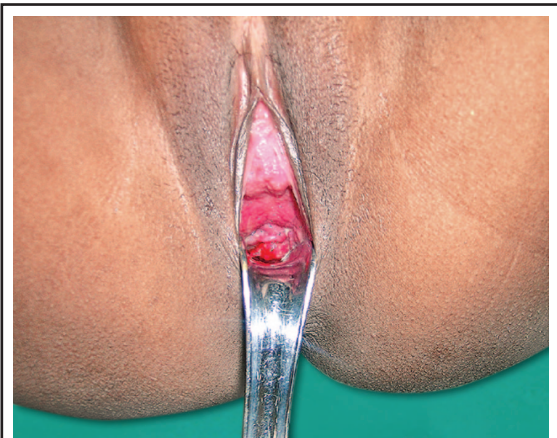

## VULVAL TUBERCULOSIS

The patient complains of a painful and tender ulcer in the vulva. Confirmation is done by biopsy. The medical treatment is the same as that outlined in pelvic tuberculosis. In unresponsive cases, local vulvectomy is to be done.

## CERVICAL TUBERCULOSIS

The presenting complaints are mucopurulent discharge and postcoital bleeding. Cervical tuberculosis



**Fig. 10.9:** Tubercular cervix proved by biopsy. The clinical diagnosis was confused with malignancy. [By courtesy: Dr. H. Roy, Patna]

on speculum examination (Fig. 10.9) appears as an ulcerated or hypertrophic growth which bleeds on touch.

**Cervical cytology:** may reveal multinucleated giant cells, epithelioid cells and dyskaryotic cells. **Biopsy** confirms the diagnosis. Antitubercular drug therapy as outlined in pelvic tuberculosis is prescribed (Table 10.7). In unresponsive cases, hysterectomy is justified.

**Chronic PID:** The term chronic pelvic inflammatory disease has largely been abandoned. The long-term sequelae of acute PID such as adhesions or hydrosalpinx are bacteriologically sterile.

True chronic PID such as **genital tuberculosis and actinomycosis** is less although the former is not infrequent in the developing countries.

## ACTINOMYCES INFECTION

It is a rare cause of upper genital tract infection. Infection is caused by *Actinomyces israelii*, a gram-positive anaerobe. It may be associated in IUCD users more with noncopper devices. Actinomyces causes chronic endometritis. There may be foul smelling vaginal discharge. **The diagnosis is usually made from tubo-ovarian abscess when the classic “Sulphergranules” are observed histologically along with gram positive filaments.** Presence of symptoms like fever, abdominal pain, abnormal uterine bleeding may necessitate the removal of IUCD. It is sensitive to penicillin, doxycycline or fluoroquinolones. **The treatment** should be continued for 12 weeks. Following the course of antibiotic treatment, Pap smear is repeated after 3 months.

## KEY POINTS

- ▶ The vaginal defence is lost following 10 days of birth till puberty, in reproductive period-during menstruation, following abortion and childbirth and following menopause.
- ▶ Pelvic inflammatory disease according to anatomic location may be in the endometrium (endometritis), the oviducts (salpingitis), the ovary (oophoritis), the myometrium (myometritis), uterine serosa and broad ligaments (parametritis) and the peritoneum (pelvic peritonitis).
- ▶ The primary organisms of PID are predominantly sexually transmitted. Acute PID is polymicrobial in nature. As the symptoms of PID are nonspecific, over treatment is preferred to missed diagnosis.
- ▶ Clinical diagnostic criteria for acute PID includes : Minimum and Additional (routine and definitive) criteria (see p. 130).

Laparoscopy is the optimum method for accurately diagnosing acute PID.

- ▶ Gonococcal affection of the tubes is by direct spread from downstairs to upstairs across the mucosal surface of the endometrium, reflux of the menstrual flow with gonococci into the tubes and carried along the spermatozoa or the trichomonads. The pathological process is initiated primarily in the endosalpinx.

For detection of Gonococcus, the materials are collected from the urethra or Bartholin's duct, cervical smear and laparoscopic collection of pus from the uterine tube. Acute gonorrhoea is treated by drugs (Table 11.2 on p. 148) to both the partners.

In acute condition, the diagnosis is confused with acute appendicitis and disturbed ectopic pregnancy.

Immediate complications include pelvic peritonitis and septicemia and late complications include infertility, chronic pelvic pain and chronic ill-health.

Repeat smears and cultures from the discharge are to be done following each menstrual period until it becomes negative for 3 consecutive reports when the patient is declared cured.

Contd...

Contd...

- *Chlamydia trachomatis* — a gram-negative obligatory intracellular bacteria, is now the commonest organism proved to be sexually transmitted from the non-gonococcal urethritis in male consort. The clinical picture is almost the same to that of gonococcal infection but is milder in nature. Perihepatic inflammation (Fitz-Hugh-Curtis syndrome) is observed in 5–10 percent women with acute PID.

The late sequelae include tubal obstruction, infertility, early abortion and ectopic pregnancy.

Detection can be done by tissue culture. The specific antibody can be detected by immunofluorescent test or complement fixation test. Chlamydial nucleic acid amplification and detection by PCR is a very sensitive and specific test. The organism is sensitive to azithromycin, erythromycin or ofloxacin. The same treatment is to be given to the sexual partner.

- The commonest organisms producing acute infection following delivery and abortion are anaerobic *Streptococcus*, *Staphylococcus pyogenes*, *Esch. coli* and *Bacteroides* groups.
- The fallopian tube is affected either following parametritis through the lymphatics producing perisalpingitis or through endosalpingitis. Tubal affection to cause infertility depends on the severity and number of episodes of the disease.
- Triple swabs are to be taken prior to bimanual examination; one from the high vagina, one from the endocervix and the third from the urethra. These are to be sent for aerobic and anaerobic culture, gram stain and drug sensitivity.
- Clinical diagnostic criteria of PID (CDC-2006) include minimum and additional ones (p. 130). Diagnostic laparoscopy is considered the gold standard (p. 130). Women may be given antibiotic therapy either as an outpatient (Table 10.4) or as an inpatient (Table 10.6) depending on her evaluation (Table 10.5).
- Few patients need surgical management (pelvic abscess, tubo-ovarian abscess) with laparotomy, posterior colpotomy or laparoscopy.
- IUD may produce pelvic infection (2–10 %). The chance is more in nullipara. The highest risk is in the first month after insertion. Bacteria ascends along the nylon threads. Actinomycosis is often implicated.
- Combined oral contraceptive use offers some protection against PID causing thick cervical mucus and decrease in duration of menstrual flow. Contact tracing and treatment of sexual partner should be a routine for effective treatment of PID.
- The incidence of genital tuberculosis is about 1 per cent amongst the gynecological patient. The pelvic organs are affected secondarily, the primary site is predominantly in lung. The spread is by hematogenous route. Fallopian tube is almost always (100%) affected by interstitial salpingitis, endometrium in 60 per cent and cervix in 15 per cent cases. Infertility is present in 70 per cent. About 10 per cent of the infertile couple have got genital tuberculosis.

Although menorrhagia may be the early symptom but more commonly, the patient presents with oligomenorrhea or amenorrhea. The diagnosis is confirmed by histological examination, culture in Löwenstein-Jensen media and guinea pig inoculation and identification of the bacteria by Ziehl-Neelsen's stain from the uterine curettage materials. PCR is more sensitive (p. 141).

- The suggestive features of HSG are extravasation of dye, rigid tubes with nodulation at places and tobacco-pouch appearance (p. 138). The result in terms of fertility following treatment (Table 10.7) is unsatisfactory. Pregnancy is rare and if occurs, risk of ectopic pregnancy is more. In uterine pregnancy, abortion is likely and a pregnancy upto term is a rarity.
- Complications of PID may be — (a) immediate (pelvic peritonitis) or (b) Late (infertility, pelvic pain, dyspareunia, ectopic pregnancy) (p. 132, 135).

# Sexually Transmitted Infections

## INTRODUCTION

**Sexually transmitted infections (STIs) include** those infections, which are predominantly transmitted through sexual contact from an infected partner. Although the transmission of the infections is mostly

due to sexual contact, other modes of transmission include placental (HIV, syphilis), by blood transfusion or infected needles (HIV, hepatitis B or syphilis), or by inoculation into the infant's mucosa when it passes through the birth canal (gonococcal, chlamydial, or herpes). Gynecological morbidities associated with

**TABLE 11.1** SEXUALLY TRANSMITTED INFECTIONS (STIs)

Disease	Agent	Prevention of STIs and RTIs
Gonorrhoea Non-gonococcal urethritis Syphilis Lymphogranuloma venereum Chancroid Granuloma inguinale Non-specific vaginitis Mycoplasma infection	<p>♦ <b>Bacterial</b></p> <p><i>Neisseria gonorrhoeae</i> <i>Chlamydia trachomatis</i> (D-K serotypes) <i>Treponema pallidum</i> <i>Chlamydia trachomatis</i> (L serotypes) <i>Hemophilus ducreyi</i> <i>Donovania granulomatis</i> <i>Hemophilus vaginalis</i> <i>Mycoplasma hominis</i></p>	<p>▲ <b>Safe sex as STIs are entirely preventable.</b></p> <p>■ <b>Use of barrier contraception:</b> Condom, diaphragm, spermicides.</p>
AIDS  Genital herpes Condyloma acuminata Molluscum contagiosum Viral hepatitis CIN	<p>♦ <b>Viral</b></p> <p><i>Human immunodeficiency virus</i> (HIV 1 or HIV 2) <i>Herpes simplex virus</i> (HSV 2) <i>Human papilloma virus</i> (HPV) HPV – 16, 18 or 31 <i>Pox virus</i> <i>Hepatitis B and C virus</i></p>	<p>■ <b>Reducing</b> the number of sexual partners — monogamous relationship reduces the risk of STIs and RTIs.</p> <p>■ <b>Contact tracing</b> and effective treatment.</p>
Bacterial vaginosis (BV) Trichomonas vaginitis	<p>♦ <b>Protozoal</b></p> <p><i>Gardnerella vaginalis</i> <i>Trichomonas vaginalis</i></p>	<p>■ <b>Screening</b> in asymptomatic or symptomatic cases for STIs and RTIs.</p>
Monilial vaginitis	<p>♦ <b>Fungal</b></p> <p><i>Candida albicans</i></p>	
Scabies Pediculosis pubis	<p>♦ <b>Ectoparasites</b></p> <p><i>Sarcoptes scabiei</i> Crab louse (<i>Phthirus pubis</i>)</p>	<p>■ <b>Aseptic procedures</b> in delivery, MTP procedures and IUCD insertion.</p>

sexually transmitted diseases (STIs) are high. Chronic pelvic infection, pain, infertility, ectopic pregnancy, vulval, and cervical neoplasia are the long-term sequelae.

Transplacental infection (during pregnancy) to the fetus results in high perinatal morbidity and mortality. **There is rising trend of STIs throughout the globe.** With the improvement of diagnostic methods and increased interest on STIs, more and more diseases are included mostly of viral origin (HIV, hepatitis B and C, HPV).

The reasons for increasing incidence are:

- Rising prevalence of viral infections like HIV, hepatitis B and C.
- Increased use of ‘Pill’ and IUCD which cannot prevent STI and there is an increased promiscuity and permissiveness.
- Lack of sex education and inadequate practice of safer sex.
- Increased rate of overseas travel.
- Increased detection due to heightened awareness.

Important sexually transmitted diseases are grouped in Table 11.1.

## GONORRHEA

Gonorrhea still remains an important health problem. The causative organism is *Neisseria gonorrhoeae* — a Gram-negative diplococcus. The incubation period is 3–7 days.

The principal site of invasion is the columnar and transitional epithelium of the genitourinary tract. As such, **the primary sites of infection are** endocervix, urethra, Skene’s gland, and Bartholin’s gland. The organism may be localized in the lower genital tract to produce urethritis, Bartholinitis, or cervicitis. Other sites of infection are oropharynx anorectal region, and conjunctiva. As squamous epithelium is resistant to gonococcal invasion, vaginitis in adult is not possible, but vulvovaginitis is possible in childhood. In about 15 percent of untreated cervicitis, gonococcal infection may ascend up to produce acute pelvic inflammatory disease (PID). Rarely, it may produce septicemia with distant involvement to cause tenosynovitis and septic

arthritis. Upper genital organs are involved as the infection spreads along the spermatozoa. Gonococci attach to the spermatozoa and are being carried up. Endometritis and salpingitis are common (see p. 129).

**It should be remembered that *N. gonorrhoeae* is often present with other sexually transmitted diseases and women with gonorrhoea are considered to be at risk for incubating syphilis. One-third of such cases are associated with chlamydial infection.**

## CLINICAL FEATURES IN ADULT

About 50 percent of patients with gonorrhoea are asymptomatic and even when the symptoms are present, they are non-specific. The clinical features of acute gonococcal infection are described as follows:

- ♦ Local.
- ♦ Distant or metastatic.
- ♦ PID (Chapter 10, p. 127).

### Local

#### Symptoms

- Urinary symptoms such as dysuria (25%)
- Excessive irritant vaginal discharge (50%)
- Acute unilateral pain and swelling over the labia due to involvement of Bartholin’s gland
- There may be rectal discomfort due to associated proctitis from genital contamination
- **Others:** Pharyngeal infection, intermenstrual bleeding.

#### Signs

- Labia may be swollen and look inflamed
- The vaginal discharge is mucopurulent
- The external urethral meatus and the openings of the Bartholin’s ducts look congested. On squeezing the urethra and giving pressure on the Bartholin’s glands, purulent exudate escapes out through the openings. Bartholin’s gland may be palpably enlarged, tender with fluctuation, suggestive of formation of abscess.
- Speculum examination reveals congested ectocervix with increased mucopurulent cervical secretions escaping out through the external os.

### Distant or Metastatic

There may be features of perihepatitis and septicemia. Perihepatitis results from spread of infection to the liver capsule. There is formation of adhesions with the abdominal wall. This is not infrequently (5–10%) associated with acute PID.

Septicemia is characterized by low grade fever, polyarthralgia, tenosynovitis, septic arthritis, perihepatitis, meningitis, endocarditis, and skin rash.

**COMPLICATIONS** — Acute pelvic inflammation leads to chronic pelvic inflammatory disease, unless adequately treated. Infertility, ectopic pregnancy (due to tubal damage), dyspareunia, chronic pelvic pain, tubo-ovarian mass, and Bartholin's gland abscess are commonly seen.

### DIAGNOSIS

Nucleic acid amplification testing (NAAT) of urine or endocervical discharge is done. First void morning urine sample (preferred) or at least one hour since the last void sample should be tested. **NAAT is very sensitive and specific (95%).**

In the acute phase, secretions from the urethra, Bartholin's gland, and endocervix are collected for Gram stain and culture.

A presumptive diagnosis is made following detection of Gram-negative intracellular diplococci on staining. Culture of the discharge in Thayer-Martin medium further confirms the diagnosis. Drug sensitivity test is also to be performed.

### TREATMENT

#### Preventive

- ◆ Adequate therapy for gonococcal infection and meticulous follow up are to be done till the patient is declared cured.
- ◆ To treat adequately the male sexual partner simultaneously.
- ◆ To avoid multiple sex partners.
- ◆ To use condom till both the sexual partners are free from disease.

**Curative:** The specific treatment for gonorrhoea is **single dose regimen** of any one of the following drugs (Table 11.2).

TABLE 11.2

#### RECOMMENDED DRUGS IN ACUTE GONORRHEA (CDC 2006)

• Ceftriaxone	— 125 mg IM
• Ciprofloxacin	— 500 mg PO
• Ofloxacin	— 400 mg PO
• Cefixime	— 400 mg PO
• Levofloxacin	— 250 mg PO

Conjunctivitis of the newborn should be treated with a single dose of ceftriaxone (20–30 mg/kg) IM and gentamicin eye ointment (1%).

It should be borne in mind that the patient with gonorrhoea must be suspected of having syphilis or chlamydial infection. As such, treatment should cover all the three.

### FOLLOW UP

Cultures should be made 7 days after the therapy. Repeat cultures are made at monthly intervals following menses for three months. **If the reports are persistently negative, the patient is declared cured.**

### SYPHILIS

Syphilis is caused by the anaerobic spirocheta *Treponema pallidum*. Syphilitic lesion of the genital tract is acquired by direct contact with another person who has open primary or secondary syphilitic lesion. Transmission occurs through the abraded skin or mucosal surface.

### CLINICAL FEATURES

The incubation period ranges between 9 and 90 days.

**The primary lesion (chancre)** may be single or multiple and is usually located in the labia. Fourchette, anus, cervix, and nipples are the other sites of lesion. A small papule is formed, which is quickly eroded to form an ulcer. The margins are raised with smooth shiny floor. The ulcer is painless without any surrounding inflammatory reaction. The inguinal glands are enlarged, discrete, and painless. The **primary chancre** heals spontaneously in 1–8 weeks leaving behind a scar.

**The tubes are not affected and infertility does not occur** unless associated with gonococcal infection.

**Secondary syphilis**—Within 6 weeks to 6 months from the onset of primary chancre, the secondary syphilis may be evidenced in the vulva in the form of **condyloma lata**. These are coarse, flat-topped, moist, necrotic lesions and teeming with treponemes. Patient may present with systemic symptoms like fever, headache, and sore throat. Maculopapular skin rashes are seen on the palms and soles. Other features include generalized lymphadenopathy, mucosal ulcers, and alopecia.

The primary and secondary stage can last upto two years and during this period, the woman is a source of infection.

**Latent syphilis**—It is the quiescence phase after the stage of secondary syphilis has resolved. It varies in duration from 2 to 20 years.

**Tertiary syphilis**—About one-third of untreated patients progress from late latent stage to tertiary syphilis. It damages the central nervous, cardiovascular, and musculoskeletal systems. Patient may present with cranial nerve palsies (III, VI, VII, and VIII), hemiplegia, tabes dorsalis, aortic aneurysm, and gummas of skin and bones. The important pathology is endarteritis and periarteritis of small and medium sized vessels. **Tertiary syphilis is characterized by gumma**. A gummatous ulcer is a deep punched ulcer with rolled out margins. It is painless with a moist leather base. Serpiginous outline may also be produced.

The systemic manifestations of the secondary and tertiary syphilis are better dealt with in Textbook of Medicine.

**Congenital syphilis**—See author's Textbook of Obstetrics (Chapter 19).

## DIAGNOSIS

1. History of exposure to an infected person.
2. Identification of the organism—*Treponema pallidum*, an anaerobe.

A smear is taken from the exudate which is obtained after teasing the primary chancre (base and edge) with a swab dipped in normal saline. It is examined under dark ground illumination through a microscope. The treponemata appear as motile bluish white cork-screw shaped organisms.

3. Serological tests:

- (a) VDRL: This is the common flocculation test performed and is **positive after 6 weeks of initial infection**.
- (b) **The specific tests include** *Treponema pallidum* hemagglutination (TPHA) test, *Treponema pallidum* enzyme immunoassay (EIA), fluorescent treponemal antibody absorption (FTA-abs) test and *Treponema pallidum immobilization (TPI) test*.
  - Fluorescent treponemal antibody absorption test (FTA-abs). FTA-abs is expensive but a **confirmatory test**. FTA-IgM is produced only in active treponemal infection and it declines after adequate treatment.
  - EIA test for treponemal specific IgG or IgM is now routinely used.
  - VDRL and TPHA tests are used for screening and FTA-abs test is used for confirmation.
  - Serological tests are invariably positive in secondary syphilis.
- (c) Currently immunoblotting and PCR tests are evaluated as more sensitive and confirmatory tests.

After successful treatment, non-specific tests become negative, whereas specific tests remain positive.

## TREATMENT (CDC RECOMMENDATION - 2006)

### Early syphilis (primary, secondary, and early latent syphilis of less than 1 year duration)

Benzathine penicillin G 2.4 million units is given intramuscularly in a single dose, half to each buttock.

In penicillin allergic cases, tetracycline 500 mg, 4 times a day or Doxycycline 100 mg BID PO for 14 days is effective.

**Late syphilis:** Benzathine penicillin G 2.4 million units is given IM weekly for 3 weeks (7.2 million units total). This should be in consultation with the STI clinic.

Alternative regimen: Doxycycline 100 mg orally twice daily or Tetracycline 500 mg orally 4 times a day for 4 weeks.

**Follow up:** Serological test is to be performed 1, 3, 6, and 12 months after treatment of early syphilis. In late symptomatic cases, surveillance is for life; the serological test is to be done annually. All women with simultaneous syphilis and HIV infection may have high rate of treatment failure.

## CHLAMYDIAL INFECTIONS

**The causative organism is** *Chlamydia trachomatis* (of D-K serotypes), an obligatory intracellular Gram-negative bacteria. Its prevalence is more than *N. gonorrhoeae* as a causative agent for STI or STD in developed countries. Chlamydia has longer incubation period (6–14 days) compared to gonorrhea (3–7 days).

The organisms affect the columnar and transitional epithelium of the genitourinary tract. The lesion is limited superficially. As there is no deeper penetration, the pathological changes to produce symptoms may not be apparent. **The infection is mostly localized** in the urethra, Bartholin's gland, and cervix. It can ascend upwards like gonococcal infection to produce acute PID. Too often (20–40%), it is associated with gonococcal infection.

**CLINICAL FEATURES** are non-specific and asymptomatic in most cases (75%). Dysuria, dyspareunia, postcoital bleeding, and intermenstrual bleeding are the presenting symptoms.

Findings include mucopurulent cervical discharge, cervical edema, cervical ectopy, and cervical friability.

The clinical features of acute PID—has been mentioned in chapter 10 (p. 129).

**COMPLICATIONS:** Urethritis and Bartholinitis are manifested by dysuria and purulent vaginal discharge. Chlamydial cervicitis spreads upwards to produce endometritis and salpingitis. Chlamydial salpingitis is asymptomatic in majority of the cases. It causes tubal scarring resulting in infertility and ectopic pregnancy. It is the more common cause of perihepatitis (**Fitz-Hugh-Curtis syndrome**) than gonococcus. The spread to the liver from the pelvic organs is via lymphatics and the peritoneal cavity.

### DIAGNOSIS

In uncomplicated cases, the materials are to be collected from the urethra and endocervical canals.

- Chlamydial nucleic acid amplification testing and detection by polymerase chain reaction (PCR) is a very sensitive and specific test (95%). First void urine specimen is most effective and specific.
- Chlamydia antigen (lipopolysaccharide) can be detected by ELISA technique. Samples are taken from endocervix (endocervical swab). Sensitivity and specificity of this test is less compared to NAAT.
- Chlamydia can be demonstrated in tissue culture. (McCoy cell monolayers). It is 100% specific. It is expensive, technically difficult and takes 3–7 days to obtain result.

TABLE 11.3

### RECOMMENDED DRUGS FOR CHLAMYDIAL INFECTIONS (CDC 2006)

♦ Azithromycin	— 1 g orally single dose or
♦ Doxycycline	— 100 mg orally BID × 7 days or
♦ Ofloxacin	— 200 mg orally BID × 7 days or
♦ Erythromycin	— 500 mg orally BID × 7 days.

The sexual partner should also be treated with the same drug regimen.

Treatment failure with the above strict guidelines are indicative of either lack of patient compliance or reinfection.

## CHANCROID (SOFT SORE)

The causative organism is a Gram-negative streptobacillus—*Hemophilus ducreyi*. The incubation period is very short 3–5 days or less.

The lesion starts as multiple vesicopustules over the vulva, vagina or cervix. It then sloughs to form shallow ulcers circumscribed by inflammatory zone. The lesion is very tender with foul purulent and hemorrhagic discharge. There may be cluster of ulcers. Unilateral inguinal lymphadenitis may occur which may suppurate to form abscess (buboes).

**DIAGNOSIS: Syphilis must be ruled out first.** Demonstration of *Ducreyi bacillus* in specialized culture media is confirmatory. Discharge from the ulcers or pus from the lymph glands is taken for culture. In the stained film (Gram stain) the organisms appear classically as 'Shoal of fish'. It is difficult to grow this organism in culture method.



**TREATMENT (CDC RECOMMENDATION)**

- ▶ Ceftriaxone 250 mg IM single dose is effective. Sexual partner should also be treated.
- ▶ Azithromycin 1 gm by mouth single dose.
- ▶ Erythromycin 500 mg by mouth every 6 hours for 7 days can also be given.

Longer course of treatment is needed for patients who are positive with HIV.

### LYMPHOGRANULOMA VENEREUM (LGV)

Lymphogranuloma venereum (LGV) is caused by one of the aggressive L serotypes of *Chlamydia trachomatis* usually acquired sexually. It is an obligatory intracellular and Gram-intermediate organism. The incubation period is 3–30 days. It is more commonly found in the sea ports of the Far East, Malaysia, Africa, and South America.

Initial lesion is a painless papule, pustule or ulcer in the vulva, urethra, rectum or the cervix. The inguinal nodes are involved and feel rubbery. There is acute lymphangitis and lymphadenitis. **The glands become necrosed and abscess (bubo) forms.** Within 7–15 days, the bubo ruptures and results in multiple draining sinuses and fistulas. The healing occurs with intense fibrosis with lymphatic obstruction. **The secondary phase** is noted by painful adenopathy. **The classical clinical sign of LGV is the “groove sign”, a depression between the groups of inflamed nodes.** The lymphatic obstruction leads to vulval swelling where as lymphatic extension to the vulva, vagina, or rectum leads to ulceration, fibrosis, and stricture of the vagina or rectum.

**COMPLICATIONS** include: (i) vulval elephantiasis, (ii) perineal scarring and dyspareunia, (iii) rectal stricture, and (iv) sinus and fistula formation.

**DIAGNOSIS**

- (a) Culture and isolation (Lymph node aspiration): of LGV (*Chlamydia* serotypes L<sub>1,2,3</sub>) is confirmatory.
- (b) Detection of LGV antigen in pus obtained from a bubo with specific monoclonal antibodies using immunofluorescence method.
- (c) Detection of LGV antigen by ELISA method.

(d) LGV complement fixation test—when positive with rising titer (>1 : 64).

(e) Intradermal Frei test is non-specific and unreliable.

**TREATMENT**

**Prevention**—Use of condom or to avoid intercourse with a suspected infected partner.

**Definitive treatment**—CDC recommends Doxycycline 100 mg BID for at least 21 days. Alternatively, azithromycin 1 g PO weekly for 3 weeks or erythromycin 500 mg orally every 6 hours for 21 days is given (indicated for pregnant women). Sexual partner should also be treated.

**Surgical**—(i) Abscess should be aspirated but not be excised. (ii) Manual dilatation of the stricture weekly. It is essential to use antibiotics during the perioperative period.

### GRANULOMA INGUINALE (DONOVANOSIS)

This is a chronic progressive granulomatous diseases of the vulva, vagina, or cervix. It is commonly found in some tropics and subtropics like South China, South India, Papua New Guinea, and South America. **The causative organism is** a Gram-negative intracellular bacillus—*Calymmatobacterium granulomatis* (*Donovania granulomatis*).

**CLINICAL FEATURES:** The disease usually manifests itself 10–80 days after coitus with an infected partner. The lesion starts as pustules, which breakdown and erode the adjacent tissues through continuity and contiguity. The ulcer looks hypertrophic (beefy red) due to indurated granulation tissue. The margins are rolled and elevated. Biopsy may be needed to exclude neoplasia. The lymph nodes do not undergo suppuration and abscess formation (cf. Lymphogranuloma venereum).

**DIAGNOSIS** is confirmed by demonstrating the *Donovan bodies* within the mononuclear cells in material (scrapings) from the ulcer when stained by the Giemsa method. **Donovan bodies are clusters of dark-staining bacteria with a bipolar (safety pin) appearance found within the mononuclear cells.**

**TREATMENT:** Usually, it does respond well to a broad spectrum antibiotic. However, CDC recommends

Doxycycline 100 mg BID for at least 3 weeks. Alternatively, ciprofloxacin 750 mg BID for at least 2 weeks is given. The residual destructive lesion in the vulva may require plastic surgery or vulvectomy.

### BACTERIAL VAGINOSIS (BV) (BACTERIAL VAGINITIS)

The causative organism was previously thought to be *Gardnerella vaginalis* (*Haemophilus vaginalis*). The present concept is that along with *G vaginalis*, anaerobic organisms such as *Bacteroides* species, *Peptococcus* species, mobiluncus, and *Mycoplasma hominis* act synergistically to cause vaginal infection. There is marked decrease in lactobacilli.

Clinically, it is characterized by creamy vaginal discharge with fishy smell without extensive evidence of inflammation.

#### CLINICAL FEATURES

Bacterial Vaginosis (BV) is characterized by malodorous vaginal discharge. The term vaginosis is preferred as there is no vaginal inflammation. The discharge is homogeneous, greyish-white and adherent to the vaginal wall. Clinical implications of BV, in pregnancy are, preterm rupture of membranes, preterm labor, and chorioamnionitis.

**COMPLICATIONS:** (i) Recurrent infection leading to PID. (ii) Development of PID following abortion or (iii) vaginal cuff cellulitis following hysterectomy (iv) Pregnancy complications: second trimester miscarriage, PROM, preterm birth, endometritis.

#### DIAGNOSIS

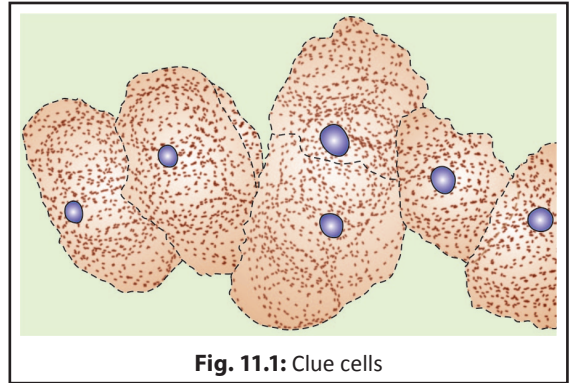
**(A) Amsel's four diagnostic criteria are:** (1) Homogeneous vaginal discharge. (2) Vaginal pH > 4.5 (litmus paper test). (3) Positive **whiff tests** (see below). (4) Presence of **clue cells** (> 20% of cells).

**(B) Gram stained vaginal smear (Hay/Ison):** Presence of more *Gardnerella* or mobiluncus morphotypes with few or absent lactobacilli.

**WHIFF TEST:** Fishy (amine) odor when a drop of discharge is mixed with 10 percent potassium hydroxide solution.

**Clue cells:** A smear of vaginal discharge is prepared with drops of normal saline on a glass slide and is seen under a microscope. Vaginal epithelial cells are

seen covered with these coccobacilli and the cells appear as stippled or granular. At times, the cells are so heavily stippled that the cell borders are obscured. **These stippled epithelial cells are called “clue cells” (Fig. 11.1).** Presence of clue cells (>20% of cells) are diagnostic of BV.



**Fig. 11.1:** Clue cells

**TREATMENT** is highly effective with metronidazole — 200 mg orally thrice daily for 7 days. Clindamycin cream (2%) and metronidazole (0.75%) gel are recommended for vaginal application daily for 5 days to prevent obstetric complications. The patient's sexual partner should be treated simultaneously. Cure rate is 80%.

### HERPES GENITALIS

The causative organism is herpes simplex virus (HSV) type 1 and 2. It is usually transmitted sexually by an infected partner but may possibly be transmitted by orogenital contact. The incubation period is 2–14 days.

**CLINICAL FEATURES:** Symptoms of the first attack usually appear less than 7 days after sexual contact. Initially, red painful inflammatory area appears commonly on the clitoris, labia, vestibule, vagina, perineum, and cervix. Multiple vesicles appear which progress into multiple shallow ulcers and ultimately heal up spontaneously by crusting. It takes about 3 weeks to complete the process. Inguinal lymphadenopathy occurs. Constitutional symptoms include fever, malaise, and headache. There may be vulvar burning, pruritus, dysuria, or retention of urine.

First episodes are severe compared to the recurrent disease. Frequency of recurrent infection is high with HSV-2.

**DIAGNOSIS**

- Virus tissue culture and isolation — confirmatory.
- Detection of virus antigen by ELISA or immunofluorescent method.
- PCR test to identify the HSV DNA is the rapid, specific, and most accurate test.

**RISKS**

- Physical and psychological trauma may precipitate recurrence.
- Adverse effects in primary infection during pregnancy.
  - Increased risks of miscarriage and pre-term labor.
  - Transfer of infection from mother to neonates during vaginal delivery, if primary (50%) or recurrent (5%).
  - Baby may suffer from damage to central nervous system. Primary genital herpes is not an indication for MTP (TOP). Anomaly scan should be done at 20 weeks gestation.
  - Delivery by cesarean section is indicated with primary genital herpes infection at the time of delivery.**

**CAUTIONS**

- ♦ **Recurrent episodes** are self-limiting and cause minor symptoms. Antiviral treatment is rarely needed.
- ♦ Daily suppressive therapy is given with valacyclovir-500 mg daily, at least for an year, when recurrences are >9 episodes per year.

**TREATMENT (CDC RECOMMENDED REGIMENS)**

The specific treatment is yet to be explored. Rest and analgesics are helpful. **Acyclovir which inhibits the intracellular synthesis of DNA by the virus, has been found to be effective in acute attacks.** It is better to be given orally in doses of 200 mg 5 times a day for 5 days. Acyclovir is effective in reducing the symptoms, duration of viral shedding, and helps in rapid healing. Its prophylactic use can reduce the episodes of recurrence. Valacyclovir 500 mg BID for 5 days or Famciclovir 250 mg orally thrice daily for 5 days can be used alternatively. Saline bath may relieve local pain.

**HUMAN IMMUNODEFICIENCY VIRUS (HIV) INFECTION AND ACQUIRED IMMUNODEFICIENCY SYNDROME (AIDS)****THE VIRUS**

The causative agents are human immunodeficiency viruses (HIV) of strains HIV 1 and HIV 2. HIV belongs to retrovirus (double stranded RNA) family. Retroviruses possess the enzyme **reverse transcriptase** which allows viral RNA to be transcribed into DNA. The viral DNA when gets incorporated into the host cell genome, **chronic infection begins.** The basic structure of this icosahedral HIV (RNA-retrovirus) consists of a core protein (P-24) with glycoprotein (GP 120; GP 41) envelope. Of the various core antigens, **P-24 is most widely used for investigation study.** Antibodies to envelope proteins (GP 120) have got some protective role. The virus is destroyed by heating at 56°C for 30 minutes or by disinfectants with glutaraldehyde.

**INCIDENCE:** The incidence is difficult to work out but the fact remains that the disease is spreading alarmingly fast both in the developed and developing countries and now has become a global problem.

In South and South East Asia, an estimated 4 million people (more than 50% of them are women and children) were with HIV. In most Asian countries, infection rates are less than 0.5 percent.

**Predominant route of infection worldwide is heterosexual contact and vertical transmission.**

**MODE OF TRANSMISSION**

- ♦ **Sexual intercourse** — Women are affected more than the men because in female, larger mucosal surface is exposed and semen contains high viral load. Transmission of virus from male to female is high. Transmission is both by **heterosexual** and **homosexual contact.**
- ♦ **Intravenous drug abusers.**
- ♦ **Transfusion of contaminated blood or blood products.**
- ♦ **Use of contaminated needles, needlestick injuries.**

- ◆ **Breastfeeding**—Infected mothers may infect their children during breastfeeding through breast milk (10–20%). More so in presence of ulcers (cracked nipples).

However, many health promoting benefits of breastfeeding may outweigh the risk of HIV transmission particularly in the developing world. For the other high risk factors for AIDS (see Table 11.4).

- ◆ **Perinatal transmission**—The vertical transmission to the neonates of the infected mothers is about 25–35%. The baby may be affected *in utero* (30%) through transplacental transfer, during delivery (70–75%) by contaminated secretions and blood of the birth canal.

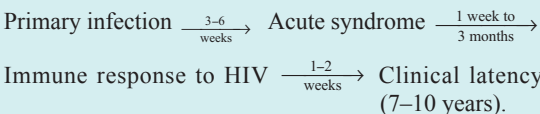
**TABLE 11.4 RISK FACTORS FOR AIDS**

- ◆ Multiple sex partners
- ◆ Prostitutes
- ◆ Homosexual males
- ◆ Intravenous drug abuser (IVDA)
- ◆ Multiple transfusions of blood or blood products
- ◆ Sexually transmitted disease
- ◆ Mother to infant

### IMMUNOPATHOGENESIS

The target for HIV is the CD4 receptor molecule. Cells within the immune system that have this molecule are: **CD4+ T lymphocytes** (predominantly affected), monocytes, macrophages and other antigen presenting cells like fibroblasts, neurons, renal, hepatic, and intestinal cells.

Following infection, there is profound cellular immunodeficiency as the CD4+ are progressively depleted by cytopathic effects of HIV.



**Immunological markers** that are used to determine the **progression of the disease are:**

- CD4 T lymphocyte count—patients with count from 200–500 cells/mm<sup>3</sup> are more likely to have

HIV related symptoms and count < 200 cells/mm<sup>3</sup> is taken into AIDS defining criteria.

- Measurement of HIV RNA levels by RT-PCR and the b DNA assays. Effectiveness of therapy is evaluated by monitoring of HIV RNA every 3–4 months.
- Raised P-24 (core) antigen titer—reflects the viral load.
- Raised serum  $\beta_2$  microglobulin—reflects the immune response.

### CLINICAL PRESENTATION

Following exposure to HIV infection, a patient develops antibodies against HIV in about 8–12 weeks. The development of antibodies marks the stage of seroconversion and in some cases manifest clinically as a **‘flu’ like syndrome**.

**Acute infection syndrome is characterized by** fever, skin rash, arthralgia, lymphadenopathy and diarrhea. This is called seroconversion illness. It lasts less than 2–3 weeks and resolves spontaneously.

After the initial exposure, the person remains asymptomatic for many years. The median time to develop AIDS is approximately 7–10 years. During this period, the patient shows progressive immune depletion. With increasing immunodeficiency, the person becomes susceptible to secondary infection by opportunistic organisms. Some individuals may just have persistent generalized lymphadenopathy during this period.

**AIDS-related complex (ARC) refers to subjects** having non-specific clinical features of weight loss, fever, diarrhea, skin rash, lymphadenopathy, herpes simplex, oral or recurrent genital candidiasis, oral or genital ulcers, PID, tubo-ovarian abscess, and thrombocytopenia without full blown pictures of AIDS.

**Any HIV infected individual with a CD4+ T cell count of < 200/μL, has AIDS by definition regardless of the presence of symptoms or opportunistic diseases.**

### HIV related other diseases:

- Common secondary infections are: atypical tuberculosis, pneumonia (*Pneumocystis carinii* pneumonia), systemic candidiasis, and meningitis.

- Encephalitis, myelopathy and polyneuropathy are neurological manifestations.
- There is an increased incidence of high-grade lymphoid neoplasms, Kaposi sarcoma and non-Hodgkin's lymphoma.
- Viral infections with herpes simplex, human papilloma virus (HPV) and cytomegalovirus (CMV) are common.

### Gynecological symptomatology

- **Infection of the genital tract** is high due to progressive immunodeficient state
  - ◆ **Vaginitis** due to recurrent candidiasis. There may be oral, esophageal candidiasis also.
  - ◆ **Pelvic Inflammatory Diseases**—with other STIs (gonorrhea, chlamydia, syphilis) are more likely (p. 147, 148 & 150).
- **Neoplasms of the genital tract are increased**
  - ◆ Increased incidence of CIN and carcinoma of the cervix. Colposcopy and cervical cytology screening should be routinely done.
  - ◆ Increased incidence of vulval intraepithelial neoplasia (VIN).
- **Increased morbidity following gynecological surgery**
  - ◆ Increased risk of wound infection and chest infection, an intensive antibiotic therapy is needed.
- **Menstrual abnormality:** Menorrhagia, amenorrhea, or abnormal uterine bleeding may be due to associated weight loss, thrombocytopenia or opportunistic infections or neoplasms.
- **Fertility** is not generally affected.
- **Pregnancy does not worsen the disease** neither the disease affect pregnancy adversely.

### Diagnosis

The effect on cellular immunity is manifested by decrease in CD4 cells. **An absolute CD 4 cell count below 200/mm<sup>3</sup> is considered as cut off point when there is risk of opportunistic infections.**

The organism can be isolated from the blood, semen, vaginal secretions, breast milk, or saliva (body fluids) of the infected persons.

### Diagnostic tests for HIV:

- ◆ Detection of IgG antibody to Gp 120 (envelope glycoprotein component) is **most commonly used**. Antibody production may take upto 3 months (window period) since the time of infection. These antibodies are not protective.
- ◆ Viral P-24 antigen can be detected very soon after the infection and it usually disappears by 8–10 weeks time.
- ◆ **ELISA (enzyme linked immunosorbent assay)** is extremely sensitive (99.5%) but less specific. It is easy, cheap, and less time consuming (2–5 hours). As such, it can be employed as a screening procedure extended to 'at risk' persons.
- ◆ **Western blot or immunoblot**—It is highly specific but complicated and time consuming (1–2 days). It is expensive too.
- ◆ **HIV RNA by PCR is the gold standard for diagnosis of HIV.** Viral DNA is amplified following isolation of the virus from peripheral mononuclear cells. PCR amplification of cDNA generated from viral RNA is reliable upto 40 copies/mL of HIV RNA.

### Causes of Death

- ◆ **Widespread infection** as it cannot be controlled effectively.
- ◆ **Profound immunodeficiency** leads to opportunistic infections and poor response to therapy.
- ◆ **Development** of unusual malignant lesions (lymphoma and Kaposi's sarcoma).

### TREATMENT: ■ Preventive ■ Definitive

#### Preventive measures include:

- 'Safer sex' practice with health education. Barrier methods (Condoms and Spermicides) are effective to reduce transmission (80%).
- **LNG-IUS with condoms** give excellent benefit.
- **Male circumcision** reduces transmission by 50%.
- **Use of blunt tipped needles** to avoid needle stick injury during surgery.
- **HIV negative blood** transfusion (screening of donors).
- **HIV negative** frozen semen to use for artificial donor insemination.

- **Postexposure prophylaxis** with zidovudine and lamivudine is advisable (given below).
- **Termination of pregnancy** in HIV positive women when requested.
- **Avoiding breastfeeding**—in the developing world, avoidance of breastfeeding may not be possible. Mother needs to be counseled as regard the risks and benefits of breastfeeding. **She is helped to make an informed choice.**
- **Infertility** — Serodiscordant couples (female HIV negative) may have assisted conception with insemination following sperm washing.
- **To maintain protocols** for correct handling of all body fluids (given below).
- **Wide spread voluntary counseling and testing (VCT).**

### Definitive

#### HIV treatment protocols change frequently.

**Antiretroviral therapy:** Antiretroviral drugs are grouped into—(A) **Nucleoside Reverse Transcriptase Inhibitors (NRTIs)**: Zidovudine, Zalcitabine, Lamivudine, Stavudine. (B) **Non-Nucleoside Reverse Transcriptase Inhibitors (NNRTIs)** : Delavirdine, Nevirapine, Efavirenz. (C) **Protease Inhibitors (PI)** : Indinavir, Saquinavir, Ritonavir. (D) **Fusion inhibitor:** Enfuvirtide. (E) **Integrase inhibitor** : Raltegravir. The combinations of these drugs are effective in increasing CD4 counts and reducing viral load. Monotherapy is not preferred as it hastens drug resistance. Combination therapy is known by the acronym **HAART** (Highly Active Antiretroviral Therapy).

**Drug combinations:** Uptodate treatment recommendations are available at : [www.cdcnpi.org](http://www.cdcnpi.org).

- ◆ Two from Gr A (NRTIs) plus one from Gr B or 2 from Gr A (NRTIs) plus one from Gr C (PI).

**Plasma HIV RNA levels indicate the degree of viral replication and CD4+ T cell count indicate level of immune competence.**

**Important side effects** of drugs are : lactic acidosis, anemia, granulocytopenia, pancreatitis, peripheral neuropathy, hepatic dysfunction, and carbohydrate intolerance.

#### When to start therapy:

- Acute HIV infection syndrome.

- Symptomatic HIV infection.
- Asymptomatic but CD 4 cell count  $< 350$  cells/mm<sup>3</sup> or with viral load—HIV RNA  $> 50,000$  copies/mL.
- Post-exposure prophylaxis (given below).
- Patients with CD 4 count  $< 200$ /mm<sup>3</sup> should also receive trimethoprim and sulfamethoxazole combination (*P. carinii* prophylaxis).
- Opportunistic infections (mycobacterium) should be treated simultaneously with specific drugs when CD4+ T cells  $< 50$ /mm<sup>3</sup>.

**With effective treatment** viral load should reach ‘undetectable’ levels ( $< 50$  copies/mL) and CD4 count should rise.

**Efavirenz** is the first line therapy in all patients **unless she is planning to conceive and has primary NRTI or NNRTI resistance.**

**When to change therapy:** (i) Failure to reduce viral load. (ii) Persistently declining CD4+ T cell count. (iii) Clinical deterioration. (iv) In presence of side effects due to drugs.

◆ **Post-exposure prophylaxis:** A combination of two NRTIs is given for 4 weeks. Prophylactic use of zidovudine (300 mg BID) and lamivudine (150 mg BID) for a period of 4 weeks immediately following an exposure may reduce the risk of seroconversion (CDC-2001).



#### Precautions to prevent occupational transmission of HIV (Universal Blood and Body Fluid Precautions)

- ◆ All blood and body fluids should be considered potentially infectious for HIV.
- ◆ Non-surgical management whenever possible.
- ◆ Barrier precautions: Use of cap, mask, gown, double gloves, eye wear (goggles), and boots.
- ◆ Use of blunt tipped needles (risk of HIV infection following needle stick injury is 0.3%).
- ◆ Washing of any body fluid contamination off the skin immediately.
- ◆ Use of disposable syringes, needles and anesthetic circuits.
- ◆ Resuscitation bags or mouthpieces should be available for emergency resuscitation.
- ◆ Thorough theater disinfection after the operation.

## GENITAL WARTS (CONDYLOMA ACUMINATA)

Condylomata are papillary lesions caused by **Human Papilloma Virus (HPV) usually type 6 and 11** (see p. 323). These are usually multiple and can be contaminated from other parts of the body. They can be transmitted sexually. Associated vaginal discharge favors their growth and so does pregnancy. Typically, they grow in clusters along a narrow stalk giving it a cauliflower appearance but at times the stalk may be broad and thick (Fig. 11.2). The condylomata may at times, spread to the vagina or even the cervix. **Anatomic distribution of anogenital HPV infection is: Cervix 70%, Vulva 25%, Vagina 10% and Anus 20%.** The lesion should be differentiated from syphilitic condylomata or vulval carcinoma. Very rarely, it becomes malignant. Conditions known to predispose women to infection with HPV are: Immunosuppression, diabetes, pregnancy, and local trauma.

There may be an **association between HPV infection and malignant epithelial transformation of the cervix, vagina and vulva. It is usually associated with HPV types 16, 18, 45, 56** (see p. 323).

**TREATMENT:** HPV vaccine (Types 6 and 11) can prevent 90% of condyloma. Most low risk and two

thirds of high risk HPV infections are spontaneously eradicated over a 24 months period.

**Different treatment modalities used are:** Cryotherapy, electrocautery, laser therapy, surgical excision or topical use of 5-fluorouracil, trichloro-acetic acid or intralesional interferon.

## MOLLUSCUM CONTAGIOSUM

Molluscum contagiosum is caused by a pox virus transmitted by body contact or towels or clothing. It is commonly seen in immunodeficient subject or with HIV infections. They vary in size upto 1 cm, dome-shaped, pearly-white in color and often umbilicated. They are usually multiple and can occur anywhere in the skin and genitalia. Microscopic appearance reveals numerous inclusion bodies (molluscum bodies) in the cytoplasm of the cells with Giemsa stain.

**Treatment:** Evacuation of caseous material from the nodule under local anesthetic is done. The floor of the nodule is then treated chemically with ferric subsulphate or trichloroacetic acid (85%) solution.

Cryotherapy with liquid nitrogen is applied until a halo of ice is formed around the lesion. Repeat application may be necessary.

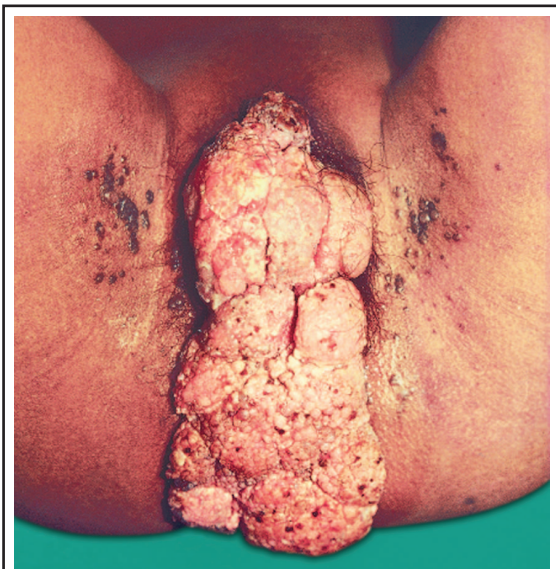## PEDICULOSIS PUBIS

The infective agent is a crab louse (*Phthirus pubis*) which affects the coarse hair of the pubis. The louse along with its eggs are attached to the hair. It is transmitted by sexual contact or infected clothes encouraged by inadequate hygiene. It produces intense pruritis → scratching → secondary infection → suppuration.

### TREATMENT

Permethrin cream (1%) is applied over the affected area and washed off after 10 minutes. Lindane 1% is used as a shampoo.

Treatment may also be done by application of 1 percent gamma-benzene hexachloride or malathion (0.5%) cream. After rubbing the preparation, the area should not be washed for 12 hours. The application may be repeated after 4 days, if necessary. It is mandatory to treat the contact and sterilize the clothings by boiling.



**Fig. 11.2.** Giant condyloma acuminata of vulva

## SCABIES

This is caused by *Sarcoptes scabiei*. It produces intense itching and often excoriation of skin. It is often associated with poor local hygiene.

### TREATMENT

Permethrin cream 5% or malathion 0.5% aguan

solution is applied to all areas of the body below the neck and washed off after 8–14 hours.

The treatment is also done by local application of 25 percent benzyl benzoate emulsion for the entire body below the neck. Single application is often enough. The clothings should be boiled. The family members are also to be treated simultaneously to prevent reinfection.

## KEY POINTS

- ▶ Sexually transmitted infections (STIs) includes those diseases which are predominantly transmitted through sexual contact from an infected partner. A patient with a STI is likely to have another one. *Chlamydia trachomatis* is now on the top in the list of the organisms causing STIs, the other common diseases are bacterial vaginosis, gonorrhoea, syphilis, and trichomonas vaginitis.
- ▶ *Neisseria gonorrhoeae* commonly invades the columnar and transitional epithelium of the genitourinary tract (endocervix, urethra, Bartholin's gland). Infertility, ectopic pregnancy, and chronic pelvic pain are the long-term complications (p. 148). Investigations should include for other STIs also.
- ▶ Herpes genitalis is caused by herpes simplex virus (HSV) type 1 and 2. Acyclovir orally in doses of 200 mg 5 times a day for 7 days is effective in reducing the constitutional symptoms, duration of viral shedding, and helps rapid healing.
- ▶ Syphilis is caused by *Treponema pallidum*. The hard chancre of primary syphilis is painless with an indurated base. VDRL and TPHA tests are used for screening and FTA-abs is used for confirmation. Treatment according to CDC recommendation includes Benzathine-penicillin IM (see p. 149).
- ▶ Chancroid (soft sore) is caused by a Gram-negative *Haemophilus ducreyi* and is always painful. Unilateral inguinal lymphadenitis may occur which may suppurate to form abscess. Demonstration of Ducreyi bacillus from the discharge of the ulcer or aspirated pus from the lymph gland is confirmatory. Ceftriaxone 250 mg IM single dose is effective.
- ▶ Granuloma inguinale is caused by Gram-negative *Donovania granulomatis*. There is localized ulcer formation without lymph node suppuration and abscess formation. Diagnosis is confirmed by demonstrating *Donovan bodies* within the mononuclear cells (p. 151). Doxycycline, 100 mg BID for at least 3 weeks is effective.
- ▶ Lymphogranuloma venerum is caused by Lserotype *Chlamydia trachomatis*. The inguinal glands are involved early, become necrosed and abscess forms. Healing occurs with intense fibrosis and lymphatic obstruction (p. 151). Doxycycline 100 mg BID for atleast 21 days is effective.
- ▶ AIDS is caused by human immunodeficiency virus (HIV). The methods of transmission are by sexual intercourse, transfusion of contaminated blood or blood products, use of contaminated needles, and vertical transmission to the baby (25–35%) during pregnancy and childbirth. Male condom is protective. It suppresses the immune system (depletion of CD 4+ T lymphocytes) so that the opportunistic organisms flare up.

Plasma HIV-RNA levels indicate the degree of viral replication and CD 4+ T cell count indicate level of immune competence (p. 156). Viral DNA amplification and detection by PCR is gold standard (p. 156). Any HIV infected individual with CD4 + T cell count < 200/μL has AIDS.

HIV related other diseases are: recurrent vaginal candidiasis, PID, CIN, VIN, atypical tuberculosis, and others as observed in an immunocompromised patient. Preventive measures (see p. 155, 156) and infection control during surgery (see p. 156) must be rigorous.



Contd...

HAART inhibits reverse transcriptase and slows down the progress of the disease. For HIV treatment protocols (see p. 156). HAART increases CD4 count and reduces viral load. Monotherapy hastens development of drug resistance.

Barrier method of contraception (condom) is effective to reduce the risk of HIV transmission and to prevent unwanted pregnancy. In addition, another contraceptive may be used to increase the contraceptive efficiency. LNG-IUS with condoms give excellent benefit.

- High risk factors for AIDS (Table 11.4) and preventive measures (p. 155, 156) must be considered in controlling AIDS.
- Condyloma accuminata is viral (HPV) in origin. HPV vaccine can prevent 90% of condyloma (p. 157).
- Molluscum contagiosum is caused by pox virus. It is commonly seen with immunodeficient subjects (p. 157).
- Bacterial vaginosis is caused by Gardnerella vaginalis. The vaginal discharge is homogeneous, adherent to vaginal wall with pH >4.7 and has an fishy odor when mixed with KOH solution (Whiff test). Presence of **clue cells** (stippled epithelial cells) on the wet smear of vaginal discharge is diagnostic. Oral metronidazole is highly effective.

# Infections of the Individual Pelvic Organs

## VULVAL INFECTION

The vulval and perineal skin is usually resistant to common infection. But the defence is lost following constant irritation by the vaginal discharge or urine (urinary incontinence). Furthermore, there may be atrophy or degenerative changes either in disease or following menopause when the infection is more likely. The vulval infection can thus occur *de novo* or may be affected secondarily, the primary site may be elsewhere in the adjacent structures. **In this section, only the lesions affecting primarily the vulva will be discussed.**

It is indeed difficult to classify the vulval infection but the following etiological classification is of help.

- I. Due to specific infection.
- II. Due to sensitive reaction.
- III. Due to vaginal discharge or urinary contamination.

### I. VULVITIS DUE TO SPECIFIC INFECTION

#### Bacterial

- ◆ Pyogenic (non-gonococcal)
- ◆ Sexually transmitted diseases (p. 146)
  - Gonorrhoea (p. 147)
  - Syphilis (p. 148)
  - Chancroid (p. 150)
  - Lymphogranuloma venereum (p. 151)
  - Granuloma inguinale (p. 151)
- ◆ Tubercular (p. 137)

#### Viral

- ◆ Condylomata accuminata (p. 157)

- ◆ Herpes genitalis (p. 152)
- ◆ Molluscum contagiosum (p. 157)
- ◆ Herpes zoster (p. 161)

#### Fungal

- ◆ Moniliasis (p. 164)
- ◆ Ringworm (p. 161)

#### Parasitic

- Pediculosis pubis (p. 157)
- Scabies (p. 158)
- Threadworm (p. 161).

## PYOGENIC INFECTION (NON-GONOCOCCAL)

**Vulval cellulitis:** The causative organism is predominantly *Staphylococcus aureus*. The vulva is swollen, red, and tender. There may be profuse exudation. The inflammation is limited, in majority, upto the labiocrural fold.

The patient complains of intense pain, itching and problem in micturition. There may be excoriation of the skin due to scratching and laceration.

Treatment is effective by systemic antibiotics, local hot compress and analgesics.

**Furunculosis:** The infection affects the hair follicles of the mons and labia majora → folliculitis → furunculitis. The offending organism is *Staphylococcus aureus*. If it is recurrent, glycosuria should be excluded. Treatment is effective with systemic and local antibiotics and local cleanliness.

**Infection of sebaceous and apocrine glands:** Infection of an apocrine or sebaceous gland looks and presents the features of a boil. If it recurs, excision is to be done in the quiescent state.

**Impetigo:** Impetigo is a pustular infection caused by *Staphylococcus aureus* or *Streptococcus*. It may be localized to vulva or spread to other parts of the body, face, or hands.

Blebs should be incised or the crusts be removed aseptically. Systemic and local antibiotics are to be prescribed.

**Erysipelas:** This rare spreading cellulitis is caused by invasion of the superficial lymphatics by  $\beta$ -haemolytic *Streptococcus*. There may be systemic constitutional symptoms. It responds well to systemic broad spectrum antibiotics.

**Intertrigo:** Intertrigo is due to irritation and infection of retained secretions in the skinfolds usually in an obese patient. It may also result from friction of the undergarments or sanitary towels.

Treatment with local hygiene and local antiseptic application is quite effective. At times, systemic antibiotics may have to be used.

### VIRAL INFECTION

**Herpes zoster:** The causative agent is varicella zoster virus (VZV). This is due to re-emergence of VZV from posterior nerve roots. It produces an inflammatory painful eruption of groups of vesicles distributed over the skin corresponding to the course of peripheral sensory nerves (dermatome). It is commonly unilateral but may extend to the thigh or buttock of the same side. The vesicles may rupture or become dry with scab formation. It resolves spontaneously in 3 weeks time.

Treatment is by analgesics to relieve pain and antibiotics to prevent secondary infection. Acyclovir 800 mg orally five times daily for 7 days is recommended. Acyclovir cream (5%) may be used locally for less severe infection.

### FUNGAL INFECTION

**Moniliasis:** See p. 164.

**Ringworm:** The causative organism is *Tinea cruris*. The lesions look bright red and circumscribed. The fungus can be detected microscopically from scraping of the lesion.

Treatment is very effective with imidazole (clotrimazole or miconazole) cream. Some fungi (*Tricho-*

*phyton rubrum*) respond well to griseofulvin 500 mg twice daily by mouth for 4 weeks.

### PARASITIC INFECTION

**Threadworm:** The causative organism is *Oxyuris vermicularis*. It is common in children. Nocturnal perineal itching with evidences of perianal excoriation is observed. The parasite is detected in the stool. Anthelmintic drugs such as mebendazole and local application of gentian violet cures the condition.

### INFECTIONS OF BARTHOLIN'S GLAND

**Bartholin's glands** are the two pea sized (2 cm) glands, located in the groove between the hymen and the labia minora at 5 O'Clock and 7 O'Clock position (see p. 2) of the vagina.

**Causative Organisms:** Although *Gonococcus* is always in mind but more commonly other pyogenic organisms such as *Escherichia coli*, *Staphylococcus*, *Streptococcus*, or *Chlamydia trachomatis* or mixed types (polymicrobial) are involved.

**Pathology:** Both the gland and the duct are involved. The epithelium of the gland or the duct gets swollen. The lumen of the duct may be blocked or remains open through which exudates escape out.

**Fate:** The infection may resolute completely or an abscess is formed. In others, the infection subsides only to recur in future. In such cases, the gland becomes fibrotic. Too often, the duct lumen heals by fibrosis with closure of the orifice → pent up secretion of the gland → formation of bartholin cyst.

**Thus, the end results of acute Bartholinitis are:** (i) Complete resolution (ii) Recurrence (iii) Abscess (iv) Cyst formation.

**Clinical Features:** Initially, there is local pain and discomfort even to the extent of difficulty in walking or sitting. Examination reveals tenderness and induration of the posterior half of the labia when palpated between thumb outside and the index finger inside the vagina (see Fig. 9.6). The duct opening looks congested and secretion comes out through the opening when the gland is pressed by fingers. The secretion should be collected with a swab for bacteriological examination.

**Treatment:** Hot compress over the area and analgesics to relieve pain are instituted. Systemic

antibiotic like ampicillin 500 mg orally 8 hourly is effective or else appropriate antibiotic according to the bacteriological sensitivity should be instituted.

**Recurrent Bartholinitis:** Periodic painful attacks cause problems in 5–10 percent women. Excision of the gland with the duct may have to be done in the quiescent phase.

### BARTHOLIN'S ABSCESS

Bartholin's abscess is the end result of acute bartholinitis. The duct gets blocked by fibrosis and the exudates pent up inside to produce abscess. If left uncared for, the abscess may burst through the lower vaginal wall. A sinus tract may remain with periodic discharge through it.

#### Clinical Features

The local pain and discomfort become intense. The patient cannot walk or even sit. Fever is often associated.

On examination, there is an unilateral tender swelling beneath the posterior half of the labium majus expanding medially to the posterior part of the labium minus. The overlying skin appears red and edematous.

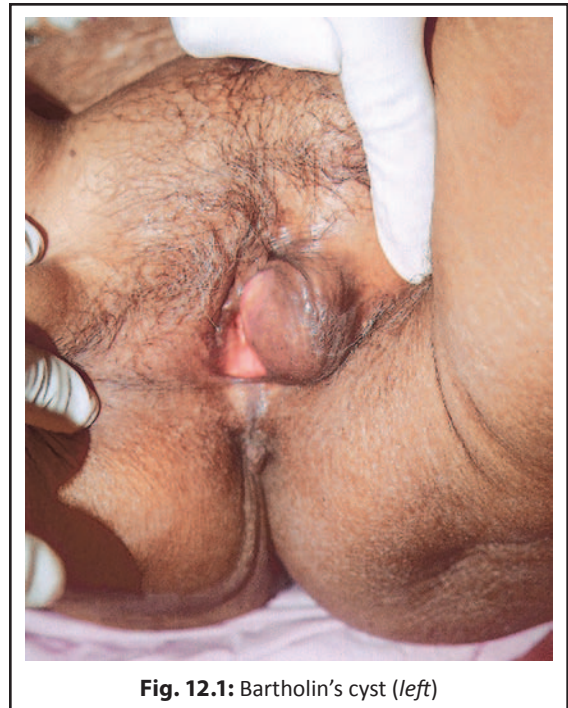**Treatment:** Rest is imposed. Pain is relieved by analgesics and daily sitz bath. Systemic antibiotic—ampicillin 500 mg orally 8 hourly or tetracycline in chlamydial infection is effective. Abscess should be drained at the earliest opportunity before it bursts spontaneously.

In case of recurrent Bartholin's abscess, excision should be done in the quiescent phase after the infection is controlled.

### BARTHOLIN'S CYST

There is closure of the duct or the opening of an acinus. The cause may be infection or trauma followed by fibrosis and occlusion of the lumen.

**Pathology:** It may develop in the duct (common) or in the gland. **Commonly, it involves the duct;** the gland is adherent to it posterolaterally. Cyst of the duct or gland can be differentiated by the lining epithelium. The content is glairy colorless fluid—secretion of the Bartholin's gland.



**Fig. 12.1:** Bartholin's cyst (*left*)

**Clinical Features:** A small size often remains unnoticed to the patient or escapes attention to the physician even following internal examination. If it becomes large (size of hen's egg), there is local discomfort and dyspareunia. Examination reveals an unilateral swelling on the posterior half of the labium majus which opens up at the posterior end of the labium minus. Its medial projection makes the vulval cleft 'S'-shaped. The overlying skin is thin and shiny. The cyst is fluctuant and not tender (Fig. 12.1).

**Treatment: Marsupialization** is the gratifying surgery for Bartholin's cyst. An incision is made on the inner aspect of the labium minus just outside the hymenal ring. The incision includes the vaginal wall and the cyst wall. The cut margins of the either side are to be trimmed off to make the opening an elliptical shape and of about 1 cm in diameter. The edges of the vaginal and cyst wall are sutured by interrupted catgut, thus leaving behind a clean circular opening.

**The advantages of marsupialization over the traditional excision operation are:** (i) Simple.

- (ii) Can be done even under local anesthesia.
- (iii) Shorter hospital stay (24 hours).
- (iv) Post-operative complication is almost nil.
- (v) Gland function (moisture) remains intact.

## VAGINAL INFECTION (VAGINITIS)

- ◆ Vulvovaginitis in childhood.
- ◆ Trichomoniasis.
- ◆ Moniliasis.
- ◆ Vaginitis due to *Chlamydia trachomatis*.
- ◆ Atrophic vaginitis.
- ◆ Non-specific vaginitis.
- ◆ Toxic shock syndrome.

### VULVOVAGINITIS IN CHILDHOOD

Inflammatory conditions of the vulva and vagina are the commonest disorders during childhood. Due to lack of estrogen, the vaginal defence is lost and the infection occurs easily, once introduced inside the vagina.

#### Etiology

- ▶ Non-specific vulvovaginitis.
- ▶ Presence of foreign body in the vagina.
- ▶ Associated intestinal infestations—threadworm being the commonest.
- ▶ Rarely, more specific infection caused by *Candida albicans* or *Gonococcus* may be implicated.

**Clinical Features:** The chief complaints are pruritus of varying degree and vaginal discharge. There may be painful micturition.

Inspection reveals soreness of the vulva. The labia minora may be swollen and red. If a foreign body is suspected, a vaginal examination with an aural or nasal speculum may help in diagnosis.

**Investigations:** The vaginal discharge is collected with a platinum loop and two smears are taken, one for direct examination and the other for Gram stain.

A small amount may be taken with a pipette for culture in Stuart's media. To exclude intestinal infestation, stool examination is of help.

**Vaginoscopy** is needed to exclude foreign body or tumor in a case with recurrent infection.

**Treatment:** In most cases, the cause remains unknown. Simple perineal hygiene will relieve the symptoms. In cases of soreness or after removal of foreign body, estrogen cream is to be applied locally, every night for two weeks. When the specific organisms are detected, therapy should be directed to cure the condition.

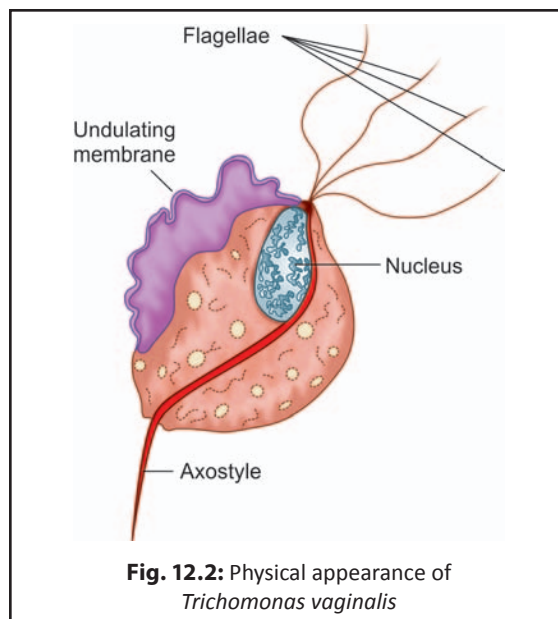
### TRICHOMONAS VAGINITIS

**Vaginal trichomoniasis is the most common** and important cause of vaginitis in the childbearing period.

**Causative Organism:** It is caused by *Trichomonas vaginalis*, a pear-shaped unicellular flagellate protozoa. It measures 20  $\mu$  long and 10  $\mu$  wide (larger than a WBC). It has got four anterior flagellae and a spear-like protrusion at the other end with an undulating membrane surrounding its anterior two-third. It is actively motile (Fig. 12.2).

#### Mode of Transmission

The organism is predominantly transmitted by sexual contact, the male harbors the infection in the urethra and prostate. The transmission may also be possible by the toilet articles from one woman to the other or through examining gloves. The incubation period is 3–28 days.



**Fig. 12.2:** Physical appearance of *Trichomonas vaginalis*

**Pathology:** In about 25 percent of women in the reproductive period, the parasites harbor in the vagina in asymptomatic state. When the local defence is impaired—during and after menstruation, after sexual stimulation, and following illness, the pH of the vagina is raised to 5.5–6.5. At this level of pH, the trichomonads thrive. The organisms usually lie in between the rugae and produce surface inflammatory reaction when the defence is lost. In about 75 percent cases, the organism can be isolated from the urethra, Skene’s tubules, or even from the Bartholin’s glands.

### Clinical Features

- There is sudden profuse and offensive vaginal discharge often dating from the last menstruation.
- Irritation and itching of varying degrees within and around the introitus are common.
- There is presence of urinary symptoms such as dysuria and frequency of micturition.
- There may be history of previous similar attacks.

Women with trichomoniasis should be evaluated for other STDs including *N. gonorrhoeae*, *C. trachomatis*, and HIV.

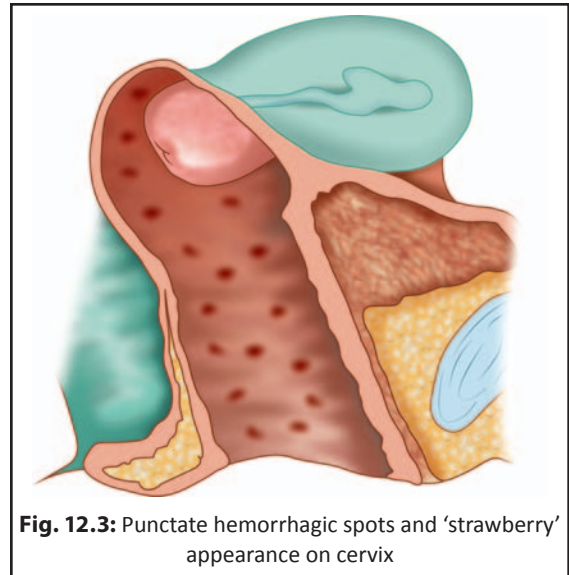
### On Examination

- There is thin, greenish-yellow and frothy offensive discharge per vaginum.
- The vulva is inflamed with evidences of pruritus.
- Vaginal examination may be painful. The vaginal walls become red and inflamed with multiple punctate hemorrhagic spots. Similar spots are also found over the mucosa of the portio vaginalis part of the cervix on speculum examination giving the appearance of ‘strawberry’ (Fig. 12.3).

### Diagnosis

- Identification of the trichomonas is done by hanging drop preparation (p. 110). If found negative even on repeat examination, the confirmation may be done by culture.
- Culture of the discharge collected by swabs in Diamond’s TYM or Feinberg Whittington medium.

In suspected cases, gonococcal or monilial infection should be excluded.



**Fig. 12.3:** Punctate hemorrhagic spots and ‘strawberry’ appearance on cervix

### Treatment

The treatment is very much effective with metronidazole. Metronidazole 200 mg thrice daily by mouth is to be given for 1 week. A single dose regimen of 2 g is an alternative. Tinidazole single 2 gm dose PO is equally effective. The husband should be given the same treatment schedule for 1 week. Resistance to metronidazole is extremely rare. The husband should use condom during coitus irrespective of contraceptive practice until the wife is cured.

## CANDIDA VAGINITIS (MONILIASIS)

### Causative Organism

Moniliasis is caused by *Candida albicans*, a gram-positive yeast-like fungus (Fig. 12.4).

### Pathology

#### Predisposing factors for *Candida vaginitis*

- ◆ Diabetes : • ↑ Glycogen in the cells, glycosuria
- ◆ Pregnancy : • ↑ Vaginal acidity, glycosuria  
• ↑ Glycogen in the cells
- ◆ Broad spectrum antibiotics : • ↓ Acid forming lactobacillus
- ◆ Combined oral pills
- ◆ Immunosuppression – HIV
- ◆ Drugs – steroids
- ◆ Thyroid, Parathyroid disease: • Obesity

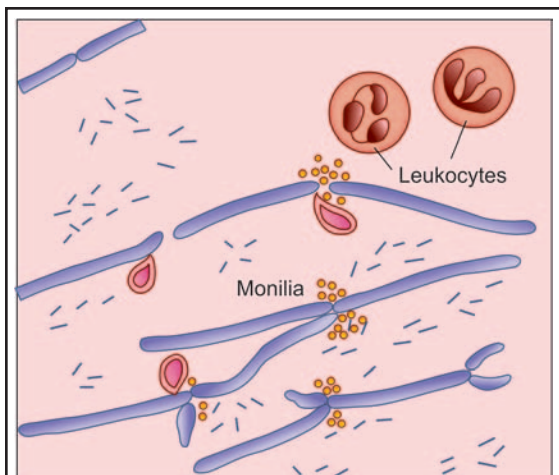


Fig. 12.4: Physical appearance of *Candida albicans*

### Clinical Features

The patient complains of vaginal discharge with intense vulvovaginal pruritus. **The pruritus is out of proportion to the discharge.** There may be dyspareunia due to local soreness.

### On examination:

- (a) The discharge is thick, curdy white and in flakes, (cottage cheese type) often adherent to the vaginal wall (Fig. 12.5).

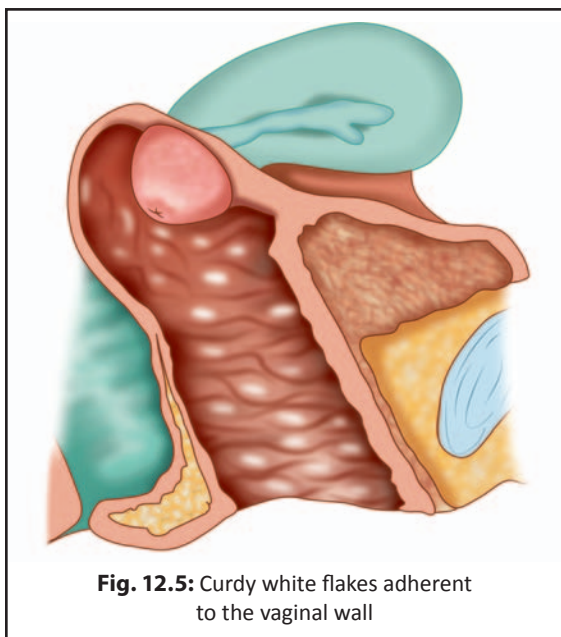


Fig. 12.5: Curdy white flakes adherent to the vaginal wall

(b) Vulva may be red and swollen with evidences of pruritus.

(c) Vaginal examination may be tender. Removal of the white flakes reveals multiple oozing spots.

**Diagnosis:** **Wet Smear** of vaginal discharge is prepared. KOH solution (10%) is added to lyse the other cells. Filamentous form of mycella, pseudohyphae can be seen under the microscope (Fig. 12.4). **Culture** in Nickerson's or Sabouraud's media—become positive in 24–72 hours (chapter 9).

**Women with recurrent** vulvovaginitis, vaginal boric acid capsule (600 mg gelatin capusles) is effective. Boric acid inhibits fungal cell wall growth.

**Treatment:** Corrections of the **predisposing factors** should be done, if possible. Local fungicidal preparations commonly used are of the polyene or azole group. Nystatin, clotrimazole, miconazole, econazole are used in the form of **either vaginal cream or pessary**.

One pessary is to be introduced high in the vagina at bedtime for consecutive 2 weeks. In severe cases, additional use of pessary in the morning is advocated. The treatment should be continued even during menstruation. *Single dose oral therapy* with fluconazole (150 mg) or itraconazole is also found effective.

Associated intestinal moniliasis should be treated by fluconazole 50 mg daily orally for 7 days. Husband should be treated with nystatin ointment locally for few days following each act of coitus. The use of condom is preferred.

Resistance to these drugs is not known. The systemic antifungal drugs fluconazole and itraconazole are effective in a single dose oral therapy.

### ATROPHIC VAGINITIS (SENILE VAGINITIS)

**Vaginitis in postmenopausal women is called atrophic vaginitis.** The term is preferable to senile vaginitis.

There is atrophy of the vulvovaginal structures due to estrogen deficiency. The vaginal defence is lost. Vaginal mucosa is thin and is more susceptible to infection and trauma. There may be desquamation of the vaginal epithelium which may lead to formation of adhesions and bands between the walls.

**TABLE 12.1 DIFFERENTIAL DIAGNOSIS OF VAGINAL DISCHARGE**

Characteristics	Trichomoniasis	Candidiasis	Bacterial vaginosis	Chlamydia	Normal vaginal discharge
Color	Greenish yellow	Curdy white	Gray white to green yellow white	Mucopurulent	White
Consistency	Thin, frothy	Thick	Thin	Thick	Thin
Whiff test (see p. 148)	Negative	Negative	Positive (Fishy amine)	Negative	Negative
pH	≥ 5	< 4.5	≥ 5	< 4.5	< 4.5
Pruritus	+++	++	Non-irritating	—	—
Diagnosis (Wet mount microscopy)	Motile <i>Trichomonas</i> (see p. 164)	Hyphae or spores (see p. 165)	Clue cells (> 20%) (see p. 152)	Chlamydia NAAT (see p. 150)	—
Treatment	Metronidazole 2 gm single dose or 200 mg. TID × 7 days (see p. 164)	Imidazole Fluconazole 150 mg P.O. weekly for 6 weeks	Metronidazole 200 mg. TID × 7 days (see p. 152)	Azithromycin 1 gm orally single dose (see p. 150)	—

### Clinical Features

- Yellowish or blood stained vaginal discharge.
- Discomfort, dryness, soreness in the vulva.
- Dyspareunia.

### On examination

- Evidences of pruritus vulvae.
- Vaginal examination is often painful and the walls are found inflamed.

**Diagnosis:** Senile endometritis may co-exist and **carcinoma body or the cervix should be excluded prior to therapy (p. 559).**

### Treatment

Improvement of general health and treatment of infection if present should be done. Systemic estrogen therapy may be considered if there is no contraindication. This improves the vaginal epithelium, raises glycogen content, and lowers vaginal pH.

Intravaginal application of estrogen cream by an applicator is also effective. About one-third of the vaginal estrogen is systemically absorbed.

### TOXIC SHOCK SYNDROME (TSS)

TSS is commonly seen in menstruating women between 15 and 30 years of age following the use of tampons (polyacrylate). Other condition associated with TSS is use of female barrier contraceptives (diaphragm). **It is characterized by the following features of abrupt onset :**

- ◆ Fever >38.9°C.
- ◆ Diffuse macular rash, myalgia.
- ◆ Gastrointestinal: Vomiting, diarrhea.
- ◆ Cardiopulmonary: Hypotension, adult respiratory distress syndrome.
- ◆ Platelets : ≤ 100,000/mm<sup>3</sup>.
- ◆ Renal : ↑ BUN (≥ twice normal).
- ◆ Hepatic : Bilirubin, SGOT, SGPT rise twice the normal level.
- ◆ Mucous membrane (vaginal, oropharyngeal) : Hyperemia.

The pathological features are due to liberation of exotoxin by *Staphylococcus aureus*. It may lead to multiorgan system failure. Blood cultures are negative.



**Treatment** is supportive. Correction of hypovolemia and hypotension with intravenous fluids and dopamine infusion is done in an intensive care unit. Parenteral corticosteroids may be used. Blood coagulation parameters and serum electrolytes are checked and corrected. Infection is controlled by  $\beta$ -lactamase resistant antistaphylococcal penicillin (cloxacillin, clindamycin and oxacillin) for 10–14 days. The tampon should be removed. Cotton tampons are the safest. Mortality following TSS is 6–10 percent.

## CERVICITIS

The term cervicitis is reserved to infection of the endocervix including the glands and the stroma. The infection may be acute or chronic.

### ACUTE CERVICITIS

The **endocervical infection** usually follows childbirth, abortion, or any operation on cervix. The responsible organisms are pyogenic (p. 127). Other common pathogens are : *Gonococcus*, *Chlamydia trachomatis*, *Trichomonas bacterial vaginosis*, *Mycoplasma* and *HPV*, the first one being less common nowadays.

The organisms gain entry into the glands of the endocervix and produce acute inflammatory changes. The infection may be localised or spread upwards to involve the tube or sideways involving the parametrium.

**Clinical Features:** The vaginal examination is painful. The cervix is tender on touch or movements. Cervix looks edematous and congested. **Mucopurulent discharge** is seen escaping out through the external os.

**Prognosis:** (a) It may resolve completely. (b) The infection may spread to involve the adjacent structures or even beyond that. (c) Becomes chronic.

**Treatment:** High vaginal and endocervical swabs are taken for bacteriological identification and drug sensitivity test. Appropriate antibiotics should be prescribed. General measures are to be taken as outlined in acute pelvic infection (ch. 10).

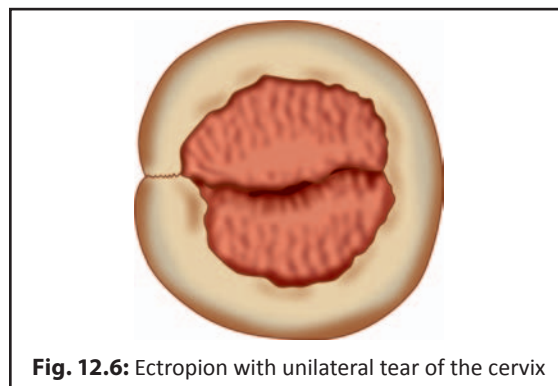
## CHRONIC CERVICITIS

**Chronic cervicitis is the commonest lesion found in women attending gynecologic outpatient.** It may follow an acute attack or usually chronic from the beginning. **The endocervix is a potential reservoir for *N. gonorrhoeae*, *Chlamydia*, HPV, mycoplasma and bacterial vaginosis.**

**Pathology:** The mucosa and the deeper tissues are congested, fibrosed, and infiltrated with leukocytes and plasma cells. The glands are also hypertrophied with increased secretory activity. Some of the gland mouths are closed by fibrosis or plugs of desquamated epithelial cells to cause retention cyst— **nabothian follicles** (Fig. 18.4). Thus, in fact, it should be called chronic endocervicitis as the ectocervix is protected by the overlying stratified squamous epithelium. There is associated lacerated and everted endocervix, the so-called **eversion or ectropion**.

**Clinical Features:** There may not be any symptom as it may be accidentally discovered during examination. Excessive mucoid discharge, at times **mucopurulent**, is the predominant symptom. History of contact bleeding may be present.

**On examination:** (a) The cervix may be tender to touch or on movement. (b) Speculum examination reveals—mucoid or mucopurulent discharge escaping out through the cervical os. There may be enlargement, congestion, or ectropion of the cervix. Associated ectopy may be present (Fig. 12.6).



**Fig. 12.6:** Ectropion with unilateral tear of the cervix

### Treatment

**Cervical scrape cytology to exclude malignancy is mandatory prior to any therapy.**

- (i) There is no place of antimicrobial therapy except in gonococcal or proved cases of chlamydial infection or bacterial vaginosis.
- (ii) The diseased tissue may be destroyed by electro or diathermy cauterization or laser or cryosurgery. The ectropion is corrected by deep linear burns and the coincidental ectopy may be coagulated (See p. 591).

## ENDOMETRITIS

During childbearing period, infection hardly occurs in the endometrium except in septic abortion or puerperal sepsis and acute gonococcal infection.

**Endometrium is protected from infection due to vaginal and cervical defence and also due to periodic shedding of endometrium.**

### ACUTE ENDOMETRITIS

It almost always occurs after abortion or childbirth. The details of such infection has been dealt on page 133. For details see author's Textbook of Obstetrics Chapter 29. Treatment of acute endometritis is similar to acute salpingitis (p. 172) for 14 days.

### CHRONIC ENDOMETRITIS

It is indeed rare for chronic endometritis to occur during reproductive period even following acute PID and endometritis. This is because of cyclic shedding of endometrium.

The infection can gain foothold, however, when there is **persistent source of infection** in the uterine cavity. Such conditions are IUCD, infected polyp, retained products, uterine malignancy, and endometrial burns due to radium. Tubercular endometritis is chronic from the beginning and has been described in p. 138.

Women often presents with purulent or seropurulent vaginal discharge. **Diagnosis** is made by cervical smear, culture of the discharge, transvaginal ultrasonography and **histology, of the endometrium.**

**Treatment:** The offending cause is to be removed or eradicated. Levofloxacin 500 mg PO daily for 14 days with Metronidazole 400 mg PO twice daily for 14 days are given.

### ATROPHIC ENDOMETRITIS (SENILE ENDOMETRITIS)

Following menopause, due to deficiency of estrogen, the defense of the uterocervicovaginal canal is lost. There is no periodic shedding of the endometrium. As a result, organisms of low virulence can ascend up to infect the atrophic endometrium. There is intense infiltration of the endometrium with polymorphonuclear leukocytes and plasma cells. The endometrium becomes ulcerated at places and is replaced by granulation tissues. The purulent discharge either escapes out of the uterine cavity or may be pent up inside producing pyometra.

**Clinical Features:** The postmenopausal women complain of vaginal discharge, at times offensive or even blood-stained. Pelvic examination reveals features of atrophic vaginitis. Purulent discharge may be seen escaping out through the cervix. In presence of pyometra, the uterus is enlarged; feels soft and tender.

### Diagnosis

**The diagnosis is confused with carcinoma of the endometrium which must be excluded prior to treatment** (see p. 356). In fact, pyometra may be present both in atrophic endometritis and endometrial carcinoma. **Ultrasonography (TVS)** is helpful to the diagnosis. Diagnostic curettage should be done and the endometrium is subjected to histological examination.

If however, **pyometra is present, drainage of pus by simple dilatation should be done first.** After 1–2 weeks, diagnostic curettage is to be done under cover of antibiotics.

**Treatment:** In women with recurrent attacks, hysterectomy should be done and **the specimen should be subjected to histological examination.**

## PYOMETRA

Collection of pus in the uterine cavity is called pyometra. **The prerequisites for pyometra formation are :**

- Occlusion of the cervical canal.
- Enough sources of pus formation inside the uterine cavity.
- Presence of low grade infection.

### Causes

- **Obstetrical**—The only condition is following infection of lochiometra.
- **Gynecological**—The conditions which are associated with pyometra are: (a) Carcinoma in the lower part of the body of uterus (b) Endocervical carcinoma (c) Senile endometritis (d) Infected hematometra following amputation, conization or deep cauterization of cervix (e) Tubercular endometritis.

**Pathology:** There is abundant secretion of pus from the offending sites. The cervical canal gets blocked due to senile narrowing by fibrosis or due to debris. The accumulated pus distends the uterine cavity. The postmenopausal atrophic myometrium fails to expel the collected pus. Thus, the uterus gets enlarged more and more with thinning of its wall. The lining epithelium is lost at places and replaced by granulation tissue.

The organisms responsible are coliforms, *streptococci* or *staphylococci*. Rarely, it may be tubercular. Except in tubercular (caseous), the fluid is thin, offensive, at times purulent or blood stained. The pus may be sterile on culture or the offending organism can be detected.

**Clinical Features:** The patient complains of intermittent blood stained purulent offensive discharge per vaginam. There may be occasional pain in lower abdomen. Systemic manifestation is usually absent.

**Per abdomen:** An uniform suprapubic swelling may be felt of varying size. It is cystic with well-defined margins but lower pole is not felt. It may be tender.

**Internal examination reveals:** The swelling is uterine in origin. The offensive discharge is seen escaping out through the cervix. **Pelvic ultrasonography** reveals distended uterine cavity with accumulation of fluid within.

**Diagnosis is confirmed** by dilatation of the cervix when pus escapes. In every case, **all types of investigations are to be made to exclude malignancy of the body of the uterus and endocervix**. Diagnostic curettage should be withheld for about 7–14 days following dilatation and drainage of pus. This will minimize such complications such as perforation of the uterus and spreading peritonitis. During the interval period, antibiotics should be prescribed.

**Treatment:** Once malignancy is excluded, the pyometra is drained by simple dilatation of the cervix. Even in non-malignant cases or in cases of recurrence, hysterectomy may be indicated. Definite surgery for malignancy is to be done following drainage of pus.

## SALPINGITIS

**Infection of the fallopian tube is called salpingitis.**

The details of salpingitis has already been described in the chapter of pelvic infection (ch. 10). The pathogenesis of salpingitis (acute and chronic) will be described in this section. **The following facts are to be borne in mind while dealing with salpingitis.**

- ◆ The infection is usually polymicrobial in nature (Table 12.2).
- ◆ Both the tubes are usually affected.
- ◆ Ovaries are usually involved in the inflammatory process and as such, the terminology of salpingo-oophoritis is preferred.
- ◆ Tubal infection almost always affects adversely the future reproductive function.

TABLE 12.2

### ORGANISMS RESPONSIBLE FOR SALPINGITIS

#### Sexually transmitted:

- ◆ *Gonococcus*
- ◆ *Chlamydia trachomatis*
- ◆ *Mycoplasma* (rarely)

#### Pyogenic:

- ◆ Aerobes – *Streptococcus*, *Staphylococcus*, *E. coli*
- ◆ Anaerobes – *Bacteroides fragilis*, *Actinomyces* (rarely), *Peptococcus*

#### Tubercular:

- ◆ *Mycobacterium tuberculosis*

### Etiology

#### I. Ascending infection from the uterus, cervix and vagina

- ◆ *Pyogenic organisms* (see Table 12.2).
- ◆ *Sexually transmitted infections* (STIs) (see Table 11.1).

#### II. Direct spread from the adjacent infection

One or both the tubes are affected in appendicitis, diverticulitis, or following pelvic peritonitis. The

organisms are usually *E. coli* or *Streptococcus fecalis*. *Bacteroides fragilis* is too often involved whenever abscess is formed.

### III. Tubercular (see p. 137, 138)

**Modes of Spread to the Tubes** (see p. 127).

## ACUTE SALPINGITIS

**Pathology:** • Pyogenic • Gonococcal

### ACUTE PYOGENIC

The pathological changes in the tubes depend on the virulence of the organisms and the resistance of the host.

There is intense hyperemia with dilated vessels visible under the peritoneal coat. The enlargement of the tube is greater than gonococcal infection because of interstitial involvement. The wall is enormously thickened and edematous. The mucopurulent or purulent exudate can be expressed out through the abdominal ostium.

Microscopically, the epithelium looks normal or the mucosa slightly edematous. The muscularis shows marked edema and acute inflammatory reaction. **As the outer coat is involved, adhesions are likely and are dense.**

If the infection is very severe, the endosalpinx is destroyed in part or whole and pus is formed. If the fimbrial end is open, the pus escapes out to cause pelvic peritonitis and abscess. The organisms may be present for even a year and as such chances of repeated infections are more.

**Acute gonococcal:** Like pyogenic infection, there is hyperemia and the tube is swollen and edematous. As the pathology is principally endosalpingitis, **adhesions are less and flimsy.**

The purulent exudate may escape in the peritoneal cavity and produces pelvic peritonitis and pelvic abscess. The ovaries may be involved in the process.

More often, the fimbriae get edematous, phymotic with closure of the abdominal ostium. The uterine opening is closed by congestion. The exudate is pent up inside the lumen producing **pyosalpinx**. The pus becomes sterile by 6 weeks and become hydrosalpinx.

TABLE 12.3

### CLINICAL DIAGNOSTIC CRITERIA FOR ACUTE SALPINGITIS

- |   |       |
|---|-------|
| <ul style="list-style-type: none"> <li>◆ Abdominal tenderness</li> <li>◆ Rebound tenderness (±).</li> <li>◆ Cervical and uterine motion tenderness.</li> <li>◆ Adnexal tenderness.</li> </ul> | Box-A |
|---|-------|

- |  |       |
|--|-------|
| <ul style="list-style-type: none"> <li>◆ Temperature (&gt; 38°C).</li> <li>◆ Leucocytosis (&gt; 10,000/mm<sup>3</sup>).</li> <li>◆ Purulent material from peritoneal cavity by laparoscopy or by culdocentesis (p. 131).</li> <li>◆ Pelvic abscess or tubo-ovarian mass on bimanual examination or on sonography.</li> </ul> | Box-B |
|--|-------|

Presence of all the features from Box-A and any one or more from Box-B are required for diagnosis.

### COMPLICATIONS OF ACUTE SALPINGITIS:

- (i) Pelvic or generalized peritonitis (ii) Pelvis cellulitis (iii) Pelvic thrombophlebitis (iv) Pelvic abscess (v) Tubo-ovarian abscess.

### FATE OF ACUTE SALPINGITIS

**Complete resolution:** Provided the tissue destruction is not appreciable, the tube returns to its normal structure and function.

But endosalpingitis too often produces loss of cilia which is responsible for **infertility** or delay in transport of the fertilized ovum, resulting in **ectopic pregnancy (10%)**.

**Chronic:** The infection may be chronic due to reinfection or flaring up of the infection at the site.

**Recurrent acute PID** is observed in about 25% cases.

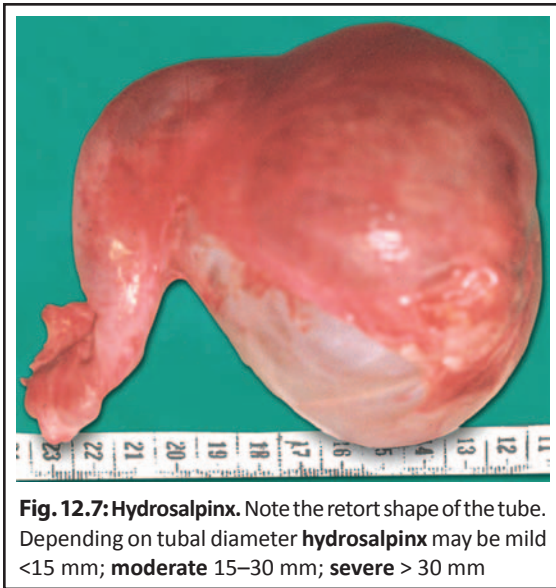
## CHRONIC SALPINGITIS

### PATHOLOGY

- Hydrosalpinx.
- Pyosalpinx.
- Chronic interstitial salpingitis.
- Salpingitis isthmica nodosa.

### Hydrosalpinx

Collection of mucus secretion into the fallopian tube is called hydrosalpinx.



**Fig. 12.7: Hydrosalpinx.** Note the retort shape of the tube. Depending on tubal diameter **hydrosalpinx** may be mild <15 mm; **moderate** 15–30 mm; **severe** > 30 mm

**Pathogenesis:** It is usually due to the end result of repeated attacks of mild endosalpingitis by pyogenic organisms of low virulence but highly irritant. The organisms involved are *Staphylococcus*, *E. coli*, *Gonococcus*, *Chlamydia trachomatis*, etc.

During initial infection, the fimbriae are edematous and indrawn with the serous surface, adhering together to produce closure of the abdominal ostium.

The uterine ostium gets closed by congestion. The secretion is pent up to make the tube distended. The distension is marked on the ampullary region than the more rigid isthmus. As the mesosalpinx is fixed, the resultant distension makes the tube curled and **looks ‘retort’-shaped**. The wall is smooth and shiny containing clear fluid inside, which is usually sterile (Figs. 12.7 and 37.55).

The uterine ostium is not closed anatomically, thus favors repeated infection. At times, there is intermittent discharge of the fluid into the uterine cavity (**intermittent hydrosalpinx or hydrops tubal profluens**).

**Hydrosalpinx** is also considered as the end stage of pyosalpinx when the pus becomes liquefied to make the fluid clear.

#### Ultrasound and Color Doppler (TVS)

Sausage-shaped complex cystic structure with reduced resistance index (RI) in the adnexal region is suggestive of the diagnosis (Fig. 12.8).

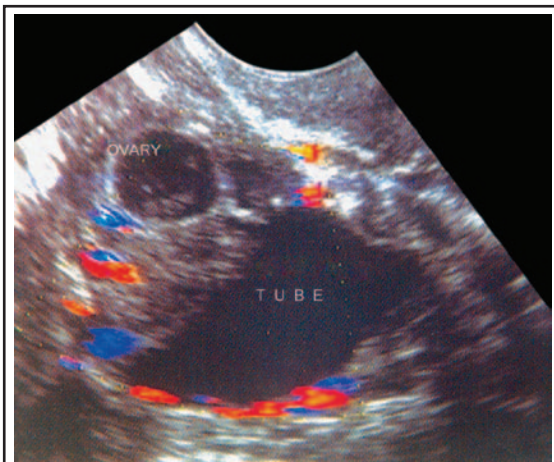
#### Complications

The following may happen : (i) Formation of tubo-ovarian cyst (ii) Torsion (iii) Infection from the gut (iv) Rupture.

**Pyosalpinx:** The pyogenic organisms, if become virulent, produce intense inflammatory reaction

**TABLE 12.4** COMPARATIVE FEATURES OF GONOCOCCAL AND PYOGENIC SALPINGITIS

Gonococcal	Pyogenic
♦ Sexually transmitted	Endogenous organisms
♦ Infection occurs usually during and following menstruation	Following abortion and childbirth
♦ <b>Mode of infection</b> —by continuity and contiguity (Fig. 10.1)	Through lymphatics and veins → pelvic cellulitis → tubal affection (Fig. 10.2)
♦ Always bilateral affection	May be unilateral
♦ Pathology <ul style="list-style-type: none"> <li>(i) Endosalpingitis</li> <li>(ii) Intraluminal exudation ++</li> <li>(iii) Closure of the abdominal ostium by indrawn fimbriae → pyosalpinx</li> <li>(iv) Peritoneal coat is less involved, adhesions—scanty and flimsy</li> </ul>	Pathology <ul style="list-style-type: none"> <li>(i) Perisalpingitis (predominantly)</li> <li>(ii) Less</li> <li>(iii) Closure by adhesions. May remain patent</li> <li>(iv) More involvement and as such adhesions are more and dense</li> </ul>
♦ Pus becomes sterile by 6 weeks → hydrosalpinx	Takes longer time (≥ 1 year), may have recurrent attack
♦ Restoration of reproductive function is unlikely.	May be possible

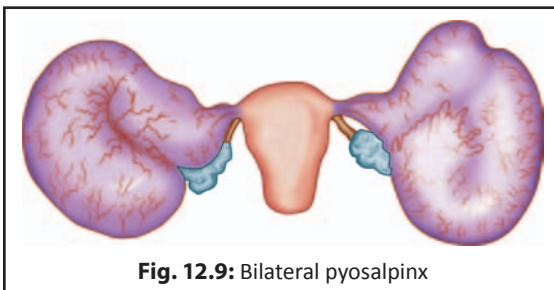


**Fig. 12.8:** Color Doppler scan (TVs) showing ovary and the tube with hydrosalpinx change

with secretion of pus. The tube becomes closed at both ends; the abdominal ostium by adhesions of the fimbriae and the uterine end by exudate. Because of intense inflammatory reaction and/or escape of pus into the peritoneal cavity, there is dense adhesions with the surrounding structures like ovaries, intestines, omentum, and pelvic peritoneum. Thus, a tubo-ovarian mass is formed. The inner wall of the tube is replaced in part by granulation tissue (Figs 12.9 and 12.11).

### Chronic Interstitial Salpingitis

The tube enlarges mainly due to great thickness of the wall. The distension of the tube by the exudate is unusual. The abdominal ostium may be closed or partially open. The adjacent organs are adherent to the tube. Microscopically, there is extensive infiltration of plasma cells and histiocytes in all the layers. The epithelium is usually intact. There is intense fibrosis of the muscle coat along with inflammatory changes.



**Fig. 12.9:** Bilateral pyosalpinx

This hinders the tubal motility and favors ectopic pregnancy.

### Salpingitis Isthmica Nodosa

**Pathogenesis:** The exact nature still remains unclear.

**The following are the probabilities:**

- (i) It is related to tubercular infection, although it may be the residue of any form of chronic interstitial salpingitis.
- (ii) There is infiltration of the tubal mucosa directly into the muscularis resembling adenomyosis of the uterus.
- (iii) It is one form of endometriosis of the tube. Absence of endometrial stroma, however, points against it.

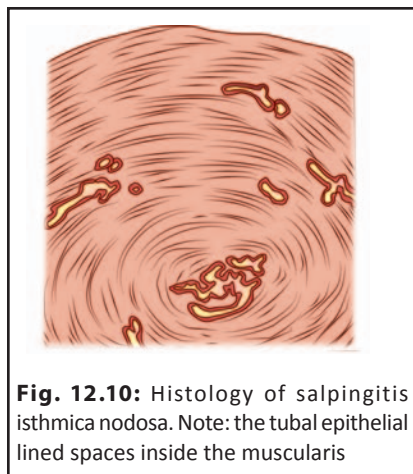
**Naked eye examination** reveals one or two nodules in the isthmus of the tube, often involving the uterine cornu. The nodule is small but may be as large as 2 cm.

**Microscopically**, there is thickening of the muscularis in which the tubal epithelium lined spaces are scattered, giving an adenomatous picture. There may be inconsistent mild inflammatory reaction (Fig. 12.10).

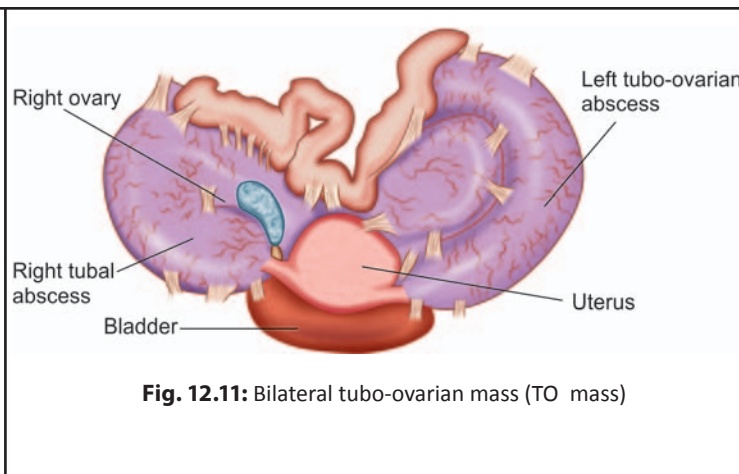
The clinical features and investigations of **salpingitis have already been described in the p. 170 (Table 12.3).**

### TREATMENT OF ACUTE SALPINGITIS/ PERITONITIS (REGIMENS RECOMMENDED BY CDC 2006)

- **Outpatient therapy:** (i) Ofloxacin 400 mg PO twice daily for 14 days plus metronidazole 500 mg PO twice daily for 14 days (see Table 10.4) are given. Patient is admitted for inpatient therapy if there is no response by 72 hours.
- **Inpatient therapy** (Temp  $>39^{\circ}\text{C}$ , toxic look, lower abdominal guarding, and rebound tenderness). Clindamycin 900 mg IV 8 hourly, plus gentamicin 2 mg/kg IV, then 1.5 mg/kg IV every 8 hours are given. This is followed by doxycycline 100 mg twice daily orally for 14 days. IV fluids to correct dehydration and nasogastric suction in the presence of abdominal distension or ileus are maintained. Laparotomy is done if there is clinical suggestion of abscess rupture.



**Fig. 12.10:** Histology of salpingitis isthmica nodosa. Note: the tubal epithelial lined spaces inside the muscularis



**Fig. 12.11:** Bilateral tubo-ovarian mass (TO mass)

### PROGNOSIS OF SALPINGITIS

With early diagnosis and therapy with potent antibiotics, the immediate risk is markedly reduced. With effective therapy, the prospect of future reproductive function of the tube is not so gloomy. But once the cilia is damaged, commonly with gonococcal infection or pyogenic infection (repeated), the prospect of future fertility is very much poor even with reconstructive surgery. Even if pregnancy occurs, chances of ectopic is more (10–15%).

### OOPHORITIS

Isolated infection to the ovaries is a rarity. The ovaries are almost always affected during salpingitis and as such the nomenclature of salpingo-oophoritis is preferred. **The affection of the ovary from tubal infection occurs by the following routes:**

- ◆ Directly from the exudates contaminating the ovarian surface producing perioophoritis.
- ◆ Through lymphatics of the mesosalpinx and mesovarium producing interstitial oophoritis.
- ◆ Blood borne—mumps.
- ◆ Through the rent of the ovulation producing interstitial oophoritis.

If the organisms are severe, an abscess is formed and a tubo-ovarian abscess results. In others, the

ovaries may be adherent to the tubes, intestine, omentum, and pelvic peritoneum producing tubo-ovarian mass (TO mass). Such a mass is usually bilateral (Fig. 12.11).

**Direct affection of the ovaries without tubal involvement** may be due to mumps or influenza. In mumps, there is no sterilizing effect on the ovaries unlike testes. This is because the capsule of the ovary is elastic and as such, ischemic injury to the graafian follicles is not likely. Even if some follicles are damaged, many are left behind to carry on the reproductive function.


The symptomatology and treatment are like those of salpingitis.

### PARAMETRITIS

Inflammation of the pelvic cellular tissue is called parametritis.

#### Etiology—(Source of Infection)

- ◆ Delivery and abortion through placental site or from lacerations of the cervix, vaginal vault, or lower uterine segment.
- ◆ Acute infections of the cervix, uterus, and tubes.
- ◆ Cesarean section or hysterectomy-abdominal or vaginal (cuff cellulitis).
- ◆ Secondary to pelvic peritonitis.
- ◆ Carcinoma cervix or radium introduction.



### Pathology

The causative organisms are anaerobic *Streptococcus*, *Staphylococcus*, *E. coli*, bacteroides species (*fragilis*, *fusobacteria*) etc. There is intense hyperemia with exudation of serous fluid, lymph, and polymorphonuclear leukocytes. The exudate may resolve completely or an abscess is formed. The purulent exudate may be localized or may have extrapelvic extension along the tract of blood vessels and ureter. The abscess thus points towards the perinephric region along the ureter, to the buttock along the gluteal vessels, to the thigh along the external iliac vessels and to the groin above the inguinal ligament.

Rarely, the abscess may burst into the pelvic organs, or into the peritoneal cavity. There may be associated pelvic thrombophlebitis with chance of 'white leg' and pyemia.

### Clinical features: ■ Acute ■ Chronic

**Acute:** The onset is usually insidious and appears about 7–10 days following initial infection.

The temperature rises to about 102°F. Pain is not a prominent feature, may be dull aching deep in the pelvis.

**On examination,** the pulse rate is raised proportionate to the temperature. There is generalized deep tenderness on lower abdomen. Rigidity is absent because the lesion is extraperitoneal. Pelvic examination reveals hot and tender vagina. There is an indurated tender mass usually unilateral, which extends to the lateral pelvic wall and to which the

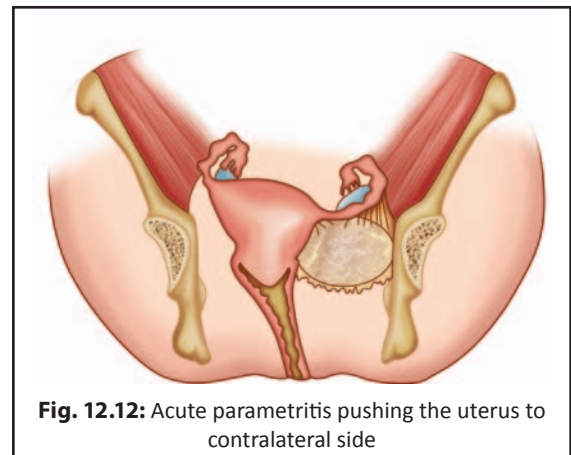
uterus is firmly fixed. The uterus is pushed to the contralateral side (Fig. 12.12).

Rectal examination confirms the indurated tender mass or horse shoe-shaped induration of the uterosacral ligaments surrounding the rectum.

**An abscess formation is featured by** spiky rise of temperature, toxic look, and fluctuant swelling in the regions mentioned earlier.

**Chronic:** The clinical features vary, as it is often associated with chronic salpingo-oophoritis and as such, the symptoms and signs are overshadowed by the latter condition.

The chief complaint is chronic deep seated pelvic pain, may be localized to one side. There is deep dyspareunia.



**Fig. 12.12:** Acute parametritis pushing the uterus to contralateral side



Pelvic examination reveals the uterus fixed to an indurated and tender mass. The uterus is also drawn to the affected side because of scarring. Movement of the cervix produces pain. **Ultrasonography** can localize the abscess with its site and extent.

### Treatment

**Acute:** The outline of management protocol is the same like that of acute salpingitis of pyogenic origin.

Only when an abscess is pointing and easily accessible that it should be drained surgically.

**Chronic:** The treatment is the same as for chronic salpingo-oophoritis. Deep pelvic short wave diathermy may be tried to relieve pain and dyspareunia. Too often, all the measures fail, hysterectomy decision may have to be considered even at an early age specially in women whose family is completed.

## PELVIC ABSCESS

**Encysted pus in the pouch of Douglas is called pelvic abscess.**

### Etiology:

#### Pelvic causes (common)

- ▶ Postabortal and puerperal sepsis.
- ▶ Acute salpingitis.
- ▶ Perforation of an infected uterus such as attempted uterine curettage in septic abortion or pyometra.
- ▶ Infection of pelvic hematocele usually following disturbed tubal pregnancy.
- ▶ Postoperative pelvic peritonitis following abdominal or vaginal operation.
- ▶ Irritant peritonitis following contamination of urine, bile, vernix caseosa, meconium (spilled during cesarean section), iodine containing dye used in hysterosalpingography or contents of ruptured ovarian cyst (sebum in dermoid cyst), etc.

#### Extrapelvic causes (rare)

Appendicitis, diverticulitis, ruptured gallbladder, perforated peptic ulcer usually produce generalized peritonitis. The condition may ultimately settle to the dependent pouch of Douglas and produces pelvic abscess.

**Clinical features:** Patient is ill from any of the causative factors mentioned earlier. **But the localization of pus in the pouch of Douglas is evidenced by:**

### Symptoms

- ◆ Spiky rise of high temperature with chills and rigor.
- ◆ Rectal tenesmus—frequent passage of loose mucoid stool.
- ◆ Pain lower abdomen—variable degrees.
- ◆ Urinary symptoms—difficulty or even retention of urine.

### Signs

**General:** The face is flushed with anxious look. Pulse rate is raised out of proportion to temperature.

#### Per abdomen:

- Tenderness and rigidity in lower abdomen.
- A mass may be felt in the suprapubic region—tender, irregular, soft, and resonant on percussion.

#### Per vaginam:

- The vagina is hot and tender.
- The uterus is pushed anteriorly; the movement of the cervix is painful.
- A boggy, fluctuant, and tender mass is felt in the pouch of Douglas.
- A separate mass may be felt through the lateral fornix.

Rectal examination defines precisely the mass in the pouch of Douglas.

### Investigations

**Blood:** There is high leukocytosis with increased polymorphs.

**Bacteriological study:** Swabs are taken from high vagina, endocervical canal and from the pus. Culture is done for both aerobic and anaerobic microorganisms. Sensitivity of the microorganisms to antibiotics is also to be detected.

### Confirmation of Diagnosis

The diagnosis is easy in most of the cases but at times confusion arises between pelvic hematocele and pelvic abscess. **Pelvic ultrasonography** reveals accumulation of fluid in the pouch of Douglas. **Examination under anesthesia (EUA) and puncture of pouch of Douglas (culdocentesis)** give the correct diagnosis. Old blood comes out in the former and pus in the latter.

### Treatment

**General:** Systemic antibiotics should cover anaerobic as well as aerobic microorganisms (broad spectrum): Cefoxitin 1–2 gm IV every 6–8 hours and gentamicin 2 mg/kg IV per 24 hours and metronidazole 500 mg IV 8 hourly are started. Antibiotic regimen may have to be changed depending upon the sensitivity report.

**Surgery:** **Posterior colpotomy** is the definitive surgery to drain the pus through posterior fornix. The loculi should be broken with finger.

**Laparotomy** is done when the patient's condition deteriorates despite aggressive management. In patients with recurrent infection and with loss of reproductive function total abdominal hysterectomy with bilateral salpingo-oophorectomy is the preferred treatment.

**The pus should be sent for culture and drug sensitivity test.**

### SYNDROMIC MANAGEMENT OF SEXUALLY TRANSMITTED INFECTIONS (WHO – 1991)

**Principle:** Treatment of STDs should be initiated at the patient's first visit to a clinic. At the same time, the

couple is counseled about the importance of condom use and prevention of STD transmission.

Syndromic managements are based on epidemiological studies all over the world. Syndromic diagnosis and laboratory assisted diagnosis have been found similar in terms of accuracy.

**Method:** Management is done by criteria for syndromic diagnosis of PID. These include detection of vaginal discharge (p. 166), abdominal pain, cervical motion tenderness, bilateral adnexal tenderness, and negative pregnancy test. Healthcare providers are trained up to follow a standardized protocol (flowcharts) to treat such a patient. This is particularly suitable in a healthcare setting of developing countries.

#### Advantages:

- ◆ It avoids delay of treatment, where laboratory facilities are limited.
- ◆ It avoids loss of patient follow up, where referral system is not well-structured.
- ◆ Continued transmission of infection is prevented.
- ◆ It is a simple, inexpensive, and rapid management for STDs.

### KEY POINTS

- ▶ In recurrent vulvitis due to fungal infection, diabetes is to be excluded.
- ▶ Bartholin's cyst usually develops in the duct. The gratifying treatment is marsupialization under local anesthesia. A normal Bartholin's gland cannot be palpated.  
Excision of Bartholin's duct and gland is indicated for persistent and/or recurrent infections specially when it occurs beyond the age of 40.
- ▶ During childbearing period, vaginal trichomoniasis is the commonest STD caused by *Trichomonas vaginalis*—a flagellated parasite. Hanging drop preparation with identification of trichomonas is diagnostic. Treatment is specific with metronidazole to both partners. The husband is to use condom during treatment. Vaginitis may be due to other causes also (p. 164).
- ▶ A vaginal discharge with pH >5.0 indicates atrophic vaginitis, bacterial vaginosis, or trichomonas infection whereas a vaginal discharge with pH <4.5 may be either physiologic or due to fungal infection. Vaginal discharge needs to be differentiated before treatment (Table 12.1)
- ▶ Moniliasis is caused by *Candida albicans*—a Gram-positive fungus. The infection is more likely related to diabetes, pregnancy, or amongst 'pill' users (p. 164). Diagnosis is by identification of the mycelia by direct smear and stained by methylene blue or culture in Sabouraud's media.

Contd...

Contd...

- Toxic shock syndrome is due to improper use of vaginal tampon. The causative organism is *Staphylococcus aureus*. Dysfunction of multiple organ system is due to the bacterial exotoxin (p. 166). Treatment is supportive.  $\beta$ -lactamase resistant anti-staphylococcal penicillin (cloxacillin, methicillin) should be the choice.
- The feature of senile endometritis may simulate endometrial carcinoma which should be ruled out prior to treatment. Common causes of pyometra are endometrial carcinoma, endocervical carcinoma, senile endometritis, infected hematometra, and tubercular endometritis.
- Pyogenic non-gonococcal organisms affect the tubes by producing perisalpingitis; gonococcal produces endosalpingitis and tubercular infection produces interstitial salpingitis.
- The organisms producing hydrosalpinx are *Staphylococcus*, *Streptococcus*, *E. coli*, *Gonococcus*, *Cl. trachomatis*, etc. Hydrosalpinx is the end result of repeated attacks of mild endosalpingitis. It may also be the end stage of pyosalpinx when the pus becomes liquefied. Prognosis of salpingitis in terms of reproductive function depends on the type of infection, severity, and number of episodes. When the cilia is damaged and or motility is impaired (adhesion), prospect is very poor.
- Salpingitis isthmica nodosa may be one variety of endometriosis or related to tubercular infection. Tube is nodular and thickened. There is proliferation of tubal epithelium within the muscle layer (mysosalpinx).
- Pelvic abscess is the encysted pus in the pouch of Douglas. The common causes are following acute salpingitis, postabortal sepsis, infected pelvic hemocele and postoperative pelvic peritonitis, etc.  
Confirmation of diagnosis is by culdocentesis and the definitive surgery is drainage of pus through posterior colpotomy.
- Endocervix is the major reservoir of pathogenic organisms. Most common site of *Chlamydia* infection in the female genital tract is the columnar cells of the endocervix.
- **Mode of spread of infection to the tubes are :** **Pyogenic infection** spreads through veins and lymphatics causing perisalpingitis and endosalpingitis. Cornual block following postabortal or puerperal sepsis may occur.  
**Gonococcal infection** ascends through continuity and contiguity causing endosalpingitis.  
**Tubercular infection** spreads through bloodstream (hematogenous) causing interstitial salpingitis.
- **Clinical diagnostic criteria for acute salpingitis include :** Abdominal tenderness, cervical or uterine motion tenderness, adnexal tenderness plus one or more other features (see p. 170).
- **Indication of surgery** for PID are restricted to life-threatening infection, not responding to medical therapy (e.g. tubo-ovarian abscess, pelvic abscess, or any clinical suspicion of abscess rupture).

# Dysmenorrhea and other Disorders of Menstrual Cycles

## DYSMENORRHEA

### Definition

Dysmenorrhea literally means painful menstruation. But a more realistic and practical definition includes cases of **painful menstruation of sufficient magnitude so as to incapacitate day-to-day activities.**



**Types:** ■ Primary ■ Secondary

### PRIMARY DYSMENORRHEA (Spasmodic)

The primary dysmenorrhea is one where there is no identifiable pelvic pathology.

**Incidence:** The incidence of primary dysmenorrhea of sufficient magnitude with incapacitation is about 15–20 percent. With the advent of oral contraceptives and non-steroidal anti-inflammatory drugs, there is marked relief of the symptom.

**Causes of pain:** The mechanism of initiation of uterine pain in primary dysmenorrhea is difficult to establish. **But the following are too often related.**

- ◆ Mostly confined to adolescents.
  - ◆ Almost always confined to ovulatory cycles.
  - ◆ The pain is usually cured following pregnancy and vaginal delivery.
  - ◆ The pain is related to dysrhythmic uterine contractions and uterine hypoxia.
1. **Psychosomatic factors** of tension and anxiety during adolescence; lower the pain threshold.
  2. **Abnormal anatomical and functional aspect of myometrium.**

**Uterine myometrial hyperactivity** has been observed in cases with primary dysmenorrhea.

The outer myometrium and the subendometrial myometrium are found to be different structurally and functionally. The subendometrial layer of myometrium is known as Junctional Zone (JZ). There is marked hyperperistalsis of the JZ in women with endometriosis and adenomyosis. In women with dysmenorrhea significant changes in JZ are seen. These include irregular thickening and hyperplasia of smooth muscle and less vascularity. This is known as **Junctional zone hyperplasia. Dysperistalsis and hyperactivity of the uterine JZ are the important mechanisms of primary dysmenorrhea.**

### 3. Imbalance in the autonomic nervous control of uterine muscle.

There is overactivity of the sympathetic nerves → hypertonicity of the circular fibers of the isthmus and internal os. The relief of pain following dilatation of the cervix or following vaginal delivery may be explained by the damage of the adrenergic neurons which fail to regenerate.

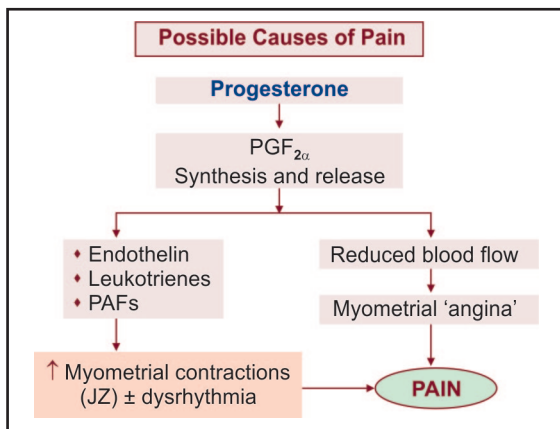
### 4. Role of prostaglandins

In ovulatory cycles, under the action of progesterone, prostaglandins ( $\text{PGF}_2\alpha$ ,  $\text{PGE}_2$ ) are synthesized from the secretory endometrium. Prostaglandins are released with maximum production during shedding of the endometrium.  $\text{PGF}_2\alpha$  is a strong vasoconstrictor, which causes ischemia (angina) of the myometrium.

Either due to increased production of the prostaglandins or increased sensitivity of the myometrium to the normal production of prostaglandins, there is increased myometrial contraction with or without dysrhythmia.

The possible cause of pain owing to JZ change is shown schematically below.

5. **Role of vasopressin:** There is increased vasopressin release during menstruation in women with primary dysmenorrhea. This explains the persistence of pain in cases even treated with antiprostaglandin drugs. The mechanism of action is yet to be explored. Vasopressin increases prostaglandin synthesis and also increases myometrial activity directly. It causes uterine hyperactivity and dysrhythmic contractions → ischemia and hypoxia → pain.
6. **Endothelins** causes myometrial smooth muscle contractions, specially in the endomyometrial Junction (JZ). Endothelins in endometrium can induce  $\text{PGF}_{2\alpha}$ . Local myometrial ischemia caused by **endothelins and  $\text{PGF}_{2\alpha}$  aggravate uterine dysperistalsis and hyperactivity.**
7. **Platelet activating factor (PAF)** is also associated with the etiology of dysmenorrhea as its concentration is found high. Leukotrienes and PAFs are vasoconstrictors and stimulate myometrial contractions.



**Patient profile:** Primary dysmenorrhea is predominantly confined to adolescent girls. It usually appears within 2 years of menarche. The mother or her sister may be dysmenorrheic. It is more common amongst girls from affluent society.

**Clinical features:** The pain begins a few hours before or just with the onset of menstruation. The severity of pain usually lasts for few hours, may extend to 24 hours but seldom persists beyond 48 hours. The

pain is spasmodic and confined to lower abdomen; may radiate to the back and medial aspect of thighs. Systemic discomforts like nausea, vomiting, fatigue, diarrhea, headache and tachycardia may be associated. It may be accompanied by vasomotor changes causing pallor, cold sweats and occasional fainting. Rarely, syncope and collapse in severe cases may be associated.

Abdominal or pelvic examination does not reveal any abnormal findings.

For detection of any pelvic abnormalities, **ultrasound** is very useful and it is not invasive.

**Treatment:** General measures include improvement of general health and simple psychotherapy in terms of explanation and assurance. Usual activities including sports are to be continued.

During menses, bowel should be kept empty; mild analgesics and antispasmodics may be prescribed. **Habit forming drugs such as pethidine or morphine must not be prescribed.** With these simple measures, the pain is relieved in majority.

**Severe cases:** ♦ **Drugs** ♦ **Surgery**

**Drugs:** The drugs used are—

- ♦ Prostaglandin synthetase inhibitors (Table 13.1).
- ♦ Oral contraceptives (combined estrogen and progestogen).

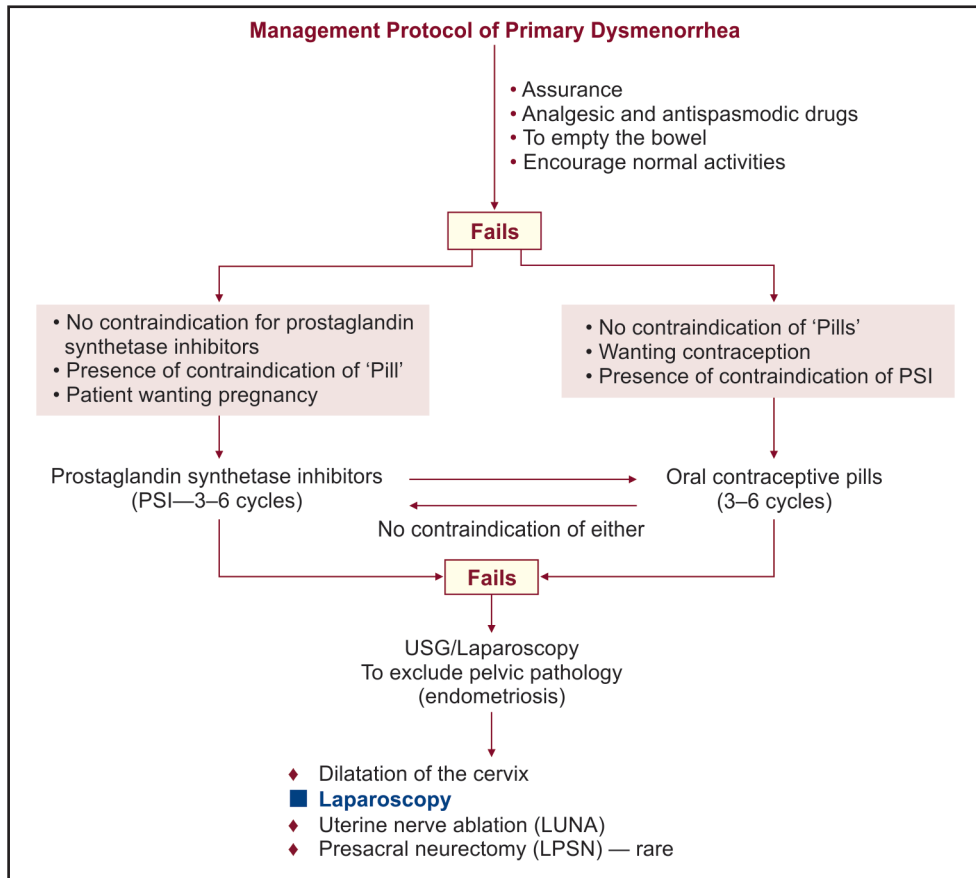
### *Prostaglandin synthetase inhibitors (PSI)*

These drugs not only reduce the prostaglandin synthesis (by inhibition of cyclo-oxygenase enzyme) but also have a direct analgesic effect. Intrauterine pressure is reduced significantly. Any of the preparations listed in the table can be used orally for 2–3 days starting with the onset of period. The drug should be continued for 3–6 cycles.

**TABLE 13.1** COMMONLY USED NSAIDs

- ♦ **Fenamate group** — Mefenamic acid 250–500 mg 8 hourly or Flufenamic acid 100–200 mg 8 hourly.
- ♦ **Propionic acid derivatives** — Ibuprofen 400 mg 8 hourly or Naproxen 250 mg 6 hourly.
- ♦ **Indomethacin** 25 mg 8 hourly.

**Newer drugs** NSAIDs (Table 13.1) inhibit two different isoforms of the enzyme cyclo-oxygenase:



COX-1 and COX-2. Selective inhibitors of the enzyme COX-2 may have similar analgesic efficacy but fewer side effects.

Transdermal use of smooth muscle relaxant glyceryl trinitrate is also used currently.

**The suitable cases are**—comparatively young age and having contraindications to 'pill'. The contraindications of its use include allergy to aspirin, gastric ulceration and history of asthma.

**Oral contraceptive pills:** The suitable candidates are patients (i) wanting contraceptive precaution, (ii) with heavy periods and (iii) unresponsive or contraindications to anti-prostaglandin drugs. The pill should be used for 3–6 cycles.

**Dydrogesterone:** It does not inhibit ovulation but probably interferes with ovarian steroidogenesis. The drug should be taken from day 5 of a cycle for 20 days. It should be continued for 3–6 cycles.

If the above protocol fails, laparoscopy is indicated to find out any pelvic pathology to account for pain, the important one being endometriosis.

**Surgery: Transcutaneous electrical nerve stimulation (TENS)** has been used to relieve dysmenorrhea. Results are not better than that of analgesics.

**Surgical procedures:** Laparoscopic uterine nerve ablation (LUNA) for primary dysmenorrhea has not been found beneficial. **Laparoscopic presacral neurectomy** is done to cut down the sensory pathways (via T<sub>11</sub>–T<sub>12</sub>) from the uterus. It is not helpful for adnexal pain (T<sub>9</sub>–T<sub>10</sub>) as it is carried out by thoracic autonomic nerves along the ovarian vessels. As such its role in true dysmenorrhea is questionable.

**Dilatation of cervical canal:** It is done under anesthesia for slow dilatation of the cervix to relieve pain by

damaging the sensory nerve endings. It is not commonly done. Late sequela may be cervical incompetence.

### SECONDARY DYSMENORRHEA (Congestive)

Secondary dysmenorrhea is normally considered to be menstruation — associated pain occurring in the presence of pelvic pathology.

**Causes of pain:** The pain may be related to increasing tension in the pelvic tissues due to pre-menstrual pelvic congestion or increased vascularity in the pelvic organs.

**Common causes of secondary dysmenorrhea:** Cervical stenosis, chronic pelvic infection, pelvic endometriosis, pelvic adhesions, adenomyosis, uterine fibroid, endometrial polyp, IUCD *in utero* and pelvic congestion. Obstruction due to mullerian malformations are the other causes.

**Patient profile:** The patients are usually in their thirties; more often parous and unrelated to any social status.

**Clinical features:** The pain is dull, situated in the back and in front without any radiation. It usually appears 3–5 days prior to the period and relieves with the start of bleeding. The onset and duration of pain depends on the pathology producing the pain. There is no systemic discomfort unlike primary dysmenorrhea. The patients may have got some discomfort even in between periods. There are symptoms of associated pelvic pathology.

Abdominal and vaginal examinations usually reveal the offending lesion. At times, the lesion is revealed by laparoscopy, hysteroscopy or laparotomy

**Treatment:** The treatment aims at the cause rather than the symptom. The type of treatment depends on the severity, age and parity of the patient.

TABLE 13.2

#### CAUSES OF UNILATERAL DYSMENORRHEA

- ◆ Ovarian dysmenorrhea
- ◆ Bicornuate uterus
- ◆ Unilateral location of pelvic endometriosis
- ◆ Small fibroid polyp near one cornu
- ◆ Right ovarian vein syndrome
- ◆ Colonic or cecal spasm

### Ovarian Dysmenorrhea

**Right ovarian vein syndrome:** Right ovarian vein crosses the ureter at right angle. During premenstrual period, due to pelvic congestion or increased blood flow, there may be marked engorgement in the vein → pressure on ureter → stasis → infection → pyelonephritis → pain.

### MITTELSCHMERZ'S SYNDROME (Ovular Pain)

Ovular pain is not an infrequent complaint. It appears in the midmenstrual period. The pain is usually situated in the hypogastrium or in either iliac fossa. The pain is usually located on one side and does not change from side to side according to which ovary is ovulating. Nausea or vomiting is conspicuously absent. It rarely lasts more than 12 hours. It may be associated with slight vaginal bleeding or excessive mucoid vaginal discharge.

The exact cause is not known. **The probable factors are:** (i) Increased tension of the Graafian follicle just prior to rupture, (ii) Peritoneal irritation by the follicular fluid following ovulation and (iii) Contraction of the tubes and uterus.

Treatment is effective with assurance and analgesics. In obstinate cases, the cure is absolute by making the cycle anovular with contraceptive pills.

### PELVIC CONGESTION SYNDROME

There is disturbance in the autonomic nervous system, which may lead to gross vascular congestion with pelvic varicosities. The patient has a congestive type of dysmenorrhea without any demonstrable pelvic pathology.

**Diagnosis** is made by physical examination, radiologic study (pelvic venography), Doppler scan, duplex ultrasound scans, CT, MRI or angiography. Laparoscopic diagnosis is difficult, as with intraperitoneal pressure and Trendelenberg position, these vessels may be compressed but will reappear as the pressure is reduced.

**The patient complains** of vague disorders with backache and pelvic pain with long standing position,

at times with dyspareunia. There may be menorrhagia or epimenorrhea. The uterus may feel bulky and boggy.

**The treatment** is unsatisfactory. Medroxy progesterone acetate (MPA) 50 mg daily for 4 months was found effective. In parous women with advancing age, hysterectomy may relieve the symptoms.

### PREMENSTRUAL SYNDROME (PMS) (Syn: Premenstrual Tension)

Premenstrual syndrome (PMS) is a psychoneuroendocrine disorder of unknown etiology, often noticed just prior to menstruation. There is cyclic appearance of a large number of symptoms during the last 7–10 days of the menstrual cycle. **It should fulfil the following criteria (ACOG):**

- ◆ Not related to any organic lesion.
- ◆ Regularly occurs during the luteal phase of each ovulatory menstrual cycle.
- ◆ Symptoms must be severe enough to disturb the life style of the woman or she requires medical help.
- ◆ Symptom-free period during rest of the cycle.

When these symptoms disrupt daily functioning they are grouped under the name **premenstrual dysphoric disorder (PMDD)**.

**Pathophysiology:** The exact cause is not known but the **following hypotheses are postulated:**

- (a) Alteration in the level of estrogen and progesterone starting from the midluteal phase. Either

there is altered estrogen: progesterone ratio or diminished progesterone level.

- (b) Neuroendocrine factors:

- ◆ **Serotonin** is an important neurotransmitter in the CNS. During the luteal phase, decreased synthesis of serotonin is observed in women suffering from PMS.
- ◆ **Endorphins:** The symptom complex of PMS is thought to be due to the withdrawal of endorphins (neurotransmitters) from CNS (see ch. 7) during the luteal phase.
- ◆  **$\gamma$ -aminobutyric acid (GABA)** suppresses the anxiety level in the brain. Medications that are GABA agonist, are effective.

- (c) Psychological and psychosocial factors may be involved to produce behavioral changes.

- (d) Others: Variety of factors have been mentioned to explain the symptom complex of PMS. These are thyrotrophin releasing hormone (TRH) prolactin, renin, aldosterone, prostaglandins, and others. Unfortunately, nothing is conclusive.

**Clinical features:** PMS is more common in women aged 30–45. It may be related to childbirth or a disturbing life event.

There are no abnormal pelvic findings excepting features of pelvic congestion.

### TREATMENT

As the etiology is multifactorial and too often obscure, various drugs are used either on speculation or empirically with varying degrees of success. **Life style modification and cognitive behavior therapy are important steps.**

#### GENERAL

- **Nonpharmacological:** (a) Assurance, Yoga, Stress management, Diet manipulation. (b) Avoidance of salt, caffeine and alcohol specially in second half of cycle improves the symptoms.
- **Nonhormonal:**

(a) Tranquilizers or antidepressant drugs, may be of help logically.

(b) Pyridoxine – 100 mg twice daily is helpful by correcting tryptophan metabolism specially following ‘pill’ associated depression.

TABLE 13.3

#### SYMPTOMATOLOGY OF PMS AND PMDD

Related to water retention	<ul style="list-style-type: none"> <li>• Abdominal bloating</li> <li>• Breast tenderness</li> <li>• Swelling of the extremities</li> <li>• Weight gain</li> </ul>
Neuropsychiatric symptoms	<ul style="list-style-type: none"> <li>• Irritability</li> <li>• Depression</li> <li>• Mood swings</li> <li>• Forgetfulness</li> <li>• Restlessness</li> <li>• Increased appetite</li> <li>• Tearfulness</li> <li>• Anxiety</li> <li>• Tension</li> <li>• Confusion</li> <li>• Headache</li> <li>• Anger</li> </ul>
Behavioral symptoms	<ul style="list-style-type: none"> <li>• Fatigue</li> <li>• Dyspareunia</li> <li>• Tiredness</li> <li>• Insomnia</li> </ul>



- (c) Diuretics in the second half of the cycle – Frusemide 20 mg daily for consecutive 5 days a week reduces fluid retention.
- (d) **Anxiolytic agents** are found to be helpful to women having persistent anxiety. Alprazolam (0.25 mg, BID) is given during the luteal phase of the cycle.
- (e) **Selective Serotonin Reuptake Inhibitors (SSRI)** and **Noradrenaline Reuptake Inhibitors (SNRI)** are found to be very effective.

**Fluoxetine** is an antidepressant that inhibits neuronal uptake of serotonin (SSRI). A single oral dose of 20 mg was found to improve the psychiatric and behavioral symptoms significantly.

The drugs are usually prescribed at least two days prior to the onset of symptoms and to be continued till menstruation starts.

**Other drugs used are:** Sertaline (50 mg/day) and Venlafaxine.

- **Hormones:** Any one of the following drugs is to be prescribed:
  - ◆ **Oral contraceptive pills:** The idea is to suppress ovulation and to maintain an uniform hormonal milieu. The therapy is to be continued for 3–6 cycles. Newer OCPs contain progestin drospirenone. It has antimineralocorticoid and antiandrogenic properties. Drospirenone containing OCPs are found to have better control of symptoms.
  - ◆ **Progesterone** is not effective in treating PMS. Levonorgestrel intrauterine system (IUS) had been used to suppress ovarian cycle.
  - ◆ **Spirolactone:** It is a potassium sparing diuretic. It has anti-mineralocorticoid and

anti-androgenic effects. It is given in the luteal phase (25–200 mg/day). It improves the symptoms of PMDD.

- ◆ **Bromocriptine:** 2.5 mg daily or twice daily may be helpful, at least to relieve the breast complaints.
- **Suppression of ovarian cycle:** Suppression of the endogenous ovarian cycle can be achieved by:
  - ◆ **Danazol** 200 mg daily is to be adjusted so as to produce amenorrhea. Barrier method of contraception should be advised during the treatment.
  - ◆ **GnRH analogues (p. 525)**— The gonadal steroids are suppressed by administration of GnRH agonist for 6 months (medical oophorectomy). GnRH analogues in PMS are used: (i) To assess the role of ovarian steroids in the aetiology of PMS. (ii) This can also predict whether bilateral oophorectomy would be of any help or not. The preparations and doses used are as given (see p. 525).
    - Goserelin (Zoladex): 3.6 mg is given subcutaneously at every 4 weeks.
    - Leuprorelin acetate (Prostap): 3.75 mg is given by SC or IM at every 4 weeks.
    - Triptorelin (Decapeptyl): 3 mg is given IM every 4 weeks.

#### **Results of GnRH agonist therapy are dramatic.**

GnRH agonist therapy is combined with estrogen progestin “add-back” (see p. 526) to combat the hypoestrogenic symptoms.

#### • **Oophorectomy**

In established cases of primary PMS with recurrence of symptoms and approaching to menopause, hysterectomy with bilateral oophorectomy is a last resort.

## KEY POINTS

- ▶ Dysmenorrhea is painful menstruation of sufficient magnitude so as to incapacitate the day-to-day activities. The incidence of primary dysmenorrhea is about 15–20 percent.

Primary dysmenorrhea is almost always confined to ovulatory cycle and relieved following pregnancy and vaginal delivery. The pain usually appears following painless periods after menarche.

While primary dysmenorrhea occurs before the age of 20, secondary dysmenorrhea may occur at any age.

- ▶ Uterine Junctional Zone (JZ) dysperistalsis and hyperactivity are the basic pathological area for primary dysmenorrhea. The biochemical mediators involved are : Progesterone,  $\text{PGF}_{2\alpha}$ , endothelin, PAFs and leukotrienes.

Prostaglandin synthetase inhibitors (NSAIDs) or oral contraceptives or dydrogesterone are usually effective to minimise pain. Only cervical dilatation is required in obstinate cases. Secondary dysmenorrhea is almost always secondary to other pelvic pathology such as PID, endometriosis or uterine fibroids or obstruction due to Mullerian malformations.

- ▶ Combined oral contraceptives reduce the severity of dysmenorrhea. It is the drug of choice when contraception is required.
- ▶ In ovarian dysmenorrhea, the pain is referred to the area innervated by T<sub>10</sub> to L<sub>1</sub> segments.
- ▶ Right ovarian vein syndrome is due to engorgement of right ovarian vein premenstrually so as to compress the right ureter with resultant pyelonephritis and pain.
- ▶ Pain due to pelvic venous congestion is relieved by continuous high dose MPA.
- ▶ Mittelschmerz's syndrome (ovular pain) — is an indirect evidence of ovulation — occurring in the midmenstrual period.
- ▶ Premenstrual syndrome (PMS) regularly occurs in the luteal phase of each ovulatory menstrual cycle.

There is no impairment of corpus luteal function for a woman who suffers from PMS. The symptoms are grouped together and described under the name PMDD (p. 182).

Women with PMDD show no deficit in cognitive function in the luteal phase.

Exact etiology is unknown. Altered estrogen : progesterone ratio; reduced circulatory level of neurotransmitters (serotonin, GABA or endorphins) in the CNS may be responsible for the symptom complex.

The symptoms are not specific (Table 13.3) and there is usually no abnormal pelvic finding.

The most useful diagnostic tool for PMS is patient's symptom diary (Table 13.3).

Treatment is supportive. Of the measures used in the management of PMS, beneficial effects are observed with selective serotonin reuptake inhibitors (SSRI). Bromocriptine is effective in relieving breast tenderness. In obstinate cases, hormones — LNG-IUS, danazol are found helpful. Results of GnRH agonist therapy are dramatic. Tranquillizers (alprazolam – 0.25 mg) and/or antidepressants (fluoxetine 20 mg daily or sertraline 50 mg/day) significantly improve the symptoms. Oral contraceptive pills suppressing ovulation, calcium, aerobic exercise are helpful in relieving symptoms of PMDD.

In proved cases — relief of symptoms producing amenorrhea either by danazol or GnRH analogues for 3 months can be achieved. Hysterectomy with bilateral salpingo-oophorectomy in patients approaching menopause may be an option.

# Abnormal Uterine Bleeding

## MENORRHAGIA (Syn: Hypermenorrhea)

### Definition

Menorrhagia is defined as cyclic bleeding at normal intervals; the bleeding is either excessive in amount (>80 mL) or duration (>7 days) or both. The term menotaxis is often used to denote prolonged bleeding.

**Causes:** Menorrhagia is a symptom of some underlying pathology—organic or functional.

#### ■ Organic

**Pelvic:** The causes are tabulated in Tables 14.1 and 14.2.

**TABLE 14.1** PELVIC PATHOLOGY

Due to congestion, increased surface area, or hyperplasia of the endometrium

- ◆ Fibroid uterus
- ◆ Adenomyosis
- ◆ Pelvic endometriosis
- ◆ IUCD *in utero*
- ◆ Chronic tubo-ovarian mass
- ◆ Tubercular endometritis (early cases)
- ◆ Retroverted uterus—due to congestion
- ◆ Granulosa cell tumor of the ovary

**Systemic:** Liver dysfunction—failure to conjugate and thereby inactivates the estrogens.

- ▶ Congestive cardiac failure.
- ▶ Severe hypertension.

### Endocrinal

- ▶ Hypothyroidism.
- ▶ Hyperthyroidism.

### Hematological

- ▶ Idiopathic thrombocytopenic purpura.
- ▶ Leukemia. ▶ von Willebrand's disease.
- ▶ Platelet deficiency.

### Emotional upset

#### ■ Functional

Due to disturbed hypothalamo-pituitary-ovarian-endometrial axis.

**TABLE 14.2** COMMON CAUSES OF MENORRHAGIA

- ▶ Dysfunctional uterine bleeding
- ▶ Fibroid uterus
- ▶ Adenomyosis
- ▶ Chronic tubo-ovarian mass

### Diagnosis

Long duration of flow, passage of big clots, use of increased number of thick sanitary pads, pallor, and low level of hemoglobin give an idea about the correct diagnosis and magnitude of menorrhagia.

### Treatment

The definitive treatment is appropriate to the cause for menorrhagia.

## POLYMENORRHEA

(SYN: EPIMENORRHEA)

### Definition

Polymenorrhea is defined as cyclic bleeding where the cycle is reduced to an arbitrary limit of less than 21 days and remains constant at that frequency. If the frequent cycle is associated with excessive and or prolonged bleeding, it is called epimenorrhagia.

### Causes

**Dysfunctional:** It is seen predominantly during adolescence, preceding menopause and following delivery and abortion. Hyperstimulation of the ovary by the pituitary hormones may be the responsible factor.

**Ovarian hyperemia** as in PID or ovarian endometriosis.

**Treatment:** Persistent dysfunctional type is to be treated by hormone as outlined in DUB (later in chapter).

## METRRORRHAGIA

**Definition:** Metrorrhagia is defined as irregular, acyclic bleeding from the uterus. Amount of bleeding is variable. While metrorrhagia strictly concerns uterine bleeding but in clinical practice, the bleeding from any part of the genital tract is included under the heading. Then again, irregular bleeding in the form of contact bleeding (Table 14.4) or intermenstrual bleeding (Tables 14.3 and 14.5) in an otherwise normal cycle is also included in metrorrhagia. In fact, it is mostly related to surface lesion in the uterus (Fig. 14.1).

### TABLE 14.3 CAUSES OF ACYCLIC BLEEDING

- ◆ DUB—usually during adolescence, following childbirth and abortion and preceding menopause
- ◆ Submucous fibroid
- ◆ Uterine polyp
- ◆ Carcinoma cervix and endometrial carcinoma

### TABLE 14.4 CAUSES OF CONTACT BLEEDING

- ◆ Carcinoma cervix
- ◆ Mucos polyp of cervix
- ◆ Vascular ectopy of the cervix especially during pregnancy, pill use cervix
- ◆ Infections—chlamydial or tubercular cervicitis
- ◆ Cervical endometriosis

### TABLE 14.5 CAUSES OF INTERMENSTRUAL BLEEDING

Apart from the causes of contact bleeding, other causes are:

- ▶ Urethral caruncle
- ▶ Ovular bleeding
- ▶ Breakthrough bleeding in pill use
- ▶ IUCD *in utero*
- ▶ Decubitus ulcer

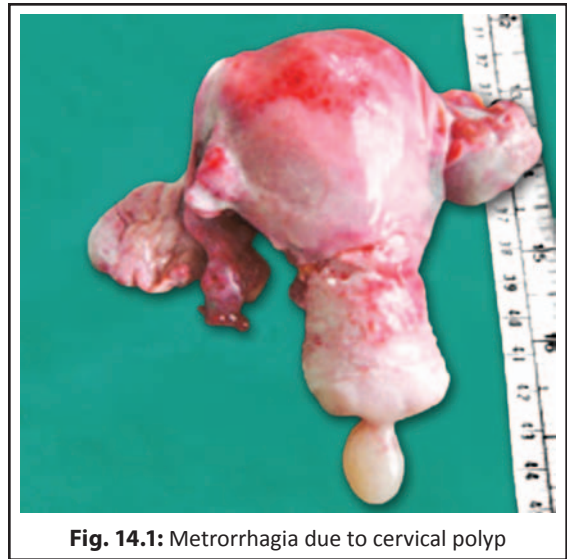


Fig. 14.1: Metrorrhagia due to cervical polyp

**Menometrorrhagia** is the term applied when the bleeding is so irregular and excessive that the menses (periods) cannot be identified at all.

### Treatment

Treatment is directed to the underlying pathology.

**Malignancy is to be excluded prior to any definitive treatment.**

## OLIGOMENORRHEA

**Definition:** Menstrual bleeding occurring **more than 35 days** apart and which remains constant at that frequency is called oligomenorrhea. Causes are mentioned in Table 14.6.

### TABLE 14.6 COMMON CAUSES OF OLIGOMENORRHEA

- ▶ Age-related—during adolescence and preceding menopause
- ▶ Weight-related—obesity (see p. 573)
- ▶ Stress and exercise related—(see p. 463)
- ▶ Endocrine disorders—PCOS (commonest), hyperprolactinemia, hyperthyroidism (see p. 466)
- ▶ Androgen producing tumors—ovarian, adrenal (see p. 386)
- ▶ Tubercular endometritis—late cases (see p. 140)
- ▶ **Drugs:**
  - Phenothiazines
  - Cimetidine
  - Methyl dopa

## HYPOMENORRHEA

**Definition:** When the menstrual bleeding is unduly scanty and lasts for less than 2 days, it is called hypomenorrhea.

### Causes

The causes may be local (uterine synechiae or endometrial tuberculosis), endocrinal (use of oral contraceptives, thyroid dysfunction, and premenopausal period), or systemic (malnutrition).

## DYSFUNCTIONAL UTERINE BLEEDING (DUB)

**Definition:** DUB is defined as **a state of abnormal uterine bleeding without any clinically detectable organic, systemic, and iatrogenic cause (Pelvic pathology, e.g. tumor, inflammation or pregnancy is excluded).**

**Heavy menstrual bleeding (HMB)** is defined as a bleeding that interferes with woman's physical, emotional, social and maternal quality of life.

### Incidence

The prevalence varies widely but an incidence of 10 percent amongst new patients attending the outpatient seems logical. The bleeding may be abnormal in frequency, amount, or duration or combination of any three. As **the diagnosis is based with the exclusion of 'organic lesion'**, so with the care and facilities to exclude such a lesion, the incidence varies. *Currently DUB is defined as a state of abnormal uterine bleeding following anovulation due to dysfunction of hypothalamo-pituitary-ovarian axis* (endocrine origin).

### Pathophysiology

**The physiological mechanism of hemostasis in normal menstruation are:** (1) Platelet adhesion formation. (2) Formation of platelet plug with fibrin to seal the bleeding vessels. (3) Localized vasoconstriction. (4) Regeneration of endometrium. (5) Biochemical mechanism involved are: In increased endometrial ratio of  $\text{PGF}_{2\alpha}/\text{PGE}_2$ ,  **$\text{PGF}_{2\alpha}$  causes vasoconstriction and reduces bleeding.** Progesterone increases the level of  $\text{PGF}_{2\alpha}$  from arachidonic acid. **Levels of endothelin**, which is a powerful vasoconstrictor is also increased. In anovulatory DUB, there is decreased synthesis of  $\text{PGF}_{2\alpha}$  and the ratio of  $\text{PGF}_{2\alpha}/\text{PGE}_2$  is low.

Anovulatory cycles are usually not associated with dysmenorrhea as the level of  $\text{PGF}_{2\alpha}$  is low. Women with menorrhagia have low level of thromboxane in the endometrium.

The endometrial abnormalities may be *primary or secondary* to **incoordination in the hypothalamo-pituitary-ovarian axis**. It is thus *more prevalent in extremes of reproductive period*—adolescence and premenopause or following childbirth and abortion.

Emotional influences, worries, anxieties, or sexual problems sometimes are enough to disturb the normal hormonal balance.

The abnormal bleeding may be associated with or without ovulation and accordingly grouped into:

- Ovular bleeding
- Anovular bleeding

### OVULAR BLEEDING

◆ **Polymenorrhea or polymenorrhagia:** The condition usually occurs following childbirth and abortion, during adolescence and premenopausal period, and in pelvic inflammatory disease.

The follicular development is speeded up with resulting shortening of the follicular phase. This is probably due to hyperstimulation of the follicular growth by FSH. Rarely, the luteal phase may be shortened due to premature lysis of the corpus luteum. Sometimes, it is related to stress induced stimulation.

Endometrial study prior to or within few hours of menstruation reveals secretory changes.

◆ **Oligomenorrhea:** Primary ovular oligomenorrhea is rare. It may be met in adolescence and preceding menopause.

The disturbance may be due to ovarian unresponsiveness to FSH or secondary to pituitary dysfunction. There is undue prolongation of the proliferative phase with normal secretory phase.

Endometrial study prior to or within few hours of menstruation reveals secretory changes.

**Functional menorrhagia:** Ovular menorrhagia is quite uncommon. Two varieties are found:

- Irregular shedding of the endometrium.
- Irregular ripening of the endometrium.

*Irregular shedding of the endometrium*

The abnormality is usually met in extremes of reproductive period.

Normally, regeneration of the endometrium is completed by the end of third day of menstruation. In irregular shedding, desquamation is continued for a variable period with simultaneous failure of regeneration of the endometrium. **The possible explanations are:**

- (i) Incomplete withdrawal of LH even on 26th day of cycle → incomplete atrophy of the corpus luteum → Persistent secretion of progesterone.
- (ii) Persistent LH → inhibition of FSH → suppresses ripening of the follicle in the next cycle → Less estrogen → less regeneration.

Endometrial sampling performed after 5th or 6th day of the onset of menstruation reveals **a mixture of secretory and proliferative endometrium**. There is total absence of any surface epithelium.

#### *Irregular ripening of the endometrium*

There is poor formation and inadequate function of the corpus luteum. Secretion of both estrogen and progesterone is inadequate to support the endometrial growth. As such, slight bleeding occurs and continues prior to the start of proper flow.

The endocrine profile in the luteal phase shows persistent low level of urinary pregnanediol level of less than 3 mg or plasma progesterone level less than 5 ng/mL.

Endometrial study prior to or soon after spotting reveals **patchy area of secretory changes amidst proliferative endometrium**.

### **ANOVULAR BLEEDING**

#### ◆ **Menorrhagia**

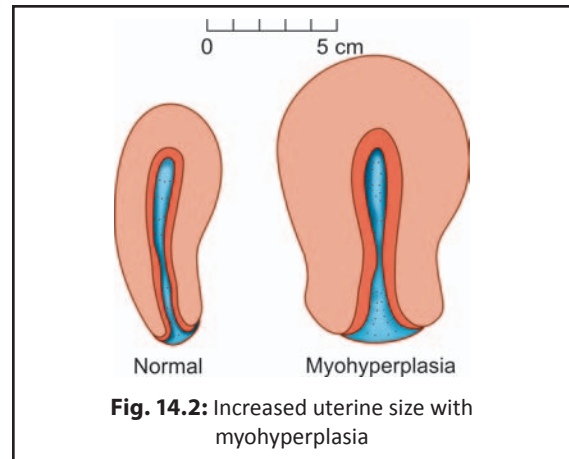
Anovular bleeding is usually excessive. In the absence of growth limiting progesterone due to anovulation, the endometrial growth is under the influence of estrogen throughout the cycle. There is inadequate structural stromal support and the endometrium remains fragile.

Thus, with the withdrawal of estrogen due to negative feedback action of FSH, the endometrial shedding continues for a longer period in asynchronous sequences because of lack of compactness.

#### ◆ **Cystic glandular hyperplasia**

(Syn: *Metropathia hemorrhagica*, *Schroeder's disease*)

This type of abnormal bleeding is usually met in premenopausal women.

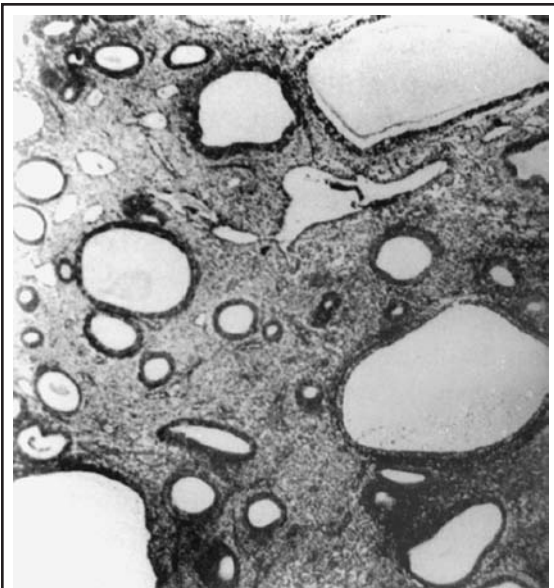


The basic fault may lie in the ovaries or may be due to disturbance of the rhythmic secretion of the gonadotropins. There is slow increase in secretion of estrogen but no negative feedback inhibition of FSH. The net effect is gradual rise in the level of estrogen with concomitant phase of amenorrhea for about 6–8 weeks. As there is no ovulation, the endometrium is under the influence of estrogen without being opposed by growth limiting progesterone for a prolonged period. After a variable period, however, the estrogen level falls resulting in endometrial shedding with heavy bleeding. Bleeding also occurs when the endometrial growth have outgrown their blood supply. Due to increased endometrial thickness, tissue breakdown continues for a long time. Bleeding is heavy as there is no vasoconstrictor effect of  $\text{PGF}_{2\alpha}$ . Bleeding is prolonged until the endometrium and blood vessels regenerate to control it.

**Changes in the uterus:** There is variable degree of myohyperplasia with symmetrical enlargement of the uterus to a size of about 8–10 weeks due to simultaneous hypertrophy of muscles (Fig. 14.2). The endometrial changes are classical. On naked eye examination, the endometrium looks thick, congested and often polypoidal (multiple polyposis).

#### **Microscopically**

- (a) There is marked hyperplasia of all the endometrial components. There is however, intense cystic glandular hypertrophy rather than hyperplasia with marked disparity in sizes. Some of the glands are small, others are large giving the appearance of “Swiss cheese” pattern (small and large holes



**Fig. 14.3.** Endometrium showing 'Swiss cheese' appearance

of Swiss cheese made in Switzerland). The glands are empty and lined by columnar epithelium.

(b) Absence of secretory changes.

(c) Areas of necrosis in the superficial layers with small hemorrhages and leukocytic infiltration (Fig. 14.3).

**Changes in the ovary:** Cystic changes may be observed involving one or both the ovaries. The cyst may be single or multiple and the fluid contains estrogen. The cyst is of follicular type. There is no evidence of corpus luteum.

**Confusion in diagnosis:** Phase of amenorrhea followed by continued bleeding per vaginum with bulky uterus is too often confused with disturbed uterine pregnancy or ectopic gestation. In anovulatory DUB, unlike normal menstruation there is no uniform sloughing of endometrium up to the basal layer. This results in excessive uterine bleeding. In anovulatory DUB, there is decreased synthesis of  $\text{PGF}_{2\alpha}$  ( $\text{PGF}_{2\alpha}/\text{PGE}_2$  is low) and thromboxane. **Due to this reason, DUB of this type is absolutely painless.**

**Atrophy of the endometrium:** This type of abnormality is commonly met in postmenopausal women but may occur in reproductive period as final involutory state of a previous metropathia.

The bleeding occurs from the rupture of the dilated capillaries beneath the atrophic surface epithelium.

**The cause of endometrial atrophy** may be due to total absence of estrogen or failure of uterine receptors to become responsive to estrogen.

### Endometrial Pattern in DUB

The following are the histological patterns found in DUB. In majority (60%), the endometrium is normal secretory in every aspect. In about 30 percent, the endometrium is hyperplastic and in the remaining, there are evidences of irregular shedding, irregular ripening, or atrophic pattern.

### Investigations

#### The investigation aims at:

- ◆ To confirm the menstrual abnormality as stated by the patient.
- ◆ To exclude the systemic, iatrogenic, and 'organic' pelvic pathology.
- ◆ To identify the possible etiology of DUB.
- ◆ To work out the definite therapy protocol.

### History

Firstly, it is to be confirmed that the bleeding is through the vagina and not from the urethra or rectum.

**The statement of excessive bleeding is assessed by** number of pads used, passage of clots (size and number), and duration of bleeding. If ambiguity is found from the estimated hemoglobin percentage, it is better to assess the blood loss by admitting the patient during period. Among the patients presenting with menorrhagia, only about 50 percent have got excess blood loss (> 80 mL).

Nature of menstrual abnormality is then to be enquired—cyclic or acyclic, its relation to puberty, pregnancy events and last normal cycle. Any emotional upset or psychosexual problem should be elicited tactfully. Use of steroidal contraceptives or IUCD insertion should be enquired. History of abnormal bleeding from the injury site, epistaxis, gum bleeding, or that suggestive of PID should be enquired.

A thorough general and relevant systemic examination is to be made in an effort to find out the cause or effect of abnormal bleeding. In a suspected case of thrombocytopenic purpura, tourniquet test is performed.

*Estimation of menstrual blood loss either directly by alkaline haematin or indirectly by pictorial chart is not routinely done.*

**Internal examination:** Bimanual examination including speculum examination should be done in all cases except in virgins, where rectal examination is to be done to exclude palpable pelvic pathology. If vaginal examination is required in virgins, it should be done under general anesthesia and along with endometrial curettage.

### Special Investigations

- ▶ **Blood values:** Hemoglobin estimation is done in every case. Serum ferritin test is not done as a routine. In pubertal menorrhagia not responding to usual therapy, platelet count, prothrombin time, bleeding time, partial thromboplastin time are to be estimated. In suspected cases of thyroid dysfunction, serum TSH, T<sub>3</sub>, and T<sub>4</sub> estimation is to be done.
- ▶ **Ultrasound and Color Doppler** findings of endometrial hyperplasia are: (i) Endometrial thickness > 12 mm. (ii) Hyperechoic and regular outline. (iii) Angiogenesis and neovascular signal study. **Transvaginal sonography (TVS)** is also very sensitive to detect any anatomical abnormality (fibroid, adenomyosis) of the uterus, endometrium and adnexae.
- ▶ **Saline Infusion Sonography (SIS)** is found very helpful (see p. 118) to diagnose endometrial polyps, submucous fibroids and uterine abnormality (septate/subseptate uterus).
- ▶ **Hysteroscopy**—is done for better evaluation of endometrial lesion and to take biopsy from the offending site under direct vision. The frequent findings of polyp and submucous fibroid are often missed by blind curettage. Hysteroscopy and directed biopsy (H and B) can be performed as an outpatient basis. H and B has replaced conventional D and C (for details see p. 194).
- ▶ **Endometrial sampling** (see p. 120) can be done as an outpatient basis. Pipelle sampler is easy

to use. As it is a blind procedure, intrauterine pathology (polyps, submucous fibroids) cannot be detected.

- ▶ **Laparoscopy:** To exclude unsuspected pelvic pathology such as endometriosis, PID or ovarian tumor (granulosa cell tumor). The indication is urgent, if associated with pelvic pain.
- ▶ **Diagnostic uterine curettage (D and C)**

Diagnostic uterine curettage is indicated in DUB: (1) To exclude the **organic lesions in the endometrium** (incomplete abortion, endometrial polyp, tubercular endometritis or endometrial carcinoma). (2) To determine the functional state of the endometrium. (3) To have incidental therapeutic benefit.

**In adolescent DUB**, it is rarely needed only if bleeding fails to stop or is severe in nature (see p. 54, 55).

**During childbearing period** (20–40 years), it should be done, **if the bleeding is acyclic. Risk of endometrial carcinoma in this age group is very low.**

**During premenopausal period**, diagnostic curettage is **mandatory** prior to any therapy to exclude endometrial malignancy.

**During post-menopausal period**, it is **mandatory** to exclude endometrial malignancy. Thin plastic endometrial tissue samplers (pipellae) are available (see Fig. 9.23). It helps to obtain adequate endometrial sample for histological examination. It is done as an OPD procedure without any anesthetic.

### Plan for Special Investigations

Blood values → Ultrasonography (to exclude structural abnormalities) → Endometrial sampling (Pipelle)/Hysteroscopy and biopsy (to exclude histological abnormalities) → Laparoscopy.

### TIME SCHEDULE FOR UTERINE CURETTAGE

Cyclic	<ul style="list-style-type: none"> <li>• Menorrhagia</li> <li>• Irregular shedding</li> <li>• Irregular ripening</li> </ul>	5–6 days prior to period 5–6 days after the period starts Soon after the period starts
Acyclic	—	Soon after the period starts
Continuous	—	Any time



## MANAGEMENT

Because of diverse etiopathology of DUB in different phases of woman's life, the management protocols have been grouped accordingly.

- ▶ Pubertal and adolescent menorrhagia <20 years (see p. 54, 55).
- ▶ Reproductive period (20–40 years).
- ▶ Premenopausal (>40 years).
- ▶ Postmenopausal (see p. 559).

### REPRODUCTIVE PERIOD

#### ◆ General ◆ Medical ◆ Surgery

##### ■ General

Rest is advised during bleeding phase. Assurance and sympathetic handling are helpful particularly in adolescents. Anemia should be corrected energetically by diet, hematinics, and even by blood transfusion. Clinically evident systemic or endocrinal abnormalities should be investigated and treated accordingly.

### MEDICAL MANAGEMENT OF DUB

Dysfunctional uterine bleeding (DUB), in majority responds well to conservative treatment during adolescence and early reproductive period. The derivatives of drugs used are listed in the Table 14.7.

■ **Hormones:** With the introduction of potent orally active progestins, they became the mainstay in the management of DUB in all age groups and practically replaced the isolated use of estrogens and androgens.

■ **Progestins:** The common preparations used are norethisterone acetate and medroxyprogesterone acetate (Table 14.7). The latter one is better than the former as it does not alter the serum lipids. **Mechanism of antiestrogenic action of progestins are:** (i) It stimulates the enzyme (17- $\beta$ -hydroxy steroid dehydrogenase) that converts estradiol to estrone (less potent). (ii) Inhibits induction of estrogen receptor. (iii) It has antimitotic effect on the endometrium. While isolated progestins therapy is highly effective in anovular DUB, in ovular DUB combined preparations of progestogen and estrogen (combined oral pills) are effective.

### The preparations are used:

- Cyclic therapy
- Continuous therapy

#### To stop bleeding and regulate the cycle:

Norethisterone preparations (5 mg tab) are used thrice daily till bleeding stops, which it usually does by 3–7 days.

### Cyclic Therapy

- 5th–25th day course
- 15th–25th day course.

#### 5th to 25th day course:

*In ovular bleeding:* **Any low dose combined oral pills are effective** when given from 5th to 25th day of cycle for 3 consecutive cycles. It causes endometrial atrophy. It is more effective compared to progesterone therapy as it suppress the hypothalamo-pituitary axis more effectively. Normal menstruation is expected to resume with restoration of normally functioning pituitary–ovarian-endometrial axis. It reduces menstrual blood loss by 50 percent. It serves as a contraceptive as well.

**TABLE 14.7 MEDICAL MANAGEMENT OF DUB**

#### (A) Hormones (see p. 525)

- ◆ Norethisterone acetate (see p. 534)
- ◆ Medroxyprogesterone acetate
- ◆ Dydrogesterone
- ◆ Equine conjugated estrogen
- ◆ Combined estrogens and progestogens (contraceptive pills)
- ◆ 19 Norsteroid derivative (Gestrinone)
- ◆ Danazol (17  $\alpha$ -ethinyl testosterone)
- ◆ Progestin releasing IUCD LNG – IUS (see p. 480)
- ◆ Mifepristone (RU 486) (see p. 537)
- ◆ GnRH analogues (see p. 525)
- ◆ Desmopressin

#### (B) Prostaglandin synthetase inhibitors (PSI)

- ◆ Fenamates (Mefenamic acid)

#### (C) Antifibrinolytic agents

- ◆ Tranexamic acid (TA)

**For side effects of each drug used—see Chapter 31**

*In anovular bleeding:* Cyclic progestogen preparation of medroxyprogesterone acetate (MPA) 10 mg or norethisterone 5 mg is used from 5th to 25th day of cycle for 3 cycles.

### 15th to 25th day course:

**In ovular bleeding, where the patient wants pregnancy or in cases of irregular shedding or irregular ripening of the endometrium,** dydrogesterone 1 tab (10 mg) daily or twice a day from 15th to 25th day may cure the state. This regimen is less effective than 5th to 25th day course. However, it does not suppress ovulation.

Adolescent anovulatory women have immaturity of H-P-O axis. They are ideal for use of short-term cyclic therapy until the maturity of the positive feedback system is established.

▲ **Continuous progestins:** Progestins also inhibit pituitary gonadotropin secretion and ovarian hormone production.

Medroxyprogesterone acetate 10 mg thrice daily is given and treatment is usually continued for at least 90 days.

Various continuous preparations may be used. Oral (Table 14.7), long-acting intramuscular injections, DMPA (see p. 491) implants (see p. 492), Progestogen only pill (see p. 491) are effective to reduce menstrual blood loss. They may also result in oligomenorrhea or amenorrhea.

Progesterone treatment helps organized endometrial shedding upto the basal layer and increases the endometrial ratio of  $\text{PGF}_{2\alpha}/\text{PGE}_2$  and thromboxane (see above).

**Estrogen:** In situations where the bleeding is acute and severe, conjugated estrogen 25 mg is given IV. It helps with rapid growth of the denuded endometrium and promotes platelet adhesiveness. It controls bleeding by process of healing. It may be repeated every four hours till the bleeding is controlled, when oral therapy is started. Once the bleeding stops, progestin (MPA 10 mg a day) is to be added. COC is used for long-term treatment. Proliferation of endometrium, increase in the level of fibrinogen, factors – V, X, and platelet aggregation are the other mechanisms of action for estrogen therapy. If bleeding continues further, D and C is indicated.

▶ **Intrauterine progestogen:** Levonorgestrel intrauterine system (LNG-IUS) induce endometrial glandular atrophy, stromal decidualization and endometrial cell inactivation (see p. 480). It is effective for 5 years. It has minimal systemic absorption. Reduction of blood loss is upto 97

percent. It is considered as medical hysterectomy. In addition to its many other health benefits it is an effective contraceptive measure (p. 484). **LNG-IUS is recommended as a first line therapy for a woman with HMB in the absence of any structural or histological abnormality.**

- ▶ **Danazol:** Danazol is suitable in cases with recurrent symptoms and in patients waiting for hysterectomy. The dose varies from 200–400 mg daily in 4 divided doses continuously for 3 months. A smaller dose tends to minimize the blood loss and a higher dose produces amenorrhea (see p. 530). It reduces blood loss by 60 percent.
- ▶ **Mifepristone (RU 486):** It is an anti-progesterone (19 nor-steroid). It inhibits ovulation and induces amenorrhea and reduces myoma size (see p. 537).
- ▶ **GnRH agonists (see p. 525):** The subtherapeutic doses reduce the blood loss whereas in therapeutic doses produce amenorrhea. It is valuable as short-term use in severe DUB, particularly if the woman is infertile and wants pregnancy. The drugs are used subcutaneously or intranasally. It improves anemia, and is helpful when used before endometrial ablation (see below). A varying degree of hypoestrogenic features may appear.

### NON-HORMONAL MANAGEMENT

- ▶ **Anti-fibrinolytic agents (Tranexamic acid)** reduces menstrual blood loss by 50 percent. It counteracts the endometrial fibrinolytic system. It is particularly helpful in IUCD induced menorrhagia. Gastrointestinal side effects are common. Antifibrinolytic agents can be used as a second line therapy.
- ▶ **Prostaglandin synthetase inhibitors:** Mefenamic acid is much effective in women aged more than 35 years and in cases of ovulatory DUB. The dose is 150–600 mg orally in divided doses during the bleeding phase. The fenamates inhibit the synthesis of prostaglandins and interfere with the binding of  $\text{PGE}_2$  to its receptor. NSAIDs can reduce menstrual blood loss by 25–40 percent. Improvement of dysmenorrhea headache, or nausea are the added benefits. Side effects (see p. 180) are often mild. **NSAIDs may be used as second line medical treatment.**

- ▶ **Desmopressin:** It is a synthetic analogue of arginine-vasopressin. It is specially indicated in cases with von Willebrand's disease and factor VIII deficiency. It is given IV (0.3 µg/kg) or intranasally.

### SURGICAL MANAGEMENT OF DUB

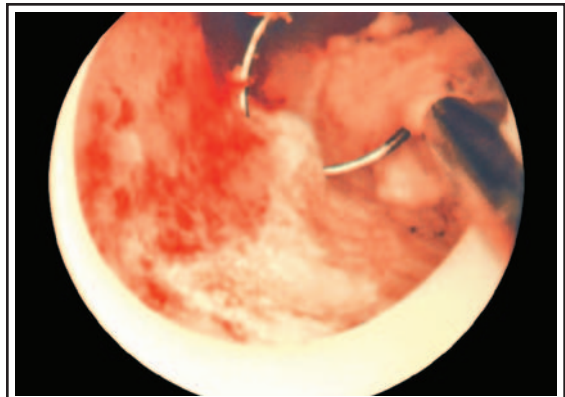
- Uterine curettage
- Endometrial ablation/resection
- Hysterectomy
- **Uterine Curettage**

It is done predominantly as a diagnostic tool for elderly women but at times, it has got hemostatic and therapeutic effect by removing the necrosed and unhealthy endometrium. It should be done following ultrasonography for detection of endometrial pathology. The indication is an urgent one, if the bleeding is acyclic and where endometrial pathology is suspected. **Ideally hysteroscopy and directed biopsy should be considered both for the purpose of diagnosis and therapy. Presently, dilatation and curettage should be used neither as a diagnostic tool nor for the purpose of therapy.**

- **Endometrial Ablation/Resection (see p. 622)**

**Indications are:** (a) Failed medical treatment, (b) Women who do not wish to preserve menstrual or reproductive function, (c) Uterus—normal size or not bigger than 10 weeks pregnancy size, (d) Small uterine fibroids (< 3 cm), (e) Women who want to avoid longer surgery, (f) Woman who prefers to preserve her uterus.

- ◆ **Laser ablation** of the endometrium using the Nd:YAG laser through hysteroscope is an



**Fig. 14.4:** Endometrial resection with the cutting loop

alternative to hysterectomy. It is employed as an elective alternative to hysterectomy or when hysterectomy has been medically contraindicated. Tissue destruction (coagulation, vaporization, and carbonization) to a **depth of 4-5 mm produces a therapeutic Ashermann's syndrome and amenorrhea.** The method should be employed in cases who have completed their families.

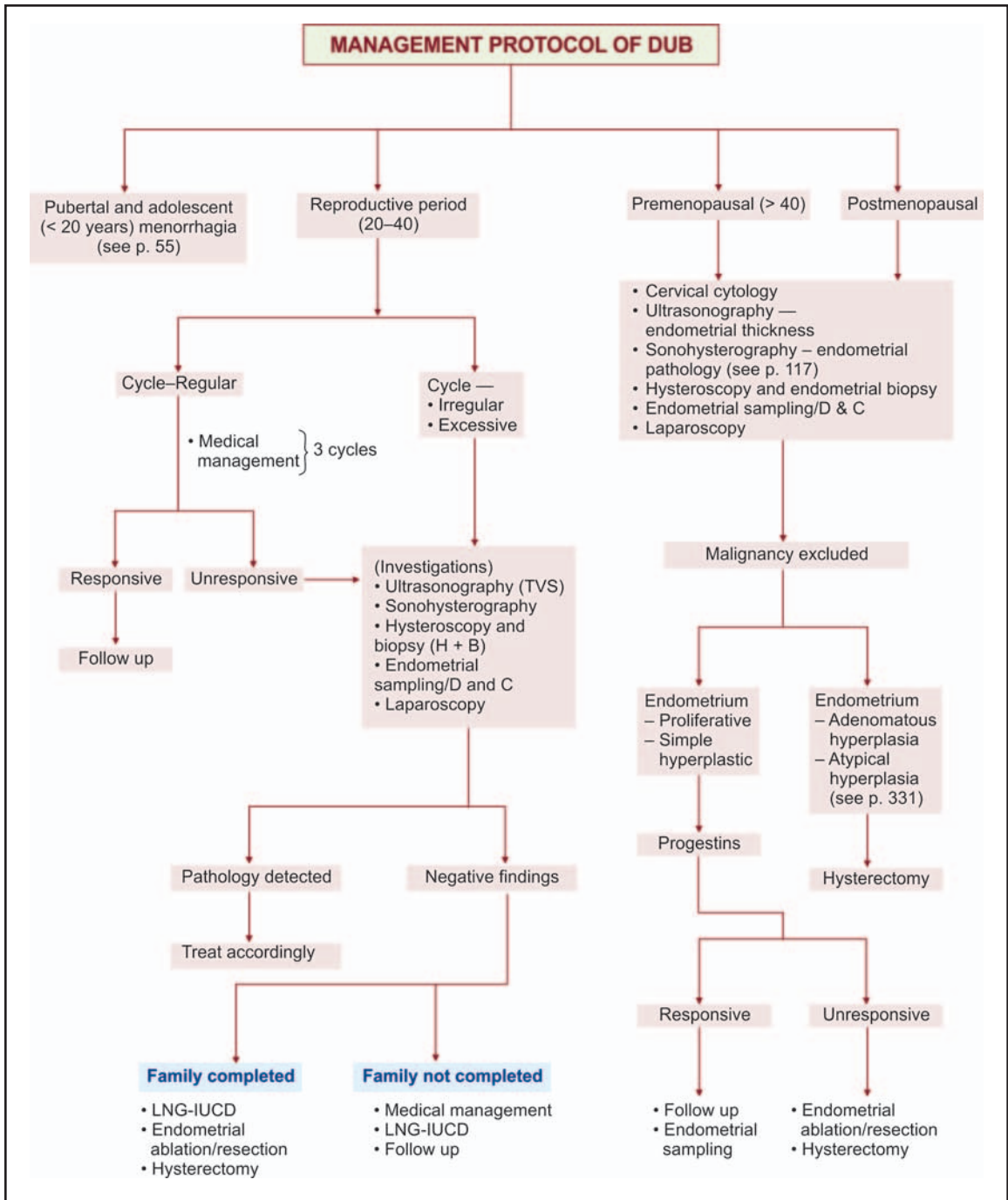
- ◆ **Uterine thermal balloon** for destruction of endometrium is currently used with satisfactory results. Endometrium is destroyed using a thermal balloon with hot normal saline (87°C) for 8–10 minutes. No dilatation of the cervical canal is needed. This procedure is suitable for women who are not suitable for general anesthetic or long duration surgery. The success rate is similar to TCRE. No pretreatment endometrial thinning is required. **This is considered as a first line therapy and is done as a day care basis.**

**TABLE 14.8 COMMON CAUSES OF ABNORMAL VAGINAL BLEEDING**

Abnormal uterine bleeding		Non-menstrual bleeding
<b>Organic</b>	<b>Hematological and Endocrine</b>	<ul style="list-style-type: none"> <li>◆ Foreign body</li> <li>◆ Urethral caruncles (see p. 413)</li> <li>◆ Genital malignancy (see Ch. 23)</li> <li>◆ Postcoital</li> <li>◆ Intermenstrual</li> <li>◆ Abortion</li> <li>◆ Breakthrough bleeding (see p. 489)</li> </ul>
<ul style="list-style-type: none"> <li>◆ Uterine fibroid</li> <li>◆ Endometriosis</li> <li>◆ Adenomyosis</li> <li>◆ Endometrial polyps</li> <li>◆ IUCD</li> <li>◆ Adnexal pathology (TO mass)</li> </ul>	<ul style="list-style-type: none"> <li>◆ Platelet deficiency</li> <li>◆ Leukemia</li> <li>◆ ITP</li> <li>◆ von Willebrand disease</li> <li>◆ Thyroid dysfunction</li> </ul>	

**SURGICAL TREATMENT OF DUB**

- **Endometrial ablation/Resection**
  - ◆ Laser
  - ◆ Rollerball
  - ◆ Thermal balloon
  - ◆ Microwave
  - ◆ Novasure
- **Resection**
  - ◆ Transcervical resection (TCRE)
- **Uterine artery embolization**
- **Hysterectomy**



◆ **Microwave endometrial ablation** is simple and carried out as an outpatient procedure. Microwave electromagnetic heat energy causes ablation of the endometrium. Endometrial tissue up to a depth of 6 mm is ablated. Temperature in the region is 75–80°C. Treatment time (2–3 minutes) is less compared to TCRE. Results are similar to TCRE.

◆ **Novasure:** Endometrial ablation is done using a bipolar radio frequency mounted on an expandable frame. This creates a confluent lesion on the entire endometrial surface. Time required for global endometrial ablation is 90 seconds approximately. Radio frequency energy vaporizes or coagulates the endometrium up to the myometrium. The procedure is quick, simple, and safe. **Women with uterine cavity < 4 cm, PID, cesarean delivery are contraindicated.**

**Pretreatment** with danazol or GnRH agonists for 3 weeks prior to endometrial ablation is helpful to make the endometrium atrophic.

◆ **Transcervical resection** of the endometrium (TCRE) through continuous flow resectoscope is quicker and less costlier than laser ablation. It can be carried out even under paracervical block. Resectoscope loop must remove the basal layer of endometrium along with superficial layer of myometrium, otherwise regeneration of endometrium causes failure of operation (Fig. 14.4).

◆ **Roller ball ablation** of endometrium is also effective. It coagulates endometrium up to a depth of about 4 mm.

These two first generation ablation methods (TRCE and REA) are used when hysteroscopic myomectomy is to be done simultaneously.

**Complications:** Infection, uterine perforations (< 1%), fluid absorption (see p. 623) may occur during hysteroscopic procedure.

### Results of Endometrial Ablation or Resection

**Overall success** with these methods is 70–80 percent. About 30–40 percent women become amenorrheic and another 50 percent will have significant decrease in blood loss. But 10 percent of women may need repeat procedure or hysterectomy. For case selection, side effects, contraindications, and complication (see p. 622).

**Uterine artery embolization** is commonly done in women with large uterine fibroid (> 3 cm) with heavy

bleeding. Particles (see p. 283) are injected to block uterine artery under local anesthesia. This shrinks fibroids. The procedure is safe and effective.

**Hysterectomy** (see p. 593) is not recommended as a first line therapy for heavy menstrual bleeding (HMB) or DUB. However, hysterectomy is justified when the conservative treatment fails or contraindicated and the blood loss impairs the health and quality of life. Presence of endometrial hyperplasia and atypia on endometrial histology is an indication for hysterectomy. The decision can be made easily as the patient is approaching 40. **Hysterectomy** may be done depending on the route by vaginal, abdominal, or laparoscopic assisted vaginal method. In this regard, the factors to consider are: uterine size, mobility, descent, previous surgery, and presence of comorbidities (obesity, diabetes, heart disease, or hypertension). Healthy ovaries may be preserved at the time of hysterectomy especially those under 45 years of age.

## ABNORMAL UTERINE BLEEDING (AUB) (FIGO, ACOG-2011)

**Any uterine bleeding outside the normal volume, duration, regularity or frequency is considered abnormal uterine bleeding (AUB).** Nearly 30% of all gynecological outpatient attendants are for AUB.

NORMAL MENSTRUATION	
Cycle interval	28 days (21–35 days)
Menstrual flow	4–5 days
Menstrual blood loss	35 mL (20–80 mL)

Abnormal menstrual bleeding pattern have been traditionally expressed by terms like menorrhagia, metrorrhagia, polymenorrhea, and oligomenorrhea (see p. 185, 186). In order to create an universally accepted nomenclature to describe abnormal uterine bleeding, International Federation of Gynecology and Obstetrics (FIGO) and American College of Obstetricians and Gynaecologists (ACOG) introduced newer system of terminology to describe AUB. **The newer classification system is known by the acronym PALM–COEIN (FIGO–2011).** It is used to classify the abnormal uterine bleeding on the basis of etiology. **Polyp, adenomyosis, leiomyoma, malignancy and coagulopathy, hyperplasia, ovulatory dysfunction, endometrial, iatrogenic, and not yet classified are the different etiological factors expressed by one (or more) letters.**

The term dysfunctional uterine bleeding (DUB), discussed above is a type of AUB, whereas no systemic or locally identifiable structural cause is found.

### Etiopathology of AUB

The common causes of abnormal uterine bleeding with the PALM–COEIN classification are shown below. The letter within the parenthesis indicate the pathology.

CLASSIFICATION OF AUB (FIGO-2011)			
Structural causes (PALM)		Nonstructural systemic causes (COEIN)	
• Polyp	AUB–P	Coagulopathy	AUB – C
• Adenomyosis	AUB–A	Ovulatory dysfunction	AUB – O
• Leiomyoma	AUB–L	Endometrial	AUB – E
– Submucosal myoma	AUB–LSM	Iatrogenic	AUB – I
– Other myoma	AUB–LO		
• Malignancy and hyperplasia	AUB–M	Not yet identified	AUB – N

### Diagnosis of Abnormal Uterine Bleeding

- A. **Detailed history taking** and physical examination should be done.
  - a. **Medical history should include:** Age of the patient, patterns of abnormal uterine bleeding, severity, associated pain, family history and use of medication.
  - b. **General and physical examination:** Pallor, edema, neck glands, thyroid, and systemic examination, and pelvic examination (per speculum, Pap smear, and bimanual examination) are included.
- B. **Laboratory investigations:** Complete hemogram, thyroid profile, pregnancy test, coagulation profile.
- C. **Imaging studies:** Ultrasonography (Transvaginal), Saline infusion sonography (SIS), hysteroscopy (SIS is superior to TVS for detection of intracavitary pathology like, polyps, submucosal fibroids).
- D. **Magnetic resonance imaging (MRI):** MRI may be used as a second line procedure especially in cases with adenomyosis (see p. 118).
- E. Histological confirmation of pathology whenever possible.

**Hysteroscopy** is superior to dilatation and curettage which is a blind procedure. Hysteroscopy allows direct visualization of endometrial cavity abnormalities. It has

a therapeutic value, as it can be used for polypectomy. It is accurate in diagnosing endometrial cancer. It can be performed in an OPD setting.

**MRI**, is useful in the diagnosis of adenomyosis when compared to ultrasonography. Myometrial heterogeneity, myometrial cysts, asymmetric myometrial thickness, and subendometrial echogenic linear striations are suggestive features to the diagnosis of adenomyosis. T2 weighted images with MRI are very informative in the diagnosis.

**Ovulatory dysfunction (AUB-O):** Disorders of ovulation like oligovulation, anovulation, polycystic ovarian changes, and corpus luteum dysfunction may result in AUB.

AUB may present in the form of menorrhagia or heavy menstruation, irregular, intermenstrual bleeding, or scanty bleeding. Most of the AUB are due to ovulatory dysfunction. Many are the result of different endocrine or metabolic dysfunction. These are polycystic ovarian syndrome, hypothyroidism, hyperthyroidism, hyperprolactinemia, obesity or due to hypothalamic dysfunction (stress, weight loss).

### Endometrial (AUB-E)

Primary disorders of the endometrium may be the cause of AUB or DUB. Imbalance in the levels of different hemostatic mechanism may be responsible for heavy menstrual bleeding (AUB). Optimum levels of endothelin-1, PG F<sub>2α</sub>, formation of platelet plug or fibrin seal are essential to control bleeding. Excess production of plasminogen activators, production of substances that promote vasodilatation (PGE<sub>2</sub>, PGI<sub>2</sub>) may result in AUB. Other local endometrial factors to cause AUB are endometrial inflammation (chronic endometritis), infection, and endometrial vascular pathology (angioma).

**Iatrogenic (AUB-I):** Iatrogenic causes of AUB are: Breakthrough bleeding following the use of combined oral contraceptives; erratic use of pills or any contraceptive steroids (vaginal rings), use of IUCDs, or LNG-IUS.

### Management options for a case with AUB

- Management issues of AUB depend upon the pathology obtained in an individual woman (discussed above).
- Women with AUB with age ≥ 45 years should have endometrial biopsy (D/C or hysteroscopy directed biopsy) as an initial step of management.
- Adolescent girls with AUB or heavy menstrual bleeding need exclusion of bleeding disorders besides other investigations. Complete hemogram, platelet count, prothrombin time, and partial thromboplastin time need to be done (Flowchart p. 194).

**KEY POINTS**

- ▶ Common causes of menorrhagia are DUB, fibroid, adenomyosis, or chronic pelvic infection.
- ▶ Common causes of contact bleeding are carcinoma cervix, cervical mucous polyp, and vascular erosion.
- ▶ Common causes of abnormal uterine bleedings are: uterine fibroid, endometriosis, adenomyosis, IUCD, TO mass, platelet deficiency, leukemia, and thyroid dysfunction.
- ▶ The endometrial pattern in DUB is secretory in 60 percent and hyperplastic in about 30 percent.
- ▶ In late secretory phase the level of both  $\text{PGE}_2$  and  $\text{PGF}_{2\alpha}$  in the endometrium increases and during ovulatory cycles  $\text{PGF}_{2\alpha}$  level rises over the  $\text{PGE}_2$ . The menstrual blood loss is inversely related to the level of endometrial  $\text{PGF}_{2\alpha}/\text{PGE}_2$  ratio.  $\text{PGE}_{2\alpha}$  causes vasoconstriction and reduces bleeding.
- ▶ Methods of assessment of menstrual blood loss are very inaccurate. Alkaline hematin method is a relatively precise method.
- ▶ In acyclic type of bleeding, diagnostic D + C should be done within 24 hours of menstruation.
- ▶ DUB is a state of abnormal uterine bleeding due to anovulation predominantly.
- ▶ D & C misses the diagnosis of uterine lesions in 10–20 percent of women as it is a blind procedure. D & C can stop the acute episode of excess uterine bleeding but not the subsequent episodes.
- ▶ Diagnostic tests in women with menorrhagia include measurement of hemoglobin, serum iron, serum ferritin, TSH, endometrial biopsy, hysteroscopy, or sonohysterography.
- ▶ Hysteroscopy and biopsy is the best method to evaluate the endometrial pathology in DUB and also to detect lesions such as submucous fibroid or polyp.
- ▶ To arrest acute episode of bleeding, potent progestogens are suitable in all phases of life; however, natural estrogen administered parenterally (conjugated estrogen 25 mg IV) is more effective in hemostasis during early reproductive period.
- ▶ For cycle regulation, either progestogens or combined preparations of estrogen and progestogen (pill) may be used.
- ▶ In refractory cases or in cases of temporary contraindication of surgery, danazol, or GnRH analogues may be used for short-term therapy.
- ▶ Prostaglandin synthetase inhibitors are effective in ovulatory DUB above the age of 35.
- ▶ Antifibrinolytic agents are suitable in case of DUB and also for bleeding following IUCD insertion.
- ▶ In cases of completed family, endometrial ablation/resection or hysterectomy are the options (see p. 194).
- ▶ Endometrial ablation or resection (TCRE) is done in a woman who is over 35 years, who do not respond to medical therapy, has completed her family and without any significant endometrial pathology (e.g. cancer, submucous fibroid > 3 cm in diameter).
- ▶ Ablation of endometrium upto a depth of 4–5 mm using laser, roller ball, thermal balloon, microwave, is an effective method. Resection of endometrium upto the basal layer is also a quicker and less costlier method. Overall, amenorrhea occurs in 30–40 percent of women, about 50 percent have decreased bleeding and 10 percent may need repeat procedure or hysterectomy.
- ▶ In perimenopausal period, genital malignancy should be ruled out prior to any therapy.
- ▶ AUB has been classified with the acronym. "PALM-COEIN" by FIGO-(2011). It broadly divides AUB into structural and non-structural causes (p. 196).
- ▶ Management options for AUB depends on individual woman's etiopathology (see Flowchart p. 194).

# Displacement of the Uterus

The uterus is not a fixed organ. Minor variations in position in any direction occur constantly with changes in posture, with straining, with full bladder or loaded rectum. Only when the uterus rests habitually in a position beyond the limit of normal variation, should it be called displacement.

## RETROVERSION

### DEFINITION

Retroversion (RV) is the term used when the long axes of the corpus and cervix are in line, and the whole organ turns backwards in relation to the long axis of the birth canal.

Retroflexion signifies a bending backwards of the corpus on the cervix at the level of internal os. **The two conditions are usually present together and are loosely called retroversion or retrodisplacement (Fig. 15.1).**

### DEGREES

Conventionally, three degrees are described.

**First degree** — The fundus is vertical and pointing towards the sacral promontory.

**Second degree** — The fundus lies in the sacral hollow but not below the internal os.

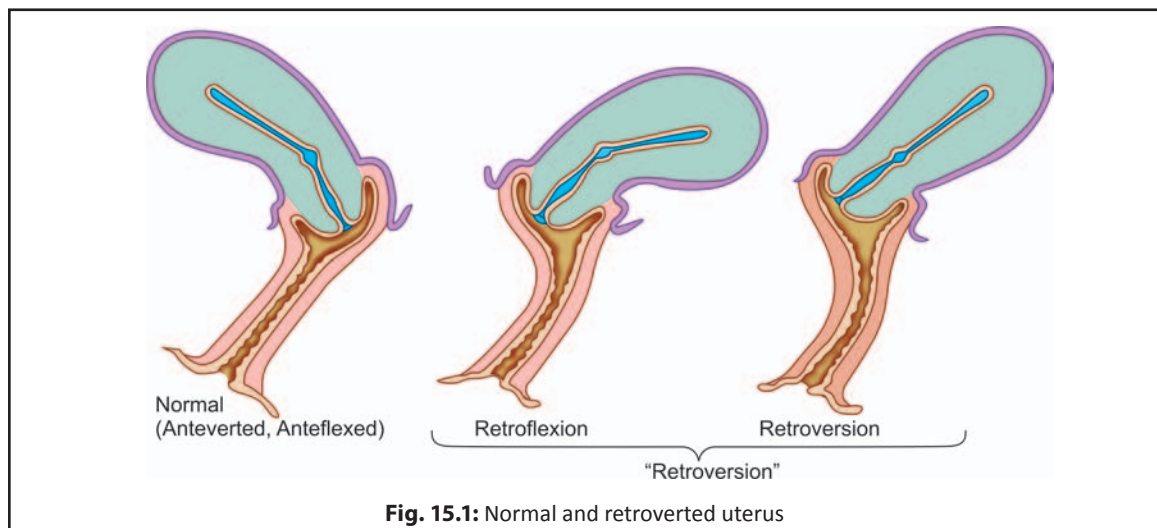
**Third degree** — The fundus lies below the level of the internal os.

### CAUSES

- Developmental
- Acquired

### Developmental

Retrodisplacement is quite common in fetuses and young children. Due to developmental defect, there is lack of tone of the uterine muscles. The infantile position is retained. This is often associated with short vagina with shallow anterior vaginal fornix.



**Fig. 15.1:** Normal and retroverted uterus



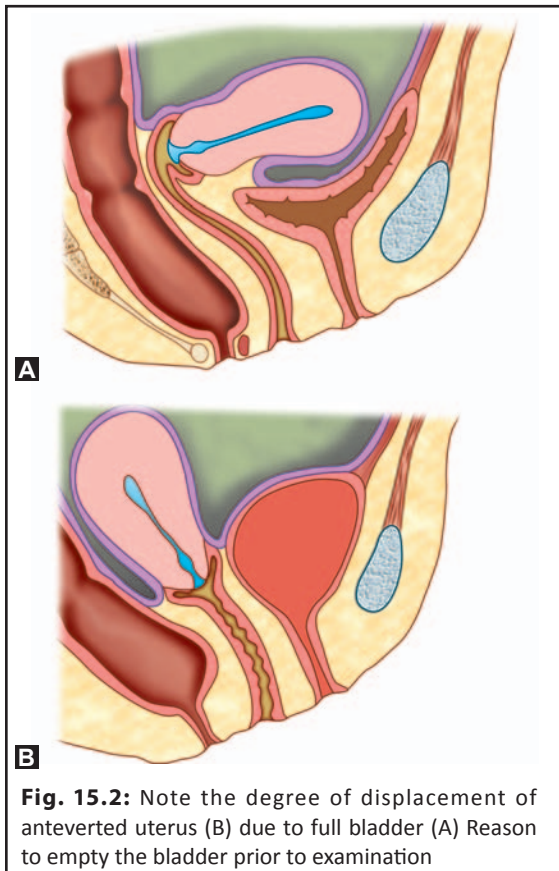
### Acquired

**Puerperal:** The stretched ligaments caused by childbirth fail to keep the uterus in its normal position. A subinvolted bulky uterus aggravates the condition.

**Prolapse:** Retroversion is usually implicated in the pathophysiology of prolapse which is mechanically caused by traction following cystocele.

**Tumor:** Fibroid, either in the anterior or posterior wall produces heaviness of the uterus and hence, it falls behind.

**Pelvic adhesions:** Adhesions, either inflammatory, operative, or due to pelvic endometriosis, pull the uterus posteriorly.



**Fig. 15.2:** Note the degree of displacement of anteverted uterus (B) due to full bladder (A) Reason to empty the bladder prior to examination

### INCIDENCE

Retroversion is present in about 15–20 percent of normal women.

### CLINICAL PRESENTATION

The condition is classified either as mobile and fixed or uncomplicated and complicated by pelvic diseases.

### MOBILE RETROVERTED UTERUS

#### Symptoms

Mobile retroverted uterus is quite common and almost always remains asymptomatic. **However, the following symptoms may be attributed to it.**

- ♦ *Chronic premenstrual pelvic pain* — It is due to varicosities in broad ligament produced by the kinks. The manifestations are those of ‘pelvic congestion syndrome’ (see p. 181, 557).
- ♦ *Backache.*
- ♦ *Dyspareunia* — Deep dyspareunia may be due to direct thrust by the penis against the retroflexed uterus or the prolapsed ovaries lying in the pouch of Douglas. Similar pain, if reproduced by pressing with examining fingers, may confirm its reality.
- ♦ *Infertility* — In third degree retroversion, the external os is away from the seminal pool at the posterior fornix during coitus or it may be occluded by the anterior vaginal wall. Associated underdevelopment of the uterus may also be a contributing factor.

The physician should however, think twice before declaring to the patient the fact that the particular symptomatology is related to the backward position of the womb. This applies especially to backache, chronic pelvic pain, or dyspareunia. In such cases, a Hodge-Smith pessary may be placed inside for about 3 months after correcting the uterine position to anteversion. If the symptoms are in abeyance during this period and recur back after its removal, it may be concluded that the symptoms are due to retroverted uterus. **This is known as ‘pessary test’.**

#### Signs

*Bimanual examination reveals* — (a) The cervix is directed upwards and forwards. (b) The body of the uterus is felt through the posterior fornix. It is found continuous with the cervix and it moves when the cervix is pressed up. The size of the uterus is difficult to assess at times.

*Speculum examination reveals* — the cervix comes in view much easily and the external os points forwards.

*Rectal examination* is of help to confirm the diagnosis.

### Fixed retroversion

The symptoms are related to the associated pelvic pathology. Menstrual abnormalities (menorrhagia), congestive dysmenorrhea, chronic pelvic pain, or dyspareunia are usually associated.

Whether the uterus is fixed or mobile can be elicited by attempting to replace it by moving the cervix backwards and by pushing the fundus upwards. Rectal examination may be more effective to elicit the findings.

It is indeed of paramount importance to identify the position of the uterus as it is often necessary to identify prior to minor intrauterine manipulations such as insertion of IUCD or introduction of uterine sound. **Emptying the bladder prior to internal examination is mandatory (Fig. 15.2).**

### DIFFERENTIAL DIAGNOSIS

The retrodisplacement may be confused with hard fecal mass in the rectum, small fibroid on the posterior wall of the uterus, and small ovarian cyst in the pouch of Douglas.

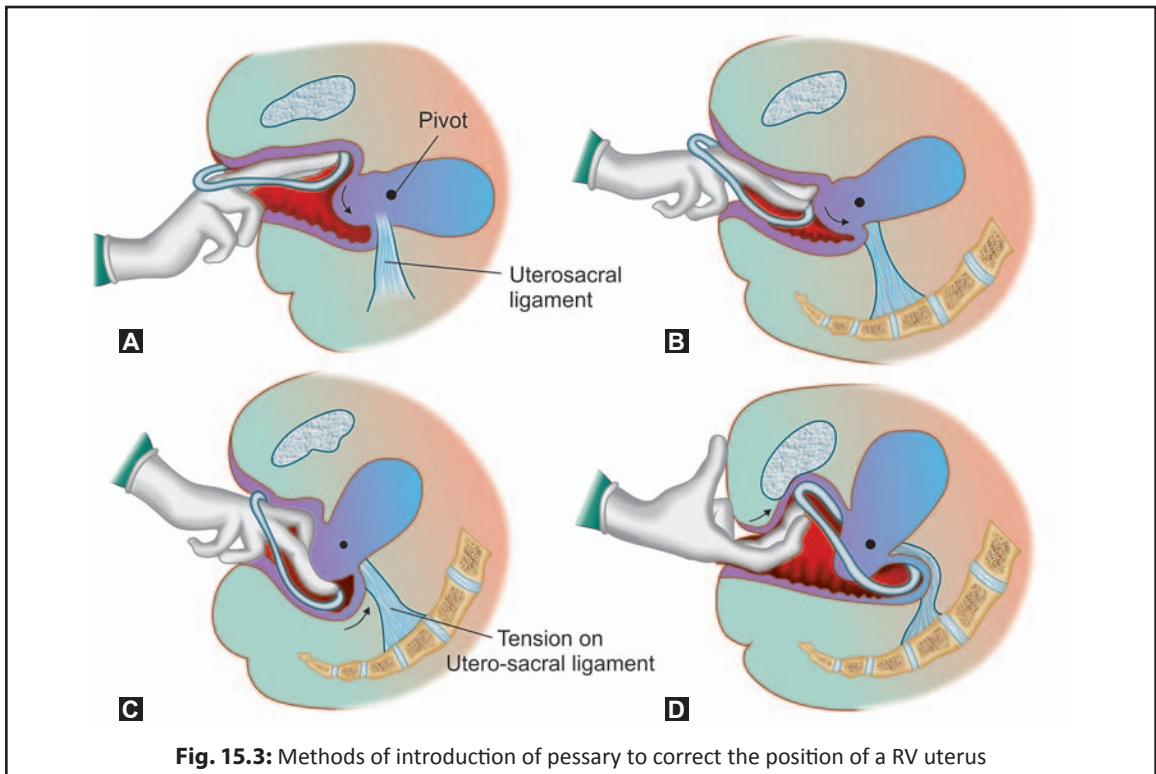
### PREGNANCY IN RETROVERTED UTERUS

**Retroversion *per se* has got practically no adverse effect either on fertility or on early pregnancy wastage.** In pregnancy, spontaneous correction usually occurs by 12–14 weeks. While the cause of infertility is mainly mechanical as mentioned earlier, repeated pregnancy wastage may be due to disturbance in uterine vascularity or due to thrust during intercourse especially in abortion prone women.

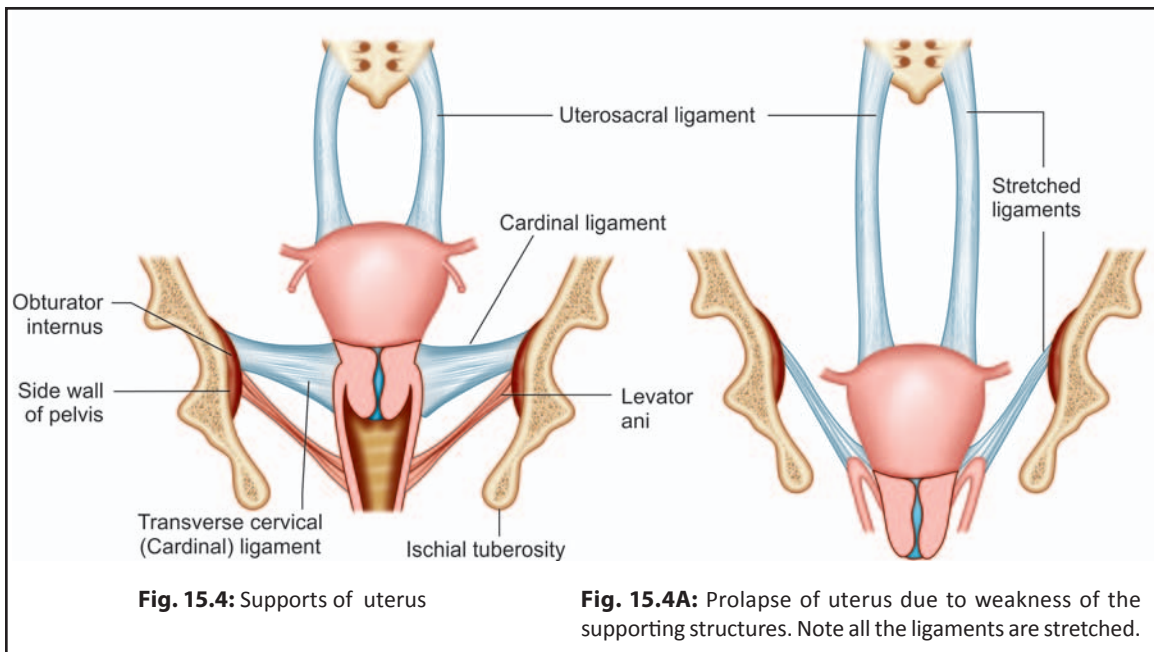
### PREVENTION

The following guidelines are of help during the weeks after abortion or childbirth:

- To empty the bladder regularly.
- To increase the tone of the pelvic muscles by regular exercise.



**Fig. 15.3:** Methods of introduction of pessary to correct the position of a RV uterus



**Fig. 15.4:** Supports of uterus

**Fig. 15.4A:** Prolapse of uterus due to weakness of the supporting structures. Note all the ligaments are stretched.

- To encourage lying in prone position for half to one hour once or twice daily between 2 and 4 weeks postpartum.

### CORRECTIVE TREATMENT

- Pessary
- Surgical

#### Pessary

Pessary is less commonly used in present day gynecologic practice. However, it may be indicated: (1) for pessary test, (2) in subinvolution of uterus (see p. 204), (3) in pregnancy when spontaneous correction to anteversion fails by 12th week.

Usually, Hodge-Smith pessary is used. The pessary acts by stretching the uterosacral ligaments so as to pull the cervix backwards (Fig. 15.3).

#### Surgical Treatment

Surgical correction is indicated in: (1) Cases where the 'pessary test' is positive indicating that the symptoms are due to retroversion. (2) Fixed retroverted uterus producing symptoms like backache or dyspareunia.

The principle of surgical correction is **ventro-suspension of the uterus** by plicating the round ligaments of both the sides extraperitoneally to the under surface of the anterior rectus sheath (see p. 603). This will pull the uterus forwards and maintains it permanently in the same position.

### PELVIC ORGAN PROLAPSE (POP)

Pelvic organ prolapse (POP) is one of the common clinical conditions met in day-to-day gynecological practice **especially among the parous women**. The entity includes descent of the vaginal wall and/or the uterus. It is in fact a form of hernia.

### SUPPORTS OF UTERUS

The uterus is normally placed in anteverted and anteflexed position. It lies in between the bladder and rectum. The cervix pierces the anterior vaginal wall almost at right angle to the axis of the vagina. **The external os lies at the level of ischial spines.**

The uterus is held in this position and at this level by supports conveniently grouped under **three tier systems**. The objective is to maintain the position and to prevent descent of the uterus through the natural urogenital hiatus in the pelvic floor (Fig. 15.4).

#### ▪ Upper tier

The upper most supports of the uterus primarily maintain the uterus in anteverted position. **The responsible structures are:**

- Endopelvic fascia covering the uterus.
- Round ligaments.

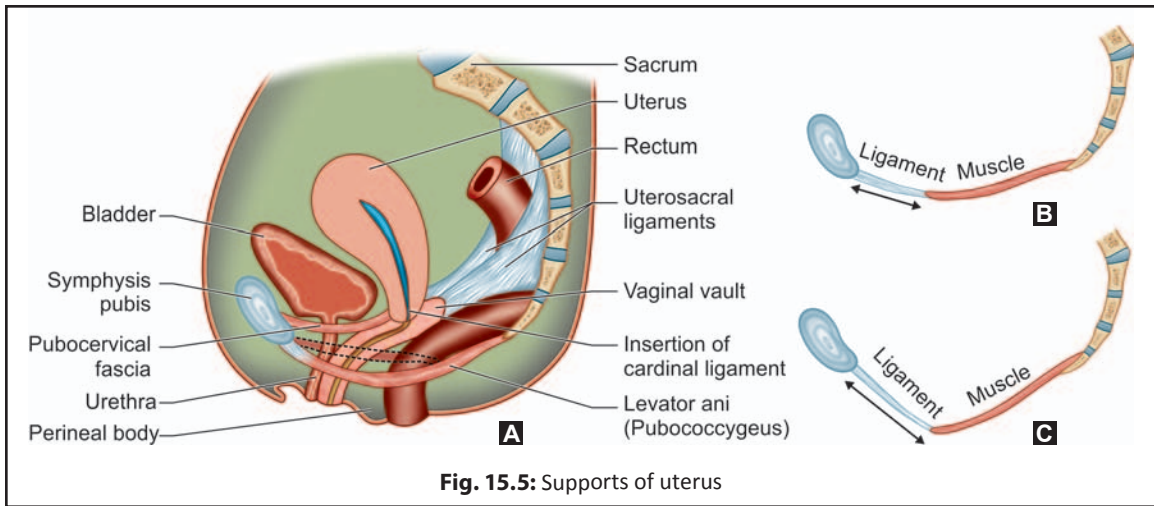


Fig. 15.5: Supports of uterus

- Broad ligaments with intervening pelvic cellular tissues.

The last two are actually acting as a guy rope with a steadying effect on the uterus. **They have no action in preventing descent of the uterus.**

- **Middle tier (Figs 15.5 and 15.6)**

This constitutes the strongest support of the uterus.

**The responsible structures are:**

- **Pericervical ring (Fig. 15.6)**—It is a collar of fibroelastic connective tissue encircling the supravaginal cervix. It is connected with the **pubocervical ligaments** and the vesicovaginal septum anteriorly, **cardinal ligaments** laterally and the **uterosacral ligaments** and the **rectovaginal septum posteriorly** (p. 24).

**Function:** It stabilizes the cervix at the level of interspinous diameter along with the other ligaments.

- **Pelvic cellular tissues**—The endopelvic fascia consist of connective tissues and smooth muscles. The blood vessels and nerves supplying the uterus, bladder, and vagina pass through it from the lateral pelvic wall. As they pass, the pelvic cellular tissues condense surrounding them and give good direct support to the viscera.

The endopelvic fascia at places is condensed and reinforced by plain muscles to form ligaments — Mackenrodt's, uterosacral, and pubocervical. On the medial side, these are attached to the pericervical ring covering the cervicovaginal junction and on the

other end are attached to the lateral, posterior, and anterior walls of the pelvis (Figs 15.5 and 15.6). These are anatomically, morphologically, and functionally the same unit. This hammock-like arrangement of condensed pelvic cellular tissues is the cardinal support of the uterus.

- **Inferior tier**

This gives the indirect support to the uterus. The support is principally given by the *pelvic floor muscles (levator ani), endopelvic fascia, levator plate, perineal body, and the urogenital diaphragm* (p. 17).

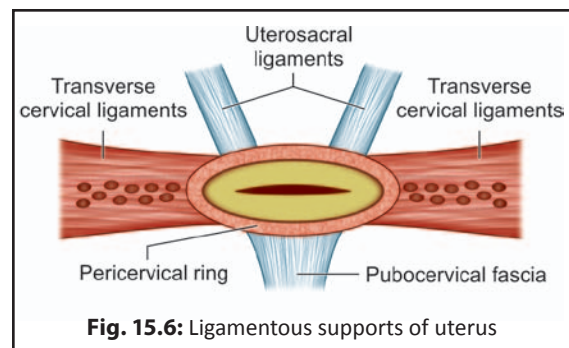


Fig. 15.6: Ligamentous supports of uterus

## SUPPORTS OF VAGINA

### SUPPORTS OF THE ANTERIOR VAGINAL WALL

- **Positional support** — In the erect posture, the vagina makes an angle of 45° to the horizontal. Normal vaginal axis is horizontal in the upper

two-third and vertical in the lower-third (see Fig. 15.5A). A well-supported vagina lies on the rectum and the levator plate (Figs. 15.5A and 15.5B). Any raised intra-abdominal pressure is transmitted exclusively to the anterior vaginal wall which is apposed to the posterior vaginal wall.

- **Pelvic cellular tissue** — The vagina is ensheathed by strong condensation of pelvic cellular tissue called **endopelvic fascia**.

Traced below, this fascia forms the posterior urethral ligament, which is anchored to the pubic bones giving strong support to the urethra. Traced laterally, this fascia forms the pubocervical fascia or ligament which is the anterior extension of the Mackenrodt's ligaments.

### SUPPORTS OF THE POSTERIOR VAGINAL WALL (FIG. 15.5)

- Endopelvic fascial sheath covering the vagina and rectum.
- Attachment of the uterosacral ligament to the lateral wall of the vault.

**The levator ani muscles with its fascial coverings:** This muscle is slug like a hammock around the midline pelvic effluents (urethra, vagina, and the anal canal). This strong, robust, and fatigue-resistant striated muscle guards the hiatus urogenitalis. It supports the pelvic viscera and counteracts the downward thrust of increased intra-abdominal pressure.

The **medial fibers** of the pubococcygeus part of levator ani muscles, are attached mainly to the urethra, vagina and rectum. Few fibrous pass behind the rectum, vagina, and the urethra forming a sling. These pubovisceral fibers of the levator ani muscles squeeze the rectum, vagina, and urethra and keep them closed by compressing against the pubic bone.

When the levator ani muscles are damaged, the pelvic floor opens and there is **widening of the hiatus urogenitalis**. The vagina is then pushed down by the increased intra-abdominal pressure. Eventually, the genital organs prolapse.

- **The levator plate (Figs. 15.5 A to C):** Clinically, it is a thick band of connective tissue formed by the medial fibers of the two levator ani muscles. Anatomically, it is the anococcygeal raphe that extends between the anorectal junction and the coccyx. Some of the fibers extend anteriorly encircling the anorectal junction and are inserted into the **perineal body**.

**The levator plate forms a horizontal supportive shelf upon which the rectum, upper vagina, and the uterus rest (Figs. 15.5A and B).** The horizontal position of this shelf is maintained by the anterior traction of the fibers of pubococcygeus and the iliococcygeus muscles. Due to its horizontal position, the levator plate can prevent the prolapse of genital organs. **The rectogenitourinary hiatus** enlarges and predisposes to prolapse of the genital organs when the levator plate

**TABLE 15.1 ETIOLOGY OF PELVIC ORGAN PROLAPSE (POP)**

ANATOMICAL FACTORS	CLINICAL FACTORS	
	Predisposing factors	Aggravating factors
<ul style="list-style-type: none"> <li>• Gravitational stress due to human bipedal posture</li> <li>• Anterior inclination of pelvis directing the force more anteriorly</li> <li>• Stress of parturition (Internal rotation) causing maximum damage to puborectal fibers of levator ani</li> <li>• Pelvic floor weakness due to urogenital hiatus and the direction of obstetric axis through the hiatus</li> <li>• Inherent weakness of the supporting structures (Genetic)</li> </ul>	<p><b>A. Acquired</b> Trauma of vaginal delivery causing injury (tear or break) to:</p> <ol style="list-style-type: none"> <li>(1) Ligaments (see p. 204)</li> <li>(2) Endopelvic fascia (see p. 204)</li> <li>(3) Levator muscle (myopathy)</li> <li>(4) Perineal body</li> <li>(5) Nerve (pudendal) and muscle damage due to repeated child birth</li> </ol>	<ul style="list-style-type: none"> <li>• Postmenopausal atrophy</li> <li>• Poor collagen tissue repair with age</li> <li>• Increased intra-abdominal pressure as in chronic lung disease and constipation</li> <li>• Occupation (weight lifting)</li> <li>• Asthenia and undernutrition</li> <li>• Obesity</li> <li>• Increased weight of the uterus as in fibroid or myohyperplasia</li> </ul> <p>These factors possibly operate where the supports of the genital organs are already weak</p>
	<p><b>B. Congenital (see p. 204)</b> Inborn weakness of supporting structures</p>	

is damaged and sags (Fig. 15.5C). This is due to the loss of tone of the levator ani muscles following injury, overstretching (child-birth process) or attenuation (menopause). Clinically, the levator plate is assessed by palpating the perineum between two fingers inside the introitus and the thumb outside. It is palpable as 2–2.5 cm band of muscle on each lateral side of the distal 1/3 of the vagina.

- **Perineal body** and urogenital diaphragm. **Perineal body** is a solid pyramidal structure at the central point of the perineum. It receives 9 muscles like the hub of a wheel that grasps the spokes. **Damage to perineal body causes loss of normal vaginal axis.**
- **Biomechanical Basis of uterovaginal supports** (Delancey – 1992) and Development of Prolapse have been discussed before (see p. 24)

### ETIOLOGY OF PELVIC ORGAN PROLAPSE (POP)

The genital prolapse occurs due to weakness of the structures supporting the organs in position. These factors may be anatomical or clinical. The clinical factors are grouped as:

- **Predisposing**    ▪ **Aggravating**

#### **PREDISPOSING FACTORS:** • Acquired • Congenital

**Acquired:** Vaginal delivery with consequent injury to the supporting structures is the single most important acquired predisposing factor in producing prolapse. The prolapse is unusual in cases delivered by cesarean section.

#### **The injury is caused by:**

- (1) Overstretching of the Mackenrodt's and uterosacral ligaments: (i) Premature bear down efforts prior to full dilatation of the cervix. (ii) Delivery with forceps or ventouse with forceful traction. (iii) Prolonged second stage of labor. (iv) Downward pressure on the uterine fundus in an attempt to deliver the placenta. (v) Precipitate labor.  
In all these conditions, the uterus tends to be pushed down into the flabby distended vagina.
- (2) Overstretching and breaks in the endopelvic fascial sheath.
- (3) Overstretching of the perineum.

- (4) Imperfect repair of the perineal injuries. Poor repair of collagen tissue.
- (5) Loss of levator function.
- (6) Neuromuscular damage of levator ani during childbirth.
- (7) Subinvolution of the supporting structures. This is particularly noticeable in: (i) Ill-nourished and asthenic women. (ii) Early resumption of activities which greatly increase intra-abdominal pressure before the tissues regain their tone. (iii) Repeated childbirths at frequent intervals.

**Congenital:** Congenital weakness of the supporting structures is responsible for nulliparous prolapse or prolapse following an easy vaginal delivery. One should be on the look out for an occult spina bifida and associated neurological abnormalities.

### CLINICAL TYPES OF PELVIC ORGAN PROLAPSE

The genital prolapse is broadly grouped into:

- **Vaginal prolapse**    • **Uterine prolapse**

While vaginal prolapse can occur independently without uterine descent, the uterine prolapse is usually associated with variable degrees of vaginal descent.

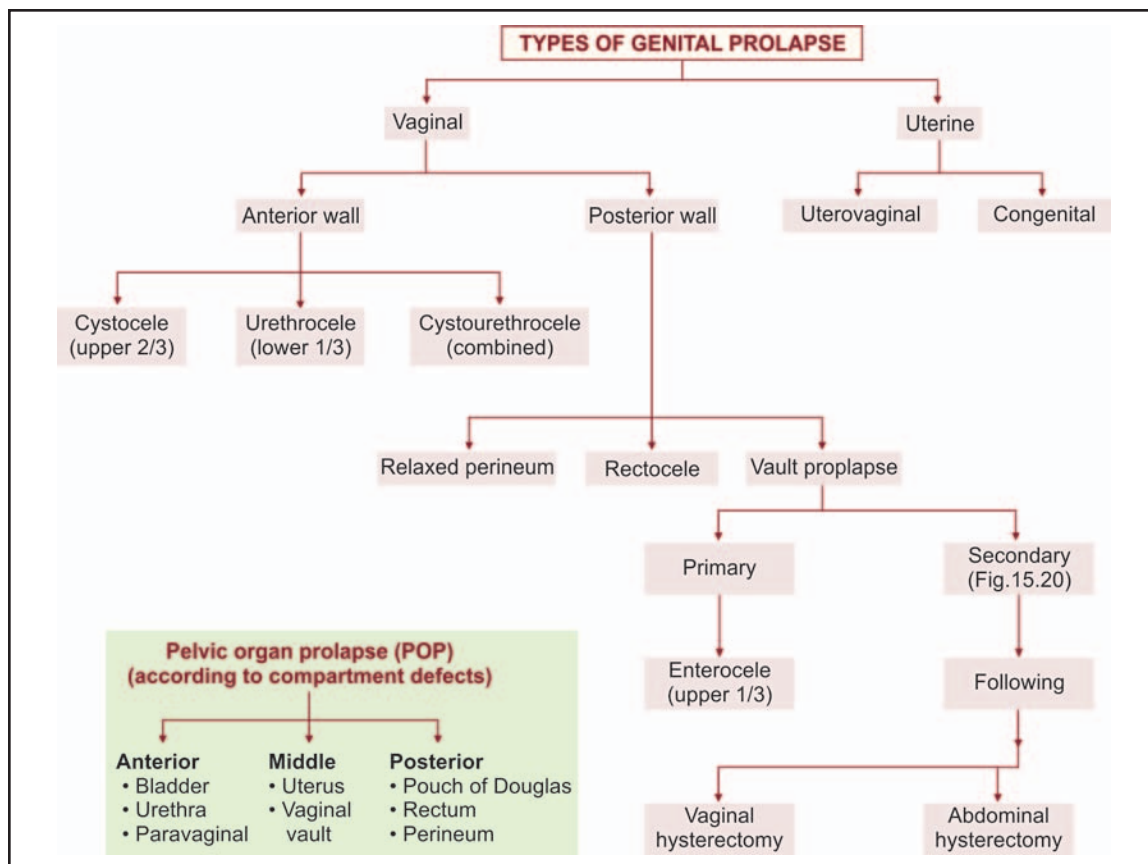
#### **VAGINAL PROLAPSE**

##### **Anterior wall**

- **Cystocele** — The cystocele is **formed by laxity and descent of the upper two-thirds of the anterior vaginal wall**. As the bladder base is closely related to this area, there is herniation of the bladder through the lax anterior wall.
- **Urethrocele** — When there is laxity of the **lower-third of the anterior vaginal wall**, the urethra herniates through it. This may appear independently or usually along with cystocele and is called cystourethrocele.

##### **Posterior wall**

- **Relaxed perineum** — Torn perineal body produces gaping introitus with bulge of the lower part of the posterior vaginal wall.
- **Rectocele** — There is laxity of the middle-third of the posterior vaginal wall and the adjacent recto-vaginal septum. As a result, there is herniation of the rectum through the lax area.



### Vault prolapse

- *Enterocele* — Laxity of the upper-third of the posterior vaginal wall results in herniation of the pouch of Douglas. It may contain omentum or even loop of small bowel and hence, called enterocele. **Traction enterocele** is secondary to uterovaginal prolapse. Pulsion enterocele is secondary to chronically raised intra-abdominal pressure.
- **Secondary vault prolapse** — This may occur following either vaginal or abdominal hysterectomy. Undetected enterocele during initial operation or inadequate primary repair usually results in secondary vault prolapse (Fig. 15.20).

### Uterine prolapse

There are two types:

- **Uterovaginal prolapse** is the prolapse of the uterus, cervix and upper vagina.

This is the commonest type. Cystocele occurs first followed by traction effect on the cervix causing

retroversion of the uterus. Intra-abdominal pressure has got piston like action on the uterus thereby pushing it down into the vagina.

- **Congenital**

There is usually no cystocele. The uterus herniates down along with inverted upper vagina. This is often met in nulliparous women and hence called **nulliparous prolapse**. The cause is congenital weak-ness of the supporting structures holding the uterus in position.

## DEGREES OF UTERINE PROLAPSE (CLINICAL)

Three degrees are described:

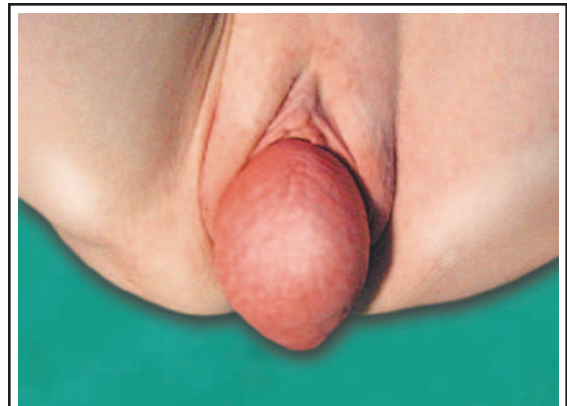**FIRST DEGREE** — The uterus descends down from its normal anatomical position (external os at the level of ischial spines) but the external os still remains inside the vagina.

**SECOND DEGREE** — The external os protrudes outside the vaginal introitus but the uterine body still remains inside the vagina (Fig. 15.8).

**THIRD DEGREE** (*Syn: Procidentia, Complete prolapse*)— The uterine cervix and body descends to lie outside the introitus (Fig. 15.9).

**Procidentia** involves prolapse of the uterus with eversion of the entire vagina.

**Complex prolapse** is one when prolapse is associated with some other specific defects. **Complex prolapse** includes the following: prolapse with urinary or fecal incontinence, nulliparous prolapse, recurrent prolapse, vaginal and rectal prolapse, or prolapse in a frail woman.



**Fig. 15.8:** Second degree uterine prolapse. Marked cystocele and there is decubitus ulcer

**TABLE 15.2**

**PELVIC ORGAN PROLAPSE (POP) QUANTITATIVE SCORING**

Stage	Description
0	No descent of pelvic organs
I	Leading edge of the prolapse remains 1 cm or more above the hymenal ring ( $\leq 1$ cm)
II	Leading edge of the prolapse extends from 1 cm above to 1 cm below the hymenal ring
III	From 1 cm beyond the hymenal ring but without complete vaginal eversion
IV	Essentially complete eversion of vagina

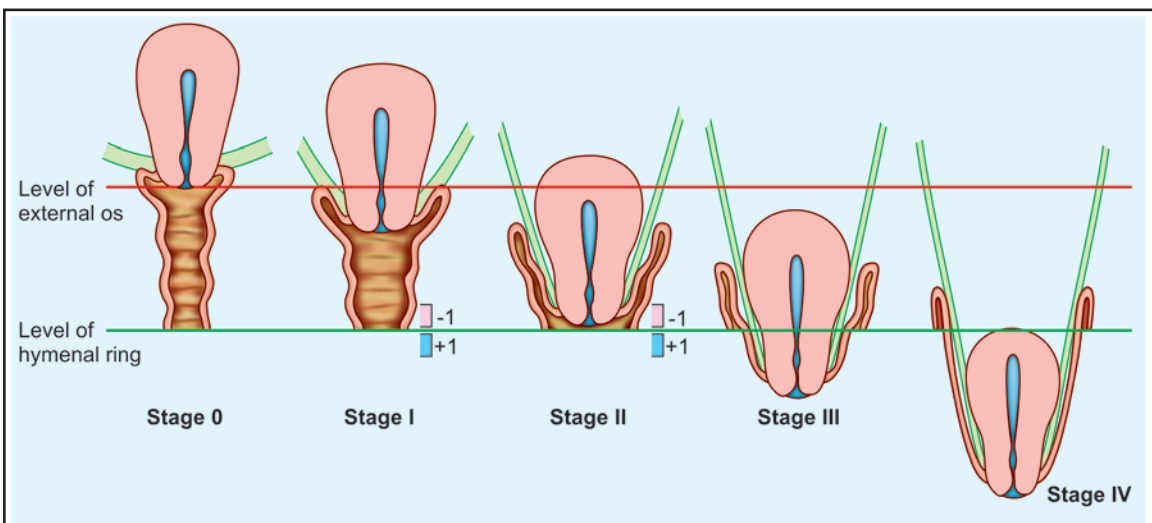
Quantitative gradings of Pelvic Organ Prolapse [ICS, AUGS, SGS – 1996]

**Pelvic Organ Prolapse Quantification (POP-Q)** system has been recommended by the International Continence Society as it standardizes terminology and is most objective, site specific and anatomical (Fig. 15.10)

**MORBID CHANGES**

**Vaginal mucosa:** The mucosa becomes stretched and if exposed to air, becomes thickened and dry with surface keratinization. There may be pigmentation.

**Decubitus ulcer (Fig. 15.8):** It is a trophic ulcer, always found at the dependent part of the prolapsed mass lying outside the introitus. There is initial surface keratinization → cracks → infection → sloughing



**Fig. 15.7:** Quantitative gradings of Pelvic Organ Prolapse [ICS, AUGS, SGS – 1996]



→ ulceration. There is complete denudation of the surface epithelium. The diminished circulation is due to constriction of the prolapsed mass by the vaginal opening and narrowing of the uterine vessels by the stretching effect.

**Management:** (a) Cervical cytology to exclude malignancy. (b) Manual reduction of prolapse. (c) Vaginal pack with roller bandage soaked with antiseptic lotion glycerin and acriflavin or using estrogen cream (postmenopausal women).

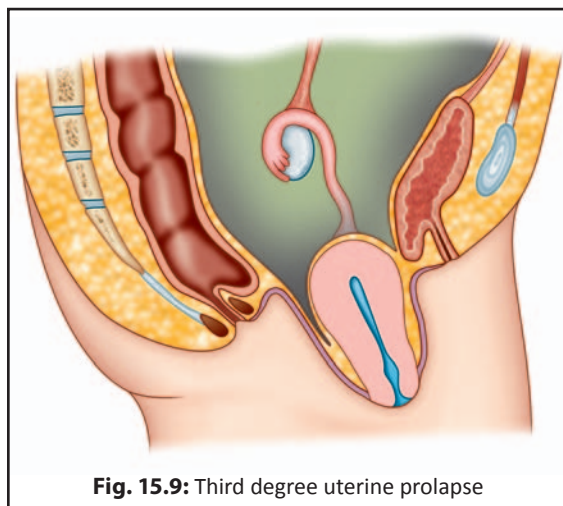
### Cervix

**Vaginal part** — There is chronic congestion which may lead to hyperplasia and hypertrophy of the fibromusculoglandular components. These lead to vaginal part becoming bulky and congested. Addition of infection leads to purulent or at times blood-stained discharge from ulceration.

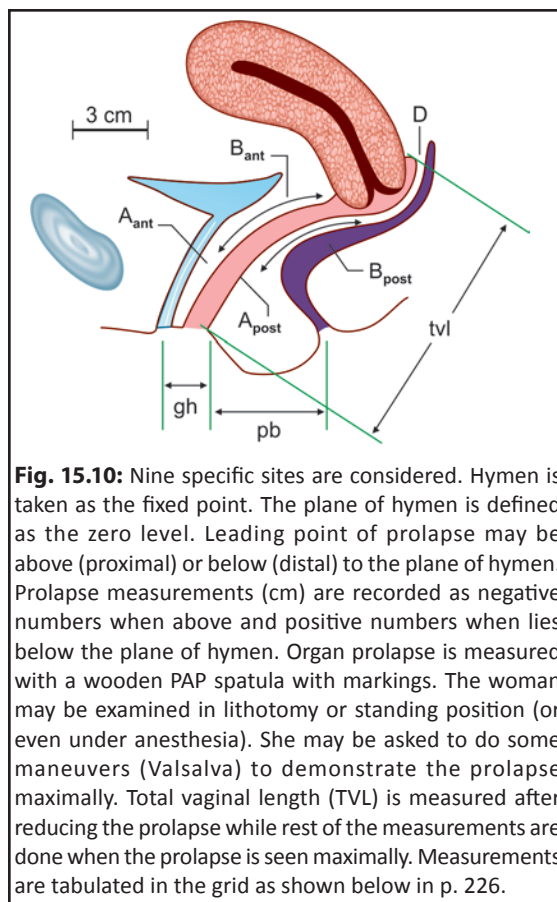
**Supravaginal part** — The supravaginal part becomes elongated due to the strain imposed by the pull of the cardinal ligaments to keep the cervix in position, whereas the weight of the uterus makes it fall through the vaginal axis. Chronic interference of venous and lymphatic drainage favors elongation.

### Urinary System

**Bladder** — There is incomplete emptying of the bladder due to sharp angulation of the urethra against the pubourethral ligament during straining. As a result, there is hypertrophy of the bladder wall and trabeculation. Incomplete evacuation also favors cystitis.



**Fig. 15.9:** Third degree uterine prolapse



**Fig. 15.10:** Nine specific sites are considered. Hymen is taken as the fixed point. The plane of hymen is defined as the zero level. Leading point of prolapse may be above (proximal) or below (distal) to the plane of hymen. Prolapse measurements (cm) are recorded as negative numbers when above and positive numbers when lies below the plane of hymen. Organ prolapse is measured with a wooden PAP spatula with markings. The woman may be examined in lithotomy or standing position (or even under anesthesia). She may be asked to do some maneuvers (Valsalva) to demonstrate the prolapse maximally. Total vaginal length (TVL) is measured after reducing the prolapse while rest of the measurements are done when the prolapse is seen maximally. Measurements are tabulated in the grid as shown below in p. 226.

**Ureters** — The ureters are carried downwards along with elongated Mackenrodt's ligaments and thus, mechanically obstructed by the hiatus of the pelvic floor. They may be compressed even by the uterine arteries at their crossing. As a result, hydroureteric changes may occur.

Infection of the bladder may thus ascend up to produce pyelitis or pyelonephritis. On rare occasions, uremia may occur, especially in long-standing cases of procidentia.

**Incarceration:** At times, infection of the para-vaginal and cervical tissues makes the entire prolapsed mass edematous and congested. As a result, the mass may be irreducible.

**Peritonitis:** Rarely, the peritoneal infection (pelvic peritonitis) may occur through the posterior vaginal wall.

**Carcinoma:** Carcinoma rarely develops on decubitus ulcer.

## SYMPTOMS

The symptoms are variable. Even with minor degree, the symptoms may be pronounced, paradoxically there may not be any appreciable symptom even in severe degree. However, **the following symptoms are usually associated:**

- (a) Feeling of something coming down per vaginam, especially while she is moving about. There may be variable discomfort on walking when the mass comes outside the introitus.
- (b) Backache or dragging pain in the pelvis.

The above two symptoms are usually relieved on lying down.

- (c) Dyspareunia.

- (d) Urinary symptoms (**in presence of cystocele**).

- ◆ Difficulty in passing urine, more the strenuous effort, the less effective is the evacuation. The patient has to elevate the anterior vaginal wall for evacuation of the bladder.
- ◆ Incomplete evacuation may lead to frequent desire to pass urine.
- ◆ Urgency and frequency of micturition may also be due to cystitis.
- ◆ Painful micturition is due to infection.
- ◆ Stress incontinence is usually due to associated urethrocele.
- ◆ Retention of urine may rarely occur.

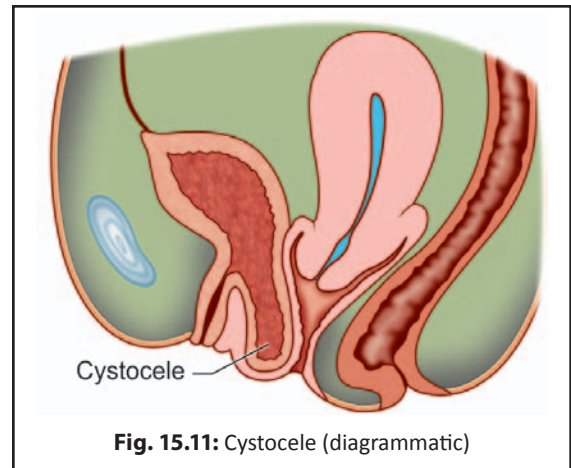
- (e) Bowel symptom (**in presence of rectocele**).

- ◆ Difficulty in passing stool. The patient has to push back the posterior vaginal wall in position to complete the evacuation of feces. Fecal incontinence may be associated.

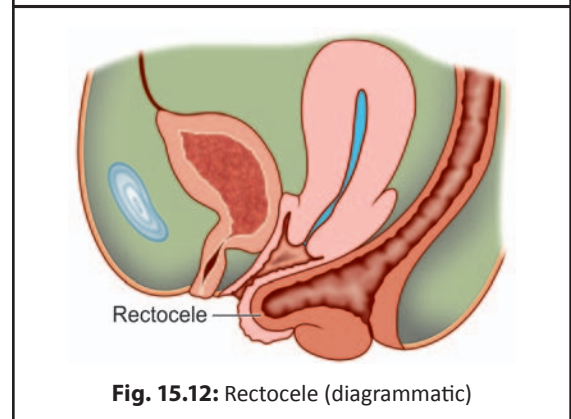
- (f) Excessive white or blood-stained discharge per vaginam is due to associated vaginitis or decubitus ulcer.

## CLINICAL EXAMINATION AND DIAGNOSIS OF POP

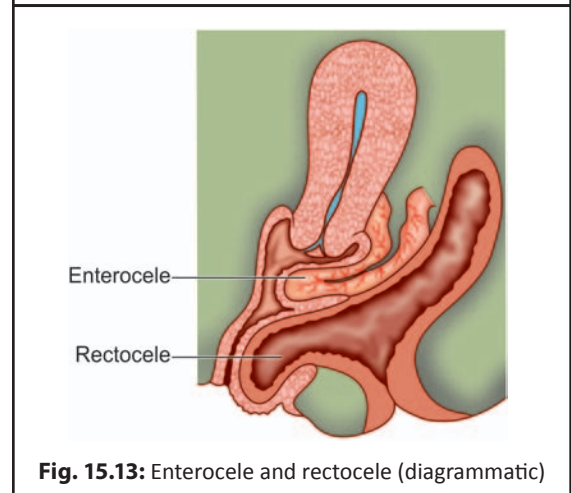
- A composite examination — inspection and palpation: Vaginal, rectal, rectovaginal or even under anesthesia may be required to arrive at a correct diagnosis.
- General examination — details, including BMI, signs of myopathy or neuropathy, features of chronic airway disease or any abdominal mass should be done.



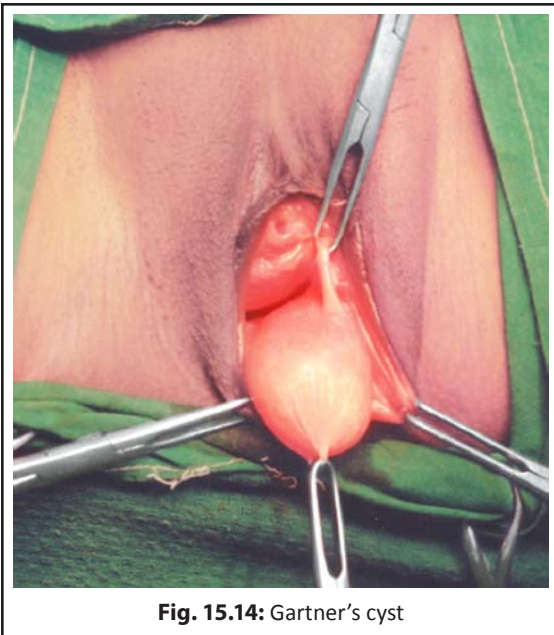
**Fig. 15.11:** Cystocele (diagrammatic)



**Fig. 15.12:** Rectocele (diagrammatic)



**Fig. 15.13:** Enterocele and rectocele (diagrammatic)



**Fig. 15.14:** Gartner's cyst

- Pelvic Organ Prolapse (POP) is evaluated by pelvic examination in both dorsal and standing positions. The patient is asked to strain as to perform a Valsalva maneuver during examination. This often helps to demonstrate a prolapse which may not be seen at rest.
- A negative finding on inspection in dorsal position should be reconfirmed by asking the patient to strain on squatting position.
- Prolapse of one organ (uterus) is usually associated with prolapse of the adjacent organs (bladder, rectum).
- Etiological aspect of prolapse should be evaluated.

**Cystocele (Fig. 15.11):** There is a bulge of varying degree of the anterior vaginal wall, which increases when the patient is asked to strain. This may be seen on inspection. In others, to elicit this, one may have to separate the labia or depress the posterior vaginal wall with fingers or using Sims' speculum, placing the patient in lateral position (see p. 103).

The mucosa over the bulge has got transverse rugosities. The bulge has got impulse on coughing, with diffuse margins and is reducible (Fig. 15.11).

**Cystourethrocele:** The bulging of the anterior vaginal wall involves the lower-third also. One may find the

urine to escape out through the urethral meatus when the patient is asked to cough — stress incontinence. **To elicit the test, the bladder should be full.**

**Relaxed perineum:** There is gaping introitus with old scar of incomplete perineal tear. The lower part of the posterior vaginal wall is visible with or without straining.

**Rectocele and enterocele:** When the two conditions exist together, there is bulging of the posterior vaginal wall with a transverse sulcus between the two. The midvaginal one being rectocele with diffuse margins and reducible. This is visualized by retracting the anterior vaginal wall by Landon's retractor. **Ultimate differentiation of the two entities is by rectal or rectovaginal examination.** In enterocele, the bulging is close to the cervix and cannot be reached by the finger inside the rectum (Figs 15.12 and 15.13).

**Uterine prolapse:** In second or third degree of prolapse, inspection can reveal a mass protruding out through the introitus, the leading part of which is the external os. In first degree of uterine descent, the diagnosis is made through speculum examination when one finds the cervical descent below the level of ischial spines on straining. In others, however, the external os is visible on separating the labia (Fig. 15.8).

**To diagnose a third degree prolapse, palpation is essential.** If the thumb placed anteriorly and the fingers posteriorly above the mass outside the introitus are apposed, it is a third degree (Fig. 15.9). *Degree of prolapse or POP quantification should be done.*

There may be evidences of decubitus ulceration or dark pigmented areas.

Bimanual examination reveals shallow vaginal fornices and normal length of the vaginal cervix with normal size uterine body. The introduction of a sound reveals marked increase in length of the uterine cavity. This signifies elongation of the supravaginal part of the cervix.

**Levator ani muscle tone** is assessed by placing examining fingers (index and middle) inside the vagina and thumb outside. The muscle (pubo vaginalis) is palpated in the lower third of vagina. Patient is asked to squeeze the anus and the muscle tone is felt. Rectal examination helps to detect deficient perineum.

## DIFFERENTIAL DIAGNOSIS

**Cystocele:** The cystocele is often confused with a cyst in the anterior vaginal wall, the commonest being Gartner's cyst (retention cyst in remnants of Wolffian duct).

### Features of Gartner's cyst (Fig. 15.14) are:

- Situated anteriorly or anterolaterally and of variable sizes.
- Rugosities of the overlying vaginal mucosa are lost.
- Vaginal mucosa over it becomes tense and shiny.
- Margins are well-defined.
- It is not reducible.
- There is no impulse on coughing.
- The metal catheter tip introduced per urethra fails to come underneath the vaginal mucosa.

## Uterine Prolapse

### (a) *Congenital elongation of the cervix* (Fig. 18.6, p. 270)

- It is unassociated with prolapse (usually).
- Vaginal part of the cervix is elongated.
- External os lies below the level of ischial spines.
- Vaginal fornices are narrow and deep.
- Cervix looks conical.
- Uterine body is normal in size and in position.

### b. *Chronic inversion* (Fig. 15.22)

- Leading protruding mass is broad.
- There is no opening visible on the leading part.
- It looks shaggy.
- Internal examination reveals — cervical rim is on the top around the mass.
- Rectal examination confirms the absence of the uterine body and a cup-like depression is felt.

### c. *Fibroid polyp* (Fig. 15.23)

- The mass is saggy with a broad leading part.
- No opening is visible on the leading part.
- Internal examination reveals the pedicle coming out through the cervical canal or arising from the cervix.
- Rectal examination reveals normal shape and position of the uterus.

## MANAGEMENT OF PROLAPSE

- Preventive
- Conservative
- Surgery

### PREVENTIVE

The following guidelines may be prescribed to prevent or minimize genital prolapse.

#### *Adequate antenatal and intranatal care*

- ◆ To avoid injury to the supporting structures during the time of vaginal delivery either spontaneous or instrumental.

#### *Adequate postnatal care*

- ◆ To encourage early ambulance.
- ◆ To encourage pelvic floor exercises by squeezing the pelvic floor muscles in the puerperium.

#### *General measures*

- ◆ To avoid strenuous activities, chronic cough, constipation and heavy weight lifting.
- ◆ To avoid future pregnancy too soon and too many by contraceptive practice.

### CONSERVATIVE

#### Indications of conservative management are:

- Asymptomatic women.
- Mild degree prolapse.
- POP in early pregnancy.

Meanwhile, following measures may be taken :

- Improvement of general measures (see above).
- Estrogen replacement therapy may improve minor degree prolapse in postmenopausal women.
- Pelvic floor exercises in an attempt to strengthen the muscles (Kegel exercises).
- Pessary treatment.

### PESSARY TREATMENT

It should be emphasized that the pessary cannot cure prolapse but relieves the symptoms by stretching the hiatus urogenitalis, thus preventing vaginal and uterine descent. **Indications of use are:**

- ◆ *Early pregnancy* — The pessary should be placed inside up to 18 weeks when the uterus becomes sufficiently enlarged to sit on the brim of the pelvis.

- ▶ *Puerperium* — to facilitate involution.
- ▶ *Patients absolutely unfit for surgery* especially with short life expectancy.
- ▶ *Patient's unwillingness* for operation.
- ▶ *While waiting for operation.*
- ▶ *Additional benefits:* Improvement of urinary symptoms (voiding problems, urgency).

## SURGICAL MANAGEMENT OF PROLAPSE

### GUIDELINES FOR PROLAPSE SURGERY

- Surgery is the treatment of symptomatic prolapse where conservative management has failed or is not indicated.
- Surgical procedures may be: (A) Restorative— (i) correcting her own support tissues (Table 15.3) or (ii) compensatory— using permanent graft material (p. 224). (B) Extirpative — removing the uterus and correcting the support tissues. (C) Obliterative — closing the vagina (colpocleisis p. 221).
- Meticulous examination, even under anesthesia, is necessary to establish the correct diagnosis of the

organ prolapsed so that effective and appropriate repair can be carried out.

- There is no single procedure for all types of prolapse. **Factors determining the choice of surgery are:** Patient's age, parity, degree of prolapse, any prior surgery for prolapse, type of prolapse (cystocele, enterocele) and associated factors (urinary/fecal incontinence, PID), any associated comorbid condition (cardiac disease).

**TYPES OF OPERATION:** See Table 15.3.

### Anterior colporrhaphy (Fig. 15.15)

This operation is designed to correct cystocele and urethrocele. The underlying principles are to excise a portion of the relaxed anterior vaginal wall, to mobilize the bladder and push it upwards after cutting the vesicocervical ligament. The bladder is then permanently supported by plicating the endopelvic fascia and the pubocervical fascia under the bladder neck in the midline.

### Steps of operation (Fig. 15.15)

#### Preliminaries

- The operation is done under general or epidural anesthesia.

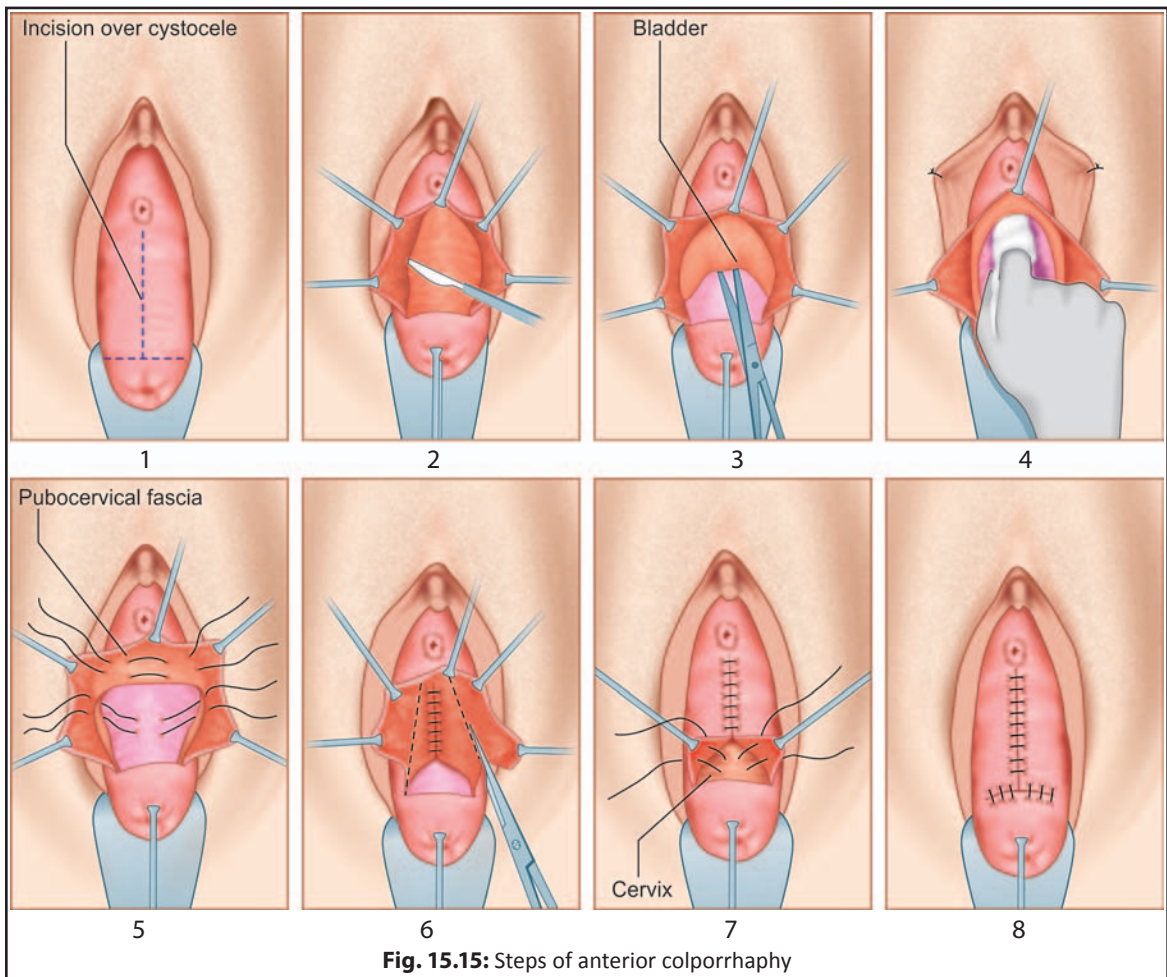
**TABLE 15.3** TYPE OF PROLAPSE AND THE COMMON SURGICAL REPAIR PROCEDURES

Organ descent	Clinical condition	Type of operation
<b>VAGINAL WALL</b> Anterior (Upper 2/3) or whole  Posterior (Lower 2/3) Posterior (Upper 1/3)  Combined anterior and posterior	Cystocele/cystourethrocele Paravaginal defect Rectocele Enterocele  Cystocele and rectocele	<ul style="list-style-type: none"> <li>◆ Anterior colporrhaphy (p. 211)</li> <li>◆ Paravaginal defect repair (p. 213).</li> <li>◆ Colpoperineorrhaphy (p. 213)</li> <li>◆ Vaginal repair of enterocele with PFR (p. 215)</li> <li>◆ McCall culdoplasty (p. 216)</li> <li>◆ Moscovitch procedure (p. 216)</li> <li>◆ Pelvic floor repair (PFR) (p. 216)</li> </ul>
<b>UTEROVAGINAL</b> Uterus along with vaginal walls	Uterovaginal prolapse	<ul style="list-style-type: none"> <li>◆ Vaginal hysterectomy with PFR (p. 217)</li> <li>◆ Fothergill's operation (preservation of uterus) (p. 216)</li> </ul>
<b>VAGINAL WALL FOLLOWING HYSTERECTOMY</b> (Vaginal or abdominal)	Vault prolapse (secondary)	<p><b>Vaginal:</b> (i) Repair of vaginal vault along with PFR (p. 213, 220)</p> <p>(ii) Sacrospinous colpopexy (p. 221)</p> <p>(iii) Colpocleisis (Le Fort) (p. 221)</p> <p><b>Abdominal:</b> (i) Sacral colpopexy (p. 221)</p>
<b>Uterus (without vaginal walls)</b>	Congenital or nulliparous prolapse	Cervicopexy or Sling (Purandare's) operation (p. 221)

- The patient is placed in lithotomy position.
- Vulva and vagina are to be swabbed with antiseptic solution.
- The perineum is to be draped with sterile towel and legs with legging.
- Bladder is to be emptied by metal catheter.
- Vaginal examination is done to assess the type and degree of prolapse.

### Actual steps (Fig. 15.15)

- Sims' posterior vaginal speculum is introduced and the anterior lip of the cervix is held by multiple teathed vulsellum and firmly brought down by assistant (Fig. 15.15.2).
- A metal catheter is introduced to know the lower limit of the bladder.
- An inverted 'T' incision is made on the anterior vaginal wall. The horizontal incision is made below the bladder and the vertical incision is made starting from the midpoint of the transverse incision up to a point about 1.5 cm below the external urethral meatus (Fig. 15.15.1).
- The triangular vaginal flaps including the fascia on either sides are separated from the endopelvic fascia covering the bladder by knife and gauze dissection. The line of cleavage is vesicovaginal space, and, if properly negotiated, the dissection is easy with minimal blood loss (Fig. 15.15.2).
- The bladder with the covering endopelvic fascia (pubocervical) is now exposed as the edges of the vaginal wall are retracted laterally.



**Fig. 15.15:** Steps of anterior colporrhaphy

- The vesicocervical ligament is held up with Allis tissue or toothed dissecting forceps and divided. The bladder is then pushed up by gauze covered finger till the peritoneum of the uterovesical pouch is visible. The vesicocervical space is now exposed (Figs 15.15.3 and 15.15.4).
- The pubocervical fascia is plicated by interrupted sutures with No 'O' chromic catgut using round body needle. The lower one or two stitches include a bite on the cervix, thus closing the hiatus through which the bladder herniates (Fig. 15.15.5).
- The redundant portion of the vaginal mucosa is cut on either side (Fig. 15.15.6).
- The cut margins of the vagina are apposed by interrupted sutures with No. 'O' chromic catgut using cutting needle (Figs 15.15.7 and 15.15.8).
- The catheter is reintroduced once more to be sure that the bladder is not injured.
- Toileting of the vagina is done.
- Vagina is tightly packed with roller gauze smeared with antiseptic cream.
- A self-retaining catheter is introduced.

The last two formalities are optional.

### Paravaginal defect and its repair (see p. 24).

Paravaginal defect is characterized by presence of rugae on the anterior vagina and absence of sulci on the lateral vagina; whereas in central defect (cystocele), rugae are absent and the lateral vaginal sulci is present.

Anterior vaginal wall prolapse (cystocele) is repaired by anterior colporrhaphy and plicating the endopelvic fascia in the midline under the bladder neck. But anterior vaginal prolapse may be due to the detachment of the endopelvic fascia from the lateral pelvic side wall. In that case, repair should be done by fixing (reattaching) the endopelvic fascia to the arcus tendineus fascia (white line) of the pelvis. This may be done retropubically through the space of Retzius or vaginally. This is indicated in cases with recurrent cystocele following repair.

### Perineorrhaphy/Colpoperineorrhaphy

It is an operation designed to repair the prolapse of posterior vaginal wall. Its uses and extent of repair are employed in:

- ◆ *Relaxed perineum* — The operation is extended to repair the torn perineal body.
- ◆ *Rectocele* — The repair is extended to correct rectocele by tightening the pararectal fascia.
- ◆ *Enterocele* — High perineorrhaphy is to be done right up to the cervicovaginal junction along with correction of enterocele.

**Restoration of perineal body is essential with any form of pelvic floor repair. This maintains the normal vaginal axis.**

### Steps of operation (Fig. 15.16)

**Preliminaries:** The preliminaries are to be followed as in anterior colporrhaphy.

### Actual steps

- A pair of Allis tissue forceps is placed on each side at the lower end of labium minus and a third pair of Allis is placed on the posterior vaginal wall in the midline well above the rectocele bulge (Fig. 15.16.1).
- A horizontal incision is made on the mucocutaneous junction joining the two Allis tissue forceps (Fig. 15.16.1).
- Through this incision, with the help of perineorrhaphy scissors, the posterior vaginal wall is dissected off from the perineal body and rectum up to the third Allis forceps placed on the posterior vaginal wall (Fig. 15.16.1).
- A vertical incision is made from the apex to the middle of the horizontal incision (inverted 'T' shaped incision) (Fig. 15.16.1).
- The two triangular flaps are now dissected laterally to expose the rectum and musculofascial structures levator ani muscle (Fig. 15.16.2).
- The lax vaginal flaps are excised.
- The rectocele is corrected by suturing the pararectal fascia with interrupted sutures.
- Two or three interrupted sutures are placed through the levator ani and fibromuscular tissues of the perineal body using No. 'I' catgut. The rectum should be pressed back by finger while the sutures are placed. The knots are to be placed at a later stage (Fig. 15.16.3).
- The cut margins of the posterior vaginal wall are approximated, starting from the apex using No. 'O' catgut until it reaches up to the perineal body (Fig. 15.16.4).
- The knots are now placed to the sutures passed through the perineal body.
- The rest of the posterior vaginal wall and the skin margins are apposed by interrupted catgut sutures (Fig. 15.16.5).
- Toileting of the vagina is done.
- Tight vaginal pack is optional.

### REPAIR OF ENTEROCELE AND VAULT PROLAPSE (FIG. 15.17)

Enterocele is almost always associated with genital prolapse. Along with repair operation, enterocele is to be corrected **transvaginally**. The principles of

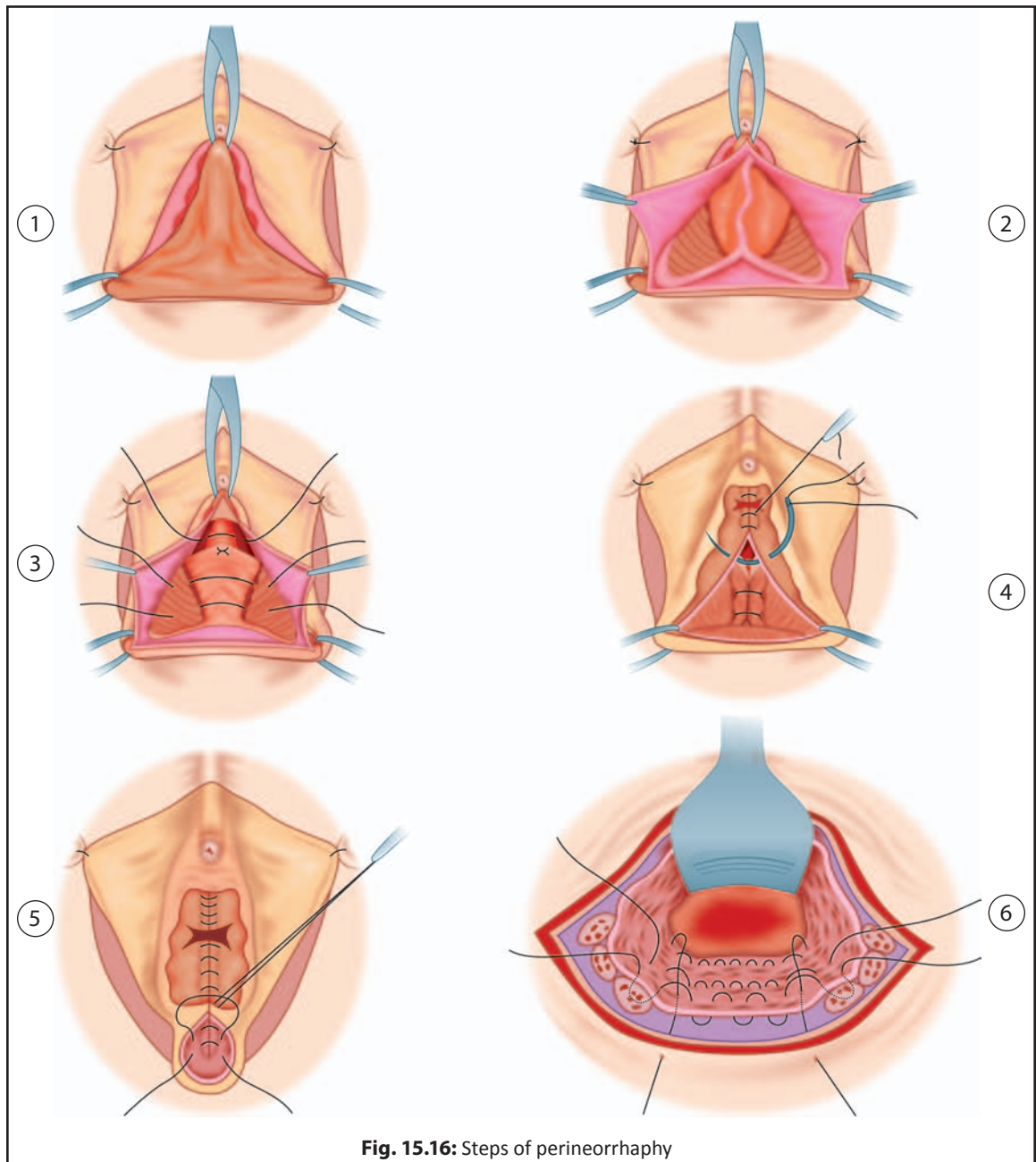
correction are to obliterate the neck of the enterocele sac as high as possible by purse string suture, to excise the excess peritoneal sac and approximation of the uterosacral ligaments (Fig. 15.17).

### Actual steps

- An inverted 'T' shaped incision is made with the vertical

arm of the 'T' extending up to the apex of the vaginal vault and the horizontal arm, along the mucocutaneous border (Fig. 15.16.1).

- Dissection is carried out to expose the enterocele sac (Fig. 15.17.(1)).
- The sac is opened, the contents (bowel, omentum) are pushed away (Fig. 15.17.(2)).



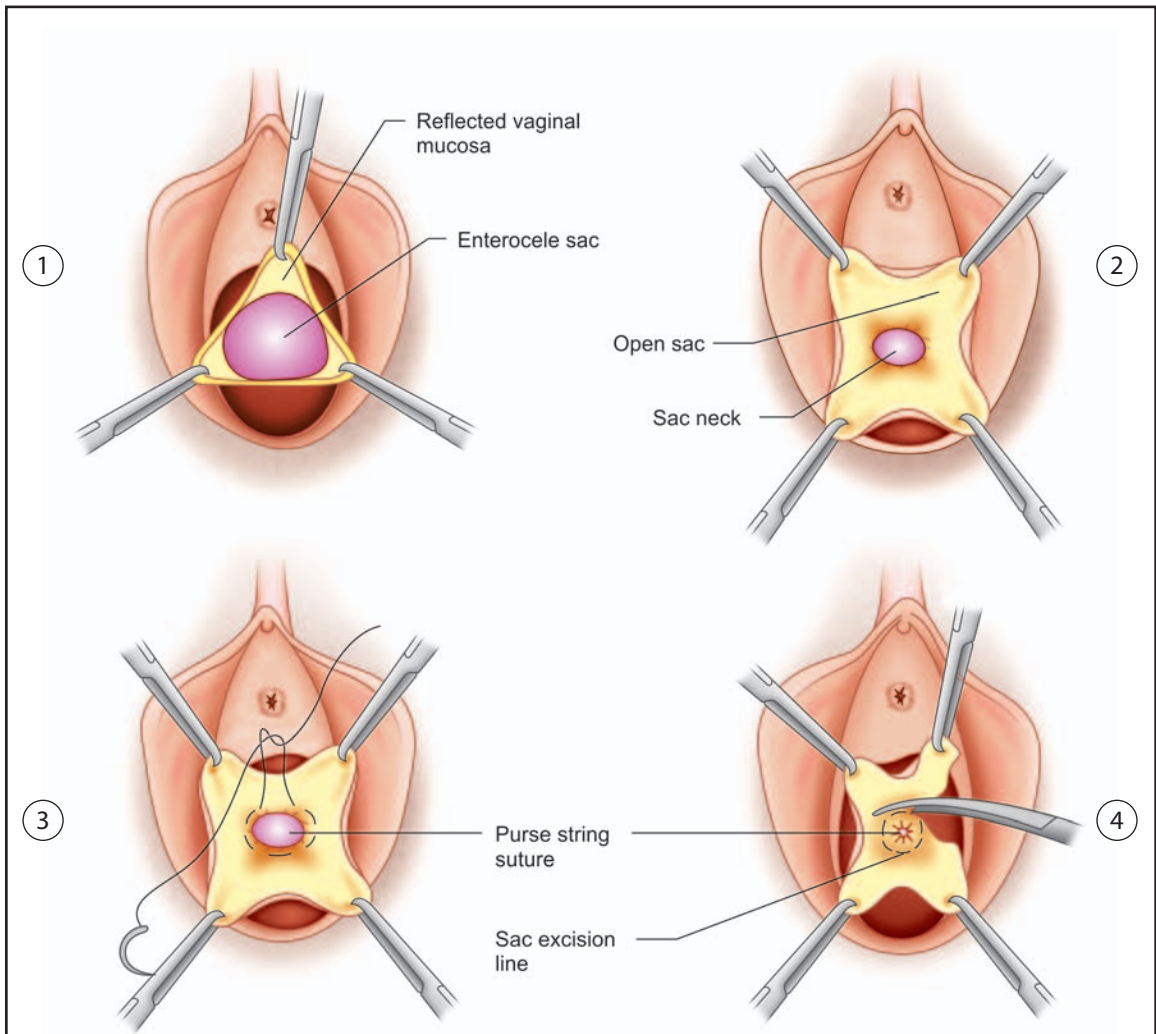
**Fig. 15.16:** Steps of perineorrhaphy



- The peritoneum of the posterior *cul-de-sac* is dissected off the anterior surface of the rectum and lower sigmoid and excised.
- A purse string suture (2-0 vicryl) is placed high at the neck of the sac and tied. The excess peritoneum is resected off (Figs 15.17.3 and 15.17.4).
- The cervix is pulled upwards. Two interrupted sutures are now placed around the uterosacral ligaments. These sutures also pass through the posterior aspect of the

cervix. These sutures are tied. Rest of the steps are same as that of perineorrhaphy.

*Vaginal repair of posthysterectomy enterocele* — The initial steps are the same as described in repair of enterocele (Fig. 15.17). When the uterus is absent as in posthysterectomy vault prolapse, a purse string suture is passed high at the neck of the enterocele sac and left untied (Fig. 15.17.3). The left-sided uterosacral ligament is picked up with the fingers of the left hand. Suture is passed through



**Fig. 15.17:** Steps of enterocele repair operation with cervix still present —

1. Dissection to expose the enterocele. 2. To open the sac and reduce the contents if any. 3. A purse string suture is placed at the neck of the sac and tied. 4. The excess peritoneum is resected

this ligament (ureter to be excluded). Fingers are mobilized to pick up the right uterosacral ligament and a bite is taken through this ligament also. This suture is tied. **Depending upon the size of the enterocele one or more such (internal McCall) suture may be placed (Fig. 15.16.6).** The purse string suture is now tied and the excess peritoneum is cut away (Fig. 15.17(4)).

Use of supportive tissue (mesh) is currently advised in cases with complex prolapse.

- The rest of the steps are same as that of peri-neorrhaphy (Fig. 15.16).

**Abdominal repair of enterocele** is done by obliterating the pouch of Douglas to prevent herniation of bowel. This is known as **Moschowitz procedure**. Generally, three to four concentric sutures are placed incorporating the uterosacral ligaments and peritoneum over the rectosigmoid.

## PELVIC FLOOR REPAIR (PFR)

Usually, the prolapse of the anterior vaginal wall is associated with any form of posterior wall prolapse and relaxed perineum. As such, the corrective operation is known as pelvic floor repair. **This includes anterior colporrhaphy and colpoperineorrhaphy.** It should be emphasized that the pelvic floor repair is not the operation for uterine descent. But as the uterine descent is most frequently associated with prolapse of the vaginal wall, pelvic floor repair has to be done along with operation for uterine descent.

## FOTHERGILL'S OR MANCHESTER OPERATION

The operation is designed to correct uterine descent associated with cystocele and rectocele where **preservation of the uterus** is desirable.

The indications are:

- Preservation of reproductive function.
- When the symptoms are due to vaginal prolapse associated with elongation of the (supravaginal) cervix.

TABLE 15.4

### COMPOSITE STEPS OF FOTHERGILL'S OPERATION

- ♦ Preliminary D + C
- ♦ Amputation of cervix
- ♦ Plication of Mackenrodt's ligaments in front of cervix
- ♦ Anterior colporrhaphy
- ♦ Colpoperineorrhaphy



The principal steps of the operation are (Table 15.4):

- Preliminary dilatation and curettage**— Uterine sound gives the idea about elongation of cervix. **Dilatation** of the cervical canal is done to facilitate the passage of the sutures passing through the cervical canal during covering of the amputated cervix by vaginal flaps. It also ensures adequate uterine drainage and prevents cervical stenosis during healing of the external os. **Curettage** is done to remove the unhealthy endometrium.
- Amputation of the cervix**— Where future reproduction is required, low amputation is to be done.
- Plication of the Mackenrodt's ligaments** in front of the cervix. This facilitates their shortening and raising the cervix so as to place it in its normal position.
- Anterior colporrhaphy.**
- Colpoperineorrhaphy.**

If the family is completed, vaginal sterilization is to be done.

## STEPS OF OPERATION

**Preliminaries:** The preliminaries are the same as those followed in anterior colporrhaphy.

### Actual steps

- Preliminary D+C.
- The next step is like that of anterior colporrhaphy up to the pushing up the bladder.
- The posterior lip of the cervix is to be held with vulsellum and the cervix is drawn upwards.

- A pair of Allis forceps is placed in the midpoint of the posterior cervicovaginal junction.
- The anterior transverse incision is now extended posteriorly across the posterior cervicovaginal junction. The lateral and posterior vaginal wall is dissected off from the cervix by scissors and finger dissection.
- The Mackenrodt's ligament with descending cervical artery of either side is clamped at a higher level of amputation, cut and replaced by ligature (chromic catgut No. '1').
- The presence of enterocele should be searched for and if detected, to be repaired (Fig. 15.17).
- The cervix is now amputated at the calculated level.
- Anterior lip of the amputated cervix is now held with single-toothed vulsellum.
- The posterior lip of the amputated cervix is covered by the vaginal flap using a **Sturmdorff suture** (vide Figs. 15.18A and B) or by Bonney's method.

In **Bonney's method**, a catgut stitch is fixed at the apex of the posterior vaginal flap. The ends of the ligature are passed through the cervical canal and are taken out laterally on either side of new posterior fornix. The ends of the ligature are tied in the midline.

- The cut ends of the Mackenrodt's ligament are sutured to the anterior surface of the cervix (Fig. 15.18C). Alternatively, the ligaments are fixed using **Fothergill's stitch** (Fig. 15.18D). Fothergill's stitch is used to make the uterus anteverted. The stitch passes through the following tissues in sequence. Vaginal skin at the level of the Fothergill's lateral point → Mackenrodt's ligament → through the cervical tissue from outside inwards → cervical tissue from inside outwards → Mackenrodt's ligament of the other side → vaginal skin (Fothergill's lateral point) of the other side.
- ◆ Pubocervical fascia is approximated as in anterior colporrhaphy.
- ◆ Redundant portion of the vaginal mucosa is excised.
- ◆ The cut margins of the vagina are apposed by interrupted sutures.
- ◆ Posterior colpoperineorrhaphy is performed.
- ◆ Toileting the vagina is done.
- ◆ Vaginal pack is given.
- ◆ Self-retaining catheter is introduced.

**Complications:** See Table 15.5. (p. 223)

### VAGINAL HYSTERECTOMY WITH PELVIC FLOOR REPAIR

The operation is often designated as Ward Mayo's operation named after Mayo (1915) and Ward (1919) both from United States.

Removal of the uterus per vaginum (vaginal hysterectomy) is mostly done in cases of uterine prolapse. It should be emphasized that hysterectomy is not the surgery for the prolapse. It is the associated repair of the pelvic floor (PFR), which is the corrective surgery for prolapse.

#### Indications

- Uterovaginal prolapse in postmenopausal women.
- Genital prolapse in perimenopausal age group along with diseased uterus like DUB, unhealthy cervix or small submucous fibroid requiring hysterectomy.
- As an alternative to Fothergill's operation where family is completed.
- As an alternative to abdominal hysterectomy in undescended uterus either as a routine or in selected cases where abdominal approach is unsafe. PFR is not done in such cases.
- As an alternative to laparoscopic assisted vaginal hysterectomy (LAVH) in selected cases of undescended uterus. Compared to LAVH, vaginal hysterectomy is less expensive and the perioperative morbidity is no different (see p. 617).

#### Principles of the operation in prolapse

- Removal of the uterus through vaginal route.
- Correction of enterocele, if any.
- Approximation of the pedicles in the midline to have a good buttress.
- Fixation of the uterosacral ligaments to the vault to prevent vault prolapse.
- Bladder support is reconstituted utilizing the broad ligaments and round ligaments as buttress.
- Repair of cystocele.
- Reconstruction of the perineum.

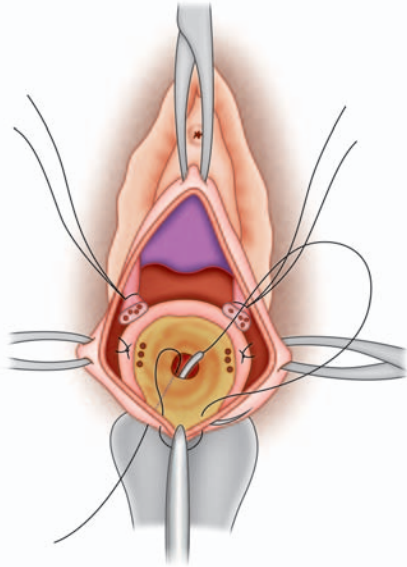
#### Steps of operation for vaginal hysterectomy (Fig. 15.19) (Indication—Genital prolapse)

##### Preliminaries

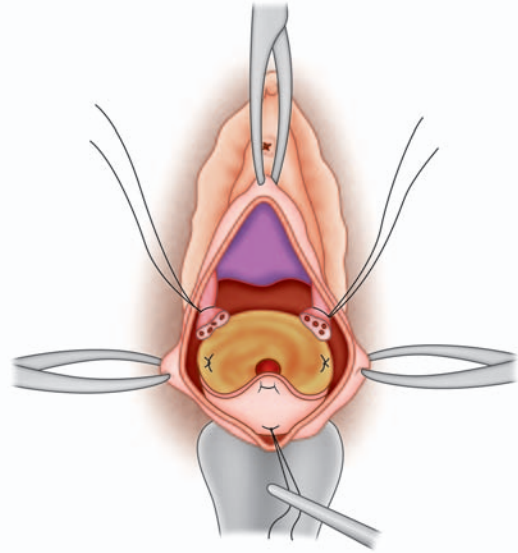
The preliminaries are the same as in anterior colporrhaphy.

##### Actual steps

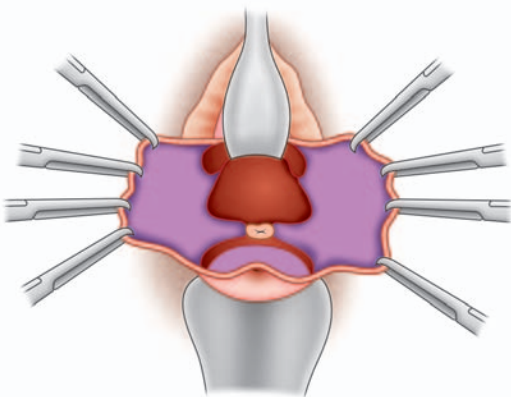
- To proceed as like that of anterior colporrhaphy up to pushing up the bladder [Fig. 15.19(1)].



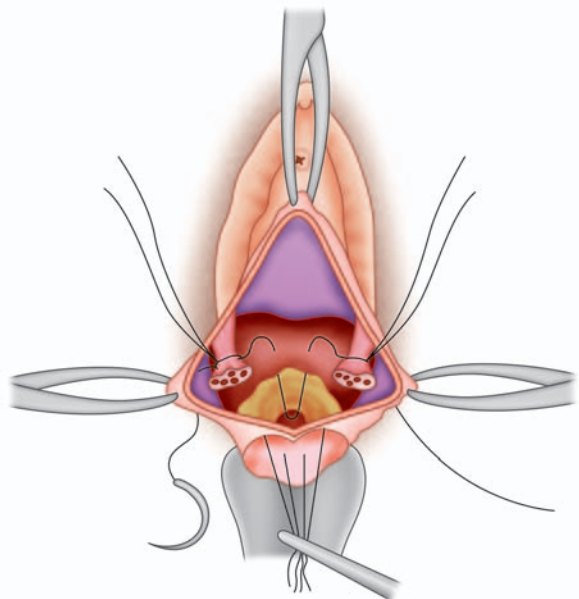
**Fig. 15.18A:** After amputation of the cervix, the raw posterior lip of the cervix is covered by the posterior vaginal mucosa using Sturmdorff suture;



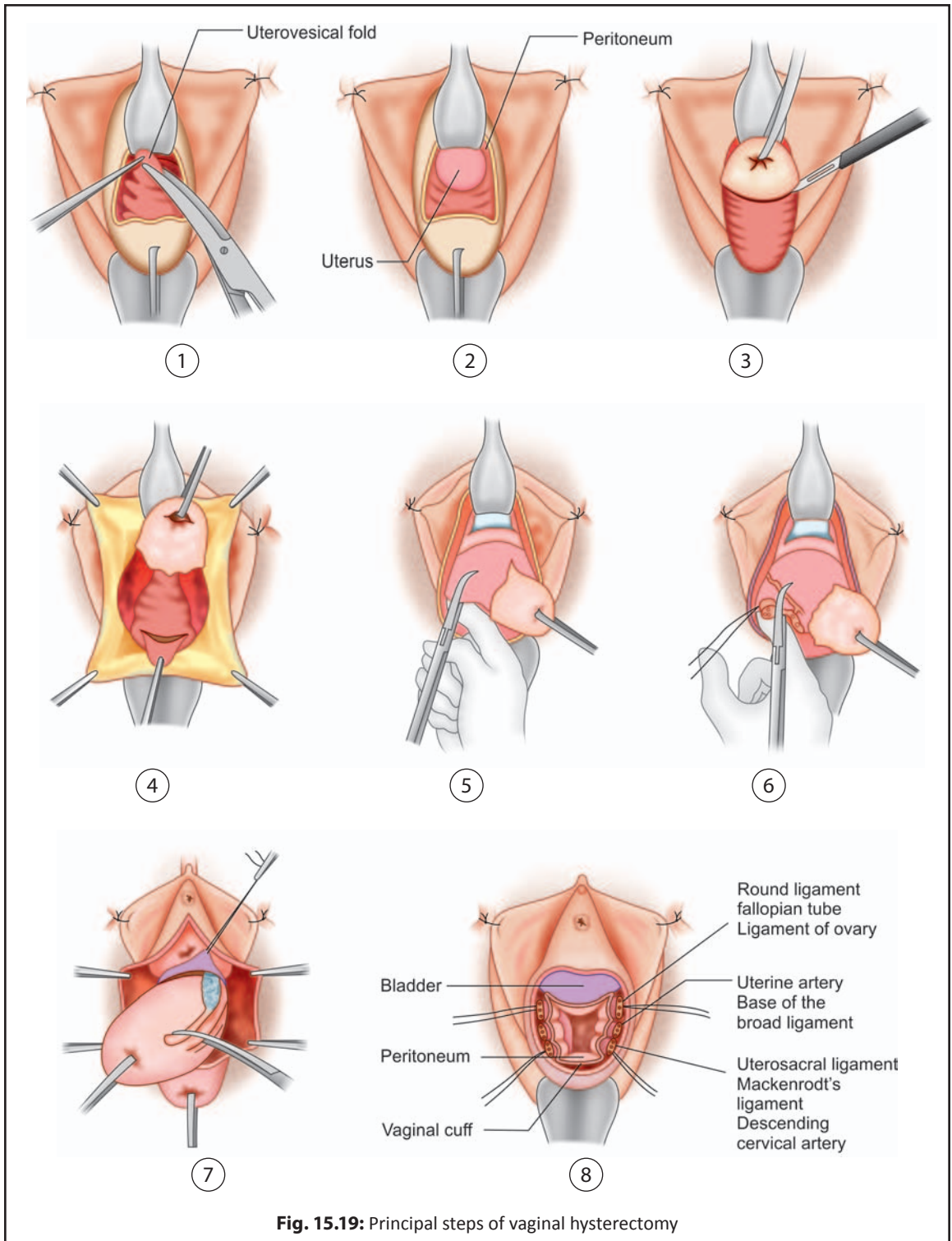
**Fig. 15.18B:** The knot is tied in the new posterior fornix



**Fig. 15.18C:** Approximation of the cut ends of the Mackenrodt's ligament and fixing them in front of the cervix



**Fig. 15.18D:** Approximation of the cut ends of the Mackenrodt's ligaments in front of the cervix using Fothergill's stitch



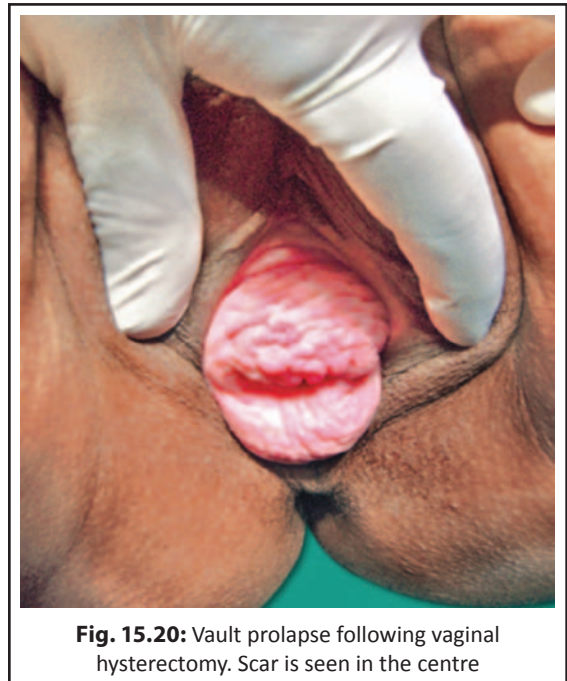**Fig. 15.19:** Principal steps of vaginal hysterectomy

- The uterovesical peritoneum is cut open. Landon's retractor is introduced and to be held by an assistant [Fig. 15.19(2)].
- The posterior vaginal wall along the cervicovaginal junction is cut as in Fothergill's operation. The vaginal wall is dissected down till the pouch of Douglas is reached. The peritoneum is cut open [Figs 15.19(3) and (4)].
- **First clamp is placed which includes** uterosacral ligament, Mackenrodt's ligament and descending cervical artery. The tissues are cut as close to the cervix and replaced by Vicryl No. 1. Similar procedures are followed on the other side [Fig. 15.19(5)].
- **Second clamp includes** uterine artery and base of the broad ligament. The structures are cut as close to the uterus and replaced by ligature (Vicryl No. 1). Same procedures are followed on the other side [Fig. 15.19(6)].
- The fundus is now brought out through the anterior pouch by a pair of Allis tissue forceps.
- **The third clamp includes** — round ligament, fallopian tube, mesosalpinx and ligament of the ovary. The structures are cut and replaced by transfixing suture (Vicryl No. '1'). Same procedures are carried out on the other side. The uterus is removed [Fig. 15.19(7)].
- Correction of the enterocele is to be done at this stage.
- Peritoneum is closed by a purse string suture [Fig. 15.19(8)].
- The sutures of the uppermost pedicles on either side are tied. The excess sutures of the uterine artery pedicle on each side are cut. The sutures of the pedicle containing the uterosacral and Mackenrodt ligaments are passed through the vault crosswise and are to be held temporarily.
- As in anterior colporrhaphy, the pubocervical fascia is approximated and fixed to the uppermost tied broad ligament pedicles to close the hiatus.
- Redundant portions of the vaginal flaps are excised and the margins approximated by interrupted sutures (Vicryl No. 'O').
- Crosswise passed sutures of the lowermost pedicles are now tied, thus fixing the ligaments with the vaginal cuff. Cardinal and uterosacral ligaments to the vaginal cuff is useful to prevent vault prolapse.
- Perineorrhaphy is done.
- Vaginal packing is optional.
- Self-retaining catheter is introduced.

### VAULT PROLAPSE (FIG. 15.20)

Posthysterectomy (vaginal or abdominal) vault prolapse is usually accompanied by an enterocele (70%). However, cystocele and or rectocele may be present. The vault prolapse in such cases may be effectively repaired transvaginally maintaining the same principle of repair of enterocele along with anterior colporrhaphy and colpoperineorrhaphy (see p. 211, 213).

Sometimes, it may require suspension of the vault with the anterior sacral ligament in front of 3rd sacral vertebra (sacral colpopexy) transabdominally using nonabsorbable sutures such as Teflon or Mersilene mesh.



**Fig. 15.20:** Vault prolapse following vaginal hysterectomy. Scar is seen in the centre

### Management of vault prolapse

**Conservative:** *Pessary treatment*—generally not recommended (see p. 210).

### Surgical:

#### Transvaginal approach

- Repair of enterocele along with pelvic floor repair (see p. 213).
- Le Fort operation.

- Colpocleisis (cases following hysterectomy).
- Sacrospinous colpopexy.

### Abdominal approach

- Vault suspension (sacral colpopexy).

**Le Fort operation:** The procedure is almost obsolete. It may be done in old age with procidentia when the patient is unfit for longer duration of surgery as vaginal hysterectomy with PFR. There should not be any uterine or pelvic pathology. Cervical cytology (pap smear) should be normal. The operation can be done under local anesthesia.

### The principle steps of the operation are:

- ◆ Denudation of rectangular vaginal flap from the anterior and posterior vaginal walls.
- ◆ Apposition of the denuded anterior and posterior vaginal walls by chromic catgut. Two small channels are thus left in the vagina one on either side for drainage.

The complications include — pyometra and urinary stress incontinence.

### Colpocleisis (after hysterectomy)

Denudation of vaginal mucosa is done all round. Successive purse string absorbable sutures are placed from above downwards to appose the vaginal walls. It is a simple, safe and effective operation for a woman who is no longer interested in coital function.

**Sacrospinous colpopexy:** The sacrospinous ligament is attached medially to the sacrum and coccyx and laterally to the ischial spine. It is within the body of coccygeus muscle. Vaginal vault is fixed to the coccygeus sacrospinous ligament complex (CSSL) of the right side. This is done under direct vision following dissection of the pararectal space. A special needle (Miya hook) is used. Overall results are good.

**Complications:** Injury to the rectum, pelvic vessels (internal pudendal, inferior gluteal), stress urinary incontinence, gluteal pain (pudendal or sciatic nerve injury). Risk of recurrence about 3%.

### Abdominal approach

**Vault suspension (Sacral colpopexy):** Principle of the operation is to suspend the vaginal vault to be anterior longitudinal ligament in front of the 3rd sacral vertebra. Non-absorbable suture material (Mersilene or Gore-Tex mesh) is used.

### Actual steps

- ◆ Abdomen is opened by vertical or transverse incision.
- ◆ A vertical incision is made on the posterior peritoneum over the sacral hollow while the rectosigmoid is pulled up laterally.
- ◆ Lateral angles of the vagina are identified and grasped with Allis tissue forceps.
- ◆ Two strips or Mersilene or Gore-Tex mesh (1.5 cm wide) are fixed to the vaginal angles and are pulled up in the midline. The other ends are fixed to the anterior longitudinal ligament in front of 3rd sacral vertebra with proper tension.
- ◆ Posterior peritoneum is sewn over the strips to make them retroperitoneal.

**Complications:** Stress urinary incontinence is an important one.

**Laparoscopic sacrocolpopexy** is found to be effective with similar result to open sacrocolpopexy.

## CERVICOPEXY OR SLING OPERATION (PURANDARE'S OPERATION)

The operation is indicated in **congenital** or **nulliparous prolapse** without cystocele where the cervix is pulled up mechanically through abdominal route. Strips of rectus sheath of either side passed extra-peritoneally are stitched to the anterior surface of the cervix by silk.

### Principle steps of the operation

- ◆ A transverse abdominal incision is made through the skin and fat.
- ◆ Two facial strips (rectus sheath) of 1.5 cm wide are dissected off, keeping its lateral attachment at the lateral border of the rectus muscle intact.
- ◆ The peritoneal cavity is opened in the midline. Bladder peritoneum is dissected off and the uterine isthmus is exposed mobilizing the bladder.
- ◆ The medial ends of the facial strips are now brought down between the leaves of the broad ligament to this site of uterine isthmus. (This procedure is technically similar as described in Gilliam operation p. 603).
- ◆ The free edges of the facial strips are now fixed at the uterine isthmus with a sturdy bite using silk. This is done after adjusting the correct position of the uterus.

Bladder peritoneum is repaired and abdomen is closed in layers. This operation may be combined with **Moschowitz procedure**. Instead of fascial strips, currently non-absorbable (Marlex or Gore-Tex) tape is used for this purpose.

To know much details and variations of all the operations, the readers are requested to consult books of operative gynecology.

## MANAGEMENT OF POP USING MESH

Synthetic and biological mesh have been used. They are found to work better compared to traditional method of repair. Some synthetic (polygalactin) and all biological materials (fascia lata, dermis, rectus sheath) are absorbable. Non-absorbable mesh are synthetic (polypropylene, polytetrafluoroethylene). Graft augments fibroblast proliferation and collagen tissue formation as they have pores. Prolene mesh (synthetic, macroporous, monofilament) is commonly used. Absorbable mesh or grafts are less likely to cause complications but failure rates are high. In contrast, nonabsorbable mesh has low failure rate but higher rate of complications.

**Suitable cases** for mesh surgery are: Symptomatic anterior/posterior vaginal wall prolapse, recurrent prolapse, prolapse due to congenital connective tissue disorder. **Complications are:** Mesh erosion, dyspareunia, vaginal pain, chronic sepsis, discharge, urinary incontinence and fistula formation.

**Contraindications:** Atrophic tissues, active pelvic infection, uncontrolled diabetes, obesity, smoking and history of pelvic radiation.

## COMPLICATIONS OF VAGINAL REPAIR OPERATIONS

### Complications of PFR

#### Operative

- ◆ **Hemorrhage**—The hemorrhage may at times be brisk. The hypovolaemic state can be tackled by infusion and blood transfusion.
- ◆ **Trauma**—The bladder in anterior colporrhaphy or rectum in perineorrhaphy may be injured. The injury should be effectively repaired else, either VVF or RVF may develop later on.

#### Postoperative: Urinary

- ◆ Retention of urine is a common complication. This is due to:
  - (i) Spasm, edema, and tenderness of pubococcygeus muscle.
  - (ii) Edema of the urethral wall.
  - (iii) Reflex from the wounds.
- ◆ Infection leading to cystitis.

#### Hemorrhage

**Primary hemorrhage** occurs within 24 hours. **It is due to** imperfect hemostasis at operation or due to slipping of the ligature.

Along with the resuscitative procedures, the patient is to be brought to the operation theater. Under anesthesia, the suture sites in the vagina, both anterior and posterior are explored and hemostatic sutures are given. The vagina should be packed tightly with dry roller gauze which should be removed after 24 hours without anesthesia.

**Secondary hemorrhage** occurs usually between 5–10th day but may occur even in the 3rd week. **It is due to sepsis of the wound.** If the hemorrhage is brisk, along with resuscitative procedures, the patient is to be brought to the operation theater and under general anesthesia, the vagina is explored. The clots are removed to find any bleeding point. **If only generalized oozing is found**, tight intravaginal pack using dry roller gauze is enough. **If bleeding point is visible**, hemostatic sutures should be given followed by vaginal packing. The plug should be removed after 24 hours. Antibiotics are to be started again.

**Sepsis:** Infection occurs on the vaginal or perineal wounds. Rarely, disruption of the perineal wound occurs.

- Late:**
- ◆ Dyspareunia
  - ◆ Recurrence of prolapse
  - ◆ VVF following bladder injury (p. 417)
  - ◆ RVF following rectal injury (p. 427)

## COMPLICATIONS OF VAGINAL HYSTERECTOMY WITH PFR

All the complications mentioned in PFR operation may occur, at times with increased intensity. Additional complications include:



**Immediate**

- Vault cellulitis
- Pelvic abscess
- Thrombophlebitis (see p. 598)
- Pulmonary embolism (see p. 598).

**Late:** • Vault prolapse (see p. 220)

TABLE 15.5	COMPLICATIONS OF FOTHERGILL'S OPERATION
<i>During operation</i>	<ul style="list-style-type: none"> <li>• Hemorrhage</li> <li>• Injury to the bladder and rectum</li> </ul>
<i>Postoperative</i>	<ul style="list-style-type: none"> <li>• Retention of urine or cystitis</li> <li>• Hemorrhage—primary or secondary</li> <li>• Infection</li> </ul>
<i>Late</i>	<ul style="list-style-type: none"> <li>• Dyspareunia</li> <li>• Cervical stenosis—hematometra</li> <li>• Infertility</li> <li>• Cervical incompetency</li> <li>• Cervical dystocia in labor</li> <li>• Recurrence of prolapse</li> </ul>

**CHRONIC INVERSION**

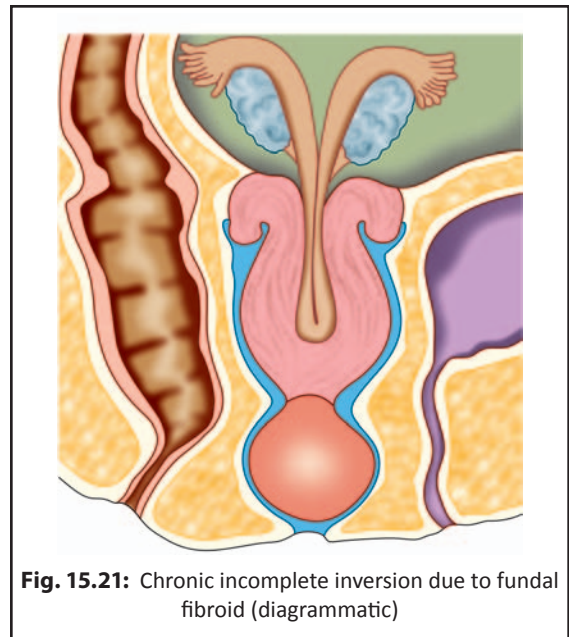
**Definition:** Inversion is a condition where the uterus becomes turned inside out; the fundus prolapsing through the cervix.

**Causes**

- ◆ Incomplete obstetric inversion unnoticed or left uncared following failure to reduce for a variable period of 4 weeks or more.
- ◆ Submucous myomatous polyp arising from the fundus → traction effect (Fig. 15.21).
- ◆ Sarcomatous changes of fundal fibroma → infiltration of malignancy into the myometrium → softening of the wall.
- ◆ Senile inversion following high amputation of the cervix. It is probably due to cervical atony and incompetence.

**Types:** Two types are described in chronic inversion.

- **Incomplete** — The fundus protrudes through the cervix and lying inside the vagina.
- **Complete** — Whole of the uterus including the cervix are inverted. The vagina may also be involved in the process.



**Fig. 15.21:** Chronic incomplete inversion due to fundal fibroid (diagrammatic)

**Symptoms**

- Sensation of something coming down per vaginam.
- Irregular vaginal bleeding.
- Offensive vaginal discharge.

**Signs:** Inspection (Fig. 15.22)

The protruding mass has got the following features :

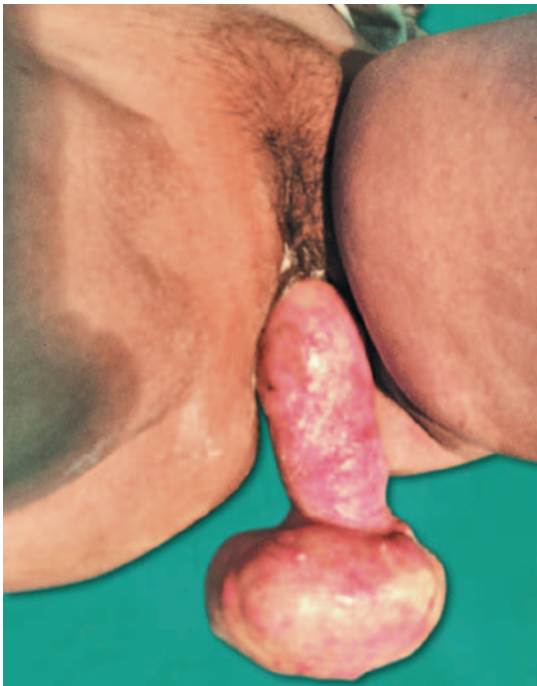- Globular,
- No opening in the leading part,
- Shaggy look,
- Tumor may be present at the bottom.

**Per vaginam:** (a) The cervical rim is felt high up in incomplete variety but not felt in complete one. (b) Cup-shaped depression at the fundus is felt or the uterus is not felt in position.

**Rectal examination:** Rectoabdominal examination is more informative to note the fundal depression or displacement of the uterus.

**Sound test:** Demonstration of shortness or absence of uterine cavity using an uterine sound is reasonably confirmative.

**EUA:** At times, it is needed to confirm the diagnosis.



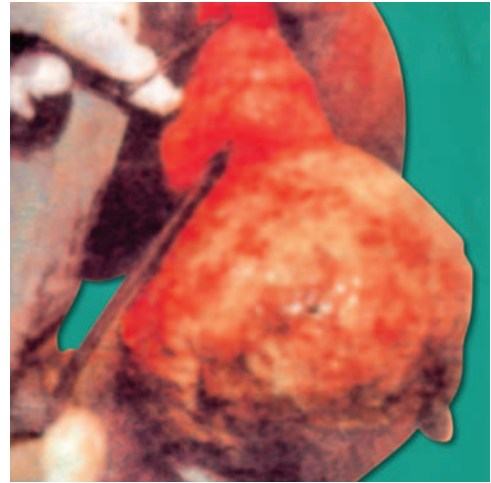
**Fig. 15.22:** Complete chronic inversion of uterus with a fundal fibroid [By courtesy : Dept. of Obst & Gynae., Govt. Maternity Hospital, Osmania Medical College, Hyderabad]

The diagnostic difficulty is much when inversion is secondary to a fibroid polyp or sarcoma and the inversion is incomplete, filling the vagina. A portion is to be removed from the tumor mass for histological examination to differentiate between a simple fibroid or sarcoma.

### Differential Diagnosis

- i. Fibroid polyp,
- ii. Uterine prolapse,
- iii. Prolapsed hypertrophied ulcerated cervix,
- iv. Fungating cervical malignancy.

**In fibroid polyp** — The uterus is in normal position and the uterine sound can be passed into the uterine cavity. In difficulty, examination under anesthesia may be required (Fig. 15.23).



**Fig. 15.23:** Cervical fibroid polyp confusing diagnosis with chronic inversion. Note the uterine sound into the cervical canal

### Treatment

**General measures:** The patients are usually anemic. Prior improvement should be made if necessary, by blood transfusion. Local sepsis is to be controlled.

**Definitive treatment:** There is no place of manipulative replacement by taxis. Rectification should be done by surgery. Preservation or removal of the uterus is determined by such factors like age, parity, associated complicating factors. If hysterectomy is contemplated, it should be done following rectification.

**Conservative surgery (see p. 602):** Rectification may be done abdominally (Haultain's operation — after cutting the posterior ring of the cervix) or vaginally (Spinelli's operation — after cutting the anterior ring of the cervix). Following Haultain's operation, some form of suspension operation has to be done to prevent posterior adhesions.

Contemplating polypectomy in suspected inversion, prior confirmation by 'sound test' is mandatory. **It is a sound policy to remove the tumor by shelling from its capsule rather than dividing the pedicle in such cases.**

## KEY POINTS

- ▶ Retroversion of the uterus is quite common and is present in about 15–20 percent of normal women. Emptying the bladder prior to its diagnosis is mandatory. Retroversion *per se* has got no adverse effect on fertility or early pregnancy.
- ▶ Pelvic Organ Prolapse is the prolapse of the pelvic organs into the vaginal canal. The important risk factors for prolapse is history of vaginal birth and age of the woman.
- ▶ Important support structures of uterus are the cardinal, uterosacral, pubocervical ligaments, endopelvic fascia, levator ani muscle (pubococcygeus, iliococcygeus, levator plate) and the perineal body.
- ▶ Prolapse is due to a combination of injury to the neuromuscular as well as supporting structures.
- ▶ Etiology of genital prolapse includes the anatomical factors, as well as the different clinical factors (p. 204).
- ▶ The hammock like arrangements of levator ani muscle, the condensed endopelvic fascia, especially the Mackenrodt's ligaments are the cardinal support of the uterus. The levator plate and the perineal body maintains the normal vaginal axis (p. 201-204).
- ▶ Cystocele and urethrocele are more common with a gynecoid pelvis than with android or anthropoid types. In cases of congenital prolapse, occult spina bifida should be looked for. Secondary vault prolapse is more following vaginal hysterectomy than abdominal one. Decubitus ulcer is a trophic ulcer. Malignancy is a rare association. Predominant urinary complaints in genital prolapse are difficulty in passing urine, incomplete evacuation, frequency, stress incontinence and rarely retention. To diagnose a third degree uterine prolapse, digital palpation is mandatory. Cystocele may be confused with Gartner's cyst. Uterine prolapse may be confused with congenital elongation of the cervix, chronic uterine inversion and fibroid polyp.
- ▶ The examination for prolapse should be done with the patient in dorsal position then standing and using Valsalva's maneuver for correct assessment.
- ▶ **Degree of urine prolapse:** *1st degree* : Uterus descends from its anatomical position but external uterine os remains in the vagina; *2nd degree* : External os protrudes outside the vaging but uterine body remains inside; *3rd degree* : Uterine body descends outside the vaginal introitus (procidencia). (p. 205).
- ▶ **Newer classifications** of pelvic organ prolapse Quantification (POP-Q) have been introduced for more objective quantification It is site specific and anatomical. Prolapse must be documented in terms of anterior or posterior vaginal wall and the uterine descent (Table 15.2). In this regard fixed anatomic reference points are used (Fig. 15.10, Fig. 15.10, Table 15.6).
- ▶ Pessary treatment may be indicated in early pregnancy, puerperium, patient unfit for surgery or while the patients are waiting for operation.
- ▶ The surgical procedures for the management of prolapse are different. The type of surgery for an individual woman depends on her age, parity, reproductive and sexual function and also the type and degree of prolapse (Table 15.3 p. 211).
- ▶ The component parts of Fothergill's operation are D+C, amputation of the cervix, plication of Mackenrodt's ligaments in front of the cervix, anterior colporrhaphy and colpoperineorrhaphy (p. 216).
- ▶ Posthysterectomy vault prolapse (0.1–10%) is usually accompanied by an enterocele (70%). Vault prolapse can be repaired either by vaginal or by abdominal route. Colpocleisis is an easy, safe and effective method for a woman who is no longer interested in coital function.
- ▶ When an enterocele is present, the sac should be dissected high up and ligated at its neck to prevent recurrence. McCall culdoplasty (p. 216) is done. External McCall suture is placed at a higher level than the internal McCall

Contd...

Contd...

(p. 216). Vicryl (1-0) suture is passed through the left posterior vaginal wall, peritoneum, pararectal fascia (uterosacral ligament) and it is then carried over in front of the sigmoid colon to include the similar points on the right hand side. One or more such sutures may be placed. It is tied after the closure of the peritoneal purse string suture (Fig. 15.16.(6)).

- Cervicopexy (sling operation) is the method of repair for a patient with congenital or nulliparous prolapse (p. 221).
- Use of mesh in the management of prolapse is found to work better. Synthetic as well as biological materials are used (p. 222). Case should be properly selected to minimize complications (p. 222).
- After pelvic floor repair, bladder drainage (transurethral catheter) for 3–5 days is generally necessary before normal voiding starts.
- The gynecologic inversion is usually incomplete. Rectal examination is more informative in the diagnosis of chronic inversion. Chronic inversion may be confused with fibroid polyp, uterine prolapse, fungating cervical malignancy or prolapsed hypertrophied ulcerated cervix. There is no place manipulative replacement of chronic inversion. Surgical rectification is done either abdominally (Haultain's) or vaginally (Spinelli's) (see p. 602, 603).

**TABLE 15.6: SITE SPECIFIC MEASUREMENTS  
IN POP-Q SYSTEM**

Site	Description	Range
Aa	Anterior vaginal wall, midline 3 cm proximal to external urinary meatus	-3 cm to + 3 cm
Bb	Anterior vaginal wall, most dependent portion between Aa and anterior fornix	-3 cm to + tvl
C	Cervix or vaginal cuff	1 tvl
D	posterior fornix or vaginal apex	+ tvl
Ap	Posterior vaginal wall, midline 3 cm proximal to hymen	-3 cm to + 3 cm
Bp	Posterior vaginal wall, most dependent portion, between Ap and posterior fornix	-3 cm to + tvl
gh	External urinary metus to posterior	2cm
tvl	Point D to the hymenal ring	10 cm
pb	Posterior hymen to anal opening	3 cm

**GRID USED TO RECORD MEASUREMENTS  
IN POP-Q SYSTEM**

Aa	Ba	C
Anterior wall (- 3 cm to + 3 cm)	Anterior wall (- 3 cm to + 8 cm)	Cervix or vaginal cuff (- 8 cm to +8 cm)
gh Genital hiatus (2 cm)	pb Perineal body (3 cm)	tvl Total vaginal length (10 cm)
Ap Posterior wall (-3 cm to +3)	Bp Posterior wall (-3 cm to +8 cm)	D Posterior fornix (-10)

# Infertility

## DEFINITION

Infertility is defined as a failure to conceive within one or more years of regular unprotected coitus.



**Primary infertility** denotes those patients who have never conceived. **Secondary infertility** indicates previous pregnancy but failure to conceive subsequently.

**Fecundability** is defined as the probability of achieving a pregnancy within one menstrual cycle. In a healthy young couple, it is 20 percent. **Fecundity** is the probability of achieving a livebirth within a single cycle.

## INCIDENCE

Eighty percent of the couples achieve conception if they so desire, within one year of having regular intercourse with adequate frequency (4–5 times a week). Another 10 percent will achieve the objective by the end of second year. As such, 10 percent remain infertile by the end of second year.

## Factors Essential for Conception

- ◆ **Healthy spermatozoa** should be deposited high in the vagina at or near the cervix (male factor).
- ◆ The spermatozoa should undergo changes (**capacitation, acrosome reaction**) and acquire motility (cervical factor).
- ◆ The **motile spermatozoa** should ascend through the cervix into the uterine cavity and the fallopian tubes.
- ◆ There should be **ovulation** (ovarian factor).
- ◆ The fallopian tubes should be patent and the oocyte should be picked up by the fimbriated end of the tube (**tubal factor**).
- ◆ The spermatozoa should **fertilize** the oocyte at the ampulla of the tube.

- ◆ The embryo should reach the **uterine cavity** after 3–4 days of fertilization.
- ◆ The **endometrium** should be receptive (by estrogen, progesterone, IGF-1, cytokines, integrins) for **implantation**, and the **corpus luteum** should function adequately.

## PHYSIOLOGICAL CONSIDERATION

Due to anovulation, infertility is the rule prior to puberty and after menopause. But it should be remembered that the girl may be pregnant even before menarche and pregnancy is possible within few months of menopause. Conception is not possible during pregnancy as the pituitary gonadal axis is suppressed by hCG and hence, no ovulation. During lactation, infertility is said to be relative. Despite the fact that the patient is amenorrheic during lactation, ovulation and conception can occur. However, in fully lactating women (breastfeeding 5–6 times a day and spending 60 minutes in 24 hours), pregnancy is unlikely up to 10 weeks postpartum.

## CAUSES OF INFERTILITY

Conception depends on the fertility potential of both the male and female partner. **The male is directly responsible in about 30–40 percent, the female in about 40–55 percent and both are responsible in about 10 percent cases.** The remaining 10 percent, is **unexplained**, in spite of thorough investigations with modern technical knowhow. It is also strange that 4 out of 10 patients of unexplained category become pregnant within 3 years without having any specific treatment.

It is also emphasized that the relative subfertility of one partner may sometimes be counterbalanced by the high fertility of the other.

### Faults in the male (Table 16.1)

- ✦ Defective spermatogenesis
- ✦ Obstruction of the efferent duct system
- ✦ Failure to deposit sperm high in the vagina
- ✦ Errors in the seminal fluid.

### DEFECTIVE SPERMATOGENESIS

FSH stimulates spermatogenesis from basal cells of the seminiferous tubules. Sertoli cells envelope the germ cells and support spermatogenesis. Sertoli cell function is controlled by FSH and testosterone. Scrotal temperature should be 1–2°F less than the body temperature. LH is required for the synthesis of testosterone from the Leydig cells. FSH also stimulates the Sertoli cells to produce androgen binding proteins (ABP) and inhibin B. ABP binds to testosterone and dihydrotestosterone to maintain the local high concentration of androgens. Spermatogenesis and sperm maturation need a high androgenic environment. Inhibin B inhibits FSH secretion. Spermatogenesis is controlled predominantly by the genes on Y chromosome. **Approximately 74 days are required to complete the process of spermatogenesis.** Additional 12–20 days are needed for spermatozoa to travel the epididymis.

### Causes of Male Infertility

The important causes of male infertility are:  
(1) Hypothalamic-pituitary disorders (1–2%).

(2) Primary gonadal disorders (30–40%). (3) Disorders of sperm transport (10–20%) and (4) Idiopathic (40–50%).

#### ◆ Congenital

- **Undescended testes:** The hormone secretion remains unaffected, but the spermatogenesis is depressed. Vas deferens is absent (bilateral) in about 1–2 percent of infertile males.
- **Kartagener syndrome** (autosomal disease)—there is loss of ciliary function and sperm motility.
- **Hypospadias** causes failure to deposit sperm high in vagina.

◆ **Thermal Factor:** The scrotal temperature is raised in conditions such as varicocele. Varicocele probably interferes with the cooling mechanism or increases catecholamine concentration. However, no definite association between varicoceles and infertility has been established.

◆ **Infection:** (a) Mumps orchitis after puberty may permanently damage spermatogenesis. (b) The quality of the sperm is adversely affected by chronic systemic illness like bronchiectasis. Bacterial or viral infection of the seminal vesicle or prostate depresses the sperm count. (c) *T. mycoplasma* or *Chlamydia trachomatis* infection is also implicated.

◆ **General Factors:** Chronic debilitating diseases, malnutrition or heavy smoking reduce

**TABLE 16.1 COMMON CAUSES OF MALE INFERTILITY**

Pre-testicular	Testicular	Post-testicular
<p><b>Endocrine</b></p> <ul style="list-style-type: none"> <li>• Gonadotropin deficiency</li> <li>• Obesity</li> <li>• Thyroid dysfunction</li> <li>• Hyperprolactinemia</li> </ul> <p><b>Psychosexual</b></p> <ul style="list-style-type: none"> <li>– Erectile dysfunction</li> <li>– Impotence</li> </ul> <p><b>Drugs</b></p> <ul style="list-style-type: none"> <li>– Antihypertensives</li> <li>– Antipsychotics</li> </ul> <p><b>Genetic</b></p> <ul style="list-style-type: none"> <li>– 47 XXY (p. 229)</li> <li>– Y chromosome deletions</li> <li>– Single gene mutations</li> </ul>	<ul style="list-style-type: none"> <li>• Immotile cilia (Kartagener) syndrome</li> <li>• Cryptorchidism</li> <li>• Infection (mumps orchitis)</li> <li>• Toxins: Drugs, smoking, radiation (p. 229)</li> <li>• Varicocele</li> <li>• Immunologic (p. 240)</li> <li>• Sertoli-cell-only syndrome (p. 229)</li> <li>• Primary testicular failure</li> <li>• Oligoastheno-teratozoospermia</li> </ul>	<p><b>Obstruction of efferent duct</b></p> <ul style="list-style-type: none"> <li>• Congenital <ul style="list-style-type: none"> <li>– Absence of Vas deferens (Cystic fibrosis)</li> <li>– Young's syndrome (p. 229)</li> </ul> </li> <li>• Acquired Infection: Tuberculosis, Gonorrhoea</li> <li>• <i>Surgical</i> <ul style="list-style-type: none"> <li>– Herniorrhaphy • Vasectomy</li> </ul> </li> </ul> <p><b>Others</b></p> <ul style="list-style-type: none"> <li>• Ejaculatory failure</li> <li>• Retrograde ejaculation</li> <li>• Hypospadias</li> <li>• Bladder neck surgery</li> </ul>

spermatogenesis. Alcohol inhibits spermatogenesis either by suppressing Leydig cell synthesis of testosterone or possibly by suppressing gonadotropin levels.

♦ **Endocrine:** Testicular failure due to gonadotropin deficiency (**Kallmann's syndrome**) is rare. FSH level is raised in idiopathic testicular failure with germ cell hypoplasia (**Sertoli-cell-only-syndrome**). Hyperprolactinemia is associated with impotence.

♦ **Genetic:** Common chromosomal abnormality in azoospermic male is Klinefelter's syndrome (47 XXY). Gene deletion have been detected in the long-arm of Y chromosome (Yq) for patients with severe oligospermia and azoospermia.

♦ **Iatrogenic:** Radiation, cytotoxic drugs, nitrofurantoin, cimetidine,  $\beta$  blockers, antihypertensive, anticonvulsant, and antidepressant drugs are likely to hinder spermatogenesis.

♦ **Immunological Factor:** Antibodies against spermatozoal surface antigens may be the cause of infertility. This results in clumping of the spermatozoa after ejaculation.

**Obstruction of the efferent ducts:** The efferent ducts may be obstructed by infection like tubercular, gonococcal or by surgical trauma (herniorrhaphy) following vasectomy. In **Young's syndrome**, there is epididymal obstruction and bronchiectasis.

### FAILURE TO DEPOSIT SPERM HIGH IN THE VAGINA (COITAL PROBLEMS)

- Erectile dysfunction
- Ejaculatory defect—premature, retrograde or absence of ejaculation
- Hypospadias.

**Sperm abnormality:** Loss of sperm motility (asthenozoospermia), abnormal sperm morphology (roundheaded sperm, teratozoospermia) are the important factors.

#### **Errors in the seminal fluid**

- Unusually high or low volume of ejaculate
- Low fructose content
- High prostaglandin content
- Undue viscosity.

## CAUSES OF FEMALE INFERTILITY

According to FIGO manual (1990) causes are: Tubal and peritoneal factors (25–35%), Ovulatory factor (30–40%) and Endometriosis (1–10%).

**Ovarian factors:** The ovulatory dysfunctions (dysovulatory) encompass:

- Anovulation or oligo-ovulation
- Decreased ovarian reserve (p. 528)
- Luteal phase defect (LPD)
- Luteinized unruptured follicle (LUF).

### ANOVLATION OR OLIGO-OVULATION

The ovarian activity is totally dependent on the gonadotropins and the normal secretion of gonadotropins depends on the pulsatile release of GnRH from hypothalamus. As such, **ovarian dysfunction is likely to be linked with disturbed hypothalamo-pituitary-ovarian axis either primary or secondary from thyroid or adrenal dysfunction.**

Thus, the disturbance may result not only in anovulation but may also produce oligomenorrhea or even amenorrhea. Anovulatory cycles usually represent a lesser degree of disturbance with these normal pathways than does amenorrhea. **Possible causes of anovulation** are given schematically.

As there is no ovulation, there is no corpus luteum formation. In the absence of progesterone, there is no secretory endometrium in the second half of the cycle. The other features of ovulation (later in the chapter) are absent.

### LUTEAL PHASE DEFECT (LPD)

In this condition, there is inadequate growth and function of the corpus luteum. There is inadequate progesterone secretion. The lifespan of corpus luteum is shortened to less than 10 days. As a result, there is inadequate secretory changes in the endometrium which hinder implantation. LPD is due to defective folliculogenesis which again may be due to varied reasons. Drug induced ovulation, decreased level of FSH and/or LH, elevated prolactin, subclinical hypothyroidism, older women, pelvic endometriosis, dysfunctional uterine bleeding are the important causes.

### LUTEINIZED UNRUPTURED FOLLICULAR SYNDROME (TRAPPED OVUM)

In this condition, the ovum is trapped inside the follicle, which gets luteinized. The cause is obscure but may be associated with **pelvic endometriosis or with hyperprolactinemia**.

**Tubal and peritoneal factors** are responsible for about 30–40 percent cases of female infertility.

The obstruction of the tubes may be due to—  
(a) **Pelvic infections causing:** (i) Peritubal adhesions (ii) Endosalpingeal damage. (b) Previous tubal surgery or sterilization. (c) Salpingitis isthmica nodosa (p. 172). (d) Tubal endometriosis (p. 174) and others. (e) Polyps or mucous debris within the tubal lumen, or tubal spasm.

**Peritoneal factors:** In addition to peritubal adhesions, even minimal endometriosis may produce infertility. Deep dyspareunia too often troubles the patient. The possible multifactorial mechanisms which operate in minimal endometriosis are depicted schematically at Table 16.2.

**Uterine factors:** The endometrium must be sufficiently receptive enough for effective nidation and growth of the fertilized ovum. **The possible factors that hinder**

**nidation are** uterine hypoplasia, inadequate secretory endometrium, fibroid uterus, endometritis (tubercular in particular), uterine synechiae or congenital malformation of uterus.

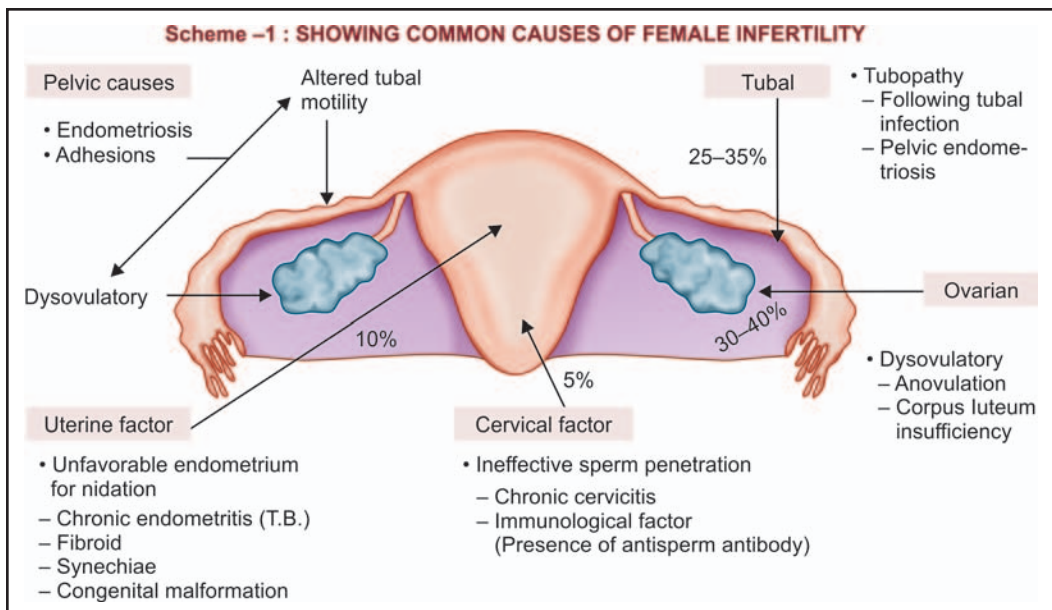
### Cervical factors

**Anatomic:** Anatomic defects preventing sperm ascent may be due to congenital elongation of the cervix, second degree uterine prolapse and acute retroverted uterus. These conditions prevent the external os to bathe in the seminal pool. Pinhole os may at times be implicated, or the cervical canal may be occluded by a polyp.

**Physiologic:** The fault lies in the composition of the cervical mucus, so much that the spermatozoa fail to penetrate the mucus. The mucus may be scanty following amputation, conization or deep cauterization of the cervix. The abnormal constituents include excessive, viscous or purulent discharge as in chronic cervicitis. Presence of antisperm or sperm immobilizing antibodies may be implicated as immunological factor of infertility.

### Vaginal factors

Atresia of vagina (partial or complete), transverse vaginal septum, septate vagina, or narrow introitus causing dyspareunia are included in the congenital group.





Vaginitis and purulent discharge may at times be implicated but pregnancy too often occurs in presence of vaginitis, specific, or nonspecific. However, dyspareunia may be the real problem in such cases.

### Combined factors

- ▶ These include the presence of factors both in the male and female partners causing infertility.
- ▶ General factors: Advanced age of the wife beyond 35 years is related but spermatogenesis continues throughout life although aging reduces the fertility in male also.
- ▶ Infrequent intercourse, lack of knowledge of coital technique and timing of coitus to utilize the fertile period are very much common even amongst the literate couples.
- ▶ Apeareunia and dyspareunia (see p. 568).
- ▶ Anxiety and apprehension.
- ▶ Use of lubricants during intercourse, which may be spermicidal.
- ▶ Immunological factors.

## INVESTIGATIONS OF INFERTILITY

### OBJECTIVES OF INVESTIGATION

- ◆ To detect the etiological factor(s).
- ◆ To rectify the abnormality in an attempt to improve the fertility.
- ◆ To give assurance with explanation to the couple if no abnormality is detected.

**When to investigate?** As per the definition, the infertile couple should be investigated after one year of regular unprotected intercourse with adequate frequency. The interval is however, shortened to 6 months after the age of 35 years of the woman and 40 years of man.

**What to investigate?** The basic investigations to be carried out are: (i) Semen analysis. (ii) Confirmation of ovulation and (iii) Confirmation of tubal patency.

It is important that both partners should come at the first visit. Detailed general and reproductive history should be taken in presence of both. However, the clinical examination of each partner is carried out separately. No one is to be blamed.

### CLINICAL APPROACH TO INVESTIGATION

- Male
- Female

#### MALE

### HISTORY

Age, duration of marriage, history of previous marriage, and proven fertility if any, are to be noted.

A general medical history should be taken with special reference to sexually transmitted diseases, mumps orchitis after puberty, diabetes, recurrent chest infection or bronchiectasis. Enquiry about relevant surgery such as herniorrhaphy, operation on testes, also about the sexual history, social habits, particularly heavy smoking and alcohol are of importance and to be made.



**TABLE 16.2** POSSIBLE MECHANISM OF INFERTILITY IN WOMEN WITH PELVIC ENDOMETRIOSIS

Ovarian dysfunction	Tubal dysfunction	Others
<ul style="list-style-type: none"> <li>• Endocrinopathies (see p. 309)               <ul style="list-style-type: none"> <li>– Defective folliculogenesis</li> <li>– Anovulation</li> <li>– Luteal phase defect (p. 237)</li> <li>– LUFS (p. 237)</li> <li>– Hyperprolactinemia (p. 464)</li> </ul> </li> <li>• Oocyte maturation defect</li> <li>• Luteolysis due to <math>\uparrow</math> PGF<sub>2<math>\alpha</math></sub></li> </ul>	<ul style="list-style-type: none"> <li>• Altered tubal motility</li> <li>• Pelvic adhesions, tubal obstruction</li> <li>• Distortion of normal tube and ovarian relationship</li> <li>• Impaired pick up of oocyte by the fimbria</li> </ul>	<ul style="list-style-type: none"> <li>• Dyspareunia (poor coital function, see p. 307, 568).</li> <li>• Abnormal peritoneal fluid (see p. 309).</li> <li>• Abnormal systemic immune response</li> <li>• Increased sperm phagocytosis by macrophages</li> <li>• Fertilization and implantation failure</li> <li>• Early miscarriage</li> </ul>

## EXAMINATION

A full physical examination is performed to determine the general state of health. Examination of the reproductive system includes—inspection and palpation of the genitalia. Attention should be paid to the size and consistency of the testicles. **Testicular volume** (measured by an orchidometer) should be at least 20 mL. Presence of varicocele should be elicited in the upright position.

## INVESTIGATIONS

- Routine investigations** include urine and blood examination including postprandial sugar.
- Semen analysis: This should be the first step in investigation** because, if some gross abnormalities are detected (example being absence of sperm), the couple should be counseled for the need of assisted reproductive technology.

**Collection:** The collection is best done by masturbation failing which by coitus interruptus. The semen is collected in a clean wide mouthed dry glass jar. The sample so collected should be sent to the laboratory as early as possible so that the examination can be performed within 2 hours. The coitus should be avoided for 2–3 days prior to the test (abstinence).

**Semen analysis (Table 16.3):** Normal reference value WHO (2010).

**TABLE 16.3 SEMEN ANALYSIS (WHO–2010)**

Semen analysis	Normal reference value and lower reference (within parenthesis) limit
Volume	2.0 mL or more (1.5 mL)
pH	7.2–7.8
Viscosity	< 3 (scale 0–4)
Sperm concentration	20 million/mL (15 million/mL)
Total sperm count	> 40 million/ejaculate (39 million/ejaculate)
Motility	> 50% progressive forward motility (Progressive motility = 32%)
Morphology	> 14% normal form (4%)
Viability	75% or more living (58%)
Leucocytes	Less than 1 million/mL
Round cells	< 5 million/mL
Sperm agglutination	< 10% spermatozoa with adherent particles

**In selected cases,** biochemical tests of creatine phosphokinase and reactive oxygen species are done as sperm function tests. Creatinine phosphokinase helps sperm transport while reactive oxygen species and the peroxides interfere with sperm function.

**Normal male fertility requires** a count of over 20 million spermatozoa per mL and a progressive motility of over 32 percent. Semen values normally vary widely. Two properly performed semen analysis at least 4 weeks apart should be done when one report is abnormal.

### Nomenclature

- **Aspermia:** Failure of emission of semen (no ejaculate).
- **Oligospermia/Oligozoospermia:** Sperm count is less than 20 million per mL.
- **Polyzoospermia:** Count is more than 350 million/mL.
- **Azoospermia:** No spermatozoan in the semen.
- **Asthenozoospermia:** Reduced sperm motility. Leucocytospermia: Increased white cells in semen.
- **Necrozoospermia:** Spermatozoa are dead or motionless.
- **Teratozoospermia:** > 70% spermatozoa with abnormal morphology.
- **Oligoasthenoteratozoospermia:** Disturbance of all 3 variables.

## IN-DEPTH EVALUATION

These are needed in cases of—(a) Azoospermia, (b) Oligospermia, (c) Low volume ejaculate, (d) Problems of sexual potency. Further diagnostic protocols has been appropriately designed (Scheme 2).

- ♦ **Serum FSH, LH, testosterone, prolactin, and TSH:** Testicular dysfunction causes rise in FSH and LH. Low level of FSH and LH suggest hypogonadotropic hypogonadism (see Scheme 2). Leydig cell dysfunction causes low testosterone and high LH level. Elevated prolactin due to pituitary adenoma may cause impotency.
- ♦ **Fructose content in the seminal fluid:** Its absence suggests congenital absence of seminal vesicle or portion of the ductal system or both.
- ♦ **Testicular biopsy:** is done to differentiate primary testicular failure from obstruction as a cause of

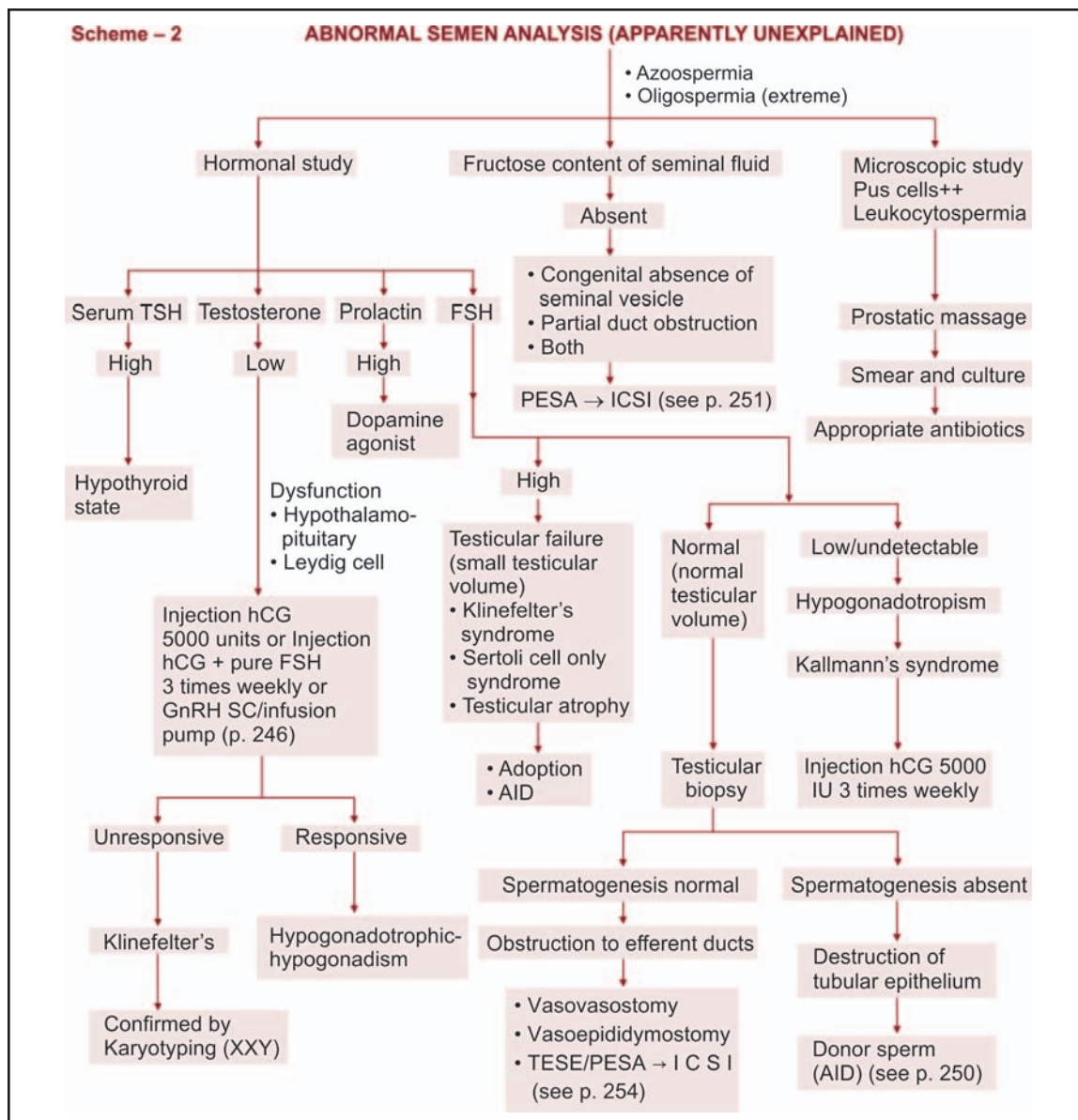
azoospermia or severe oligospermia. **The biopsy material is to be sent in Bouin's solution and not in formol saline.** Testicular tissues may be cryopreserved for future use in IVF/ICSI.

**Transrectal ultrasound (TRUS):** is done to visualize the seminal vesicles, prostate and ejaculatory ducts obstruction. Indications of TRUS are: (i) Azoospermia or severe oligospermia with a normal testicular volume, (ii) Abnormal digital rectal examination, (iii) Ejaculatory

duct abnormality (cysts, dilatation or calcification), (iv) Genital abnormality (hypospadias).

**Vasogram** is a radiographic study done to evaluate the ejaculatory duct obstruction. It is mostly replaced by TRUS.

♦ **Karyotype analysis:** This is to be done in cases with azoospermia or severe oligospermia and raised FSH. Klinefelter's syndrome (XXY) is the commonest. Micro deletions of the long arm of Y chromosome can also cause severe seminal abnormalities.



- ♦ **Immunological tests:** Two types of antibodies have been described—sperm agglutinating and sperm immobilizing; the latter is probably related to infertility. The antibodies are produced following infection (orchitis), trauma or vasectomy. These antibodies can be detected from the serum by the sperm immobilizing test. Presence of sperm antibodies in the cervical mucus is demonstrated by **postcoital test** (see p. 115, 239).
- ♦ **Presence of plenty of pus cells** requires prostatic massage. The collected fluid is to be examined by staining and culture to detect the organisms and appropriate antibiotic sensitivity.

## FEMALE

**HISTORY:** Age, duration of marriage, history of previous marriage with proven fertility if any, are to be noted.

**A general medical history** should be taken with special reference to tuberculosis, sexually transmitted disease, features suggestive of pelvic inflammation or diabetes.

**The surgical history** should be directed especially towards abdominal or pelvic surgery. This may be related to peritubal adhesions.

**Menstrual history** should be taken in details. Wide spectrum of abnormalities ranging from hypomenorrhea—oligomenorrhea to amenorrhea are associated with disturbed hypothalamopituitary ovarian axis which may be either primary or secondary to adrenal or thyroid dysfunction.

**Previous obstetric history**—It is including number of pregnancies, the interval between them and pregnancy related complications are to be enquired. In the case of secondary infertility, the obstetric history is important. The history of puerperal sepsis may be responsible for ascending infection and tubal damage. Uterine synechiae may be due to vigorous curettage.

**Contraceptive practice** should be elicited. IUCD use may cause PID.

**Sexual problems** such as dyspareunia, and loss of libido are to be enquired. It should be born in mind that the female orgasm is not essential for fertility and loss of semen from the vaginal orifice following coitus is normal.

## EXAMINATIONS

General, systemic and gynecological examinations are made to detect any abnormality which may hinder fertility.

**General examination** must be thorough—special emphasis being given to obesity or marked reduction in weight (BMI). Hirsutism, acne, acanthosis nigricans (p. 459) or underdevelopment of secondary sex characters are to be noted. Physical features pertaining to endocrinopathies are carefully evaluated to detect features of PCOS and galactorrhea.

**Systemic examination** may accidentally detect such abnormalities like hypertension, organic heart disease, chronic renal lesion, thyroid dysfunction, and other endocrinopathies.

**Gynecological examination** includes adequacy of hymenal opening, evidences of vaginal infections, cervical tear or chronic infection, undue elongation of the cervix, uterine size, position and mobility, presence of unilateral or bilateral adnexal masses—fixed or mobile with or without tenderness and presence of nodules in the pouch of Douglas.

**Speculum examination** may reveal abnormal cervical discharge. The discharge is to be collected for Gram stain and culture. Cervical smear is taken as a screening procedure as a routine or in suspected cases.

## SPECIAL INVESTIGATIONS—Guidelines:

- ♦ In the presence of major fault in male such as azoospermia due to testicular destruction or intersex, there is very little scope to proceed for investigation for the female partner. However, considering the place of Assisted Reproductive Technology (ART) female investigation may not be withheld (p. 251).
- ♦ Similarly, when a major defect is detected in female such as müllerian agenesis or intersex, infertility investigations should be suspended. However, correctable abnormality should be rectified first prior to investigation, e.g. narrow vaginal introitus, overt hypothyroidism or diabetes mellitus.
- ♦ Noninvasive or minimal invasive methods are to be employed prior to major invasive one.

However, it is not uncommon to have pregnancy soon after the first visit.

- ◆ Detection of abnormality of one factor does not negate investigation for another defect elsewhere. Multiple defects may be present in the same case, e.g. tubal defects may be associated with anovulation.
- ◆ Pregnancy following laparoscopy and dye test or hysterosalpingography is not uncommon. It is presumed that small flimsy adhesions or any mucus plug obstructing the tubal lumen is removed during such procedures. The cervical spasm may be relieved during dilatation.
- ◆ Genital tuberculosis as a cause of infertility is to be kept in mind especially in the developing countries. The association is as high as 10–15 percent in contrast to a low figure of 0.5 percent in the developed countries.

**Ovarian factors:** Ovarian dysfunctions (dysovulatory) commonly associated with infertility are:

- Anovulation or oligo-ovulation (infrequent ovulation).
- Luteal phase defect (LPD).
- Luteinized unruptured follicle (LUF).

## DIAGNOSIS OF OVULATION

The various methods used in practice to detect ovulation are grouped as follows (Table 16.4):

- **Indirect** • **Direct** • **Conclusive**

### INDIRECT

The indirect or presumptive evidences of ovulation are commonly used in clinical practice. These are inferred from :

- Menstrual history.
- Evaluation of peripheral or endorgan changes due to estrogen and progesterone.
- Direct assays of gonadotropins or steroid hormones preceding, coinciding or succeeding the ovulatory process.

### MENSTRUAL HISTORY

The following features in relation to menstruation are strong evidences of ovulation.

**TABLE 16.4**    **DIAGNOSIS OF OVULATION**

#### Indirect

- ◆ Menstrual history
- ◆ Evaluation of peripheral or endorgan changes
  - BBT
  - Cervical mucus study
  - Vaginal cytology
  - Hormone estimation (see Table 16.6)
    - Serum progesterone
    - Serum LH
    - Serum estradiol
    - Urine LH
  - Endometrial biopsy
- ◆ Sonography (TVS)

#### Direct

Laparoscopy

#### Conclusive

Pregnancy

- Regular normal menstrual loss between the age of 20–35.
- Midmenstrual bleeding (spotting) or pain or excessive mucoid vaginal discharge (Mittelschmerz syndrome).
- Features suggestive of premenstrual syndrome or primary dysmenorrhea.

### EVALUATION OF PERIPHERAL OR ENDORGAN CHANGES (TABLE 16.4)

#### Basal body temperature (BBT)

*Observation:* There is “biphasic pattern” of temperature variation in ovulatory cycle. If pregnancy occurs, the rise of temperature sustains along with absence of the period. In anovulatory cycle, there is no rise of temperature throughout the cycle.

*Principle:* The rise of temperature is secondary to rise in progesterone output following ovulation. Progesterone is thermogenic. The primary reason for the rise is the increase in the production and secretion of norepinephrine which is also thermogenic.

*Procedures:* The patient is instructed to take her oral temperature **daily on waking in the morning before rising out of the bed**. The temperature is recorded on a special chart. Days when intercourse takes place should also be noted on the chart for better evaluation of coital frequency.

**Interpretation:** The body temperature maintaining throughout the first half of the cycle is raised to 0.5° to 1°F (0.2°–0.5°C) following ovulation. The rise sustains throughout the second half of the cycle and falls about 2 days prior to the next period—called 'biphasic pattern' (Fig. 16.1). There may be a drop in the temperature to about 0.5°F before the rise and almost coincides with either LH surge or ovulation. The demonstrable rise actually occurs about 2 days after the LH peak and with a peripheral level of progesterone greater than 5 ng/mL.

**Clinical importance:** Maintenance of BBT chart during investigation is of help in determining ovulation and timing of post-coital test, endometrial biopsy, cervical mucus or vaginal cytology study for ovulation. It also helps the couple to determine the most fertile period, if the cycle is irregular.

### Limitations of BBT

- BBT indicates ovulation retrospectively.
- It cannot predict ovulation precisely with time.
- Rarely, ovulation has been observed though BBT is monophasic.

### How long to keep the record?

It should not be continued for more than 3–4 months for investigation purpose. However, it has to be maintained for longer periods during management of ovulation induction.

### Cervical mucus study

Alteration of the physicochemical properties of the cervical mucus occurs due to the effect of estrogen and progesterone.

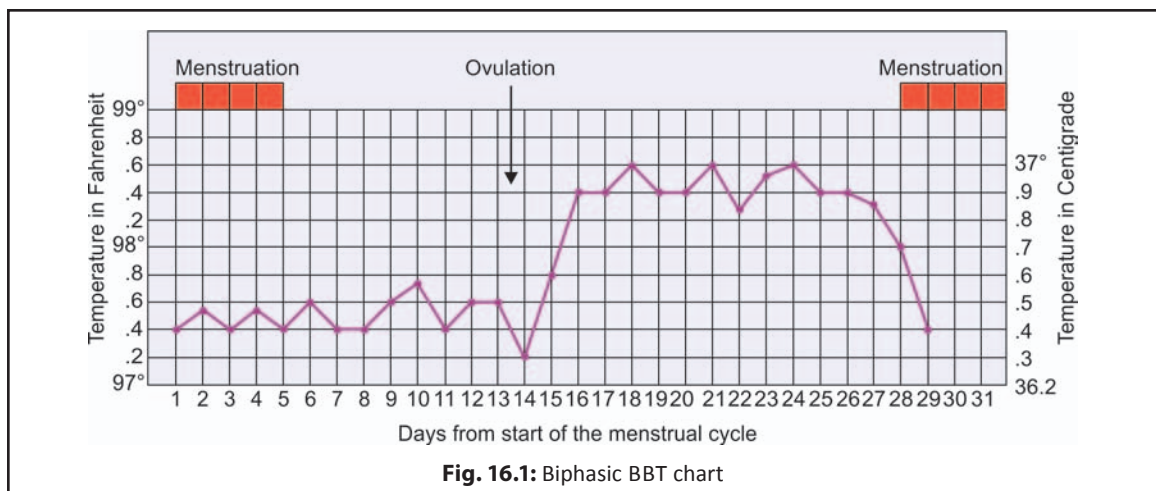
Disappearance of fern pattern beyond 22nd day of the cycle, which was present in the midcycle is suggestive of ovulation. Persistence of fern pattern even beyond 22nd day suggests anovulation. Progesterone causes dissolution of the sodium chloride crystals. Following ovulation, there is loss of stretchability (spinbarkeit), which was present in the mid cycle (see p.115).

### Vaginal cytology

Maturation index shifts to the left from the midcycle to the mid second half of cycle due to the effect of progesterone (see p.114). However, a single smear on day 25 or 26 of the cycle reveals features of progesterone effect, if ovulation occurs.

### Hormone estimation

- ♦ **Serum progesterone:** Estimation of serum progesterone is done on day 8 and 21 of a cycle (28 days). An increase in value from less than 1 ng/mL to greater than 6 ng/mL suggests ovulation.
- ♦ **Serum LH:** Daily estimation of serum LH at mid cycle can detect the LH surge. Ovulation occurs about 34–36 hours after beginning of the LH surge. It coincides about 10–12 hours after the LH peak.



- ♦ **Serum estradiol** attains the peak rise approximately 24 hours prior to LH surge and about 24–36 hours prior to ovulation.

The serum LH and estradiol estimation is used for in vitro fertilization.

### Urinary LH

LH kits are available to detect midcycle LH surge. **Ovulation usually occurs within 14–26 hours of detection of urine LH surge and almost always within 48 hours.** (The test should be done on a daily basis. It is started 2–3 days before the expected surge depending upon the cycle length).

### Endometrial biopsy

Endometrial tissues to detect ovulation (endometrial sampling) can easily be obtained as an outpatient procedure using instruments such as Sharman curette or Pipelle endometrial sampler. Dilatation and curettage is, however reserved in cases where bulk endometrial study is required as in endometrial tuberculosis.

**When to do? Biopsy is to be done on 21st–23rd day of the cycle.** Barrier contraceptive should be prescribed during the cycle to prevent accidental conception. However, if the cycle is irregular, it is done within 24 hours of the period.

*Findings:* Evidences of secretory activity of the endometrial glands in the second half of the cycle give not only the diagnosis of ovulation but can predict the functional integrity of the corpus luteum.

**Subnuclear vacuolation is the earliest evidence** appearing 36–48 hours following ovulation.

*Cause:* The secretory changes are due to the action of progesterone on the estrogen primed endometrium.

**SONOGRAPHY:** Serial sonography (TVS) during mid cycle can precisely measure the Graafian follicle just prior to ovulation (18–20 mm). It is particularly helpful for confirmation of ovulation following ovulation induction, artificial insemination, and *in vitro* fertilization. **The features of recent ovulation are** collapsed follicle and fluid in the pouch of Douglas.

## DIRECT

**LAPAROSCOPY:** Laparoscopic visualization of recent corpus luteum or detection of the ovum from the

aspirated peritoneal fluid from the pouch of Douglas is the only direct evidence of ovulation.

**Conclusive:** Pregnancy is the surest evidence of ovulation.

## LUTEAL PHASE DEFECT (LPD)

**Diagnosis** of LPD is difficult. However, it is based on the following:

- ♦ BBT chart—(a) Slow rise of temperature taking 4–5 days following the fall in the midcycle. (b) Rise of temperature sustains less than 10 days.
- ♦ Endometrial biopsy—Biopsy done on 25–27th day of the period reveals the endometrium at least 3 days out of phase (**Example:** If the biopsy is done on 25th day of cycle, the endometrial changes observed correspond to the day 22). This lag phase endometrium must be proved in more than one cycle (see p. 93). However, it is not conclusive.
- ♦ Serum progesterone estimated on 8th day following ovulation is less than 10 ng/mL.

## LUTEINIZED UNRUPTURED FOLLICLE (LUF)

Luteinized unruptured follicle (LUF) syndrome refers to an infertile woman with regular menses and presumptive evidences of ovulation without release of the ovum from the follicle (trapped ovum). The features of ovulation—formation of corpus luteum and its stigma are absent. It is often associated with pelvic endometriosis.

**Diagnosis:** In the presence of biologic effects of progesterone in the early luteal phase:

- Sonography: Persistence of echo-free dominant follicle beyond 36 hours after LH peak.
- Laparoscopy: Failure to observe a stigma of ovulation.
- Ovarian biopsy: Conclusive proof is determination of ovum amidst the structure of corpus luteum.

## TUBAL FACTORS (TABLE 16.6)

The anatomical patency and functional integrity of the tubes are assessed by the following tests:

- ◆ Dilatation and insufflation test (DI) p. 587
- ◆ Hysterosalpingography (HSG) p. 588
- ◆ Laparoscopy and chromopertubation (see below)
- ◆ Sonohysterosalpingography
- ◆ Falloposcopy
- ◆ Salpingoscopy.

### INSUFFLATION TEST (RUBIN'S TEST)

**Principle:** The underlying principle lies with the fact that the cervical canal is in continuity with the peritoneal cavity through the tubes. As such, entry of air or CO<sub>2</sub> into the peritoneal cavity when pushed transcervically under pressure, gives evidence of tubal patency.

**When to be done?** It should be done in the post-menstrual phase at least 2 days after stoppage of menstrual bleeding.

**Limitation:** It should not be done in the presence of pelvic infection.

**Observations:** The patency of the tube is confirmed by: (1) fall in the pressure when raised beyond 120 mm Hg, (2) hissing sound heard on auscultation on either iliac fossa and (3) shoulder pain experienced by the patient (irritation of the diaphragm by the air).

**Drawbacks:** In about one-third of cases, it gives false-negative findings due to cornual spasm. It also cannot identify the side and site of the block in the tube. As such, it is inferior to other methods of tubal study. This test is not commonly done these days.

### HYSTEOSALPINGOGRAPHY (HSG) P. 588

**Principle:** The principle is the same like that of insufflation test. Instead of air or CO<sub>2</sub>, dye is instilled transcervically.

**When to be done?** As in D + I.

**Limitation:** As in D + I.

**Advantages:** It has got distinct advantages over insufflation test. It can precisely detect the side and site of block in the tube. It can reveal any abnormality in the uterus (congenital or acquired like synechiae, fibroid). As such, insufflation of the tubes has largely been replaced by HSG (Fig. 16.3).

**Disadvantages** (p. 588): It involves radiation risk (p. 589).

## LAPAROSCOPY AND CHROMOPERTUBATION (FIG. 16.3)

**Laparoscopy is the gold standard (definitive method) for evaluation of tubal factors of infertility.**

It is done after male factor and ovulatory functions have been found normal or corrected. The indications of its use are mentioned in Table 16.5.

TABLE 16.5	INDICATIONS OF LAPAROSCOPY IN INFERTILITY
Diagnostic	<ul style="list-style-type: none"> <li>• Age &gt; 35 years</li> <li>• Abnormal HSG</li> <li>• Failure to conceive after reasonable period (6 months) with normal HSG</li> <li>• Women with comorbid pelvic pathology (PID, endometriosis).</li> <li>• Unexplained infertility</li> </ul>
Operative	<ul style="list-style-type: none"> <li>• Ovarian drilling (p. 247, 471)</li> <li>• Reconstructive tubal surgery</li> <li>• Adhesiolysis (Table 16.9)</li> <li>• Fulguration of endometriotic implants</li> <li>• GIFT and ZIFT procedures</li> </ul>

### BENEFITS OF LAPAROSCOPIC EVALUATION

- ◆ **TUBES:** for detection of tubal patency, block (site and side), motility, hydrosalpinx change, adhesions, fimbrial agglutination.
- ◆ **OVARIES:** PCOS changes (p. 459), endometriosis, PID (p. 130).
- ◆ **UTERUS:** anomalies (p. 43), fibroids.
- ◆ **PERITONEAL FACTORS:** adhesions, PID, endometriosis, tuberculosis.
- ◆ **Therapy** at the same sitting (as appropriate) (p. 614).

**Drawbacks:** Laparoscopy is more invasive than HSG. It cannot detect abnormality in the uterine cavity or tubal lumen. Thus, the two procedures (HSG and laparoscopy) should be regarded as complementary to each other and not a substitute to the other procedure.

**When to be done?** It may be done in the proliferative phase. When done in the secretory phase, recent corpus luteum may be seen and endometrial biopsy can be taken in the same sitting.



### SONOHYSTEROSALPINGOGRAPHY

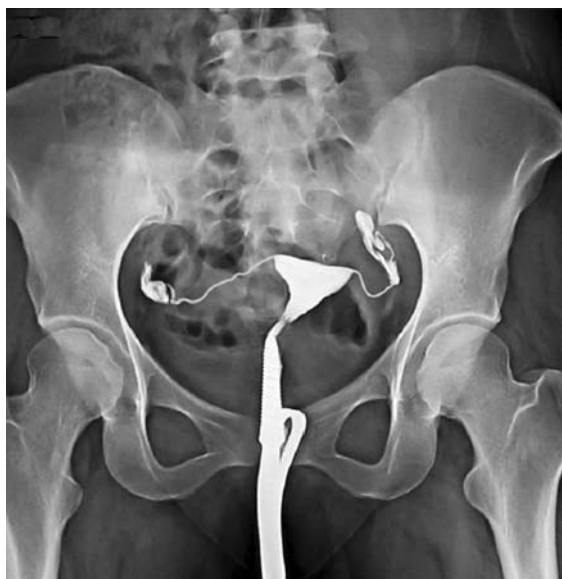**Principle:** Normal saline is pushed within the uterine cavity with a pediatric Foley catheter. The catheter balloon is inflated at the level of the cervix to prevent fluid leak. Ultrasonography of the uterus and fallopian tubes are done. Ultrasound can follow the fluid through the tubes up to the peritoneal cavity and in the pouch of Douglas.

**Advantages:** It is a noninvasive procedure. It can detect uterine malformations, synechiae, or polyps (superior to HSG). Tubal pathology could be detected as that of HSG. There is no radiation exposure.

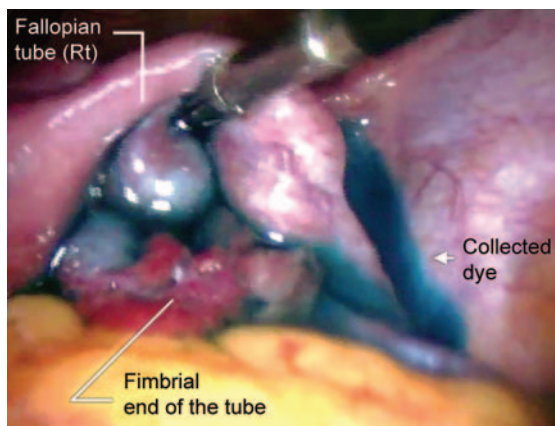
**Fallopiscoposcopy** is to study the entire length of tubal lumen with the help of a fine and flexible fiberoptic device. It is performed through the uterine cavity, using a hysteroscope. It helps direct visualization of tubal ostia, mucosal pattern, intratubal polyps, or debris.

**Salpingoscopy:** Tubal lumen is studied introducing a rigid endoscope through the fimbrial end of the tube. It is performed through the operating channel of a laparoscope.

**Uterine factor:** Uterine factors commonly associated with subfertility are submucous fibroids (see p. 273), congenital malformations (see Ch. 4),



**Fig. 16.2:** Hysterosalpingogram showing bilateral peritoneal spillage



**Fig. 16.3:** Chromopertubation shows the patency of the tubes with spillage of dye (methylene blue) in the peritoneal cavity (Courtesy: Dr. Manoj Samanta)

and intrauterine adhesions (Asherman's syndrome). They are more likely to cause recurrent pregnancy loss rather than primary infertility.

Ultrasonography, HSG, hysteroscopy, and laparoscopy are needed in the evaluation of uterine factor for subfertility.

**Cervical factor (Table 16.6):** The cervix functions as a biological valve. This is in the sense that, in the proliferative phase, it permits the entry of sperm and in the secretory phase, hinders their penetration (Fig. 16.4). As such, dysfunction at this level should be carefully evaluated. This is done by:

#### Postcoital test (PCT) (Sims-Huhner test)

**Principle:** PCT is to assess the quality of cervical mucus and the ability of sperm to survive in it. This has been described in Chap. 9, p. 114, 115.

#### Sperm cervical mucus contact test (SCMCT)

This *in vitro* cross over test is performed using midcycle cervical mucus of the wife and semen of the husband under question and compare with donor sperm and donor cervical mucus (see p. 115). **Postcoital test for diagnosis of cervical factor for infertility is no longer recommended** (see p. 114, 115).

**Endocrinopathy:** In-depth investigations in suspected or overt endocrinopathy with or without menstrual abnormality or ovarian dysfunction include estimation of serum TSH, prolactin, FSH,

**TABLE 16.6** INFERTILITY WORK UP CALENDAR

Identification of factor	Methods employed	Day of cycle	Observation	
<b>OVULATION</b>	<ul style="list-style-type: none"> <li>• BBT</li> <li>• Endometrial biopsy</li> <li>• Cervical mucus Nature Threadability Fern pattern</li> </ul>	Throughout cycle D 21–23 D 12–14 and D 21–23	Biphasic pattern Secretory endometrium D 12–14 D 21–23 Clear, watery Thick, viscid + – + –	
	<ul style="list-style-type: none"> <li>• Vaginal cytology</li> </ul>	D 12–14 and D 21–23	D 12–14 D 21–23 Discrete cells Folded edges. Pyknotic nuclei, In clumps background background clear dirty	
	<ul style="list-style-type: none"> <li>• Serum progesterone</li> <li>• Serum LH</li> <li>• Urinary LH (p. 237)</li> <li>• Serial transvaginal sonography</li> <li>• Laparoscopy</li> </ul>	D 8 and D 21 Midcycle daily (D 12–14) D 12–14 Secretory phase	D-8 < 1 ng/mL D-21 > 6ng/mL Ovulation: About 10–12 hours after LH surge Follicular measurements-approaching 20 mm Recent corpus luteum	
	<b>TUBAL FACTOR</b>	<ul style="list-style-type: none"> <li>• Insufflation test</li> </ul>	Proliferative phase - 2 days after the bleeding stops	i. Drop in pressure when raised to 120 mm Hg ii. Hissing sound on iliac fossa iii. Shoulder pain
		<ul style="list-style-type: none"> <li>• Hysterosalpingography</li> </ul>	As above	Spillage of dye into the peritoneal cavity
<ul style="list-style-type: none"> <li>• Laparoscopy and dye test</li> </ul>		Proliferative phase (7th-10th day of cycle) RCOG	<ul style="list-style-type: none"> <li>• Peritubal pathology</li> <li>• Pelvic pathology (Endometriosis)</li> <li>• Ovulation</li> <li>• Tubal patency by dye spillage from both the tubes</li> </ul>	
<ul style="list-style-type: none"> <li>• Sonohysterosalpingography</li> <li>• Falloposcopy</li> </ul>		Proliferative phase Proliferative phase	Better than HSG for detection of intra-uterine pathology. Tubal luminal pathology	
<b>CERVICAL</b>	<ul style="list-style-type: none"> <li>• Postcoital test (PCT)</li> </ul>	Around ovulation (D 12–14)	Presence of progressive motile sperm (10 per high power field)	
	<ul style="list-style-type: none"> <li>• Sperm cervical mucus contact test (SCMCT)</li> </ul>	As above	Sperm antibodies (see p. 114, 242)	

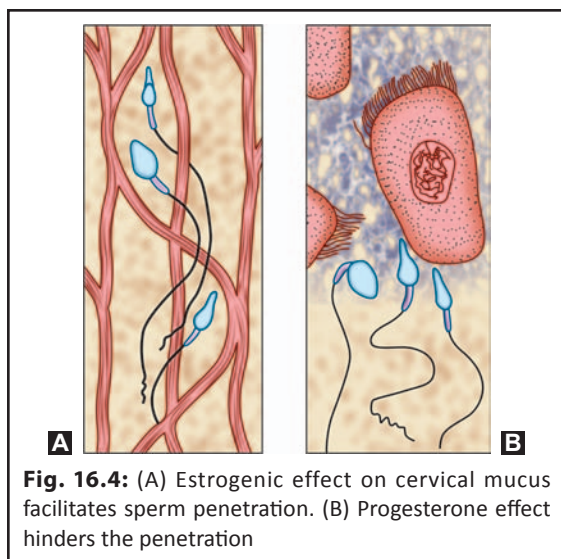
LH, dehydroepiandrosterone sulphate, testosterone, and progesterone in midluteal phase. In cases with family history of diabetes, postprandial blood sugar is to be estimated.

**Immunological factor:** Human sperm has immunologic potential. Sperm elicit antibodies against the antigens. The antibodies against sperm

may affect fertility by immobilizing sperm or causing agglutination.

Male may also produce autoantibodies against sperm antigens. Sperm coated with these antibodies fail to migrate through the cervix.

**Most common variety of antisperm antibodies are IgG, IgM, and IgA isotypes.** IgG may be found



**Fig. 16.4:** (A) Estrogenic effect on cervical mucus facilitates sperm penetration. (B) Progesterone effect hinders the penetration

in cervical mucus, serum, and semen. Agglutinating antibodies of IgA class are found in cervical mucus and seminal plasma. The IgM (larger) molecules are found exclusively in the serum. **These immunoglobulins can bind to different parts of the sperm (e.g. head, body, or tail) and make them immobile.**

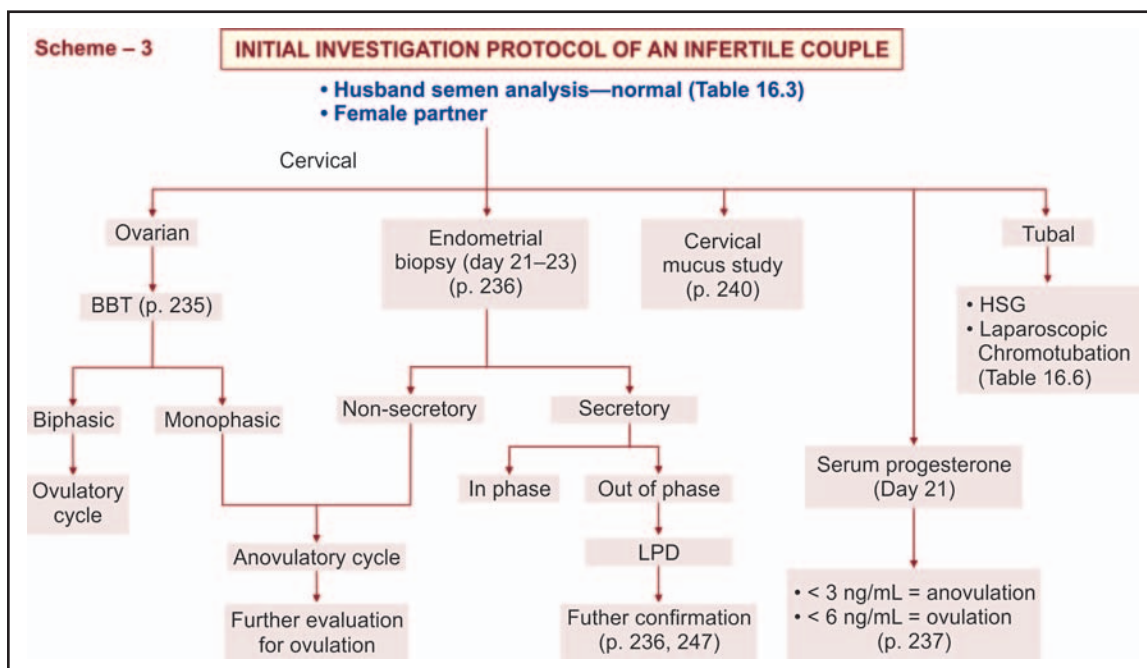
Detection of antisperm antibody has not been found to be helpful in the management of infertility. Treatment of antisperm antibodies has not improved the pregnancy outcome. Therefore, antisperm antibody testing is rarely done these days, specially with the advent of IUI, IVF, or ICSI (see p. 251).

**Unexplained infertility** is defined when no obvious cause for infertility has been detected following all standard investigations. These include semen analysis, ovulation detection, tubal and peritoneal factors, endocrinopathy, and PCT. Overall incidence is 10–20 percent. With expectant management about 60 percent of couples with unexplained infertility will conceive within a period of 3 years. IVF and ET (see p. 251) may be an option for those who fail to respond.

## TREATMENT OF INFERTILITY

### COUPLE INSTRUCTIONS

**Assurance:** The infertile couple remains psychologically disturbed right from the beginning, more so as the investigation progresses. The couple in such cases should be tactfully handled to minimize psychological upset.



When minor defects are detected in both the husband and the wife, each of which alone could not cause infertility but in combination, they significantly decrease the fertility potential. As such, **the faults should be treated simultaneously and not one after the other**. Even when a gross abnormality is detected and the prospect of pregnancy is bleak, an optimistic discussion is worth rewarding.

**Body weight:** Overweight or underweight of any partner should be adequately dealt with to obtain an optimum weight. Body mass index of 20–24 is optimum.

**Smoking and alcohol:** Excess smoking or alcohol consumption is to be avoided.

**Coital problems:** The coital problems should be carefully evaluated by intelligent interrogation. Advice to have intercourse during the midcycle too often gives the result early enough even prior to investigation. Using LH test kit, one can detect LH surge in urine by getting a deep blue color of dipstick. The test should be performed daily between day 12 and day 16 of a regular cycle. Timed intercourse over 24–36 hours after the color change reasonably succeeds in conception. Minor psychosexual problems should be corrected accordingly.

► Male ► Female ► Combined

## MALE INFERTILITY

**The treatment of male is indicated in** (i) extreme oligospermia, (ii) azoospermia, (iii) low volume ejaculate and (iv) impotency. Management is often difficult and unsatisfactory.

To improve spermatogenesis the following measures may be helpful.

- ▲ **General care:** Improvement of general health, reduction of weight in obese, avoidance of alcohol and heavy smoking are of help.
- ▲ Medications that interfere spermatogenesis (p. 228) should be avoided.
- In **hypogonadotropic-hypogonadism**, the disorders of spermatogenesis can be treated with the following therapy with varying success.
  - hCG 5000 IU intramuscularly once or twice a week is given to stimulate endogenous testosterone production.

- hMG or pure FSH (75–150 IU) is added to hCG when there is no sperm in the ejaculate with hCG alone.
- Dopamine agonist (cabergoline) is given in hyperprolactinemia to restore normal prolactin and testosterone level. This improves libido, potency and fertility.
- Pulsatile GnRH therapy in infertile male with GnRH deficiency (Kallmann's syndrome) is effective. It is administered by minipump infusion. Target is to maintain normal adult male LH levels. Cases with hypogonadotropic hypogonadism may also respond with GnRH therapy.
- **Hypergonadotropic-hypogonadism**, no form of medical treatment can improve fertility in men (see p. 233). Treatment options available are insemination with donor sperm or adoption when no sperm is available. IVF with ICSI may be done in cases with severe oligospermia.
- Clomiphene citrate 25 mg orally daily for 3 months is given. It increases serum level of FSH, LH and testosterone.
- **Presence of antisperm antibodies** in the male and its significance is unclear. Currently intrauterine insemination (IUI) is the choice of treatment for such cases (see p. 250).
- **Leukocytospermia:** Genital tract infection needs prolonged course of antibiotics. Generally doxycycline or erythromycin is given for a period of 4–6 weeks depending on the response. However, leukocytospermia does not always predict infection and it may not have any effect on fertility.
- **Retrograde ejaculation:** Phenylephrine ( $\alpha$ -adrenergic agonist) is used to improve the tone of internal urethral sphincter. Sperm may be recovered from the neutralized urine. Processed spermatozoa could be used for IUI (see p. 250).
- Teratospermia, asthenospermia: Specific causes are unknown. No treatment is available. Donor insemination (AID) is the option (see p. 250).
- Genetic abnormality: Artificial insemination with donor sperm (AID) is the option as no other treatment is available.

### ▲ Surgical

- ▶ When the patient is found to be azoospermic and yet testicular biopsy shows normal spermatogenesis, obstruction of vas must be suspected. This should be corrected by microsurgery—vasoepididymostomy or vasovasostomy. After vasovasostomy patency is obtained in about 80 percent of cases and pregnancy rate is about 50 percent.
- ▶ Surgery for varicocele for improvement of fertility is not helpful. Hydrocele is corrected by surgery.
- ▶ Orchidopexy in undescended testes should be done between 2–3 years of age to have adequate spermatogenesis in later life.

### ▲ Impotency

Psychosexual treatment may be of help. Hyperprolactinaemia needs further investigation and treatment (see p. 471). For erectile dysfunction sildenafil (25–100 mg) or tadalafil (10–20 mg) is currently advised. A single dose (depending on response) is given orally one hour before sexual activity. In unresponsive cases, artificial insemination is to be thought of (see p. 250).

## ASSISTED REPRODUCTIVE TECHNOLOGY (ART) FOR MALE INFERTILITY (P. 240)

Prospect of male infertility has improved significantly with the advent of ART. IUI, TESE, PESA, MESA and intracytoplasmic sperm injection (ICSI) are now the treatment available for infertile males (see p. 251).

## FEMALE INFERTILITY

For convenience, the treatment modalities in female infertility are grouped as follows according to the disorders identified:

- Ovulatory.
- Tubal.
- Associated disorders like endometriosis, infections or endocrinopathy.
- Cervical.
- Immunological.
- Unexplained infertility.
- Uterovaginal canal.
- Assisted reproductive technology (ART).



## OVULATORY DYSFUNCTION

### ■ Anovulation ■ LPD ■ LUF

For WHO classification—see p. 258.

### ■ Anovulation

Anovulation is a common factor for female infertility. It may be present in otherwise normal menstrual cycle or may be associated with oligomenorrhea or amenorrhea.

**Induction of Ovulation** — Measures are :

➤ General ➤ Drugs ➤ Surgery

### GENERAL

- Psychotherapy to improve the emotional causes, if any.
- Reduction of weight in obesity as in PCOS cases (see p. 470) is essential to have a good response of drug therapy for induction. This facilitates spontaneous ovulation.

**DRUGS:** The following drugs are of use either singly or in combination (Table 16.7).

TABLE 16.7

### DRUGS USED IN INDUCTION OF OVULATION

#### Stimulation of ovulation

- ◆ Clomiphene citrate (CC)
- ◆ Letrozole (p. 533)
- ◆ hMG (Humegon, Pergonal) (FSH 75 IU + LH 75 IU)
- ◆ FSH
  - purified urinary FSH (u FSH)
  - highly purified urinary FSH (Metrodin HP)
  - recombinant FSH (r FSH)
- ◆ hCG (Profasi, Pregnyl)
  - recombinant hCG
- ◆ GnRH (see p. 246)
- ◆ GnRH analogues (see p. 252)

#### Correction of Biochemical Abnormality

- ◆ Hyperinsulinemia (insulin resistance) -Metformin (see p. 470) (insulin sensitiser)
- ◆ Androgen excess - Dexamethasone (see p. 470)
- ◆ Prolactin raised - Bromocriptine (see p. 471)

#### Substitution therapy

- ◆ Hypothyroidism - Thyroxin
- ◆ Diabetes mellitus - Antidiabetic drugs

**TABLE 16.8** OBJECTIVES OF MONITORING FOR INDUCTION OF OVULATION

- To select time for preovulatory administration of hCG.
- To prevent ovarian hyperstimulation syndrome.
- To select time for intercourse or artificial insemination.
- To select time for ovum retrieval in IVF.

### Monitoring during ovulation induction (Table 16.8)

For diagnosis of ovulation, BBT recording is enough. With some therapies, diagnosis of ovulation is obtained from BBT chart supplemented by cervical mucus study (clear, watery, stretchable type). But when a complicated regimen is followed to achieve pregnancy by time intercourse or by ART, a detailed monitoring is a must which is only possible in selected centers. Not only the drugs are costly, the regimens are complicated and time consuming.

Apart from BBT chart and cervical mucus study which are noninvasive, simple and quite informative, other parameters used are serial estimation of plasma  $E_2$  and ultrasonic measurement of growing follicles (folliculometry). These last two are obligatory in ART.

#### CLOMIPHENE CITRATE: Patient selection

- ◆ Normogonadotropic—normoprolactinemic patients who are having normal cycles with absent or infrequent ovulation.
- ◆ PCOS cases with oligomenorrhea or amenorrhea. The estradiol level should be  $> 40$  pg per mL.
- ◆ Hypothalamic amenorrhea following stress or 'pill' use.

**Dose:** Clomiphene therapy is simple, safe and at the same time cost-effective. Most centers use an initial dose of 50 mg daily. Dose is increased in 50 mg steps to a maximum 250 mg daily, if ovulation is not induced by the lower dose. The actual starting day of its administration in the follicular phase varies between day 2 and day 5 and therapy is given for 5 days. Ovulation is expected to occur about 5–7 days after the last day of therapy. Therapy for six cycle is generally given.

**Mechanism of action of clomiphene:** Clomiphene citrate is anti-estrogenic as well as weakly estrogenic.

It blocks the estrogen receptors in the hypothalamus. This results in increased GnRH pulse amplitude causing increased gonadotropin secretion from the pituitary. Anti-estrogenic effects are seen on the endometrium and on the cervical mucus.

**SIDE EFFECTS:** Hot flushes, nausea, vomiting, headache, visual symptoms and ovarian hyperstimulation (rare). Incidence of abortion and congenital fetal malformations are not increased.

**Couple instruction:** The couple is advised to have sexual intercourse as per following guidelines:

- ◆ Daily or on alternate days beginning 5–7 days after the last dose of clomiphene therapy.
- ◆ Several times for 24–48 hours after the color change in urine when tested by LH kit.
- ◆ Number of times over 24–36 hours following hCG administration.

*Result:* Successful induction rate is as high as 80 percent but cumulative pregnancy rate is about 70 percent over 6–9 cycles. **The discrepancy is due to** premature luteinization, LPD, cervical mucus hostility and other non-ovulatory factors. The incidence of multiple pregnancy is about 7 percent.

#### Adjuvant therapy

Despite the high success rate of clomiphene, some adjuvant therapy is often needed.

- Hyperinsulinemia and Insulin sensitizer** - Patients with polycystic ovarian disease with BMI  $> 25$  (see p. 459) are often found insulin resistant. Obese women with PCOS often suffer from impaired glucose tolerance (33%) or type 2 diabetes (10%). Correction of their metabolic abnormality (see p. 470) along with weight reduction gives satisfactory result. **Treatment with metformin (insulin sensitizer) is found to reduce hyperinsulinemia and hyperandrogenemia.** Combination treatment with metformin and clomiphene increases ovulation rate significantly.
- Pre-existing or induced **elevated androgens** may be suppressed by dexamethasone 0.5 mg daily for 10 days, starting from 1st day of cycle. The drug should be stopped soon after ovulation.

- c. Eltroxin 0.1 mg may be administered daily during the therapy in obese patients with **subclinical hypothyroidism**.
- d. **Elevated prolactin level** with or without galactorrhea indicates abnormal GnRH pulse secretion. This causes ovulatory dysfunction, LPD or amenorrhea. **Bromocriptine or cabergoline (dopamine agonist)** therapy (see p. 470) increases the ovarian responsiveness to clomiphene. Patients with normal or minimally elevated prolactin when treated with bromocriptine and clomiphene are found to have increased pregnancy.

*Results:* Dopamine agonist treatment normalizes prolactin level (80%), restores cyclic menses (80%) and ovulation in majority (70%) of women.

*Side effects:* Nausea, dizziness, vomiting and orthostatic hypotension are common. Side effects of cabergoline are less, especially when it is used by the vaginal route.

- e. **hCG:** In cases of anovulation due to failure of LH surge, hCG 5000 IU is administered usually 7 days after the last dose of clomiphene therapy. Prior monitoring of serum estradiol level and ultrasonic measurement of follicular diameter (18–20 mm) is preferred to get a good result.
- f. Growth hormone—is combined to the poor responders especially, in the elderly group.
- g. Because of the anti-estrogenic effect of clomiphene citrate, the cervical mucus becomes thick and viscid and it hinders sperm penetration. Conjugated estrogen 1.25 mg given daily for 10 days starting on first day of cycle may be helpful.

**AROMATASE INHIBITORS:** Letrozole - see p. 533.

## GONADOTROPINS

### Prerequisites for gonadotropin therapy

- ♦ **Ovarian reserve** must be present (p. 528, 529). Decline in fertility status due to oocyte depletion is known as **decreased ovarian reserve**. **Age of the woman is the strongest determinant of ovarian reserve. Value of serum FSH more than 10 IU/L, measured on D3, is suggestive of poor ovarian reserve.**
- ♦ Other (non-ovulatory) factors for infertility must be ruled out. hMG (human menopausal

gonadotropin) is a mixture of FSH and LH [Pergonal = FSH (75 IU) + LH (75 IU)].

## INDICATIONS OF GONADOTROPIN USE

- Hypogonadotropic hypogonadism (WHO Group I). See p. 258.
- Clomiphene failed or resistant cases (WHO Group II). See p. 258.
- Unexplained infertility.
- Sub-fertile women who are elderly.

## DOSE SCHEDULE

- ♦ hMG stimulates follicular growth with a variable dose schedule starting with a low dose (75 IU 1M/day)
- ♦ Stimulation is started any time from D<sub>2</sub> to D<sub>5</sub> of the cycle and is continued for 7–10 days depending on the response.
- ♦ Follicular growth is monitored with serum estradiol estimation and follicular number and size are measured by transvaginal sonography (TVS).
- ♦ Serum estradiol level of 500–1500 pg/mL (150–300 pg/mature follicle) and maximum follicular diameter of 18–20 mm are optimum. Endometrial thickness (TVS) ≥ 8–9 mm (trilaminar) is taken as optimum.
- ♦ When these optimum levels are obtained, 5000–10000 IU of hCG is administered 1M to induce ovulation.
- ♦ Endometrial thickness of 8–10 mm (as measured by TVS) on the day of hCG administration favors successful implantation.
- ♦ Ovulation is expected to occur, approximately 36 hours after the hCG administration.

*Gonadotropin regimens may be “step up” or “step down” depending upon the response of the women to exogenous gonadotropin.*

## Couple instruction

Couple is advised for the timing of intercourse or insemination (ART) accordingly (see above).

Patients with PCOS are more sensitive to hMG stimulation. Purified FSH (metrodin) or highly

purified FSH (metrodin HP) or recombinant FSH (Gonal F, Recegon) have been used successfully with minimal side effects.

**In cases of hypergonadotropic hypogonadism,** high gonadotropin levels are lowered with the use of combined estrogen and progestogen preparations (oral pill). Use of long-acting GnRH agonist also suppresses high endogenous gonadotropin levels (see p. 525). When the levels reach normal, gonadotropin therapy may be employed to achieve ovulation. The success rate is poor.

### **SIDE EFFECTS OF GONADOTROPIN THERAPY (SEE P. 527)**

#### **Contraindications of Gonadotropin therapy**

- (1) Primary ovarian failure with raised serum FSH and (2) Uncontrolled thyroid and adrenal dysfunction.
- (3) Sex hormone dependent tumor in the body.
- (4) Pituitary tumor. (5) Ovarian cysts.

*Results:* Pregnancy rate after six courses of treatment is 90 percent. Incidence of multiple pregnancy (10–30%), overall incidence of miscarriage (20–25%) and ectopic pregnancy are high. Risks of congenital anomalies are not increased.

**GnRH: Exogenous GnRH**—Pulsatile GnRH treatment stimulates physiologic levels of pituitary gonadotropin secretion. So development of follicular growth, selection, recruitment and ovulation occurs as in normal menstrual cycle.

**Patient selection:** When ovulatory dysfunction is due to:

- Hypothalamic amenorrhea
- Hypogonadotropic hypogonadism
- Women with hyperprolactinemia.

GnRH is administered intravenously or subcutaneously with an infusion pump in a pulsatile fashion.

A pulse of 5 µg is used IV at every 90 minutes. Follicular growth is similar to a normal menstrual cycle. Follicular growth monitoring, hCG administration and couple instructions are same as in hMG therapy.

*Results:* Pregnancy rate is 80 percent following six courses of treatment. Multiple pregnancy rate is 5 percent. Overall risk of miscarriage is 30 percent. The risk of ovarian hyperstimulation is low (see p. 529).

### **GnRH analogues (p. 525)**

#### **Patient selection**

- ♦ Patients refractory to gonadotropins.
- ♦ Patients having elevated LH.
- ♦ Patients with normal gonadotropins.
- ♦ Patients with premature follicular luteinization or premature ovulation due to premature LH surge.

GnRH agonist (buserelin, nafarelin) is given subcutaneously or intranasally either maintaining a short or long protocol. GnRH agonist is used for down regulation of pituitary gland by desensitization of pituitary GnRH receptors (see p. 67). GnRH agonist initially produce stimulation of gonadotropin secretion known as ‘flare’ effect. Generally, this flare effect lasts for about 2–3 weeks. Adequate pituitary suppression is achieved when serum estradiol level is less than 10 pg/mL and FSH level is less than 10 mIU/mL. Follicular stimulation is achieved with highly purified or recombinant FSH. Follicular number and growth monitoring is similar as in hMG therapy. hCG is also administered when criteria is fulfilled as discussed with hMG therapy (see p. 245).

*Results*—ovulation rate is about 75 percent and pregnancy rate is about 25 percent.

**GnRH antagonists**—can block pituitary GnRH receptors completely without any initial stimulation (flare effect). Cetrorelix is currently being tried to prevent premature LH surge. As with GnRH analogue, gonadotropin stimulation is done (see above).

When pregnancy occurs following superovulation with GnRH agonist therapy, **luteal phase support should be maintained** by giving hCG and/or progesterone.

It should be emphasized that the gonadotropins, GnRH and GnRH analogues are costly drugs. **Their uses have to be monitored carefully with sophisticated gadgets** not only to control the regimen but also to minimize the hazards (Table 16.7). Thus, its use is restricted in selected centres and is commonly used in ART.



## LUTEAL PHASE DEFECT (LPD)

**Treatment:** The following treatment may be of help in the idiopathic groups:

- Natural progesterone as vaginal suppositories 100 mg thrice daily starting from the day of ovulation is effective. It should be continued until menses begins. If menses fails to appear after 14 days, pregnancy test is to be done. If the test is positive, it should be continued upto 10th week of pregnancy.
- hCG is a potent luteotropic hormone, however, the response of LPD to hCG is unpredictable.
- In unresponsive cases, clomiphene citrate may be tried. It increases FSH which may improve folliculogenesis and normal corpus luteum formation with adequate production of progesterone. In refractory cases, IVF may be tried.

## LUTEINIZED UNRUPTURED FOLLICLE (LUF)

Defective folliculogenesis or inadequate LH surge may be corrected with:

- Optimally timed intramuscular injection of hCG 5000–10,000 IU.
- Administration of ovulation inducing drugs in the follicular phase followed by ovulatory hCG (5000–10000 IU).
- Bromocriptine therapy, if associated with hyperprolactinemia (see p. 471).

## SURGERY

- **Laparoscopic ovarian drilling (LOD) or laser vaporization:** This is done by multiple puncture (4–6 sites) of the cysts in polycystic ovarian syndrome by diathermy or laser. It reduces systemic and intraovarian androgen levels. This procedure is helpful in clomiphene resistant, hyperandrogenic anovulatory women. The woman ovulates spontaneously following LOD (p. 471).
- **Wedge resection:** This is not commonly done these days. Bilateral wedge resection of the ovaries is done in PCOS as cases where clomiphene citrate fails to induce ovulation. It produces adhesions.
- **Surgery** for pituitary prolactinomas (see p. 471).
- **Surgical removal** of virilizing or other functioning ovarian or adrenal tumor (see p. 574).

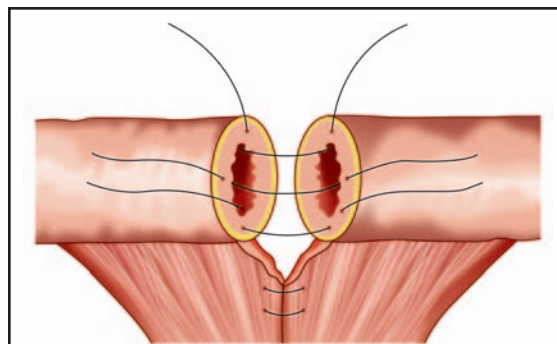
- **Uterovaginal surgery** (p. 249).

- **Bariatric surgery** (p. 249).

## TUBAL AND PERITONEAL FACTORS

Tubal factors for infertility are corrected only by surgery. The different surgical methods are:

- Peritubal adhesions:** Correction is done by salpingo-ovariolysis either by laparoscopy or by laparotomy.
- Proximal tubal block:** Salpingography under fluoroscopy may be helpful to remove any block due to mucus plugging. Otherwise proximal tubal cannulation with a guide wire under hysteroscopic guidance is done. In about 85 percent cases, tubal patency can be restored and over all pregnancy rate of about 45–60 percent is reported. **Cannulation and balloon tuboplasty can avoid the need of ART which is expensive.**
- Distal tubal block:** (a) *Fimbrioplasty/fimbriolysis*—release of fimbrial adhesions and/or dilatation of fimbrial phimosis. (b) *Neosalpingostomy*—to create a new tubal opening in an occluded tube.
- Mid tubal block:** *Reversal of tubal ligation*—pregnancy rates after this procedure varies between 50–82 percent. Success rate depends on—(a) age, (b) the method of sterilization (Pomeroy's, Fallope rings, Diathermy, etc.), (c) site of anastomosis (isthmic-isthmic or isthmic-cornual), (d) final length of reconstructed tube. Risk of ectopic pregnancy following tubal reanastomosis is 3–7 percent.



**Fig. 16.5:** Tubotubal anastomosis. Placement of four to five interrupted sutures using 8-0 polyglactin (under 10 x magnification)

## GUIDELINES FOR TUBAL SURGERY

- Tubal surgery may be considered in young women after previous tubal sterilization or in women with mild disease at the distal tubal segment.
- Tubal surgery may be tried for mild proximal tubal block.
- Preoperative assessment and planning for surgery has to be done by HSG and or laparoscopy and if possible, by falloposcopy to assess the tubal mucosa.
- Prior counseling of the couple about the hazards of surgery and prospect of future pregnancy should be done.
- In tubercular salpingitis, surgery is to be withheld. Following antitubercular therapy, IVF-ET may be employed, when the endometrium becomes free from lesion.
- IVF is considered as the best treatment option for any complicated tubal occlusive disease.
- Salpingectomy should be done before IVF when hydrosalpinges are present.

## METHODS OF TUBAL SURGERY

**Tuboplasty** is the name given to the finer surgery on the tubes to restore the anatomy and physiology as far as practicable (Table 16.9).

- The **operation** can be done by conventional methods, or by microsurgical techniques which may be employed following laparotomy or by laparoscopy (Fig. 35.5).
- **Microsurgical techniques give better result** due to minimal tissue handling and damage, perfect hemostasis and minimal adhesion formation. **Laparoscopic surgery gives the best result.**
- Nylon may be used as a temporary splint to facilitate suturing the ends. It should be removed following anastomosis and if kept inside, should be removed after 48 hours to minimize mucosal damage.
- Intraoperative instillation of Ringer lactate mixed with heparin or hydrocortisone may be employed to minimize adhesion formation.

## ADJUVANT THERAPY

**Adjunctive procedures to improve the result of tubal surgery include** prophylactic antibiotics, use of adhesion prevention devices (interceed, seprafilm) and postoperative hydrotubation.

**Hydrotubation:** Hydrotubation is a procedure to flush the tubal lumen by medicated fluids passed transcervically through a cannula. The fluid contains antibiotic and hydrocortisone (Gentamicin 80 mg and dexamethasone 4 mg in 10 mL distilled water). It should be done in postmenstrual phase.

**Results of tuboplasty:** The result depends upon the nature of pathology, type of surgery and techniques employed—macro or microsurgery. **Overall pregnancy rate (following laparoscopic surgery) is as follows:** Salpingo-ovariolysis 65%; Fimbrioplasty 32%; Tubotubal anastomosis 75%; Tubocornual anastomosis 55%. The result is better in microsurgical techniques when done laparoscopically. **The result is best in reversal tubal sterilization by tubotubal anastomosis using microsurgical techniques.**

**TABLE 16.9 TUBOPLASTY OPERATION**

<b>Adhesiolysis (Salpingo-ovariolysis)</b>	Separation or division of adhesions
<b>Fimbrioplasty</b>	Separation of the fimbrial adhesions to open up the abdominal ostium
<b>Salpingostomy</b>	That creates a new opening in a completely occluded tube. It is called <b>terminal or 'cuff'</b> at the abdominal ostium. The eversion of the neo-ostium is maintained by few stitches of 6-0 Vicryl
<b>Tubotubal anastomosis</b>	When the segment of the diseased tube following tubectomy operation is resected and end to end anastomosis is done (Fig. 16.5)
<b>Tubocornual anastomosis</b>	When there is cornual block, the remaining healthy tube is anastomosed to the patent interstitial part of the tube

### Factors for Poor Outcome Following Tuboplasty

- Dense pelvic adhesions.
- Loss of fimbriae.
- Bilateral hydrosalpinx > 3 cm (see p. 171).
- Length of the reconstructed tube < 4 cm.
- Reversal done after 5 years of sterilization operation.
- Presence of other factors for infertility.

### ENDOMETRIOSIS

Minimal asymptomatic pelvic endometriosis may be an incidental finding and intensive medical or surgical therapy does not improve the fertility status. However, the therapy should be instituted in minimal endometriosis with otherwise unexplained infertility. Mild endometriosis with involvement of the ovary or moderate endometriosis should be treated with drugs or surgery or both. For details see Chapter 21.

### CERVICAL FACTOR

Cervical mucus protects sperm from the hostile environment of the vagina and also from phagocytosis. The cervical mucus quality can be improved by conjugated estrogen 1.25 mg orally daily starting on day eight for 5 days.

In proved cases of *Cl. trachomatis* or *M. hominis*, doxycycline 100 mg twice daily for 14 days is to be given to both the partners. **Cervical factor when cannot be treated, is overcome by ART procedures like IUI, IVF or GIFT (see p. 251).**

### IMMUNOLOGICAL FACTOR

**In the presence of antisperm antibodies** in the cervical mucus, dexamethasone 0.5 mg at bed time in the follicular phase may be given. As there is no distinct benefit of such treatment in antisperm antibody positive patients, COH and IUI or IVF (p. 251) or ICSI (p. 254) is recommended.

**UTEROVAGINAL SURGERY:** The operations in the uterus to improve the fertility includes:

- ▮ **Myomectomy (see p. 281)** especially in submucous fibroid. Care should be taken to prevent or to minimize adhesions causing tubopathy.

- ▮ **Metroplasty (see Ch. 4)** either removal of septum or unification operation may be tried when no other cause is detected. This abnormality seldom causes infertility.

- ▮ **Adhesiolysis (Hysteroscopic)** with insertion of IUCD in uterine synechiae (see p. 472).

- ▮ **Enlargement of the vaginal introitus** (Fenton's operation p. 592) or removal of vaginal septum causing dyspareunia results in improvement of fertility.

- ▮ **Endometrial polyps:** Hysteroscopic polypectomy.

**BARIATRIC SURGERY: Obesity** is associated with hypogonadotrophic hypogonadism. Serum free testosterone concentrations are inversely related to body weight and BMI. Estrogen levels are raised due to increased aromatase activity in adipose tissue.

Obesity reduces fertility. Obese women require higher doses of gonadotropins to achieve pregnancy. Women with BMI > 35 kg/M<sup>2</sup> are considered for bariatric surgery.

**Method:** An adjustable silicone band is placed (laparoscopically) around the upper part of the stomach to create a small upper gastric pouch. This limits hunger and food intake by early feeling of satiety.

Bariatric surgery improves the problems of anovulation, hirsutism, insulin resistance and PCOS.

### UNEXPLAINED INFERTILITY

**Unexplained infertility** is earmarked to those couples who have undergone complete basic infertility work up and in whom no abnormality has been detected (normal semen quality, ovulatory function, normal uterine cavity and bilateral tubal patency) and still remains infertile. It is the diagnosis of exclusion. The incidence is extremely variable and largely dependent on the magnitude of the indepth investigation protocol extended to the couple. **The reported incidence varies from 10–30 percent.**

About 40 percent of these couples become pregnant within 3 years without having any specific treatment.

**Therapy:** The prospect of spontaneous conception decreases with increasing age of the woman and the duration of infertility. The recommended treatment for unexplained infertility are induction of ovulation,

IUI, Superovulation combined with IUI and Assisted Reproductive Technology (see below).

**Combined factor:** The faults detected in both the partners **should be treated simultaneously and not one after the other.**

## ARTIFICIAL INSEMINATION (AI)

Different methods are :

- ◆ IUI—Intrauterine insemination
- ◆ Fallopian tube sperm perfusion.

## INTRAUTERINE INSEMINATION (IUI)

IUI may be either AIH (artificial insemination husband) or AID (artificial insemination donor). Husband's semen is commonly used. **The purpose of IUI** is to bypass the endocervical canal which is abnormal and to place increased concentration of motile sperm as close to the fallopian tubes. The indications are tabulated in Table 16.10.

**TECHNIQUE:** Common methods to extract sperm from the seminal plasma are: washing, swim-up and density gradient centrifugation. Swim-up method allows most motile sperm to swim-up into the supernatant. Compared to washing method it contains no dead sperm and cellular debris. About 0.3 mL of washed and concentrated sperm is injected through a flexible polyethylene catheter within the uterine cavity around the time of ovulation (Table 16.12). Washing in culture media removes the proteins and prostaglandins from semen that may cause uterine cramps or anaphylactoid reactions.

**Density gradient centrifugation** recovers most highly motile as well as morphologically normal sperm. **The processed motile sperm count for insemination should be at least 1 million.** Best results are obtained when the motile sperm count exceeds 10 million. Normal sperm survive in this female reproductive tract and can fertilize an egg for at least 3 days but an oocyte survives only for 12–24 hours. The procedure may be repeated 2–3 times over a period of 2–3 days. To increase sperm motility, pentoxifylline (phosphodiesterase inhibitor) has been used. Generally 4–6 cycles of insemination with superovulation is advised (see Table 16.6).

**TABLE 16.10 INDICATIONS OF IUI**

- ◆ Hostile cervical mucus
- ◆ Cervical stenosis
- ◆ Oligospermia or asthenospermia
- ◆ Immune factor (male and female)
- ◆ Male factor—impotency or anatomical defect (hypospadias) but normal ejaculate can be obtained
- ◆ Unexplained infertility

**TABLE 16.11 TIMING OF IUI**

- ◆ Natural cycles  
Cervical mucus study, BBT chart, urine LH surge  
**IUI × 2, likely on day 12 and 14**
- ◆ Clomiphene induced cycles  
**IUI - hand 7 days after completion of CC**
- ◆ Urinary LH detection  
**IUI - 24 hours after color change**
- ◆ Use of hCG and sonography
  - hCG at 18 mm diameter of the follicle  
**IUI × 2, following 34–40 hours of hCG administration**

**Timing of IUI:** In cervical insemination, timing is not so much vital because the sperm can survive in the cervical canal for a day or two. As the reservoir function is not available in IUI, some form of **controlled ovarian hyperstimulation (COH)** is required (Table 16.11).

## RESULTS

Cumulative conception rates after 12 insemination cycles is 75–80%. The best results are obtained in the treatment of cervical factor and unexplained infertility and in stimulated cycle. IUI along with superovulation (induction of ovulation with hMG/ FSH hCG) gives higher result.

## ARTIFICIAL (THERAPEUTIC) INSEMINATION DONOR (AID)

When the semen of a donor is used for insemination it is called therapeutic insemination donor. **The indications are:**

- ▲ Untreatable azoospermia, asthenospermia.
- ▲ Genetic disease.

- ▲ Rh-negative donor insemination—for woman with Rh-sensitization.

The donor should be healthy and of the same ethnic group as husband. He should be serologically and bacteriologically free from venereal diseases including AIDS and hepatitis. The recipient and donor must be matched for blood grouping and Rh typing. Either fresh or frozen semen is used. Sperm specimen should only be used when it is kept sequestered for at least 180 days and thereafter it has been found negative for HIV. The legal, psychological and religious aspects should be counseled before its application.

**Results:** A total of 3–6 cycles may have to be utilized to get a success. The success rate is about 50–60 percent. Insemination when combined with superovulation, enhances success rate.

### FALLOPIAN TUBE SPERM PERFUSION

Indications are same as that of IUI.

**Technique:** Large volume of washed and processed sperm is injected within the uterine cavity around the time of ovulation (Table 16.12). This causes perfusion of the fallopian tubes with spermatozoa. In conjunction with ovulation induction pregnancy rate is 25–30 percent per cycle.

## ASSISTED REPRODUCTIVE TECHNOLOGY (ART)

The ART encompasses all the procedures that involve manipulation of gametes and embryos outside the body for the treatment of infertility (Table 16.12).

### IN VITRO FERTILIZATION AND EMBRYO TRANSFER (IVF-ET)

The field of reproductive medicine has changed for ever with the birth of Louise Brown in 1978 by IVF-ET. **Patrick Steptoe and Robert Edwards of England are remembered for their revolutionary work.**

The past decade has witnessed two more dramatic changes in the technique protocol of IVF-ET. One such change was from natural cycle to superovulation protocol and the other one was replacement of

TABLE 16.12	ASSISTED REPRODUCTIVE TECHNIQUES (ART)
IVF-ET	: <i>In vitro</i> fertilization and embryo transfer
GIFT	: Gamete intra-fallopian transfer
ZIFT	: Zygote intra-fallopian transfer
POST	: Peritoneal oocyte and sperm transfer
TET	: Tubal embryo transfer zone
SUZI	: Subzonal insemination
ICSI	: Intracytoplasmic sperm injection
AH	: Assisted hatching
IVM	: <i>In vitro</i> maturation of oocyte
PGD	: Preimplantation genetic diagnosis
Cryopreservation	: embryo/oocyte/ovarian tissue/sperm
Gestational Surrogacy	
<b>SPERM RETRIEVAL TECHNIQUES</b>	
TESE	: Testicular sperm extraction
MESA	: Microsurgical epididymal sperm aspiration
PESA	: Percutaneous epididymal sperm aspiration

laparoscopy by vaginal sonography for ovum retrieval.

### PATIENT SELECTION (IDEAL)

- Age < 35 years
- Presence of ovarian reserve (D-3, serum FSH <10 IU/L).
- Husband—normal seminogram.
- Couple must be screened negative for HIV and hepatitis.
- Normal uterine cavity as evaluated by hysteroscopy/sonohysterography.

### PRINCIPAL STEPS OF AN ART CYCLE

1. Down regulation using GnRH agonist.
2. Controlled ovarian hyperstimulation (COH).
3. Monitoring of follicular growth.
4. Oocyte retrieval.
5. Fertilization *in vitro* (IVF, ICSI, GIFT).
6. Transfer of gametes or embryos.
7. Luteal support with progesterone.



**TABLE 16.13** INDICATIONS OF IVF

- Tubal disease (see p. 658)
- Unexplained infertility
- Endometriosis
- Male factor infertility
- Multiple factors (female and male)
- Failed ovulation induction
- Ovarian failure (Donor oocyte IVF)
- Women with normal ovaries but no functional uterus (Müllerian agenesis)
- Women with genetic risk (IVF and PGD)

### GnRH ANALOGUES FOR DOWN REGULATION

Currently most ART procedures involve the use of GnRH agonists (see p. 525).

- GnRH agonist therapy used for down regulation of pituitary to prevent premature LH surge. It gives higher pregnancy rates.
- GnRH agonist therapy is continued either subcutaneously or intranasally during the gonadotropin treatment phase (see p. 525).
- GnRH antagonists are currently tried along with gonadotropin stimulation to prevent premature LH surge or premature ovulation. Cetrorelix and Ganirelix are the available drugs (see p. 525).

Different schedules for GnRH agonist are available:

- *Long follicular down regulation*—When therapy is started in the follicular phase of previous cycle.
- *Long luteal down regulation* (most commonly used) therapy is begun on 0–21 of the previous cycle. Gonadotropin stimulation is started following the menses (see p. 526).
- *Short 'flare' protocol* - therapy is started in the follicular phase (0-1) along with gonadotropin stimulation. This is also called flare protocol, as gonadotropin can work over the stimulatory effect of GnRH agonist. In short ('flare') protocol, GnRh agonist (leuprolide acetate 1.0 mg daily) is given on cycle day 2–4, continuing thereafter at a reduced dose (0.5 mg daily). Gonadotropin stimulation begins on cycle D<sub>3</sub>. Adjustments of gonadotropin dose is done depending upon the response.

### NATURAL CYCLE

In the first case, Steptoe and Edwards (1978) achieved success from collecting the oocyte from a **natural cycle**, 36

hours after the onset of LH surge. Compared to stimulated IVF cycles, **it has few advantages**. It requires no medication, less cost, minimizes complication (multiple pregnancy, OHSS). **Disadvantages** are: high cycle cancellation rates due to premature LH surge. It has a low success rate. **The other advantages of induction of superovulation are:** improved quality of the oocyte, timing of ovulation can be controlled, suited to the personnel involved and extended to all cases of ovulatory dysfunction (Fig. 16.6).

### CONTROLLED OVARIAN HYPERSTIMULATION (COH)

Gonadotropin stimulation is begun once pituitary down regulation is achieved (serum E<sub>2</sub> < 40 pg/mL and no ovarian follicles are seen > 10 mm on TVS). Exogenous gonadotropins for (uFSH, rFSH, HMG) ovarian stimulation are used. The drug regimens used differ in each center. Following drugs or combination of drugs are commonly used (Table 16.14).

### MONITORING OF FOLLICULAR GROWTH

The follicular growth response is monitored by cervical mucus study, sonographic measurement of the follicles and serum estradiol estimation, commencing on the 8th day of treatment cycle. The endometrial thickness (stripe) ≥ 8–9 mm (trilaminar) is optimum. When two or more follicles are 17–18 mm in diameter and serum E<sub>2</sub> levels > 250 pg/mL/per follicle, 5,000–10,000 IU of hCG (250).µg of recombinant hCG) is given intramuscularly. Oocyte is retrieved 36 hours after the hCG is given. hCG induces oocyte maturation. The individual woman may be a **high responder or a poor responder** (see p. 525). Depending upon the response, management is done (see p. 525).

**TABLE 16.14** OVARIAN STIMULATION REGIMEN

- ◆ Clomiphene citrate (CC)
- ◆ CC + human menopausal gonadotrophin (hMG)
- ◆ CC + pure FSH
- ◆ CC + Recombinant FSH
- ◆ hMG
- ◆ FSH (see Table 16.7)
- ◆ GnRH analogues + hMG or pure FSH

*hCG is administered in each regimen (see Table 16.7)*

## OOCYTE RETRIEVAL

Oocyte retrieval is done aseptically through vaginal route under ultrasound guidance. With the development of vaginal transducers, vaginal needle aspiration is done about 36 hours after hCG administration but before ovulation occurs (Fig. 16.6). Intravenous analgesia and sedation (propofol) is adequate in most of the cases. The oocyte is readily recognizable as a single cell surrounded by a mass of cumulus cells. After recovery, the oocytes are maintained in culture *in vitro* for 4–6 hours.

## FERTILIZATION (IN VITRO)

The sperm used for insemination *in vitro* is prepared by the wash and swim-up or density gradient centrifugation (preferred) technique. Approximately 50,000 to 100,000 capacitated sperm are placed into the culture media containing the oocyte within 4–6 hours of retrieval. The eggs may demonstrate signs of fertilization when examined 16–18 hours after insemination (presence of two pronuclei in the presence of a second polar body). **Sperm density and motility are the two most important criteria for successful IVF.** The semen is collected just prior to ovum retrieval.

## EMBRYO TRANSFER

The fertilized ova at the 6–8 blastomere stage are placed into the uterine cavity close to the fundus about 3 days after fertilization through a fine flexible soft catheter transcervically. **Not more than three embryos are transferred** per cycle to minimize multiple pregnancy.

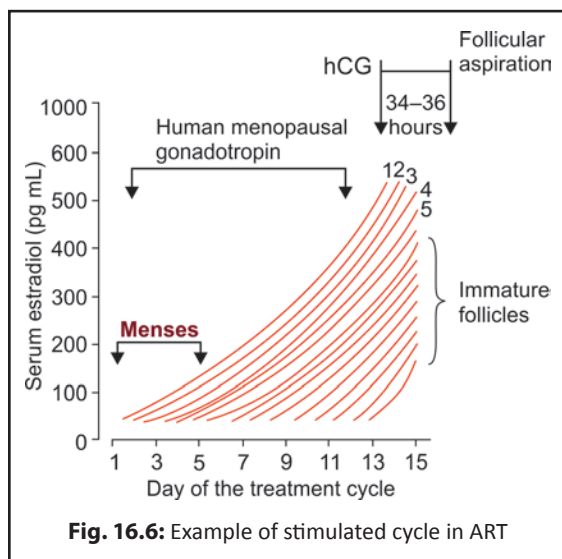


Fig. 16.6: Example of stimulated cycle in ART

The process of transfer should be accurate, atraumatic and aseptic. Small volume transfer using soft catheter under ultrasound guidance gives the best result. Trial transfer is beneficial. The number of embryos to be transferred depends mainly on maternal age and the embryo quality.

Excess oocytes and embryos can be **cryopreserved** for future use. This will reduce the cost of ovulation stimulation as well as the risk of ovarian hyperstimulation (see p.526).

**Luteal phase support** is maintained with progesterone. It is started on the day after oocyte retrieval. hCG is given in supplemental doses (1,500–2,500 IU). Micronized progesterone 200 mg thrice a day oral or as vaginal suppository (preferred) or progesterone in oil injection 50 mg IM daily is continued for about 14 days. By this time diagnosis of pregnancy by estimation of  $\beta$ -hCG (quantitative value) is possible.

**Result:** The overall **live birth rate varies from 32.7 percent per oocyte retrieval.**

There is increased risk of miscarriage (18%), multiple pregnancy (31%), ectopic (0.9%), low birth weight baby and prematurity. The risk of congenital malformation of the baby remains similar to general population.

## PROGNOSTIC FACTORS FOR IVF-ET

1. **Maternal age**—there is age related decline in response to ovarian stimulation, less oocytes, poor oocyte quality, less embryos and implantation rate.
2. **Ovarian reserve**—declines with age (see p.528).
3. **Indication of IVF and past reproductive success.** Women with tubal or ovulatory factors, endometriosis, or unexplained factor—have higher success rate compared to women with poor ovarian reserve.
4. **Presence of hydrosalpinges**—affect the outcome adversely.
5. **Fibroid uterus**—especially the submucous or interstitial variety have adverse outcome.
6. **Smoking**—poor outcome.

## GAMETE INTRAFALLOPIAN TRANSFER (GIFT)

GIFT was first described by Asch and colleagues in 1984. It is a more invasive and expensive procedure than IYF but

the result seems better than IYF. In this procedure, both the sperm and the unfertilized oocytes are transferred into the fallopian tubes. Fertilization is then achieved *in vivo*.

**The prerequisite for GIFT procedure is to have normal uterine tubes.** The indications are the same as that of IYF except the tubal factor. Best result is obtained in unexplained infertility and the result is poor in male factor abnormality.

The superovulation is done as in IYF. Two collected oocytes along with approximately 200,000–500,000 motile sperm for each fallopian tube are placed in a plastic tube container. It is then passed through laparoscope and inserted 4 cm into the distal end of the fallopian tube where the combination is injected.

**Result:** The overall delivered pregnancy rate is as high as 27–30 percent.

### ZYGOTE INTRAFALLOPIAN TRANSFER (ZIFT)

Zygote intrafallopian transfer was first described by Devroey *et al.* (1986).

The placement of the zygote (following one day of *in vitro* fertilization) into the fallopian tube can be done either through the abdominal ostium by laparoscope or through the uterine ostium under ultrasonic guidance.

This technique is a suitable alternative of GIFT when defect lies in the male factor or in cases of failed GIFT. **Results** (29–30%) are similar to that of IYF. GIFT or ZIFT is avoided when tubal factors for infertility are present.

The risk of ectopic pregnancy is high for GIFT and ZIFT compared to IYF.

## MICROMANIPULATION

### INTRACYTOPLASMIC SPERM INJECTION (ICSI)

ICSI was first described by van Steirteghem and colleagues in Belgium (1992).

#### Indications

- Severe oligospermia (5 million sperm/mL)
- Asthenospermia, teratospermia
- Presence of sperm antibodies
- Obstruction of efferent duct system (male)
- Congenital absence of vas (bilateral)
- Failure of fertilization in IVF
- Fertilization of cryopreserved oocytes (with hardened zona pellucida)
- Unexplained infertility.

Sperm is recovered from the ejaculate. Otherwise sperm is retrieved by TESE (testicular sperm extraction) or by MESA (microsurgical epididymal sperm aspiration) procedures.

**Technique:** One single spermatozoon or even a spermatid is injected directly into the cytoplasm of an oocyte by micropuncture of the zona pellucida. This procedure is carried out under a high quality inverted operating microscope. The oocyte is stabilized at 6 or 12 O'clock position and entered at the 3 O'clock position. The injecting pipette pierces the zona and oolemma and the sperm is injected directly into the ooplasm (Fig. 16.7).

ICSI is found to be very effective compared to other micromanipulation methods like subzonal insemination (SUZI). ICSI is very effective to reduce the need of AID.

**Results:** Fertilization rate is about 60–70 percent. Pregnancy rate is 20–40 percent per embryo transfer.

### EMBRYO OR OOCYTE DONATION

Ovum donation and IVF can help women with successful pregnancy. The essential requirements for successful outcome are: (i) successful ovum donation and IVF. (ii) Embryo-endometrial synchronization and (iii) Exogenous hormonal support until luteal-placental shift (see p. 257).

#### Indications

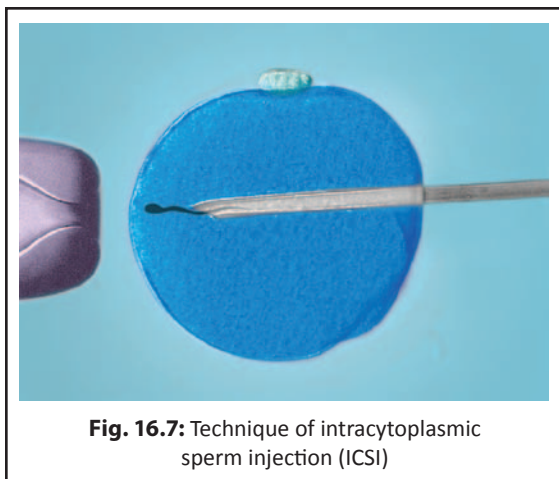
- Women with premature ovarian failure.
- Women with removed ovaries.
- Older women (poor oocyte quality).
- Failure to respond with superovulation regimen (poor ovarian reserve, see p. 528).
- Women with repeated failure of ART cycles.
- Genetic disease.

*The oocytes are collected from:*

- Sister or a friend (age between 21 and 34 years).
- Those for IVF candidates, excess oocytes following retrieval and cryopreservation (see above).
- One undergoing laparoscopic sterilization (with financial compensation).
- The oocyte donor like the semen donor must be screened for infection and genetic diseases (see p. 250).

Successful implantation needs a perfect coordination of embryo and the endometrium. Estrogen therapy (in the





**Fig. 16.7:** Technique of intracytoplasmic sperm injection (ICSI)

recipient) is started at the same time when the donor gets cycle stimulation. Progesterone treatment in the recipient generally begins on the day the donor undergoes ovum retrieval. Generally D3 embryos are transferred on the fourth day of progesterone therapy.

**Luteal support:** As the recipient has no corpus luteum, exogenous luteal support is needed. Exogenous estrogen and progesterone treatment should therefore be continued until 10 weeks of gestation. Oocytes and embryos can be cryopreserved (at  $-196^{\circ}$  under liquid nitrogen) for restoration of fertility in future. Survival of cryopreserved embryo is more than that of oocytes.

**Results:** Livebirth rate is approximately 55 percent.

### GESTATIONAL SURROGACY

A woman without a functional uterus (developmental or hysterectomy), can have her genetic offspring with the help of ART. Embryos are transferred to the uterus of another woman who is willing to carry the pregnancy on behalf of the infertile couple.

### CRYOPRESERVATION OF OVARIAN TISSUE

Restoration of reproductive function of a woman undergoing chemotherapy or radiotherapy is possible these days with the help of cryobiology. Cryopreservation of ovarian tissue or autotransplantation may allow natural pregnancy later on. With this method, ovulation using exogenous gonadotropins can be achieved.

### OOCYTE CRYOPRESERVATION

By freezing is an alternative method. Verification, using high concentration of cryoprotectant can solidify cells

without ice formation. Human pregnancies and deliveries from verified mature oocytes have been recorded.

### PREIMPLANTATION GENETIC DIAGNOSIS (PGD)

Can be performed on polar bodies removed from oocytes before fertilization. It can be done by blastomere biopsy. Genetic screening can avoid transferring embryos with aneuploidy and autosomal recessive or autosomal dominant gene mutation.

### HEALTH HAZARDS OF ART

- **Birth defects:** Most of the ART procedures are not associated with any increased risk of fetal congenital malformations or birth defects. ICSI is often done due to male factors for infertility and it eliminates the natural process of sperm selection. It is not yet certain whether ICSI is associated with increased chromosomal abnormalities of the off-spring.
- **Increased** miscarriage, multiple pregnancy and ectopic and heterotrophic pregnancy have been observed.
- **Perinatal mortality** and morbidity are high.
- **Ovarian hyperstimulation syndrome** (see p. 525) though rare but is a known health risk.
- **Fertility drugs and cancer**—no association have been found between ovulation induction drugs and ovarian cancer.
- **Psychological stress** and anxiety of the couple are severe. It is especially so when there is failure in the treatment or with a pregnancy loss.

### PROGNOSIS OF INFERTILITY

The pregnancy rate within 2 years after the start of investigation, ranges between 30–40 percent. The rate is however, increased to about 50–60 percent, if AID cases are included.

**Adoption:** In spite of excellent advances in the field of infertility management, expectations are not always fulfilled. Couple must understand the infertility factors, cost and risk of management. End point of management must be realistically understood. Adoption is an alternative for many couples.

**KEY POINTS**

- ▶ Infertility is defined as a failure to conceive within 1 year of regular unprotected coitus.
- ▶ 10 percent remain infertile by the end of 2nd year. The incidence increases further after the age of 30 years.
- ▶ In fully lactating women, pregnancy is unlikely up to 10 weeks postpartum.
- ▶ Male factor is responsible in 30–40 percent, the female in 40–50 percent, both in 10 percent and unexplained in 10 percent.
- ▶ Common causes of male infertility include defective spermatogenesis, obstruction of efferent duct, failure to deposit sperm high in vagina and error in seminal fluid (Table 16.1).
- ▶ Important causes of female infertility are tubal factor (25–35%), ovulatory factor (20–25%) and endometriosis (0–10%) (Scheme 1).
- ▶ Ovulatory dysfunction is likely to be linked with disturbed hypothalamo-pituitary-ovarian axis either primary or secondary from thyroid or adrenal dysfunction.
- ▶ Luteal phase defect is observed with older women, drug induced ovulation, elevated prolactin, patients with repeated pregnancy wastage, pelvic endometriosis, DUB and subclinical hypothyroidism.
- ▶ Serum progesterone more than 10 ng/mL on 8th postovulatory day indicates adequate luteal function.
- ▶ Luteinized unruptured follicle is often associated with pelvic endometriosis or with hyperprolactinemia.
- ▶ Tubal factors are related to tubal infection, peritubal adhesions or endometriosis. The commonest peritoneal factor is endometriosis.
- ▶ Investigation of the infertile couple should be started after 1 year. The initial investigations of an infertile couple include: semen analysis (Male factor), hysterosalpingography (tubal factor), BBT and/or serum progesterone (evidence of ovulation) (Scheme 3).
- ▶ BBT increases when circulating level of progesterone is increased following ovulation.
- ▶ Diagnosis of ovulation is from indirect, direct and conclusive evidences (see Table 16.4).
- ▶ Subnuclear vacuolation of the endometrial glandular epithelium is the earliest evidence of ovulation (36–48 hours).
- ▶ A persistent rise in BBT and/or a serum progesterone more than 5 ng/mL is the presumptive evidence of ovulation. Sonographic evidences of ovulation are collapsed follicle and fluid in the pouch of Douglas. Pregnancy is the surest evidence of ovulation.
- ▶ A thorough investigation following an abnormal semen analysis, is needed to find out the specific cause of male infertility (Scheme 2).
- ▶ Tubal factor is assessed by HSG and laparoscopy; the two are complimentary. Sonohysterosalpingography has got no radiation exposure. Falloposcopy and salpingoscopy are used to study the tubal mucosa (Table 16.6).
- ▶ Postcoital test (PCT) is done in late proliferative phase. The examination is done 8–12 hours after coitus. The presence of active motile sperm numbering at least 10 per HPF is satisfactory. Routine PCT is not recommended. Presence of antisperm antibodies may not be the cause of infertility.
- ▶ Of all the etiological factors, greatest success is obtained following treatment of anovulation.
- ▶ For induction of ovulation, the commonly used drugs are clomiphene citrate, hMG, FSH, hCG, GnRH analogues, bromocriptine (see Table 16.7).

*Contd...*

Contd...

The suitable patients for clomiphene citrate (CC) are—normogonadotropic-normoprolactinemic, PCOS with amenorrhea or hypothalamic amenorrhea (see p. 243).

Following CC therapy, incidence of multiple gestation is about 5 percent and all being twins. The incidence of miscarriage, ectopic pregnancy or congenital malformation is not increased.

Women with PCOS who do not ovulate with CC, insulin sensitizers (metformin) and/or LOD (p. 247) is effective in inducing ovulation.

- Gonadotropin therapy is indicated in cases with hypogonadotropic-hypogonadism and clomiphene failure (see p. 245).
- GnRH is used in a pulsatile manner for cases with hypothalamic amenorrhea and hypogonadotropic hypogonadism.
- GnRH analogues are used in patients refractory to gonadotropins, with elevated LH, with normal gonadotropins or in cases with premature LH surge (see p. 246).

Gonadotropins and GnRH analogues and hCG are mostly used in ART with careful monitoring.

- Hyperprolactinemia and anovulation (5–10%) are due to inhibition of gonadotropin secretion. Serum FSH, estradiol levels are low. Women suffer from oligomenorrhea or amenorrhea. Bromocriptine is indicated in cases of hyperprolactinemia with or without galactorrhea.
- Corpus luteum insufficiency can be treated by progesterone as vaginal suppositories or by hCG. LPD is currently thought to be a normal biologic variant and not a true cause of infertility.
- Unruptured luteinized follicle is treated by intramuscular injection of hCG 5000–10,000 IU or ovulation inducing drugs, or bromocriptine if associated with hyperprolactinemia.
- Tuboplasty is the surgical procedure performed to restore the anatomy and physiology of the tube (Table 16.9). Endoscopic surgery gives the best result. Prognosis for fertility depends upon the extent and the site of damage to the tube. Tubal reconstructive surgery may be considered for mild proximal tubal block. For any complicated tubal occlusive disease, IVF is the best therapy (see p. 251).
- Proximal tubal obstruction is usually treated by cannulation through tubes with catheters under hysteroscopic visualization. No tubal surgery should be attempted in women with pelvic tuberculosis. IVF may be considered once endometrium is free from the disease (see p. 247).

Overall result in terms of pregnancy following tuboplasty ranges between 15-60 percent. The pregnancy rate after salpingolysis and fimbrioplasty is about 65 percent. The result is best in reversal of tubal sterilisation by tubo-tubal anastomosis (see p. 247).

- Any form of therapy for minimal endometriosis does not improve fertility status. Unexplained infertility is observed in about 10-15 percent cases. Women with mild endometriosis can be treated with COH (p. 239) and IUI to improve fertility.
- Assisted reproductive technology (ART) includes different methods (see Table 16.12). These are expensive and need sophisticated laboratory facilities (p. 251).
- The best results of IUI are obtained in the treatment of cervical factor and unexplained infertility (Table 16.10) and in stimulated cycle (controlled ovarian hyperstimulation). Overall pregnancy rate ranges between 20-40 percent.
- Controlled ovarian hyperstimulation (COH) and IUI (Table 16.11) are the options for women with unexplained infertility and for women whose male partner (husband) suffers from oligospermia.

Contd...

Contd...

- ▶ Donor insemination (AID) should be performed with frozen sperm, stored at least for 6 months. The donor should be retested negative for antibodies to HIV during the time of insemination. This is because antibodies to HIV may take several months to develop after the infection (see p. 250).
- ▶ IVF-ET (Steptoe and Edwards–1978)—overall pregnancy rate varies from 20 to 30 per oocyte retrieval. Take home baby rate is about 15-20 percent per procedure (p. 251).
- ▶ GIFT (Asch—1984) procedure needs normal fallopian tubes. In some centers the success rate of GIFT and IVF-ET is the same (p. 253).
- ▶ ICSI (Van Steirteghem – 1992) is an effective method for male infertility (severe oligospermia or sperm dysfunction). It reduces the need of AID (p. 254).
- ▶ Pregnancy following donor oocyte or embryo is the option for women with ovarian failure, removed ovaries or with genetic disease (p. 254).
- ▶ The pregnancy rate within 2 years after the start of investigations for infertility is 30-40 percent. The rate is however increased to 50-60 percent, if AID cases are included. When the couple fails to conceive after 2 years of therapy, the chance of conception is remote.
- ▶ Health hazards of ART include psychological stress of the couple, increased number of pregnancy loss, multiple pregnancy and ectopic pregnancy. Risk of fetal congenital malformations is not increased. Ovarian hyperstimulation syndrome is rare but a known health hazard (p. 255).
- ▶ Ovarian hyperstimulation syndrome (see p. 529) is a complication of ovulation induction. Basic pathology is increased capillary permeability (VEGF) leading to ascites, hypovolemia, oliguria and electrolyte imbalance. Management is conservative. Abdominal paracentesis, to relieve respiratory distress and human albumin (IV), to correct hypovolemia may be needed.
- ▶ According to WHO, Ovulatory disorders (p. 243) are grouped into:
  - Group I: **Hypothalamic-Pituitary failure:** women in this group have hypogonadotrophic hypogonadism, low gonadotrophin and oestrogen level, normal prolactin and negative progesterone challenge test. Included in this group are: stress related amenorrhea, Kallmann's syndrome, anorexia nervosa (p. 464). These women are treated with hMG or GnRH.
  - Group II: **Hypothalamic-Pituitary Dysfunction**—Women are normogonadotrophic, norm oestrogenic, anovulatory and oligomenorrhoeic. Women with PCOS are in this group (p. 459). These women are treated with clomiphene citrate.
  - Group III: **Ovarian failure**—Women are hypergonadotrophic and hypogonadal with low estrogen level (p. 463). These women are treated with ovum donation.

# Benign Lesions of the Vulva and Vagina

## VULVAL EPITHELIAL DISORDERS

### TERMINOLOGY, DEFINITION AND TYPES

Non-neoplastic epithelial disorder of vulval skin and mucosa have been classified according to International Society for the Study of Vulvovaginal Diseases (ISSVD). Broadly these include lichenoid, acanthotic (squamous hyperplasia) pattern and other dermatoses. Lesions having neoplastic potentials as changed. VIN (see p. 318) lesions have been excluded from the classification. The classification of ‘non-neoplastic epithelial disorders of vulva, skin and mucosa’ has been presented below (Table 17.1).

**ETIOLOGY:** Multiple factors such as traumatic (scratching), autoimmune allergic (atopic), irritation, nutritional (deficiency of folic acid, vitamin B<sub>12</sub>, riboflavine, achlorhydria, etc.), infection (fungus), metabolic or systemic (hepatic, hematological), etc. are implicated. **Autoimmune disorders** like thyroid disease, pernicious anemia and diabetes are often associated. About 40 percent women are having or going to develop an autoimmune condition. **Patient’s personal or family history of atopic conditions** (asthma, eczema, hay fever) should be taken. **Drugs:** β-blockers, angiotensin-converting enzyme (ACE) inhibitors, may be associated. Common allergens are: cosmetics, synthetic underwears and fragrances.

### LICHEN SCLEROSUS

The epithelium is metabolically active. It usually occurs following menopause; may occur even in childhood but in that case, it resolves after menarche.

**Distribution of lesion:** The entire vulva is involved. Lesion encircles the vestibule. It involves clitoris,

TABLE 17.1

### CLASSIFICATION OF VULVAL DERMATOSES (ISSVD-2006)

- |  |   |
|--|---|
| <ul style="list-style-type: none"> <li>■ <b>A. Spongiotic pattern</b> <ul style="list-style-type: none"> <li>• Atopic dermatitis</li> <li>• Contact dermatitis (allergic and irritant)</li> </ul> </li> <li>■ <b>B. Acanthotic pattern</b> <ul style="list-style-type: none"> <li>• Psoriasis</li> <li>• Lichen simplex chronicus</li> </ul> </li> <li>■ <b>C. Lichenoid pattern</b> <ul style="list-style-type: none"> <li>• Lichen sclerosus</li> <li>• Lichen planus</li> </ul> </li> <li>■ <b>D. Granulomatous pattern</b> <ul style="list-style-type: none"> <li>• Crohn’s disease</li> </ul> </li> </ul> | <ul style="list-style-type: none"> <li>■ <b>E. Vasculopathic pattern</b> <ul style="list-style-type: none"> <li>• Aphthous ulcers</li> <li>• Behçet’s disease</li> <li>• Plasma cell vulvitis</li> </ul> </li> <li>■ <b>F. Others</b> <ul style="list-style-type: none"> <li>• Dermal sclerosis pattern</li> <li>• Vesicubullous pattern</li> <li>• Acantholytic pattern</li> </ul> </li> </ul> |
|--|---|

labia minora, inner aspects of labia major and the skin around the anus. It is usually bilateral and symmetrical in a figure of eight distribution. It does not involve the vestibule or extend into the vagina or anal canal. It may even extend to the perineum and beyond the labiocrural folds to the thighs. It may also affect other parts of the body (trunk and limbs—18%). The distribution of lesion is thus more wider.

**Histology:** The epithelium is thin with epidermal atrophy. At times, there is hyperkeratosis, parakeratosis, acanthosis and elongation of rete ridges with evidence of collagen hyalinization. Fibroblasts are absent. There is presence of inflammatory cells including lymphocytes and plasma cells (Fig. 17.2).

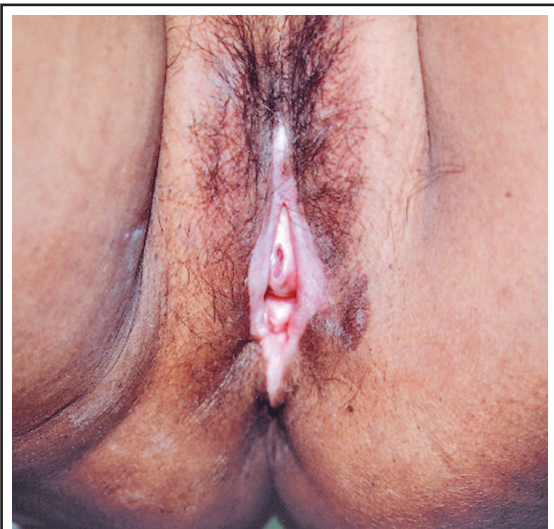
**Clinical features:** Pruritus is more than soreness. There is dyspareunia (excluding childhood), sleeplessness and dysuria. Dyspareunia is due to stenosis of the vulval outlet (Fig. 17.1). The skin is thin and looks white. Inflammatory adhesions of the labia minora and fusion may cause difficulty with micturition and even retention of urine. There may be narrowing of vaginal introitus. Pruritus is related to active inflammation with erythema. Scratching results in subepithelial hemorrhages (ecchymosis).

**Diagnosis:** The diagnosis should be confirmed by biopsy having characteristic changes. Biopsy can be taken with a punch biopsy forceps (keyes) under local anesthesia as an outpatient procedure. Monsel's solution (ferric subsulfate) is applied to control bleeding.

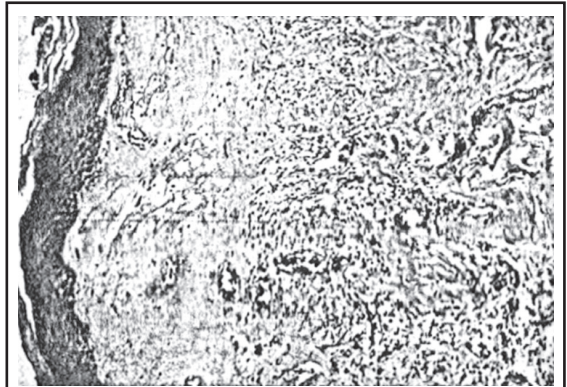
The **risk of malignancy is about 1-4 percent**. Women, nonresponsive to topical steroids or having hyperkeratotic lesion on biopsy, needs excision. This chronic disease often has the episodes of spontaneous remissions and exacerbations.

**Lichen planus** may affect the skin anywhere on the body. It affects the mucosal surfaces (oral mucosa) and presents with polygenal flat-topped purpuric plaques. The lesion may be erosive and presents more with pain than pruritus.

**Lichen simplex chronicus** presents with severe intractable pruritus, especially at night. Nonspecified



**Fig. 17.1:** Lichen sclerosus



**Fig. 17.2:** Histologic picture of Lichen sclerosus showing atrophic and flat epithelium with loss of rete ridges. There is presence of hyalinized collagen tissue and chronic inflammatory cells.

inflammation involves the labia majora, mons pubis and the inner thighs. There may be erythema, swelling and lichenification. Symptoms may be exacerbated by chemicals or low body iron stores. Main stay of treatment is to avoid any irritants, antihistaminics, ultrapotent topical steroids (clobetasol) is helpful to break the itch-scratch cycle.

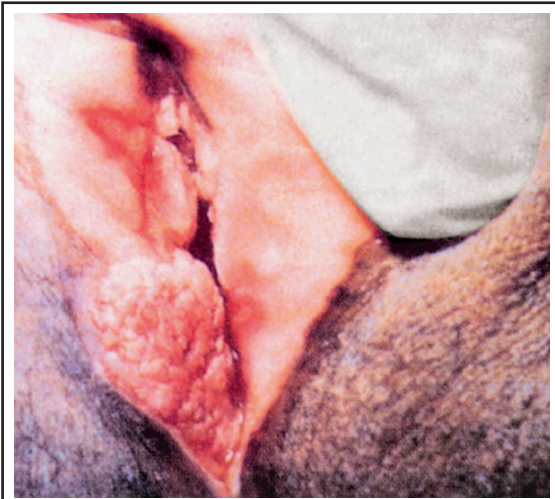**Investigations** are done to look for thyroid dysfunction, diabetes, STIs, serum ferritin (as 20 percent women suffer iron deficiency anemia), autoimmune candidates (asthma, eczema) and skin biopsy (cases with suspicion of VIN/cancer).

**Extramammary Paget's disease** of the vulva is a rare condition, seen in postmenopausal women. It presents with pruritus. On examination, the lesion appears florid eczematous with erythema and excoriation. It can be associated with underlying adenocarcinoma. The gastrointestinal, urinary tract and the breasts should be checked.

Surgical excision is recommended to exclude adenocarcinoma of a skin appendage. Photodynamic therapy and topical imiquimod have been used with some success. Recurrence is common.

**Vulval Intraepithelial Neoplasia (VIN)**—presents as vulval skin disorders (see p. 318).

**Plasma cell (zoon's) vulvitis** is a rare chronic inflammatory condition of the vulva. It presents with symptoms of pruritus, burning, dyspareunia and dysuria. It is commonly present in postmenopausal women. Histologically, it is characterized by plasma



**Fig. 17.3:** Vulval dystrophy associated with malignancy

cell infiltration, vessel dilatation and hemosiderin deposition. It is an autoimmune disorder.

**Topical ultra-potent steroids** (clobetasol) are used for the treatment.

**Vulval Crohn's disease:** Crohn's disease affecting the intestine may involve the vulva in late stage of the disease in about 25% of cases. The vulva is swollen, edematous with granulomas, abscesses, draining sinuses and ulceration. Surgery may cause sinus and fistula formation and tissue breakdown. Therefore, it should be avoided.

**Treatment** includes metronidazole and oral immunomodulations.

**Psoriasis** is a common and generalized skin disease of multifactorial origin. Vulval skin is affected in about 20 percent of these affected women. The disease is chronic and has phases remissions and exacerbations.

**Skin changes are:** Silvery scale appearance and bleeding on gentle scraping. Vulval psoriasis may resemble candidiasis. Psoriasis usually does not involve the vaginal mucosa.

### RELATION WITH MALIGNANCY

About 50 percent of all invasive carcinomas of the vulva arise in an area of chronic vulval epithelial disorder. **The malignant potential of vulval intra-epithelial neoplastic (VIN) disorders is about 2–4 percent** and that for non-neoplastic epithelial

disorders is very low. The chance is more with hyperplastic variety with cellular atypia (Fig. 17.3).

### DIAGNOSIS OF VULVAL EPITHELIAL DISORDERS

Skin biopsy is not needed when a diagnosis can be made on clinical examination. **Biopsy is required** if the woman fails to respond to treatment or there is clinical suspicion of VIN or cancer (see p. 318).

**The sites for biopsy are** from the margins of cracks and fissures and the sky blue areas left behind after applying 1 percent aqueous toluidine blue to the vulva and washing it off after 1 minute with 1 percent acetic acid. Women suspected to have lichen sclerosus or lichen planus should be investigated for other autoimmune conditions if there are clinical symptoms or signs.

### TREATMENT OF VULVAL EPITHELIAL DISORDERS

#### General

- ♦ Patients should avoid the use of deodorants, spermicides, depilatory creams and perfumes (allergic or irritant dermatitis).
- ♦ A non-irritant soap should be used in the area and dried carefully without much rubbing.
- ♦ The patient should use either cotton underwear or nothing at all.
- ♦ Histopathological diagnosis has to be made by biopsy prior to institution of any therapy.

#### Individual protocol

##### Lichen sclerosus and lichen planus

Ultrapotent topical steroids clobetasol is very effective. Local application has to be continued nightly daily for 1 month followed by alternate night for the second month and thereafter twice weekly. Usually, there is improvement following topical use of clobetasol for a period of 3 months. Failure of improvement needs exclusion of coexisting fungal infection, use of irritant cream or carcinoma. **Lesions resistant to corticosteroids need treatment with tacrolimus and pimecrolimus. There are immunosuppressants and calcineurin inhibitors.** Surgery and CO<sub>2</sub> laser vaporization may be needed to release adhesion for the treatment of urinary retention or narrow vaginal introitus.

Use of cryotherapy or laser ablation is rarely needed. Release of labial or preputial adhesions may be needed.

### Acanthotic Pattern Squamous cell hyperplasia

- ◆ Without atypia—Potent fluorinated corticosteroid cream, clobetasol propionate 0.05 percent have been recommended.
- ◆ With atypia—Considering the risk involved in development of malignancy, local vulvectomy is justified. There is a chance of recurrence.

Local therapy with antimetabolic agent such as fluorouracil, which inhibit an enzyme essential for pyrimidine synthesis is helpful when applied as 5 percent cream twice daily for a minimum period of 6–8 weeks.

**Psoriasis:** Emollients, topical steroids and calcipotriene are used to control the symptoms.

### WHITE LESIONS OF THE VULVA

The melanocytes lose their ability to manufacture melanin resulting in depigmentation and subsequent white lesions. **The lesions include:**

- Lichen sclerosus
- Squamous cell hyperplasia
- Vitiligo
- Albinism—enzyme deficiency preventing normal formation of melanin
- Leukoderma
- Intertrigo.

**Red lesions of the vulva** are due to infection (candida), allergy, dermatitis and melanosis.

## VULVAL ULCERS

Vulval ulcers are predominantly due to sexually transmitted diseases. Rarely, it may be due to non-

specific causes. Malignant ulcer is also rare. The various etiological factors related to vulval ulcers are given in the Table 17.2.

All are described in appropriate chapters (see p. 147, 318, 332). **Other systemic diseases with vulvar manifestation** are mentioned below (see Table 17.2).

**Crohn's disease:** It affects primarily the intestine and may involve the vulva in late stage of the disease in about 25 percent of cases. The ulcer looks granulomatous like knife cuts in the skin.

### BEHÇET'S DISEASE

This is a rare chronic inflammatory disease characterized by recurrent oral and genital ulcers (cervix, vulva or vagina) with ocular ulcer (anterior uveitis). It may be the manifestation of an underlying autoimmune process. Monoarticular arthritis may also be associated. The vulval ulceration may be extensive and leaving behind dense scar after healing.

There is no specific treatment. Topical and systemic corticosteroids are used for relief of the symptoms. Systemic immunosuppressants are found useful.

**LIPSCHUTZ ULCER:** The lesion affects mainly the labia minora and introitus. In acute state, there may be constitutional upset with lymphadenopathy. The causative agent may be Epstein-Barr virus. Treatment is with antiseptic lotions and ointment.

**VULVAL ULCER: Leukemia**—Rarely may cause nodular infiltration and ulceration of the vulva.

**Dermatological disorders:** Disseminated lupus erythematosus may cause recurrent ulcerations of the vulva and mucous membrane of the mouth and vagina.

**TABLE 17.2** ULCERS OF THE VULVA

STD related (see chapter 11)	Idiopathic	Tuberculosis	Malignancy (see chapter 23)	Systemic disease related or dermatoses
<ul style="list-style-type: none"> <li>• Syphilis</li> </ul>		Tubercular	<b>Primary</b> <ul style="list-style-type: none"> <li>• Squamous cell carcinoma</li> <li>• Malignant melanoma</li> <li>• Basal cell carcinoma</li> </ul> <b>Secondary</b> <ul style="list-style-type: none"> <li>• Leukemia</li> <li>• Choriocarcinoma (p.362)</li> </ul>	<ul style="list-style-type: none"> <li>• Lupus erythematosus</li> </ul>
<ul style="list-style-type: none"> <li>• Herpes genitalis</li> <li>• Chancroid</li> </ul>	Behçet's disease			<ul style="list-style-type: none"> <li>• Crohn's disease</li> <li>• Lichen planus</li> </ul>
<ul style="list-style-type: none"> <li>• Granuloma inguinale</li> </ul>	Aphthous ulcers			<ul style="list-style-type: none"> <li>• Lichen sclerosus</li> </ul>
<ul style="list-style-type: none"> <li>• Lymphogranuloma venereum</li> </ul>	Lipschutz ulcers			<ul style="list-style-type: none"> <li>• Sjogren's syndrome</li> </ul>



### VULVAL MANIFESTATIONS OF SYSTEMIC DISEASES

1. **Dermatologic disorders:** (i) Contact dermatitis—due to agents that may be locally irritant. (ii) Psoriasis. (iii) Ulceration due to disseminated lupus erythematosus.
2. **Vulval ulceration or deposits** due to leukemia.
3. **Acanthosis nigricans**—hyperpigmented lesion of the vulva. It may be associated with glucose intolerance (insulin resistance), chronic anovulation and androgen excess (see p. 459).
4. **Chronic vulvovaginal candidiasis**—Due to diabetes, obesity and antibiotic use. Correction of basic pathology and prolonged topical antifungal therapy clears the infection.
5. **Behçet's syndrome** (see above).
6. **Sjogren's syndrome:** Patients present with vaginal dryness and pain associated with ocular or oral dryness. There may be arthralgia, myalgia (presence of auto-antibodies).

### MISCELLANEOUS SWELLINGS

#### VULVAL CYSTS

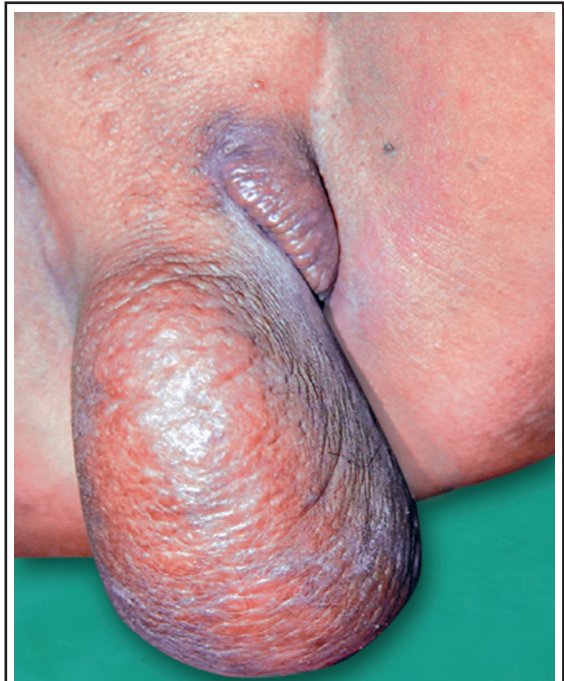**Bartholin's cyst**—See p. 162.

**Sebaceous cyst**—These are usually multiple and are formed by accumulation of the sebaceous material due to occlusion of the ducts. These are located in the labia majora. If infected, treatment is done by antibiotics and surgical drainage.

**Cyst of the canal of Nuck**—Part of the processus vaginalis, which accompanied the round ligament and got obliterated prior to birth may persist to form a cyst. It invariably occupies the anterior part of the labium majus.

#### INGUINOLABIAL HERNIA

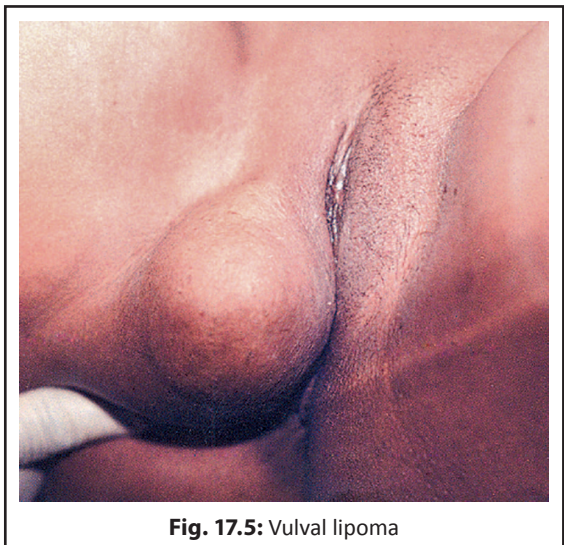When the entire processus vaginalis remains patent, there may be herniation of the abdominal contents along the tract. The hernia may be limited to the inguinal canal or may extend up to the anterior part of the labium majus. The contents of the sac may be intestine or omentum. The swelling is reducible and



**Fig. 17.4:** Vulval fibroma

[By courtesy: Dr (Ms) C Das, Professor, Department of Obst-gyne, NRS Medical College, Kolkata, India]

impulse on straining can be elicited. **One should be conscious of the entity** as casual surgical incision on labial swelling may cause inadvertent injury to the gut.



**Fig. 17.5:** Vulval lipoma

### VULVAL VARICOSITIES

These are met predominantly during pregnancy and subside following delivery. Sometimes, they may produce intolerable aching on standing. Support pads and tights or T-bandage may be tried to relieve the symptoms. If these fails, treatment by injecting sclerosing fluids or high ligation of the long saphenous vein may be of help.

### ELEPHANTIASIS VULVAE

It is mainly due to consequence of lymphatic obstruction by microfilaria (filariasis). Plastic surgery may be tried to restore the normal anatomy along with antifilarial treatment. There is a chance of recurrence.

## BENIGN TUMORS OF THE VULVA

▲ **Fibroma, lipoma, neurofibroma:** These are all benign tumors of varying sizes. Fibroma is the most common benign solid tumor of the vulva. It arises from deeper connective tissues of the labia majora (dermatofibroma). Vulval fibroma grow slowly. It may be small but malignant change is very low. Surgical removal is necessary as they produce discomfort (Figs 17.4 and 17.5).

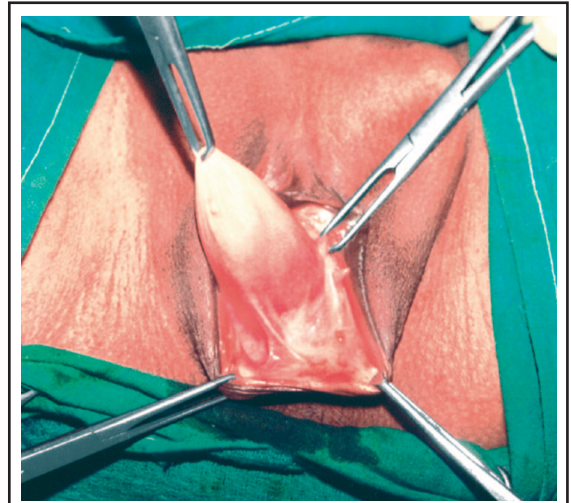
▲ **Hydradenoma:** Hydradenoma arises from the sweat gland in the vulva, usually located in the anterior part of the labia majora (38%). It rarely exceeds 1 cm. It is a benign lesion but its reddish look and complex adenomatous pattern on histology may be confused with adenocarcinoma. Simple excision and biopsy is adequate.

### VULVAL ENDOMETRIOSIS

Vulval endometriosis is usually found at the site of old obstetric laceration, episiotomy or area of excised Bartholin's duct cyst. It may appear as a swelling near the insertion of the round ligaments in the anterior part of the labia majora. It may be associated with pelvic endometriosis. Its presence is limited only during reproductive period and becomes enlarged and tender during menstruation. Treatment is surgical excision and *confirmation by biopsy* (endometrial glands and stroma with hemosiderin laden macrophages).

## VAGINAL WALL CYSTS

Vaginal cyst is rare as there is no gland in the mucous coat. Small cysts may remain unnoticed. The common



**Fig. 17.6:** Gartner's duct cyst

cysts that are found include Gartner's duct cyst and epithelial inclusion cyst.

### GARTNER'S CYST

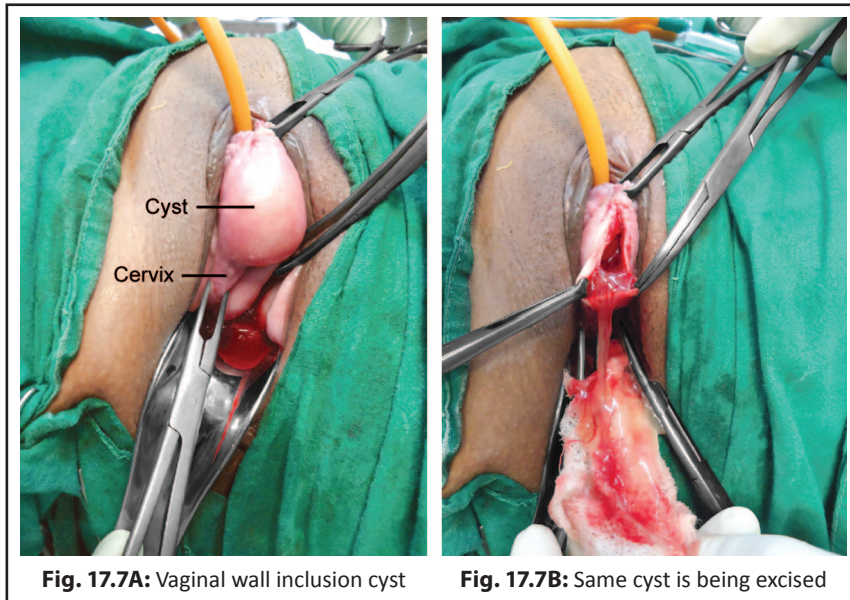
**The Gartner's duct cyst** is usually situated in the anterolateral wall of the vagina. The epithelium is low columnar and secretes mucinous material which is pentup to form the cyst. The treatment is by surgical excision (Fig. 17.6).

**INCLUSION CYST:** Common vulvar cysts are epidermal inclusion cysts or sebaceous cysts. Usually, they are located beneath the epidermis in the anterior half of labia majora. Alternative histogenesis is embryonic remnants or occlusion of pilosebaceous ducts of sweat glands.

**The vaginal epithelial inclusion cysts** arise from the epithelium buried under the mucosa during healing from a traumatic injury following childbirth or surgery. They are usually located in the lower-third of the vagina on the posterior or posterolateral wall. The lining epithelium is stratified squamous. The content is a thick cheesy substance. The treatment in symptomatic cases is by surgical excision (Figs 17.7A and B).

## VULVAL PAIN SYNDROME

Vulvar pain sensation may be burning, stinging or irritation. It may be due to several reasons:



**Fig. 17.7A:** Vaginal wall inclusion cyst

**Fig. 17.7B:** Same cyst is being excised

- ◆ Aphthous ulcer
- ◆ Vulval dermatoses
- ◆ Herpes genitalis
- ◆ Pudendal or genitofemoral nerve neuralgia
- ◆ Vulvodynia (burning vulva syndrome)
- ◆ Vulval vestibulitis syndrome
- ◆ Referred pain from urethral or vagina
- ◆ Psychological.

**Vulvodynia** is a severely painful socially debilitating disease where infection, invasive disease or inflammation have been excluded. It is **characterized by burning sensation over the vulva (burning vulva syndrome)**. It is often seen in perimenopausal or postmenopausal women. Exact etiology is not known. Clinical examination does not reveal any abnormality in many cases. **Treatment is unsatisfactory.** Tricyclic antidepressant (amitriptyline) is found helpful. A dose

of 60 mg/day for 3–6 months is given. Gabapentin is also beneficial. Psychosexual counseling and behavior therapy are needed for some cases. Surgery is contraindicated.

**Vulval vestibulitis syndrome** is a condition of hyperesthesia (allodynia), pain without any painful stimuli. It is characterized by pain around the ducts of Bartholin gland and the introitus. There may be superficial dyspareunia and vestibular tenderness on touch. **Treatment:** Treatment needs sympathetic approach. Considering the various, etiologies, numerous treatment options are available. Improvement of vulvar local hygiene, control of infective agents and allergens, diet modification (low oxalate), psychological (**tricyclic antidepressants**), **gabapentin**, **biofeedback**, behavioral treatment and even surgery (vestibuloplasty, laser vaporization) have been tried. Treatment results are often unsatisfactory.

**KEY POINTS**

- ▶ Lichen sclerosus usually occurs following menopause. The lesion can extend beyond the labiocrural folds to the thighs. Pruritus is more than soreness. The risk of malignancy is 1–4 percent.
- ▶ Hyperplastic dystrophy is usually confined to inner aspects of labia majora, the labia minora and the introitus. Pruritus is the chief complaint.

Women with lichen sclerosus or planus should be investigated for autoimmune conditions (p. 259)

About 50 percent of all invasive carcinomas of the vulva arise in an area of chronic vulval epithelial disorder. Only 2–4 percent of VIN may develop malignancy. Multiple biopsies are to be taken from the sky blue areas left behind after applying 1 percent aqueous toluidine blue and washed off with 1 percent acetic acid. Cases with atypia have got increased chance of malignancy. Considering the risk, local vulvectomy is justified especially with atypia (see p. 319).

- ▶ Vulval cyst may be—Bartholin's cyst, sebaceous cyst or cyst of canal of Nuck.
- ▶ Vulval ulcers are predominantly STI related but other pathology may be there (Table 17.2)
- ▶ Vulvodynia is a painful condition of the vulva of unknown etiology. Psychosexual counseling, behavioral therapy, tricyclic antidepressants (amitriptyline) are helpful.
- ▶ Vulval vestibulitis syndrome—may be a generalized or focal painful condition of unknown etiology. Topical agents (steroids, antifungal creams), vestibulectomy, behavioral therapy, have been tried.
- ▶ Vaginal ulcer is rare. Common vaginal cysts are Gartner's cyst and epithelial inclusion cyst.

# Benign Lesions of the Cervix

## CERVICAL ECTOPY (EROSION)

### DEFINITION

Cervical ectopy is a condition where the squamous epithelium of the ectocervix is replaced by columnar epithelium, which is continuous with the endocervix. It is not an ulcer (Fig. 18.1).

### ETIOLOGY

- Congenital
- Acquired

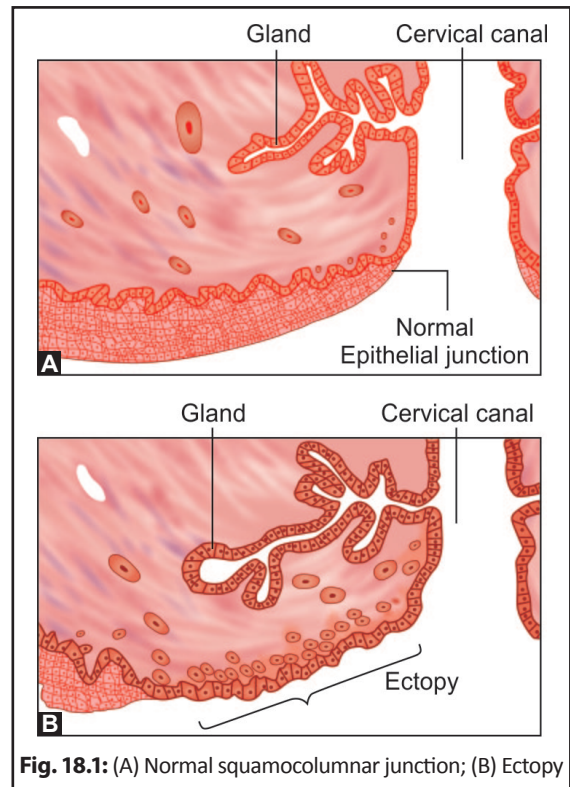
### CONGENITAL

At birth, in about one-third of cases, the columnar epithelium of the endocervix extends beyond the external os. This condition persists only for a few days until the level of estrogen derived from the mother falls. Thus, the congenital ectopy heals spontaneously.

### ACQUIRED

**Hormonal:** The squamocolumnar junction is not static and its movement, either inwards or outwards is dependent on estrogen. When the estrogen level is high, it moves out so that the columnar epithelium extends onto the vaginal portion of the cervix replacing the squamous epithelium. **This state is observed during pregnancy and amongst ‘pill users’**. The squamocolumnar junction returns back to its normal position after 3 months following delivery and little earlier following withdrawal of ‘pill’.

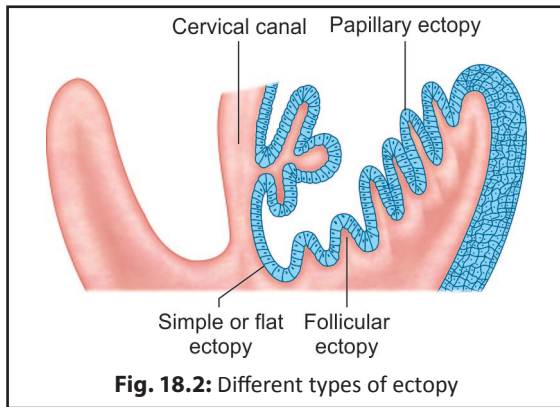
**Infection:** The role of infection as the primary cause of ectopy has been discarded. However, chronic cervicitis may be associated or else the infection may supervene on an ectopy because of the delicate columnar epithelium which is more vulnerable to trauma and infection.



**Fig. 18.1:** (A) Normal squamocolumnar junction; (B) Ectopy

### PATHOGENESIS

In the active phase of ectopy, the squamocolumnar junction moves out from the os. The columnar epithelium of the endocervix maintains its continuity while covering the ectocervix replacing the squamous epithelium. The replaced epithelium is usually arranged in a **single layer (flat type)** or may be so hyperplastic as to fold inwards to accommodate in the increased area—a **follicular ectopy**. At times, it becomes heaped up to fold inwards and outwards—



a **papillary ectopy** (Fig. 18.2). Underneath the epithelium, there are evidences of round cell infiltration and glandular proliferation. The features of infection are probably secondary rather than primary. The columnar epithelium is less resistant to infection than the squamous epithelium.

During the process of healing, the squamocolumnar junction gradually moves up towards the external os. The squamous epithelium grows beneath the columnar epithelium until it reaches at or near to its original position at the external os. Alternatively, the replacement is probably by squamous metaplasia of the columnar cells. The possibility of squamous metaplasia of the reserve cells is also likely (details in Chapter 22).

During the process, the squamous epithelium may obstruct the mouth of the underlying glands (normally not present in ectocervix) → pent up secretion → retention cyst → **Nabothian follicle**. Alternatively, the epithelium may burrow inside the gland lumina. **This process of replacement by the squamous epithelium is called epidermidization.**

## CLINICAL FEATURES

**Symptoms:** The lesion may be asymptomatic. However, the following symptoms may be present.

- ♦ Vaginal discharge—The discharge may be excessively mucoid. It may be mucopurulent, offensive and irritant in presence of infection; may be even blood-stained due to premenstrual congestion.
- ♦ Contact bleeding especially during pregnancy and ‘pill use’ either following coitus or defecation may be associated.
- ♦ Associated cervicitis may produce backache, pelvic pain and at times, infertility.

**Signs:** Internal examination reveals (Figs 18.3):

- ♦ Per speculum—There is a bright red area surrounding and extending beyond the external os in the ectocervix. The outer edge is clearly demarcated. The lesion may be smooth or having small papillary folds. It is neither tender nor bleeds to touch. On rubbing with a gauze piece, there may be multiple oozing spots (sharp bleeding in isolated spots in carcinoma).

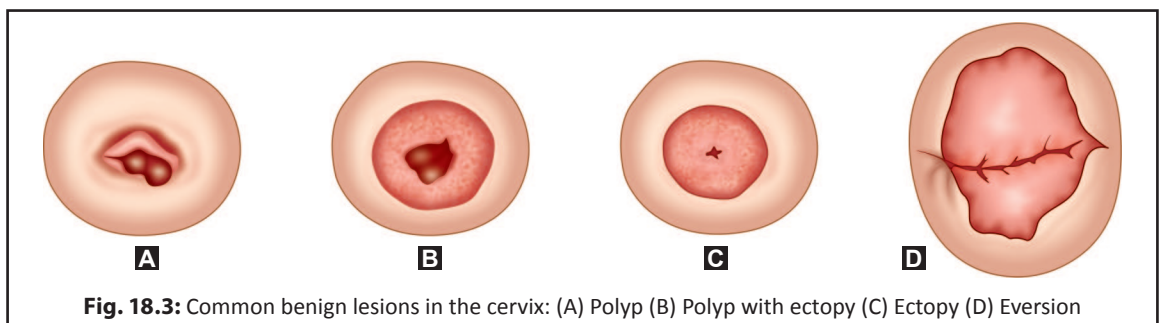
The feel is soft and granular giving rise to a grating sensation.

**DIAGNOSIS**—The diagnosis is confused with:

**Ectropion:** The lips of the cervix are curled back to expose the endocervix. This may be apparent when the lips of the cervix are stretched by the bivalve speculum.

**Early carcinoma:** It is indurated, friable and usually ulcerated which bleeds to touch. Confirmation is by biopsy (see p. 344).

**Primary lesion (chancere):** The ulcer has a punched-out appearance (see p. 148).



**Tubercular ulcer:** There is indurated ulcer with caseation at the base. Biopsy confirms the diagnosis.

### MANAGEMENT

**Guidelines:** All cases should be subjected to cytological examination from the cervical smear to exclude dysplasia or malignancy (see p. 110).

### Symptomatic cases

- ♦ Detected during pregnancy and early puerperium, the treatment should be withheld for at least 12 weeks postpartum. In pill users, the ‘pill’ should be stopped and barrier method is advised.
- ♦ Persistent ectopy with troublesome discharge should be treated surgically by—(i) thermal cauterization (see Fig. 34.2), (ii) cryosurgery and (iii) laser vaporization (see p. 561).

All the methods employed are based on the principle of destruction of the columnar epithelium to be followed by its healing by the squamous epithelium.

## EVERSION (ECTROPION)

In chronic cervicitis, there is marked thickening of the cervical mucosa with underlying tissue edema. These thickened tissues tend to push out through the external os along the direction of least resistance. The entity is most marked where the cervix has already been lacerated. In such conditions, the longitudinal muscle fibers are free to act unopposed. As a result, the lips of the cervix curl upwards and outwards to expose the red looking endocervix so as to be confused with ectopy (Figs 18.3).

## CERVICAL TEAR

Varying degrees of cervical tear is invariable during vaginal delivery. One or both the sides may be torn or the tear may be irregular (stellate type). If there is no superimposed infection and the tear is small, the torn surfaces may appose leaving behind only a small notch. However, if infection supervenes, eversion occurs confusing the diagnosis of ectopy (Figs 18.3).

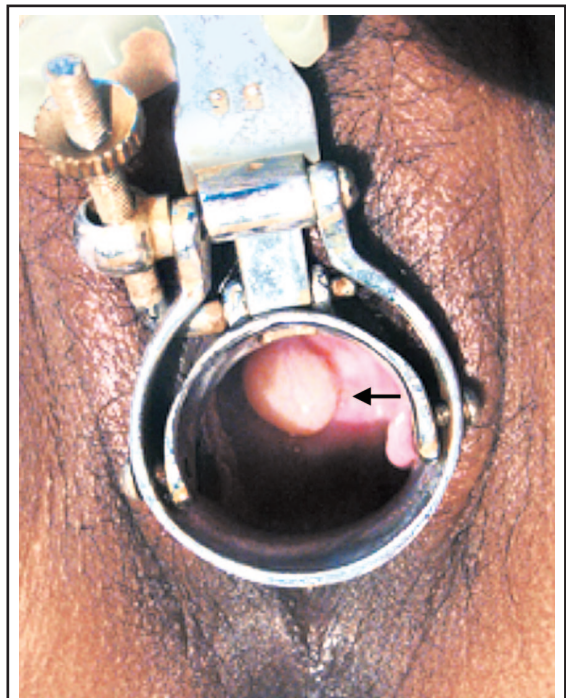
Non-obstetric causes of cervical lacerations are during operative procedures of dilatation of the cervix. Postmenopausal atrophy or chronic cervicitis predisposes to tear.

## CERVICAL CYSTS

**NABOTHIAN CYSTS (FIG. 18.4):** These are usually multiple. They are formed due to blocking of the cervical gland mouths usually as a result of healing of ectopy (epidermidization). The pent up secretion produces cysts of varying sizes from microscopic to pea. **The presence of the cysts furthest from the external os indicates the extent of transformation zone.** The lining epithelium is columnar. The treatment is directed towards chronic cervicitis.

**ENDOMETRIOTIC CYSTS:** These are situated in the portio vaginalis part of the cervix. The cyst is small and reddish and of less than 1 cm in diameter. It is more explained by the implantation theory. The implantation of the endometrium occurs during delivery or surgery. The lining epithelium shows endometrial glands and stroma.

Symptoms include intermenstrual or postcoital bleeding, deep dyspareunia and dysmenorrhea.



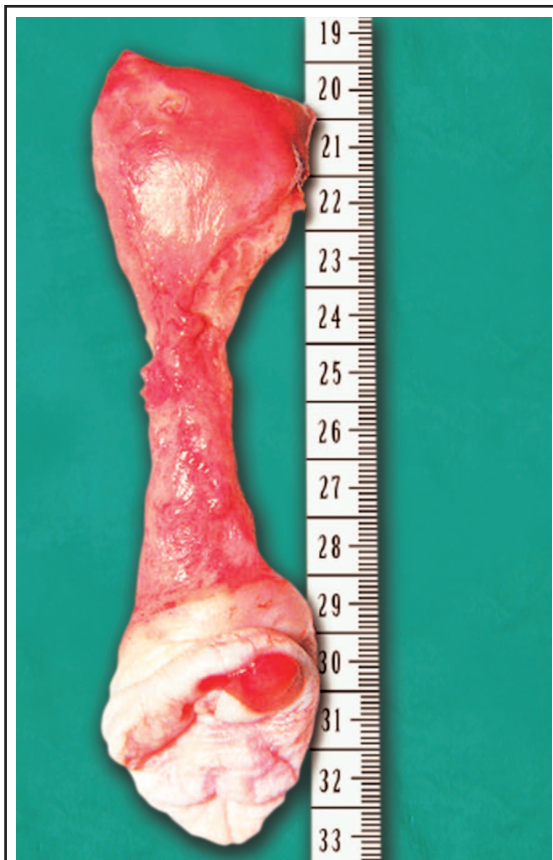**Fig. 18.4:** Nabothian cyst of cervix (arrow)

Speculum examination reveals a small reddish cyst. The treatment is destruction by cauterization and rarely by excision.

**MESONEPHRIC CYSTS:** These are usually situated on the outside of the cervical stroma. They seldom exceed 2.5 cm. These are lined by cuboidal epithelium. They are asymptomatic. The existence of the cyst is discovered on speculum examination and confirmation by excision biopsy.

### ELONGATION OF THE CERVIX

The normal length of the cervix is about 2.5 cm. The vaginal and the supravaginal parts are of equal length. The elongation may affect either part of the cervix.



**Fig. 18.5:** Supravaginal elongation of cervix in prolapse

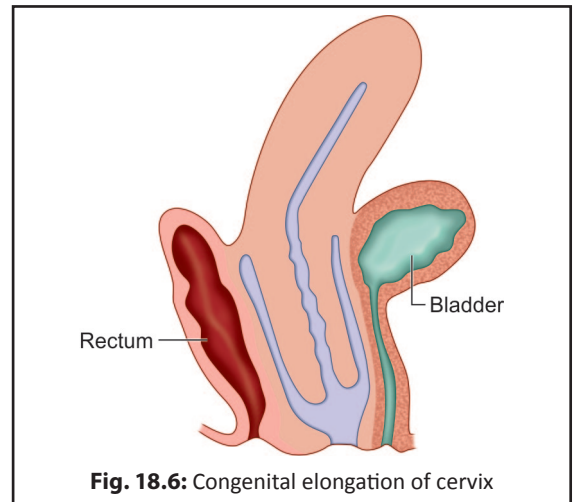
**CAUSES:** Elongation of the supravaginal part is commonly associated with the uterine prolapse. The mechanism has been described in p. 207.

Vaginal part is always elongated congenitally. Chronic cervicitis may produce some hypertrophy and makes the cervix bulky.

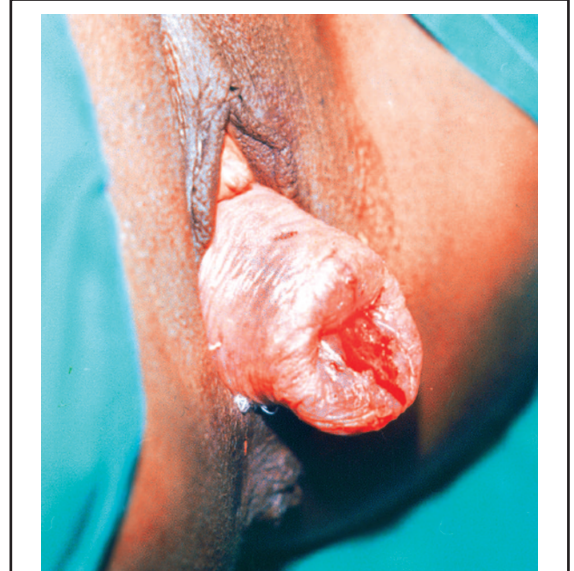### SYMPTOMS

There is no specific symptom for supravaginal elongation. However, congenital elongation of the vaginal part may present the following:

- ◆ Sensation of something coming down



**Fig. 18.6:** Congenital elongation of cervix



**Fig. 18.7:** Congenital elongation of cervix with prolapse



- ◆ Dyspareunia
- ◆ Infertility

**PELVIC EXAMINATION:** Supravaginal elongation is featured by (Fig. 18.5):

- ▶ Associated uterine prolapse.
- ▶ Fornix—shallow.
- ▶ Vaginal cervix—normal length.
- ▶ Uterine body—normal in size.
- ▶ Uterocervical canal—increased in length evidenced by introduction of an uterine sound. This indirectly proves that the increase is in the supravaginal part.

Congenital elongation is featured by (Fig. 18.6):

- ◆ Fornix—deep.
- ◆ Vaginal cervix—elongated.
- ◆ Uterine body—normal in size.
- ◆ Uterocervical canal—increased in length, evidenced by uterine sound.

**Treatment: Supravaginal elongation (Fig. 18.5)**—As it is associated with uterine prolapse, its treatment protocol will be the same as that for prolapse.

#### **Congenital elongation (Fig. 18.7)**

The excess length of the cervix is amputated (cervical amputation). In presence of congenital prolapse, some form of cervicopexy has to be done (see p. 221).

### KEY POINTS

- ▶ Chronic cervicitis and cervical erosion are the two most common cervical lesions encountered in gynecological practice.
- ▶ Cervical ectopy (erosion) may be congenital (circumoral) or acquired due to hormonal effect as observed during pregnancy and 'pill users'. The role of infection as the primary cause has been discarded.
- ▶ Histologically, the erosion is either flat, papillary or of follicular variety.
- ▶ Healing of the ectopy occurs through replacement of the columnar epithelium by downgrowth of the squamous epithelium or by squamous metaplasia of the columnar cells or the reserve cells. This process of replacement is called epidermidization. Ectopy is not a precancerous state.
- ▶ Ectopy is not an ulcer as it is entirely lined by columnar epithelium.  
All cases should be subjected to cytological examination to exclude dysplasia or malignancy.
- ▶ In asymptomatic cases, treatment should be withheld.  
Detected during pregnancy, treatment should be withheld for at least 12 weeks postpartum.
- ▶ Persistent ectopy with troublesome discharge should be treated surgically by thermal cauterization, cryosurgery or best by laser vaporization.
- ▶ Cervical cysts may be Nabothian, endometriotic or mesonephric. The confirmation of diagnosis is by histology.
- ▶ Supravaginal elongation of the cervix is associated with uterine prolapse and elongation of the vaginal part of the cervix is congenital in origin. Supravaginal elongation needs to be differentiated from congenital elongation of the cervix (see p. 270).

# Benign Lesions of the Uterus

## FIBROID

Fibroid is **the commonest benign tumor of the uterus** and also the commonest benign solid tumor in female. Histologically, this tumor is composed of smooth muscle and fibrous connective tissue, so named as uterine leiomyoma, myoma or fibromyoma.

### INCIDENCE

It has been estimated that at least 20 percent of women at the age of 30 have got fibroid in their wombs. Fortunately, most of them (50%) remain asymptomatic. The incidence of symptomatic fibroid in hospital outpatient is about 3 percent. A high incidence of 10 percent prevails in England. In colored races (black women), the incidence is even higher.

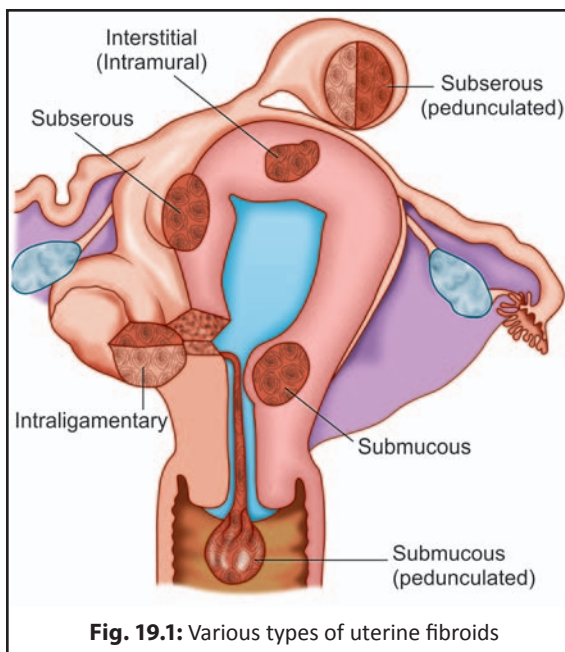
These are more common in nulliparous (Fig. 19.2) or in those having one child infertility (Table 19.1). The prevalence is highest between 35–45 years.

### HISTOGENESIS

#### Origin

The etiology still remains unclear. The prevailing hypothesis is that, it arises from the neoplastic single smooth muscle cell of the myometrium. The stimulus for initial neoplastic transformation is not known. The following are implicated:

- ◆ **Chromosomal abnormality**—In about 40 percent of cases, there is a varying type of chromosomal abnormality, particularly the chromosome six or seven (rearrangements, deletions). Somatic mutations in myometrial cells may also be the cause for uncontrolled cell proliferation.
- ◆ **Role of polypeptide growth factors**—Epidermal growth factor (EGF), insulin-like growth factor-1 (IGF-1),



**Fig. 19.1:** Various types of uterine fibroids

transforming growth factor (TGF), stimulate the growth of leiomyoma either directly or via estrogen.

- ◆ A positive family history is often present.

#### Growth

It is predominantly an estrogen-dependent tumor. Estrogen and progesterone is incriminated as the cause. Estrogen dependency is evidenced by:

- ◆ Growth potentiality is limited during childbearing period.
- ◆ Increased growth during pregnancy.
- ◆ They do not occur before menarche.
- ◆ Following menopause, there is cessation of growth and there is no new growth at all.

- ◆ It seems to contain more estrogen receptors than the adjacent myometrium.
- ◆ Frequent association of anovulation.

The growth potentiality is not squarely distributed amongst the fibroids which are usually multiple, some grow faster than the others. On the whole, the rate of growth is slow and it takes about 3–5 years for the fibroid to grow sufficiently to be felt per abdomen (cf—ovarian tumor grows in months).

Increased risk	Reduced risk
<ul style="list-style-type: none"> <li>• Nulliparity</li> <li>• Obesity</li> <li>• Hyperestrogenic state</li> <li>• Black women</li> </ul>	<ul style="list-style-type: none"> <li>• Multiparity</li> <li>• Smoking</li> </ul>

However, **the fibroid grows rapidly** during pregnancy or amongst pill users (high dose pills). Rapid growth may also be due to degeneration or due to malignant change.

The newer low dose oral contraceptives are not associated with increase in the growth of a fibroid.

**TYPES: • Body • Cervical (see chart below)**

**Body:** The fibroids are mostly located in the body of the uterus and are usually multiple (Figs 19.1 and 19.2).

**Interstitial or intramural (75%)**

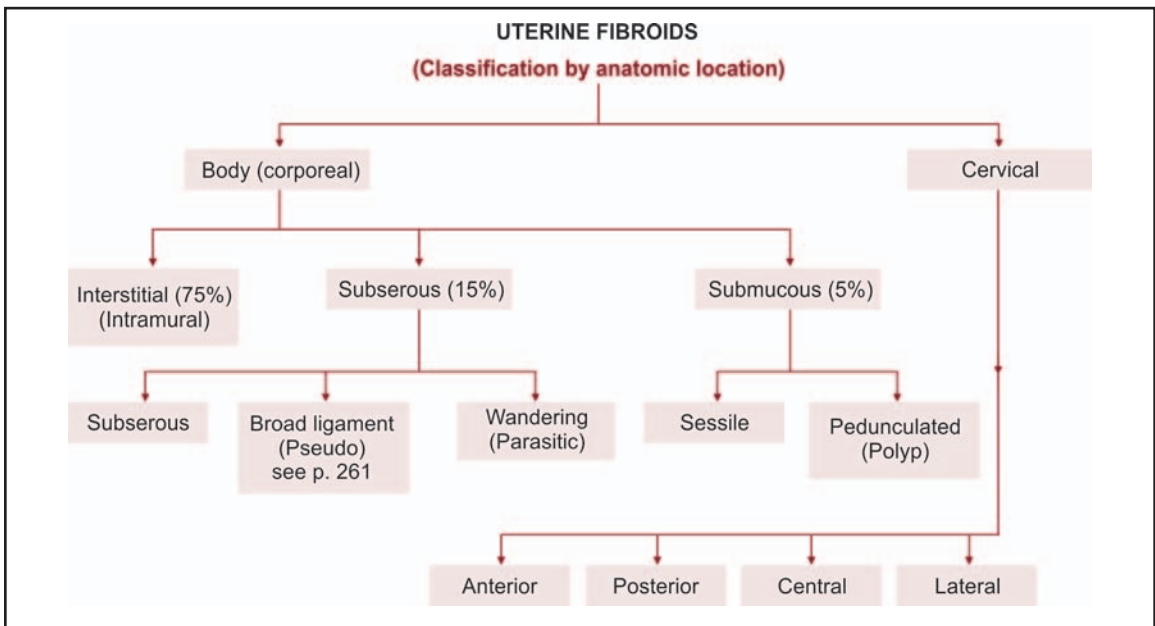
Initially, the fibroids are intramural in position but subsequently, some are pushed outward or inward. Eventually, in about 70 percent, they persist in that position.

**Subperitoneal or subserous (15%)**

In this condition, the intramural fibroid is pushed outwards towards the peritoneal cavity. The fibroids are either partially or completely covered by peritoneum. When completely covered by peritoneum, it usually attains a pedicle—called pedunculated subserous fibroid. On rare occasion, the pedicle may be torn through; the fibroid gets its nourishment from the omental or mesenteric adhesions and is called ‘**wandering**’ or ‘**parasitic**’ fibroid. Sometimes, the intramural fibroid may be pushed out in between the layers of broad ligament and is called broad ligament fibroid (false or pseudo).

**Submucous (5%) (Fig. 19.3)**

The intramural fibroid when pushed toward the uterine cavity, and is lying underneath the endometrium, it is called submucous fibroid. Submucous fibroid can make the uterine cavity irregular and distorted. Pedunculated submucous fibroid may come out through the cervix (Fig. 19.7). It may be infected or ulcerated to cause metrorrhagia. Although, **this**



variety is least common (about 5 %) but it produces maximum symptoms (Fig. 19.12).

### Cervical (see Figs 19.10 and 36.50)

Cervical fibroid is rare (1–2 %). In the supravaginal part of the cervix, it may be interstitial or subperitoneal variety and rarely polypoidal. Depending upon the position, it may be anterior, posterior, lateral or central. Interstitial growths may displace the cervix or expand it so much that the external os is difficult to recognize. **All these disturb the pelvic anatomy, specially the ureter.**

In the vaginal cervix, the fibroid is usually pedunculated and rarely sessile.

**Pseudocervical fibroid:** A fibroid polyp arising from the uterine body when occupies and distends the cervical canal, it is called pseudocervical fibroid.

## BODY OR CORPOREAL FIBROIDS

### PATHOLOGY

#### Naked eye appearance

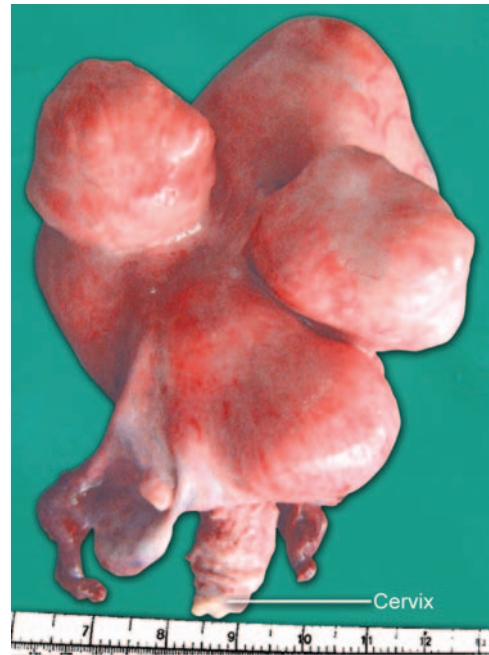The uterus is enlarged; the shape is distorted by multiple nodular growth of varying sizes. Occasionally, there may be uniform enlargement of the uterus by a single fibroid. The feel is firm (Fig. 19.3).

Cut surface of the tumor is smooth and whitish. The cut section, in the absence of degenerative changes, shows features of whorled appearance and trabeculation. These are due to the intermingling of fibrous tissues with the muscle bundles.

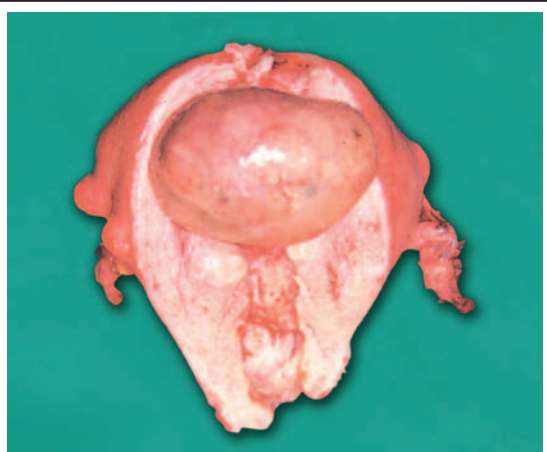**The false capsule** (see Fig. 37.48) is formed by the compressed adjacent myometrium. They have more parallel arrangement and are pinkish in color in contrast to whitish appearance of the tumor. The capsule is separated from the growth by a thin loose areolar tissue. The blood vessels run through this plane to supply the tumor. It is through this plane that the tumor is shelled out during myomectomy operation. The periphery of the tumor is more vascular and have more growth potentiality. **The center of the tumor is least vascular and likely to degenerate.** It is due to contraction of the false capsule that makes the cut surface of the tumor to bulge out.

**TABLE 19.2 THE FATE OF A SUBMUCOUS FIBROID**

- Surface necrosis
- Polypoid change—following pedicle formation
- Infection
- Degenerations including sarcomatous change



**Fig. 19.2:** Multiple fibroids causing marked distortion of the uterus. The uterine corpus is almost completely replaced by multiple myomas in subserous, intramural and submucous positions.



**Fig. 19.3:** Cut section of a uterus showing a submucous fibroid

**Microscopic appearance (Fig. 19.4)**

The tumor consists of smooth muscles and fibrous connective tissues of varying proportion. Originally, it consists of only muscle element but later on, fibrous tissues intermingle with the muscle bundles. As such, the nomenclature of ‘fibroids’ although commonly used, is inappropriate and should better be called either ‘myomata’ or fibromyomata.

**SECONDARY CHANGES IN FIBROIDS****TABLE 19.3** SECONDARY CHANGES IN A FIBROID

◆ Degenerations	◆ Infection
◆ Atrophy	◆ Vascular changes
◆ Necrosis	◆ Sarcomatous change

**DEGENERATIONS**

**Hyaline degeneration is the most common (65%)** type of degeneration affecting all sizes of fibroids except the tiny one. It is common specially in tumors having more connective tissues. The central part of the tumor which is least vascular is the common site. The feel becomes soft elastic in contrast to firm feel of the tumor.

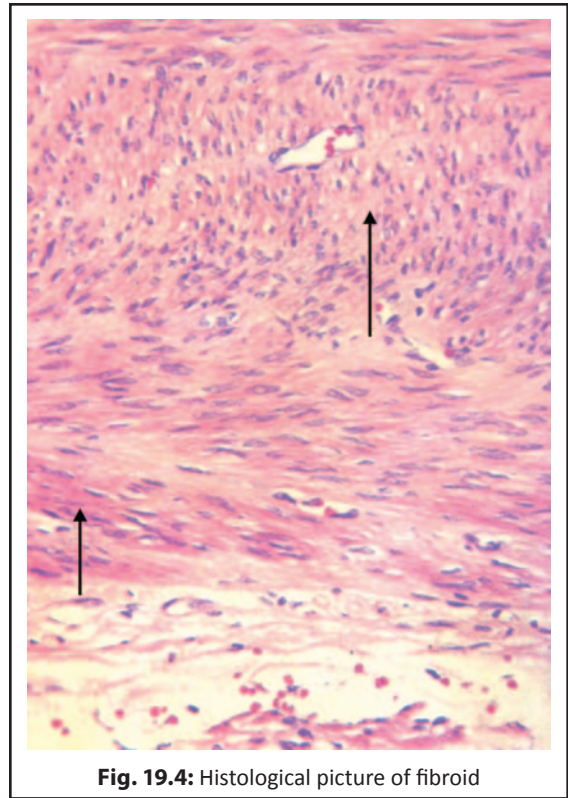
Naked eye examination on the cut surface shows irregular homogenous areas with loss of whorl-like appearance.

Microscopic examination reveals hyaline changes of both the muscles and fibrous tissues.

**Cystic degeneration** usually occurs following menopause and is common in interstitial fibroids. It is formed by liquefaction of the areas with hyaline changes. The cystic spaces are lined by irregular ragged walls. The cystic changes of an isolated big fibroid may be confused with an ovarian cyst or pregnancy.

**Fatty degeneration** is usually found at or after menopause. Fat globules are deposited mainly in the muscle cells.

**Calcific degeneration (10%)** usually involves the subserous fibroids with small pedicle or myomas of postmenopausal women. It is usually preceded by fatty degeneration. There is precipitation of calcium carbonate or phosphate within the tumor. When whole of the tumor is converted into a calcified mass, it is called **“womb stone”** (see p. 662).

**Fig. 19.4:** Histological picture of fibroid

**Red degeneration** (carneous degeneration) occurs in a large fibroid mainly during second half of pregnancy and puerperium. Partial recovery is possible and as such called necrobiosis. The cause is not known but is probably vascular in origin. Infection does not play any part.

Naked eye appearance of the tumor shows dark areas with cut section revealing raw-beef appearance often containing cystic spaces. The odor is often fishy due to fatty acids. Color is due to the presence of hemolysed red cells and hemoglobin.

Microscopically, evidences of necrosis are present. Vessels are thrombosed but extravasation of blood is unlikely.

**Atrophy:** Atrophic changes occur following menopause due to loss of support from estrogen. There is reduction in the size of the tumor. Similar reduction also occurs following pregnancy enlargement.

**Necrosis:** Circulatory inadequacy may lead to central necrosis of the tumor. This is present in submucous polyp or pedunculated subserous fibroid.

**Infection:** The infection gains access to the tumor core through the thinned and sloughed surface epithelium of the submucous fibroid. This usually happens following delivery or abortion. Intramural fibroid may also be infected following delivery.

**Vascular changes:** Dilatation of the vessels (telangiectasis) or dilatation of the lymphatic channels (lymphangiectasis) inside the myoma may occur. The cause is not known.

**Sarcomatous changes:** Sarcomatous change may occur **in less than 0.1 percent cases**. The usual type is leiomyosarcoma. Recurrence of fibroid polyp, sudden enlargement of fibroid or fibroid along with postmenopausal bleeding raises the suspicion.

### Associated Changes in the Pelvic Organs

**Uterus:** The shape is distorted; usually asymmetrical but at times, uniform. Myohyperplasia is almost a constant finding. It may be due to hyperestrinism or work hypertrophy in an attempt to expel the fibroid.

The endometrium may be of normal type. In others, there are features of anovulation with evidences of hyperplasia. There is dilatation and congestion of the myometrial and endometrial venous plexuses. The endometrium as a result becomes thick, congested and edematous. The endometrium overlying the submucous fibroid may be thin and necrotic with evidences of infection.

**TABLE 19.4**    **COMPLICATIONS OF FIBROIDS**

- ◆ Degenerations
- ◆ Necrosis
- ◆ Infection
- ◆ Sarcomatous change (rare)
- ◆ Torsion of subserous pedunculated fibroid
- ◆ Hemorrhage
  - Intracapsular
  - Ruptured surface vein of subserous fibroid → intraperitoneal
- ◆ Polycythemia due to
  - Erythropoietic function by the tumor
  - Altered erythropoietic function of the kidney through ureteric pressure

The uterine cavity may be elongated and distorted in intramural and submucous varieties.

**Uterine tubes:** The frequent tubal infection (about 15%) detected in association with fibroid seems coincidental.

**Ovaries:** The ovaries may be enlarged, congested and studded with multiple cysts. The cause may be due to hyperestrinism.

**Ureter:** There may be displacement of the anatomy of the ureter in broad ligament fibroid. The compression effect results in hydroureter and or hydronephrosis.

**Endometriosis:** There is increased association of pelvic endometriosis and adenomyosis (30%).

**Endometrial carcinoma:** The incidence remains unaffected.

## CLINICAL FEATURES

### PATIENT PROFILE

The patients are usually nulliparous or having long period of secondary infertility. However, early marriage and frequent childbirth make its frequency high even amongst the multiparous women. The incidence is at its peak between 35–45 years. There is a tendency of delayed menopause.

**Symptoms:** The majority of fibroids remain asymptomatic (75%). They are accidentally discovered by the physician during routine examination or at laparotomy or laparoscopy.

The symptoms are related to anatomic type and size of the tumor. **The site is more important than the size.** A small submucous fibroid may produce more symptoms than a big subserous fibroid.

### MENSTRUAL ABNORMALITIES

(a) **Menorrhagia (30%) is the classic symptom of symptomatic fibroid.**

The menstrual loss is progressively increased with successive cycles. It is conspicuous in submucous or interstitial fibroids. **The causes are:**

- ◆ Increased surface area of the endometrium (Normal is about 15 sq cm).
- ◆ Interference with normal uterine contractility due to interposition of fibroid.
- ◆ Congestion and dilatation of the subjacent endometrial venous plexuses caused by the obstruction of the tumor.
- ◆ Endometrial hyperplasia due to hyperestrinism (anovulation).

- ◆ Pelvic congestion.
  - ◆ Role of prostanoids—imbalance of thromboxane (TXA<sub>2</sub>) and prostacyclin (PGI<sub>2</sub>) with relative deficiency of TXA<sub>2</sub>.
- (b) **Metrorrhagia or irregular bleeding may be due to:**
- ◆ Ulceration of submucous fibroid or fibroid polyp.
  - ◆ Torn vessels from the sloughing base of a polyp.
  - ◆ Associated endometrial carcinoma.

### Symptoms of Fibroid Uterus

- ◆ Asymptomatic—majority (75%)
- ◆ Menstrual abnormality: Menorrhagia, metrorrhagia (p. 186).
- ◆ Dysmenorrhea
- ◆ Dyspareunia
- ◆ Infertility
- ◆ Pressure symptoms
- ◆ Recurrent pregnancy loss (miscarriage, preterm labor)
- ◆ Lower abdominal or pelvic pain
- ◆ Abdominal enlargement.

**Dysmenorrhea:** The congestive variety may be due to associated pelvic congestion or endometriosis. Spasmodic type is associated with extrusion of polyp and its expulsion from the uterine cavity.

Subserous, broad ligament or cervical fibroids are usually unassociated with menstrual abnormalities.

**Infertility:** Infertility (30%) may be a major complaint.

**The probable known attributing factors are:**

#### Uterine

- Distortion and or elongation of the uterine cavity → difficult sperm ascent.
- Preventing rhythmic uterine contraction due to fibroids during intercourse → impaired sperm transport.
- Congestion and dilatation of the endometrial venous plexuses → defective nidation.
- Atrophy and ulceration of the endometrium over the submucous fibroids → defective nidation.
- Menorrhagia and dyspareunia.

#### Tubal

- Cornual block due to position of the fibroid.
- Marked elongation of the tube over a big fibroid.
- Associated salpingitis with tubal block.

**Ovarian:** • Anovulation

**Peritoneal:** • Endometriosis

**Unknown—**(majority)

**Pregnancy-related problems** like abortion, preterm labor and intrauterine growth restriction are high. The reasons are defective implantation of the placenta, poorly developed endometrium, reduced space for the growing fetus and placenta. Red degeneration and torsion of subserous pedunculated fibroid is common in pregnancy. Labor dystocia, postpartum hemorrhage are also more.

#### Pain lower abdomen

The fibroids are usually painless. Pain may be due to some complications of the tumor or due to associated pelvic pathology.

#### Due to tumor

- Degeneration
- Torsion subserous pedunculated fibroid
- Extrusion of polyp.

#### Associated pathology

- Endometriosis
- PID

#### Abdominal swellings (lump)

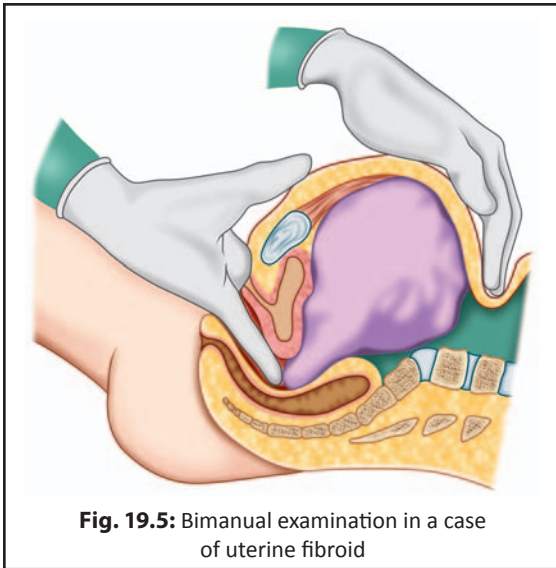
The patient may have a sense of heaviness in lower abdomen. She may feel a lump in the lower abdomen even without any other symptom.

#### Pressure symptoms

**Pressure symptoms are rare in body fibroids.** The fibroids in the posterior wall may be impacted in the pelvis producing constipation, dysuria or even retention of urine. A broad ligament fibroid may produce ureteric compression → hydroureteric and hydronephrotic changes → infection → pyelitis.

#### Signs

General examination reveals varying degrees of pallor depending upon the magnitude and duration of menstrual loss.



**Fig. 19.5:** Bimanual examination in a case of uterine fibroid

### Abdominal examination

The tumor may not be sufficiently enlarged to be felt per abdomen. But if enlarged to 14 weeks or more, the following features are noted.

### Palpation

- Feel is firm, more toward hard; may be cystic in cystic degeneration.
- Margins are well-defined except the lower pole which cannot be reached suggestive of pelvic in origin.
- Surface is nodular; may be uniformly enlarged in a single fibroid.
- Mobility is restricted from above downwards but can be moved from side to side.

### Percussion

The swelling is dull on percussion.

### Pelvic examination

Bimanual examination reveals the uterus irregularly enlarged by the swelling felt per abdomen. **That the swelling is uterine is evidenced by:**

- Uterus is not felt separated from the swelling and as such a groove is not felt between the uterus and the mass (Fig. 19.5).
- The cervix moves with the movement of the tumor felt per abdomen.

The only exception of these two findings is a subserous pedunculated fibroid. As such, such type is

**TABLE 19.5**

### CAUSES OF SYMMETRICAL ENLARGEMENT OF UTERUS

- |  |                   |
|--|-------------------|
| • Pregnancy                                  | • Hematometra     |
| • Submucous or intramural (solitary) fibroid | • Lochiometra     |
| • Adenomyosis                                | • Malignancy      |
| • Myohyperplasia                             | – Carcinoma body  |
| • Pyometra                                   | – Choriocarcinoma |
|  | – Sarcoma         |

**TABLE 19.6**

### LIFE-THREATENING COMPLICATIONS OF FIBROIDS

- ♦ Persistent menorrhagia, metrorrhagia or continued vaginal bleeding → severe anemia
- ♦ Severe intraperitoneal hemorrhage due to rupture of veins over subserous fibroid
- ♦ Severe infection leading to peritonitis or septicemia
- ♦ Sarcoma (rare)

too often confused with an ovarian tumor. However, a submucous fibroid may produce symmetrical enlargement of the uterus and at times, it is difficult to diagnose accurately.

## INVESTIGATIONS

The investigations aim at:

- To confirm the diagnosis
- Preoperative assessment

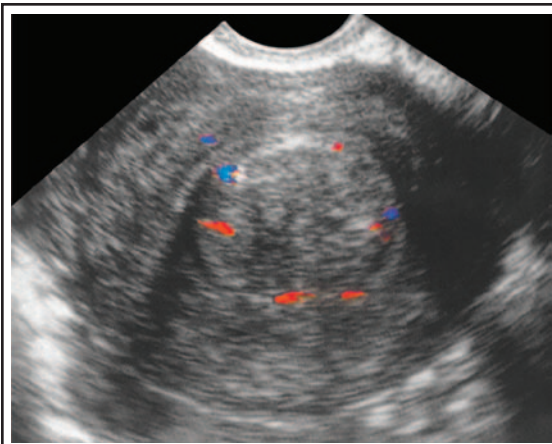
### To confirm the diagnosis

Although, the majority of uterine fibroids can be diagnosed from the history and pelvic examination but at times pose problems in diagnosis.

### Ultrasound and Color Doppler (TVS) findings are:

- Uterine contour is enlarged and distorted.
- Depending on the amount of connective tissue or smooth muscle proliferation, fibroids are of different echogenicity-hypoechoic or hyperechoic.
- Vascularization is at the periphery of the fibroid.
- Central vascularization indicates degenerative changes. **Ultrasound** is an useful diagnostic tool to confirm the diagnosis of fibroid. **Transvaginal ultrasound** can accurately assess the myoma location, dimensions volume and also any adnexal pathology. Hydroureter or hydronephrotic changes can be





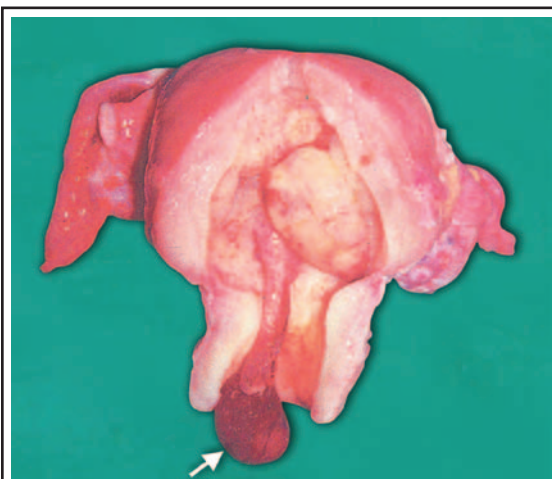**Fig. 19.6:** Ultrasonographic view of a uterine fibroid

diagnosed. **Three-dimensional** ultrasonography can locate fibroids accurately. Serial ultrasound examination is needed during medical or conservative management (Figs 19.6, 19.7 and 19.13).

**Saline Infusion Sonography (SIS)** is helpful to detect any submucous fibroid or polyp (p. 118).

**Magnetic resonance imaging (MRI)**—is more accurate compared to ultrasound. It helps to differentiate adenomyosis from fibroids. MRI is not used routinely for the diagnosis. It is expensive and not widely available.

**Laparoscopy**—Laparoscopy is helpful, if the uterine size is less than 12 weeks and associated with pelvic pain and infertility. Associated pelvic endometriosis



**Fig. 19.7:** Submucous fibroid polyps, sessile and pedunculated arrow (see also Fig. 37.49)

and tubal pathology can be revealed. It can also differentiate a pedunculated fibroid from ovarian tumor, not revealed by clinical examination and ultrasound.

**Hysteroscopy** is of help to detect submucous fibroid in unexplained infertility and repeated pregnancy wastage. The presence and site of submucous fibroid can be diagnosed by direct visualization during hysteroscopy (Fig. 19.8). Submucosal fibroid can be resected at the same time using a resecting hysteroscope.

**HSG** when done, a filling defect can be seen.

**Uterine curettage**—In the presence of irregular bleeding, to detect any co-existing pathology and to study the endometrial pattern, curettage is helpful. It additionally helps to diagnose a submucous fibroid by feeling a bump. However, hysteroscopy and biopsy is a better alternative.

**Preoperative assessment:** Apart from routine preoperative investigations, intravenous pyelography to note the anatomic changes of the ureter may be helpful.

**Differential diagnosis:** The fibroid of varying sizes may be confused with: (1) Pregnancy (2) Full bladder (3) Adenomyosis (4) Myohyperplasia (5) Ovarian tumor (6) TO mass. The differentiating features are described in p. 298, ch. 20.

## MANAGEMENT OF FIBROID UTERUS

### ■ Symptomatic ■ Asymptomatic

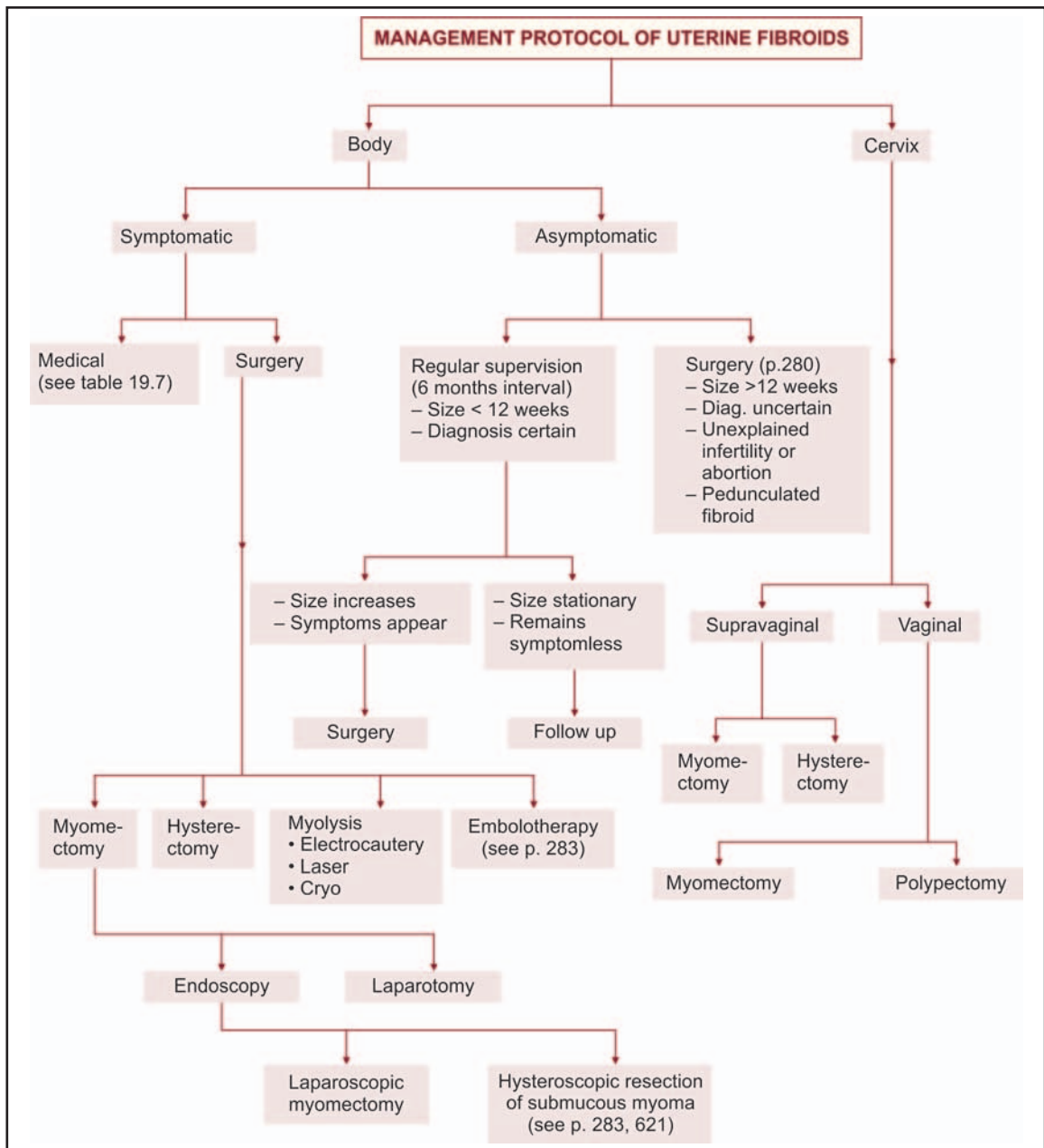
#### Symptomatic fibroids

#### MEDICAL MANAGEMENT

Drug therapy has established a firm place in the management of symptomatic fibroids. The drugs are used either as a temporary palliation or may be used in rare cases, as an alternative to surgery. **Prior to drug therapy, one must be certain about the diagnosis.**

**The objectives of medical treatment are:**

- ◆ To improve menorrhagia and to correct anemia before surgery.
- ◆ To minimize the size and vascularity of the tumor in order to facilitate surgery.
- ◆ In selected cases of infertility to facilitate hysteroscopic or laparoscopic surgery (see chapter 35).



- ◆ As an alternative to surgery in perimenopausal women or women with high-risk factors for surgery.
- ◆ Where postponement of surgery is planned temporarily.

#### **To minimize blood loss**

As a temporary palliation, various drugs are used to minimize blood loss and to correct anemia when

**TABLE 19.7**

#### **DRUGS USED TO MINIMIZE BLOOD LOSS**

Antiprogesterones (Mifepristone)  
 Danazol  
 GnRH analogs: ◆ Agonists ◆ Antagonists  
 LNG-IUS  
 Prostaglandin synthetase inhibitors

a definite surgery cannot be undertaken for certain periods (Table 19.7).

**Antiprogesterones** (p. 537)—Mifepristone (RU 486) is very effective to reduce fibroid size and also menorrhagia. It may produce amenorrhea. It reduces the size of the fibroid significantly. A daily dose of 25–30 mg is recommended for 3 months. 5 mg daily dose is also found effective. Long-term therapy is avoided as it causes endometrial hyperplasia. Asoprisnil is used with success. It is a selective progesterone receptor modulator. It does not cause endometrial hyperplasia.

**Danazol** (p. 530)—can reduce the volume of a fibroid slightly. Because of androgenic side effects, danazol is used only for a period of 3–6 months. Danazol administered daily in divided doses ranging from 200–400 mg for 3 months minimizes blood loss or even produce amenorrhea by its antigonadotropin and androgen agonist actions.

**GnRH agonists** (p. 525)—Drugs commonly used are goserelin, luporelin, buserelin or nafarelin (see p. 525). **Mechanism of action is sustained pituitary down regulation and suppression of ovarian function.** Optimal duration of therapy is 3 months. Addback therapy may be needed to combat hypestrogenic symptoms (see p. 527).

**GnRH antagonists** (p. 527)—Cetorelix or ganirelix causes immediate suppression of pituitary and the ovaries. They do not have the initial stimulatory effect. Benefits are same as that of agonists (see Table 19.8). Onset of amenorrhea is rapid.

**Prostaglandin synthetase inhibitors**—These are used to relieve pain due to associated endometriosis or degeneration of the fibroid. They cannot improve menorrhagia due to fibroids.

**Levonorgestrel-releasing Intrauterine System (LNG-IUS)** reduces blood loss and uterine size. However, this is not recommended when the uterine size is >12 weeks or there is distortion of uterine cavity.

**Preoperative therapy:** It is indeed advantageous to reduce the size and vascularity of fibroid prior to either myomectomy or hysterectomy. While operation will be technically easier in broad ligament or cervical fibroid, in myomectomy, there may be little difficulty in enucleation of the tumor from its pseudocapsule.

**TABLE 19.8** ADVANTAGES OF GnRH ANALOGUE

**Advantages**

- Improvement of menorrhagia and may produce amenorrhea.
- Improvement of anemia.
- Relief of pressure symptoms.
- Reduction in size (50%) when used for a period of 6 months.
- Reduction in vascularity of the tumor.
- Reduction in blood loss during myomectomy.
- May facilitate laparoscopic or hysteroscopic surgery.

**Disadvantages**

- Hypoestrogenic side effects (Vasomotor symptoms, Trabecular bone loss).
- Cost (high).
- Regrowth of myomas on cessation of therapy.
- Degeneration (some leiomyomas)—causing difficulty in myoma enucleation.

However, with the stoppage of the therapy, the tumor will attain its previous size slowly. Benefits (see Table 19.8) are achieved when therapy is given for a period of three months.

## SURGICAL MANAGEMENT OF FIBROID UTERUS

■ **Myomectomy**

(may be done by)

- ▶ Laparotomy
- ▶ Laparoscopy
- ▶ Hysteroscopy

■ **Embolotherapy**

- Myolysis
- Hysterectomy

■ **Myomectomy (see p. 604, Tables 19.9 to 19.12)**

Myomectomy is the enucleation of myomata from the uterus leaving behind a potentially functioning organ capable of future reproduction.

As such, the surgeon should be satisfied with the operation designed to serve the objective. It is indeed useless to perform a hectic surgery to remove such myomata only to leave behind an uterus which is unlikely to conceive in future.

Among the contraindications few are relative rather than absolute. Restoration of anatomy and function of the uterus, tubes and ovaries following myomectomy

**TABLE 19.9** IMPORTANT CONSIDERATIONS PRIOR TO MYOMECTOMY

- It should be done mainly to preserve the reproductive function.
- The wish to preserve the menstrual function in parous women should be judiciously complied with.
- Myomectomy is a more risky operation when the fibroid(s) is too big and too many.
- Risk of recurrence and persistence of fibroid is about 30–50 percent.
- Risk of persistence of menorrhagia is about 1–5 percent.
- Risk of relaparotomy is about 20–25 percent.
- Pregnancy rate following myomectomy is about 40–60 percent.
- Pregnancy following myomectomy should have a mandatory hospital delivery, although the chance of scar rupture is rare (little more when the cavity is open).

**TABLE 19.10** INDICATIONS OF MYOMECTOMY

- ◆ Persistent uterine bleeding despite medical therapy.
- ◆ Excessive pain or pressure symptoms.
- ◆ Size >2 weeks, woman desirous to have a baby.
- ◆ Unexplained infertility with distortion of the uterine cavity.
- ◆ Recurrent pregnancy wastage due to fibroid.
- ◆ Rapidly growing myoma during follow-up.
- ◆ Subserous pedunculated fibroid.

**TABLE 19.11** PRE-REQUISITES TO MYOMECTOMY

- ◆ Hysteroscopy or hysterosalpingography—to exclude any submucous fibroid or a polyp or any tubal block.
- ◆ Hysteroscopy/endometrial biopsy—in cases of irregular cycles, not only to remove a polyp but also to exclude endometrial carcinoma.
- ◆ Examination of the husband from fertility point of view (semen analysis).

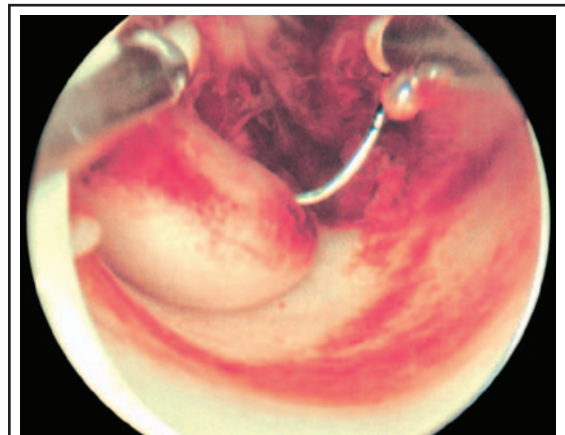
**TABLE 19.12** CONTRAINDICATIONS OF MYOMECTOMY

- ◆ Infected fibroid.
- ◆ Growth of myoma after menopause.
- ◆ Suspected malignant change (sarcoma).
- ◆ Parous women where hysterectomy is safer and is a definitive treatment (Table 19.9).
- ◆ Functionless fallopian tubes (bilateral hydrosalpinx, tubo-ovarian mass) – decision must be judicious with the advent of microsurgery and ART.
- ◆ Pelvic or endometrial tuberculosis.
- ◆ During pregnancy or during cesarean section.

are important, not only for future reproductive function but also to avoid the future hazards (see Table 19.9).

However, the final decision as to whether to perform myomectomy or hysterectomy is to be taken following laparotomy. As such, it is prudent on the part of surgeon to declare the operative decision as **‘myomectomy to be tried’** and if the conditions arise so, it may end in hysterectomy.

Pretreatment with GnRH analogs may be used to reduce the size and vascularity of the uterus. Steps of myomectomy and complications of myomectomy have been discussed (see p. 605).



**Fig. 19.8:** Hysteroscopic view of a submucous fibroid. Endoscopic resection is possible

**Vaginal myomectomy:** Submucous pedunculated myoma can be removed vaginally. **Morcellation** (removal by piecemeal) is needed if the tumor is large. A moderate size fibroid can be removed by twisting. In that case, fibroid is grasped with a sponge forceps.

### ■ Endoscopic Surgery

▲ **Hysteroscopy:** Generally a fibroid of 3–4 cm in diameter or a polyp is resected with a hysteroscope. Pedicle or the base of the fibroid is coagulated using electrocautery (Fig. 19.8). Nd:YAG laser can also be used (p. 123).

Complications of hysteroscopic surgery are uterine perforation, fluid overload, hemorrhage and others (see p. 623).

▲ **Laparoscopy:** Subserous and intramural fibroids could be removed laparoscopically. Electrocautery, laser and extra-corporeal sutures are used for hemostasis. Laparoscopic surgery is not suitable when the fibroid is large, deep intramural, multiple or technically inaccessible. Leiomyomas can be desiccated (**myolysis**) using laser or bipolar diathermy. Complications of laparoscopic surgery, contraindications and others are discussed in Chapter 35 (p. 619).

■ **Embolotherapy:** Uterine artery embolization (UAE) causes avascular necrosis followed by shrinkage of fibroid. Uterine arteries are occluded by injecting polyvinyl alcohol particles through percutaneous femoral catheterization. This may be an option to women with symptomatic fibroid where surgery is not preferred.

**Result:** Improvement of menorrhagia is observed in 80–90 percent with 60 percent reduction in size.

**Complication of UAE:** *Postembolization syndrome:* Fever, sepsis, myometrial infarction and necrosis, amenorrhea and ovarian failure. *Complications related to the procedure:* femoral artery injury.

**Contraindications:** Active pelvic infection, desire for future pregnancy, drug allergy.

**Ultrasound:** MRI-guided focussed high-energy ultrasound waves induce coagulative necrosis in myomas. It causes localized thermal ablation of the fibroid tissue. It may need multiple treatments.

It causes less pain compared to UAE. It has less postoperative complications.

■ **Hysterectomy:** Hysterectomy in fact, is the operation of choice in symptomatic fibroid when there is no valid reason for myomectomy. The patients over the age of 40 years and in those not desirous of further child are the classic indications.

**Total hysterectomy is performed. However, a subtotal hysterectomy may have to be done in few conditions (see p. 593).**

**Removal of the ovary:** It is preferable to remove the ovaries in postmenopausal women and to preserve the same in earlier age, if they are found healthy. (For details see p. 593).

### Advantages of hysterectomy

- There is no chance of recurrence.
- Adnexal pathology and the unhealthy cervix, if any, are also removed.

TABLE 19.13

### INDICATIONS OF EMERGENCY SURGERY IN A FIBROID

- ◆ Torsion of a subserous pedunculated fibroid.
- ◆ Massive intraperitoneal hemorrhage following rupture of veins over subserous fibroid.
- ◆ Uncontrolled infected fibroid.
- ◆ Uncontrolled bleeding fibroid.

### Place of vaginal hysterectomy

Fibroids with size of 10–12 weeks of pregnancy associated with uterine prolapse are better dealt by the vaginal route. Vaginal hysterectomy with repair of pelvic floor is the operation of choice. Pretreatment with GnRH analog may facilitate vaginal hysterectomy.

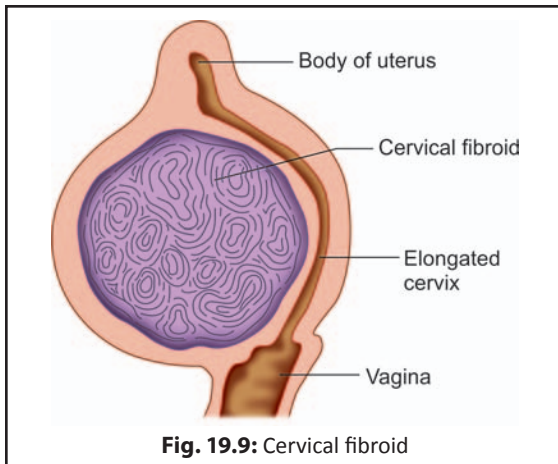
### ASYMPTOMATIC FIBROID (75%)

Fibroids detected accidentally on routine examination for complaints other than fibroids are dealt with as follows:

- Observation
- Surgery

### Observation

**A certain diagnosis of fibroid should be a must, prior to contemplating expectant management.** The risk of sarcomatous changes is so insignificant (0.1%) that prophylactic removal of fibroid is unjustified in asymptomatic cases.



**Fig. 19.9:** Cervical fibroid

#### Indications of expectant management:

- ◆ Size <12 weeks (of pregnancy size)
- ◆ Diagnosis certain
- ◆ Follow up possible

Periodic examination at interval of 6 months is needed. If the symptoms of fibroid appear and or it grows and increases in size, surgery is indicated.

#### CERVICAL FIBROID (FIGS 19.9 AND 19.10)

##### Symptoms

In nonpregnant state, the symptoms are predominantly due to pressure effect on the surrounding structures.

**Anterior cervical:** Bladder symptoms like frequency or even retention of urine are conspicuous. The retention is more due to pressure than elongation of urethra.

**Posterior cervical:** (Fig. 37.51) Rectal symptom is in the form of constipation.

**Lateral cervical:** Vascular obstruction may lead to hemorrhoids and edema legs (rare). The ureter is pushed laterally and below the tumor.

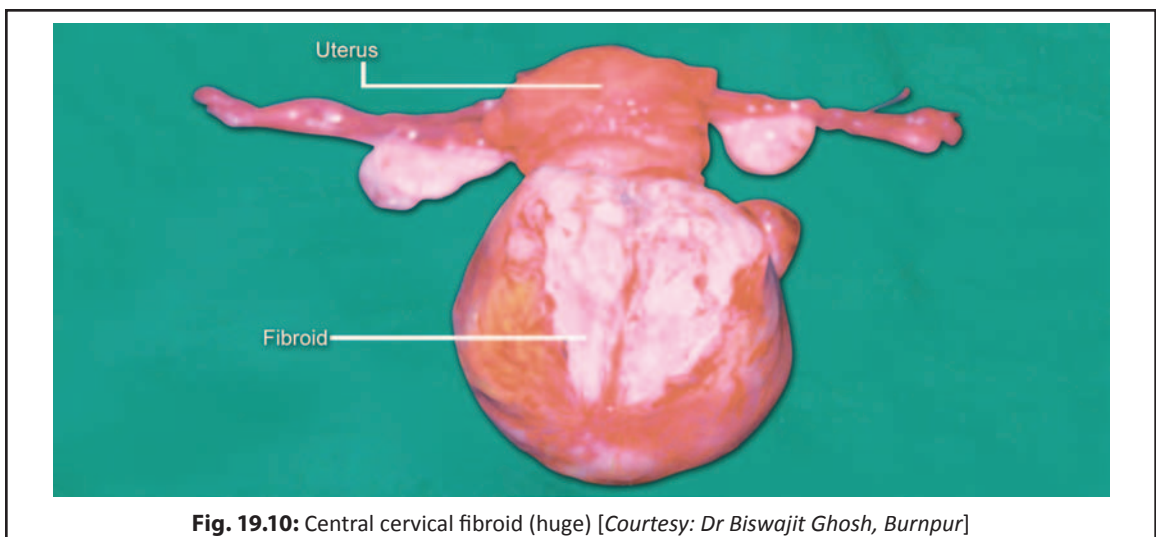
**Central cervical (Fig. 19.10):** Central fibroid produces predominantly bladder symptoms. The cervix is expanded on all sides. The uterus sits on the top of the expanded cervix (lantern on the dome of St. Paul's).

In pregnancy, it remains asymptomatic but produces insuperable obstruction during labor.

Fibroids arising from the vaginal part of the cervix may remain asymptomatic during non-pregnant state but produces obstruction during labor. If pedunculated, there may be a sensation of something coming down or if infected a foul smelling discharge per vaginum (Fig. 19.14).

##### Treatment

**Supravaginal fibroids:** Myomectomy may be tried if the patient is young and desirous of having a baby. But, it is not only technically difficult but the anatomic and functional restoration of the cervix cannot be adequate to achieve the objective of future reproduction.



**Fig. 19.10:** Central cervical fibroid (huge) [Courtesy: Dr Biswajit Ghosh, Burnpur]

As such, mostly it is dealt with by hysterectomy. **The principle to be followed is enucleation followed by hysterectomy** to minimize the injury to the ureter. Preoperative GnRH analogs administration for 3 months facilitates surgery.

**Vaginal part fibroids:** If the tumor is sessile, myomectomy and if pedunculated, polypectomy is done.

## POLYPS

Benign	Malignant
– Mucous	– De novo
– Fibroid	– Secondary changes of benign polyp
– Placental	

**Benign:** Polyp is a clinical entity referring a tumor attached by a pedicle.

**Mucous: The commonest type of benign uterine polyp is mucous one.** It may arise from the body of the uterus or from the cervix (Fig. 19.11).

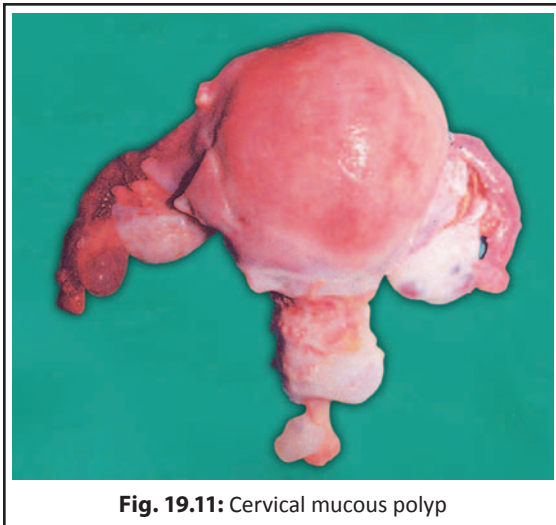


Fig. 19.11: Cervical mucous polyp

**Risk factors:** Hormone replacement therapy, tamoxifen therapy, diabetes, hypertension, obesity and increased patient age are the important risk factors.

**Pathogenesis—Body:** A part of the thick endometrium projects into the cavity and ultimately attains a pedicle.

**Naked eye appearance** shows a small polyp size of about 1–2 cm, looks reddish and feels soft. The

pedicle may at times be long enough to make the polyp protruded from the cervix.

**Microscopically** — The core contains stromal cells, glands and large thick-walled vascular channels. The surface is lined by endometrium. The tip may undergo squamous metaplasia. Malignant change is rare but may coexist with endometrial carcinoma. The pedicle contains thin fibrous tissue with thin blood vessels. Rarely, smooth muscles invade the polyp and is then called adenomyomatous polyp.

**Predictors of malignancy are:** (a) Size >10 mm (b) Postmenopausal status and (c) Abnormal uterine bleeding.

**Cervical:** The polyp mainly arises from the endocervix and rarely from the ectocervix. The stimulus of epithelial overgrowth is probably due to hyperestrogenism, chronic irritation by infection or localized vascular congestion.

Naked eye appearance shows the polyp of usually small size rarely exceeding 1–2 cm, single and red in color. The pedicle may at times be long enough to reach the vaginal introitus (Figs 19.11 and 19.13).

**Microscopically**—The stroma consists of fibrous connective tissues with numerous small blood vessels and occasional cervical glands. The lining epithelium is tall columnar like that of endocervix. The tip may undergo squamous metaplasia. Malignant change is rare and usually of squamous cell carcinoma.

**Symptoms:** There may not be any symptom. The entity is accidentally discovered during speculum examination, following hysterosalpingography (filling defect) or hysteroscopy.

**However, the following symptoms are related:**

- ♦ Irregular uterine bleeding, either pre or postmenopausal
- ♦ Contact bleeding, if the polyp is situated at or outside the cervix
- ♦ Excessive vaginal discharge which may be offensive.
- ♦ Multiple endometrial polyps may cause infertility or miscarriage in young women.

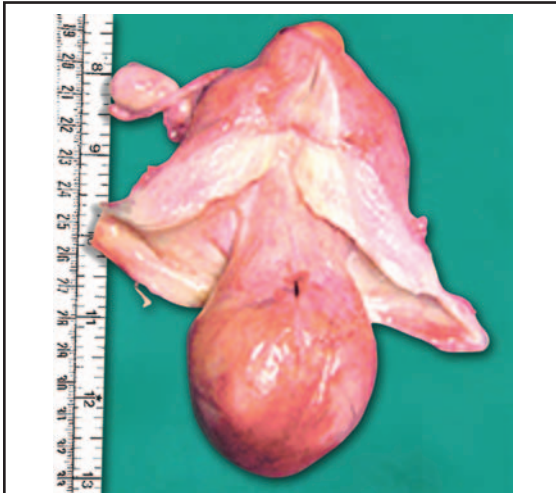
**Signs:** Unless the polyp is at or outside the external os, no positive finding is present.

However, if it protrudes out of the cervix, it feels soft, slippery and is small in size. Per speculum, it

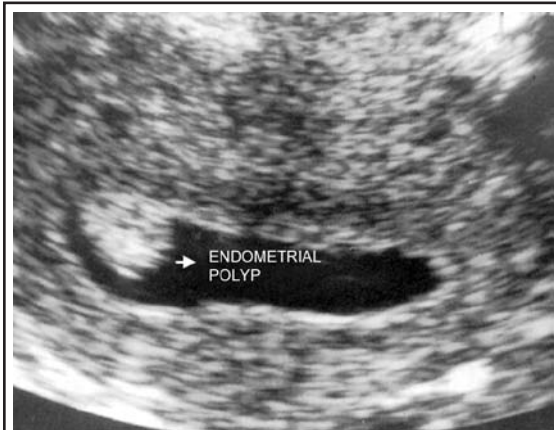looks reddish in color, usually attached with a slender pedicle.

### FIBROID POLYP

The fibroid polyp may arise from the body of the uterus or from the cervix.



**Fig. 19.12:** Fibroid polyp. Note the wide pedicle and thinning out of the cervix



**Fig. 19.13:** Sonogram (TV) of the uterus showing an echogenic area within the endometrial cavity—submucous polyp

### Pathogenesis

#### Body (Fig. 19.12)

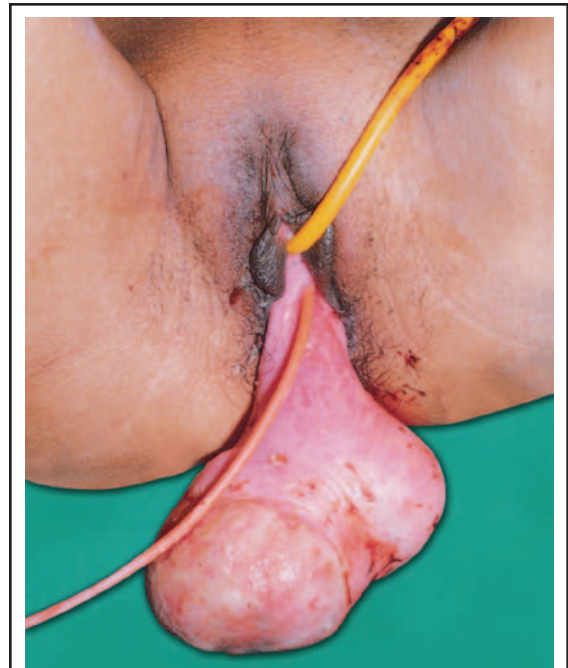
Fibroid polyp is almost always due to extrusion of a submucous fibroid into the uterine cavity. During this process, it attains a pedicle which is often broad and

usually attached to the posterior wall. The torn ends of the pseudocapsule are retracted in the base of the pedicle. The uterus contracts to expel the polyp out and as a result, the polyp may be pushed out through the cervix to lie even in the vagina.

**Naked eye** — The polyp is usually single, of varying sizes. There may be evidences of necrosis, infection and hemorrhage specially at the tip. The pedicle is broad. There may be associated other varieties of fibroids in the uterus.

**Microscopically**, the polyp including the pedicle is covered by endometrium. In the tip, there may be squamous metaplasia. The core of the polyp is composed of fibromuscular structures. The pedicle is composed of fibrous tissues with slender blood vessels.

**Cervical (Fig. 19.14):** Cervical fibroid polyp usually arises from the ectocervix and from its posterior lip. It may be small and usually single. At times, it is big enough to distend the vagina or even comes out of the introitus confusing the diagnosis of uterine inversion.



**Fig. 19.14:** Cervical fibroid polyp may be confused with inversion. *Catheters* : one in urethra and the other in the cervical canal—[By courtesy: Prof. D. Banerjee, NRSMC&H]



**Symptoms:** The patients are usually in reproductive period. The chief complaints are :

- ◆ Intermenstrual bleeding, often continuous, especially in fibroid polyp arising from the body.
- ◆ Colicky pain in the lower abdomen due to uterine contraction in an effort to expel the polyp out of the uterine cavity.
- ◆ Excessive vaginal discharge which may be offensive.
- ◆ Sensation of something coming down when the polyp becomes big distending the vagina.
- ◆ It may remain asymptomatic also.

**Signs:** General examination reveals varying degrees of anemia.

#### Per vagina

- ◆ The uterus may be bulky.
- ◆ The cervix may be patulous and the tip of the polyp is felt or else, the polyp is felt distinctly outside the external os.

**Speculum examination**—reveals the size and color of the polyp which is usually pale; may be hemorrhagic. Whereas, the attachment of the pedicle to the cervix can be visualized but attachment higher up may be at times difficult to locate (Fig. 19.11).

#### Investigations

- ◆ **Transvaginal sonography (TVS)**, the polyp is seen as an echogenic mass.
- ◆ **Saline infusion sonography** (gold standard), the polyp is seen as a echogenic mass much better compared to TVS.
- ◆ **Hysteroscopy**—to visualize the uterine polyp (Fig. 35.10) and simultaneously polypectomy could be done.
- ◆ **Hysterography**—to detect the filling defect in a fibroid polyp.
- ◆ **Examination under anesthesia** and exploration of the uterine cavity by curette or ovum or ring forceps can help in diagnosis of an uterine polyp. In all cases, following polypectomy histological examination should be done.
- ◆ **Sound test**—to differentiate a fibroid polyp from chronic inversion, sound test is done. If an uterine sound is passed all round between the pedicle and the dilating cervical canal, it is a polyp. In

complete chronic inversion, the sound cannot be passed (see Fig. 15.21).

#### Placental Polyp

A retained bit of placental tissue when adherent to the uterine wall gets organized with the surrounding blood clots.

**Clinical features:** There is history of recent childbirth or abortion. Irregular bleeding per vaginum and offensive vaginal discharge are present dated back to the pregnancy events.

#### MANAGEMENT OF A POLYP

Endometrial polyp may be removed by doing hysteroscopy and resection (p. 621, 622). It can also be removed by uterine curettage or using ring or ovum forceps. In cases of recurrence and patients who have completed the family, hysterectomy is justified. **The causes of recurrence of polyps are:** (1) Incomplete removal (2) Persistence of the cause leading to polyp formation (3) Malignancy. Cervical polyps are removed by twisting of the pedicle. The base of the pedicle should be cauterized to prevent recurrence.

**Hysteroscopy** is useful to locate the position, size and the base of the polyp. Submucous fibroid polyps can be resected out hysteroscopically as an outpatient basis (Fig. 19.8). **Endometrial polyps that cause infertility, postmenopausal bleeding or abnormal uterine bleeding should be removed hysteroscopically under direct vision.** It is superior to blind avulsion. After the polyp is removed, endometrium is curetted to rule out coexisting pathology (5%).

**Histology:** Histologically the polyp may be—adenomatous (80%), cystic, fibrous, vascular and fibromyomatous. There may be ulceration of the dependent portion of the polyp. Malignant change of an endometrial polyp is extremely rare (0.5%).

#### Big fibroid polyp lying in the vagina

One should be sure that it is a polyp and not uterine inversion or fibroid with inversion (see above).

- ▶ **Diagnosed polyp**—Removal of polyp by **morcellement** (piecemeal) followed by transfixation suture on the pedicle and removal of the redundant pedicle distal to the ligature.

- Associated with chronic uterine inversion—** The incision is made close to the fibroid and to enucleate it.

**When hysterectomy is indicated,** the polyps of such type are expected to be infected and are to be removed first. Antibiotics are to be administered. The general condition of the patient is to be improved and hysterectomy should be done at a later date.

The polyps should be sent for histological examination after its removal.

## KEY POINTS

- Fibroid is the most common pelvic tumor. The incidence of symptomatic fibroid varies from 3–10 percent. It is common in nulliparous and the prevalence is highest between 35–45 years.

Fibroid arises from the smooth muscle elements of the myometrium, could be genetically determined and the growth is dependent on the polypeptide growth factors (EGF, IGF-1, TGF) and estrogen. It is slow growing compared to ovarian neoplasm.

Fibroids may affect the reproductive outcome adversely by enlargement and distortion of the uterus, anovulation cervical or cornual black or poor endometrial vascularity.
- Corporeal fibroid is common and often multiple. All fibroids are interstitial but later on become submucous or subserous. Cervical fibroid is rare (1–2%).

Fibroid has got a false capsule formed by the compressed myometrium. The center is least vascular and degeneration is common.

Hyaline degeneration is the commonest secondary change and sarcoma is rare 0.1 percent. Red degeneration occurs mainly in pregnancy and puerperium.

Associated endometriosis and adenomyosis is found in 30 percent and pelvic infection in 15 percent.

Majority of fibroids remain asymptomatic (75%). Menorrhagia is the classic symptom of fibroid. Pelvic examination is supportive—the tumor of uterine origin. For confirmation of diagnosis, the help of sonography, laparoscopy, hysteroscopy or HSG or rarely CT, MRI may be useful in selected cases.

Life-threatening complications include—severe anemia, intraperitoneal hemorrhage from ruptured veins over the subserous fibroid, severe infection and sarcomatous changes.

There is definite place of observation in asymptomatic fibroid provided one is certain of diagnosis and follow-up is possible.
- Medical management aims mostly as palliative and the drugs used are antiprogestones, danazol, GnRH analogs (agonists and antagonists) and LNG-IUS. Benefits of preoperative GnRH analog therapy are many (see Table 19.8).

The surgical treatment of fibroid may be hysterectomy or myomectomy, depending upon the age of the patient and need for preservation of reproductive function. Indications of myomectomy may be either due to a symptomatic or due to an asymptomatic fibroid (see Table 19.10). Contraindications must be carefully judged (Table 19.12).

Laparoscopic or hysteroscopic procedures can be done with reduced morbidity.

Myomectomy is a risky operation. Prior to myomectomy, there are many important considerations (Table 19.9). There is chance of recurrence (30–50%), persistence of menorrhagia (1–5%) and relaparotomy (20–25%). Pregnancy rate following myomectomy is about 40–60 percent. Subserous and interstitial fibroids could be removed laparoscopically. Hysteroscopic resection of the submucous fibroid can be done in selected cases (Fig. 19.8).

Uterine Artery Embolization (UAE) and myolysis are the other methods of treatment (p. 283). The newest modality of management is uterine artery embolization which is an ambulatory and nonsurgical management.
- The commonest type of benign uterine polyp is a mucous one. Risk factors for polyps are: hormone replacement therapy, tamoxifen therapy or increased patient age (p. 285). A big polyp may be confused with chronic uterine inversion or may be associated with it. Malignant transformation of endometrial polyps is about 0.5%. Hysteroscopic removal of endometrial polyps is superior to blind avulsion.

# Benign Lesions of the Ovary

## OVARIAN ENLARGEMENT

- Non-neoplastic
- Neoplastic (Benign)

### NON-NEOPLASTIC

The non-neoplastic enlargement of the ovary is usually due to accumulation of fluid inside the functional unit of the ovary.

#### The causes are:

- ◆ Follicular cysts.
- ◆ Corpus luteum cyst.
- ◆ Theca lutein and granulosa lutein cysts.
- ◆ Polycystic ovarian syndrome (see p. 459).
- ◆ Endometrial cyst (chocolate cyst) — see p. 308.

Except the last one, all are functional cysts of the ovary and are loosely called cystic ovary.

#### The features of the functional cysts are:

- a. Related to temporary hormonal disorders.
- b. Rarely becomes complicated.
- c. Sometimes confused with neoplastic cyst but can be distinguished by the following features:
  - ▶ Usually 6–8 cm in diameter.
  - ▶ Usually asymptomatic.
  - ▶ Spontaneous regression usually following correction of the functional disturbances to which it is related.
  - ▶ Unilocular.
  - ▶ Contains clear fluid inside unless hemorrhage occurs.
  - ▶ Lining epithelium corresponds to the functional epithelium of the unit from which it arises.

## FOLLICULAR CYSTS

### Follicular cysts are the commonest functional cysts.

They are usually multiple and small as seen in cases of cystic glandular hyperplasia of the endometrium or in association of fibroid. Hyperestrinism is implicated as its cause. However, an isolated cyst may be formed in unruptured Graafian follicle, which may be enlarged but usually not exceeding 5 cm. The cyst is lined by typical granulosa cells without lutein cells or the cells may be flattened due to pressure (Fig. 20.1).

In majority of cases, the detection is made accidentally on bimanual examination, sonography, laparoscopy or laparotomy. The cyst may remain asymptomatic or may produce vague pain.

**Management:** A follicular cyst  $\leq 3$  cm requires no further investigations. A simple cyst,  $< 8$  cm,

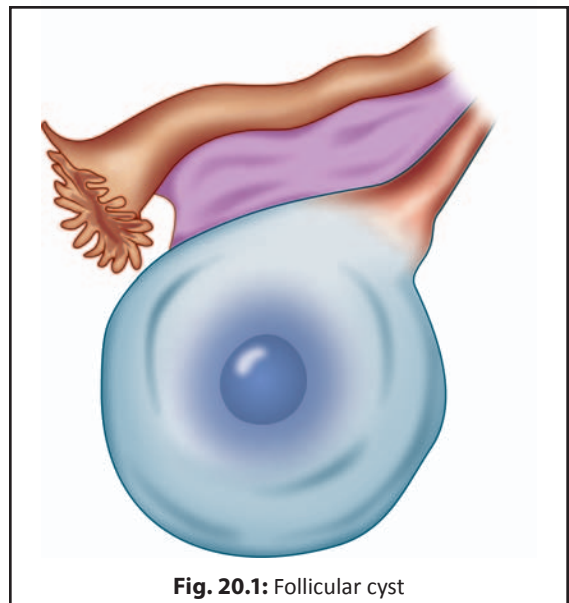


Fig. 20.1: Follicular cyst

unilocular, echo free without solid areas or papillary projections, with normal serum CA 125 (p. 377) should be followed up with repeat ultrasound in 3 to 6 months time.

Whenever a cyst persists or grow, it should be removed by laparoscopy/laparotomy.

### Corpus Luteum Cysts

Corpus luteum cyst usually occurs due to overactivity of corpus luteum. There is excessive bleeding inside the corpus luteum. In spite of the blood filled cyst, the progesterone and estrogen secretion continues. As a result, the menstrual cycle may be normal or there may be amenorrhea or delayed cycle. It is usually followed by heavy and/or continued bleeding. It is then confused with a case of **threatened abortion** or else, if the intracystic bleeding is much, it may rupture producing features of acute intraperitoneal hemorrhage with clinical picture simulating disturbed **tubal ectopic pregnancy**.

It may often be associated with pregnancy and persists for about 12 weeks. Unless complicated, spontaneous regression is expected.

If features of acute abdomen appears, laparotomy with enucleation of the cyst is to be done along with resuscitative measures as in disturbed tubal pregnancy.

These two types of cysts are rather uncommon in women taking oral contraceptive pills. As such, if the cyst persists after three months of pill therapy, it is more likely to be a neoplastic cyst.

### Lutein Cysts (Fig. 20.2)

Lutein cysts are usually bilateral and caused by excessive chorionic gonadotropin secreted in cases of gestational trophoblastic tumors. These may also be formed with administration of gonadotropins or even clomiphene to induce ovulation. These are usually lined either by theca lutein cells, called theca lutein cyst or by granulosa lutein cells, called granulosa lutein cyst.

Spontaneous regression is expected within few weeks following effective therapy of the tumors with the gonadotropin level returning back to normal.

## BENIGN OVARIAN NEOPLASMS

### INCIDENCE

The incidence of ovarian tumor amongst gynecologic admission varies from 1–3%. About 75% of these are benign.

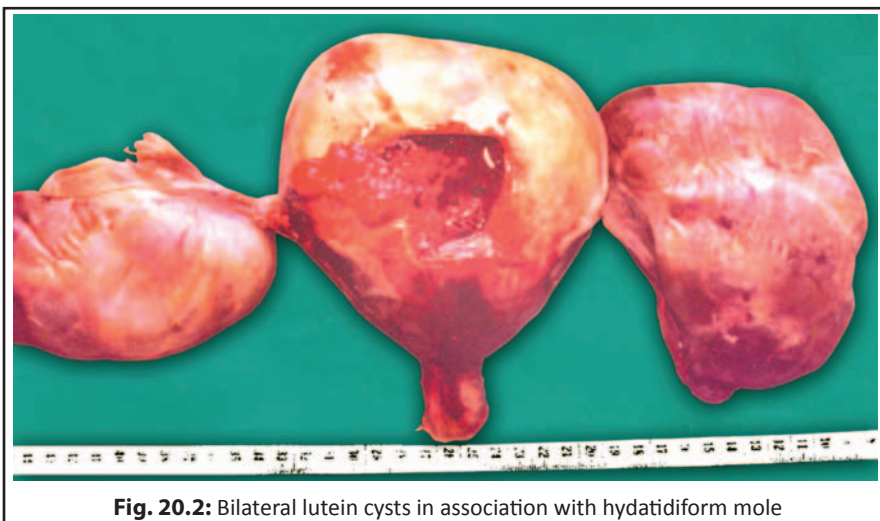
### CLASSIFICATION

The classification of ovarian tumor is unsatisfactory and full of confusion.

**The ovarian tissues are constantly in a dynamic state.** They are under the action of the gonadotropins and have got steroidogenic potentialities. Even before puberty and after menopause, the ovarian tissues remain in a dynamic state.

**The principal ovarian tissue components are:**

- ◆ Epithelial cells derived from the **celomic epithelium**.



**Fig. 20.2:** Bilateral lutein cysts in association with hydatidiform mole

**TABLE 20.1 CLASSIFICATION OF OVARIAN TUMOR****I. Epithelial tumor (60–70%)**

These tumors may be benign, borderline malignant or malignant.

- a) Serous tumor
- b) Mucinous cyst adenoma
- c) Endometrioid tumors
- d) Mesonephroid or clear cell tumors
- e) Brenner tumors
- f) Mixed epithelial tumors
- g) Undifferentiated carcinoma
- h) Unclassified epithelial tumors

**II. Sex cord stromal tumors (6–10%)**

- a) Granulosa cell tumors
- b) Tumors of thecoma-fibroma group
  - Thecoma • Fibroma • Unclassified
- c) Androblastoma
  - Sertoli cell tumor
  - Sertoli leydig cell tumor
  - Hilus cell tumor
- d) Gynandroblastoma
- e) Unclassified

**III. Lipid cell tumor****IV. Germ cell tumors of the ovary (20–25% of all primary ovarian neoplasms)**

- I. *Germ cell tumors*
  - a) Dysgerminoma
  - b) Endodermal sinus tumor
  - c) Embryonal cell carcinoma
  - d) Polyembryoma
  - e) Choriocarcinoma
  - f) Teratoma:
    - i. Immature;
    - ii. Mature (Dermoid cyst);
    - iii. Monodermal: • Struma ovarii • Carcinoid
  - g) Mixed forms (combinations of types A to F)
- II. *Tumors composed of germ cells and sex cord stromal derivatives*
  - a) Gonadoblastoma
  - b) Mixed germ cell — sex cord stromal tumor

**V. Gonadoblastoma****VI. Unclassified****VII. Secondary metastasis**

- ◆ Oocytes derived from the primitive **germ cells**.
- ◆ Mesenchymal elements from the **gonadal stroma**.

The classification given in the text is based on **WHO classification (Table 20.1)**.

Although full classification of the ovarian neoplasms has been presented, **only the benign ovarian tumors and that too, only the common varieties** will be presented in this chapter. These are:

- Mucinous cyst adenoma
- Serous cyst adenoma
- Brenner tumor
- Dermoid cyst
- Endometrioid tumors
- Clear cell tumors

These cysts constitute about 80 percent of the primary ovarian tumors and are called ovarian cysts as opposed to cystic ovaries in functional ones.

The cell types of ovarian epithelial tumors recapitulate the mullerian duct epithelium (serous from endosalpinx, mucinous from endocervix, endometrioid from endometrium).

**MUCINOUS CYST ADENOMA****Origin**

The following diverse modes of origin of mucinous cyst adenoma are described:

- ▶ It arises from the totipotent surface epithelium of the ovary.
- ▶ Its association with Brenner tumor suggests its origin as mucinous metaplasia of the epithelioid cells.

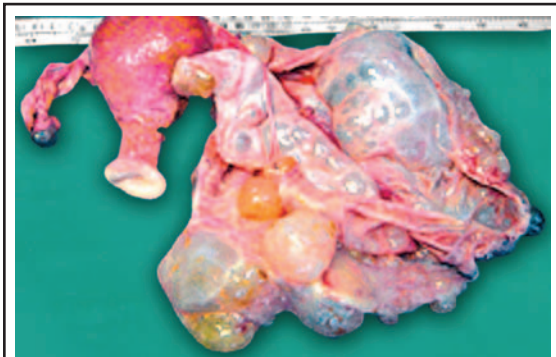**Pathology**

These are quite common and account for about 20–25 percent of all ovarian tumors. The tumors are bilateral in about 10 percent cases. The chance of malignancy is about 5–10 percent.

### Naked eye appearance

It may attain a huge size if left uncared for. In fact, **it is the largest benign ovarian tumor**.

The wall is smooth, lobulated with whitish or bluish white hue. At places, it is thin so as to be translucent.



**Fig. 20.3:** Cut section showing mucinous cyst adenoma

### On cut section

The content inside is thick, viscid, mucin — a glycoprotein with high content of neutral polysaccharides. It is colorless unless complicated by hemorrhage. The cyst is frequently multiloculated, sometimes with papillary growth arising from the septum (Fig. 20.3).

### Microscopic examination

The cyst is lined by a single layer of tall columnar epithelium with dark staining basal nucleus but without any cilia. The epithelial characteristics are like those of endocervix (Figs 20.4 and 20.5).

## SEROUS CYST ADENOMA

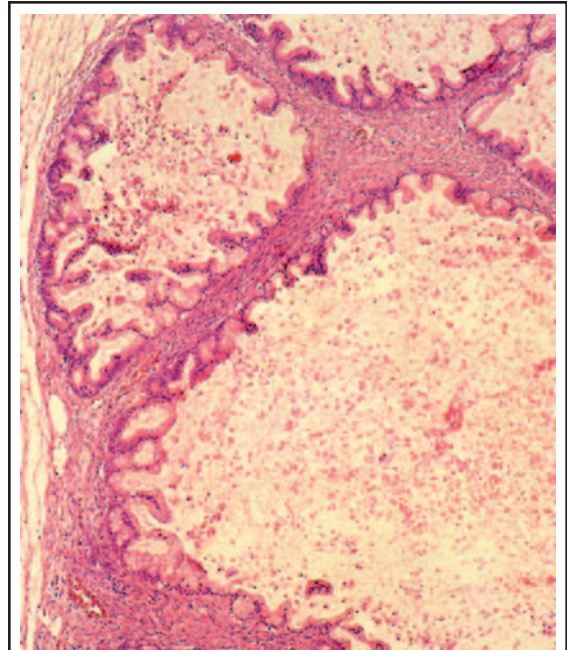
### Origin

Serous cyst arises from the totipotent surface epithelium of the ovary.

It is quite common and **accounts for about 40%** of ovarian tumors. It is **bilateral in about 40 percent** and **chance of malignancy is about 40%**.

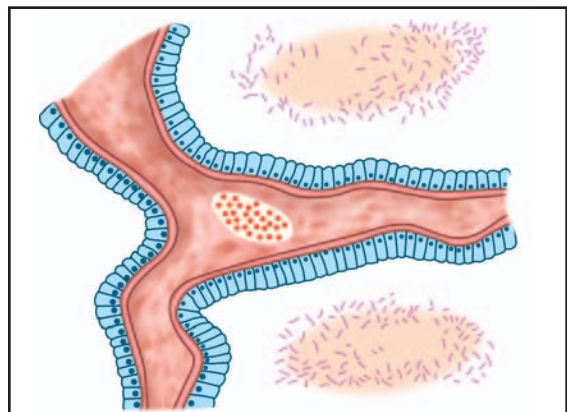
### Pathology

The cysts are not so big as that of mucinous type. As the secretion is not abundant, there is more chance of



**Fig. 20.4:** Microphotograph showing the lining epithelium of mucinous cyst adenoma. The epithelium does not invade the wall and the serosa is intact

proliferation of the lining epithelium to form papillary projection. As such, intracystic hemorrhage is more likely. Often, the papillary growth projects outwards perforating the cyst wall in about 15% cases.



**Fig. 20.5:** Diagrammatic picture showing a single layer of tall columnar epithelial cells with basal nuclei. These cells secrete mucin—mucinous cyst adenoma

### Naked eye appearance

The wall is smooth, shiny and greyish white. At times, there are exuberant papillary projection. It may be multilobulated on cut section. The content fluid is clear, rich in serum proteins—albumin and globulin.

### Microscopic examination

It is lined by a single layer of cubical epithelium.

The papillary structures consist of broad dense fibrous stroma covered by single or multiple layers of columnar epithelium. There may be presence of ciliated, secretory and peg cells resembling tubal epithelium (Fig. 20.6).

**Psammoma Bodies:** These are tiny, spherical, laminated calcified structures which are most often found in areas of cellular degeneration (15%). Its presence *per se* does not denote malignancy. It is not present in slow growing tumor.

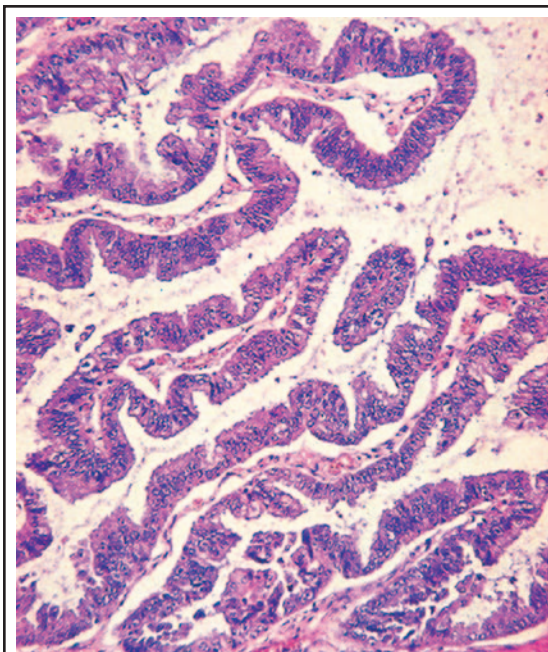
**Endometrioid tumors** are rare (5%) and consists of epithelial cells resembling those endometrium. Endometrioid carcinomas (malignant variety) may occur.

**Clear cell (mesonephroid) tumors** contain cells with abundant glycogen and are called **hobnail cells**. The nuclei of the cells protrude into the glandular lumen. They occur in women 40–70 years of age and are highly aggressive.

## BRENNER TUMOR

Brenner tumor account for 1–2 percent of all ovarian tumors, 8–10 percent are bilateral and usually seen in women above the age of 40. Majority are solid and are less than 2 cm in diameter. It usually arises from squamous metaplasia of surface epithelium. Gross picture of Brenner is similar to that of fibroma.

**Histologically islands of transitional epithelium (Walthard nests) in a compact fibrous stroma are seen. The cells look like “coffee bean” as the nuclei have longitudinal grooves.** They are usually benign in nature. Estrogen is secreted by the tumor and the woman may present with abnormal vaginal bleeding. Unilateral oophorectomy in a young woman and total hysterectomy and bilateral salpingo-oophorectomy in elderly women is the treatment choice.



**Fig. 20.6:** Microphotograph showing the lining epithelium of papillary serous cyst adenoma. The cells form long papilliform processes

## DERMOID CYST

**Origin:** Dermoid cyst arises from the germ cells arrested after the first meiotic division.

**Pathology:** Dermoid cyst constitutes about 97 percent of teratomata. Its incidence is about 30–40 percent amongst ovarian tumors. The tumor is bilateral in about 15–20 percent. It constitutes about 20–40 percent of all ovarian tumors in pregnancy. **Torsion is the most common (15–20%) and rupture is an uncommon (1%) complication. The chance of malignancy is about 1–2 percent.** Squamous cell carcinoma is the commonest.

### Naked eye appearance (Fig. 20.7)

The cyst is of moderate size. The capsule is tense and smooth. On cut section, the content is a predominantly sebaceous material with hair. There may be clear fluid (cerebrospinal fluid) derived from the neural tissues (choroid plexus). There is one area of solid projection called **Rokitansky’s protuberance** which is covered by skin with sweat and sebaceous glands. It is here that teeth and bones are found. **Histological**

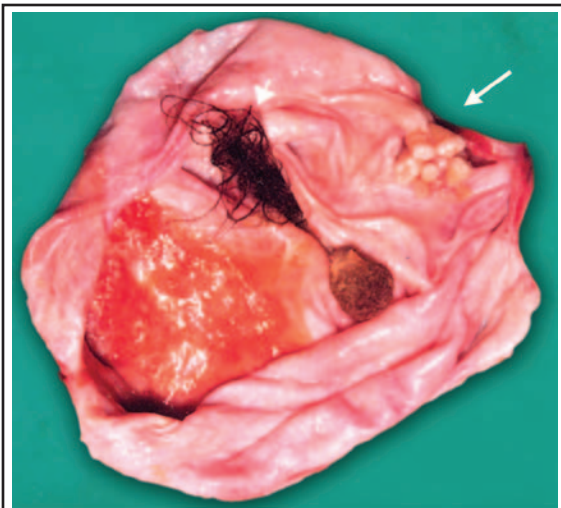
**TABLE 20.2 DIFFERENTIATION BETWEEN BENIGN AND MALIGNANT OVARIAN TUMORS**

CLINICAL EXAMINATION		LAPAROTOMY FINDINGS	
<i>Benign</i>	<i>Malignant</i>	<i>Benign</i>	<i>Malignant</i>
▶ Unilateral	Bilateral	■ Ascites—Absent	Present — often hemorrhagic
▶ Mobile	Fixed	■ Exophytic growth on surface — Absent	Present
▶ Feel — Cystic	Solid/variegated	■ Adhesions — Absent	Present
▶ Surface — Smooth	Irregular	■ Cut section — Cystic	Solid and hemorrhagic areas
▶ Ascites — Absent	Present	■ Peritoneal nodules — Absent	Present
▶ Growth — Slow	Rapid		
▶ Patient's Age — Younger	Older		
▶ Nodules in POD — Absent	Present		
DIAGNOSTIC CRITERIA OF AN OVARIAN TUMOR ON ULTRASONOGRAPHY			
<i>Benign</i>		<i>Malignant</i>	
◆ Cystic areas with uniformly thin or thick multiple linear echoes (see Fig. 20.11).		◆ Cystic areas with irregular heterogenous solid part in more than 50% total tumor volume	
◆ Color Doppler (TVS) evaluation of blood flow: Regular vascular branching and flow.		◆ Neovascularization, low resistance flow with pulsatility index <1.0	

section should be made from this area. A rare one consists predominantly of thyroid tissue — called **struma ovarii**, which may be associated with hyperthyroidism.

### MICROSCOPIC EXAMINATION

The wall is lined by stratified squamous epithelium; and at places by granulation tissue. The epithelium



**Fig. 20.7:** Cut section of a dermoid cyst showing hair and teeth

may be transitional or columnar. **The most common tissue elements are ectodermal.**

The terminology of ‘dermoid cyst’ is misnomer, as apart from ectodermal element, there may be endodermal and mesodermal tissues as well. Besides dermal components bone, cartilage, neural tissue, thyroid and salivary gland tissues are often present.

### STRUMA OVARIII AND STRUMAL CARCINOIDS

Rarely ovarian teratomas contain a specialized tissue type. **Struma ovarii is composed of thyroid tissue.** This accounts for less than 3% of **mature teratomas.** Malignant changes in a struma ovarii is extremely rare. **Strumal carcinoids** are also rare teratomas. Primary carcinoid tumors of the ovary account for less than 5% of ovarian teratomas. These tumors may be **hormonally active with secretion of serotonin, bradykinin and other peptide hormones from the argentaffin cells** as found in gastrointestinal tract or bronchial tissues. **Carcinoid syndrome** is characterized by episodic facial flushing, abdominal pain, diarrhea and bronchospasm. Metastatic carcinoid tumors are often bilateral. Carcinoid syndrome is more common in metastatic carcinoid than in ovarian primaries.



## CLINICAL FEATURES OF BENIGN TUMORS

**Age:** Benign tumors predominantly manifest in the late childbearing period. However, dermoid (90%) specially with mucinous cyst adenoma, is common in the reproductive period. As such, the dermoid is more common during pregnancy (10 percent).

**Parity:** There is no correlation with parity of the patient (c.f. Fibroid — more related with nulliparity).

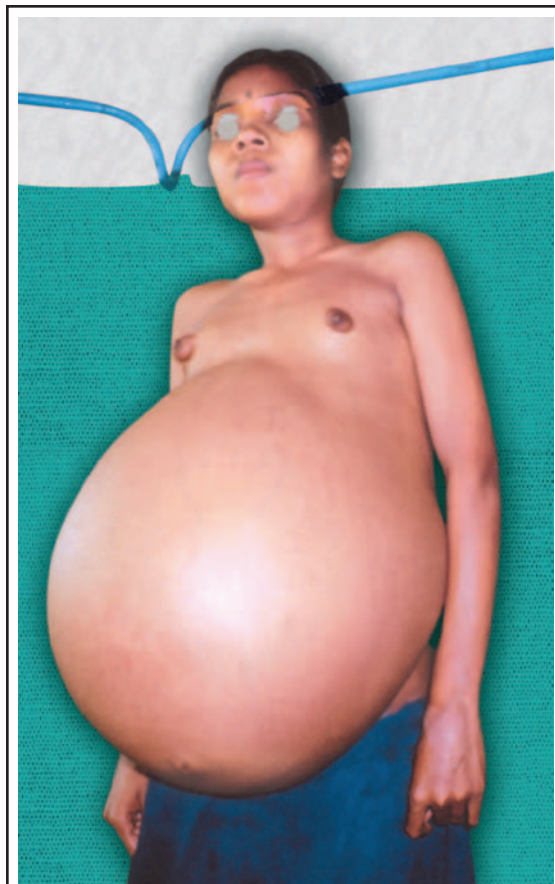■ **Symptoms:** Most tumors are asymptomatic. These are detected accidentally by a general physician to find a lump in the lower abdomen during routine abdominal palpation or by a gynecologist to find a tumor during pelvic examination, laparoscopy or laparotomy.

However, the patient may present the following symptoms:

- Heaviness in the lower abdomen.
- A gradually increasing mass in lower abdomen (ovarian tumor grows in months — c.f. fibroid).
- Dull aching pain in lower abdomen.
- In neglected cases, the tumor may be big enough to fill whole of the abdomen. It then produces cardiorespiratory embarrassment or gastrointestinal symptoms like nausea or indigestion.
- **Menstrual pattern remains unaffected unless associated with hormone producing tumors** — menorrhagia or postmenopausal bleeding or precocious puberty in feminizing tumor-like granulosa cell tumor or amenorrhea in masculinizing tumor-like Sertoli-Leydig cell tumor (p. 386).

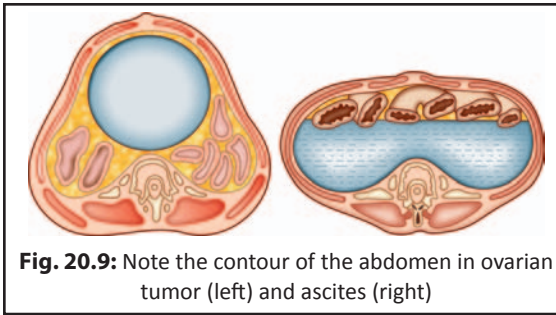
### ■ Signs

- ▶ **General condition** remains unaffected. However, in huge mucinous cyst adenoma, the patient may be cachectic due to protein loss (Fig. 20.8).
- ▶ **Pitting edema** of legs may be present when a huge tumor presses on the great veins.
- ▶ **Abdominal examination:** An ovarian tumor which is enlarged sufficiently so as to occupy the lower abdomen presents with the following:



**Fig. 20.8:** Marked enlargement of the abdomen due to a huge mucinous cyst adenoma [Courtesy: Dr A Halder, Asst Professor, Obstetrics Gynecology, NB Medical College, Sushrutnagar, Darjeeling].

- ▶ **Inspection:** There is bulging of the lower abdomen over which the abdominal wall moves freely with respiration. The mass may be placed centrally or in one side. At times, the mass fills the entire abdominal cavity everting the umbilicus with visible veins under the skin; the flanks remain flat (c.f. Flanks are full with ascites) (Fig. 20.9).
- ▶ **Palpation**
  - ◆ Feel is cystic or tense cystic. Benign solid tumors such as fibroma, thecoma, Brenner tumor are rare.



**Fig. 20.9:** Note the contour of the abdomen in ovarian tumor (left) and ascites (right)

- ◆ Freely mobile from side to side but restricted from above down unless the pedicle is long. Too big a tumor or adhesions make its mobility restricted.
- ◆ Upper and lateral borders are well-defined but the lower pole is difficult to reach suggestive of pelvic origin. However, with long pedicle, the tumor may be displaced upwards so as to reach the lower pole.
- ◆ Surface over the tumor is smooth but often grooved in lobulated tumor.
- ◆ It is usually not tender.
- ▶ **Percussion (Fig. 20.9):** Percussion note is dull in the center and resonant in the flanks (c.f. In ascites — just the opposite). A fluid thrill may be elicited when the walls are thin and the content is watery. Co-existing ascites may be present even in a benign solid tumor (fibroma) and is called Meigs' syndrome.

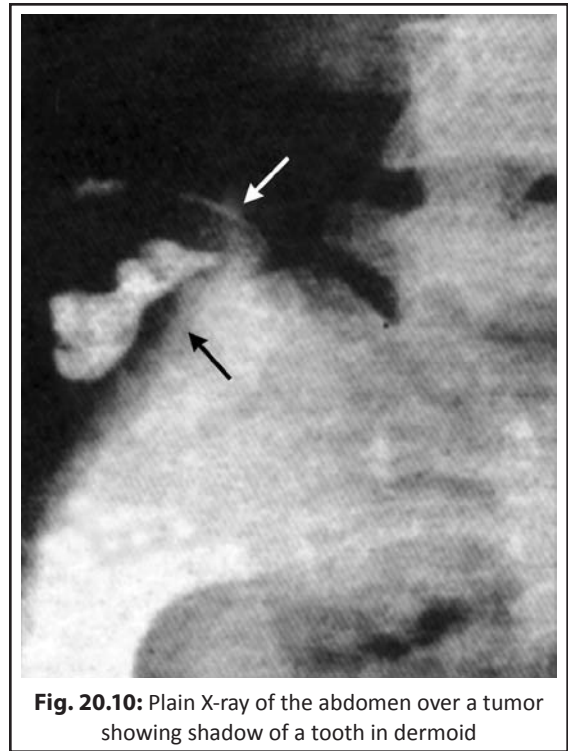
**Meigs' syndrome:** Ascites and right side hydrothorax in association with fibroma of the ovary, Brenner, thecoma and granulosa cell tumor is called Meigs' syndrome (p. 652). There is spontaneous remission of ascites and hydrothorax on removal of the tumor. Ascites and hydrothorax when present in conditions other than those mentioned above, are called pseudo-Meigs' syndrome.

**Auscultation:** A friction rub may be present over the tumor (Hissing sound over a vascular fibroid, gargling sound in ascites and FHS over a pregnant uterus).

#### ▶ Pelvic examination

##### **Bimanual examination reveals (Fig. 9.10)**

- ◆ The uterus is separated from the mass.
- ◆ A groove is felt between the uterus and the mass.



**Fig. 20.10:** Plain X-ray of the abdomen over a tumor showing shadow of a tooth in dermoid

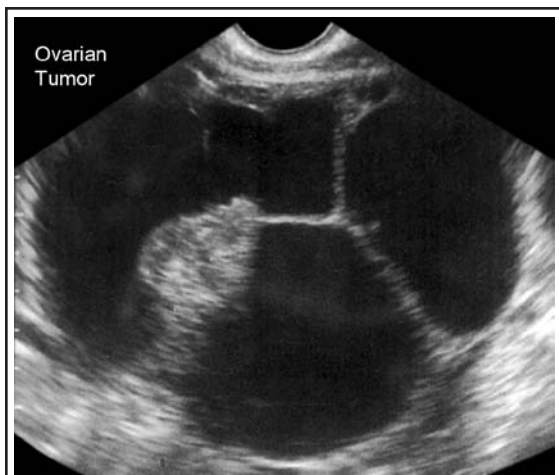- ◆ Movement of the mass per abdomen fails to move the cervix (p. 108).
- ◆ On elevation of the mass per abdomen, the cervix remains in stationary position (p. 108).
- ◆ The lower pole of the cyst can be felt through the fornix.
- ◆ Absence of pulsation of the uterine vessels through the fornices.

It is indeed difficult to identify a huge cyst even by bimanual examination as the findings are all obscured. It is also difficult to foretell from which side the tumor arises. However, with elevation of the tumor per abdomen, the stretched pedicle may be felt through the corresponding fornix. **If a cyst is felt lying anterior to the uterus, it is more likely to be dermoid.**

#### ■ Special Investigations

If the clinical features are equivocal, the following may be employed to substantiate the diagnosis.

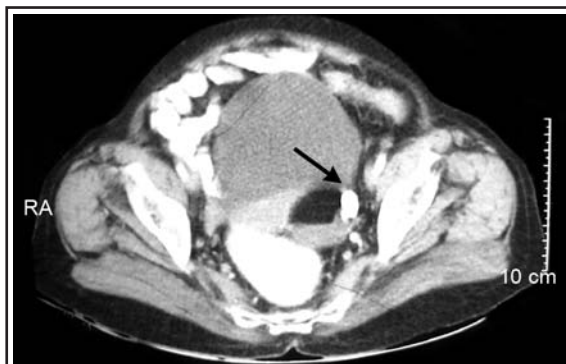- ▶ **Sonography (Fig. 20.11)** — It can identify the uterus and the tumor in the same scan. Transvaginal sonography with color flow



**Fig. 20.11:** Sonography (TV) of a benign ovarian cyst—multilocular with thin septum

Doppler gives information about the tumor volume, cyst wall, septa and the vascularity. Presence of the following ultrasonographic features suggest the high risk of malignancy: (1) Multilocular cyst. (2) Presence of solid areas. (3) Metastasis. (4) Ascites and (5) Bilateral tumors.

- ▶ **CT — (Fig. 20.12).** The presence of an adnexal mass with mixed attenuation due to the presence of large amount of fat, calcification and tooth.
- ▶ **MRI —** is helpful to determine whether the cyst is likely to be benign or malignant. It is not done as a routine.



**Fig. 20.12:** CT scan shows a typical benign cystic teratoma containing fat, dental elements (arrow) and a fat-fluid level (p. 651)

- ▶ **Serum CA 125 —** (see p. 377).
- ▶ **EUA —** In doubtful diagnosis especially in virgins, EUA is helpful.
- ▶ **Laparoscopy —** This is of help to differentiate a painful cystic mass with disturbed ectopic pregnancy.
- ▶ **Straight X-ray of the abdomen over the tumor —** The finding of a shadow of teeth or bones is a direct evidence of a dermoid cyst. An outline of a soft tissue shadow may also be visible (Fig. 20.10).
- ▶ **Laparotomy —** If the clinical and ancillary aids fail to diagnose the mass, laparotomy is justified to arrive at a diagnosis. This is especially indicated when a suspected functional cyst fails to regress in follow up.
- ▶ **Cytology —** When the patient presents with ascites or pleural effusion, cytological examination of the aspirated fluid is done for malignant cells. Ultrasound guided cyst aspiration for cytological diagnosis of malignancy is not recommended.

#### DIFFERENTIAL DAGNOSIS OF A BENIGN OVARIAN TUMOR

An ovarian tumor, apparently uncomplicated, may be confused (depending upon its size) with the following (see also p. 569):

- ◆ Full bladder
- ◆ Pregnancy
- ◆ Fibroid
- ◆ Chocolate cyst of the ovary (see p. 308, 312)
- ◆ Encysted peritonitis
- ◆ Ascites
- ◆ Functional ovarian cyst
- ◆ Pregnancy with fibroid.

**Full bladder:** Always examine the patient with the bladder empty; if necessary following catheterization. One should not be confused with overflow incontinence in chronic retention as normal urination, as stated by the patient.

**Pregnancy:** A pregnancy of 16–18 weeks is very much deceptive and one should be very much careful to exclude pregnancy during childbearing period irrespective of the status of the women. If necessary, the help of X-ray or sonar may be taken. If none

is available, it is a sound policy to re-examine the patient after 4 weeks when all the diagnostic features of pregnancy will be clinically evident.

**Fibroid:** Confusion arises especially in cases of pedunculated subserous fibroid more so, if degeneration occurs. Sonar or laparoscopy may be helpful. However, in either condition laparotomy is indicated when the diagnosis can be made.

**Chocolate cyst of the ovary** (see p. 312).

**Encysted peritonitis:** There may be features of tubercular affection elsewhere or in the abdomen. The encysted mass is usually irregular, not movable with ill-defined margins and usually situated high up. Pelvic examination usually gives a negative finding.

**Ascites:** There is fullness of the flanks. On percussion, flanks are dull with resonance in the center. There may be presence of fluid thrill and positive shifting dullness. On auscultation, there is absence of any rub sound unlike in ovarian tumor.

Sometimes, the ovarian tumor is so big as in mucinous cyst adenoma, that it is difficult to differentiate by clinical examination alone. In such cases, abdominal paracentesis and examination of the fluid can give a clue in the diagnosis.

**Functional cyst:** These cysts are small and re-examination after 12 weeks solves the diagnosis

in most cases. The follicular or corpus luteum cyst usually regresses, while neoplastic cyst usually increases in size. Laparoscopy is of help.

**Pregnancy with fibroid:** In such condition, the pregnant uterus feels more soft and cystic but the fibroid feels little firm. As such, the former is confused as ovarian cyst and the latter one as uterus. Sonar can differentiate and prevent an unnecessary laparotomy with mistaken diagnosis of pregnancy with ovarian cyst.

### COMPLICATIONS OF BENIGN OVARIAN TUMORS

- ◆ Torsion of the pedicle (axial rotation)
- ◆ Intracystic hemorrhage
- ◆ Infection
- ◆ Rupture
- ◆ Pseudomyxoma peritonei
- ◆ Malignancy (Table 20.5)

### TORSION OF THE PEDICLE (AXIAL ROTATION)

TABLE 20.3

#### STRUCTURES FORMING THE OVARIAN PEDICLE (FIG. 20.13)

##### Laterally

- ◆ Infundibulopelvic ligament containing structures therein, i.e. ovarian vessels, nerves and lymphatics.

##### Medially

- ◆ Ovarian ligament.
- ◆ Medial end of the Fallopian tube.
- ◆ Mesosalpinx containing utero-ovarian anastomotic vessels.

##### Middle

- ◆ Broad ligament.

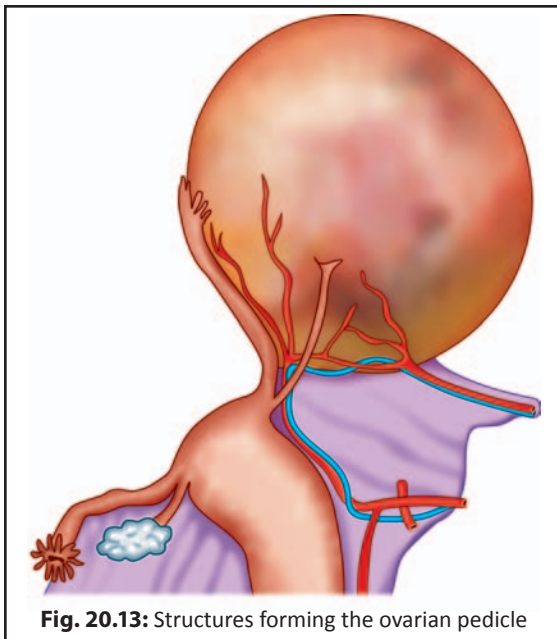


Fig. 20.13: Structures forming the ovarian pedicle

The axial rotation is found in about 10–15 percent cases at operation. It is common in tumor having:

- Moderate size, preferably with round contour.
- Moderate weight as *dermoid cyst* (due to high fat content).
- Free mobility.
- Long pedicle.

As such, **the complication is more common in dermoid or serous cystadenoma. The etiology of torsion of the pedicle is obscure.**

**Predisposing factors for Torsion:**

- Trauma.
- Violent physical movements.
- Contractions of pregnant uterus.
- Intestinal peristalsis.

These probably initiate axial rotation.

**Precipitating factor:** The hemodynamic theory is perhaps most satisfactory to explain the final onslaught of torsion. Slight axial rotation of the pedicle → venous occlusion and partial arterial compression → intermittent forcible arterial pulsation → further aggravating the axial rotation until it becomes complete. The rotation occurs usually towards midline. Torsion leads to ischemia and tissue necrosis (Fig. 20.15).

**Fate:** The partial torsion may often untwist spontaneously but if complete torsion of few turns occur, there is obstruction of both the veins and arteries. As a result, there is intense venous congestion with extravasation of blood inside the cyst. The cyst becomes tense and may rupture or else, the intestine may adhere to the gangrenous cyst, which may be infected; the organisms are derived from the gut or from the uterine tube. Rarely, the pedicle may be detached; the **tumor gets its nourishment from some other abdominal structures to which it is adherent (parasitic tumor)**.

**The clinical presentation** depends on the extent of interference with ovarian blood supply. With complete vascular occlusion, the pain will be severe. **The lump** may be present before or manifested with pain.

**Abdominal examination** reveals a tender, tense cystic mass, with restricted mobility, situated in the hypogastrum and arising from the pelvis.

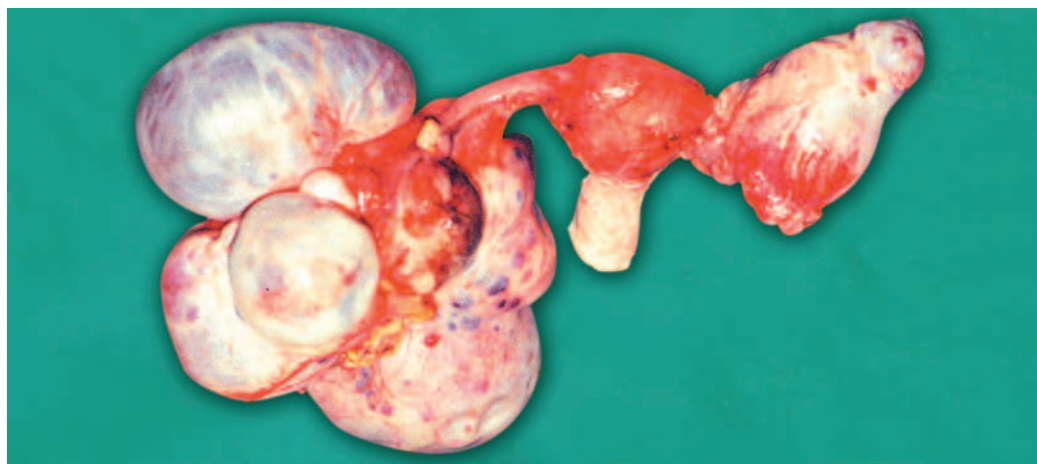
**Pelvic examination** reveals the mass felt per abdomen is separate from the uterus.

Ultrasonography.

**TABLE 20.4****SUMMARY OF TORSION OF OVARIAN PEDICLE**

- ▶ Common in dermoid or simple serous cyst.
- ▶ Partial axial rotation followed by complete torsion.
- ▶ Symptoms of acute hypogastric pain with a lump.
- ▶ General condition remains unaffected.
- ▶ Abdominal examination: a tense cystic tender mass in the hypogastrum arising from the pelvis.
- ▶ Pelvic examination: mass is separate from the uterus.
- ▶ Treatment : Laparotomy/Laparoscopy and ovariectomy.

**Treatment:** To control pain, morphine 15 mg IM is given. Laparotomy is to be done at the earliest. The definitive surgery is usually ovariectomy (salpingo-oophorectomy) as the structures usually become gangrenous. The clamps are placed prior untwisting the pedicle to minimize dislodgement of the thrombi.



**Fig. 20.14:** Bilateral ovarian tumor in a perimenopausal woman treated by total hysterectomy with bilateral salpingo-oophorectomy

However, for better grip, clamps may be placed after untwisting the pedicle (Table 20.3).

**Intracystic Hemorrhage:** It is more common in serous cyst adenoma with papillary varieties. Intracystic hemorrhage also occurs following venous congestion due to axial torsion of the pedicle and also in malignant changes.

**Infection:** Infection is common following torsion. The organisms are derived from the intestines or uterine tubes when they are adherent to the cyst.

**Rupture:** Rupture of the cyst usually follows in big and tense cysts with degeneration of a part of cyst wall. The rupture also occurs following intracystic hemorrhage or direct trauma, in papillary variety or in malignancy.

**Pseudomyxoma Peritonei:** It is a condition of mucinous ascites usually secondary to mucinous tumor of intra-abdominal organ. Its exact nature of origin is not known. **But it is often associated with mucinous cyst adenoma of the ovary, mucocele of the appendix and gallbladder and intestinal malignancy.**

Spontaneous perforation of mucinous cyst may lead to implantation of the cells of low grade malignancy on the peritoneum. Or else, the mesothelium of the peritoneum is converted to high columnar epithelium with secretory activity. The cell type is similar to mucinous cyst adenoma.

Even after removal of the ovarian tumor, these cells continue to secrete mucin. There is a tendency of recurrence. *The prognosis is poor due to inanition, infection and intestinal obstruction.* Treatment remains unsatisfactory.

*Hysterectomy, bilateral salpingo-oophorectomy* with removal of mucin, peritoneal implants along with appendix is recommended. Recurrence is high unless implants are removed entirely.

**Malignancy:** The malignancy rate varies (see Table 20.5). **The malignant potentiality is maximum in serous cyst adenoma especially of papillary variety and least in dermoid.** The former gives rise to adenocarcinoma and the latter to squamous cell carcinoma.

TABLE 20.5

COMMON EPITHELIAL OVARIAN TUMORS AND THEIR FREQUENCY (%)

Type	All ovarian neoplasm	Ovarian cancers
Serous	20 – 40	30 – 40
Mucinous	20 – 25	5 – 10
Endometrioid	5	15 – 20
Brenner	1 – 2	Rare

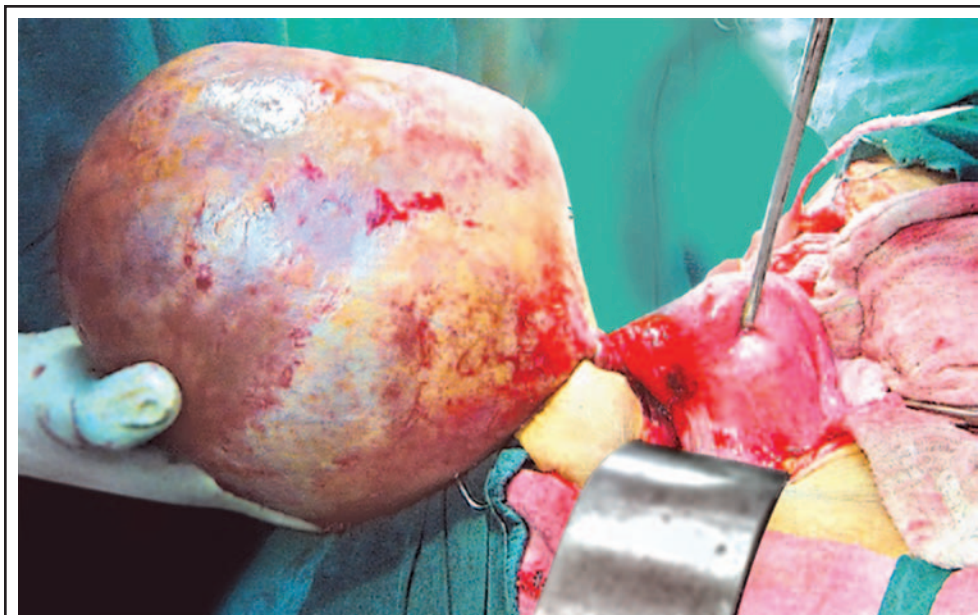
## MANAGEMENT OF A BENIGN OVARIAN TUMOR

Once an ovarian tumor is diagnosed, the patient should be admitted for operation — sooner the better. This is because, **the complication can occur at any time and the nature of the tumor cannot be assessed clinically.** A clinically benign tumor may turn into a malignant one at operation. In others, even a benign tumor removed may be proved malignant on histological examination.

Differentiation between benign and malignant ovarian tumors could be made by clinical examination, ultrasonography, laparotomy and finally by biopsy (see p. 294).

### Guidelines for Surgery in an Apparently Benign Tumor

- **Incision** should be vertical paramedian sufficiently big enough to deliver the cyst intact. An attempt to tap a cyst to minimize its size and to deliver it with a small incision is to be condemned. The content may be mucinous, sebaceous material, infective or malignant fluid which contaminates the peritoneal cavity. The longitudinal incision also allows adequate exposure in the upper abdomen.
- **To inspect** the nature of the peritoneal fluid — clear, straw color, hemorrhagic or infective. A sample of the fluid or peritoneal washings should be sent for cytological examination.
- **To deliver the tumor** intact and to note it carefully about its nature (see Table 20.2 on p. 294).



**Fig. 20.15:** Torsion of the pedicle of an ovarian tumor. Note the turns in the pedicle and stretched Fallopian tube

- **To inspect and to palpate** the other ovary, pelvic organs, omentum, liver, under surface of diaphragm and para-aortic group of lymph glands.
- **To proceed** for the definitive surgery (see below).
- **To cut the tumor** and inspect the inner side for any evidence of malignancy. In suspected cases, the facility of frozen section is invaluable (Table 20.2 on p. 294).
- It is not prudent to bisect the contralateral ovary, if it looks absolutely normal.

### DEFINITIVE SURGERY

#### In young patients

- Ovarian cystectomy leaving behind the healthy ovarian tissue is the operation of choice.
- Ovariectomy (salpingo-oophorectomy) is reserved for a big tumor that has destroyed almost all the ovarian tissues or for a gangrenous cyst.
- If both the ovaries are involved, ovarian cystectomy should be done at least in one ovary.
- Retention of the uterus for possible ART may be considered when bilateral ovariectomy has to be done.

#### In parous women around 40 years

- Total hysterectomy with bilateral salpingo-oophorectomy is to be done (Fig. 20.14).

#### In between these two extremes of age

Individualization is to be done as regards the nature of surgery. Due consideration is to be given about the reproductive and menstrual function.

In all cases, the entire tumor is to be sent for histological examination. If a part is to be sent, **a small piece from the comparatively solid or thick capsule is to be selected.**

### BORDERLINE EPITHELIAL TUMORS OF THE OVARY

Borderline malignant epithelial tumors have got some but not all the features of malignancy. They are of low malignant potential. The characteristic features are:

- ◆ They constitute 10–20% of all epithelial tumors of the ovary.
- ◆ These tumors are intermediate in position between benign and the malignant in term of histology and prognosis.

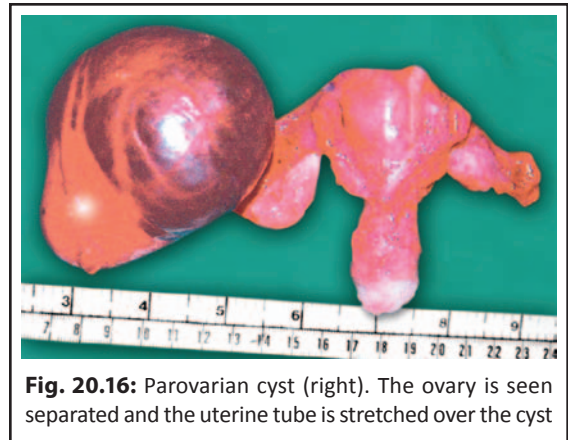
- ◆ Formation of microscopic papillary projections.
- ◆ There is stratification of epithelial cells of the papillae.
- ◆ There is epithelial cell pleomorphism.
- ◆ Presence of papillary projection on the external surface.
- ◆ Detachment of cellular clusters from the sites of origin.
- ◆ Increased cellular mitotic activity.
- ◆ Presence of nuclear atypia of varying degrees.
- ◆ No invasion of ovarian stroma.
- ◆ Generally found in the younger age group and carry good prognosis.

**Treatment:** Unilateral oophorectomy is optimum specially for the young women. When there is bilateral ovarian involvement or peritoneal spread, total hysterectomy with bilateral salpingo-oophorectomy and excision of the involved peritoneum are done. Risk of recurrence is low.

### PAROVARIAN CYST (FIG. 20.16)

Parovarian cyst may **arise either from the vestigial remnants of Wolffian in the mesosalpinx or from the peritoneal inclusions or from tubal epithelium (Fig. 20.16).**

The ovary is separated and the uterine tube is stretched over the cyst. The cyst is unilocular; the wall



**Fig. 20.16:** Parovarian cyst (right). The ovary is seen separated and the uterine tube is stretched over the cyst

is thin and contains clear fluid. The wall consists of connective tissue lined by a single layer of cuboidal or flat epithelium. There may be a thin muscle tissue along with secretory epithelium suggesting tubal origin.

The cysts are always benign. The **presenting features are like those of benign ovarian tumor. It can undergo torsion like that of ovarian tumor (Fig. 37.64).**

Removal of the tumor, when it burrows in the broad ligament, needs a cautious approach as the ureter is either placed at the bottom or on the top of the cyst. An incision is made anterior and parallel to the round ligament (see Fig. 34.8). Enucleation of the tumor is done leaving behind the ovary. Hemostasis at the base is achieved by ligature taking care not to injure the ureter.

### KEY POINTS

- The functional cysts of the ovary are predominantly follicular cyst and corpus luteum cyst. Follicular cysts are the most common and the initial management is conservative. Treatment of unruptured corpus luteum cyst is conservative.
- Ovarian cystic mass 8 cm or more after menopause or before puberty or a solid tumor at any age indicates laparotomy.
- Theca lutein cysts are due to excessive gonadotropin (endogenous or exogenous) stimulation of the ovaries. Fifty percent of molar pregnancies and 10 percent of choriocarcinomas have associated bilateral theca lutein cysts (p. 363). They usually regress spontaneously with normalization of serum hCG level.
- The following criteria must be fulfilled for conservative management of an ovarian cyst : (i) Asymptomatic. (ii) Unilateral. (iii) Size < 8 cm. (iv) Unilocular cyst without any solid area. (v) Normal CA 125. (vi) No ascites. Followed by — (vii) Ultrasound re-examination at 3-6 months time.

*Contd...*



Contd...

- ▶ Mucinous cyst adenoma accounts for 20-25% of all ovarian tumors. They are bilateral in 10% and chance of malignancy is 5-10%.

The content is mucin — a glycoprotein with high content of neutral polysaccharides.

It is lined by tall columnar epithelium with deep stained basal nucleus without cilia, the structure like that of endocervix.

- ▶ Serous cyst adenoma accounts for 40% of ovarian tumors. It is bilateral in 40% and chance of malignancy is about 40%.

It is lined by cubical epithelium. In papillary type, the lining epithelium is like that of Fallopian tube.

- ▶ Dermoid cyst accounts for 15-20% amongst ovarian tumors. It is bilateral in 15-20 percent. Chance of malignancy is least — 1-2%. If an ovarian cyst is lying anterior to uterus, it is likely to be dermoid.

- ▶ Fibromas are most common benign, solid tumours of the ovary. They have low malignant potential (Table 20.5)

- ▶ Meigs' syndrome is ascites and hydrothorax in association with fibroma of the ovary.

- ▶ Ovarian tumor is commonly confused with full bladder, pregnancy, fibroid or ascites.

- ▶ Torsion of the pedicle is the commonest complication of benign cystic ovarian tumor and the rarest one is malignancy.

Pseudomyxoma peritonei is usually associated with mucinous cyst adenoma of the ovary, mucocele of the appendix and gallbladder and intestinal malignancy.

- ▶ The malignancy is highest in papillary variety of serous cyst adenoma being adenocarcinoma and lowest one in dermoid being squamous cell carcinoma (see Table 20.5).

- ▶ In young women, conservative surgery, either ovarian cystectomy or ovariectomy (oophorectomy) is to be done. In patient around 40 years and above, total hysterectomy with bilateral salpingo-oophorectomy is justified.

- ▶ Borderline epithelial tumors of the ovary are of low malignant potential. Though there is cellular mitotic activity and nuclear atypia (see p. 305), stromal invasion is absent. Unilateral oophorectomy is the optimum treatment specially for a young woman. In elderly women total hysterectomy, bilateral salpingo-oophorectomy and omentectomy are done. Chemotherapy is not usually considered following surgery.

- ▶ 5 years survival rate for patients with borderline epithelial ovarian cancer (grade O) is close to 100%.

- ▶ In all cases, the tumor is subjected to histopathological study to note the nature of the tumor and to exclude malignancy.

# Endometriosis and Adenomyosis

## ENDOMETRIOSIS

### DEFINITION

**Presence of functioning endometrium (glands and stroma) in sites other than uterine mucosa is called endometriosis.** It is not a neoplastic condition, although malignant transformation is possible.

These ectopic endometrial tissues may be found in the myometrium when it is called endometriosis interna or **adenomyosis**. More commonly, however, these tissues are found at sites other than uterus and are called endometriosis externa or generally referred to as endometriosis.

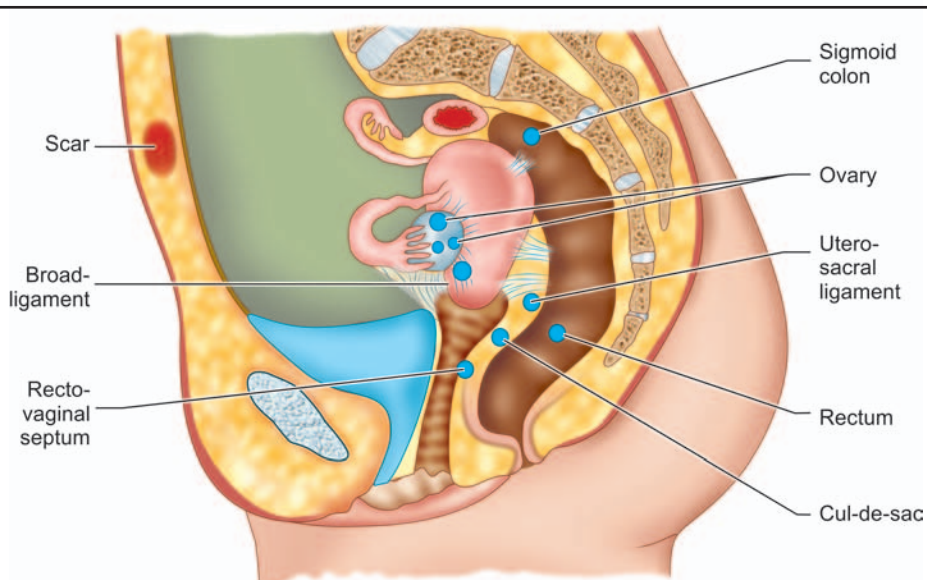
**Endometriosis is a disease of contrast. It is a benign but it is locally invasive, disseminates**

widely. Cyclic hormones stimulate growth but continuous hormones suppress it.

### PREVALENCE

During the last couple of decades, the prevalence of endometriosis has been increasing both in terms of real and apparent. **The real one** is due to delayed marriage, postponement of first conception and adoption of small family norm. **The apparent one** is due to increased use of diagnostic laparoscopy as well as heightened awareness of this disease complex amongst the gynecologists.

The prevalence is about 10 percent. However, prevalence is high amongst the infertile women (30–40%) as based on diagnostic laparoscopy and laparotomy.



**Fig. 21.1:** Common sites of endometriosis

**SITES (Table 21.1)**♦ **Abdominal** ♦ **Extra-abdominal** ♦ **Remote**

**Abdominal:** It can occur at any site but is usually confined to the abdominal structures below the level of umbilicus.

**Extra-abdominal:** The common sites are abdominal scar of hysterotomy, cesarean section, tubectomy and myomectomy, umbilicus, episiotomy scar, vagina and cervix.

Common sites	Rare and remote sites
♦ Ovaries	• Umbilicus
♦ Pelvic peritoneum	• Abdominal scar
♦ Pouch of Douglas	• Episiotomy scar
♦ Uterosacral ligaments	• Lungs
♦ Rectovaginal septum	• Pleura
♦ Sigmoid colon	• Ureter
♦ Appendix	• Kidney
♦ Pelvic lymph nodes	• Arms • Legs
♦ Fallopian tubes	• Nasal mucosa

**PATHOGENESIS** still remains unclear and is full of theories. **The principal ones are:**

**Retrograde Menstruation (Sampson's theory)**

There is retrograde flow of menstrual blood through the uterine tubes during menstruation. The endometrial fragments get implanted in the peritoneal surface of the pelvic organs (dependent sites, e.g. ovaries, uterosacral ligaments). Subsequently, cyclic growth and shedding of the endometrium at the ectopic sites occur under the influence of the endogenous ovarian hormones. Retrograde menstruation *per se* is unlikely to produce endometriosis. Probably, a genetic factor or favorable hormonal milieu is necessary for successful implantation and growth of the fragments of endometrium. While this theory can explain pelvic endometriosis, it fails to explain the endometriosis at distant sites.

**Coelomic metaplasia (Meyer and Ivanoff)**

Chronic irritation of the pelvic peritoneum by the menstrual blood may cause coelomic metaplasia which results in endometriosis. Alternatively, the müllerian tissue remnants may be trapped within the peritoneum. They could undergo metaplasia and be transformed into endometrium.

This theory can explain endometriosis of the abdominal viscera, the rectovaginal septum and the umbilicus.

Sites	Theory
• Pelvic endometriosis • Pelvic peritoneum	♦ Retrograde menstruation ♦ Coelomic metaplasia
• Abdominal viscera • Rectovaginal septum • Umbilicus	♦ Coelomic metaplasia
• Abdominal scar • Episiotomy scar • Vagina, cervix • Lymph nodes • Distant sites (Lungs, pleura, skin, lymph nodes, nerves)	♦ Direct implantation ♦ Lymphatic spread ♦ Vascular spread * Genetic * Immunologic

**Direct Implantation**

According to the theory, the endometrial or decidual tissues start to grow in susceptible individual when implanted in the new sites. Such sites are abdominal scar following hysterotomy, caesarean section, tubectomy and myomectomy. Endometriosis at the episiotomy scar, vaginal or cervical site can also be explained with this theory.

This theory however, fails to clarify endometriosis at sites other than mentioned.

**Lymphatic Theory (Halban):** It may be possible for the normal endometrium to metastasize the pelvic lymph nodes through the draining lymphatic channels of the uterus. This could explain the lymph node involvement.

**Vascular Theory:** This is sound at least to explain endometriosis at distant sites such as lungs, arms or thighs.

**Genetic and Immunological Factors**

Genetic basis of endometriosis probably accounts for less than 10 percent of the patients. There is 6–7 times increased incidence in first degree relatives. Multifactorial inheritance is thought of. However, a defect of local cellular immunity may be responsible for the ectopic tissue to grow in abnormal sites only in susceptible women.

Peritoneal macrophages normally remove the menstrual debris by phagocytosis. Pelvic endometriosis is associated

with a **subclinical peritoneal inflammation** resulting in increase in peritoneal fluid. In patients with endometriosis, the activated macrophages secrete several factors like cytokines, interleukin-1,  $\alpha$  TNF, integrins and angiogenic factors. These factors promote the growth of endometrial cells over the ectopic sites. Ectopic endometrium is more resistant to apoptosis. Furthermore activated macrophages reduce sperm motility, increase sperm phagocytosis and interfere with fertilization.

**Environment theory** suggests somatic mutations of cells due to environmental factors (pollutants, dioxins). Ovarian and deep infiltrating endometriotic lesions are explained with this theory.

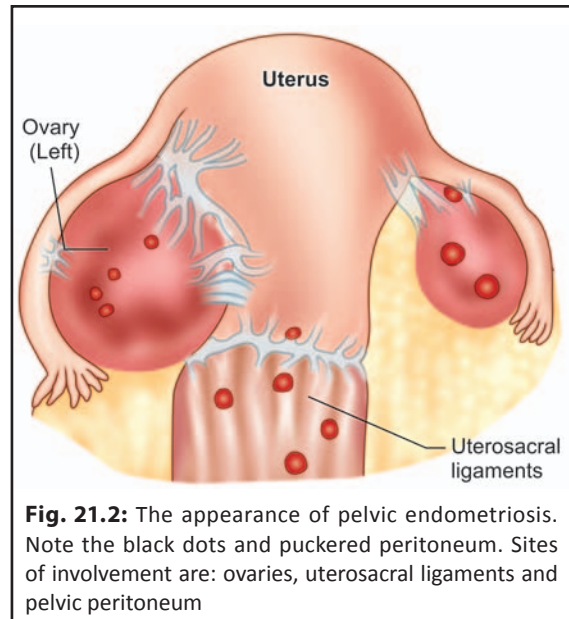
Thus, it is certain that, not all cases of endometriosis at different sites can be explained by a single theory.

### **PATHOLOGY—General Considerations**

- ♦ The endometrium (glands and stroma) in the ectopic sites has got the potentiality to undergo changes under the action of ovarian hormones
- ♦ While proliferative changes are constantly evidenced, the secretory changes are conspicuously absent in many; may be due to deficiency of steroid receptors in the ectopic endometrium
- ♦ Cyclic growth and shedding continue till menopause. The periodically shed blood may remain encysted or else, the cyst becomes tense and ruptures
- ♦ As the blood is irritant, there is dense tissue reaction surrounding the lesion with fibrosis. If it happens to occur on the pelvic peritoneum, it produces adhesions and puckering of the peritoneum
- ♦ If encysted, the cyst enlarges with cyclic bleeding. The serum gets absorbed in between the periods and the content inside becomes chocolate colored. Hence, the cyst is called **chocolate cyst** which is commonly located in the ovary. **Chocolate cyst may also** be due to hemorrhagic follicular or corpus luteum cyst or bleeding into a cystadenoma. For this reason, the term endometrial cyst or endometrioma is preferred to chocolate cyst
- ♦ In spite of dense adhesions amongst the pelvic structures, the **fallopian tubes remain patent**.

**Naked Eye Appearance:** The appearance of the lesion depends to a great extent on the organ(s) involved, extent of the lesion and reaction of the surrounding tissues.

**Pelvic endometriosis:** Typically, **there are small black dots, the so called ‘powder burns’ seen on the uterosacral ligaments and pouch of Douglas**



**Fig. 21.2:** The appearance of pelvic endometriosis. Note the black dots and puckered peritoneum. Sites of involvement are: ovaries, uterosacral ligaments and pelvic peritoneum

(Fig. 21.2). Fibrosis and scarring in the peritoneum surrounding the implants is also a typical finding. **Other subtle appearances are:** *red flame shaped areas, red polypoid areas, yellow brown patches, white peritoneal areas, circular peritoneal defects or subovarian adhesions*. These lesions are thought to be more active than the “powder burn” areas.

The ovaries are frequently involved usually bilaterally. The endometriomas (chocolate cysts) are of varying sizes and are visible as bluish colorations. The ovaries get adherent to the pelvic structures including rectum and sigmoid colon.

**Microscopic Appearance:** There is presence of endometrial tissue—**both glands and stroma**. Due to pressure effect, the lining epithelium of the cyst may be absent or flattened (cuboidal) or replaced by granulation tissue. Adjacent to the lining epithelium, there may be presence of large polyhedral **phagocytic cells, laden with blood pigment—hemosiderin** (pseudoxanthoma cells). The cyst wall is composed of fibrous tissue and compressed ovarian cortex.

### **CLINICAL FEATURES OF PELVIC ENDOMETRIOSIS**

#### **Patient Profile**

The age is between 30–45. The patients are mostly nulliparous or have had one or two children long years prior to appearance of symptoms. Infertility, voluntary postponement of first conception until at a late age

and higher social status are often related. Thus, it is more common in private than hospital patients. There is often family history of endometriosis. Outflow tract obstruction is an important cause when it is seen in teenagers (10%).

### Symptoms

- ♦ About 25 percent of patients with endometriosis have no symptom, being accidentally discovered either during laparoscopy or laparotomy.
- ♦ Symptoms are not related with extent of lesion. Even when the endometriosis is widespread, there may not be any symptom; conversely, there may be intense symptoms with minimal endometriosis.
- ♦ Depth of penetration is more related to symptoms rather than the spread. Lesions penetrating more than 5 mm are responsible for pain, dysmenorrhea and dyspareunia.
- ♦ Non-pigmented endometriotic lesions compared to the classic pigmented “powder burns” lesions produce more prostaglandin F (PGF) and hence are more painful.
- ♦ The symptoms are mostly related to the site of lesion and its ability to respond to hormones. Midline lesions are more symptom producing. Degree of pain is not related to the severity of endometriosis.

### Dysmenorrhea (70%)

There is progressively increasing secondary dysmenorrhea. The pain starts a few days prior to menstruation; gets worsened during menstruation and takes time, even after cessation of period, to get relief of pain, (co-menstrual dysmenorrhea). Pain usually begins after few years pain-free menses. The site of pain is usually deep seated and on the back or rectum.

Increased secretion of PGF 2 $\alpha$ , thromboxane  $\beta_2$  from endometriotic tissue is the cause of pain.

**Abnormal menstruation (20%):** Menorrhagia is the predominant abnormality. If the ovaries are also involved, polymenorrhea or epimenorrhagia may be pronounced. There may be premenstrual spotting.

**Infertility (40–60%):** Whether endometriosis causes infertility or infertility produces endometriosis is not clear. Endometriosis is found in 20–40 percent of infertile women, where as in about 40–50 percent patients with endometriosis suffer from infertility. The

multiple factors involved in producing infertility have been depicted in p. 231 (Table 16.2).

### Dyspareunia (20–40%)

The dyspareunia is usually deep. It may be due to stretching of the structures of the pouch of Douglas or direct contact tenderness. As such, it is mostly found in endometriosis of the rectovaginal septum or pouch of Douglas and with fixed retroverted uterus.

### Chronic Pelvic Pain

The pain varies from pelvic discomfort, lower abdominal pain or backache. The cause may be multifactorial. These include—(i) Inflammation in the peritoneal implants and release of PGF, and also due to adhesions and ovarian cysts. (ii) Action of inflammatory cytokines released by the macrophages. (iii) Invasion of nerves or involvement of bladder and bowel. The pain aggravates during period.

### Abdominal Pain

There may be variable degrees of abdominal pain around the periods. Sometimes, the pain may be acute due to rupture of chocolate cyst.

### Other Symptoms

The symptoms are related to the organ involved.

- ♦ Urinary—frequency, dysuria, back pain or even hematuria
- ♦ Sigmoid colon and rectum—painful defecation (dyschezia), diarrhea, constipation, rectal bleeding or even melena
- ♦ Chronic fatigue, perimenstrual symptoms (bowel, bladder)
- ♦ Hemoptysis (rarely), catamenial chest pain
- ♦ Surgical scars—cyclical pain and bleeding (see Fig. 21.5).

**Abdominal Examination:** Abdominal palpation may not reveal any abnormality. A mass may be felt in the lower abdomen arising from the pelvis—enlarged chocolate cyst or tubo-ovarian mass due to endometriotic adhesions. The mass is tender with restricted mobility.

### Pelvic Examination

Bimanual examination may not reveal any pathology. **The expected positive findings are**—pelvic tenderness, nodules in the pouch of Douglas, nodular feel of the uterosacral ligaments, fixed retroverted uterus or unilateral or bilateral adnexal mass of varying sizes (Fig. 21.3).

Speculum examination may reveal bluish spots in the posterior fornix.

Rectal or rectovaginal examination is often helpful to confirm the findings.

### DIAGNOSIS

**Clinical diagnosis** is by the classic symptoms of progressively increasing secondary dysmenorrhea, dyspareunia and infertility. This is corroborated by the pelvic findings of nodules in the pouch of Douglas, nodular feel of the uterosacral ligaments, fixed retroverted uterus and unilateral or bilateral adnexal mass. However, physical examination has poor sensitivity and specificity. Many patients have no abnormal findings on examination.

**Serum marker CA 125**—A moderate elevation of serum CA 125 is noticed in patients with severe endometriosis. It is not specific for endometriosis, as it is significantly raised in epithelial ovarian carcinoma (see p. 377, 522, 653). However, it is helpful to assess the therapeutic response and in follow up of cases and to detect any recurrence after therapy. **Monocyte Chemotactic Protein (MCP-1)** level is increased in the peritoneal fluid of women with endometriosis.

### IMAGING

**Ultrasonography** is not much helpful to the diagnosis. TVS can detect ovarian endometriomas. Transvaginal (TVS) and Endorectal ultrasound are found better for rectosigmoid endometriosis.

**Magnetic Resonance Imaging (MRI)** is a diagnostic tool. There is a characteristic hyperintensity on T1 weighted images and a hypointensity on T2 weighted images.

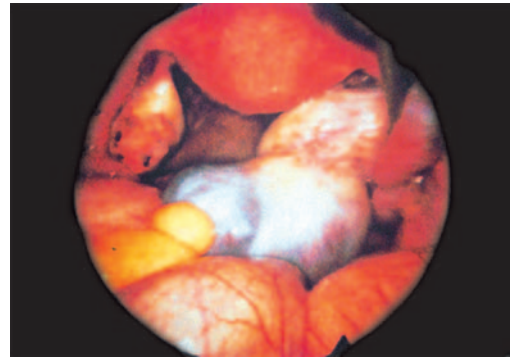
CT is better compared to ultrasonography in the diagnosis. MRI is useful for deep infiltrating endometriosis.

**Colonoscopy**, rectosigmoidoscopy and cystoscopy are done when respective organs are involved.

**Laparoscopy is the gold standard.** Confirmation is done by double puncture laparoscopy or by laparotomy.

**Other benefits are:** ♦ Confirmation of the lesion with site, size and extent. ♦ Biopsy can be taken at the same time. ♦ Staging (p. 309) can be done. ♦ Extent of adhesions could be recorded. ♦ Opportunity to do laparoscopic surgery if needed (p. 306).

The classic lesion of pelvic endometriosis is described as 'powder burns' or 'match stick' spots on



**Fig. 21.3:** Laparoscopic view of pelvic endometriosis: left ovary-endometriotic implants, right ovary-chocolate cyst

the peritoneum of the pouch of Douglas (see p. 309). Findings may be recorded on video or DVD (RCOG-2006) Microscopically some of these lesions contain endometrial glands, stroma and hemosiderin-laden macrophages.

**Biopsy confirmation** of excised lesion is ideal but negative histology does not exclude it. None of the imaging techniques including ultrasound, can diagnose specifically the peritoneal endometriosis. Empiric medical treatment is usually not recommended except for pain relief and to reduce menstrual flow.

### DIFFERENTIAL DIAGNOSIS

**Chronic pelvic infection** is most often confused with symptomatic endometriosis. The clinical presentation is almost similar. Laparoscopy is helpful in actual diagnosis.

**Ovarian endometrioma (chocolate cyst):** Ovary is the most common site for endometriosis. It starts with a superficial endometriotic implant over the ovarian surface. The endometriotic tissue gradually invades the ovarian stroma. Cyst formation is due to periodic shedding and bleeding from the implant.

Leakage of this altered blood along with inflammation, leads to adhesion formation with the adjacent structures. Fallopian tubes may be affected. Epithelial lining of the cyst contain endometrial glands and stroma. Due to pressure effect the lining epithelium may be flattened. When the cyst ruptures the characteristic thick, tarry fluid (chocolate material) escapes.

If asymptomatic, may be confused with **benign ovarian tumor** and in symptomatic one, with **malignant ovarian**. Presence of nodules in the pouch of Douglas

further confuses the diagnosis. **Ultrasonography** showing homogeneous internal echoes may be helpful (see Fig. 21.4). **Laparoscopy** differentiates one from the other. Too often, the diagnosis is made only during laparotomy.

**Rupture of the chocolate cyst:** During operation, while separating the adhesions, the cyst invariably ruptures with escape of chocolate colored blood. The rupture of the cyst can occur spontaneously causing acute abdomen with clinical features suggestive of acute ectopic. Acute abdomen **is confused with** torsion or rupture of the ovarian tumour, disturbed ectopic pregnancy, appendicitis or diverticulitis.

**COMPLICATIONS OF ENDOMETRIOSIS**

- **Endocrinopathy**—This may be mostly responsible for infertility (Table 21.3)
- **Rupture** of chocolate cyst
- **Infection** of chocolate cyst
- **Obstructive features:**
  - Intestinal obstruction
  - Ureteral obstruction → hydroureter → hydronephrosis → renal infection
- **Malignancy** is rare, the commonest one being adenoacanthoma.



TABLE 21.3	ENDOCRINOPATHY IN ENDOMETRIOSIS
♦	Corpus luteum insufficiency (p. 237).
♦	Luteolysis due to ↑ PGF2α.
♦	Luteinized unruptured follicle (LUF) (p. 237).
♦	Anovulation.
♦	Elevated prolactin level.
♦	Double LH peak.

**Staging**

The diagnosed endometriosis should be appropriately staged based on laparoscopic findings.

- ♦ To predict prognosis
- ♦ To choose therapy
- ♦ To evaluate the treatment protocol.

The scoring is (revised) by the American Fertility Society and is presented in Table 21.4. **The stage is determined by adding specific points given to each.**

**Limitations of AFS staging**

- Laparoscopy or laparotomy has to be done.
- Interobserver and intraobserver variation.
- No correlation between the extent of disease and the degree of symptoms.

**TABLE 21.4** AMERICAN FERTILITY SOCIETY SCORING SYSTEM OF ENDOMETRIOSIS (REVISED)

	Endometriosis	< 1 cm	1–3 cm	> 3 cm
Peritoneum	Superficial	1	2	4
	Deep	2	4	6
	<b>R</b> Superficial	1	2	4
Ovary	Deep	4	16	20
	<b>L</b> Superficial	1	2	4
	Deep	4	16	20
Posterior cul-de-sac obliteration	Partial	Complete		
	4	40		
Ovary	Adhesions	< 1/3 Enclosure	1/3–2/3 Enclosure	> 2/3 Enclosure
	<b>R</b> Filmy	1	2	4
	Dense	4	8	16
	<b>L</b> Filmy	1	2	4
	Dense	4	8	16
	<b>R</b> Filmy	1	2	4
Tube	Dense	4*	8*	16
	<b>L</b> Filmy	1	2	4
	Dense	4*	8*	16

\* If the fimbriated end of the fallopian tube is completely enclosed, change the point assignment to 16.  
 • **Stage I** (minimal) = 1–5      • **Stage II** (mild) = 6–15  
 • **Stage III** (moderate) = 16–40 • **Stage IV** (severe) = > 40.  
*The findings are depicted in a pictorial chart*

- Staging has not been correlated with fertility outcome.
- Staging has not been correlated with optimum mode of therapy.

**TREATMENT OF ENDOMETRIOSIS**

Endometriosis needs to be treated as it is a progressive disease (30–60%).

- ♦ Preventive    ♦ Curative

**Preventive**

The following guidelines may be prescribed to prevent or minimize endometriosis:

- To avoid tubal patency test immediately after curettage or around the time of menstruation
- Forcible pelvic examination should not be done during or shortly after menstruation.

- Married women with family history of endometriosis are encouraged not to delay the first conception but to complete the family.

**Curative:** The objectives are:

- To abolish or minimize the symptoms—pelvic pain and dyspareunia
- To improve the fertility
- To prevent recurrence.

But, it is difficult to achieve the objectives because of obscure etiology and unpredictable life history. The results of treatment are difficult to evaluate because of lack of uniform staging or grading. **The following facts are to be borne in mind.**

- ♦ Asymptomatic in good number of cases.
- ♦ Subjective symptoms are not proportionate to objective signs.
- ♦ Frequent association with infertility.
- ♦ Remission during pregnancy and menopause.

Prerequisites prior to therapy are accurate diagnosis with the help of laparoscopy along with staging and pictorial documentation.

#### Treatment options for Pelvic Endometriosis:

- ▶ **Expectant Management** (observation only)
- ▶ **Medical Therapy:** • Hormones • Others
- ▶ **Surgery:** • Conservative • Definitive
- ▶ **Combined Therapy:** • Medical and Surgical

#### Determinants of Treatment Options

- Age of the patient.
- Size and extent of lesions.
- Severity of symptoms.
- Location of disease.
- Desire for fertility.
- Results of previous therapy.

#### Expectant Treatment

Endometriosis is a progressive disease in about 30–60 percent of women. It is not possible to predict in which woman it will progress. Some form of treatment is often needed regardless of the clinical profile and to arrest the progress of the disease. However, in women with minimal to mild endometriosis role of any treatment is controversial. Cumulative pregnancy rate is similar when expectant treatment is compared with conservative surgery. Case selection is important (see Table 21.5).

**TABLE 21.5**

#### CASE SELECTION FOR EXPECTANT TREATMENT

- ♦ Minimal endometriosis with no other abnormal pelvic finding
- ♦ Unmarried
- ♦ Young married who are ready to start family
- ♦ Approaching menopause

#### Protocols for Expectant Management

Observation with administration of non-steroidal anti-inflammatory drugs or prostaglandin synthetase inhibiting drugs are used to relieve pain. Ibuprofen 800–1200 mg or mefenamic acid 150–600 mg a day is quite effective.

The married women are encouraged to have conception. Pregnancy usually cures the condition. This is due to absence of shedding and decidual changes in the ectopic endometrium causing its necrosis and absorption.

#### Hormonal Treatment

The aim of the hormonal treatment is **to induce atrophy of the endometriotic implants**. It should be considered suppressive rather than curative because of high recurrence rate.

The mechanism of endometrial atrophy is either by producing ‘*pseudopregnancy*’ (combined oral pills) or by ‘*pseudomenopause*’ (Danazol) or by ‘*medical oophorectomy*’ (GnRH agonists). The hormonal use is gratifying in superficial peritoneal implants and endometriomas of less than 1 cm.

The drugs used are combined estrogen and progesterone (oral pill), progesterone, danazol and GnRH analogues. All the drugs are used continuously to produce amenorrhea and as such individualization of the dose is required.

#### Combined estrogen and progesterone

The low dose contraceptive pills may be prescribed either in a cyclic or continuous fashion with advantages in young patients with mild disease who want to defer pregnancy. It causes endometrial decidualization and atrophy (see p. 191). It may induce amenorrhea. It relieves dysmenorrhea. **Anastrozole** an aromatase inhibitor is found to reduce the growth and pain of endometriosis (p. 534).

**Progesterone:** It causes decidualization of endometrium and atrophy (see p. 191). High doses may suppress ovulation and induce amenorrhea.



Oral route is commonly used. Injectable preparations as depot form should be withheld in patients wishing to conceive. Ovulation may remain suspended for several months following withdrawal of the therapy. The side effects (see p. 537) are well-tolerated. The drug is comparatively cheaper than danazol. **Progesterone Antagonists** (Mifepristone 50–100 mg/day) has also been found effective.

**Levonorgestrel-releasing-IUCD** when used, is found to reduce dysmenorrhea, pelvic pain, dyspareunia and menorrhagia significantly. It is specially useful for rectovaginal endometriosis.

### Danazol (p. 530)

Danazol therapy is to be started from the day 5 of the menstrual cycle. The dose (600–800 mg daily) is variable and depends upon the extent of the lesions but should be adequate enough to produce amenorrhea. **The patient should use barrier methods of contraception** to avoid virilization of a female fetus in accidental pregnancy. *Resolution of*

*endometriotic lesions has been seen in about 80% of cases but the recurrence rate is high (40%).* The side effects are at times intense and intolerable to the extent of discontinuation of the therapy. A few often persist even after the therapy. The drug is costlier than progestogen. **Gestrinone** (p. 531) has got the same mechanism of action like that of danazol. The side effects are less than danazol. Administration is simple, twice a week (see Table 21.6).

**GnRH analogues (p. 525)**—When used continuously act as medical oophorectomy, a state of hypoestrinism and amenorrhea. The goal is to maintain a reduced level of serum estrogen (30–45 pg/mL) so that growth of endometriosis is suppressed. The side effects are more tolerable than danazol. The drugs have got limited availability and costliest of all the drugs used. Long-term therapy (more than 6 months) should be avoided (see add-back therapy p. 527, 528).

**Results: The efficacy of the hormone therapy is judged by** relief of symptoms, reduction of the

**TABLE 21.6 HORMONES USED IN ENDOMETRIOSIS**

Drugs	Dose	Mechanism	Side effects
Combined estrogen progestogen (oral pill)	1–2 tablets 6–9 months	Pseudopregnancy	Tolerated (see ch. 29)
<b>Progestogens (p. 534)</b> <i>Oral</i> • Medroxyprogesterone acetate • Dydrogesterone • Norethisterone <i>IM</i> • Medroxyprogesterone <i>IUCD</i> • Levonorgestrel-releasing-IUCD (p. 459)	10 mg thrice daily × 6–9 months 10–20 mg daily × 6–9 months 10–30 mg daily × 6–9 months  150 mg 3 months interval × 2	Pseudopregnancy	Tolerated (see p. 537)
Danazol (p. 530)	400–800 mg orally in 4 divided doses × 6–9 months	Pseudomenopause	Less tolerated (see p. 531)
Gestrinone (p. 530)	1.25 or 2.5 mg twice a week × 6–9 months	Pseudomenopause	Well tolerated (see p. 531)
GnRH analogues (p. 525)	• Leuprolide 3.75 mg IM monthly × 6 months • Nafarelin 200 µg intranasally daily × 6 months • Goserelin 3.6 mg depot IM monthly × 6 months	Medical oophorectomy	Well tolerated (see p. 526)

volume of the lesions as revealed by second look laparoscopy, improvement of fertility and prevention of recurrence. For quick relief of symptoms and reduction of the volume of the lesion, GnRH analogues are the best. Progestogens take some time to achieve these objectives. Danazol is placed midway between the two.

Taking every aspect together (pain relief, pregnancy rates, recurrence rates, costs and side effects), no single medical treatment is superior to others.

Following medical suppression or other conservative surgery, residual endometriotic lesions may regenerate once the ovarian function is reestablished. **Overall recurrence rate is about 40 percent after 5 years.**

## SURGICAL MANAGEMENT OF ENDOMETRIOSIS

### Indications

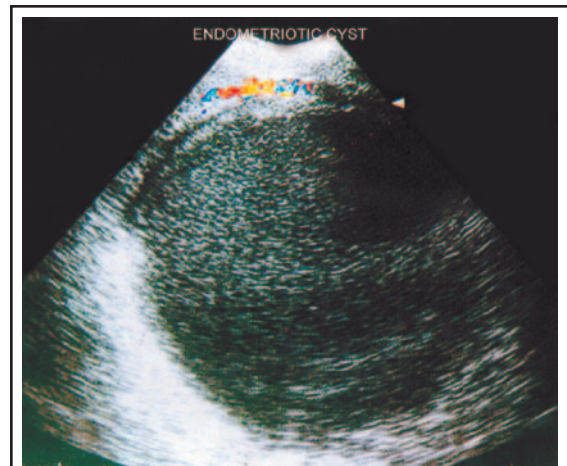
- ◆ Endometriosis with severe symptoms unresponsive to hormone therapy.
  - ◆ Severe and deeply infiltrating endometriosis to correct the distortion of pelvic anatomy.
  - ◆ Endometriomas of more than 1 cm.
- Surgery may be conservative or definitive.

### CONSERVATIVE SURGERY

**Conservative surgery** is planned to destroy the endometriotic lesions in an attempt to improve the symptoms (pain, subfertility) and at the same time to preserve the reproductive function.

**Laparoscopy** is commonly done to destroy endometriotic lesions by excision or ablation by electrodiatherapy or by laser vaporization. **Conservative surgical treatment in minimal to mild endometriosis (ablation plus adhesiolysis) improves the fertility outcome.** Laparoscopic uterosacral nerve ablation (LUNA) is done when pain is very severe. The advantage of laser is to cut the tissues precisely with least chance of damage to the underlying vital structures. Great deal of technical expertise is essential to avoid injury to the ureters.

Surgical treatment improves fertility and symptoms in women with moderate and severe endometriosis.



**Fig. 21.4:** Color Doppler Scan (TV) of an ovarian endometrioma (chocolate cyst). Internal echoes are homogeneous. Increased vascularity is seen at the ovarian hilus

## OVARIAN ENDOMETRIOMAS (see Fig. 21.4)

- ◆ **Small endometrioma (< 3 cm)** is aspirated laparoscopically. The cyst cavity is irrigated with normal saline. Cyst wall epithelium is destroyed by laser vaporization.
- ◆ **Large endometrioma (≥ 4 cm)** is often associated with extensive adhesion to other pelvic structures. Laparoscopy is necessary for ovarian cystectomy and adhesiolysis.

**Results:** Laparoscopic cystectomy is effective in relieving pain in about 74% cases of mild to moderate disease. Pregnancy rate is observed in about 60% cases with moderate and 35% cases with severe disease. Restoration of normal pelvic anatomy improves fertility in cases with severe endometriosis. High pregnancy rate is observed within first 6 months of conservative surgery.

**Infertility associated with endometriosis:** When there is no improvement of infertility due to endometriosis with the usual treatment, couple should be counseled for ART (p.251). Controlled ovarian hyperstimulation with IUI, IVF, GIFT and ICSI are the different methods (see p. 250).

**Definitive surgery:** It is indicated in women with **advanced stage endometriosis** where there is: (i) No prospect for fertility improvement. (ii) Other forms of treatment have failed. (iii) Women with completed family.

**Definitive surgery means** hysterectomy with bilateral salpingo-oophorectomy along with resection of the endometrial tissues as complete as possible.

### Combined Medical and Surgical

**Preoperative hormonal therapy** aims at reduction of the size and vascularity of the lesion which facilitate surgery. The idea of **postoperative hormonal therapy** is to destroy the residual lesions left behind after surgery and to control the pain. But it does not improve fertility. It is generally avoided.

Duration of therapy is usually 3–6 months preoperatively and 3–6 months postoperatively. The **cumulative probability of pregnancy at 3 years following laparoscopic surgery was 47%** (51% for stage I, 45% of stage II, 46% of stage III and 44% for stage IV). **Overall risk of recurrence is 40% by 5 years time.**

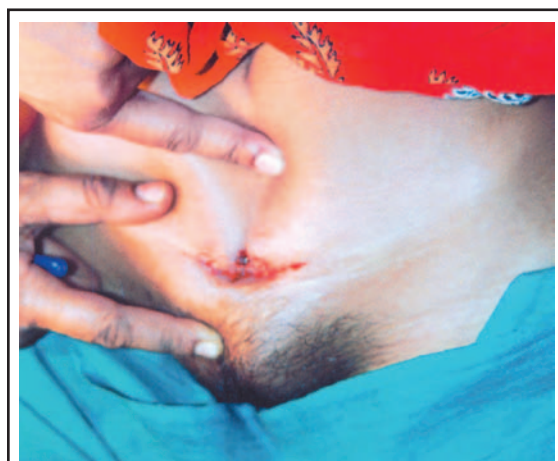**Empirical treatment** of pelvic pain with the presumptive diagnosis of pelvic endometriosis may be given with combined oral contraceptives.

### ENDOMETRIOSIS AT SPECIAL SITES

- ♦ Abdominal scar
- ♦ Bladder and ureter
- ♦ Cervix and vagina
- ♦ Umbilicus
- ♦ Gut
- ♦ Lung

**Scar (Fig. 21.5):** It usually manifests following **abdominal hysterotomy**, cesarean section, myomectomy or even tubectomy. Implantation theory can explain its entity.

The patient complains of painful nodular swelling over or adjacent to the scar which increases in size and often bleeds during periods. The size is variable, nodular feel, tender with restricted mobility.



**Fig. 21.5:** Bleeding from a scar endometriosis. The patient was examined during her menstruation

Associated pelvic endometriosis is usually absent. The same type of nodular swelling can be found over episiotomy scar. **Treatment** is by excision. Hormone therapy is ineffective.

**Umbilicus:** There is nodular painful swelling which increases in size and becomes tender during period. At times, bleeding may also occur. Coelomic metaplasia theory can explain its origin.

**Treatment** is by excision.

**Bladder:** The patient complains of dysuria, frequency, hematuria and lower abdominal pain specially during periods. Cystoscopic examination reveals blue area of the mucosa. IVP may reveal ureteric stricture and hydronephrotic or even hydronephrotic changes on the affected side.

**Treatment** is not much effective with hormones. Local excision of the bladder wall and repair should be done. In ureteric involvements, the segment of the ureter is to be excised followed by implantation of the ureter to the bladder.

**Gut:** The rectum, sigmoid colon or even the small intestine are the common sites. Coelomic metaplasia theory can explain the endometriosis at these sites. **The mucosa is not involved, a differentiating feature from malignancy.**

The patient complains of periodic colicky pain on defecation or at times bleeding per rectum specially during periods. Associated pelvic endometriosis is a constant feature. There may be even features of subacute intestinal obstruction.

Rectal examination and investigations like sigmoidoscopy and barium enema confirm the diagnosis.

**Lung, pleura, and brain** are the rare sites. This may cause catamenial pneumothorax or seizures during mens.

**Treatment:** Hormone treatment may be effective. If it fails, surgery may have to be done. In young patients, resection anastomosis and in patients above 40, removal of the ovaries may help regression of the lesions.

**Cervix and vagina:** The lesions are usually due to implantation of the endometrium over the trauma inflicted at operation or following delivery. The only complaint may be dyspareunia. The lesion is revealed by speculum examination. Confusion may arise with carcinoma cervix. There is, bleeding on touch in carcinoma cervix. Confirmation is done by biopsy. **Treatment** by hormone is ineffective. Surgical excision may be required.

## ADENOMYOSIS

**DEFINITION:** Adenomyosis is a condition where there is ingrowth of the endometrium, both the glandular and stromal components, directly into the myometrium.

**CAUSES:** The cause of such ingrowth is not known. It may be related to repeated childbirths, vigorous curettage or excess of estrogen effect. Pelvic endometriosis co-exists in about 40 percent.

**PATHOGENESIS:** Histologically, it is characterized by the extension of endometrial glands and stroma beneath the endometrial—myometrial interface (EMI). As the submucosa is absent, endometrial glands lie in direct contact with the underlying myometrium. It forms nests, deep within myometrium. Subsequently, there is myometrial hyperplasia around the endometriotic foci. Myometrial zone anatomy was observed by MRI. A junctional zone (with low signal intensity on T2 weighted images) is defined at the innermost layer of myometrium. It is thought that the disturbance of normal junctional zone (JZ) predisposes to secondary infiltration of endometrial glands and stroma to inner myometrial zone. The disturbance of junctional zone (JZ) may be due to the endometrial factors, genetic predisposition or altered immune response. Trauma to the deeper endometrium (repeated curettage), causing breakdown of EMI is also taken as an important etiologic factor.

**PATHOLOGY:** The growth and tissue reaction in the endometrium depend on the response of the ectopic endometrial tissues to the ovarian steroids. If the basal layer is only present, the tissue reaction is much less, as it is unresponsive to hormones. But, if the functional zone is present which is responsive to hormones, the tissue reaction surrounding the endometrium is marked. There is hyperplasia of the myometrium producing diffuse enlargement of the uterus, sometimes symmetrically but at times, more on the posterior wall. The growth may be localized or may invade a polyp (adenomyomatous).

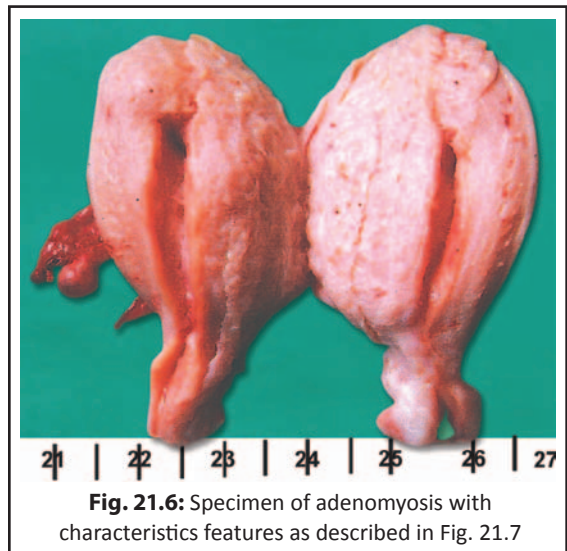
**Naked eye appearance:** There is diffuse symmetrical enlargement of the uterus; the posterior wall is often more thickened than the anterior one. The size usually does not increase more than a large orange (12–14 weeks pregnant uterus). On cut section, there is thickening of the uterine wall. The cut surface presents characteristic trabeculated appearances. **Unlike fibroid, there is no capsule surrounding the**

**growth.** There may be visible blood spots at places (Figs 21.6 and 21.7).

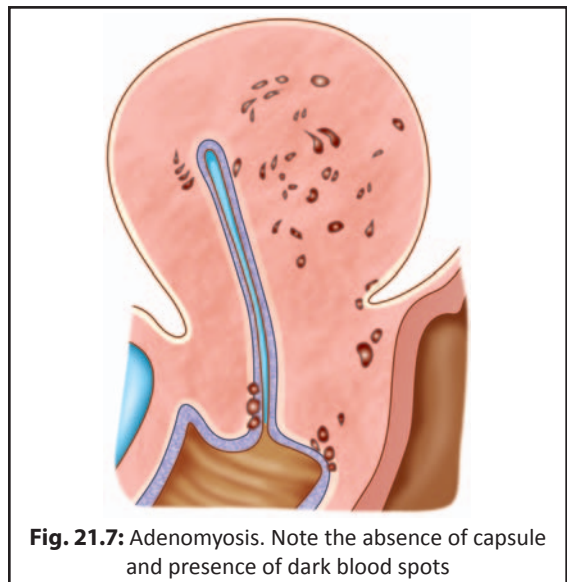
**Histological examination:** Histological examination reveals glandular tissue like that of endometrium surrounded by stromal cells in the myometrium. The response of the ectopic endometrial tissue to ovarian hormones is minimal as the invasion is predominantly in the basal layer (Fig. 21.8).

## CLINICAL FEATURES

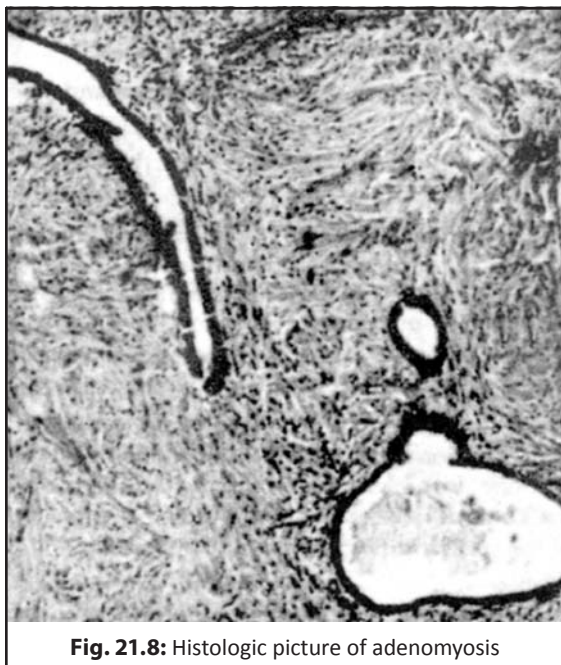In about one-third, it remains asymptomatic being discovered on histological examination.



**Fig. 21.6:** Specimen of adenomyosis with characteristic features as described in Fig. 21.7



**Fig. 21.7:** Adenomyosis. Note the absence of capsule and presence of dark blood spots



**Fig. 21.8:** Histologic picture of adenomyosis

**Patient profile:** The patients are usually parous with age usually above 40.

**Symptoms: Menorrhagia (70%)**—The excessive bleeding is due to increased uterine cavity, associated endometrial hyperplasia and inadequate uterine contraction. *During normal menstruation, there are antegrade propagation of subendometrial contractions from the fundus to the cervix. In adenomyosis with distortion of junctional zone myometrial contractions are abnormal and inadequate (see below).*

**Dysmenorrhea (30%)**—Progressively increased colicky pain during period is due to retrograde pattern of uterine contractions. It also depends on the number and depth of adenomyotic foci in the myometrium. When the depth of penetration is  $\geq 80\%$  of the myometrium, the pain is severe. Other causes of pain are—local tissue edema and prostaglandins.

**Dyspareunia or frequency of urination**—are due to enlarged and tender uterus.

**Infertility:** Women with adenomyosis have a higher incidence of infertility and miscarriage. **The reasons are:** (a) abnormal function of the subendometrial myometrium, (b) retrograde myometrial contractions, (c) interference in sperm transport and blastocyst implantation and (d) abnormal endometrial immune response and nitric oxide level.

**Signs:** Abdominal examination may reveal a hypogastric mass arising out of the pelvis and

occupying the midline. The size usually does not exceed 14 weeks pregnant uterus.

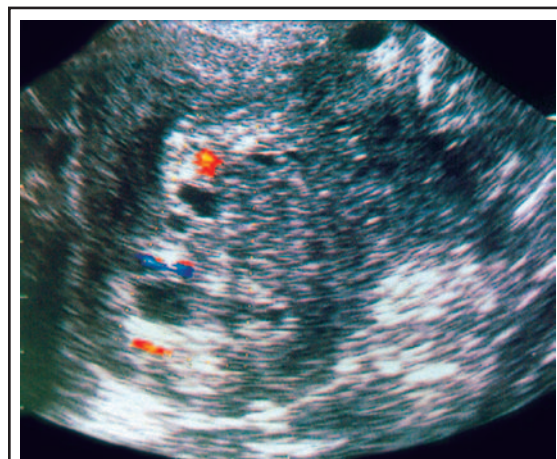
Pelvic examination—reveals uniform enlargement of the uterus.

The findings, however, may be altered due to associated fibroid or pelvic endometriosis.

**Ultrasound and Color Doppler (TVS) characteristics are:** Myometrium normally has three distinct zones of different echogenicity. The inner layer is hypoechoic relative to the middle and outer layer. This subendometrial halo is characteristic in adenomyosis. Other features are: (i) heterogenous echogenicity, (ii) hypoechoic myometrium with multiple small cysts in the myometrium (honeycomb appearance), (iii) increased vascularity within the myometrium (see Fig. 21.9).

**Magnetic Resonance Imaging (MRI):** It is more specific to the diagnosis. Low signal intensity JZ  $\leq 8$  mm excludes the disease. Whereas JZ thickness  $\geq 12$  mm is suggestive of adenomyosis.

**TREATMENT:** The treatment is surgical. There is little place of hormone therapy. Treatment with progestins or cyclic estrogen and progestin have got little benefit. **Levonorgestrel-releasing-IUS** (p. 479) is found to improve the menorrhagia and dysmenorrhea. **Danazol**—loaded (300–400 mg) intrauterine device (IUD) is also found to improve the symptoms of menorrhagia and dysmenorrhea. Serum danazol levels were not detectable and the side effects were minimal.



**Fig. 21.9:** Transvaginal Color Doppler Scan showing diffusely enlarged uterus with anechoic cysts. 'Swiss cheese' pattern with increased vascularity is suggestive of adenomyosis

**Surgical management:** (A) Conservative surgery: • Adenomyomectomy • Uterine mass reduction (Laparotomy or laparoscopy). (B) Hysterectomy (parous and aged women).

### STROMAL ENDOMETRIOSIS

This is a rare condition where the endometrial stromal cells, without glandular components, are present in places other than uterine mucosa.

**PATHOGENESIS:** The stromal cells extend into the myometrium or even broad ligament along the course

of the lymphatics and muscle bundles. As there is a chance of recurrence, it is considered as locally malignant. The uterus is uniformly enlarged as in adenomyosis. Microscopic examination reveals round and oval cells of endometrial stroma.

**Clinical features** are similar to a case of adenomyosis.

**TREATMENT:** Hysterectomy with bilateral salpingo-oophorectomy is the effective surgery. In younger patients, the ovaries may be preserved. Radiotherapy may be needed in proved cases following its recurrence or incomplete surgery.

## KEY POINTS

- The presence of functioning endometrium (stroma and glands) in sites other than uterine mucosa is called endometriosis. Endometriosis is a disease seen in the reproductive years of a woman as its growth depends on estrogen. The incidence is about 10 percent but incidence is high (30–40%) amongst infertile women as based on diagnostic laparoscopy and laparotomy. The commonest abdominal site is ovary followed by pouch of Douglas and uterosacral ligaments (organs on the dependent part of the pelvis).
- Endometriosis is a disease of contrast. It is a benign disease but it is locally invasive, disseminates widely and proliferates in the lymph nodes. Minimal disease may have severe pain whereas large endometriosis may remain asymptomatic. Cyclic hormones stimulates growth whereas continuous hormones suppress it.
- Abdominal scar is the commonest site of endometriosis following hysterectomy, hysterotomy, cesarean section, tubectomy or myomectomy (Fig. 21.5).
- The disease is full of theories and no one single theory can explain endometriosis at all sites. Genetic basis and defect of local cellular immunity may be implicated (Table 21.2). In spite of dense adhesions amongst the pelvic structures, the fallopian tubes are usually patent. In pelvic endometriosis, typically there are small black dots—'powder burns' or "gunshot" seen on uterosacral ligaments and pouch of Douglas. Other lesions are flame-shaped polypoidal, hemorrhagic and white patches.
- About 25 percent have got no symptom. Symptoms are not related to the extent of lesion. Severity of endometriosis and the degree of pelvic pain are not always proportional. Unlike primary dysmenorrhea, the pain lasts for many days before and after the menstruation.
- Dysmenorrhea is associated in 50 percent, menorrhagia in 60 percent and infertility in 40–60 percent. Endometriosis is found in 30–40 percent of infertile women.
- Clinical diagnosis is by the classic symptoms of progressively increasing dysmenorrhea, dyspareunia, infertility and feel of nodules in the pouch of Douglas. Confirmation is by laparoscopy or laparotomy.
- Histologic diagnosis of endometriosis is ideal. Microscopic diagnostic features are: presence of endometrial glands, stroma and hemosiderin-laden macrophages.
- Double puncture laparoscopy is considered the 'gold standard' for the diagnosis.
- The natural course of the disease is ill understood. It is progressive in about 30–60 percent patients and for the remainder it is either static or resolve spontaneously. Unfortunately, it is impossible to predict in which patient it will progress. Red blood filled lesions are the most active phase of endometriosis. Serum marker CA 125 is helpful in follow up cases of proved endometriosis.

Contd...

Contd...

- Endometriosis is often associated with tubal and ovarian damage (see Table 21.4). These combined factors along with endocrinopathy (Table 21.3) may be responsible for infertility. However, the association of minimal to mild endometriosis and infertility is controversial.
- The complications include endocrinopathy (LPD, anovulation, LUF or elevated prolactin level) rupture chocolate cyst, infection of the cyst or obstructive features (intestinal or ureteric).  
Other complications of endometriosis are: Acute abdomen due to rupture of chocolate cyst, infection of the cyst, colorectal obstruction and ureteral obstruction.
- The short-term goals of treatment for endometriosis are : (i) relief of pain and (ii) improvement of fertility. The long-term goal is to prevent progression or recurrence of the disease.
- Expectant treatment is extended to unmarried or young married with no abnormal pelvic findings. Endometriosis causes pelvic inflammation. So the drugs used are non-steroidal, anti-inflammatory drugs (NSAIDs) or prostaglandin synthetase inhibitors.
- The hormonal treatment should be considered suppressive rather than curative. The mechanism of atrophy can be explained by pseudopregnancy or by pseudomenopause or by medical hypophysectomy (see p. 311). The commonly used hormones are given in the Table 21.6.

The objective of medical therapy is to create amenorrhea (hypoestrogenic state). Aromatase inhibitors (letrozol 2.5 mg daily) are used to inhibit aromatase which converts androgens to estrogens. Estrogen promotes its growth (p. 310, 531). The overall fertility rate and the recurrence rate is about 40 percent.

- The effect of danazol is by its 'pseudomenopause' response. The side effects are due to its androgenic and anabolic properties (see p. 530). GnRH agonists produce 'Medical oophorectomy' and the side effects are due to the estrogen deprivation (see p. 525). 'Add back' therapy is suggested with chronic use of GnRH agonists.
- Conservative surgery in endometriosis includes removal of all macroscopic endometriosis, lysis of adhesions and restoration of normal pelvic anatomy. The surgery is preferably done by laparoscopy (diathermy, laser vaporization). Endoscopic laser surgery is the best in selected cases for the treatment of pain and to prevent the disease progress.
- Ovarian endometriosis (< 3 cm) is treated by laparoscopic cyst aspiration. The cyst wall is vaporized to destroy the mucosal lining. Large ovarian endometrioma (> 3 cm) is treated by laparoscopic ovarian cystectomy. Laparoscopic adhesiolysis should be done at the same time. Laparoscopic ovarian cystectomy improves fertility.
- Preoperative medical treatment with GnRH analogue may reduce the vascularity and the extent of the disease. Postoperative medical treatment should not prevent pregnancy as the chance of pregnancy is highest during the first 6–12 months after the conservative surgery.
- Definitive surgery includes total hysterectomy with bilateral salpingo-oophorectomy. Laparotomy is done for advanced stage disease or in women who has completed her family.
- Postoperative estrogen replacement therapy after total hysterectomy and bilateral oophorectomy may be given 3 months after surgery. The risk of recurrence is very low.
- Adenomyosis primarily occurs in parous women over the age of 35. Adenomyosis is associated with pelvic endometriosis in 40 percent. Menorrhagia (70%) and dysmenorrhea are the chief complaints. Uterus is diffusely enlarged (2–3 times). Uterine size > 14 weeks gestation is rare.

Hormone treatment is often ineffective. Levonorgestrel-releasing IUS (p. 484) is found to improve menorrhagia and dysmenorrhea. Hysterectomy is the effective treatment in a parous and aged women.

# Premalignant Lesions

## PREMALIGNANT VULVAL LESIONS

Premalignant vulval lesions include:

- ◆ Vulval intraepithelial neoplasia (VIN).
- ◆ Paget's disease (p. 319).
- ◆ Lichen sclerosus (p. 259).
- ◆ Squamous cell hyperplasia (p. 262).
- ◆ Condyloma accuminata (see p. 157).

## VULVAL INTRAEPITHELIAL NEOPLASIA (VIN)

The different degrees of VIN are:

**VIN-I:** Corresponds to mild cellular atypia. The lesion is limited to the deeper one-third of the epithelium.

**VIN-II:** Corresponds to moderate cellular atypia. The lesion is limited up to middle-third of the epithelium.

**VIN-III:** Corresponds to severe cellular atypia and carcinoma-*in-situ*. The abnormal cells involve whole thickness of the epithelium. There is no stromal invasion.

### The following facts are to be borne in mind:

- ◆ It is more frequent in patients in the age group 20–40 years, i.e. at a younger age group compared to vulval carcinoma. **The average age is as low as 33 years.**
- ◆ It is often related with STD such as condyloma accuminata, herpes simplex virus II, gonorrhoea, syphilis or *Gardnerella vaginalis*.
- ◆ HPV associated VIN is seen more in young women. HPV 6 and 11 are associated with vulval condylomas. HPV 16, 18, 31, 35 are associated with VIN lesions.

- ◆ There is increased prevalence of associated CIN (10–80%).
- ◆ Regression frequently occurs in young woman, during pregnancy or when it is caused by viral infection.
- ◆ Rarely progresses to invasive carcinoma (< 10%). It takes 20–30 years (for CIN 10–15 years) to progress to invasive cancer.

## DIAGNOSIS

The chief complaints may be pruritus vulvae, lump or bleeding from a vulval ulcer. It may be even symptomless.

Local examination reveals a lesion in the vulva with white, grey, pink or dull red color. Lesions look rough, raised from the surface and often multifocal. Application of 5 percent acetic acid turns VIN lesions white with punctuation and mosaic patterns. These changes are best seen with a colposcope.

Cytologic screening of the vulva is not useful and unreliable.

Confirmation of diagnosis is done by biopsy. Usually 3–5 mm diameter dermal punch is taken under local anesthetic. The small amount of bleeding is controlled using Monsel's solution (ferrous sulphate). Larger biopsy when required may be taken using a scalpel. Multiple site biopsies are useful.

A complete pelvic examination is to be done. **To exclude vaginal or cervical neoplasia, cytologic evaluation has to be performed.**

## HISTOLOGY

The cells exhibit features of malignancy. There is complete loss of polarity and stratification. Cellular immaturity, nuclear abnormalities and mitotic activity



vary depending upon the grade of VIN. There is hyperkeratosis, acanthosis (hyperplasia of epidermis) and chronic inflammatory cell infiltration. Koilocytes (see p. 112) may be present. The rete ridges are large and elongated. Basement membrane remains intact. There is no evidence of involvement of the dermis.

### TREATMENT OF VIN

The fact remains that VIN has got low malignant potential. The risk of progression to invasive disease is less than 10 percent. Hence conservative management is generally accepted.

#### Medical

Medical treatment is done for young woman to control the symptoms. Topical fluorinated steroid ointment can be applied twice daily for a period of about 6 months. Commonly used preparations are 0.1 percent triamcinolone acetonide, or 0.1 percent betamethasone valerate. Local application of chemotherapy in the form of 5 percent 5-fluorouracil (5-FU) cream may be used in recurrent lesions. The result is however unsatisfactory.

Whatever therapy is employed, it is mandatory for regular follow up. Biopsies to be taken freely whenever an abnormal area is detected.

**Surgery:** The following are the types of surgery:

- ◆ **Local excision—Wide local excision** with 1 cm margin is reserved in young patient with localized lesion.
- ◆ **Laser therapy**—CO<sub>2</sub> laser vaporization is gaining increasing popularity in the treatment of vulval epithelial atypia. It gives better cosmetic results with lower recurrence rate. In multifocal lesion, simple excision of the individual lesion(s) is done. Skinning vulvectomy is less commonly done. Cryosurgery and loop electrosurgical excision procedure (LEEP) has been used.
- ◆ **Simple vulvectomy**—It is employed in diffuse type especially in postmenopausal women (see p. 607). Long-term follow-up is needed as the risk of recurrence is high (40–70%).

### PAGET'S DISEASE

This is a special type of VIN. The lesion grows horizontally within the epidermis. The rete ridges tend to push into the dermis without actually penetrating it.

The characteristic histologic picture is presence of Paget cells in the epidermis. The cells are large—round or oval in shape with abundant pale cytoplasm. There may be presence of mucopolysaccharides in most of the cells. Nuclear mitotic figures are rare.

Associated adenocarcinoma of apocrine gland (adenocarcinoma in situ) is present in about 10 percent of the cases. **There is high incidence (30%) of associated carcinomas of other organs (breast, cervix, ovary, GI tract and bladder).**

**Symptoms** are mainly pruritus, vulvar soreness, pain or bleeding.

Local examination reveals—labia majora appear red, scaling, with elevated lesion. There may be associated white lesions. The skin is usually indurated.

### TREATMENT

Simple vulvectomy is done. Multiple biopsies are to be taken to exclude associated adenocarcinoma of the apocrine glands. If it is found positive, bilateral lymph node dissection should be done at a second stage.

## VAGINAL INTRAEPITHELIAL NEOPLASIA (VAIN)

The etiologic agent is oncogenic HPV. In 70 percent cases of VAIN there is associated CIN. It is diagnosed by colposcopy (see CIN).

### PATHOLOGY

**VAIN-I:** There is minimal loss of stratification and polarity of the cells.

**VAIN-II:** Epithelial abnormality extends onto the middle-third of the epithelium.

**VAIN-III:** Carcinoma-*in-situ*—There is loss of polarity and stratification through all layers. Basement membrane remains intact.

### DIAGNOSIS

- ◆ **Vaginal scrape cytology** ◆ **Colposcopy**
- ◆ **Biopsy**

### MANAGEMENT

- a. Local excision for biopsy is diagnostic and therapeutic also. This is suitable for a small lesion.
- b. 5-Fluorouracil (5-FU) cream is to be applied at night for a period of 5–10 days and to be repeated every 2 weeks for 2–3 courses.

c. Ablation therapy is by:

- ▶ **Electrocautery**    ▶ **Laser** (see p. 123)
- ▶ **Excision of vaginal vault**

## CERVICAL INTRAEPITHELIAL NEOPLASIA (CIN)

### NOMENCLATURE

**Rubin** (1910) introduced the term ‘*carcinoma-in-situ*’ as a forerunner of invasive carcinoma.



**Walters and Regan** (1956) introduced the concept of **dysplasia**. **Richart** (1967) brought-forth the concept of CIN where cervical squamous epithelium is replaced by cells with varying degrees of atypia.

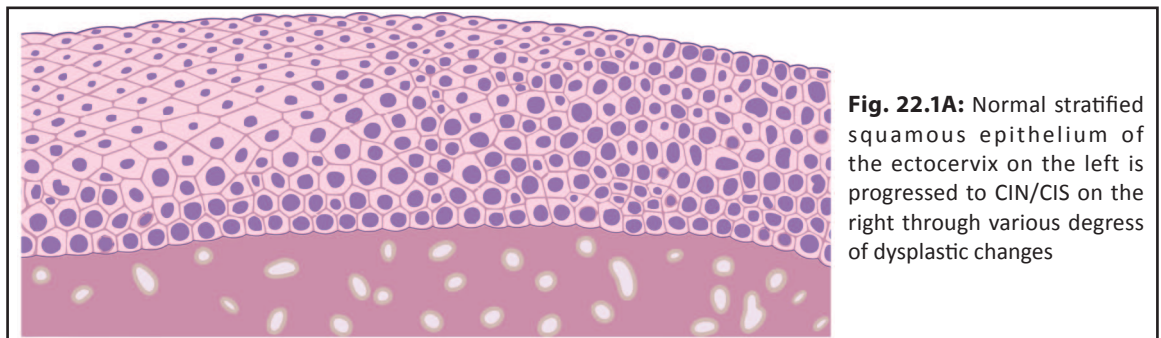
**World Health Organization (WHO)** in 1975 classified the CIN into three categories correlating with former gradings of dysplasia and CIS. The grading is done according to the thickness occupied by the undifferentiated cells.

**Bethesda system** (1988) classified cytologic abnormalities of premalignant lesions into three

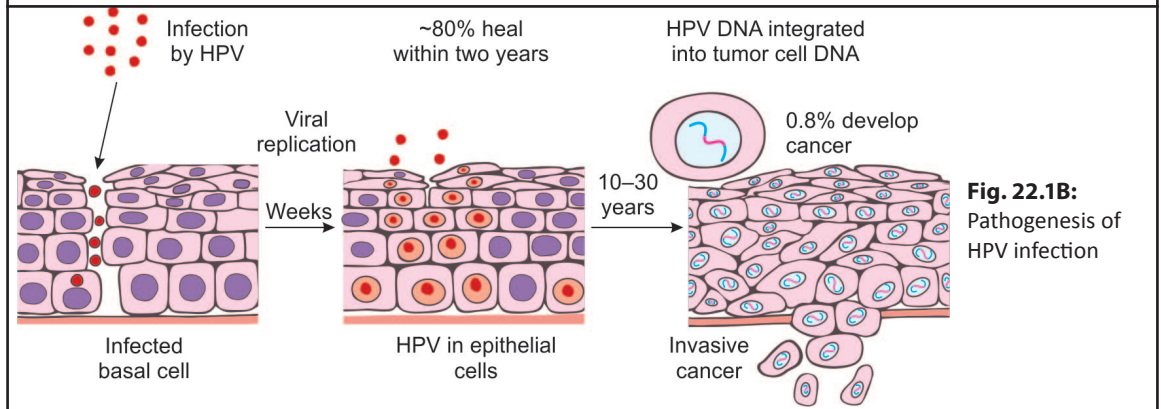
Dysplasia	CIN	Limit of histologic changes	Bethesda (see p. 113)
Mild	CIN I	Basal one-third	LSIL
Moderate	CIN II	Basal half to two-third	} HSIL
• Severe	CIN III	• Whole thickness except one or two superficial layers	
• CIS		• Whole thickness	

categories: (a) atypical squamous cells (ASC), (b) low grade squamous intraepithelial lesions (LSIL) and (c) high grade squamous intraepithelial lesion (HSIL) (see p. 113, Ch. 9). LSILs include CIN I and the changes of HPV (Koilocytic atypia).

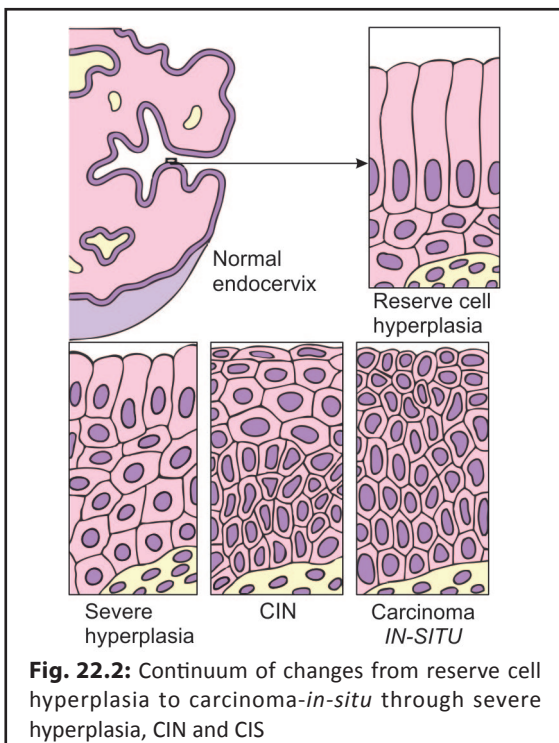
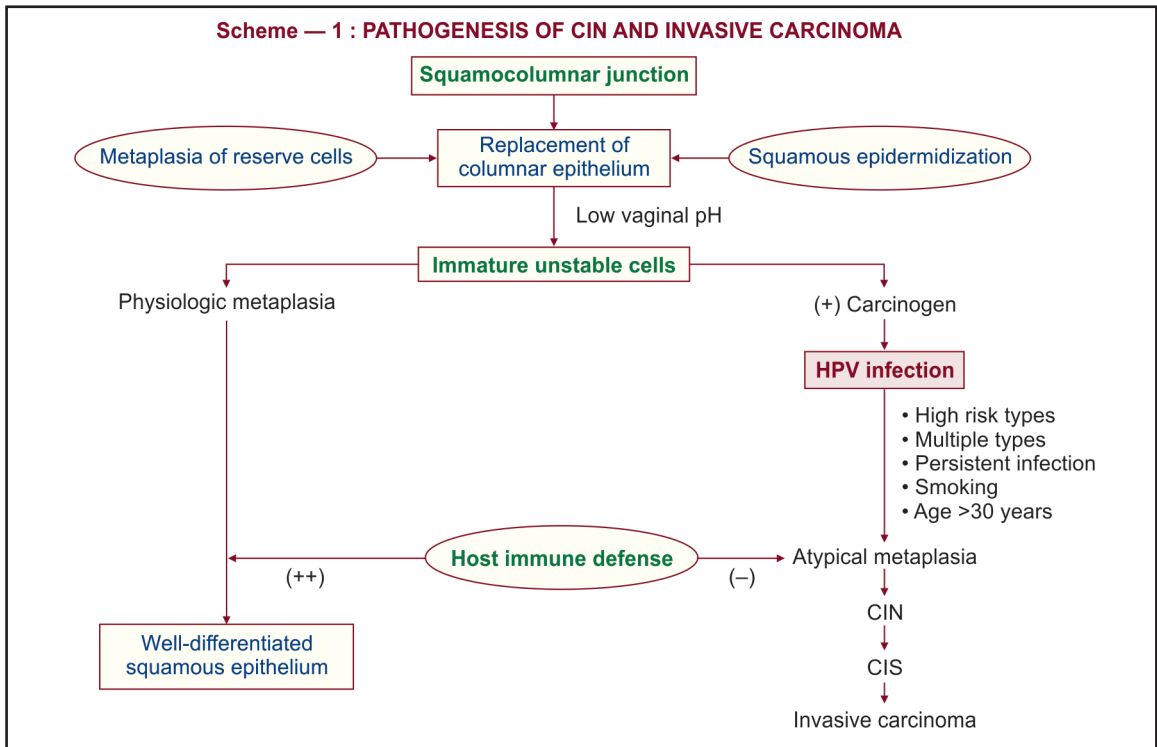
**The cytologic and histologic correlation** of mild, moderate and severe dysplasia, carcinoma-*in-situ*, CIN and the Bethesda’s system have been mentioned in Table 22.1. However, there is considerable degree of overlapping regarding the precise definition of



**Fig. 22.1A:** Normal stratified squamous epithelium of the ectocervix on the left is progressed to CIN/CIS on the right through various degrees of dysplastic changes



**Fig. 22.1B:** Pathogenesis of HPV infection



each category of intraepithelial neoplasia. There is no sharp morphologic boundary between them. This creates disagreements in the diagnosis of severity of the lesion.

Thus, the newer terminology CIN, is intended to emphasize that the **disease is a continuum and reflects the prognostic significance, if left untreated** (Fig. 22.1).

**Squamocolumnar junction (SCJ)** is the meeting point of columnar epithelium, that lines the endocervical canal, with squamous epithelium that lines the ectocervix (Fig. 22.3). This SCJ is a dynamic point. It moves up and down in relation to different phases of life, e.g. puberty, pregnancy and menopause.

In presence of estrogen the vaginal epithelium accumulates glycogen. The lactobacilli act on glycogen to produce the acid pH (lactic acid) of vagina.

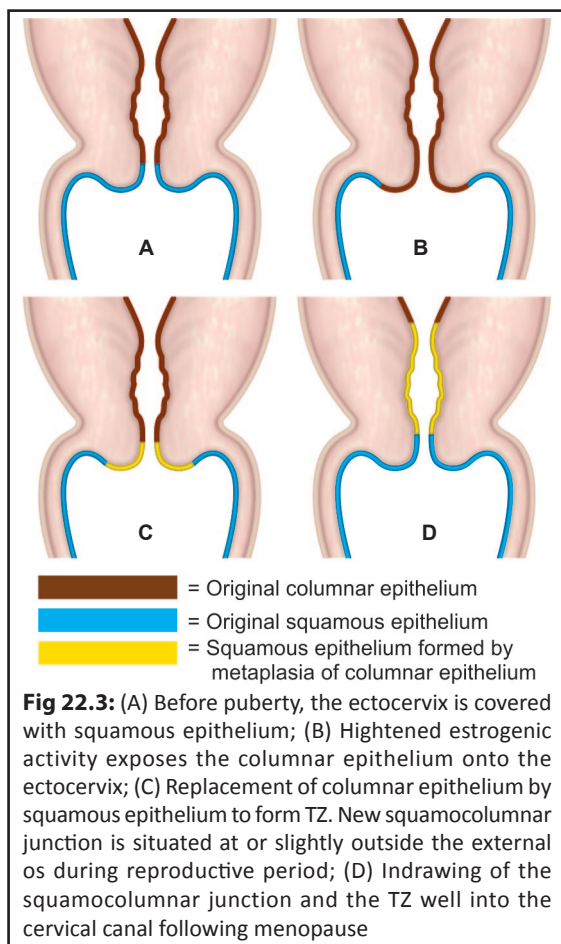
The **metaplasia** extends from the original SCJ (now squamosquamous) outside to the newly developed (physiologically active) SCJ (now squamocolumnar) inside (Figs 22.3). This area is defined as **transformation zone (TZ)**.

**PATHOGENESIS:** The process of carcinogenesis starts at the ‘**transformation zone**’ (TZ). The zone is not static but in a dynamic state. Two mechanisms are involved in the process of replacement of endocervical columnar epithelium by squamous epithelium.

- ◆ By squamous metaplasia of the subcolumnar reserve cells (Fig. 22.2).
- ◆ Squamous epidermidization by ingrowth of the squamous epithelium of the ectocervix under the columnar epithelium.

Initially, the squamous cells are immature but ultimately become mature and indistinguishable to the adjacent squamous epithelium.

This metaplastic process is very active at the time of menarche and during and after first pregnancy. These periods are of high estrogenic phase which lowers the vaginal pH. The acid pH probably is an important trigger for the metaplastic process. This



metaplastic cells have got the potentiality to undergo atypical transformation by trauma or infection.

The prolonged effect of carcinogens can produce continuous changes in the immature cells which may lead to malignancy. Early age sexual activity and multiple sexual partners are the most consistent risk factors. HPV infection is transmitted through sexual activity. Microtrauma (sexual intercourse) causes viral entry to the epithelium (basal or parabasal cells) of the transformation zone adjacent to the SCJ. HPV-DNA positivity is strongly related with the number of sexual partners. Women with multiple partners have high HPV DNA positivity rate (60%) compared to women with single partner (21%). **The important factors in the genesis of cervical cancer are: (i) Infection with high-risk HPV, (ii) Multiple types of HPV, (iii) Persistence of infection, (iv) Age > 30 years, (v) Smoking, and (vi) Compromised host immunodefense.**

#### LIFE CYCLE OF UNSTABLE EPITHELIUM (SCHEME - 2)

The cases of CIN I or II may revert back to normal and these are most often related to infection or removed during biopsy. Some, however, either remain static or progress to CIN III.

CIN III, however, is more susceptible to progress into invasive carcinoma. This is more so in cases of carcinoma-*in-situ*.

Thus, it is apparent that some of these epithelial atypia either remain stationary, regress or even progress to invasive carcinoma.

TABLE 22.2

#### RISK FACTORS FOR CIN AND CERVICAL CANCER

- ◆ Infection: HPV (16, 18, 31, 33), HIV, Chlamydia.
- ◆ Early sexual intercourse ( $\leq 16$  years).
- ◆ Sexually transmitted diseases.
- ◆ Early age of first pregnancy.
- ◆ Too many and too frequent births.
- ◆ Low socioeconomic status.
- ◆ Multiple sexual partners.
- ◆ Immunosuppressed (HIV positive) individuals.
- ◆ Husband whose previous wife died of cervical malignancy.
- ◆ Oral pill users.
- ◆ Smoking habits.

The real problem, at least to a clinician, to ascertain which one and how long the mild or moderate

## SCHEME—2: LIFE CYCLE OF UNSTABLE CERVICAL EPITHELIUM

Cervical epithelium	CIN I	CIN II	CIN III/CIS	
Regression to normal (%)	60	40	30	
Persistence (%)	30	35	50	
Progression to CIN III/CIS (%)	10	20	—	
Progression to invasion (%)	< 1	5	20	
Duration of disease progression (years)	Normal	CIN I, II	CIN III/CIS	Invasion
	0	5	10	20
Age of the patient (year)		25–30	30–35	40–45

dysplasia takes to proceed to invasive carcinoma without passing through CIS. As such, even a CIN I or II should not be ignored, but to be followed up carefully.

### EPIDEMIOLOGY

**Prevalence:** CIN is predominantly a disease of younger women. The mean age for carcinoma-*in-situ* is about 30 years, about 15 years less than that of invasive carcinoma. CIN like invasive carcinoma is most often related to some risk factors.

**Infectious agents:** The causative agents appear to be transmitted to the susceptible women during intercourse. Two viruses are implicated as casual agents.

### HUMAN PAPILLOMA VIRUS (HPV)

HPV is epitheliotropic and plays an important role in the development of CIN. HPV infected cells (**koilocytes**) are characterized by enlarged cells with perinuclear halos. The nucleus is large, irregular and hyperchromatic (Fig. 22.4). Depending on their oncogenic potential, HPV types are broadly grouped into two. More than 130 HPV types have been identified.

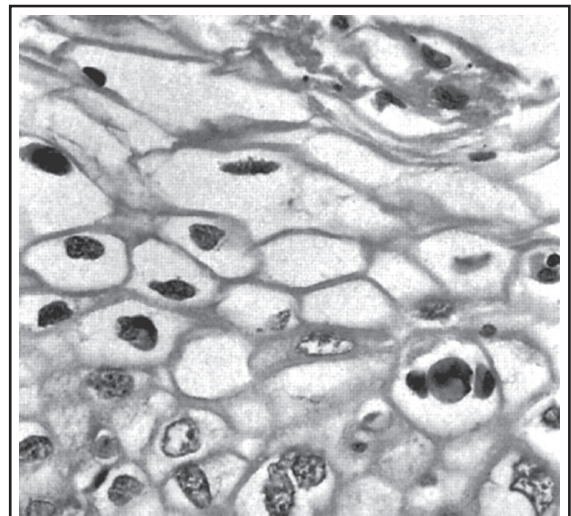
- ◆ High oncogenic risk—Types 16, 18, 31, 33, 35, 45, 56.
- ◆ Low oncogenic risk—Types 6, 11, 42, 43.

Over 99.7 percent of patients with CIN and invasive cancer are found to be positive with HPV DNA. HPV DNA detection in cervical tissues may be a screening procedure as that of Pap smear. Polymerase chain reaction or southern blot or **hybrid capture (HC)** technique is used for HPV DNA detection.

**Pathogenesis of HPV Infection:** HPV is epitheliotropic. Cervical epithelium → Infection (Latent/Active with virus replication) → Oncogenic HPV DNA integration to human genome → up-regulation of viral oncogenes → expression of E6 and E7 oncoproteins → Interference of tumor suppressor genes (p53 and Rb) → host cell immortalization and HPV induced neoplastic transformation.

Viral DNA activates host cell p53 proteins. Activated p53 causes cell apoptosis (cell death) and thus stop the viral multiplication. But HPV E6 and E7 oncoproteins cause proteolytic degradation of P53. This causes host cell immortalization and viral multiplication.

**HPV Triage Strategy** includes: (i) Pap Smear test (LBC p. 112, 113) → An atypical smear (after exclu-



**Fig. 22.4:** Koilocyte is the hallmark of cellular changes in HPV infection. Koilocytes are large, vacuolated squamous cells with a clear perinuclear halo. The nuclei are hyperchromatic, irregular with multinucleate forms

sion of infection), (ii) HPV testing → high-risk HPV positive, (iii) Colposcopy. This triage strategy can detect CIN II and III lesions effectively and reduces the load of colposcopy clinic.

**Triage screening:** (i) Liquid-based thin layer cytology (p. 109) evaluation → Atypical squamous cells.  
 (ii) Hybrid capture 2 for HPV DNA (see p. 324).  
 (iii) HPV DNA Test → Positive (High risk viruses) → Colposcopy → Biopsy  
 Negative → Repeat smear after one year

## DIAGNOSIS OF CIN

### ■ Cytologic Screening

Exfoliative cytology (Papanicolaou and Traut, 1943) has become the gold standard for screening. The smear should contain cells from SCJ, TZ and the endocervix. Ayre's spatula and an endocervical brush is used for the purpose. Cells are spread on a single slide and fixed immediately (see p. 111).

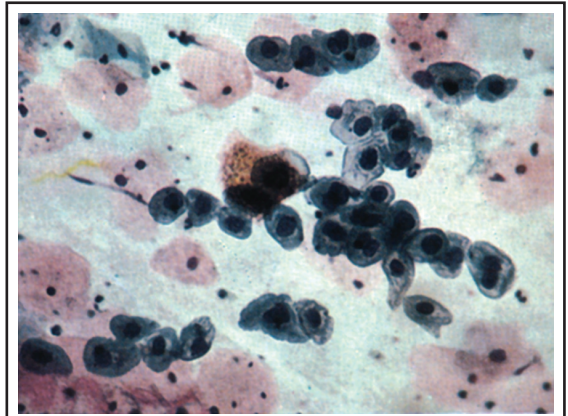
- (i) Dyskaryotic cells (see p. 112) are atypical cells with hyperchromatic large nuclei having abundant cytoplasm (Fig. 22.5).
- (ii) Carcinoma-*in-situ* cells contain hyperchromatic nuclei, coarse chromatin and lesser cytoplasm. There may be multiple nuclei and abnormal mitotic figures (Table 22.4).

Mild dyskaryotic smear is correlated with CIN II/III lesion in about 50 percent of cases. Severe dyskaryosis is correlated with about 90 percent of CIN II/III (Table 22.6).

**■ HPV-DNA testing is useful in cervical screening:** Hybrid capture method can reliably detect the high risk HPV types within hours. However, **only about 2–5 percent of women diagnosed with HPV DNA will ever develop CIN.** Nearly 80 percent test positive women will clear the infection (HPV) by their own immune defense. Positive test result in elderly women (> 30 years) suggests colposcopic examination. **HPV-DNA testing is an adjunct to cytology.** Quantitative HPV testing is more important compared to qualitative result.

**■ Visual inspection with acetic acid (VIA):** A speculum is introduced and acetic acid is applied to the cervix. Those women with acetowhite lesions are considered for colposcopic examination and/or biopsy.

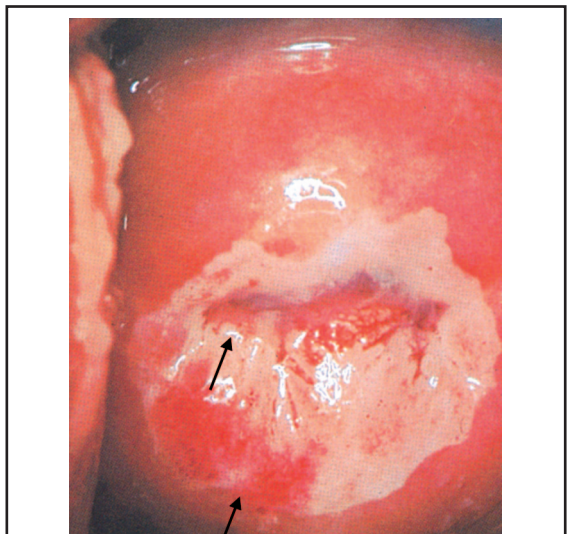
**■ Colposcopy:** Colposcopy is *in-situ* examination of the cervix with a low magnification (6–16 times) microscope (Fig. 9.20). It is complementary and not



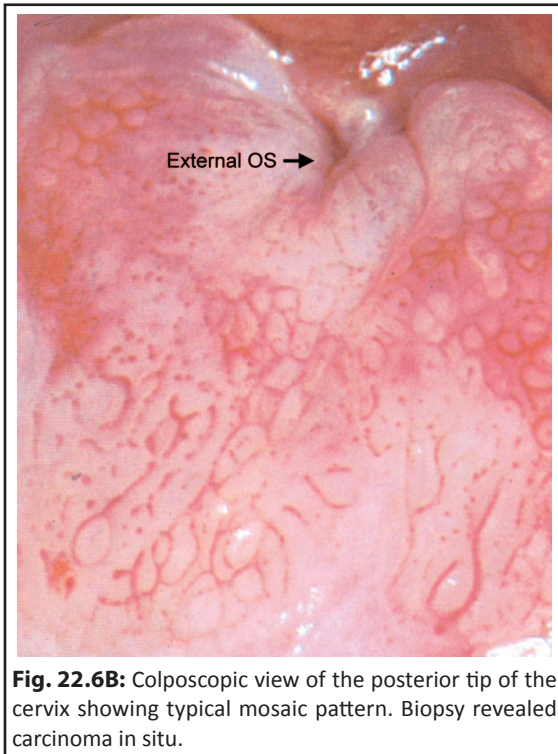
**Fig. 22.5:** Smear showing dyskaryotic cells

a substitute for cytology. Cytology is the laboratory method while colposcopy is the clinical method of detection. Cytology evaluates the morphological changes of the exfoliated cells. Colposcopy evaluates mainly the changes in the terminal vascular network of the cervix which reflect the biochemical and metabolic changes of the tissue. In fact, cytology identifies the patient having cervical neoplasm, colposcopy identifies the site where from biopsies are to be taken.

**Satisfactory colposcopic examination** includes visualization of the original SCJ, columnar epithelium



**Fig. 22.6A:** Colposcopic view of acetowhite epithelium (Schiller's negative) around the external os is seen. Squamo-columnar junction is clearly seen (arrow)



**Fig. 22.6B:** Colposcopic view of the posterior tip of the cervix showing typical mosaic pattern. Biopsy revealed carcinoma in situ.

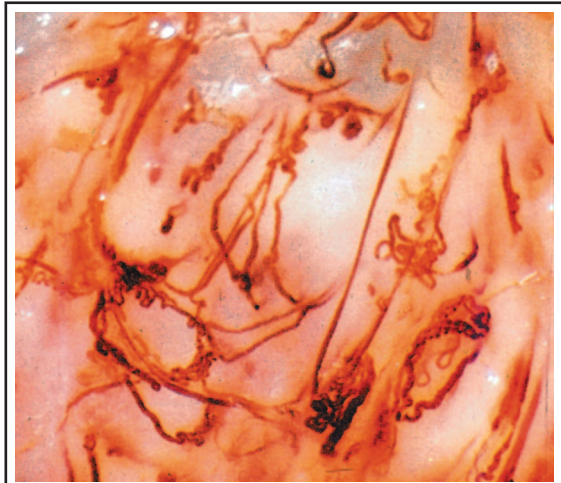
lium, and the transformation zone in entirety. For procedure of colposcopy, see p. 115.

### Indications

- Those having abnormal cytology.
- Those with grossly abnormal cervical lesions even if cytology is negative.
- Those with postcoital bleeding even if the smear is negative.

## ABNORMAL COLPOSCOPIC FINDINGS

- **White epithelium**—leukoplakia.
- **Aceto white epithelium**—epithelium turning white following application of 5 percent acetic acid due to cell protein coagulation (Fig. 22.6A).
- **Punctuation**—dilated capillaries which appear on the surface as dots (end on view of vessels).
- **Mosaic**—capillaries encircling polygonal shaped blocks of epithelial cells (Fig. 22.6B).
- **Atypical blood vessels** with irregular diameter and branching are suggestive of invasive carcinoma (see Fig. 22.7)



**Fig. 22.7:** Atypical blood vessels in invasive carcinoma

- **Irregular surface contour** with ulceration and friability.

■ **Cervicography:** Photographs are taken from the cervix. Film is viewed by an expert colposcopist. Similar to colposcopy, cervix is treated with 5% acetic acid before photography. It is complementary to cytology and colposcopy.

### ■ Biopsy with or without colposcopy

#### A. Colposcopy available (see p. 115)

- ◆ Colposcopy detects an abnormal area → biopsy is taken under its guidance (targeted biopsy).

#### B. Colposcopy not available

- ◆ **Schiller's test:** Employing iodine solution (Schiller's 0.3% or Lugol's 5%), multiple punch biopsies are taken from the **unstained areas**. Stained areas (normal) appear brown due to presence of glycogen
- ◆ Alternatively, ring biopsy is taken from the squamocolumnar junction and subjected to serial sections.
- ◆ **Endocervical curettage** is mandatory whether or not the entire transformation zone can be seen.

Cervical glandular intraepithelial neoplasia (CGIN) of the cervix is rare. Screening with cytology and even colposcopy are unsatisfactory. Cone biopsy is both diagnostic and therapeutic for young women with highgrade CGIN.

**Diagnostic Conization (see p. 589)**

In fact, the need for diagnostic cone biopsy has been reduced at least 80 percent by the use of colposcopically directed biopsies (Table 22.3).

**TABLE 22.3****INDICATIONS OF DIAGNOSTIC CONIZATION**♦ **Colposcopy available**

- Entire limits of the lesion not seen.
- Transformation zone not seen.
- Evidences of microinvasion on biopsy, colposcopy or cytology.
- Significant CIN on endocervical curettage.
- Normal colposcopic findings with abnormal cytology/biopsy.
- High grade CGIN lesion.

♦ **Colposcopy not available**

- Abnormal smear with healthy cervix.
- Positive diagnosis of CIS to exclude invasive carcinoma.
- Biopsy report is inconsistent with cytologic findings.

**TABLE 22.4****HISTOLOGIC PICTURE OF CIS (FIG. 22.8)**

- ♦ The entire epithelial layer is affected.
- ♦ There is loss of stratification and polarity.
- ♦ The cells vary in size and shape.
- ♦ The nuclei stain deeply with presence of frequent mitosis and abnormal chromatin pattern.
- ♦ The nuclei are larger and hyperchromatic with scanty cytoplasm.
- ♦ The basement membrane remains intact

**TABLE 22.5****FEATURES OF A DYSKARYOTIC CELL**

- Increased cell size.
- Pleomorphism—different staining appearance.
- Cells vary in their size and shape.
- Multinucleation.
- Clumping of chromatin—varying degree.
- Aneuploidy.
- Alteration in nuclear membrane.
- Perinuclear halo.

**TREATMENT OF CIN**▶ **Preventive** ▶ **Definitive**■ **PREVENTIVE**

▼ **HPV vaccines** has been developed from the capsid coat of the virus. It has high immunogenicity. Bivalent vaccines (cervarix) against HPV types 16, 18 and quadrivalent (Gardasil) against HPV types 16, 18, 6, 11 are effective in prevention of about 90% cervical cancer. Both the vaccines have some cross protection against HPV types 31, 33 and 45. Vaccines are given to girls aged 12–18 years, in three doses IM over the deltoid muscle. The impact of vaccines is greatest when it is given to females who have not been already infected. This is the reason it is recommended to adolescent girls. Vaccines are safe and well tolerated.

Vaccine induced neutralizing antibodies (IgG, IgA) works locally (cervix) by preventing the attachment of the virus to the cervical epithelium.

**Immune defense is type specific and is effective only when given prophylactically.**

**Vaccines are effective for atleast 7.5 years.**

However, screening with Pap test should be continued as the vaccines are type specific and do not protect against the other types of HPV.

▼ **Other measures**

- ▶ To delay sexual exposure until the cervical epithelium, especially in the transformation zone, has attained physiological maturity.
- ▶ To maintain a local hygiene and to treat vaginal infections.
- ▶ To use condom specially during early sexual life.
- ▶ To maintain penile hygiene as it may be the reservoir for high risk HPV.
- ▶ Reducing or quitting smoking reduces CIN.

■ **DEFINITIVE TREATMENT**

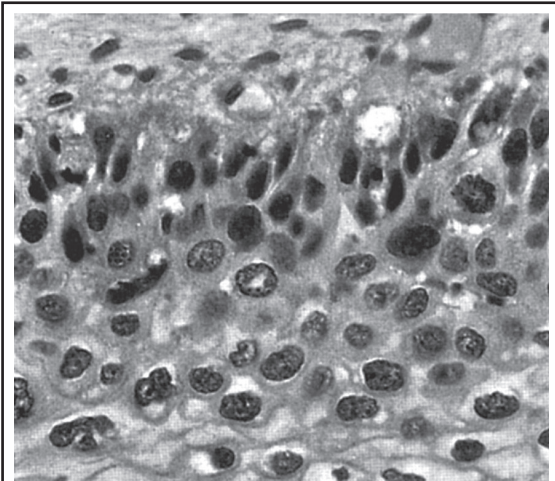
The treatment modalities depend on:

- ♦ Age of the patient.
- ♦ Desire for reproduction.
- ♦ Risk factors present. ♦ Degree of dysplasia.
- ♦ Facilities available for follow up such as colposcopy and/or cytology.

**Treatment options are:**

- a. *Observation with repeat smear and colposcopy every 4–6 months.*





**Fig. 22.8:** Histology of carcinoma-*in-situ* of cervix. Marked nuclear abnormalities are seen throughout most of the thickness. Abnormal mitotic figures are present

b. *Local ablative methods*

- Cryotherapy
- Cold coagulation
- Electrodathermy
- Laser vaporization

c. *Excisional methods*

- Large loop (electrosurgical) excision of transformation zone (LLETZ).
- Cone excision—using a knife or laser.

d. *Hysterectomy*—abdominal or vaginal.

**CIN I:** Women with CIN I, confirmed on biopsy, is kept under observation with Pap smear follow up at 6 months or HPV DNA test at 12 months. If both the tests are negative routine recall (screening) is done.

**CIN II:** The fact that over a prolonged follow-up, about 10–15 percent of CIN I and II progress to CIS. Then again, it is quite impossible to predict which one will remain stationary and which one will progress to severe dysplasia or CIS. **As such, CIN II is commonly treated with LLETZ.**

### CIN III AND CIS

#### Patient desirous for reproduction

The basic concept is that CIN is a superficial lesion. As such, complete destruction of the lesion is considered to be a satisfactory treatment.

Pretreatment accurate evaluation about the extent of lesion and exclusion of invasive carcinoma with the available gadgets (cytology, colposcopy and directed biopsy) is a sine-qua-non to get a good result.

Recurrence rate is high in cases of large lesions or those involving the endocervical glands.

#### ■ ABLATION OF THE LOCAL LESION

The following criteria should be fulfilled :

- ◆ The entire lesion is visualized within the transformation zone.
- ◆ No evidence of microinvasion or invasion.
- ◆ No endocervical glandular involvement.
- ◆ No discrepancy in cytology, colposcopy and biopsy report.

#### Methods of local ablation

- ◆ **Cryotherapy** acts on the principle of crystallizing the intracellular water at temperature of  $-90^{\circ}\text{C}$  (see p. 591). It uses either nitrous oxide or carbon dioxide. Depth of tissue destruction is 5 mm. This method is ideal for minor degree and localized CIN lesions. Double freeze technique (freeze-thaw-freeze) increases the effectiveness of cryotherapy (see p. 591).
- ◆ **Cold coagulation** destroys cervical tissue at a temperature of  $100-120^{\circ}\text{C}$ . It does not need any anesthesia. Depth of tissue destruction is about 4 mm.
- ◆ **Electrodathermy** destroys cervical tissue up to a depth of 8–10 mm using a unipolar needle electrode. It is done under general anesthesia.
- ◆ **Carbon dioxide laser** through colposcopic guidance—can destroy the epithelium by vaporization up to a depth of 7 mm. The method is of choice when CIN extends onto the vaginal fornices.

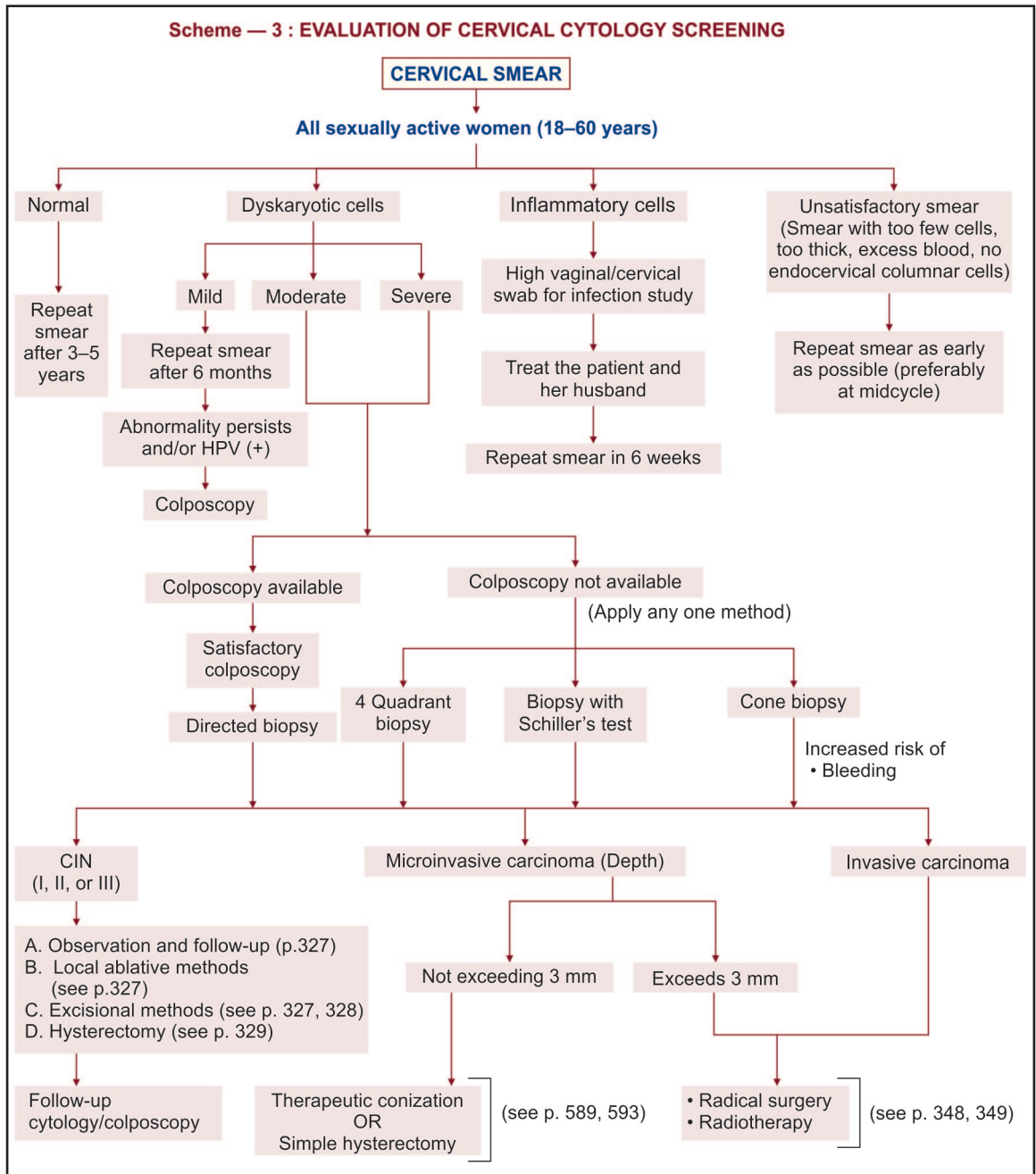
**Advantages of laser vaporization:** (a) preservation of transformation zone for subsequent follow up, (b) precision control technique in depth and breadth and (c) rapid healing.

#### Contraindications of Ablation Treatment

- ◆ Suspected invasive lesion or glandular disease.
- ◆ SCJ not clearly seen.
- ◆ Discrepancy in smear/colposcopy/biopsy finding.

#### ■ Excision

**Conization (see p. 589, Ch. 34):** While cold knife conization is commonly done but laser excision cone biopsy is preferable, as it can be done as outpatient



under local anesthesia with colposcopic guidance. Blood loss is also less. Conization for CIN is as effective as hysterectomy provided the cone margins are free of disease. Complications such as hemorrhage, infection, cervical stenosis or incompetence depend on the length of cone excised.

■ **Large loop excision of the transformation zone (LLETZ) or Loop electrosurgical excision procedure (LEEP)**

A loop (2–3 cm) of very thin stainless-steel wire is used for excision of the TZ. Blended current (cutting

and coagulation), low voltage output is used. It is a simple and quicker procedure. It is done under local anesthesia. Tissue up to a depth of 10 mm or more can be removed and sent for histological examination. Complications are minimal as compared to cone excision.

**Follow up** protocol includes an initial post-treatment cytology at 6 months and then repeated at 12 months. Thereafter, cytology is repeated at 3 yearly intervals.

### Recurrence

The recurrence rate is about 3–5% and development of invasive carcinoma ranges between 0.1–0.4 percent.

Any recurrence of vaginal intraepithelial neoplasia diagnosed with colposcopic follow-up, requires treatment by excision biopsy, carbon dioxide laser vaporization or topical 5-fluorouracil (5-FU).

### ■ Hysterectomy

- ◆ CIN lesion associated with other gynecologic problems such as prolapse, fibroid, pelvic inflammatory disease or endometriosis.
- ◆ CIN extends into the vagina.
- ◆ Persistent dyskaryotic smear even with treatment.
- ◆ High grade CGIN in elderly women.
- ◆ Patients with CIN 3.
- ◆ Patients with poor compliance for follow up.
- ◆ Cancer phobia.

Removal of vaginal cuff is done, if the lesion extends to the vaginal fornices.

## PREMALIGNANT ENDOMETRIAL LESION

There is ample evidence that both endometrial hyperplasia and carcinoma are estrogen-dependent. Long-term unopposed estrogen, particularly around the time of menopause, often leads to various types of endometrial hyperplasia (Fig. 22.9).

**Risks:** A significant number of such cases will develop invasive carcinoma during the period of 2–8 years (Table 22.6). It has been estimated that about 25 percent of adenomatous hyperplasia, 50 percent of atypical hyperplasia and 100 percent of carcinoma-*in-situ* will develop endometrial carcinoma, if left untreated.

### ETIOLOGY

Endometrial hyperplasia develops in women of 40–50 years. Amongst numerous factors, unopposed estrogen appears to be the primary factor. Pre-menopausal persistent anovulation is almost a constant factor. In the postmenopausal women with obesity, peripheral conversion of androgens into estrogen is a risk factor. Long-term estrogen stimulation in condition of polycystic ovarian syndrome or feminizing ovarian tumor may predispose to endometrial cancer (Table 22.7).

### DIAGNOSIS

- ◆ There is no classic symptom of premalignant lesions. But the constant feature is abnormal perimenopausal uterine bleeding and ultimate diagnosis is by uterine curettage and histology.

**TABLE 22.6**

### CLASSIFICATION OF ENDOMETRIAL HYPERPLASIA (ISGP) (Precursors to Endometrial Carcinoma)

Type of hyperplasia	Progression to cancer (%)
Simple (cystic without atypia)	1
Complex (adenomatous without atypia)	3
Simple (cystic with atypia)	8
Complex (adenomatous with atypia)	29

**TABLE 22.7**

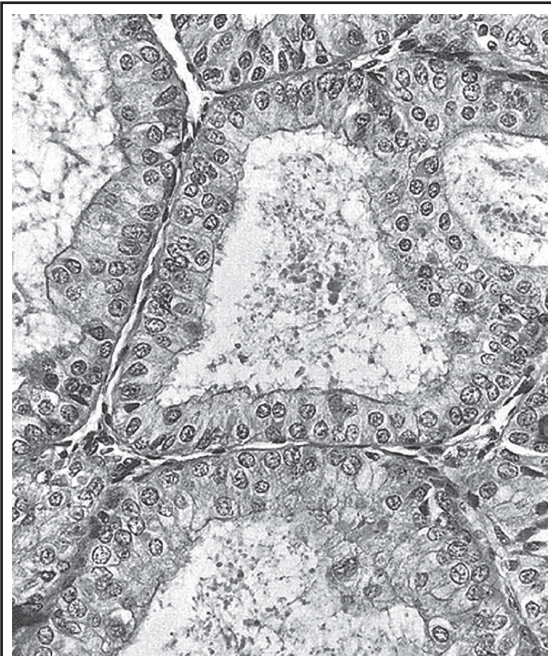
### RISK FACTORS

- ◆ Unopposed estrogen stimulation
- ◆ Delayed menopause
- ◆ PCOS
- ◆ Nulliparity
- ◆ Previous radiation therapy
- ◆ Family history of endometrial carcinoma, carcinoma of breast, ovary or colon
- ◆ Tamoxifen therapy
- ◆ Diabetes
- ◆ Obesity
- ◆ Hypertension

**TABLE 22.8**

### PROTECTIVE FACTORS

- ◆ Multiparity
- ◆ Normal weight
- ◆ Combined oral contraceptive use
- ◆ Progestogen therapy
- ◆ Menopause <49 years



**Fig. 22.9:** Complex endometrial hyperplasia with nuclear stratification and cytological atypia. The glands are dilated. Mitosis is present in stroma also

- ◆ Accidental diagnosis is made during investigation of infertility, DUB, PCOS or excised specimen of removed uterus.
- ◆ Diagnosis by screening procedures extended to 'at risk' women is not as effective like that of CIN. Vaginal pool smear, endometrial aspiration (pipelle endometrial sampling), endometrial biopsy

(curettage) and vaginal ultrasound (see p. 117) are the different methods available for screening.

### HISTOLOGY

**Simple hyperplasia:** Endometrium is thick. The glands are dilated and have outpouching and invaginations. They are crowded and have irregular outlines. The stroma is more dense and cellular.

**Complex hyperplasia (Fig. 22.9):** Endometrium is thicker. The gland are crowded and arranged back to back with reduced stroma. Most glands have irregular outlines. There are papillary processes and intraluminal bridges within the glands. Epithelial pseudostratification is present.

**Atypical hyperplasia:** The endometrial glands have cytologic atypia. The gland outlines are of complex hyperplasia in type. The nuclei of the glands show enlargement, irregular size and shape, hyperchromasia and coarse chromatin.

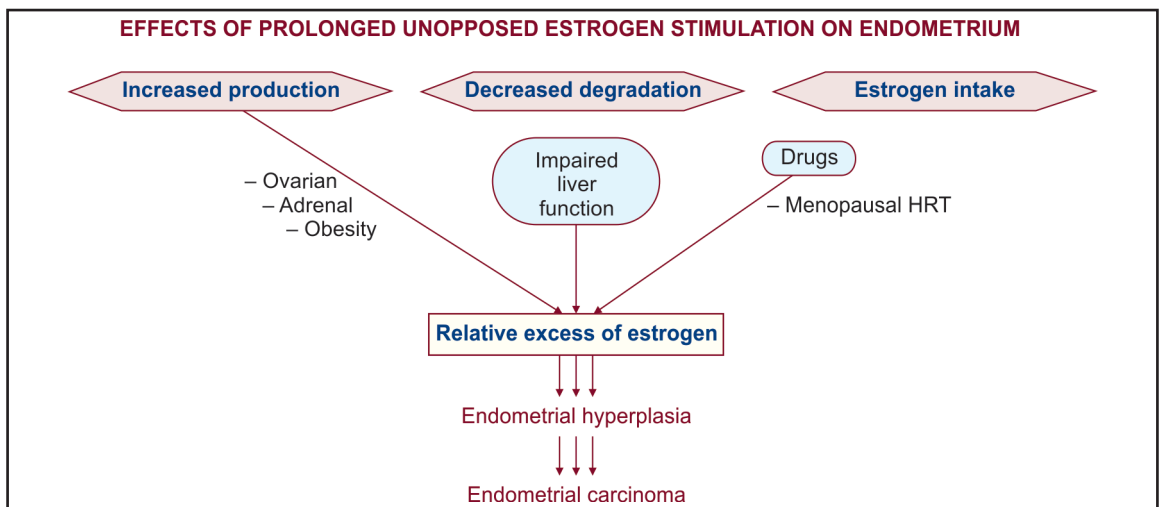
**Carcinoma-in-situ:** Commonly describes a lesion with severe cytologic as well as architectural abnormalities of the glands.

### MANAGEMENT

- Preventive
- Definitive treatment

#### Preventive

- ◆ To maintain ideal body weight.
- ◆ Estrogen use in non-hysterectomized women should be restricted. The combined estrogen-



progestogen preparations reduce the risks than estrogen alone.

- ◆ Screening of ‘at risk’ women mentioned earlier should be done by periodic endometrial sampling.

**Definitive treatment**—Treatment depends on:

- ◆ **Age of the patient**
- ◆ **Histologic type of hyperplasia**

**Young patient with cystic or adenomatous hyperplasia:**

- **Cyclic progestogen therapy** for 6–9 months may be helpful. Follow-up at interval of 6 months by endometrial sampling is essential to note whether its regression is there or not.
- **Induction of ovulation** in cases of PCOS to improve the fertility (p. 462, 470) in a young woman, is advised.

- **Atypical hyperplasia** requires therapy with a progestin (provera 10 mg bid) continuously or cyclically for 6–9 months. Periodic endometrial sampling at least every 6 months is essential.

**Perimenopausal and postmenopausal women:**

- **Hyperplasia without atypia:** Continuous progestin therapy may be considered. However, hysterectomy with bilateral salpingo-oophorectomy is done as an alternative as the risk of carcinoma increases with age.
- **Moderate to severe atypical hyperplasia** and also those women who fail to respond with progestin therapy should be considered for hysterectomy.

## KEY POINTS

- The premalignant lesions of the vulva include vulval intraepithelial neoplasia (VIN), Paget’s disease, lichen sclerosus, squamous hyperplasia and condyloma accuminata.
- Multicentric disease should be considered when VIN is diagnosed. VIN needs long term follow up as the recurrence risk is high. Women with VIN presents commonly with complaints of itching, soreness, or burning or may remain asymptomatic. Invasive potential of VIN is less (<10%) compared to CIN (40%). For confirmation of carcinoma-*in-situ*, 3–5 mm diameter dermal punch biopsy is taken under local anesthetic. Alternatively, colposcopic examination and biopsy may be done after application of 5 percent acetic acid.
- Surgery for carcinoma-*in-situ* includes—simple excision wide local excision, skinning vulvectomy, simple vulvectomy and laser therapy. Regular follow up is mandatory. Paget’s disease is often associated with carcinoma breast. Simple vulvectomy is the surgery.
- Predisposing factors for VAIN include infection with HPV, herpes virus II, immunosuppression or radiation. VAIN is diagnosed by exfoliative cytology, colposcopy and biopsy. The treatment is by 5-Fluorouracil cream or by ablation therapy by cryosurgery or laser.
- CIN is a spectrum of premalignant changes in the cervical epithelium showing varying degree of cellular atypia. It is a continuum of changes that begin with mild atypia and may progress to CIS. There is no sharp boundary between them.
- Pap smear (cytology) is the gold standard for screening and has reduced the incidence of invasive carcinoma of cervix by about 80 percent and the mortality by 70 percent. The false-negative rate of Pap smear is about 5–15 percent. Liquid-based cytology is found to be superior (see p. 113).
- Combined testing of HPV DNA and cervical cytology should preferably be done in women older than age >30.
- Squamous intraepithelial lesion (SIL) is a cytologic term, used in Bethesda classification (1988). LSIL corresponds to HPV infection and CIN I whereas HSIL corresponds to CIN II, CIN III and CIS.

The squamocolumnar junction (SCJ) is a dynamic level that lies near the external os during the reproductive life. It moves further down during pregnancy and recedes up into the endocervical canal after menopause.

*Contd...*

Contd...

The process of pathogenesis starts at the 'transformation zone'. The acid pH is probably an important trigger for the metaplastic process. This metaplastic cells can undergo atypical transformation by trauma or infection, if the host response is poor.

- The exact cause of CIN is unknown. HPV infection is an increased risk factor. Human papilloma virus (HPV) types having high oncogenic risk are: 16, 18, 31, 33, 58 and 68. Not all women with HPV infection progress to CIN and HPV infection may regress (80%) spontaneously.

**HPV vaccines** against HPV types 16, 18 (Bivalent) or HPV types 16, 18, 6, 11 (Quadrivalent) are effective in prevention of 90% of cervical cancer. Vaccines are given to girls aged 12–18 years in three doses. Both the vaccines have some cross protection against HPV types 31, 33 and 45. Vaccines are type specific and effective only when given prophylactically (see p. 326). Vaccines are safe and well-tolerated.

- The risk of progression of CIN to invasive carcinoma is variable. The risk of malignant progression is lowest with CIN I—1 percent, moderate with CIN II—5 percent and highest with CIN III—20 percent. It is indeed difficult to ascertain which type of CIN and with what time CIN lesions will proceed to invasive carcinoma. CIN should be observed as it usually regresses spontaneously.
- The mean age of CIN is about 30 years. Some of the documented risk factors are early sexual intercourse, early age of first pregnancy, too many and too frequent births, low socioeconomic status, multiple sexual partners, immunosuppressed (HIV positive) individuals, STD, husband whose previous wife died of cervical malignancy, oral pill users, smoking habits, etc.
- Cytologic and colposcopic findings are aids to the diagnosis but biopsy is only confirmatory.
- The triage strategy (see p. 323) includes Pap smear test (see p. 110) → atypical smear → HPV DNA assay using hybrid capture 2 → High-risk HPV → Colposcopy (see p. 324). This strategy eliminates the need for unnecessary colposcopic examinations and also frequently repeated Pap smears, when it is negative.
- Colposcopy is the examination of the cervix with magnification (6–16 times). Colposcopy is done when the Pap smear is abnormal. Biopsy is indicated when the colposcopic findings (see p. 324) are abnormal. Conization of the cervix (p. see 589) is performed when there is any discrepancy of cytology, colposcopy and biopsy reports.
- CIN 1 should be observed rather than treated as it regresses spontaneously. LLETZ (LEEP) is used to treat CIN 2 AND 3. Cone excision should be done to detect cervical glandular disease as cytology and colposcopy are not reliable.

The aim of therapy is to destroy all the abnormal (CIN) areas. Cryotherapy, cold coagulation, Electrodiathermy, Laser and LLETZ all can destroy the lesion. In cases with completed family, hysterectomy is the preferred treatment. In conservative surgery, long-term follow-up should be done.

Microinvasive carcinoma requires a conization specimen. Conization is as effective as hysterectomy for CIN, provided the cone margins are free of disease.

- Follow up of patients treated for CIN is cytology at 6 months and then repeated at 12 months. Thereafter cytology is repeated at 3 yearly intervals. The risk of recurrence of CIN following initial therapy is about 3–5 percent.
- CIN lesions detected during pregnancy needs to be evaluated in puerperium as such a lesion may regress spontaneously.
- The premalignant endometrial lesions include simple hyperplasia, complex hyperplasia, atypical simple hyperplasia and atypical complex hyperplasia (WHO). In young patients with cystic or glandular hyperplasia, cyclic progestogen therapy for 6–9 months may be helpful. If regression fails to occur or in perimenopausal women, hysterectomy with bilateral salpingo-oophorectomy should be done.

Atypical hyperplasia in peri or postmenopausal women is considered for hysterectomy.

- VAIN is associated with CIN in 70% of cases.
- VAIN is caused by oncogenic HPV. Other risk factors are similar to CIN.

# Genital Malignancy

## GENERAL CONSIDERATION

There is wide range of geographical variation in the incidence of major genital malignancies, the reason is far from clear. In USA (1985), cancer of the breast, ovary and uterus accounts for 51 percent of all cancers among females. These sites accounted for 28 percent of all deaths caused by cancer. In most of the developed countries, cancer of the breast tops the list in female malignancies; **whereas in the developing countries, including India, genital malignancies top the list.** There is also not only wide variation in the incidence but also in the distribution and life time risk of the major genital malignancies (Tables 23.1 to 23.3).

**TABLE 23.1** INCIDENCE OF MAJOR GENITAL MALIGNANCIES PER 100,000 WOMEN

	<i>Developed countries</i>	<i>Developing countries</i>
Carcinoma cervix	4–15	30–40
Carcinoma body	10–20	5
Carcinoma ovary	12–15	4–6

**TABLE 23.2** DISTRIBUTION OF GENITAL MALIGNANCY (%)

	<i>Developed countries</i>	<i>Developing countries</i>
Carcinoma cervix	60	80
Carcinoma body	25–30	5
Carcinoma ovary	10	10–15

**TABLE 23.3** LIFE TIME RISK OF PELVIC MALIGNANCY

	<i>Carcinoma cervix</i>	<i>Carcinoma body</i>	<i>Carcinoma ovary</i>
USA			
♦ Black	1.9	1.2	1.0
♦ White	0.9	2.7	1.4
UK			
♦ Scotland	1.2	0.8	1.3
Japan	1.8	0.3	0.5
India (Mumbai)	2.2	0.2	0.8

## VULVAL CARCINOMA

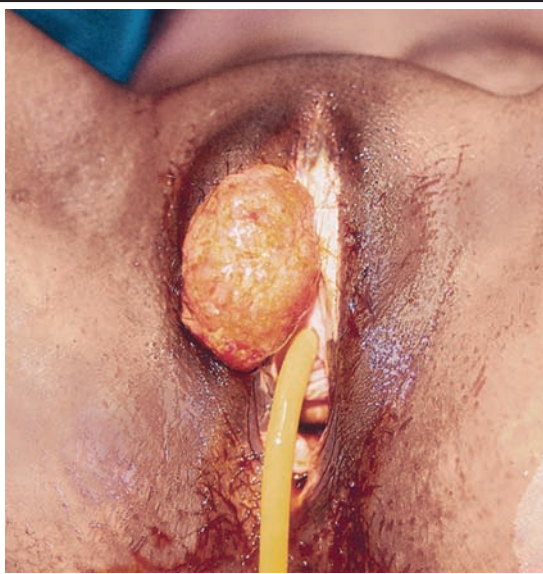### INCIDENCE

The lesion is rare, about 1.7 per 100,000 females. The distribution varies from 3-5 percent amongst genital malignancies.

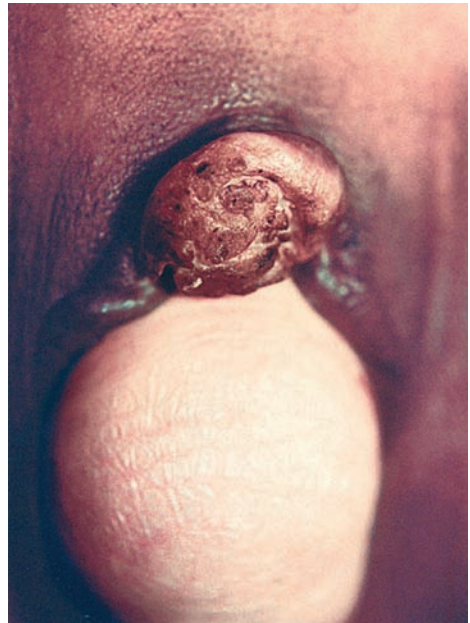### ETIOLOGY

The etiology remains unclear. But the following factors are often related.

- ♦ Usually occurring in postmenopausal women with a median age of 60.
- ♦ More common amongst whites.
- ♦ Increased association with obesity, hypertension, diabetes and nulliparity.
- ♦ Associated vulval epithelial disorders (lichen sclerosus) specially of atypical type are the risk factors.
- ♦ Human papilloma virus (HPV) DNA (type 16, 18) has been detected in patients with invasive vulval cancer.



**Fig. 23.1:** Vulval carcinoma on labium majus (commonest site)



**Fig. 23.2:** Procidentia associated with carcinoma clitoridis (second common site of vulval malignancy)

- ◆ Vulval cancer may have a causal relation with condyloma accuminata (HPV 6, 11), syphilis and lymphogranuloma venereum.
- ◆ Chronic pruritus usually precedes invasive vulval cancer.
- ◆ Chronic irritation of the vulva by chemical or physical trauma associated with poor hygiene may be a predisposing factor.
- ◆ Other primary malignancies have been observed in about 20 percent of cases with vulval cancer. Cervix is most commonly affected; other sites are breast, skin or colon.

### **PATHOLOGY**

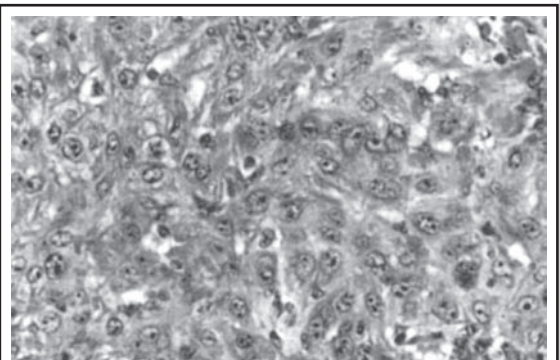
**Sites:** The commonest site is labium majus followed by clitoris and labium minus. Anterior two-third are commonly affected. Malignant ulcer on the contralateral side may be multifactorial (Figs 23.1 and 23.2).

### **Naked Eye**

- *Ulcerative:* The features are raised everted edges, sloughing base with surrounding induration. This is common.
- *Hypertrophic:* The overlying skin may be intact or it ulcerates sooner or later. This is rare.

### **HISTOLOGICAL TYPES OF VULVAL CANCERS**

- Squamous cell carcinoma—90% (Fig. 23.3)
- Melanoma 5%
- Adenocarcinoma (Bartholin's gland)
- Basal cell carcinoma
- Sarcoma



**Fig. 23.3:** Histologic picture of vulval squamous cell carcinoma



## SPREAD

**Direct:** The direct spread occurs to the urethra, vagina, rectum and even to pelvic bones. As the disease progresses, other sites in the vulva may develop neoplasia, so that multifocal sites do occur.

**Lymphatics:** It is the commonest method of spread of lesion. It is estimated that in about 50 percent, the lymph glands are involved by the time the patient consults the physician. **The following facts are to be borne in mind:**

- The lymphatic spread is primarily by embolization and only at a late stage, the spread is by permeation to fill the lymphatic channels.
- Contralateral metastases are not infrequent (25%) as the lymphatics of the vulva cross the midline.
- When the ipsilateral nodes are not involved from a lesion located on one side, spread to the contralateral groin node is very unlikely.
- The lymph node involvement follows a sequential pattern. The lymphatics of labia → superficial inguinal lymph nodes → deep inguinal lymph nodes → pelvic nodes.
- Pelvic nodes are secondarily involved in about 20 percent with affected inguinal nodes. The **nodes involved are** obturator, external iliac, hypogastric and common iliac.
- Lymphatics of the clitoris, anus and rectovaginal septum may drain directly into the pelvic lymph nodes.
- Involvement of pelvic nodes, bypassing the inguinal lymph nodes, is less than 3 percent.
- Incidence of lymph gland involvement is directly related to the site, size of the lesion and the depth of stromal invasion (see Table 23.4). Chance of bilateral lymph node involvement also increases when the midline structures (clitoris, perineum) are involved.
- Histologically proved groin node involvement is present in 25 percent when missed on clinical assessment. In almost 25 percent, the nodes are histologically negative when clinically thought to be involved. Approximate incidence of lymph node involvement is given in Table 23.4.
- Regional lymph nodes are assessed clinically and also by using MRI (p. 118), **sentinel node lymphoscintigraphy** (p. 341), ultrasound and PET (p. 119).

<i>Depth of invasion (mm)</i>	<i>Percent with positive nodes</i>
<1	0
1–2	7.5
2.1–3	10.0
3.1–5	30

**Hematogenous:** This is rare but may occur in advanced cases.

## CLINICAL FEATURES

**Patient profile:** The patients are usually postmenopausal, aged about 60 years often with obesity, hypertension and diabetes.

## Symptoms :

- Asymptomatic
- Pruritus vulvae
- Swelling with or without offensive discharge
- Difficulty in urination
- Vulval ulceration
- Bleeding
- Inguinal mass
- Pain

## Signs

- Vulval inspection reveals an ulcer or a fungating mass on the vulva. The ulcer has a sloughing base with raised, everted and irregular edges and it bleeds to touch. Surrounding tissue may be edematous and indurated.
- Associated vulval lesions mentioned earlier may be present.
- Inguinal lymph nodes of one or both the sides may be enlarged and palpable. The enlargement may also be due to infection.
- Clinical examination of the pelvic organs, including the cervix, vagina, urethra and rectum must be done. This is due to the coexistence of other primary cancers in the genital tract.

## Diagnosis

The diagnosis is confirmed by biopsy.

- ◆ When a definite growth is present, the biopsy is to be taken from the margin.
- ◆ Cystourethroscopy, Proctoscopy CT/MRI scan (for nodes) may be needed.

- ◆ In cases of vulval dystrophy, the sites are from multiple areas usually from the persistent red areas or from stained areas following toluidine blue test.

### DIFFERENTIAL DIAGNOSIS

The lesion needs differentiation from:

- ◆ Condyloma accuminata
- ◆ Syphilitic ulcer
- ◆ Tubercular ulcer
- ◆ Lymphogranuloma venereum
- ◆ Soft sore.

**STAGING:** The staging is based on clinical examination and includes only the primary carcinoma, excluding melanoma. The FIGO classification is widely used.

### CAUSES OF DEATH

- Uremia—from ureteric obstruction due to enlarged common iliac and paraaortic nodes.
- Rupture of the femoral vessels by the overlying involved inguinal lymph glands.
- Sepsis.

### MANAGEMENT

#### Prophylactic

- ◆ Adequate therapy for non-neoplastic epithelial disorders of the vulva (see chapter 17).
- ◆ Adequate therapy for persistent pruritus vulvae in postmenopausal women (see p. 553).
- ◆ Frequent use of multiple biopsies in conservative treatment of VIN.
- ◆ Liberal use of simple vulvectomy in postmenopausal women with VIN where follow-up facilities are not available.

#### Definitive Treatment

##### ■ Microinvasive lesion

There is increased incidence of lymph node involvement in lesion of more than 1 mm invasion. It is thus prudent to perform **radical vulvectomy with bilateral groin node dissection in all cases of stromal invasion more than 1 mm.**

However, if the invasion is less than 1 mm, wide local excision with or without ipsilateral groin lymphadenectomy may be done with follow up. Generally, there is no lymph gland involvement (see

Table 23.4). Tumor free surgical margin should be at least 1 cm to prevent local recurrence.

##### ■ Frank invasion

**Radical vulvectomy with bilateral inguofemoral lymphadenectomy** is the ideal surgery (see p. 607). Three separate incision (one for radical vulvectomy and one each for groin node dissection) approach is currently preferred instead of en-block approach (Fig. 33.14).

#### FIGO STAGING OF CARCINOMA OF THE VULVA (2009)

<b>Stage I</b>	Tumor confined to the vulva.
IA	Lesions ≤ 2 cm in size, confined to the vulva or perineum and with stromal invasion ≤ 1.0 mm*, no nodal metastasis.
IB	Lesions > 2 cm in size or with stromal invasion > 1.0 mm*, confined to the vulva or perineum, with negative nodes.
<b>Stage II</b>	Tumor of any size with extension to adjacent perineal structures (1/3 lower urethra, 1/3 lower vagina, anus) with negative nodes.
<b>Stage III</b>	Tumor of any size with or without extension to adjacent perineal structures (1/3 lower urethra, 1/3 lower vagina, anus) with positive inguino-femoral lymph nodes.
IIIA	(i) With 1 lymph node metastasis (≥ 5 mm), or (ii) 1–2 lymph node metastasis(es) (< 5 mm)
IIIB	(i) With 2 or more lymph node metastases (≥ 5 mm), or (ii) 3 or more lymph node metastases (< 5 mm).
IIIC	With positive nodes with extracapsular spread
<b>Stage IV</b>	Tumor invades other regional (2/3 upper urethra, 2/3 upper vagina), or distant structures.
IVA	Tumor invades any of the following : (i) upper urethral and/or vaginal mucosa, bladder mucosa, rectal mucosa, or fixed to pelvic bone, or (ii) fixed or ulcerated inguino-femoral lymph nodes.
IVB	Any distant metastasis including pelvic lymph nodes.

\* The depth of invasion is defined as the measurement of the tumor from the epithelial-stromal junction of the adjacent most superficial dermal papilla to the deepest point of invasion.

Pelvic node metastases are rare unless inguino-femoral nodes are involved. Pelvic lymphadenectomy in cases of positive deep node involvement is omitted in preference to external radiation on the groin and pelvis—in the form of 4500 to 5000 cGy, usually 4–6 weeks after surgery.

Negative **sentinel lymph node** (p. 341) biopsy for micrometastasis may avoid extensive lymphadenectomy. Radical vulvectomy is often associated with major long-term morbidity, sexual dysfunction and loss of body image (see p. 607). Radical local excision of the vulva with wide margins (1–3 cm) is considered to be an alternative to radical vulvectomy with equal result.

**I** *If the general condition is poor and/or in presence of medical diseases*

The following principles may be adopted:

- Two stage operation is preferred. Total vulvectomy followed by at a later date, bilateral inguino-femoral lymphadenectomy.
- Total vulvectomy followed by full pelvic and groin irradiation (megavoltage therapy).
- **Neoadjuvant chemotherapy**—chemotherapy followed by surgery, radiotherapy or both.
- **Technically inoperable or recurrent lesion**
  - **Chemotherapy** (cisplatin, bleomycin, 5-FU) can be used as radiation sensitizer.
  - **Chemoradiation therapy** may be combined as primary therapy or following surgical excision of the tumor.
  - **Radiotherapy** can be used as a primary therapy for advanced disease.

## RESULTS

**With negative groin nodes**, the 5 year survival rate for invasive carcinoma ranges from 90–100 percent.

**With positive groin nodes**, the survival rate falls to 20–55 percent. **With positive pelvic nodes**, the survival rate falls even below 20 percent.

### Prognostic Factors for Vulval Squamous Cell Carcinoma

- ◆ Clinical stage of the disease.
- ◆ Site of the tumor (p. 334).
- ◆ Depth of stromal invasion.
- ◆ Lymph node involvement (inguino-femoral and pelvic).

- ◆ Tumor diameter and differentiation.
- ◆ DNA ploidy status (as discussed in p. 380).

**Prognosis:** Approximate 5-year survival rate in squamous cell carcinoma is tabulated in Tables 23.5A and 23.5B.

TABLE 23.5A		TABLE 23.5B	
Stage	Survival (%)	Survival by node status (5 years)	
I	90–100	Negative nodes	80–100%
II	65–75	Positive inguinal } femoral nodes	30–50%
III	35–45	Positive pelvic nodes	
IV	20–30		

**Melanoma** is the second most common vulval cancer. The common sites are the clitoris and labia minora. It may arise from a junctional nevus. Radical vulvectomy and bilateral regional lymphadenectomy (en-block) is the preferred treatment. Pelvic lymphadenectomy does not alter the prognosis. Radiation therapy, adjuvant chemotherapy, or immunotherapy are ineffective. Overall prognosis is poor.

## BARTHOLIN'S GLAND CARCINOMA

The surgery is like that of squamous cell carcinoma of the vulva. In addition, part of the lower vagina, levator ani and the ischio-rectal fat are to be removed. Prognosis in a case of Bartholin gland carcinoma is similar to squamous cell carcinoma when compared stage for stage of the disease.

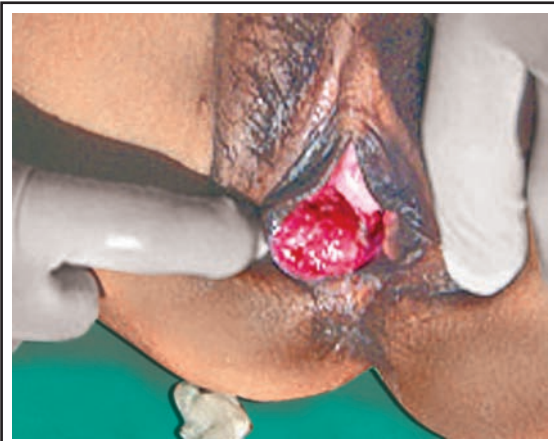## VAGINAL CARCINOMA

- ◆ Primary ◆ Secondary

### PRIMARY

**INCIDENCE:** The incidence of primary vaginal carcinoma is very rare (about 0.6 per 100,000 women). It constitutes about 1 percent of genital malignancies. **The primary vaginal carcinoma should fulfil the following criteria.**

- ◆ The primary site of growth is in the vagina.
- ◆ The cervix and the vulva must not be involved.
- ◆ There must not be clinical evidence of metastatic disease.



**Fig. 23.4:** Vaginal carcinoma

**ETIOLOGY:** Exact etiology is unknown. Following factors are often related:

- ◆ HPV may have a causal relationship.
- ◆ Progression from vaginal intraepithelial neoplasia (VAIN).
- ◆ Women with history of cervical cancer (multi-centric neoplasia).
- ◆ Diethyl stilboesterol (DES) is related with clear cell adenocarcinoma of the vagina. This is found in those who had history of intrauterine exposure to diethyl stilboesterol.
- ◆ Previous irradiation therapy to the vagina or immunosuppression.
- ◆ Prolonged use of pessary.
- ◆ More common amongst whites than blacks.

### **PATHOLOGY**

**Site:** The commonest site is in the upper-third of the posterior wall.

**Naked eye:** The growth may be ulcerative or fungative.

**Histopathology:** Squamous cell carcinoma accounts for more than 90 percent of the cases. The rest are adenocarcinoma, melanoma, fibrosarcoma, sarcoma botryoides (p. 369) and malignant mixed mullerian tumors.

Spread is by direct continuity, by lymphatics (see p. 29 anatomy) and rarely, blood borne. Inguinofemoral lymph nodes and pelvic lymph nodes are commonly

involved. Hematogenous spread involves the lungs, liver or the bones.

**CLINICAL FEATURES:** The mean age of the patient is about 55 years.

### ■ **Symptoms**

- ◆ May be asymptomatic, being accidentally discovered during routine screening procedures.
- ◆ Abnormal vaginal bleeding including post-coital bleeding is conspicuously present as an early symptom.
- ◆ Foul smelling discharge per vaginum.

### ■ **Signs**

- ◆ Speculum examination reveals an ulcerative, nodular or exophytic growth.
- ◆ The cervix looks apparently normal.

### ■ **Diagnosis**

- ◆ During cytology, screening procedure to detect abnormal cells.
- ◆ Colposcopic examination and targeted biopsy are helpful for patients with abnormal cytology or unexplained vaginal bleeding.
- ◆ Cystourethroscopy, proctosigmoidoscopy, CT/MRI (for nodes), are done.
- ◆ Biopsy from clinically suspected lesion.

### **STAGING**

The clinical staging as outlined by FIGO is tabulated below:

<b>STAGING OF VAGINAL CARCINOMA FIGO (1995)</b>	
<b>Stage-0</b>	Carcinoma <i>in situ</i>
<b>Stage-I</b>	Carcinoma is limited to the vaginal wall.
<b>Stage-II</b>	Carcinoma has involved subvaginal tissue but has not extended to the pelvic wall
<b>Stage-III</b>	Carcinoma has extended to the pelvic wall
<b>Stage-IV</b>	Carcinoma has extended beyond the true pelvis or has involved the mucosa of the bladder or rectum. <ol style="list-style-type: none"> <li>a. Adjacent organs are involved (bladder, rectum)</li> <li>b. Distant organs are involved</li> </ol>

## ■ TREATMENT

Radiotherapy or surgery or the combination is the accepted modality of therapy for invasive primary carcinoma of the vagina. Choice depends on the clinical stage, anatomical location and size of the lesion.

### ▲ STAGE I

#### ◆ Growth limited to the upper-third

Radical hysterectomy, partial vaginectomy and bilateral pelvic lymphadenectomy is the treatment of choice (as that of stage IB carcinoma cervix).

#### ◆ Growth limited to the lower-third

Radical vulvectomy with removal of bilateral inguinofemoral lymph nodes along with vaginectomy.

### ▲ STAGE II-IV

Radiation by external beam therapy with intracavity or interstitial radiation. Care is to be taken to prevent bladder or rectal injury.

**Pelvic exenteration operation** (see p. 351) is done when there is failure with radiation therapy.

### Radiotherapy

Radiation therapy is widely used as a primary treatment for invasive vaginal cancer. External radiation with 4500 to 5000 cGy is administered on the pelvis encompassing the vagina. Additional 3000 to 4000 cGy is delivered locally in the form of interstitial therapy (brachytherapy) with iridium or cobalt.

Teletherapy (external radiation) reduces the tumor volume and sterilizes the regional (pelvic and inguinofemoral) lymph nodes. Complications of radiotherapy (see p. 508) include vaginal stenosis, bladder and rectal fistula.

**CURE RATE:** Overall 5-year survival rate ranges from 80 percent for stage I disease to 10 percent for stage IV disease.

## CLEAR CELL ADENOCARCINOMA

Primary vaginal adenocarcinoma is rare. This is found in adolescent girls who have had history of intrauterine exposure to diethyl stilbestrol in the first trimester of pregnancy.

The approximate risk of an offspring to develop the clear cell adenocarcinoma of the vagina following DES exposure is 1 in 1000 or less. These patients are more likely to develop vaginal adenosis (see p. 521) but, rarely clear cell adenocarcinoma.

The lesion usually involves the upper-third of the anterior vaginal wall. The cervix may also be involved.

**TREATMENT:** Radical hysterectomy, vaginectomy with pelvic lymphadenectomy is the treatment of choice.

Radiotherapy is reserved for advanced cases.

## SECONDARY

Secondary vaginal malignancy follows carcinoma vulva, cervix or urethra by direct spread. Metastases in the lower-third of the anterior vaginal wall or vault occur in cases of choriocarcinoma (Fig. 23.16) or endometrial carcinoma.

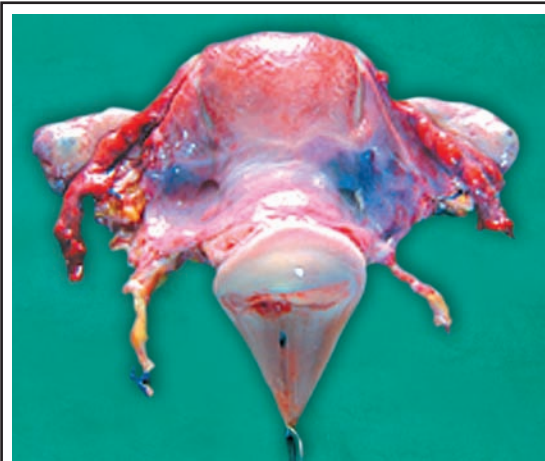## CARCINOMA CERVIX

### MAGNITUDE OF THE PROBLEM

- Incidence of cervical cancer is steadily declining in the developed world.
- Pap smear has reduced the incidence of cervical cancer by nearly 80 percent and death by 70 percent.
- Cervical cancer is an entirely preventable disease as the different screening, diagnostic and therapeutic procedures are effective.
- At present throughout the globe, there are nearly 1 million women each year having cervical cancer.
- Cancer cervix is the most common cancer in women of the developing countries where screening facilities are inadequate.

**INCIDENCE:** In most of the developing countries, carcinoma of the breast and cervix are the leading sites of malignancies in female and are major public health problems.

In India, twelve population-based cancer registries (PBCRs) showed cancer breast was the most common followed by cancer of the cervix (ICMR-2004). Amongst female cancers, relative proportion of cancer breast varied between 21 and 24 percent whereas that of cancer cervix was between 14 and 24 percent. In India, an overall incidence of 23.5/100,000 has been observed (WHO 2008).



**Fig. 23.5:** Ulcerative type of cervical malignancy with a friable growth on the posterior lip. Radical hysterectomy done. Uterine arteries are ligated at origin (p. 351)

Major factors affecting the prevalence of carcinoma cervix in a population are economic factor, sexual behavior and degree of effective mass screening.

**EPIDEMIOLOGY:** This has been discussed in CIN (p. 323). In India, the prevalence is more amongst the comparatively younger age group. Carcinoma cervix is rare in women who are sexually not active (nuns, virginal women). Male circumcision is only partially protective against cervical carcinogenesis.

**GROSS PATHOLOGY:** The site of the lesion is predominantly in the ectocervix (80%) and the rest (20%) are in the endocervix.

#### Naked Eye

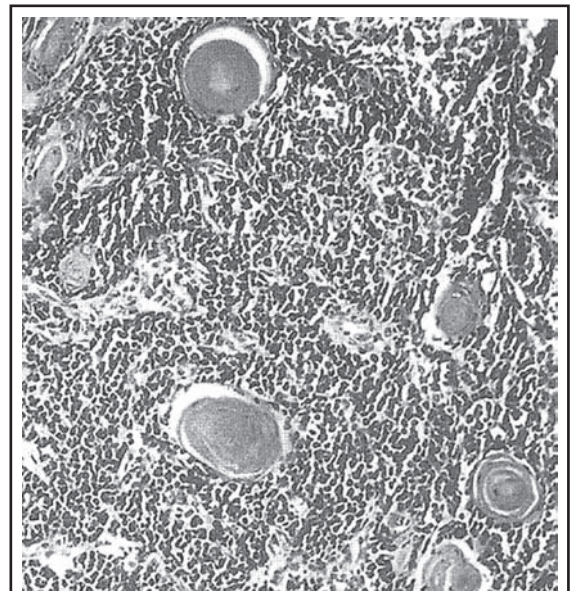
- ◆ **Exophytic:** These arise from the ectocervix and form friable masses almost filling up the upper vagina in late cases (Fig. 23.8).
- ◆ **Ulcerative:** The lesion excavates the cervix and often involves the vaginal fornices (Fig. 23.5).
- ◆ **Infiltrative:** These are found in endocervical growth. They cause expansion of the cervix, so that it becomes barrel-shaped.

#### HISTOPATHOLOGY (FIG. 23.6)

The commonest variety is squamous cell carcinoma (85-90%) either well-differentiated or moderately or

poorly differentiated. These arise from the ectocervix. **The sources of the squamous epithelium which turn into malignancy are**—squamocolumnar junction, squamous metaplasia of the columnar epithelium.

- ◆ Squamous cell carcinoma is further subdivided histologically into three groups: (i) large cell keratinizing, (ii) large cell non-keratinising and (iii) small cell type. Patients with small cell type have got poor prognosis compared to the large cell types.
- ◆ Adenocarcinoma (10–15%) develops from the endocervical canal, either from the lining epithelium or from the glands.
- ◆ Currently increased number of cervical adenocarcinomas are observed specially in the younger age group. The majority (80%) of them are purely **endocervical type**. The remainders are endometrioid, clear cell, adenosquamous or a mixed type. *Adenoma-malignum* is an extremely well-differentiated adenocarcinoma with favorable prognosis.
- ◆ Neuroendocrine tumors, sarcomas and lymphomas are rare tumors of the cervix.



**Fig. 23.6:** Histology of squamous cell carcinoma of the cervix (small cell type). Keratin pearls are seen

**MODE OF SPREAD**

**Direct extension:** The growth spreads directly to the adjacent structures, to the vagina and to the body of the uterus. It extends laterally to the parametrium, paracervical and paravaginal tissues. Here, the tumor cells surround and compress the ureter. It may spread backwards along the uterosacral ligament, to involve the rectum or forwards to involve the base of the bladder, specially in endocervical growth.

**Lymphatic: The primary group involved are** — parametrial nodes, internal iliac nodes, obturator, external iliac nodes and sacral nodes. **The secondary nodes involved are** — common iliac group, the inguinal nodes and paraaortic nodes (Table 23.6).

**Sentinel lymph node (SLN)** is the first node that drains a primary tumor. In most cases (85%) there is a single sentinel lymph node (see p. 608). This node can be detected by intraoperative lymphatic mapping injecting methylene blue dye into the tumor or lymphoscintigraphy using technetium 99.

**Hematogenous:** Blood borne metastasis is late and usually by veins rather than the arteries. Lungs, liver or bone are usually involved.

**Direct implantation:** Direct implantation of the cancer cells at operation on the vault of the vagina or abdominal or perineal wound is very rare.

The risk of ovarian metastases in stage I squamous cell carcinoma of the cervix is 0.5 percent and it is 1.7 percent for adenocarcinoma.

**The fallacies are** — difficult to assess the lymph node involvement on clinical examination which adversely affects the prognosis. There is also difficulty in differentiation of inflammatory and malignant induration of the parametrium.

**TABLE 23.7****STAGING PROCEDURES ALLOWED BY FIGO**

PROCEDURE USED	TO DETECT
<ul style="list-style-type: none"> <li>◆ Inspection of cervix and vagina</li> <li>◆ Pelvic examination (vaginal, rectovaginal) under anesthesia</li> </ul>	
<ul style="list-style-type: none"> <li>◆ Lymph node palpation</li> <li>◆ Colposcopy (p. 324)</li> <li>◆ Hysteroscopy (p. 619)</li> <li>◆ Cystoscopy (p. 122)</li> <li>◆ Biopsy (p. 589)</li> <li>◆ Endocervical curettage (p. 357)</li> <li>◆ Conization (p. 589)</li> </ul>	Enlargement and site  Extension and depth of tumor spread
<ul style="list-style-type: none"> <li>◆ Chest X-ray</li> <li>◆ Skeletal X-ray</li> <li>◆ Intravenous urogram/USG</li> <li>◆ Barium enema</li> <li>◆ Proctoscopy</li> </ul>	Pulmonary metastasis Bone metastasis Hydronephrosis Large bowel involvement Rectal involvement

*Ultrasonography, lymphangiography, CT and MRI, PET, radionucleotide scanning studies, laparoscopy/laparotomy are optional and not to be used for FIGO staging.*

**TABLE 23.6****INVOLVEMENT OF LYMPH NODES IN DIFFERENT STAGES (APPROXIMATE)**

Stage	Pelvic nodes (%)	Paraaortic nodes (%)
0	0	0
Ia <sub>1</sub> (<3 mm)	0–0.5	0
Ia <sub>2</sub> (3–5 mm)	5	< 1
Ib	16	2
II	30	15
III	44	30
IV	55	40

**Staging: The purposes of staging are** to determine the prognosis, to formulate the line of treatment and to compare the results of one to the other.

**Staging of cervical cancer is based principally on clinical examination.** Pelvic examination (speculum, bimanual and rectal examination) should be done under anesthesia. The routine supplementary investigations include X-ray chest, intravenous pyelography, cystoscopy and proctoscopy. In cases of suspected pelvic inflammation, a course of antibiotic should be given prior to clinical staging.

**Final staging cannot be changed once therapy has begun.** If any doubt exists as to which stage should be assigned, the lower stage should be chosen.

**CT scan, MRI, Positron Emission Tomography (PET), Lymphangiography (p. 117)** can detect involvement of the pelvic or periaortic lymph nodes and parametrium. MRI is helpful to detect parametrial extension and to define the tumor volume. But these findings do not change FIGO stage of disease.

The clinical staging as recommended by FIGO is tabulated below:

FIGO STAGING OF CARCINOMA OF THE CERVIX (2009)	
STAGE	INVASIVE CARCINOMA
<b>Stage-I</b>	The carcinoma is strictly confined to the cervix (extension to the corpus would be disregarded).
<b>Stage-IA</b>	Invasive carcinoma which can be diagnosed only by microscopy with deepest invasion $\leq 5.0$ mm and largest extension $\leq 7.0$ mm.
<b>Stage-IA<sub>1</sub></b>	Measured stromal invasion of $\leq 3.0$ mm in depth and horizontal extension of $\leq 7.0$ mm
<b>Stage-IA<sub>2</sub></b>	Measured stromal invasion of $> 3.0$ mm and not $> 5.0$ mm with an extension of not $> 7.0$ mm.
<b>Stage-IB</b>	Clinically visible lesions limited to the cervix uteri or pre-clinical cancers greater than stage 1A*.
<b>Stage-IB<sub>1</sub></b>	Clinically visible lesion $\leq 4.0$ cm in greatest dimension.
<b>Stage-IB<sub>2</sub></b>	Clinically visible lesion $> 4.0$ cm in greatest dimension.
<b>Stage-II</b>	Cervical carcinoma invades beyond the uterus, but not to the pelvic wall or to the lower third of the vagina.
<b>Stage-IIA</b>	Without parametrial invasion.
<b>Stage-IIA<sub>1</sub></b>	Clinically visible lesion $\leq 4.0$ cm in greatest dimension.
<b>Stage-IIA<sub>2</sub></b>	Clinically visible lesion $> 4.0$ cm in greatest dimension.
<b>Stage-IIB</b>	With obvious parametrial invasion.
<b>Stage-III</b>	The tumor extends to the pelvic wall and/or involves lower third of the vagina and/or causes hydronephrosis or non-functioning kidney**
<b>Stage-IIIA</b>	Tumor involves lower third of the vagina, with no extension to the pelvic wall.
<b>Stage-IIIB</b>	Extension to the pelvic wall and/or hydronephrosis or non-functioning kidney.

Contd...

Contd...

<b>Stage-IV</b>	The carcinoma has extended beyond the true pelvis or has involved (biopsy proven) the mucosa of the bladder or rectum. A bullous edema, as such, does not permit a case to be allotted to Stage IV.
<b>Stage-IVA</b>	Spread of the growth to adjacent organs.
<b>Stage-IVB</b>	Spread to distant organs.

\* All macroscopically visible lesions even with superficial invasion are allotted to stage IB carcinomas. Invasion is limited to a measured stromal invasion with a maximal depth of 5.0 mm and a horizontal extension of not  $> 7.0$  mm. Depth of invasion should not be  $> 5.0$  mm taken from the base of the epithelium of the original tissue—superficial or glandular. The depth of invasion should always be reported in mm, even in those cases with "early (minimal) stromal invasion" ( $\sim 1.0$  mm). The involvement of vascular, lymphatic spaces should not change the stage allotment.

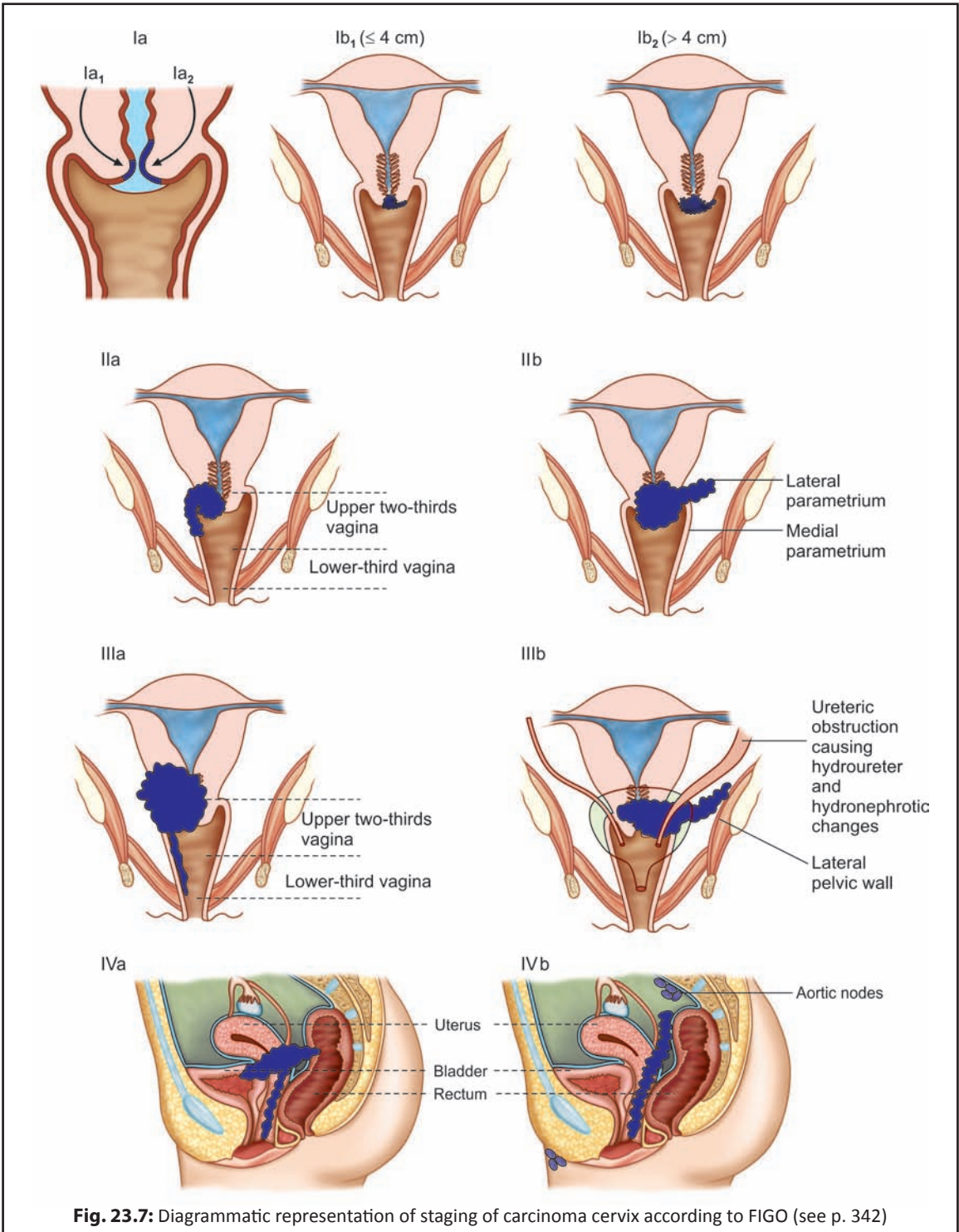
\*\* On rectal examination, there is no cancer-free space between the tumor and the pelvic wall. All cases with hydronephrosis or non-functioning kidney are included, unless they are known to be due to another cause.

## PROGNOSIS

### The prognosis depends on the following:

- Stage of the lesion at the initial therapy is the most important factor in the outcome of the treatment.
- Endocervical tumor is diagnosed late and grows faster.
- Depth of tumor invasion when  $< 1$  cm, less lymph nodes are involved and improved survival is observed.
- Tumor size more than 4 cm is associated with more lymph node metastasis and poor survival.
- Well-differentiated squamous cell carcinoma grows slowly and metastasizes late than the anaplastic type.
- Young age is usually associated with poorly differentiated squamous cell carcinoma or adenocarcinoma and is prognostically poor.
- Lymph node involvement (pelvic and paraaortic) reduces the survival rate by 50 percent.
- HPV positive younger patients have better prognosis.





**Fig. 23.7:** Diagrammatic representation of staging of carcinoma cervix according to FIGO (see p. 342)

### Surgical staging of cancer cervix:

There are often discrepancies between clinical staging and surgicopathological findings. Surgical staging can minimize this by identifying the occult tumor spread and also the extra pelvic disease. Assessment of the pelvic and paraaortic nodes are done by surgical approach. This is done either by extraperitoneal approach or by laparoscopy.

### DIAGNOSIS

- ◆ Early carcinoma
- ◆ Advanced carcinoma/Late carcinoma.

#### Early carcinoma (Table 23.8)

**Nomenclature:** The concept of early carcinoma of the cervix is not well-defined. Presumably, it should include those lesions which have got minimal morbidity and deaths with the best available therapy and a maximal 5-year survival rate. With these criteria, the following stages as per FIGO classification are included in the category of early carcinoma.

**TABLE 23.8 EARLY CARCINOMA**

Stage	5-year survival rate (%)
la <sub>1</sub>	98.7
la <sub>2</sub>	95.9
lb <sub>1</sub>	90.4
lb <sub>2</sub>	79.8

Thus all these have got 5-year survival rates ranging between 80-100 percent. Stage II reduces the 5-year survival rate to as low as 55-70 percent. As such, **it is inappropriate to include any lesion extending beyond the cervix as early carcinoma.**

As the presentation of the case differs, these are grouped as:

#### ◆ Preclinical ◆ Clinical

#### Preclinical

There may not be any symptom nor any pelvic finding to raise any suspicion. The cervix may look apparently healthy. The diagnosis is made by the following:

- ◆ Incidental on histological examination of tissues removed by biopsy, portio amputation or removal of the uterus.
- ◆ During screening procedures.

Cytologically suspicious smear is subjected to colposcopy followed by directed biopsy. In the absence of colposcopy, **Schiller's test** directed biopsy is to be taken. If a positive lesion is found, diagnostic conization has to be done and subjected to serial sections. Depending upon the degree of neoplastic changes and/or its invasion to the adjacent stroma, the lesions are diagnosed as follows:

#### ◆ Stage 0 ◆ Stage Ia ◆ Stage Ib

#### Stage 0

The neoplastic changes involve whole thickness of the epithelium **but the basement membrane remains intact.**

#### Stage Ia (Microinvasive carcinoma)

Microinvasive carcinoma is one which is predominantly intraepithelial carcinoma, except that **there is disruption of the basement membrane.** The neoplastic epithelium invades the stroma in one or more places but limited up to 5 mm from the overlying basement membrane. As such, the depth of invasion is measured by using a microscope with an ocular micrometer.

The malignant cells maintain their connection with the overlying intraepithelial neoplasm. The cords of malignant cells may become confluent or invade the lymphovascular channels, irrespective of depth of penetration.

The mean age is 38-42 years.

**In majority, the entity is asymptomatic.** There may be blood stained discharge, intermenstrual, postcoital or postmenopausal bleeding. The cervix may look abnormal like erosion, eversion or cervicitis.

**The diagnosis is made only on cone biopsy of the cervix.** Initial screening may be done with cytology, colposcopy and directed biopsy along with endocervical curettage.

The patient with microinvasive carcinoma may be treated even with conservative surgery when there is no risk of lymph node metastasis.

**Stage Ib:** The invasion of the malignant cells to the underlying stroma exceeds 5 mm. There is no clinical manifestation and the cervix may look apparently normal.

- **Clinical: Stage Ib (overt)**

**Symptoms:** The duration of symptoms is not proportionate to the stage of the disease.

- Menstrual abnormalities in the form of contact bleeding or bleeding on straining (during defecation), intermenstrual bleeding are very much suspicious, specially over the age of 35.
- Excessive white discharge which may be at times offensive.

## SIGNS

### Speculum Examination Reveals

- Either a red granular area which looks like an ectopy (erosion) extending from the external os or a **nodular growth** or an **ulcer**. The lesion bleeds on friction. **It should be done prior to bimanual examination**. The cervical lesion may not be visible due to bleeding from the friable lesion caused by digital examination.

**Bimanual examination reveals** the lesion is indurated, friable and bleeds to touch. Cervix is freely mobile.

**Rectal examination reveals** the parametrium absolutely free.

### Confirmation of diagnosis is by biopsy

Ancillary aids for confirmation of staging:

- ◆ Cystoscopy
- ◆ X-ray chest
- ◆ Intravenous pyelography
- ◆ Proctoscopy.

All these give a negative finding and, as such, the clinical staging of Ib is thereby confirmed.

### Advanced Carcinoma/Late Carcinoma

All cases of carcinoma with stage II and onwards are arbitrarily called advanced carcinoma considering the reduced 5-year survival rate compared to earlier stages. In fact, in India, this group comprises about 80 percent of the total cervical carcinoma patients attending the hospitals for treatment.

## PATIENT PROFILE

The patients are usually multiparous, in pre-menopausal age group. They have previous history of postcoital or intermenstrual bleeding which they ignored.

**Symptoms:** As previously mentioned, the duration of symptoms is not proportionate to the stage of the disease. However, the following symptoms may be evident depending upon the extent of the lesion.

- **Irregular or continued vaginal bleeding** which may at times be brisk.
- **Offensive vaginal discharge**.
- **Pelvic pain** of varying degree: This may be either due to involvement of uterosacral ligament leading to backache or deep seated pain due to involvement of sacral plexus.
- **Leg edema** is due to progressive obstruction of lymphatics and/or iliofemoral veins by the tumor.
- **Bladder symptoms** include frequency of micturition, dysuria, hematuria or even true incontinence due to fistula formation.
- **Rectal involvement** is evidenced by diarrhea, rectal pain, bleeding per rectum or even rectovaginal fistula (see Fig. 23.7).
- **Ureteral obstruction** is due to progressive growth of tumor laterally. There may be frequent attacks of pyelonephritis due to ureteric obstruction.

Ultimately, the patient may be **cachectic, anemic with edema legs**. **Ultimately uremia develops**.

**Speculum examination** reveals the nature of the growth, ulcerative or fungating which bleeds to touch.

**Bimanual examination** reveals the induration and extent of the growth to the vagina and to the sides. The induration of the bladder base may be felt through the anterior fornix in advanced cases.

**Rectal examination** is invaluable to note the involvement of the parametrium and its extent in relation to the lateral pelvic wall. Nature of induration is to be noted carefully. **If it is smooth**, the possibility of inflammation has to be excluded and antibiotics has to be given prior to final assessment for staging. **In malignancy, the induration is nodular**. Incidental involvement of the rectum has to be noted.

**For confirmation of diagnosis**, *biopsy* is mandatory (see p. 589). If the lesion is small, wedge biopsy is taken which should include a portion of the healthy tissue as well. If it is big, a bit may be taken from a comparative noninfective area. There may be brisk hemorrhage which can be effectively controlled by plugging.

## DIFFERENTIAL DIAGNOSIS

The growth needs to be differentiated from:

- ◆ Cervical tuberculosis (p. 143).
- ◆ Syphilitic ulcer (p. 149).
- ◆ Cervical ectopy (p. 267).
- ◆ Products of conception in incomplete abortion.
- ◆ Fibroid polyp (p. 285).

## COMPLICATIONS

The following complications may occur sooner or later, as the lesion progresses.

- ◆ Hemorrhage.
- ◆ Frequent attacks of ureteric pain, due to pyelitis and pyelonephritis and hydronephrosis.
- ◆ Pyometra — specially with endocervical variety.
- ◆ Vesicovaginal fistula.
- ◆ Rectovaginal fistula—This is comparatively rare because of the interposition of the pouch of Douglas. The rectum may be involved either through the uterosacral ligament or through rectovaginal septum.

## Causes of Death

The patient may die of:

**Uremia:** This is due to ureteric obstruction following parametrial involvement. There is hydronephrosis and pyelonephrosis. Infection supervenes, thereby further compromising kidney functions.

**Hemorrhage:** The vaginal bleeding from the growth may be brisk or continuous. This leads to anemia and ill health.

**Sepsis:** Localized pelvic or generalized peritonitis may occur which may be fatal.

**Cachexia:** The cumulative effect of the factors mentioned leads to cachectic condition. The cancerous tissues have got depressant action on general metabolism.

**Metastases** to the distant organs commonly observed are—lung (36%), lymph nodes (30%), bone (16%) and abdominal cavity (7%). These may be fatal.

## MANAGEMENT OF CARCINOMA CERVIX

### ◆ Preventive ◆ Curative

### PREVENTIVE

#### Primary Prevention

It involves identifying the causal factors and eliminating or preventing those from exerting their effects. These are easy to enumerate, but difficult to implement in practice.

#### ◆ Identifying ‘high-risk’ female

- Women with high risk HPV infection (p.323).
- Early sexual intercourse.
- Early age of first pregnancy.
- Too many births/too frequent birth.
- Low socioeconomic status.
- Poor maintenance of local hygiene.

#### ◆ Identifying ‘high-risk’ males

- Multiple sexual partners.
- Previous wife died of cervical carcinoma.

It is indeed an uphill task to prevent these epidemiological factors. However, cancer consciousness, proper health education of the population, specially amongst the poor socioeconomic group could be important steps in prevention.

- **Prophylactic HPV vaccine** (see p. 326) is approved to all school girls (12–18 years) and women (16–25 years). Three doses are to be given (Bivalent 0–2–6 month, Quadrivalent 0–1–6 month).
- **Use of condom** during early intercourse, raising the age of marriage and of first birth, limitation of family, maintenance of local hygiene and effective therapy of STIs are the positive steps in prevention.
- **Removal of cervix during hysterectomy** as a routine for benign lesion is a definite step in prevention of stump carcinoma. The incidence may be as high as 1 percent.

**Secondary prevention:** It involves identifying and treating the disease earlier in the more treatable stage.

**This is done by screening procedures.** The details have been described in chapters 8 and 21. The abnormal cervical pathology likely to progress to invasive carcinoma can be detected. Its effective therapy reduces dramatically the incidence of invasive carcinoma in areas where it has been implemented. Even when the invasive carcinoma is detected, it is so early that a 85–100 percent 5-year survival rate could be achieved.

### Downstaging Screening (WHO 1986)

Downstaging for cervical cancer is **defined as** “the detection of the disease at an earlier stage when it is still curable. Detection is done by nurses and other paramedical health workers using a simple speculum for visual inspection of the cervix”.

The “downstaging screening” is an experimental approach suggested by WHO as an alternative to regular cytological screening. In the developing countries, where effective mass screening cannot be extended and the majority of cases of carcinoma cervix are diagnosed at an advanced stage, ‘down staging screening’ offers at least an **early detection of disease. Compared to cytological screening it is suboptimal.** But in places where prevalence of cancer is high and cytological screening is not available, “downstaging screening” is useful. **The strategy is, however, not expected to lower the incidence of cancer cervix, but it can certainly minimize the cancer death through early detection.**

**Downstaging procedure:** A female primary health care worker is trained for 2–3 weeks to perform speculum examination. They are trained to distinguish a normal cervix from an abnormal one.

**Characters of a normal cervix:** Pink in color, round in shape, smooth surface and does not bleed on touch. Whereas an **abnormal cervix has the following characters:** Reddish, red or white area of patch, growth or ulcer on the surface and bleeds on touch.

Once the abnormality is suspected, the case is referred to a center where diagnosis and treatment of premalignant and malignant lesions are done.

**Curative:** Ideally, the management of the patient with cervical cancer is a team approach. Both the gynecologist and radiooncologist should review the patient along with the biopsy report and the plan outlay

be individualized. Due consideration should be given to:

- ◆ General condition of the patient.
- ◆ Stage of the disease.
- ◆ Facilities available—surgical and radiotherapy.
- ◆ Wish of the patient to be judiciously complied with.

### Pretreatment Evaluation

Irrespective of the treatment modalities (surgery or radiotherapy) the following evaluations are to be made apart from those already done (Table 23.7) for staging purposes.

### Serum Marker (see p. 521)

**SCC (Squamous Cell Carcinoma) antigen is the serum marker.** Although the antigen is not specific, it has been useful as a means to monitor treatment response and to predict tumor recurrence.

### Pretreatment Preparations

Irrespective of the methods of treatment, general health of the patient must be improved. Due attention is to be paid to correct anemia and malnutrition. This not only makes the patient sufficiently fit to withstand surgery but rise in hemoglobin percentage improves the tissue oxygenation needed for effective ionizing effect of irradiation.

## TREATMENT MODALITIES OF CARCINOMA CERVIX

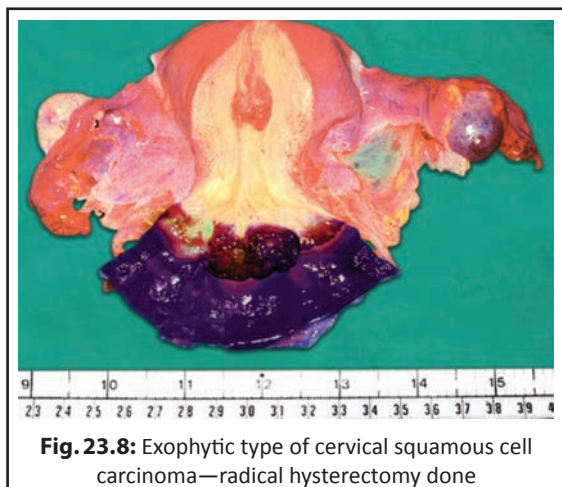
The types of treatment employed for the invasive carcinoma are as follows:

- Primary surgery
- Primary radiotherapy
- Chemotherapy
- Combination therapy

**Surgery:** The types of surgery employed in invasive carcinoma are:

### Radical Hysterectomy (Fig. 23.8)

**John Clark** (1898) first did the operation while working as a resident in Johns Hopkins Hospital. This operation is commonly done abdominally and is known by different names (**Wertheim** of Viena–1898, **Okabayashi** of Japan–1921, **Meigs** of USA–1944). **Extensive vaginal**



**Fig. 23.8:** Exophytic type of cervical squamous cell carcinoma—radical hysterectomy done

**operation** was subsequently developed to minimize the mortality and morbidity from abdominal approach. Pelvic lymph nodes are removed by bilateral extraperitoneal approach. This operation is also popularly known by different names (**Schauta** of Viena–1902, **Mitra** of India–1957). There have been several modifications of the techniques of radical hysterectomy and bilateral pelvic lymphadenectomy at present.

**The surgery includes** (Fig. 34.13) removal of the uterus, tubes and ovaries of both the sides (ovaries may be spared in young women), upper half of vagina, parametrium (most of cardinal and uterosacral ligaments) and the draining primary cervical lymph nodes (parametrial, obturator, internal and external iliac groups and sometimes common iliac. **Sacral group is not removed**). Paraortic lymph node evaluation is done. Any enlarged paraortic lymph node is sampled and sent for frozen section biopsy. Radiation therapy is to be considered if lymph nodes are found involved. Generally, **negative sentinel lymph nodes may allow omission of lymphadenectomy of the nodal basin.**

**Limitation:** It is ideally limited to early stage disease (Table 23.10).

#### Advantages of Surgery over Radiotherapy

- ◆ Spread of the disease can be determined more thoroughly by surgicopathological staging.
- ◆ Surgical staging (Laparotomy or Laparoscopy) and assessment of paraortic and pelvic nodes, can predict the survival rate accurately.
- ◆ Preservation of ovarian function, if desired, specially in a young woman.
- ◆ Ovaries may be transposed out of the radiation field if radiation is considered in the postoperative period.
- ◆ Retention of more functional and pliable vagina for sexual function.
- ◆ Psychologic benefit to the patient in that her cancer bearing organ has been removed.

**Special indications:** As previously mentioned, there is no superiority of surgery over radiotherapy when the patients are placed in ideal circumstances. But, there are conditions where **radiotherapy is contraindicated** and only the surgical treatment has to be provided.

### CONTRAINDICATION OF RADIOTHERAPY

- ◆ Associated PID—acute or chronic, pelvic kidney.
- ◆ Associated myoma, prolapse (proctidentia), ovarian tumor or genital fistula.
- ◆ Young patient (to preserve ovarian function).
- ◆ Vaginal stenosis — placement of radiation source is inadequate.
- ◆ Cases with adenocarcinoma or adenosquamous carcinoma — surgery is preferred.

**TABLE 23.9** BRACHYTHERAPY TECHNIQUES

	<b>Amount of radium placement</b>	<b>No. of application</b>	<b>Duration</b>
<b>Paris technique</b>	Intrauterine tandem 33.3 mg — one Vaginal ovoid 13.3 mg — two or three	One	120 hours
<b>Manchester technique</b>	Intrauterine tandem 30–50 mg Vaginal colpostat 30–50 mg	Two	72 hours each at interval of 7 days
<b>Stockholm technique</b>	Intrauterine tandem 50 mg — one Vaginal plaque — 65–80 mg	Three	24 hours each at weekly interval

## DISADVANTAGES OF SURGERY

See complications (below). Women with comorbidities (obesity, heart disease) are at risk for surgery.

### Postoperative Complications

**Major postoperative complications** as observed following total abdominal hysterectomy have been discussed (see p. 596). **Other complications include:** ureteric fistula (about 1%), vesicovaginal fistula (0.5%), bladder dysfunction, cystitis pyelonephritis and rectal dysfunction. There may be lymphocyst in the pelvis, lymphoedema of one or both the legs, dyspareunia and recurrence. The mortality rate of the procedure is less than 1 percent.

**Bladder dysfunction** (atony) is a known complication. This is due to damage of the sympathetic and parasympathetic fibers to and from the bladder and urethra. Continuous catheterization for bladder drainage is maintained for a period of 6–10 days.

**Neuropathies** due to nerve injuries (Femoral, Obturator, Sciatic, Genitofemoral, Ilioinguinal, Lateral femoral cutaneous and Pudendal nerves.

**Lymphocyst formation** is a frequent complication. Tissue fluid, lymph and blood are collected to form the cyst following radical hysterectomy. Lymphocyst is best diagnosed by ultrasound. Rarely, it may be of large size to cause pain and ureteral or venous obstruction. Adequate suction drainage of the retroperitoneal space postoperatively is an important preventive measure. Majority resolve spontaneously. Sometimes, it may drain through vagina. Rarely, needle aspiration is needed when the size is large or it produces symptoms.

#### ◆ Pelvic exenteration

This type of ultraradical surgery is named after **Brunschwig**. This procedure is done in a very selective cases only:

- Stage IVA disease.
- Central pelvic recurrent carcinoma (biopsy proven) without any metastasis.
- Completely resectable tumor mass.
- Absence of ureteral obstruction, sciatic pain or unilateral leg edema.
- Woman should be psychologically and physically adjusted to cope with urinary and fecal stomas.

**Contraindications of pelvic exenteration** are extra-pelvic spread of disease with distant metastasis to liver, lungs or bones.

### Types

- ◆ **Anterior exenteration:** It consists of radical hysterectomy, removal of urinary bladder and implantation of ureters either in the sigmoid colon or into an artificial bladder made from an ileal loop (ileal bladder).
- ◆ **Posterior exenteration:** It consists of radical hysterectomy, removal of rectum and a permanent colostomy.
- ◆ **Complete or total:** It consists of combination of anterior and posterior exenteration with a permanent colostomy and an ileal bladder. The operative mortality of such type of operation is about 10–20 percent and with a 5-year survival rate of about 10 percent only.
- ◆ **Laparoscopic radical hysterectomy (LRH) with pelvic and aortic lymphadenectomy** is done for early invasive disease (stage I, IIA). Ovarian vessels, round ligaments and uterine vessels are divided abdominally and are stapled. A vaginal probe (colpotomizer) helps easier dissection. The uterosacral ligaments parametria are resected and stapled. The specimen is removed vaginally. Vaginal cuff is closed by endostitch. Pelvic and aortic lymphadenectomy is done.

### Primary Radiotherapy

Cancer of the cervix was the first cancer of an internal organ to be treated with ionizing radiation using radium by Margaret Cleves in 1903. **Primary therapy (chemoradiation)** is given in locally advanced (stage IIB to IVA) disease (see below).

External photon beam radiation and brachytherapy are the two main methods (see p. 506, 507).

## ADVANTAGES OF PRIMARY RADIOTHERAPY

- Wider applicability in all stages of carcinoma cervix.
- Survival rate 85%, comparable with that of surgery in early stages.
- Less primary mortality and morbidity.
- Individualization of dose distributions/requirement possible.

## EARLY STAGES

**Brachytherapy technique** is employed (ch. 30). Small radioactive sources, mainly radium sulphate is mixed with some inert powder and packed in small needles or tubes. These are used for interstitial, intracavitary or surface applications. Radiation sources for intracavitary radiation are Radium ( $^{226}\text{Ra}$ ), Cesium ( $^{137}\text{Cs}$ ) or Cobalt ( $^{60}\text{Co}$ ). The container is made up of platinum, gold or alloy steel to absorb alpha and beta particles and allowing the gamma rays to sterilize the cancer cells. In carcinoma cervix, the tandems are inserted in the uterine cavity and the ovoids and colpostats are placed in the vaginal vault under anesthesia. Different methods of brachytherapy are in vogue (see Fig. 23.9). High dose **brachytherapy** is safe and effective (NICE 2010).

**In Paris and Manchester techniques**, the source strength is smaller but exposure time is increased. The vaginal source is away from the cervix. They are used with either preloaded or afterloaded special applicators. One treatment period in Paris technique is 96–200 hours as compared to Stockholm technique where each application is 24–28 hours in duration (see Table 23.10). Manchester system, which is a modification of the Paris technique, delivers constant isodose at different depths, regardless of the size of the uterus and vagina.

**In Stockholm technique** (Fig. 23.9), large high intensity source with less exposure time is given, but the vaginal source is closer to the cervix.

These three basic techniques are followed all through the world in the brachytherapy for carcinoma cervix. After

loading remote control technique (see p. 506) is used for calculated dose distribution and to prevent radiation hazard. Fletcher-Suit afterloading modification system is widely used these days.

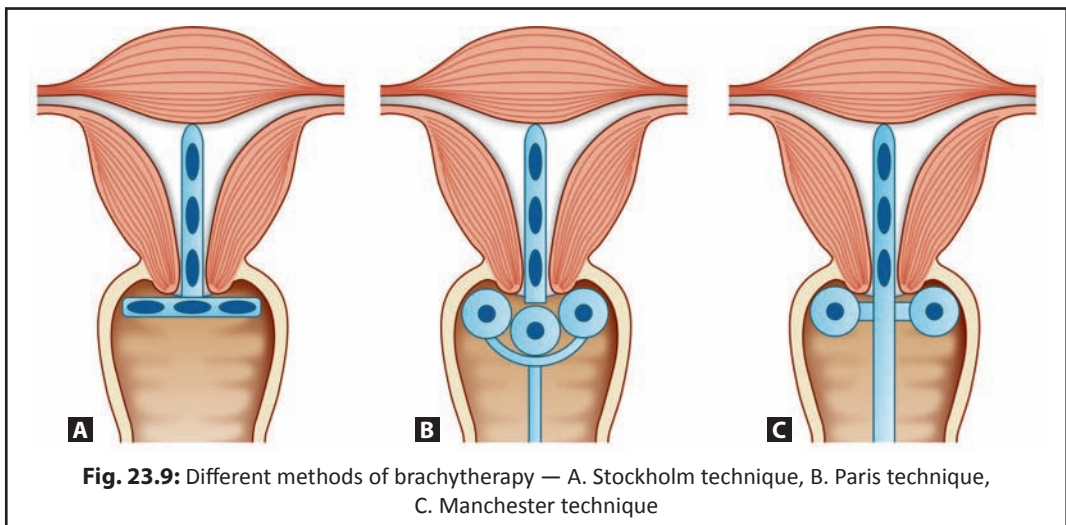
## DISADVANTAGES OF RADIOTHERAPY

Intestinal and urinary strictures, fistula formation (2–6%), vaginal fibrosis and stenosis causing dyspareunia, radiation menopause (p. 64), fibrosis of bowel and bladder. **Ovarian transposition (ovariopexy)** well out of the range of pelvic irradiation may be done to avoid radiation menopause. For other complications of radiation (see p. 508).

**Calculation of the dose (see p. 507):** The radium dose is conventionally calculated with respect to the amount of radiation received at two arbitrary points A and B. **Point A** is 2 cm cephalic and 2 cm lateral to the external os and is the point of crossing of the uterine artery and ureter. **Point B** is 2 cm cephalic and 5 cm lateral at the same plane and is approximately the site of obturator gland (Fig. 30.2).

It has been calculated that point A gets about 7000–8000 cGy and point B 2000 cGy. Taking into consideration that cancerolytic dose is approximately 7000 to 7500 cGy, the rest of the dose at point B is supplemented by external beam irradiation of 4000 cGy spreading over another three weeks. For external irradiation, linear accelerator with energy of 4 million electron volts or more is commonly used.

In the immediate vicinity of the source, the vagina and cervix get and tolerate about 20,000 to 30,000 cGy. Bladder,



**Fig. 23.9:** Different methods of brachytherapy — A. Stockholm technique, B. Paris technique, C. Manchester technique



**TABLE 23.10** MANAGEMENT OPTIONS OF CARCINOMA CERVIX  
MICROINVASIVE (STAGE IA), EARLY INVASIVE (STAGE IB, IIA) AND ADVANCED (STAGE IIB-IV) CARCINOMA

<i>Depth of invasion</i>	<i>Stage</i>	<i>Pelvic lymph node involvement</i>	<i>Surgery</i>	<i>Pelvic lymph adenectomy</i>
<ul style="list-style-type: none"> <li>Invasion <math>\leq</math> 3 mm</li> <li>No lymphovascular space (LVS) invasion</li> </ul>	IA <sub>1</sub>	0–0.6%	<ul style="list-style-type: none"> <li>Therapeutic conization of cervix (knife cone p. 590)</li> <li>Simple trachelectomy (see p. 607), provided strongly motivated for long-term follow up. Surgical margin (10 mm) must be free of disease</li> <li>Simple hysterectomy</li> </ul>	No
<ul style="list-style-type: none"> <li>Invasion 3–5 mm and horizontal spread <math>&lt;</math> 7 mm</li> </ul>	IA <sub>2</sub>	0.6–10%	<ul style="list-style-type: none"> <li>Simple trachelectomy</li> <li>Simple hysterectomy</li> </ul>	±
<ul style="list-style-type: none"> <li>Lymphovascular space involvement irrespective of depth of penetration</li> </ul>	IA <sub>1</sub> /IA <sub>2</sub>	6.5%	<ul style="list-style-type: none"> <li>Radical trachelectomy</li> <li>Modified radical hysterectomy (Type - I)</li> </ul>	+ +
<ul style="list-style-type: none"> <li>Stromal invasion exceeds <math>&gt;</math> 5 mm</li> </ul>	IB, IIA	16–44%	<ul style="list-style-type: none"> <li>Radical hysterectomy, pelvic lymphadenectomy (Type III) with paraaortic lymph node evaluation. External radiation if the nodes are positive OR Primary Radiation with concomitant platinum based chemotherapy (chemoradiation)</li> </ul>	+
ADVANCED CANCER	IIB-IVA IVB	30–55%	<ul style="list-style-type: none"> <li>Chemoradiation/Palliative Surgery (Nephrostomy/Colostomy)</li> <li>Chemoradiation ± Palliative radiotherapy</li> </ul>	

**Type I:** Extradiscal hysterectomy; pubocervical ligament is incised allowing lateral deflection of the ureter. **Type II** (Modified radical). Medial half of the Mackenrodt and Uterosacral ligaments along with selective (clinically enlarged palpable) lymph nodes and upper (2 cm) of vagina are removed. The uterine arteries are ligated at the site of crossing the ureters. The medial half of the parametria and proximal uterosacral ligaments are resected. **Type III** Radical hysterectomy with removal of the uterus, upper third of vagina, paracervical and paravaginal tissues are done. The uterine artery is ligated at its origin (internal iliac artery). Uterosacral and Cardinal ligaments are resected at their attachments to the sacrum and pelvic side wall. Bilateral pelvic lymphadenectomy is done. **Type IV** (Extended radical hysterectomy) see p. 597. **Type V** (Partial exenteration) see p. 349.

ureter and rectum can tolerate up to 7000 cGy. Small gut on the other hand has a tolerance limit of only 4500 cGy.

**For the prevention of radiation damage** to the adjacent viscera, packing the vagina should be done carefully with gauze around the vaginal ovoids or needles. Recent development of tungsten inserts with plastic applicator (colpostats) has minimized excess gamma irradiation of

the vaginal wall. Calculation of the amount of irradiation in rectum and bladder is done by dosimeter and required dose modification can be done as and when necessary (for treatment field—see p. 508).

With the advent of computer dosimetry, exact calculation of the doses on each patient for each application is being provided. **Intensity modulated radiation therapy**

(IMRT), based on computer generated algorithms can distinguish accurately the target tissue volume and normal tissue. IMRT can treat the tumor with higher doses accurately, sparing the normal tissues with minimal toxicity (see p. 510).

- **Advanced cases:** As the blood supply is poor, the resultant anoxia may be overcome by irradiating these cases in a special chamber under condition of hyperbaric oxygenation.
- **Recurrent cervical carcinoma:** Incidence of recurrence or persistent disease after therapy is about 35%. Whole pelvic irradiation with external beam radiotherapy has been advocated.
- **Carcinoma cervix detected after simple hysterectomy:** The management protocol depends upon the following factors : (i) **Cancer histology:** microinvasive/invasive; (ii) **Surgical tissue margin:** negative/positive; (iii) **Residual tumor mass:** absent or present.

**Management options:** (1) **Radical surgery** to remove rest of tissues including the regional nodes. This is specially done in a young patient. (2) **Radiation therapy:** (a) Brachytherapy when there is no or minimal residual disease. (b) Full intensity radiotherapy when gross residual disease is present.

- ▼ **Complications of radiotherapy:** Perforation of the uterus may result during introduction of uterine tandem. Radiation reactions are the major complications (See p. 508).
- ▼ **Combination therapy:** In the form of surgery, radiotherapy and chemotherapy may be done, one following the other.
- ◆ **Surgery followed by radiotherapy**
  - This is indicated in cases with **positive lymph nodes** detected following surgery.
  - **Accidental discovery of invasive carcinoma cervix** of a uterus removed by simple hysterectomy.
  - When **positive tissue resection margin** is present.

The objective of this form of therapy is to sterilize the cancer cells in the pelvic lymph nodes. The fact remains that even by pelvic lymph node dissection it is not possible to remove all the positive nodes. Radiation dose is reduced to 4500 cGy in 24 fractions over 5 weeks.

- ◆ **Postoperative adjuvant chemoradiation therapy** (extended field radiation and platinum-

based chemotherapy) significantly improved the survival rate when given following radical hysterectomy.

#### ◆ **Radiotherapy followed by surgery**

- **Endocervical carcinoma** with barrel-shaped cervix.
- **Bulky tumor:** Radiotherapy controls sepsis, the growth shrinks and the tumor resectability is improved.

#### ◆ *Neoadjuvant chemotherapy*

Chemotherapy is given before surgery. This shrinks the tumor and surgical resection is then possible.

Three cycles of platinum-based combination chemotherapy with radiation therapy followed 3–6 weeks by radical hysterectomy and lymphadenectomy is done. This has improved the resectability of the bulky  $\geq 4$  cm (stage IB<sub>2</sub> and bulky IIA) disease. This regimen had shown better overall disease free survival rate and reduced recurrence. Due to fibrosis, surgery may be difficult. Risk of ureteric fistula may be more. **The drugs used are in combination of Cisplatin, Ifosfamide or Paclitaxel.**

**Concurrent chemoradiation** includes radiation and weekly cisplatin-based combination chemotherapy. **Cisplatin-based concurrent chemoradiation** is used as a treatment of choice in: (a) Early stage (IA<sub>2</sub>, IB, IIA) disease after radical hysterectomy. (b) As a primary treatment for patients with bulky ( $\geq 4$  cm) tumor (stage IB and IIA) and (c) locally advanced (stage IIB to IVA) disease as a primary therapy. Chemotherapy sensitizes the cancer cells to radiation and improves the survival rate.

- **Laparoscopic Assisted Vaginal Radical Trachelectomy with Pelvic and Aortic Lymphadenectomy (LARVT)** was designed (Daniel Dargent 1987) to treat early invasive cervical cancer. This is done in a young woman where childbearing function is to be preserved. Initially, pelvic and aortic lymph node dissection is done. **Vaginal radical trachelectomy is done only when these nodes are negative.** Laparoscopic approach is similar to LARVH (p.349). Vaginal part includes resection of cervical, vaginal, paracervical and paravaginal tissues. Vaginal cuff is resected circumferentially about 2 cm below the cervicovaginal junction. Ideally, the resected

cervical tissue margins should be free of disease as evaluated by frozen section.

**Indications of trachelectomy are:** (i) Preservation of fertility, (ii) early stage disease (stage IA1, A2, IBI), (iii) small tumor volume (< 2 cm), (iv) no pelvic node metastasis, (v) cancer margin is at 1 cm below the internal os on MRI.

## PLANNING OF TREATMENT MODALITIES

**A. Early Stage Disease:** See Table 23.10 (p. 351)

For **early stage disease**, the survival rate following treatment by either radical hysterectomy and pelvic lymphadenectomy or with primary radiation (see p. 352) with concurrent chemoradiation are almost equal.

**B. Advanced Stage Disease:** See p. 352

## PALLIATIVE TREATMENT

Palliative treatment is primarily aimed to provide comprehensive care for relief of symptoms along with treatment of cancer in the advanced stage.

*A purulent or foul vaginal discharge* is treated with antimicrobial vaginal creams or suppositories.

**Bleeding:** Palliative radiation therapy (180–200 eGy/day) or chemotherapy may be used to relieve symptoms of pain or bleeding. Tight vaginal pack soaked in Monsel's solution (Ferric Subsulfate) against the cervix may control bleeding temporarily.

**Pain:** Palliation of pain is done either by reducing the pain stimulus or by raising the pain threshold. Pain from bone metastasis is mainly due to prostaglandin production. It is best controlled by using nonsteroidal anti-inflammatory drugs (NSAIDs). Palliative radiation with 2000 cGy over five treatment course may be an alternative. Anxiolytic (benzodiazepines) or antidepressant drugs (amitriptyline) may be helpful to raise the pain threshold. Opioid (oral morphine 3–10 mg) combined with paracetamol or aspirin, given at a regular interval (4–5 hours) is widely used to reduce pain perception.

Neuropathic pain is difficult to manage. Regional blockade with local anesthetic techniques has been considered in some cases. Pudendal block is helpful for lower pelvic and perineal pain. Intrathecal (spinal, epidural) opioids are appropriate for pain from any region. Unilateral cordotomy (C 1-2) is considered for widespread pain which is refractory.

## CARCINOMA OF CERVIX AND PREGNANCY

Incidence of invasive carcinoma of the cervix is about one in 2500 pregnancies.

Diagnosis is often late. Cone biopsy may be necessary for confirmation. **Complications of cone biopsy include:** Hemorrhage, abortion, preterm labor and infection (see p. 590).

**Management:** The following points are taken into consideration before actual management: (A) Period of gestation, (B) survival of the fetus and (C) wishes of the patient.

(A) **Patient with microinvasive carcinoma** may be followed up to term. Patient is reevaluated following delivery and treated as in the nonpregnant state.

(B) **Advanced stage:** In the first trimester, treatment modality is the same as in the nonpregnant state. In late pregnancy, following maturity, fetus is delivered by classical cesarean section. Subsequent treatment with either radical surgery or radiotherapy is the same as in the nonpregnant state.

**Prognosis:** Clinical stage of the disease is the single most important prognostic factor. Stage for stage survival outcome appears to be no different between pregnancy and nonpregnant state (for details see author's Textbook of Obstetrics, ch. 21).

## RESULTS OF THERAPY FOR CARCINOMA CERVIX

The result of therapy is expressed in terms of 5-year survival rate. The overall 5-year survival rate is tabulated in Table 23.11.

There is about 30 percent recurrence after 5 years. The recurrence **sites are** in the side wall of the pelvis

**TABLE 23.11** 5-YEAR SURVIVAL RATE

Stage	5-year survival rate (%)
IIa	76.0
IIb	73.3
IIIa	50.5
IIIb	46.4
IVa	29.6
IVb	22.0

and central pelvis. **A patient is declared cured if she remains well even after 10 years following initial therapy.** The chance of survival rate of the patient after the symptoms appear, if left untreated, is about 2 years.

### Recurrent Cervical Cancer

Risk factors for recurrent disease are: Large tumor size, lymphovascular space invasion, positive lymph nodes, advanced stage disease.

**Most common site** of recurrence is pelvic side wall. Features of disease recurrence are: Pain in the pelvis, back, unilateral leg edema, ureteral obstruction, vaginal bleeding, palpable tumor in the pelvis and lymphadenopathy. Single agent or multiagent chemotherapy with cisplatin, paclitaxel or ifosfamide is used. Palliative radiation therapy may be used to those who have been treated initially with surgery.

**Follow up:** The majority of the recurrences occur in the first 2 years. As such, the follow up protocols should be at 3–4 months interval for the first 2 years then at 6 months interval for next 2 years and thereafter annually. Thorough physical examination is done including examination of supraclavicular and inguinal lymph nodes. Cervical or vaginal cytology is performed. Chest X-ray is done annually.

**STUMP CARCINOMA:** When the carcinoma develops in the cervical stump left behind after subtotal hysterectomy, it is called stump carcinoma. **In true stump carcinoma,** malignancy develops 2 years after primary surgery. If it occurs earlier to that, it is presumed that the carcinoma was present at the time of primary surgery and, as such it is called coincidental, residual or false stump carcinoma.

**The incidence** may be as high as 1 percent. It is difficult to stage the disease.

There is also difficulty in the **treatment.** Dense adhesions of bladder, rectum and also ureters with the stump make the operation difficult and risky. The radiation therapy is also technically difficult, because of absence of uterus and close proximity of bladder and rectum to the radiation source. Radical parametrectomy, removal of cervix, upper vagina and pelvic lymphadenectomy is done in early stage disease.

External beam radiation therapy is given when the cervix is short. Vaginal radium application (vaginal cone) is also used. The prognosis is unfavorable. The 5-year survival rate varies from 30–60 percent.

## ENDOMETRIAL CARCINOMA

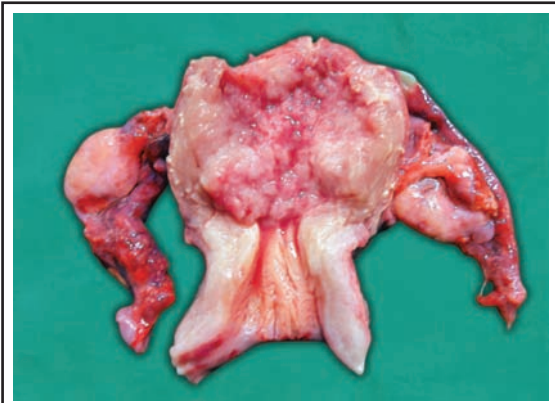
**INCIDENCE:** The incidence is higher amongst the white population of the United States and lowest in India and Japan. In North America, amongst the whites, carcinoma body is the leading site of genital malignancy followed by ovary and cervix. In the USA, a woman has about 1 percent chance of developing endometrial carcinoma during her lifetime. In India, it ranks third amongst genital malignancy next to cervix and ovary.

While in the Western countries, there has been increased incidence of carcinoma body relative to cervical one and the ratio becomes almost 1:1; in India, the incidence still remains low and the ratio ranges *between 1:8 and 1:15*. **The high prevalence of cancer cervix is due to infection with HPV** (p. 323) in presence of other cofactors (p. 322) and lack of screening facilities (see p. 324).

The higher incidence in the Western countries may be real or apparent. The real one is due to high expectation of life and injudicious use of estrogen in postmenopausal women and the apparent one is due to its detection, out of increased awareness amongst the gynecologists.

**ETIOLOGY:** The following are found to be related to carcinoma body of the uterus:

- ◆ **Estrogen**—Persistent stimulation of endometrium with unopposed estrogen is the single most important factor for the development of endometrial cancer.
- ◆ **Age**—About 75 percent are postmenopausal with a median age of 60 (c.f. Carcinoma cervix is more common in perimenopausal period). About 10 percent of women with postmenopausal bleeding have endometrial cancer.
- ◆ **Parity**—It is quite common in unmarried and in married, nulliparity is associated in about 30 percent. (c.f. – Carcinoma cervix is associated more with multiparae).
- ◆ **Late menopause**—The chance of carcinoma increases, if menopause fails to occur beyond 52 years.
- ◆ **Corpus cancer syndrome**—encompasses – obesity, hypertension and diabetes.



**Fig. 23.10:** Diffuse type of endometrial carcinoma

- ◆ **Obesity** leads to high level of free estradiol as the sex hormone binding globulin level is low.
- ◆ **Unopposed estrogen stimulation** in conditions such as functioning ovarian tumors (granulosa cell) or polycystic ovarian syndrome (PCOS) is associated with increased risk of endometrial cancer. Unopposed estrogen replacement therapy (see p. 329) in postmenopausal women is associated with increased risk of endometrial cancer. Use of cyclic progestin reduces the risk. Prior use of combined oral contraceptives reduces the risk significantly (50%).
- ◆ **Tamoxifen** is antiestrogenic as well as weakly estrogenic. It is used for the treatment of breast cancer. Increased risk of endometrial cancer is noted when it is used for a long time due to its weak estrogenic effect.
- ◆ **Family history or personal history** of colon, ovarian or breast cancer increases the risk of endometrial cancer. Genetic inheritance (Lynch 11 syndrome family) is currently thought of (see p. 520).
- ◆ **Fibroid** is associated in about 30 percent cases.
- ◆ **Endometrial hyperplasia** precedes carcinoma in about 25 percent cases.

**PATHOLOGY: Naked eye**—The uterus may be smaller, normal or even enlarged (due to myohyperplasia, myometrial involvement, pyometra or associated fibroid). Two varieties are found:

■ **Localized** ■ **Diffuse**

**Localized:** The usual site is on the fundus. It is either sessile or pedunculated. Myometrial involvement is late.

**Diffuse:** The spread is through the endometrium. The myometrium is commonly invaded; may invade to reach the serosal coat (Fig. 23.10).

**Microscopic Appearances**

The following varieties are noted:

- Adenocarcinoma (endometrioid 80%) (Fig. 23.11).
- Adenocarcinoma with squamous elements.
- Papillary serous carcinoma (5–10%) (virulent).
- Mucinous adenocarcinoma (5%).
- Clear cell adenocarcinoma (5%).
- Secretory carcinoma (1%).
- Squamous cell carcinoma.
- Mixed carcinoma.

**SPREAD**

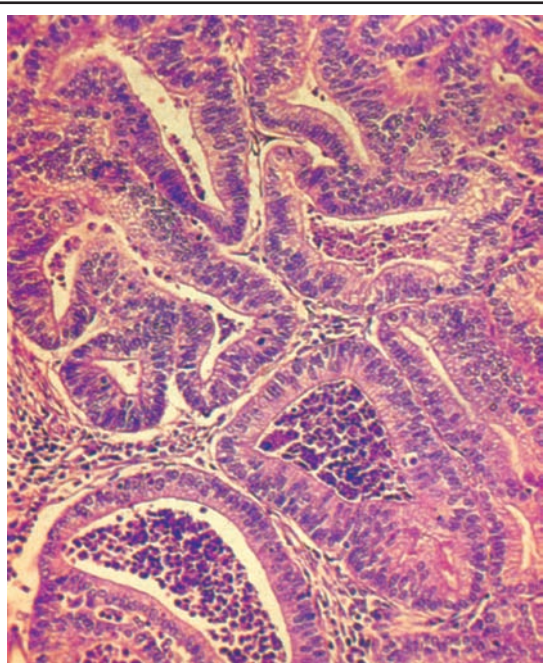
**Direct:** As it is slow growing, it is confined to the stroma for a long time but eventually, it spreads in all directions. Thus, it may infiltrate the myometrium and spread to the parametrium or into the peritoneal cavity. It may spread downwards to **involve the cervix in about 15 percent**.

**Lymphatic:** The lymphatic spread is usually late. Lymphatic spread involves **pelvic, paraaortic (through infundibulopelvic ligament) and rarely inguinal and femoral (through lymphatics of round ligament) nodes**.

Lymph node metastasis depends on the degree of tumor differentiation, myometrial invasion, tumor size and the surgical pathological stage of the disease. Pelvic lymph node involvement in stage I disease varies from about 4 percent in grade 1 and 2 disease with superficial myometrial involvement to about 40 percent with grade 3 tumor with deep myometrial invasion. Approximately, 50 percent of the patients with pelvic lymph nodes will have paraaortic lymph node metastasis. In stage II disease incidence of pelvic lymph node metastasis increases to 30–45 percent. Lymph node metastasis is the most important prognostic factor.

The **tubes and ovaries** are involved (3–5%) either by direct spread or by lymphatics.

**The vagina is involved in about 10–15 percent cases.** The metastasis to the lower-third of the anterior



**Fig. 23.11:** Adenocarcinoma of the endometrium, the commonest histologic type. There is significant cellular mitotic activity. The glands are arranged back-to-back

vaginal wall is probably through lymphatic or by retrograde venous flow. The vault metastasis following hysterectomy may be due to direct implantation or may be explained by previous lymphatic or venous embolism.

**Hematogenous:** Blood borne spread occurs late. The common sites of metastases are lungs, liver, bones and brain.

**Staging:** The staging is based on endometrial histology and surgical evaluation, adopted by FIGO (2009, see p. 357). Approximately 75 percent patients present with stage I disease.

### CLINICAL FEATURES

**Patient profile:** The patient is usually a nullipara, likely to be postmenopausal. There may be history of delayed menopause. She may be obese; likely to have hypertension or diabetes (Table 23.13).

#### Symptoms

- ◆ Postmenopausal bleeding (75%) which may be slight, irregular or continuous. The bleeding at times may be excessive.

- ◆ In premenopausal women, there may be irregular and excessive bleeding.
- ◆ At times, there is watery and offensive discharge due to pyometra.
- ◆ Pain is not uncommon. It may be colicky due to uterine contractions in an attempt to expel the polypoidal growth.
- ◆ Few patients (<5%) remain asymptomatic.

**Signs:** The patient presents with the features as mentioned in patient profile. There may be varying degrees of pallor.

**Pelvic examination:** Speculum examination reveals the cervix looking healthy and the blood or purulent offensive discharge escapes out of the external os.

Bimanual examination reveals—The uterus is either atrophic, normal or may be enlarged due to spread of the tumor, associated fibroid or pyometra. The uterus is usually mobile unless in late stage, when it becomes fixed.

Rectal examination corroborates the bimanual findings.

Regional lymph nodes and breasts are examined carefully.

## DIAGNOSIS OF ENDOMETRIAL CARCINOMA

The following guidelines are prescribed:

- ◆ A case of postmenopausal bleeding is considered to be due to endometrial carcinoma unless proved otherwise.
- ◆ Finding a benign condition to account for postmenopausal bleeding does not negate a thorough investigation to rule out carcinoma. The two lesions may co-exist.
- ◆ History and clinical examination are to be recorded, as mentioned earlier.
- ◆ **Endometrial biopsy** – using a Sharman curette or a soft, flexible, plastic suction cannula (pipelle) has been done with reliability (90%). This is done as an outpatient procedure (Fig. 9.22). Histology is the definitive diagnosis.
- ◆ **Papanicolaou smear** is not a reliable diagnostic test for endometrial carcinoma. It is positive only in 30 percent cases of endometrial cancer.

- ◆ **Ultrasound and color Doppler (TVS):** Findings suggestive of endometrial carcinoma are — (i) Endometrial thickness  $\geq 4$  mm. (ii) Hyperechoic endometrium with irregular outline. (iii) Increased vascularity with low vascular resistance. (iv) Intrauterine fluid. However, it cannot replace definitive biopsy.
- ◆ **Hysteroscopy**—It helps in direct visualization of endometrium and to take target biopsy.
- ◆ **Fractional curettage**—It is not only **the definite method of diagnosis** but can detect the extent of growth. This is done under anesthesia with utmost gentleness to prevent perforation of the uterus. If pyometra is detected, the procedure is withheld for about 1 week to avoid perforation and systemic infection.

#### The orderly steps for fractional curettage:

- Endocervical curettage (ECC).
- To pass an uterine sound to note the length of the uterocervical canal.
- Dilatation of the internal os.
- Uterine curettage at the fundus and lower part of the body. The endometrial tissue is usually profuse and often dark color.
- Finally, a polyp forceps is introduced in case any endometrial polyp has escaped the curette.

The specimens, so obtained, should be placed in **separate containers**, labelled properly and submitted for histological examination.

- **Computed Tomography (CT) scan** of pelvis and abdomen may be used to detect lymph node metastases (p. 118).
- **Magnetic Resonance Imaging (MRI)** can detect myometrial invasion (see p. 118).
- **Positron Emission Tomography** (see p. 119).

**Surgical staging:** Increased inaccuracy of clinical staging and the importance of prognostic factors, some of which can only be identified surgically, resulted in introduction of surgicopathological staging by FIGO in 2009.

<b>Stage</b>	<b>Description</b>
<b>Stage I*</b>	Tumor confined to the corpus uteri
IA*	No or less than half myometrial invasion
IB*	Invasion equal to or more than half of the myometrium
<b>Stage II*</b>	Tumor invades cervical stroma, but does not extend beyond the uterus**
<b>Stage III*</b>	Local and/or regional spread of the tumor
IIIA*	Tumor invades the serosa of the corpus uteri and/or adnexae*
IIIB*	Vaginal and/or parametrial involvement*
IIIC*	Metastases to pelvic and/or para-aortic lymph nodes*
IIIC1*	Positive pelvic nodes
IIIC2*	Positive paraaortic lymph nodes with or without positive pelvic lymph nodes
<b>Stage IV*</b>	Tumor involves bladder and/or bowel mucosa, and/or distant metastases.
IVA*	Tumor invasion of bladder and/or bowel mucosa
IVB*	Distant metastases, including intraabdominal metastases and/or inguinal lymph nodes

\* Either G<sub>1</sub>, G<sub>2</sub> or G<sub>3</sub>. Depending upon the percentage of solid nonsquamous component, G<sub>1</sub> has  $\leq 5\%$ , G<sub>2</sub> has 6–50% and G<sub>3</sub> has  $> 50\%$  of solid component.

\*\* Endocervical glandular involvement only is considered as Stage I and no longer as Stage II.

\* Positive cytology has to be reported separately without changing the stage.

## MANAGEMENT OF ENDOMETRIAL CARCINOMA

- ◆ Preventive
- ◆ Curative

**PREVENTIVE:** Primary prevention includes:

- ◆ Strict weight control beginning early in life.

- ◆ To restrict the use of estrogen after menopause in nonhysterectomized women. If at all it is needed, cyclic administration of progestogen preparations are added and continued under supervision.
- ◆ Education as regard the significance of irregular bleeding per vaginum in perimenopausal and postmenopausal period.

Secondary prevention includes:

- ◆ Screening of 'high risk' women at least in menopausal period to detect the premalignant or early carcinoma is a positive step.

### Methods

- ◆ The cytologic specimens are obtained by either endometrial aspiration or endometrial lavage. If suspicious cells are detected, histological specimen is obtained by uterine curettage.
- ◆ The presence of abnormal endometrial cells in vaginal pool cytology requires a diagnostic curettage.
- ◆ Judicial hysterectomy in premalignant lesions of the corpus (see p. 331).

TABLE 23.13

### 'HIGH RISK' FACTORS FOR ENDOMETRIAL CANCER

- ◆ Late menopause
- ◆ Nulliparity
- ◆ Unopposed estrogen therapy
- ◆ History of persistent anovulation (PCOS)
- ◆ History of irregular and excessive premenopausal bleeding
- ◆ Obesity, diabetes, hypertension
- ◆ Personal or family history of breast, ovary, colon or endometrial cancer
- ◆ Atypical endometrial hyperplasia (p. 331)
- ◆ Tamoxifen therapy
- ◆ Radiation menopause.

### CURATIVE

**Pretreatment work up:** As the patients are usually aged, obese and often complicated with medical disorders, careful systemic examination and necessary investigations are mandatory before formulating the line of treatment. Along with a gynecologic oncologist, a physician's help may be needed.

**Pretreatment preparations (Table 23.14):** The same protocol as mentioned in cases of carcinoma cervix is to be followed.

## TREATMENT MODALITIES OF CARCINOMA ENDOMETRIUM

- Surgery
- Radiotherapy
- Chemotherapy
- Combined therapy

TABLE 23.14

### PREOPERATIVE EVALUATION

- ◆ Blood examination — complete hemogram, postprandial sugar, urea, creatinine and electrolytes.
- ◆ Liver and renal function tests.
- ◆ Urine — Routine examination for – protein, sugar and pus cells.
- ◆ ECG and X-ray chest for cardiopulmonary assessment.
- ◆ Abdominal and pelvic ultrasonography for ascites, metastasis (liver), pelvic/paraortic nodes.
- ◆ MRI/CT imaging (optional) to assess the extra-uterine spread of the disease and the degree of myometrial invasion.
- ◆ Steroid receptor status.

### SURGERY

**Extrafascial hysterectomy** is the preferred treatment for endometrial carcinoma confined to the body. The surgery includes removal of the uterus, tubes and ovaries of both the sides and cuff of vagina. Removal of vaginal cuff is not essential as it neither improves the survival nor reduces the recurrence rate.

### IN STAGE I, SURGERY IS THE MAINSTAY OF TREATMENT

#### Surgical procedures (surgical staging p.357)

- ◆ **Incision** longitudinal midline or paramedian is of choice for better exposure.
- ◆ **Peritoneal washings** are taken for cytology.
- ◆ **Thorough exploration** of liver, diaphragm, omentum, pelvic organs, pelvic and paraortic lymph nodes, is done.
- ◆ **Suturing** the cervix and fimbrial end of the fallopian tubes to prevent tumor cells spillage during operation are not essential.
- ◆ **Not to hold** the uterus by a vulsellum. Instead, traction is given by placing long straight artery forceps on either side of uterine cornu (Fig. 34.4).



- ◆ **Total abdominal hysterectomy (extrafascial)** with bilateral salpingo-oophorectomy is performed.
- ◆ **Uterus** is cut open in the operating room – for evaluation of tumor size, cervical extension and myometrial invasion.
- ◆ **Presence of big tumor (>2 cm)**, cervical extension, poor tumor differentiation and myometrial invasion (>1/2 thickness) as determined by frozen section biopsy, indicates pelvic and paraaortic lymph node sampling.
- ◆ **Lymph node sampling** of the following areas is done : (i) Common iliac (ii) External iliac (iii) Internal iliac (iv) Obturator and (v) Paraaortic.
- ◆ **Vaginal hysterectomy** may be done selectively (stage I, with well-differentiated tumor) in patients with uterovaginal prolapse or with extreme obesity.
- ◆ **Laparoscopic** hysterectomy (TLH. see p. 617) with bilateral salpingo-oophorectomy and lymph node sampling are done for staging and treatment of endometrial carcinoma (stage I).

### IN STAGE II CARCINOMA

#### Management options are:

- A. Radical hysterectomy bilateral salpingo-oophorectomy with pelvic and para-aortic lymphadenectomy (see p. 348).
- B. Combined radiation and surgery: Radiation (external and intracavitary) followed in 6 weeks by total abdominal hysterectomy and bilateral salpingo-oophorectomy. or
- C. Initial surgery (modified radical hysterectomy) followed by external and intravaginal radiation.

### RADIOTHERAPY

**The primary treatment by radiotherapy** is indicated in:

- ◆ Women found unfit for surgery
- ◆ Women with significant medical comorbidities.
- ◆ Surgically inoperable disease
- ◆ Those with high-risk of recurrence
- ◆ Patients with advanced disease for palliation therapy.

**Contraindications of radiotherapy:** Presence of a pelvic mass, pelvic kidney, pyometra, pelvic abscess, previous laparotomies and/or adhesions with bowel and prior pelvic radiation.

### COMBINED THERAPY (SURGERY AND RADIATION)

Combined therapy has shown high degree of success in this disease.

TAH-BSO followed by adjuvant radiotherapy 4–6 weeks after surgery, in a selected case, is done **to prevent loco regional recurrence**

- ◆ **No myometrial invasion stage IA (G1, 2):** Observation only.
- ◆ **Myometrial invasion <1/2 thickness (stage IA, G2 disease):** Vaginal vault radiation (5000–6000 cGy) using colpostats after-loading techniques.
- ◆ **Myometrial invasion >1/2 thickness (stage IB):** Whole pelvis external beam radiation (4500–5000 cGy) over 5–6 weeks plus vaginal cuff boost.
- ◆ **Radiation therapy:** Adjuvant radiotherapy (brachytherapy and pelvic radiation) reduces loco-regional recurrence in cases with high risk endometrial cancer.

### STAGE III AND IV ENDOMETRIAL CANCER

**In locally advanced disease:** Adjuvant chemotherapy followed by pelvic radiation is done. Combination chemotherapy is commonly used. **Drugs comprise:** adriamycin, cisplatin and cyclophosphamide.

**External pelvic and intracavitary radiation followed by extended hysterectomy** 6 weeks later in cases of:

- Highly anaplastic tumor
- Papillary serous carcinoma
- Clear cell carcinoma.

These tumors have got high rate of recurrence both locoregional and systemic.

### CHEMOTHERAPY

Chemotherapy is used in advanced and recurrent cases or in metastatic lesions.

- ◆ **Progestogens** — are widely used. The response is good in well-differentiated carcinoma with

adequate estrogen and progesterone receptors (see p. 534).

Any one of the drugs—17 hydroxyprogesterone caproate (1 g/week. IM), medroxy progesterone acetate (1 g/week. IM or 150 mg/day oral) or megestrol acetate (160 mg/day orally) is of use. The drug is to be continued for at least 3 months. If responsive, may be continued for longer period with reduced doses.

- ◆ **Tamoxifen** is a nonsteroidal agent with anti-estrogenic as well as weakly estrogenic properties. It is used 10 mg twice daily along with progestogen therapy. It blocks the tissue estrogen receptor. It is effective in patients with hormone receptor positive tumors (see p. 534).
- ◆ **Cytotoxic drugs**— are being tried either singly or in combination but without any superiority over the hormonal therapy. **The drugs commonly used are adriamycin, cisplatin, carboplatin, paclitaxel and cyclophosphamide** (see ch. 30, Table 30.6).

**RECURRENT DISEASE:** Common sites for recurrence are the vagina and the pelvis. The extrapelvic metastases are seen in the lung, lymph nodes (aortic), liver, brain and bones. Majority (60%) of recurrences are seen within 2 years of initial therapy.

- ◆ Radiation therapy is the choice for isolated recurrence following surgical treatment.
- ◆ Exenterative surgery for recurrent endometrial cancer is of limited value.
- ◆ Hormonal therapy and chemotherapy (see p. 513) have been used depending on the individual case.

### FOLLOW-UP OF PATIENTS

Following initial therapy, patient is examined every 4 months for the first 2 years, every 6 months for next 2 years and thereafter, annually. Evaluation of symptoms, thorough clinical examination and X-ray chest (annual) are essential. Other investigations are: mammography (annual) and CT, MRI when clinically indicated. Regular estimation of serum CA 125 may be helpful in some cases.

### PLACE OF HORMONE REPLACEMENT THERAPY

Estrogen replacement therapy to combat the estrogen deficiency symptoms following treatment

of endometrial cancer is a debatable issue. In a patient with severe postmenopausal symptoms progestin (medroxy progesterone acetate, 5–10 mg daily) may be a choice. Non-hormonal therapy (clonidine) can also be used (p. 61). Urogenital symptoms can be improved using topical estrogen (p. 62).

**PROGNOSIS:** The poorly differentiated tumor, the greater degree of myometrial penetration, lymphovascular space invasion and the advanced stages are prognostically poor. Aneuploid tumors are prognostically worst. Histologically non-endometrioid tumors are aggressive and carry increased risk of recurrence. The prognostic factors to be considered are tabulated in Table 23.15.

**TABLE 23.15** PROGNOSTIC FACTORS IN ENDOMETRIAL ADENOCARCINOMA

- ◆ Age at diagnosis (older the patient poorer the prognosis).
- ◆ Stage of the disease.
- ◆ Histologic type (typical adenocarcinomas — better prognosis, papillary serous, clear cell carcinoma — poor prognosis).
- ◆ Histologic differentiation.
- ◆ Histologic grade (p. 357): grade 3 tumors have 5 times more risk of recurrence and low 5 year survival rate.
- ◆ Myometrial penetration.
- ◆ Lymphovascular space invasion.
- ◆ Lymph node metastasis.
- ◆ Extension to cervix.
- ◆ Peritoneal cytology.
- ◆ Tumor size (>2 cm → more lymph node metastasis).
- ◆ Hormone receptor status (receptor positive tumors have got better prognosis).
- ◆ Ploidy status — aneuploid tumors have got poor prognosis compared to diploid tumors.
- ◆ Oncogene expression — HER-2/neu, poor prognosis (see ch. 30, p. 520).

**TABLE 23.16** 5-YEAR SURVIVAL RATE

Stage	Overall survival rate (%)
I	81–91
II	67–77
III	30–60
IV	5–20

## GESTATIONAL TROPHOBLASTIC DISEASE (GTD)

**Gestational Trophoblastic Disease (GTD) is a spectrum of abnormal growth and proliferation of the trophoblasts that continue even beyond the end of pregnancy.** GTN encompasses persistent hydatidiform mole, invasive mole, choriocarcinoma and a rare entity of placental site trophoblastic tumor (Table 23.17).

**Diagnosis of postmolar GTN is made** when the hCG level plateaus for 3 or more consecutive weeks or reelevates. **This may occur in 15–20 percent following hydatidiform mole.** Some, however, follow abortion, ectopic and even normal pregnancy.

**Persistent Gestational Trophoblastic Neoplasia (GTN):** Persistent GTN is evidenced by persistence of trophoblastic activity following evacuation of molar pregnancy. **This is clinically diagnosed** when the patient presents with (a) Irregular vaginal bleeding. (b) Subinvolution of the uterus. (c) Persistence of theca lutein cysts and (d) Level of hCG either plateaus or reelevates after an initial fall. After molar evacuation serum  $\beta$  hCG becomes normal in about 7–9 weeks.

Postmolar GTN of serious nature may be either invasive mole or choriocarcinoma but **GTN after non-molar pregnancy is always a choriocarcinoma.**

TABLE 23.17

### GESTATIONAL TROPHOBLASTIC NEOPLASIA (GTN)

- Persistent hydatidiform mole
- Invasive mole
- Choriocarcinoma
- Placental site trophoblastic tumor

♦ **Non-metastatic disease (confined to the uterus)**

♦ **Metastatic disease:**

**A. Low risk (good prognosis)**

- Disease is present < 4 months duration
- Initial serum hCG level < 40,000 mIU/mL
- Metastasis limited to lung and vagina
- No prior chemotherapy

**B. High risk (poor prognosis)**

- Long duration of disease (> 4 months)
- Initial serum hCG > 40,000 mIU/mL
- Brain or liver metastasis
- Failure of prior chemotherapy
- Following term pregnancy
- WHO score  $\geq 7$  (see p. 364)

**Incidence:** The incidence of GTN is about 1 in 5000 pregnancies in oriental countries and 1 in 50,000 in Europe and North America. More than 50 percent occur after molar pregnancy, about 25 percent after abortion and/or ectopic pregnancy and a few after normal pregnancy. **Non-metastatic (locally invasive) lesions develop in 15 percent and metastatic lesions develop in about 4 percent of patients after molar evacuation.**

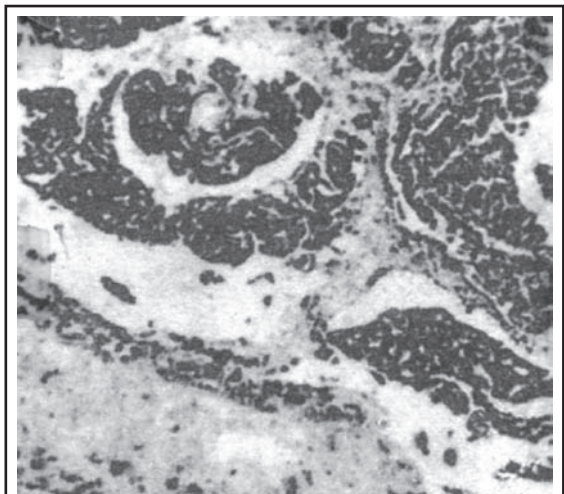
### Placental Site Trophoblastic Tumor

The tumor arises from the trophoblast of the placental bed. Incidence is less than 1 percent of all patients with GTN. 15–20 percent of these patients develop metastases. Syncytiotrophoblast cells are generally absent, instead intermediate trophoblast cells are predominant.  $\beta$  hCG secretion is low but human placental lactogen (hPL) is secreted and this is monitored during the follow up. **The entity is not responsive to chemotherapy. Hysterectomy is the preferred treatment. Serial serum hPL** may be a reliable marker and hPL is useful for immunohistochemical staining to confirm the diagnosis.

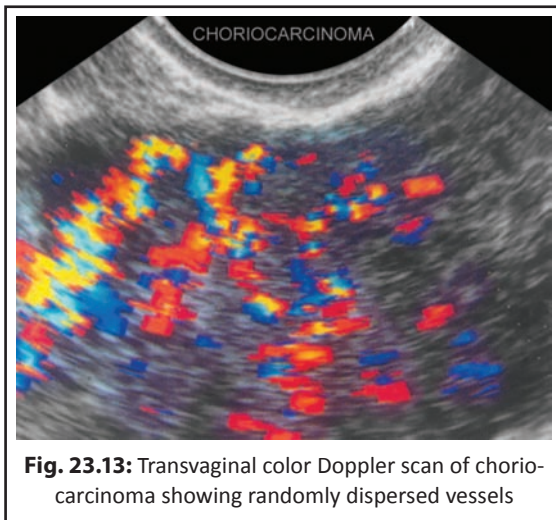
## INVASIVE MOLE (CHORIOADENOMA DESTRUENS)

Invasive mole comprises about 15 percent of all GTN.

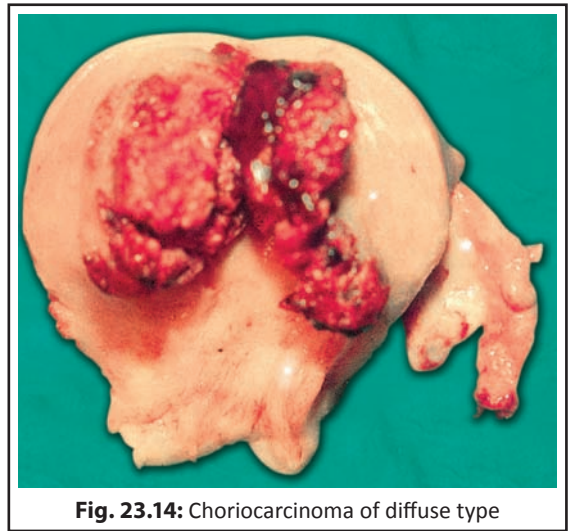
The prominent features of this type of mole are invasive and destructive potentialities. Invasive mole shows abnormal penetration through the muscle layers of



**Fig. 23.12:** Histological section of invasive mole showing structures of villi with marked trophoblastic proliferation deep in myometrium



**Fig. 23.13:** Transvaginal color Doppler scan of choriocarcinoma showing randomly dispersed vessels



**Fig. 23.14:** Choriocarcinoma of diffuse type

the uterus. The uterine wall may be perforated at multiple areas showing purple, fungating growth with massive intraperitoneal hemorrhage. The neoplasm may invade the pelvic blood vessels and metastasizes to vagina or distant sites as like those in choriocarcinoma.

### Diagnosis

- ◆ **On laparotomy:** (a) Perforation of the uterus through which purple fungating growth is visible. (b) Hemoperitoneum.
- ◆ **Histology**—There is penetration of the uterine wall by the hyperplastic trophoblastic cells which **still retain villus structures. There is no evidence of muscle necrosis** (Fig. 23.12). The materials for uterine curettage are often deceptive as the lesion may be deep inside the myometrium.
- ◆ **Persistent high level** of urinary or serum hCG.

## CHORIOCARCINOMA

Choriocarcinoma is a highly malignant tumor arising from the chorionic epithelium. It should be remembered that it is not a tumor of the uterus which is secondarily involved.

About 3–5 percent of all patients with molar pregnancies develop choriocarcinoma. Amongst all patients with choriocarcinoma, around 50 percent develop following a hydatidiform mole, 30 percent occur after a miscarriage or an ectopic pregnancy and 20 percent after an apparently normal pregnancy. **Trophoblastic disease following a**

**normal pregnancy is either choriocarcinoma or PSTT and not a benign or invasive mole.**

**PATHOLOGY:** The primary site is usually anywhere in the uterus. Rarely, it starts in the tube or ovary. Ovarian choriocarcinoma (non-gestational) may also be associated with malignant teratoma or dysgerminoma.

### Naked Eye Appearances (Fig. 23.14)

The lesion is usually localized nodular type. It looks red, hemorrhagic and necrotic. At times, the lesion is diffuse involving the entire endometrium. The nodular type may be located deep in the myometrium with overlying endometrium intact. This often gives the false-negative diagnosis on uterine curettage.

### Microscopic Appearance (Fig. 23.15)

There are anaplastic sheets or columns of trophoblastic cells invading the uterine musculature. There are **evidences of necrosis and hemorrhage. Villus pattern is completely absent.**

**Ovarian enlargement:** Bilateral lutein cysts are present in about 30 percent. These are due to excessive production of chorionic gonadotropin.

**SPREAD OF GTN:** Apart from the local spread, vascular erosion takes place early and hence distant metastases occur rapidly. **The common sites of metastases are** lungs (80%), anterior vaginal wall (30%), brain (10%), liver (10%) and others.

**CLINICAL FEATURES OF GTN:** The clinical features depend on the location of the primary growth and on its secondary deposits.

**Patient profile:** There is usually a history of molar pregnancy in recent past. Rarely, its relation with a term pregnancy, abortion or ectopic pregnancy may be established. **GTN after a non-molar pregnancy is always a choriocarcinoma.**

**Symptoms:** The following are the usual symptoms :

- ◆ Persistent ill health.
- ◆ Irregular vaginal bleeding, at times brisk.
- ◆ Continued amenorrhea.

Other symptoms due to metastatic lesions are:

**Lung:** Cough, breathlessness, hemoptysis.

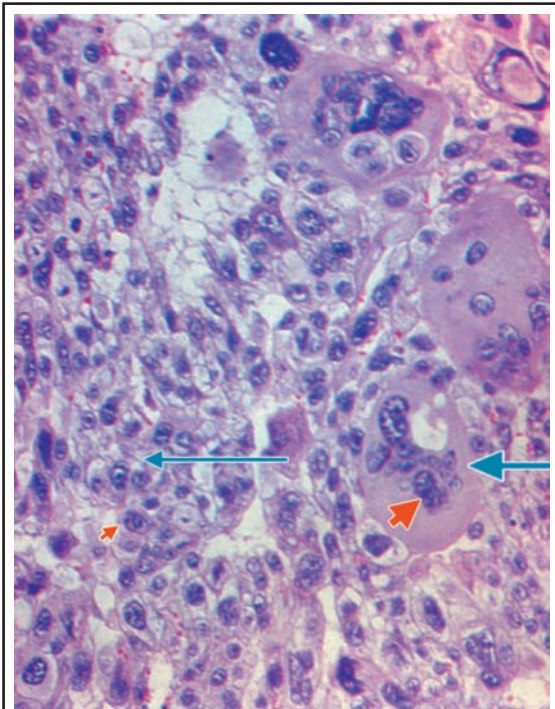
**Vaginal:** Irregular and at times brisk hemorrhage.

**Cerebral:** Headache, convulsion, paralysis or coma.

**Liver:** Epigastric pain, jaundice.

**Signs:**

- Patient looks ill.
- Pallor of varying degrees.



**Fig. 23.15:** Histologic picture of choriocarcinoma. The cytotrophoblast cells are well-defined with clear cytoplasm (thin arrow). The syncytiotrophoblast cells are arranged in sheets of multi-nucleated cytoplasm (thick arrow)

Physical signs are evident according to the organ involved.

**Bimanual examination reveals** subinvolution of the uterus. There may be a purplish red nodule in the lower-third of the anterior vaginal wall (Fig. 23.16). Unilateral or bilateral enlarged ovaries may be palpable through lateral fornices.

**SPECIAL INVESTIGATIONS:** The methods extended are not only to establish the diagnosis but also to note the metastatic sites which help in staging.

#### Diagnostic criteria for post-molar GTN (FIGO)

Levels of serum  $\beta$ hCG are followed up.

1.  $\geq$  Four values of plateaued hCG ( $\pm$  10%) over at least 3 weeks time.
2. A rise of hCG of  $>$  10% for  $>$  3 values over at least 2 weeks time.
3. Histologic diagnosis of choriocarcinoma.
4. Persistence of hCG beyond 6 months of mole evacuation.

Metastatic brain lesion is suspected when the ratio of hCG in spinal fluid/in serum is more than 1 : 60.

**Chest X-ray:** X-ray shows ‘cannon ball’ shadow or ‘snow storm’ appearance due to numerous tumor emboli (Fig. 23.17). Pleural effusion may be present.

**Pelvic sonography:** Sonography helps not only to localize the lesion but to differentiate GTN from a normal pregnancy.

**Diagnostic uterine curettage:** Pretherapy D and C reduces the intrauterine tumor bulk. However, routine D and C for histologic diagnosis is not required. It reveals the characteristic histological pattern. It is emphasized that, the curetted material may not reveal the diagnosis in all the cases, as the lesion may be deep in the myometrium or the uterus may not be the primary site. One should be very careful and alert while doing uterine curettage as brisk hemorrhage may occur for which a life saving hysterectomy may have to be done.

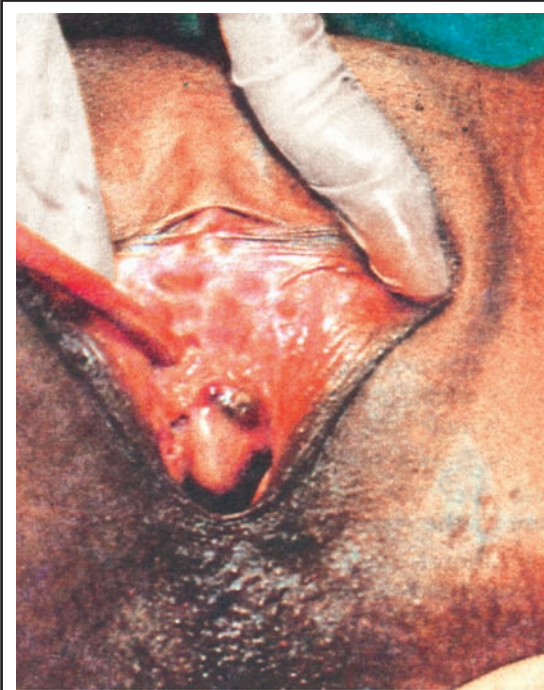#### For Diagnosis of Metastases

##### Vaginal nodules

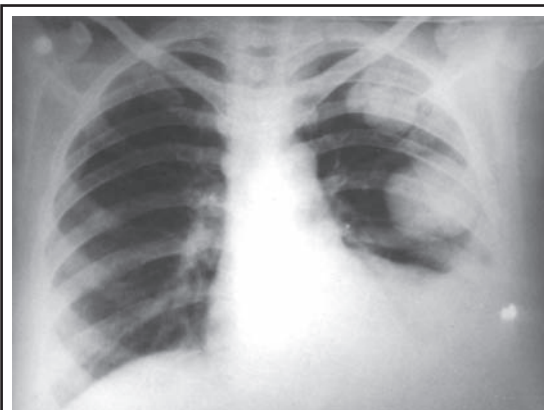
Excision biopsy or biopsy should not be done. Massive hemorrhage following resection may need packing or selective embolization.

**Cerebral:**

- The ratio of hCG levels in spinal fluid and serum is higher than 60.
- CT scan or MRI.



**Fig. 23.16:** Note the purplish red metastatic nodule in the lower third of anterior vaginal wall (sub-urethral). Metastases may occur in vaginal fornices also



**Fig. 23.17:** Cannon ball shadow in the left apical and mid region of the lung with pleural effusion in choriocarcinoma [By courtesy — Eden Hospital, MCH, Kolkata]

**Liver:**

- CT scan; Ultrasonography.

**Chest:**

- X-ray (metastasis); CT may show micro-metastases which are not visible on a chest radiograph.

Metastases to other sites are uncommon when pelvic examination and chest X-ray are normal.

#### WHO PROGNOSTIC SCORING SYSTEM OF GESTATIONAL TROPHOBLASTIC DISEASE AS MODIFIED BY FIGO (2000)

PARAMETER	SCORE			
	0	1	2	4
Age (years)	< 40	> 40	—	—
Antecedent pregnancy	Mole	Abortion	Term	—
Interval (month) <sup>‡</sup>	< 4	4–6	7–12	≥ 13
Pretreatment hCG (IU/L)	< 10 <sup>3</sup>	10 <sup>3</sup> –10 <sup>4</sup>	10 <sup>4</sup> –10 <sup>5</sup>	> 10 <sup>5</sup>
Largest tumor (cm)	< 3	3–5	> 5	—
Site of metastases	Lung Pelvis	Spleen Kidney	GI tract Liver	Brain
No. of metastases detected	—	1–4	5–8	> 8
Prior chemotherapy	—	—	Single drug	Multiple drugs

**Total score:** < 6 is low risk and a total score ≥ 7 is high risk.  
<sup>‡</sup> **Interval:** Time between antecedent pregnancy and start of chemotherapy.

**Staging:** The anatomic staging for gestational trophoblastic tumors (GTT) as described by FIGO is tabulated below:

#### FIGO ANATOMIC STAGING FOR GTT

<b>Stage I</b>	The lesion is confined to the uterus.
<b>Stage II</b>	The lesion spreads outside the uterus but is confined to the genital organs.
<b>Stage III</b>	The lesion metastasizes to the lungs.
<b>Stage IV</b>	The lesion metastasizes to sites such as brain, liver or gastrointestinal tract.

**The drawbacks of the anatomic staging are:**

- ◆ As the site of lesion cannot be located precisely, even though hCG is elevated, it is not logical to categorize the lesion to be as stage I.
- ◆ It does not help in treatment.
- ◆ The prognosis is poorly correlated.

**MANAGEMENT OF GTN****◆ Preventive ◆ Curative****■ PREVENTIVE**

**I Prophylactic chemotherapy** in 'at risk' women following evacuation of molar pregnancy may be considered. It prevents uterine invasion or metastasis. 'At risk' women are:

- Age of patient > 35 years.
- Initial levels of serum hCG  $\geq 100,000$  IU/mL.
- hCG level fails to become normal by 7–9 weeks time or there is re-elevation.
- Histologically diagnosed as infiltrative mole.
- Evidence of metastases irrespective of the level of hCG.
- Previous history of a molar pregnancy.
- Woman who is unreliable for follow up.

**Disadvantage** of routine chemotherapy is unnecessary exposure of the toxic drugs to all women who may not need it. Majority (80–90%) of women do not develop persistent GTN.

**I Meticulous follow up** following evacuation of hydatidiform mole is essential for at least 6 months to detect early evidence of trophoblastic reactivation. **A single agent chemotherapy is highly effective in non-metastatic and low-risk metastatic GTN.**

**I Selective hysterectomy** in hydatidiform mole over 35 years. There is 4 fold reduction in the risks of choriocarcinoma.

**I Diagnostic uterine curettage** in unexplained abnormal bleeding, 8 weeks following term delivery or abortion.

**I** In suspected cases, serum hCG is to be determined.

**■ CURATIVE****◆ Chemotherapy ◆ Surgery ◆ Radiation**

**Chemotherapy:** The advent of chemotherapy has revolutionized the treatment of both the non-metastatic and metastatic lesion of choriocarcinoma. Chemotherapy is now the mainstay in the treatment.

Whether a single agent (Table 23.19) or multidrug regimen (Tables 23.20 and 23.21) is to be used, depends on the risk factors present. **In general, patients with non-metastatic (low risk) and good prognosis disease are treated effectively with single agent therapy (Methotrexate or Actinomycin). The patients with poor prognosis metastatic disease should be treated with combination drug regimen (EMACO regimen).**

Whatever drugs are used, the basic formalities are to be followed as tabulated in Table 23.18.

**TABLE 23.18** FORMALITIES TO BE FOLLOWED DURING THERAPY

Blood counts Liver function Kidney function	} Daily
X-ray chest	
Serum/urine hCG	Weekly

- ◆ Treatment course should not be repeated if:
  - WBC < 3000 cu mm
  - Polymorphonuclear leucocytes < 1500 cu mm
  - Platelet counts < 100,000 cu mm
  - Significant elevation of BUN, SGPT
- ◆ Continue treatment at 1–3 weekly interval until three consecutive negative weekly hCG titers.

• **Management of GTN** needs thorough assessment of the extent of the disease. **Chemotherapy regimen is decided** on the consideration of anatomic staging (p. 364), risk factor assessment (p. 360) and WHO prognostic scoring (p. 364).

MANAGEMENT OF GTN	
<b>A. Stage I</b> Low risk GTN	<ul style="list-style-type: none"> <li>Single agent chemotherapy.</li> </ul>
High risk or Resistant	<ul style="list-style-type: none"> <li>Combination therapy</li> <li>Family completed → hysterectomy.</li> </ul>
<b>B. Stage II and III</b> Low risk GTN	<ul style="list-style-type: none"> <li>Single agent chemotherapy.</li> <li>Hysterectomy (family completed) to reduce tumor mass.</li> </ul>
High risk or Resistant	<ul style="list-style-type: none"> <li>Combination therapy</li> <li>Hysterectomy — to reduce (trophoblastic) tumor mass.</li> </ul>
<b>C. Stage IV</b>	<ul style="list-style-type: none"> <li>Combination chemotherapy.</li> <li>Surgery (hepatic resection, craniotomy).</li> <li>Radiation (cerebral metastasis).</li> </ul>

TABLE 23.19 SINGLE DRUG REGIMEN IN LOW-RISK CASES			
Methotrexate	1–1.5 mg/kg	IM/IV	Days 1, 3, 5 and 7
Folinic acid	0.1–0.15 mg/kg	IM	Days 2, 4, 6 and 8

**The courses are to be repeated at interval of 7 days**

TABLE 23.20 MAC PROTOCOL IN LOW-RISK CASES			
Methotrexate	1–1.5 mg/kg	IM/IV	Days 1, 3, 5 and 7
Folinic acid	0.1–0.15 mg/kg	IM	Days 2, 4, 6 and 8
Actinomycin D	12 µg/kg	IV	Days 1–5
Cyclophosphamide	3 mg/kg	IV	Days 1–5

**The courses are to be repeated at interval of 2 weeks**

In poor prognosis metastatic disease, best results are obtained with EMA-CO protocol (Table 23.21).

TABLE 23.21 EMA-CO PROTOCOL IN POOR PROGNOSIS METASTATIC DISEASE		
	Drug	Dose
<b>Day 1</b>	Etoposide	100 mg/m <sup>2</sup> in 200 mL saline infused over 30 minutes
	Actinomycin D	0.5 mg IV bolus
<b>Day 1</b>	Methotrexate	100 mg/m <sup>2</sup> bolus followed by 200 mg/m <sup>2</sup> IV infusion over 12 hours
	Etoposide	100 mg/m <sup>2</sup> in 200 mL saline infused over 30 minutes
	Actinomycin D	0.5 mg IV bolus
<b>Day 2</b>	Folinic acid	15 mg IM every 12 hours for 4 doses beginning 24 hours after starting methotrexate
	Cyclophosphamide	600 mg/m <sup>2</sup> IV in saline over 30 minutes
<b>Day 8</b>	Vincristine (oncovin)	1 mg/m <sup>2</sup> IV bolus

**The course will restart after 7–14 days, if possible. Generally 2 additional courses are given after the hCG levels become normal.**

### SURVEILLANCE DURING AND AFTER THERAPY OF GTN

Serum hCG value monitoring every week → once negative → every 2 weeks for 3 months → every month for 1 year → every 6–12 months for life or at least 3–5 years.

- ◆ **Remission:** 3 consecutive normal weekly hCG values.
- ◆ **Response:** > 10% decline in hCG during one cycle treatment.
- ◆ **Plateau:** ± 10% change in hCG during one cycle.
- ◆ **Resistance:** 10% rise in hCG during one cycle or plateau for two cycles of chemotherapy.

**Place of Hysterectomy:** Primary hysterectomy has got a limited place. Chemotherapy alone is successful in curing 85 percent of patients with non-metastatic and good prognosis metastatic GTN.



In patients with non-metastatic or good prognosis metastatic disease, **hysterectomy decreases the number of courses of chemotherapy.**

#### INDICATIONS OF HYSTERECTOMY

- ❖ Lesions confined to the uterus in women aged > 35 years, not desirous of fertility
- ❖ Placental site trophoblastic tumor
- ❖ Intractable vaginal bleeding
- ❖ Localized uterine lesion resistant to chemotherapy
- ❖ Accidental uterine perforation during uterine curettage.

It is preferable to start chemotherapy → surgery on day 3 → followed by chemotherapy as per schedule.

#### Type of Surgery

- ◆ Total hysterectomy is enough. The ovaries are usually not involved and if involved, can be effectively cured with postoperative chemotherapy.
- ◆ Lung resection (thoracotomy) in pulmonary metastasis in drug resistant cases.
- ◆ Craniotomy for control of bleeding.

**Radiation:** Patients with brain metastases require whole-brain radiation therapy (3000 cGy over 10 days). Intrathecal high dose methotrexate may be administered to prevent hemorrhage and for tumor shrinkage.

**Liver metastasis:** Interventional radiology (hepatic artery ligation or embolization) or whole liver radiation (2000 cGy over 10 days) along with chemotherapy may be effective. Hepatic metastasis has a poor prognosis.

**Transplacental metastases to the fetus** is rare and the prognosis is poor.

**Prognosis:** The cure rate is almost 100 percent in low risk and about 70 percent in high risk metastatic groups.

**Recurrences:** For non-metastatic GTN : 2–3 percent; ‘Good prognosis’ metastatic disease : 3–5 percent and ‘Poor prognosis’ disease : 21 percent. Recurrence following 12 months of normal hCG level is < 1 percent.

#### Prevention of Recurrent Disease

Additional cycle of chemotherapy following normalization of hCG level, should be given as follows : For non-metastatic disease — one cycle; for good prognosis metastatic disease — two cycles; for poor prognosis metastatic disease — three cycles.

**Future childbirth:** There is no adverse effect on the subsequent pregnancy provided the conception occurs after 1 year of completion of chemotherapy. **Pregnancy** should be confirmed by USG early and hCG level is to be measured 6 weeks after delivery to exclude persistent GTN. Incidence of placenta accreta is increased.

**Follow up** is mandatory for all patients at least for 2 years. Serum hCG is measured weekly until it is negative for three consecutive weeks. Thereafter it is measured monthly for 6 months and 6 monthly thereafter for life. Increased risk for the development of secondary malignancies after treatment with multiple agent chemotherapy has been observed.

## SARCOMA UTERUS

**Incidence:** Sarcoma of the uterus is rare and constitutes about 3 percent of uterine malignancy.

#### CLASSIFICATION OF UTERINE SARCOMAS (GYNECOLOGIC ONCOLOGY GROUP)

- ◆ Leiomyosarcomas
- ◆ Endometrial stromal sarcomas
- ◆ Malignant mixed müllerian tumor (homologous and heterologous)
- ◆ Other uterine sarcomas.

The commonest one arises from the intramural part. The consistency is soft and friable. The cut surface shows hemorrhage and irregular margins. There is no whorl appearance nor any capsule. *Tumors with more than 10 mitotic figures/10 high-power field have poor prognosis.*

**Endometrial stromal tumors** arises from endometrial stromal cells. **Depending on mitotic activity endometrial stromal tumors are of three types:** (i) endometrial stromal nodule (mostly benign), (ii) endolymphatic stromal myosis (low grade malignancy) and (iii) endometrial stromal sarcoma (high grade malignancy).

**Leiomyosarcomas** are of different clinicopathologic types. **Intravenous leiomyomatosis** — where benign smooth muscle grows into venous channels within the broad ligaments, uterine and iliac veins. Prognosis following surgery is excellent.

**Leiomyomatosis peritonealis disseminata** – where benign smooth muscle nodules grow over the peritoneal surfaces. It is thought to arise from the metaplasia of subperitoneal mesenchymal stem cells to smooth muscle, fibroblasts, myofibroblasts under the influence of estrogen and progesterone.

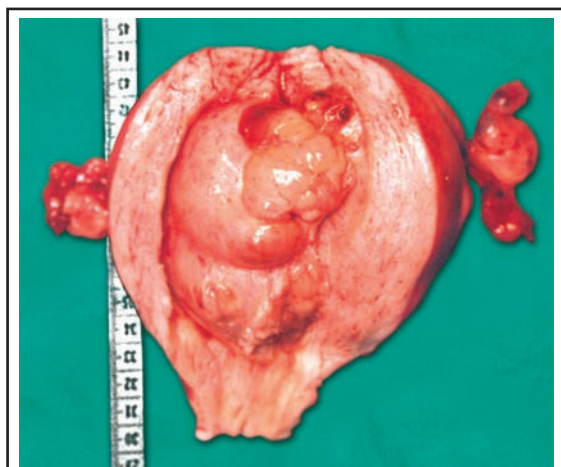**Sarcomatous change of fibroid** occurs in about 0.1 percent cases. When it does, the fibroid becomes soft. The cut section shows yellowish appearance with hemorrhage and cystic degeneration. **The whorl appearance is lost (Fig. 23.18).**

**Malignant mixed müllerian tumors (MMMT)** of the uterus usually forms a large fleshy mass protruding into the uterine cavity with a broad base. Majority (90%) presents with postmenopausal bleeding.

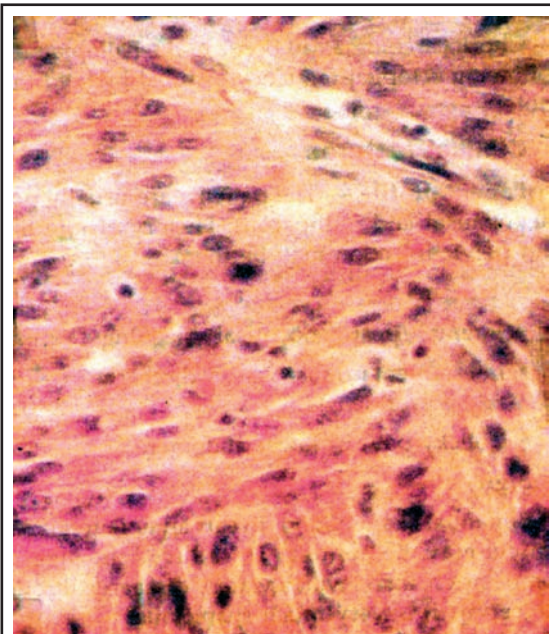
**Microscopic appearance:** Uterine sarcomas may be pure (single cell type) or mixed (more than one cell type). The tumor is termed *homologous* when the tissue elements are native (smooth muscle) or *heterologous* when tissue elements are not native (cartilage, striated muscle, bones). This is due to the totipotent nature of endometrial stromal cells.

Histologically, three types of cells are seen — spindle, round or combination of the two along with giant cells. **The commonest is spindle cell type (Fig. 23.19).**

Malignant mixed müllerian tumor is evidenced by presence of **both the structures of sarcoma and carcinoma (carcinosarcoma).**



**Fig. 23.18:** Endometrial stromal sarcoma of uterus



**Fig. 23.19:** Microscopic picture of leiomyosarcoma showing large spindle-shaped cells with pleomorphic nuclei. There is moderate cellular atypia

### SPREAD

- ◆ Blood borne: This is the commonest mode of spread. The organs involved are liver, lungs, kidneys, brain, bones, etc.
- ◆ Directly to the adjacent structures.
- ◆ Lymphatic spread to the regional lymph glands.

### CLINICAL FEATURES

**Patient profile:** The age is usually between 40 and 60 years. There may be history of pelvic irradiation either for induction of menopause or malignancy.

**Symptoms:** There is no specific symptom.

- ◆ Irregular premenopausal or postmenopausal vaginal bleeding.
- ◆ Abnormal vaginal discharge — offensive, watery associated at times with expulsion of fleshy necrotic mass.
- ◆ Abdominal pain — due to involvement of the surrounding structures.
- ◆ Pyrexia, weakness and anorexia.

**Suspected sarcomatous change in a fibroid is evidenced by:**

- ◆ Postmenopausal bleeding.
- ◆ Rapid enlargement of fibroid.
- ◆ Recurrence following myomectomy or polypectomy.

**Pelvic examination:** There is no specific finding. The uterus may be enlarged and irregular. Parametrium may be thickened and indurated.

Speculum examination may reveal a polypoidal mass protruding out through the external os.

**DIAGNOSIS**

- Diagnosis is made usually following histological examination of the removed uterus.
- Diagnostic uterine curettage may reveal the mucosal form of sarcoma.
- Histologic examination of the removed polyp.

**TREATMENT**

Total hysterectomy with bilateral salpingo-oophorectomy is to be done. This should be followed by external pelvic radiation.

**Leiomyomatosis Peritonealis Disseminata**

Total abdominal hysterectomy, bilateral salpingo-oophorectomy, omentectomy and excision of gross disease should be done. Overall prognosis is satisfactory.

- ◆ If the cervix is also involved, radical hysterectomy should be done.
- ◆ **Radiation therapy** (adjuvant) preoperative or postoperative is helpful to decrease the pelvic recurrence in endometrial stromal sarcoma and MMMT.
- ◆ **Several chemotherapeutic agents** have been tried in cases with metastatic disease. Doxorubicin, dimethyl-triazeno-imidazole carboxamide (DTIC), cisplatin gemcitabine, docetaxel and ifosfamide are the drugs used either singly or in combination with varying response.
- ◆ Watchful expectancy may be extended in cases of sarcoma detected accidentally from the well-encapsulated fibroid following myomectomy.

**PROGNOSIS**

The prognosis is unsatisfactory. The 5-year survival rate ranges from 10–30 percent. Sarcoma in fibroid has got a better prognosis.

## SARCOMA BOTRYOIDES (Embryonal Rhabdomyosarcoma)

This is special type of mixed mesodermal tumor (rhabdomyosarcoma) commonly arising from the cervix and sometimes from the vagina or the uterus. It may affect both the adult and the child (usually before the age of 8).

**CLINICAL FEATURES**

**The presenting features are:**

- ◆ Blood stained watery vaginal discharge
- ◆ Anemia and cachexia
- ◆ Vaginal examination reveals pinkish, grape-like polypoidal soft growth arising from the cervix. It may often fill up the whole vagina.

**Diagnosis is confirmed** by histologic appearances of loose myxomatous stroma, pleomorphic malignant cells with occasional striated rhabdomyoblasts.

**TREATMENT:** Intravenous administration of VAC therapy (vincristine, actinomycin-D, cyclophosphamide) and radiation has been found very much effective. The drugs should be administered every 3 weeks over a period of 6 months. Chemotherapy with local resection of the disease gives better result. Radiation therapy may be needed. The results of multimodality approach are better.

**PROGNOSIS:** Local recurrence and distant metastases are common. Prognosis is poor.

## CARCINOMA FALLOPIAN TUBE

### ■ Primary ■ Secondary

**PRIMARY**

Primary carcinoma of the fallopian tube is very rare. The incidence of tubal carcinoma is less than 0.5 percent of gynecological malignancies.

**Predisposing factors are:** Infertility, nulliparity and family history of ovarian cancer. Women with BRCA1 or BRCA2 mutations are at high risk.

**PATHOLOGY:** The site is usually in the ampullary part and the mucosa is commonly affected. The fimbrial end usually gets blocked resulting in hydrosalpinx or hematosalpinx (Fig. 37.57). It is mostly unilateral (80%).

**Microscopic appearance:** It is mostly adenocarcinoma (papillary serous) 90%.

**SPREAD:** Apart from direct spread, the lymphatic spread to the regional lymph glands (para-aortic) usually occurs. Blood borne spread to distant organs can occur in late stages.

Choriocarcinoma can occur in the fallopian tube following ectopic pregnancy or tubal hydatidiform mole.

**CLINICAL FEATURES: Patient profile** — The patients are usually post-menopausal and nulliparous. History of infertility and pelvic infection may be there.

#### Symptoms

- ◆ Vaginal (postmenopausal) bleeding.
- ◆ Intermittent profuse watery discharge (hydrops tubae profluens).
- ◆ Colicky pain in lower abdomen.

**Signs:** Bimanual examination reveals a unilateral mass which may be tender. If reduced in size on compression, along with a watery discharge through the cervix, it is very much suspicious.

#### DIAGNOSIS

- ◆ Most often accidentally discovered on laparotomy and histologic examination of the excised tube.
- ◆ Clinical features — as mentioned earlier.
- ◆ Suspected features are:
  - Persistent postmenopausal bleeding with uterine pathology being excluded by curettage.
  - Persistent positive Papanicolaou smear with a negative cervical and endometrial pathology.
  - Serum CA 125 is elevated in most cases (85%).
- ◆ Laparoscopy: In cases of persistent postmenopausal bleeding with a negative uterine pathology.
- ◆ Ultrasound can help in the preoperative diagnosis. A fluid filled sausage shaped mass separate from the uterus and ovary is seen. Ascites may be present.

#### TREATMENT

**Prophylactic surgery** in high risk cases needs bilateral salpingo-oophorectomy once child bearing is completed.

**Actual Treatment:** Total hysterectomy with bilateral salpingo-oophorectomy along with omentectomy. This should be followed by **platinum based combination chemotherapy** as an adjuvant therapy. In advanced cases, radiotherapy is considered (see ch. 30).

**PROGNOSIS:** The prognosis is unfavorable mostly due to late diagnosis. The 5-year survival rate ranges between 25 and 40 percent.

#### SECONDARY

This is more common (90%) than the primary. **The common primary sites are** ovary, uterus, breast and gastrointestinal tract.

The mode of spread from the ovary or uterus is probably by lymphatics rather than a direct one.

### MALIGNANT OVARIAN TUMORS

**INCIDENCE:** Ovarian malignancy constitutes about 15–20 percent of genital malignancy. It is more prevalent in USA and Scandinavian countries but much less in Oriental or Latin American and Asian countries including Japan and India. Approximately, 1 in every 70 newborn females in the United States will live to develop ovarian cancer. Twenty percent of ovarian neoplasms are malignant. **It is more common amongst nulliparous.** It is the fourth most common cause of cancer deaths in women exceeded only by breast, colon and lung malignancies.

#### INCIDENCE AND DEATH RATE OF OVARIAN CANCER FOR DIFFERENT COUNTRIES

Countries per 100,000	Incidence per 100,000	Death rate
Sweden	14.9	12.9
Norway	14.2	9.5
US (Whites)	13.3	7.3
UK	11.1	9.1
India	4.6	
Japan	2.7	2.1

## EPIDEMIOLOGY

Highest incidence is recorded in the industrialized countries (Sweden, USA and UK). There is significant reduction in the risk with increasing parity. Nulligravidas carry a higher risk for ovarian malignancy. **Incessant ovulation theory** (Fathalla, 1971) suggests repeated ovulatory trauma to the ovarian epithelial lining is a promoting factor for carcinogenesis. Combined oral contraceptive pills reduce the risk significantly as also repeated pregnancies. The role of ovulation inducing drugs is yet uncertain. Use of coffee, tobacco, alcohol and dietary fat has been implicated. Association of ovarian cancer with talc and asbestos has also been mentioned. Breastfeeding, tubal ligation and hysterectomy have been associated with reduction in the risk.

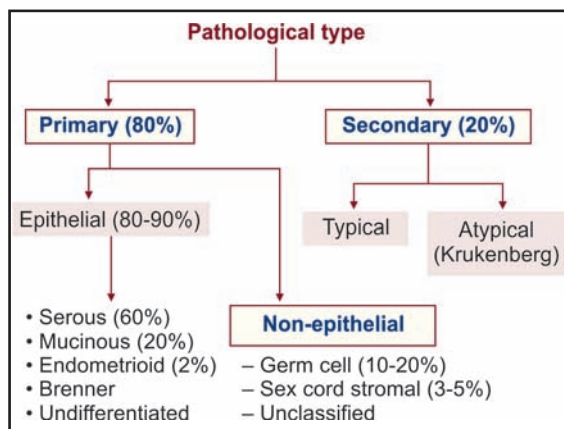
## GENETICS AND OVARIAN MALIGNANCY

### Hereditary ovarian cancer occurs in two forms:

- (i) **Hereditary breast ovarian cancer syndrome (BOC)** is observed in 80–95 percent cases of all familial ovarian cancers. BRCA1 (chromosome 17q) and BRCA2 (chromosome 13q) gene mutations are observed in majority of such cases (serous not mucinous carcinoma). These patients present at an earlier age.
- (ii) **Hereditary nonpolyposis colorectal cancer (HNPCC)**—is an autosomal dominant transmission. Women with HNPCC (Lynch II syndrome) have life time risk of about 50% for endometrial cancer and 12% for ovarian cancer. The risks of other cancers like genitourinary in addition to HNPCC are high. It is due to mutations in three DNA mismatch repair genes (MLH1, MSH2 and MSH6).

However, majority of epithelial ovarian cancers are not familial or hereditary. **Familial cancer account for less than 10 percent of all ovarian cancers (p. 520).**

## PATHOLOGY OF OVARIAN MALIGNANCY



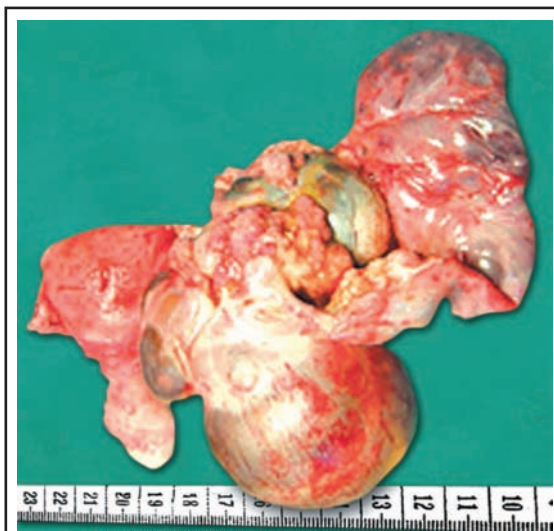
**General considerations: Malignant epithelial tumors constitute about 90 percent of all primary ovarian carcinomas.** The nonepithelial malignant tumors such as gonadal stromal or germ cell tumors are indeed rare, present special problems in extremes of age and are of pathologist's curiosity. These will be dealt separately. **Thus, in the discussion to follow, only the malignant epithelial tumors will be described.**

**Primary epithelial:** Malignant epithelial tumors include both cystic and solid types. **These are bilateral in about 50 percent** (Fig. 23.24). Cystic is more common than solid. These may arise *de novo* as malignant or more commonly, they result from malignant changes of benign cystic tumors.

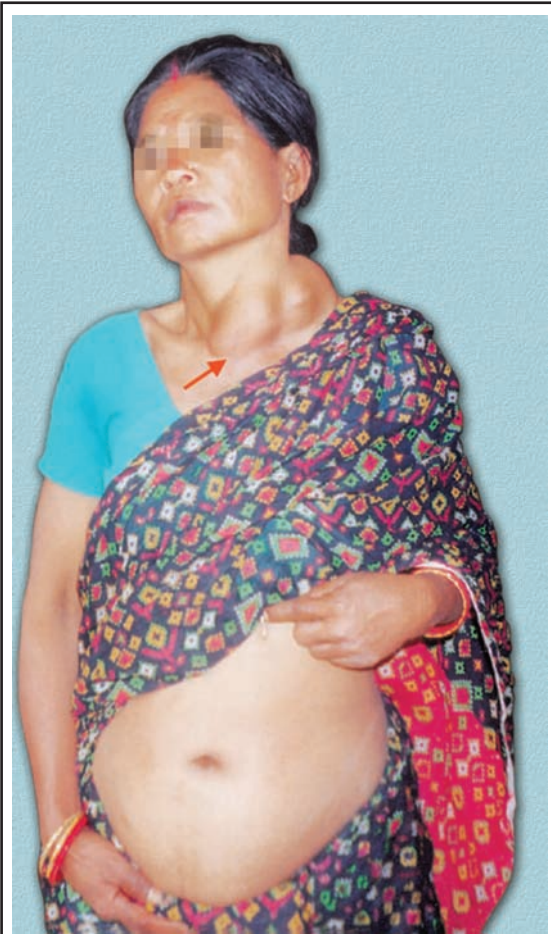Endometrioid carcinoma is associated with endometrial carcinoma in 20 percent and ovarian endometriosis in 10 percent cases. In less than 5 percent, it may arise from the endometrial cyst.

## CYSTIC

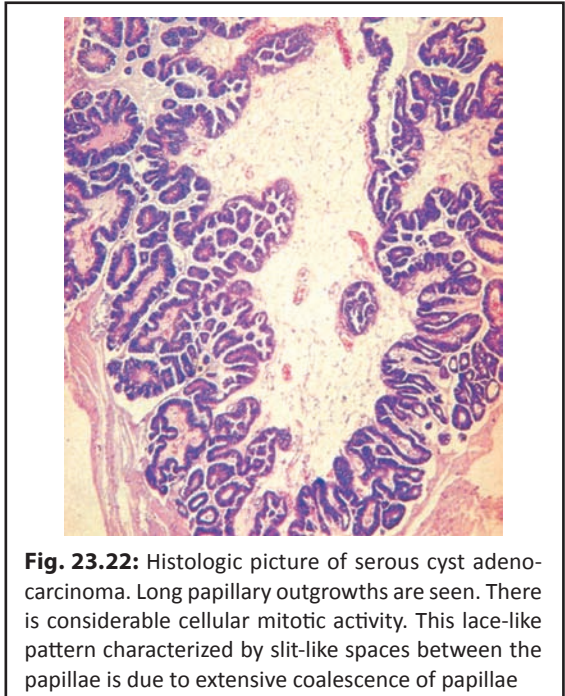
**Naked eye appearances:** The wall of the cystic tumor becomes shaggy. There may be papillary projection at places. Cut section shows solid areas with hemorrhage at places. The papillae become friable, the base becomes broad and indurated. In mucinous type, it is filled up with gelatinous material (Fig. 23.20).



**Fig. 23.20:** Cut section of a mucinous cyst adenocarcinoma. The tumor was multilocular with polypoid growths



**Fig. 23.21:** Case of advanced ovarian malignancy with enlarged left supraclavicular glands (Virchow's gland) [By courtesy — Dr A Halder, Asst. Professor, Dept. G and O, NBMC and H, Sushrutnagar, Darjeeling]



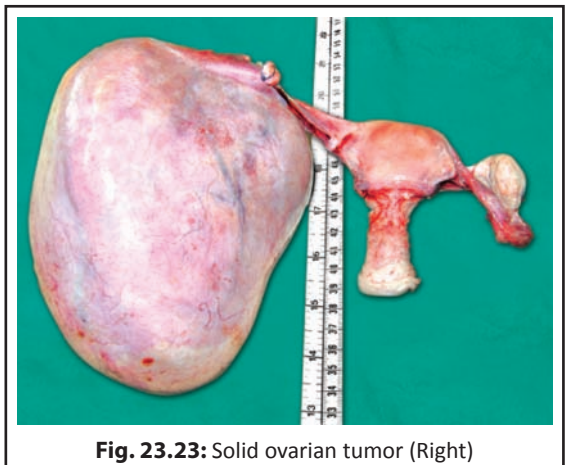
**Fig. 23.22:** Histologic picture of serous cyst adenocarcinoma. Long papillary outgrowths are seen. There is considerable cellular mitotic activity. This lace-like pattern characterized by slit-like spaces between the papillae is due to extensive coalescence of papillae

**Solid (Fig. 23.23):** It attains a moderate size. The external surface is smooth and often lobulated. Subserous blood vessels may be prominent. Cut section shows greyish granular appearance, at times brain-like. There may be irregular cystic spaces due to necrosis.

Microscopic appearance reveals adenocarcinoma or carcinoma without adenomatous pattern.

**Microscopic picture:** The histologic appearance in each type is tabulated in Table 23.22.

TABLE 23.22	
Type of tumor	Histologic picture
Serous cyst carcinoma	Adenocarcinoma
Mucinous cyst carcinoma	Adenocarcinoma (Fig.23.22)
Malignant dermoid	Squamous cell carcinoma
Endometrioid or adenoacanthoma	Adenocarcinoma



**Fig. 23.23:** Solid ovarian tumor (Right)

## FIGO STAGING OF CARCINOMA OVARY

The staging aims at:

- ◆ Better choice of adjuvant therapy
- ◆ Better assessment of prognosis

The staging is done following laparotomy (staging laparotomy) and is followed as per FIGO-1988 (Table 23.24).

**SPREAD: Natural path of spread:** The tumors spread along the peritoneal surface to involve ovarian, parietal and intestinal peritoneal surfaces as well as the undersurface of the diaphragm, particularly on the right side. **The modes of spread are:**

- Transcoelomic
- Lymphatic
- Direct
- Hematogenous

**Transcoelomic:** Implantation of malignant cells occurs by:

- ◆ Direct exfoliation of cells as in papillary cyst adenocarcinoma.
- ◆ Penetration of tumor capsule.
- ◆ Rupture of the capsule.

The exfoliated cells in the peritoneal fluid flow along the paracolic gutters.

Multiple secondary deposits are formed on the peritoneal surfaces specially in the pouch of Douglas, in the omentum, diaphragm, retroperitoneal nodes and serous surfaces of the abdominopelvic organs.

### Lymphatics

The lymphatic spread is to the draining lymph nodes namely paraaortic and superior gastric nodes. The pelvic nodes may be involved through peritoneal permeation into the subperitoneal lymphatics (Table 23.23). **The left supraclavicular nodes are enlarged due to** obstruction of the efferent lymphatic channel of the nodes by the tumor emboli, as it enters the thoracic duct just prior to its drainage into the left subclavian vein (Fig. 23.22).

Stage	Paraaortic (%)	Pelvic (%)
I and II	20	30
III and IV	65	67

Lateral lymphatic spread through the broad ligament to the pelvic nodes may occur. Retrograde lymphatic spread in advanced disease may occur to the inguinal nodes through the round ligament.

**Direct:** After the capsule is broken, the spread occurs directly to the adjacent organs such as tubes, broad ligament, intestines, omentum and uterus.

**Hematogenous:** The blood stream metastasis is late and the involved organs are lungs, liver, bones, etc.

### CLINICOPATHOLOGIC EXPLANATION

**Ascites:** Ascites is due to obstruction of peritoneal fluid outflow principally through the diaphragm. There is also increased transudation of serum across the peritoneal surfaces. The secretion is not from the tumor bearing peritoneum but from the tumor-free areas.

**Liver:** The involvement of liver is usually blood borne when the guts are involved.

### Contralateral Ovary (Fig. 23.24)

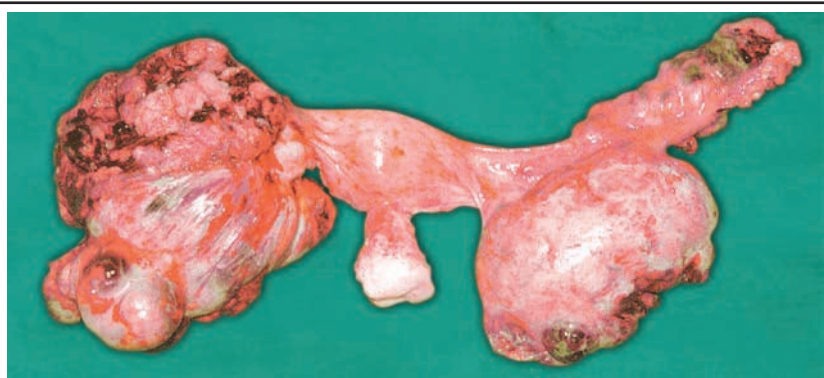The contralateral ovary is involved in majority of metastatic ovarian malignancy. Even in primary malignancy, the contralateral involvement may be due to retrograde lymphatic spread through paraaortic glands. Direct implantation or multicentric origin may also be a possibility.

**Uterus:** The body is mostly affected either due to lymphatics or through transtubal spread. The cervical involvement is rare.

**Right-sided pleural effusion:** More ascitic fluid reaches the right subdiaphragmatic space along the wider right paracolic gutter. This is facilitated by the increased negative suction created by liver during respiration. The fluid so collected can pass freely across the diaphragm. This is because of free communication of submesothelial network of lymphatic capillaries with the corresponding plexuses on the thoracic surface of the diaphragm underlying the pleura on the right side → right pleural effusion. Alternatively, there is more presence of wide pleuroperitoneal sinuses on the right side and hence producing right pleural effusion.

### CLINICAL FEATURES

**Patient profile:** Although no age is immune to ovarian malignancy, but about 60 percent of ovarian



**Fig. 23.24:** Bilateral malignant epithelial tumors of the ovary  
(By courtesy: Dr. Biswajit Ghosh, Burnpur)

neoplasms in postmenopausal and about 20 percent in premenopausal women are malignant. There is increased association of nulliparity and with a family history.

▲ **Symptoms:** In its **early stage**, ovarian carcinoma is a notoriously silent disease (asymptomatic). The

presenting complaints are usually of short duration and insidious in onset. Symptoms are not specific.

- ◆ Feeling of abdominal distension and vague discomfort.
- ◆ Features of dyspepsia such as flatulence and eructations.

#### STAGING OF CARCINOMA OF THE OVARY (FIGO – 1988)

<b>STAGE I</b>	Growth limited to the ovaries (A) Growth limited to one ovary; no ascites No tumor on the external surface; capsule intact (B) Growth limited to both ovaries; no ascites. No tumor on the external surfaces; capsule intact (C) Tumor either stage IA or IB, but tumor on surface of one or both ovaries; or with capsule ruptured; or with ascites present containing malignant cells or with positive peritoneal washings.
<b>STAGE II</b>	Growth involving one or both ovaries with pelvic extension (A) Extension and/or metastases to the uterus and/or tubes (B) Extension to other pelvic tissues (C) Tumor either Stage IIA or IIB, but tumor on surface on one or both ovaries; or with capsule(s) ruptured or with <b>ascites</b> present containing malignant cells or with positive peritoneal washings.
<b>STAGE III</b>	Tumor involving one or both ovaries with peritoneal implants outside the pelvis and/or positive retroperitoneal or inguinal lymph nodes. Superficial liver metastasis equals stage III. Tumor is limited to the true pelvis but with histologically proven malignant extension to small bowel or omentum. (A) Tumor grossly limited to the true pelvis with <b>negative nodes</b> but histologically confirmed microscopic seeding of abdominal peritoneal surfaces. (B) Tumor involving one or both ovaries with histologically confirmed implants of abdominal peritoneal surfaces with none exceeding 2 cm in diameter. <b>Nodes are negative.</b> (C) Abdominal implants greater than 2 cm in diameter and/or positive retroperitoneal or inguinal nodes.
<b>STAGE IV</b>	Growth involving one or both ovaries with distant metastases. If pleural effusion is present, there must be positive cytology to allot a case to stage IV. Parenchymal liver metastasis equals stage IV.



- ◆ Loss of appetite with a sense of bloating after meals.
- ◆ In pre-existing tumor.
  - Appearance of dull aching pain and tenderness over one area.
  - Rapid enlargement of the tumor.

Gradually, more pronounced symptoms appear. These are:

- ◆ Abdominal swelling which may be rapid.
- ◆ Dull abdominal pain.
- ◆ Sudden loss of weight.
- ◆ Respiratory distress — may be mechanical due to ascites or due to pleural effusion.
- ◆ Menstrual abnormality is conspicuously absent except in functioning ovarian tumors (mentioned later in the chapter).

**Signs:** The following are the findings in an established case of ovarian malignancy.

#### ▲ General Examination Reveals

- ◆ Cachexia and pallor of varying degree.
- ◆ Jaundice may be evident in late cases.
- ◆ Left supraclavicular lymph gland (Virchow's) may be enlarged (Fig. 23.21).
- ◆ Edema leg or vulva is characteristic of malignant and not of benign neoplasm.

#### ▲ Per Abdomen

- ◆ Liver may be enlarged, firm and nodular.
- ◆ A mass is felt in the hypogastrium; too often it may be bilateral. It has got the following features:
  - Feel — solid or heterogenous.
  - Mobility — mobile or restricted.
  - Tenderness — usually present.
  - Surfaces — irregular.
  - Margins — well-defined but the lower pole is usually not reached.
  - Percussion — usually dull over the tumor; may be resonant due to overlying intestinal adhesions.

#### ▲ Per Vaginum

- ◆ The uterus may be separated from the mass felt per abdomen.

- ◆ Nodules may be felt through the posterior fornix. If it is more than 1 cm, the diagnosis of malignancy is almost certain.

#### ▼ SPECIAL INVESTIGATIONS

##### Investigation aims at:

- To confirm malignancy preoperatively.
- To identify the extent of lesion.
- To detect the primary site.

##### To Confirm Malignancy

- Cytologic examination for detection of malignant cells is carried out from the fluid collected by abdominal paracentesis or “cul-de-sac” aspiration.
- Tumor marker: In epithelial carcinoma, there is no specific tumor marker. But, elevated CA-125 level > 65 U/mL with a pelvic mass may be suggestive. Other biomarkers: HE4, CA-19-9, CA-15-3, OVXI may also be suggestive.

##### ▼ To identify the extent of lesion

- ◆ **Straight X-ray** chest to exclude pleural effusion and chest metastasis.
- ◆ **Barium enema** to detect any lower bowel malignancy.
- ◆ **Cytologic examination** of thoracentesis fluid.
- ◆ **Sonography** is of limited help but can be employed to detect involvement of the omentum or contralateral ovary.
- ◆ **Computed Tomography (CT)** is helpful for retroperitoneal lymph node assessment and detection of metastasis (liver, omentum). It helps in staging of ovarian carcinoma (see p. 662).
- ◆ **Magnetic Resonance Imaging (MRI)** is helpful to determine the nature of ovarian neoplasm and also for the retroperitoneal lymph nodes and detection of metastasis. It can also detect relapse of the tumor following initial treatment.
- ◆ **Positron Emission Tomography (PET)** can differentiate normal tissues from cancerous tissues. It is more sensitive than CT or MRI (p. 119).
- ◆ Intravenous pyelography.
- ◆ Examination under anesthesia.
- ◆ Diagnostic uterine curettage.

### To Detect the Primary Site

- ◆ Barium meal X-ray.
- ◆ Gastroscopy/colonoscopy.
- ◆ Mammography.

### DIAGNOSIS

- ◆ Clinical.
- ◆ Ancillary aids.
- ◆ Operative findings.
- ◆ Histologic confirmation.

**Clinical:** Clinical diagnosis in early stage is very much deceptive because of:

- **No age specificity:** Although more prevalent beyond the age of 45 (40% of ovarian neoplasms are malignant), no age is immune to ovarian cancer. All physicians must be aware of the possible significance of persistent gastrointestinal symptoms in women over the age of 40 with a history of ovarian dysfunction.
- **No specific symptom:** It may remain asymptomatic in about 15 percent when first diagnosed.
- **Unrelated to duration of symptoms: Even with symptoms** of short duration may have extensive spread, conversely a long-standing tumor may remain benign.
- **Unrelated to the size of the tumor:** A big tumor may remain benign for a long time whereas, a small enlarged ovary may be found malignant.

The cumulative effects of such vagaries explain the fact that at the time of diagnosis, about 70 percent of patients with epithelial carcinomas have metastases outside the pelvis. **The most common sites of metastases are—peritoneum (85%), omentum (70%), contralateral ovary (70%), liver (35%), lung (25%) and uterus (20%).**

In established and/or advanced cases of malignancy, the clinical features as mentioned earlier are enough to arrive at a diagnosis.

### Ancillary Aids

- Detection of malignant cells from the ascitic fluid collected by abdominal paracentesis or cul-de-sac aspiration is a positive proof of abdominal malignancies. When combined with presence of a pelvic mass almost confirms ovarian malignancy.

- Noninvasive methods such as MRI or CT scan have not yet proved to be much useful in diagnosis. Transvaginal sonography improves the detection rate (see p. 117).
- Examination under anesthesia may be useful in doubtful cases, specially in an obese patient.
- Laparoscopy too has got limited scope in confirmation of malignancy. It can just detect a neoplasm.
- Elevation of serum CA 125 beyond 35 U/mL may be suggestive.

### Operative Findings

- Nature of peritoneal fluid.  
While hemorrhagic fluid is very much suggestive but a clear or straw color fluid cannot rule out malignancy.
- Nature of the tumor: Differentiation between a benign and malignant tumor may be possible clinically, with laparotomy findings and with ultrasonographic criteria (see p. 294).
- Metastatic nodules on the peritoneal surfaces and omentum.

**Histological diagnosis:** All ovarian tumors irrespective of their nature must be subjected to histologic examination. This not only confirms the diagnosis but also identifies the type and grade of malignancy.

## MANAGEMENT OF EPITHELIAL OVARIAN CANCER

### ■ Preventive ■ Curative

#### PREVENTIVE

**Primary prevention:** Because of dearth about the knowledge of epidemiology of ovarian cancer, the primary prevention cannot be clearly formulated. However, the preventive measures are:

- (i) **Genetic screening for BRCA 1 and BRCA 2** for women with high risk for ovarian and breast cancer.
- (ii) **Annual mammographic screening** for women with strong family history of breast cancer.
- (iii) **Periodic screening** for other malignancies (colonoscopy, endometrial biopsy) for women with Lynch II syndrome.

- (iv) **Combined oral contraceptive pills** as a preventive measure is recommended to a woman specially belonging to Lynch type II families.
- (v) **Prophylactic oophorectomy along with hysterectomy** specially in 'high risk' women (Table 23.24) is a preventive measure against ovarian malignancy. **The cases include:**
- Nulliparous women aged > 45 years.
  - A woman of any age who has a history of ovarian, endometrial or colonic carcinoma in first degree relative (mother and sister).
  - Grossly abnormal ovary in premenopausal group (ovarian volume > 20 cm<sup>3</sup>).
  - Woman who had one ovary removed for benign neoplasm.
  - Previous history of breast carcinoma.
  - Any woman with radiation induced menopause.

### Guidelines for Management of an Enlarged Ovary

- An ovarian enlargement of  $\geq 8$  cm during childbearing period deserves careful follow up.
- In postmenopausal women, any ovarian enlargement should be assessed by serum CA-125 and transvaginal sonography.
- Cysts that are simple, unilocular,  $\leq 8$  cm in diameter with normal serum CA-125 — can be managed conservatively. Women should be under follow up with ultrasound scan and serum CA-125 at an interval of 4 months.
- Early laparotomy is indicated in following cases:
  - The ovary enlarges progressively beyond 8 cm while under observation.
  - Any symptomatic ovarian tumor regardless of size.

### Secondary Prevention (Screening for Ovarian Cancer)

Natural history of the disease is not well understood. There is no preinvasive stage like that of cervical intraepithelial neoplasia. As such, screening aims at detecting early ovarian malignancy in asymptomatic women. Till date no specific method of screening for early detection of epithelial ovarian cancer is available.

### Screening Procedures

▲ **Clinical:** Regular and periodic clinical examination of the 'high risk' group is done. Bimanual pelvic examination in an asymptomatic woman may detect an adnexal mass. However, clinical examination is not very specific.

▲ **Tumor markers:** CA 125 is a glycoprotein, which has been used for screening of epithelial cancers of the ovary. Value more than 35 U/mL is suggestive of epithelial ovarian cancer. It is also used for monitoring a patient during chemotherapy and for follow up. But it is not a tumorspecific antigen. There are several other conditions, where level of CA-125 is raised:

- ◆ Normal woman (1%).
- ◆ Carcinomas of the breast, lung, colon and endometrium.
- ◆ Endometriosis.
- ◆ Pelvic inflammatory disease.
- ◆ Peritonitis.

The serum level of CA-125 falls after surgical resection of the tumor or following chemotherapy. Elevated level indicates bulky residual disease or tumor recurrence or resistant clones to chemotherapy. Serum half life of CA-125 is 20 days.

Other tumor markers of value are macrophage colony-stimulating factors (M-CSF), OVXI, HER-2/neu and inhibin (see p. 521).

▲ **Ultrasound imaging:** Transvaginal color Doppler imaging has been able to differentiate benign from malignant tumors by assessment of its vascular supply and intratumoral blood flow. Increased neoangiogenesis in ovarian malignancy causes central neovascularity. Study of **vascular parameters**, e.g. Pulsatility Index (PI) < 1.0 or Resistive Index (RI) < 0.4 increases the risk of malignancy.

Recently **three dimensional**, contrast enhanced, power Doppler sonography is found to be more diagnostic.

▲ **Risk of Malignancy Index (RMI):**  $RMI = U \times M \times CA\ 125$ ; U = USG score (one point each for : multi-locular cyst; solid areas; metastasis; ascites; bilateral lesions), M = 3 (postmenopausal women) and CA-125 level in U/mL. The risk of cancer is 75% when the RMI value is > 250 (see p. 570).

### ▲ Genetic Testing (see p. 371)

**TABLE 23.24** 'HIGH RISK' WOMEN

- ◆ Age group 40–60 years
- ◆ Familial cancers : Breast, endometrial, ovarian, colorectal
- ◆ History of removal of benign ovarian tumor or breast carcinoma
- ◆ Postmenopausal palpable ovary (volume > 8 cm<sup>3</sup>)
- ◆ Relative or absolute infertility
- ◆ Dysgenetic gonad
- ◆ Fertility drugs use (incessant ovulation)
- ◆ Women workers in asbestos related industries

#### PROTECTIVE FACTORS FOR OVARIAN MALIGNANCY

- ◆ Combined oral contraceptives
- ◆ Pregnancy
- ◆ Tubal ligation, hysterectomy
- ◆ Breastfeeding

### TREATMENT OF MALIGNANT OVARIAN TUMOR

- Surgery ■ Chemotherapy
- Radiotherapy ■ Combined therapy

#### SURGICAL TREATMENT OF OVARIAN CANCER

**Surgery is the keystone in the primary treatment of ovarian malignancy.**

#### The aims are:

- To stage the disease (staging laparotomy) accurately, thereby allowing better choice of adjuvant therapy and a better assessment of prognosis.
- To perform effective surgical removal.

#### Practical Guidelines

- **Liberal vertical incision** to minimize chance of rupture of the tumor and to facilitate better exploration.
- **To note the character of the ascitic fluid**, if any, and to collect sample for cytology. If appreciable

fluid is not available, then a sample of peritoneal wash with 100 mL saline in the subdiaphragmatic area is to be collected.

- **A systematic (visual and manual) exploration** — palpation of liver, gastrointestinal tract, subdiaphragmatic area, omentum and paraaortic lymph nodes. This is done in a clockwise fashion starting from the cecum.
- **Pelvic exploration** — nature of the tumor, extent of adhesions, condition of the contralateral ovary, uterus and tubes and palpation of pelvic lymph nodes.
- **Any metastatic deposit** over the peritoneal surfaces, under surface of the diaphragm should be biopsied. Pelvic and paraaortic lymph node sampling should be done.
- **In the absence of any metastatic disease**, multiple peritoneal biopsy, scraping from the diaphragm for cytology should be taken. Occult metastasis has been found in about 10–40 percent of early stage (stage I and II) epithelial ovarian cancer.

### PRIMARY SURGERY

#### A. Early stage disease (Stage Ia, G<sub>1</sub>, G<sub>2</sub>):

- a. **Young woman** → Unilateral oophorectomy (fertility sparing surgery) → Routine follow up and monitoring → Completion of family → Removal of the uterus and the other ovary.
- b. **Elderly woman** → Hysterectomy and bilateral Salpingo-oophorectomy.
- c. **In Stage Ia, G<sub>3</sub> disease and others stage I diseases:** Staging Laparotomy → Hysterectomy and bilateral Salpingo-oophorectomy. Chemotherapy is considered for most patients.

- B. Advanced stage disease:** Exploratory Laparotomy → **Cytoreductive or debulking surgery**. This includes : Total abdominal hysterectomy bilateral salpingo-oophorectomy, complete omentectomy, retroperitoneal lymph node sampling and resection of any metastatic tumor (Fig. 37.60). **Optimum cytoreductive surgery** is aimed to reduce the residual tumor load ≤ 1–2 cm in diameter. Lesser the residual tumor volume (< 1 cm), better is the survival.

**Maximum cytoreductive surgery** may need resection of a segment of bowel, bladder or the lymph nodes. Removal of omental cake by cytoreductive surgery improves the result of subsequent chemotherapy or radiotherapy. Large tumor masses have huge number of poorly oxygenated cells in the “resting” phase (G<sub>0</sub>) (see p. 511), those are resistant to any type of therapy. Lesser the residual tumor mass (< 5 mm) higher the survival rate. Appendectomy is done in cases with mucinous ovarian cancer.

### ADJUVANT CHEMOTHERAPY

- A. In stage Ia (Grade I) epithelial carcinoma** → No adjuvant chemotherapy.
- B. In all other stage I disease** → Adjuvant chemotherapy with carboplatin and paclitaxel for six cycles.
- C. Advanced stage disease.**
- ◆ **Chemotherapy:** Chemotherapy is used widely following surgery to improve the result in terms of survival. Drugs are given for five or six cycles at 3-4 weekly interval (see p. 516).
  - ◆ **Combination chemotherapy:** Paclitaxel (175 mg/m<sup>2</sup>) and carboplatin (400 mg/m<sup>2</sup>) are commonly used (Table 23.25).

Patients who are hypersensitive to paclitaxel, topotecan 1 mg/m<sup>2</sup> for 5 days, every 3 weeks or Gemcitabine 800 mg/m<sup>2</sup>, every 3 weeks is given (p. 516).

- **Platinum compounds (cisplatin, carboplatin)** are the **most effective drugs** in terms of tumor response and survival rate (see p. 516). Like alkylating agents they cause cross linkage of DNA strands. **They can be used either singly or in combination with paclitaxel (see below).**
- **Taxane derivatives** (paclitaxel, docetaxel) are found to be very effective in ovarian cancer (see p. 517). Paclitaxel is derived from the bark of the pacific yew tree. Docetaxel is semisynthetic and its side-effects are less (peripheral neuropathy). Taxane derivatives prevent cell division by polymerization of microtubules and making them excessively stable. They are found to be effective even in cisplatin resistant ovarian cancer. **Paclitaxel is recommended as the primary**

**treatment of all epithelial ovarian cancer following optimal cytoreductive surgery.**

TABLE 23.25

#### RECOMMENDED DRUGS AND DOSES OF CHEMOTHERAPY (CP)

Drugs	Dose	Cycle	Interval
Carboplatin (CP)	400 mg/M <sup>2</sup> or AUC 5	6	3 weeks
Paclitaxel (T)	135 mg/M <sup>2</sup>	6	3 weeks

- ◆ **Combination chemotherapy:** Drugs acting in different ways on the cell cycle (see p. 513), with different toxicities, are combined. Therefore efficacy is expected to be more and chance of drug resistance is low. **Currently paclitaxel and carboplatin combination chemotherapy is found to have better survival rate in advanced ovarian cancer (Tables 23.25 and 23.26).**

Efficacy of **docetaxel** has been found similar to paclitaxel. **Gemcitabine** or **Topotecan** has got similar efficacy.

The recommended drugs and doses for chemotherapy of ovarian carcinoma (CAP and CP) are tabulated below (Table 23.26).

TABLE 23.26

#### RECOMMENDED DRUGS AND DOSES OF CHEMOTHERAPY (CAP AND CP)

Drugs	Dose	
	CAP	CP
Cyclophosphamide (C)	500 mg/m <sup>2</sup>	750–1000 mg/m <sup>2</sup>
Adriamycin (A)	50 mg/m <sup>2</sup>	
Cisplatin (P)	50 mg/m <sup>2</sup>	50–100 mg/m <sup>2</sup>

Drugs are given IV on day 1 every 4 weeks interval as toxicity permits (see ch. 30, p.516, 517)

- ◆ **Single agent:** Alkylating agents (melphalan, cyclophosphamide, ifosfamide) are commonly used (see Table 23.27).
- ◆ **Intraperitoneal chemotherapy** is used only for minimal (< 2 cm) or microscopic residual disease. The drugs can penetrate only few millimeters. Moreover, serum levels are similar to those seen after IV chemotherapy. Currently both platinum (cisplatin) and taxanes (docetaxel) are used. There

Drug	Dose	Route	Cycle	Interval
Melphalan	200 µg/kg per day for 5 days	oral	6	4 weeks
Cisplatin	75 mg/M <sup>2</sup>	IV	6	4 weeks
Carboplatin	400 mg/M <sup>2</sup>	IV	6	4 weeks
Paclitaxel	175 mg/M <sup>2</sup>	IV	6	4 weeks

is distinct benefit of intraperitoneal cisplatin and docetaxel over their intravenous use.

#### Primary chemotherapy for advanced ovarian cancer

is done either by IV (docetaxel or paclitaxel and carboplatin) or by intraperitoneal chemotherapy to improve the overall survival.

- ◆ **Neoadjuvant chemotherapy and interval cytoreductive surgery:** Few cycles of chemotherapy followed by interval primary cytoreductive surgery may be done. **Indications are :** (i) Advanced epithelial ovarian cancer, (ii) High risk for surgery, (iii) Associated comorbid conditions (pleural effusion), (iv) Predicted to be suboptimally resected. Patient should have histological diagnosis of the tumor (biopsy). **Benefits of neoadjuvant chemotherapy are :** (i) Rapid clinical improvement. (ii) Subsequent surgery is easier and morbidity is reduced, (iii) Optimum cytoreduction with minimal residual disease may be possible.
- ◆ **Radiotherapy:** There is very little scope of radiotherapy as an adjunct to surgery because of the advent of chemotherapy.
- ◆ **Radioactive isotopes (see p. 506):** In early cases of ovarian cancer, radioactive phosphorus (<sup>32</sup>P) is instilled into the peritoneal cavity. The isotopes are taken up by macrophages and the radiation effects are limited to superficial 4–6 mm of peritoneal lining. <sup>32</sup>P acts by emitting β-rays. Bowel complications are increased.
- ◆ **Hormone therapy:** Tamoxifen, leuprolide acetate (GnRH agonist), Aromatase inhibitors are being studied in relapsed cases of ovarian tumor.
- ◆ **Immunotherapy:** With the use of cytokines, interferon or interleukin-2 is under trial. Herceptin, an antibody, when used along with chemotherapy improves the response rate (see p. 519).

- ◆ **Gene and Molecular therapy** — see page 520.

#### Place of Fertility Sparing Surgery in Ovarian Malignancy

- Unilateral malignant ovarian tumor (border line/stage IA)
- Patient willing to preserve her fertility
- Patient motivated and consented for close follow up
- Contralateral ovary clinically normal

### SECONDARY SURGERY

**Secondary Cytoreductive Surgery** may be done in some selected cases where (i) There is no response or partial response to primary chemotherapy. (ii) Recurrence following primary cytoreductive surgery and chemotherapy. (iii) Following initial suboptimal debulking followed by chemotherapy and (iv) Clinically persistent tumor at second-look laparotomy.

**Second look surgery** is not a routine management. The procedure is similar to staging laparotomy. It may be done either by laparoscopy or by laparotomy. It is done in patient with no evidence of persistent tumor after an interval of chemotherapy.

The **findings** of second look surgery may be:

- (1) Negative (both clinically and microscopically)
- (2) Microscopically positive but clinically negative
- (3) Positive (both clinically and microscopically)

#### Reasons for Poor Outcome in Ovarian Cancer

- ◆ Late diagnosis (p. 373, 374)
- ◆ No preinvasive stage of the disease
- ◆ No effective screening procedure
- ◆ No correlation of symptoms with the tumor size
- ◆ Extent of tumor spread is often unknown
- ◆ Limitations of cytoreductive surgery
- ◆ Variable chemosensitivity
- ◆ Radiation dose restriction by neighboring organs
- ◆ Tumor cells are freely mobile within the peritoneal cavity

A laparoscopy prior to laparotomy is advised. Currently, CT, MRI and serum CA-125 are being evaluated as an alternative to second look laparotomy. Better survival rate following second look surgery is however questionable.

### PROGNOSTIC FACTORS IN OVARIAN MALIGNANCY

- Surgical stage of the disease — worse beyond stage II (Table 23.28).
- Histological type — endometrioid tumor has got a higher survival rate than serous type because the former tumor is highly well-differentiated.
- Histological grade of the tumor — higher the grade, poorer the prognosis.
- Peritoneal cytology — positive malignant cells, higher the risk.
- Presence of ascites — higher the risk.
- Presence of metastatic disease before cytoreductive surgery — poor the prognosis and shorter the survival.
- Volume of residual tumor after primary surgery — when < 5 mm better the prognosis.
- Ploidy status – diploid tumors are prognostically better compared to aneuploid tumors.
- Degree of oncogene expression (see p. 520 chap. 30).

**TABLE 23.28** APPROXIMATE 5 YEAR SURVIVAL

Stage	5-year survival (%)
I	75 – 90
II	60 – 70
III	20 – 40
IV	5 – 10

### PRIMARY PERITONEAL CARCINOMA

**Papillary serous carcinoma of the peritoneum** is a rare type of primary peritoneal adenocarcinoma (PPA). It constitutes 7–20% of all epithelial ovarian carcinoma.

#### Criteria for Diagnosis of PPA (GOG 1993)

- ◆ The ovaries are either absent or normal in size (< 4 cm diameter).
- ◆ Extra-ovarian sites are more involved than that of the ovarian surfaces.

- ◆ Microscopically the ovaries are either not involved or exhibit cortical implants < 5 mm in depth.
- ◆ The histologic and cytologic tumor character is serous type. FIGO staging for ovarian carcinoma is followed. Management is according to ovarian carcinoma grade and staging. Prognosis is generally poor.

### GERM CELL TUMORS OF THE OVARY

Germ cell tumors constitute about 15–20 percent of all ovarian neoplasms and they are the second common ovarian tumors. For classification see p. 291. They have got varying degrees of malignant potentiality. About 3 percent of these tumors are malignant. Germ cell tumors occur predominantly in children and young adults. They arise from embryonic germ cells.

#### DYSGERMINOMA

Dysgerminoma is the commonest (30–40%) malignant germ cell tumor. It arises from undifferentiated form of germ cells. It is often (5%) associated with dysgenetic gonad (see Ch. 27). The counterpart of dysgerminoma in male is seminoma. Majority (75%) of the tumors occur before the age of 30 years.

hCG assays are often positive, confusing the diagnosis with pregnancy. It may coexist with pregnancy (20–30%). Dysgerminoma may be associated with choriocarcinoma or endodermal sinus tumor. Tumor markers  $\alpha$ -fetoprotein (AFP) and hCG may be positive in that situation. Karyotyping is needed specially when a premenarcheal girl presents with a pelvic mass.

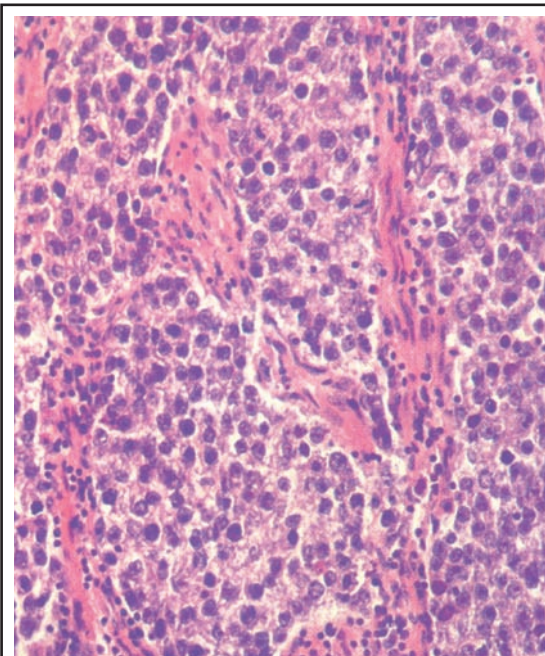
**Pathology:** The shape is usually round or oval and is usually 5–15 cm in diameter; feel is boggy, at times, it is firm rubbery. It may be bilateral (10%). Cut section shows pink or yellow color. Microscopic appearance reveals uniform large round cells (monotonous pattern), arranged in cords or clumps with abundant clear cytoplasm. Nuclei are large, irregular and hyperchromatic with varying degree of mitosis. There is intense infiltration of lymphocytes and plasma cells in the fibrous septum (Fig. 23.25). In more than 50 percent, they are potentially malignant.

Clinical features are not specific for the tumor.

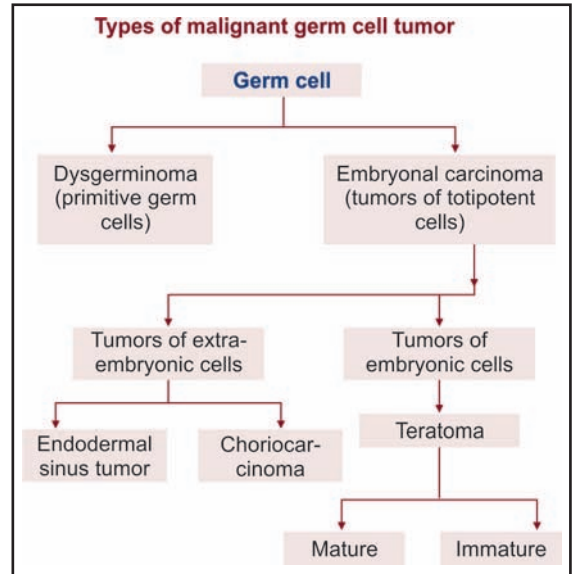
**Treatment:** Majority (75%) of dysgerminomas are confined to one ovary and are stage I at the time of diagnosis.

**In a young patient** where preservation of fertility is desired, laparotomy for surgical staging and unilateral salpingo-oophorectomy is done. If there is any suspicion of involvement to the other ovary, bisection of the contralateral ovary and excisional biopsy should be done. The tumor is sensitive to both chemotherapy and radiotherapy. **Systemic chemotherapy is the treatment of choice, where fertility is to be preserved, even in the presence of metastatic disease.**

Different chemotherapeutic agents are used either singly or in combination (see ch. 30). Carboplatin 400 mg/M<sup>2</sup>, IV, every 4 weeks, for 6 courses have been used as a single agent therapy where the tumor has been removed completely. BEP (Bleomycin, Etoposide and Cisplatin), **VBP** (Vinblastin, Bleomycin and Cisplatin), **VAC** (Vincristine, Actinomycin and Cyclophosphamide) are the commonly used drugs for the germ cell tumors. The most effective chemotherapeutic regimens used are BEP, VBP and VAC (see Table 23.29 and p. 516, 517). Combination chemotherapy has significantly improved the survival rate.



**Fig. 23.25:** Histologic picture of dysgerminoma cells are mostly uniform (monotonous pattern) in size. The stroma is dense with lymphocytic infiltrate



Patient with Y chromosome as detected on karyotyping should have both the ovaries (gonads) removed.

**Radiotherapy:** Loss of fertility is a problem with radiation therapy. So, radiation therapy is not used in young patients.

**Recurrent disease** is treated either with combination chemotherapy or radiation therapy. Combination chemotherapy with POMB-ACE (Vincristine, bleomycin, methotrexate, cisplatin, etoposide, actinomycin D and cyclophosphamide) is preferred (see p. 516, 517). Radiation therapy is considered for patients who had been treated with combination chemotherapy earlier.

**Overall survival** following unilateral oophorectomy in early stage (stage Ia) disease 100 percent and following cisplatin-based combination chemotherapy in advanced disease is 75 percent.

**TABLE 23.29** RECOMMENDED DRUGS AND DOSES OF CHEMOTHERAPY (BEP, VBP)

Drugs	Dose	Schedule
Bleomycin (B)	15 units/M <sup>2</sup>	Every week
Etoposide (E)	100 mg/M <sup>2</sup>	On days 1-3, every 4 weeks
Cisplatin (P)	100 mg/M <sup>2</sup>	Every 3 weeks
Vinblastin (V)	12 mg/M <sup>2</sup>	Every 3 weeks

Drugs are given IV for 3–4 cycles, combinations used are BEP and VBP.



## IMMATURE TERATOMA

Immature teratomas are derived from the three germ layers — ectoderm, mesoderm and endoderm (see p. 294). These are rare and constitute less than 1 percent of ovarian teratomas. **It is the third common germ cell malignancies.** It is commonly (50%) seen in women between the ages of 10 and 20 years and rarely seen after menopause. Immature teratomas are almost never bilateral.

**Pathology:** Varying grades of undifferentiated tissue elements are present. Prognosis depends on the quantity of immature neural tissue elements. The prognosis of immature teratoma depends mainly on the tumor grade and the stage of the disease. Grade 3 tumor has poor prognosis. Serum AFP levels may be raised. Mature teratoma carries excellent prognosis.

**Treatment:** Unilateral oophorectomy with surgical staging is the optimum treatment when the tumor is confined to one ovary. For elderly women hysterectomy and bilateral salpingo-oophorectomy is ideal. **Adjuvant chemotherapy** for patients beyond stage IaGI is indicated. BEP (see above) is preferred, though VAC regimen is also effective.

## ENDODERMAL SINUS TUMOR (YOLK SAC TUMOR)

These tumors arise from the primitive yolk sac.

It is observed mostly between 15 and 20 years of age. **It is the second most common (20%) malignant germ cell tumor of the ovary.** Endodermal sinus tumors are unilateral and are usually solid, more than 10 cm in diameter.

Characteristic histological feature is the presence of cystic spaces lined by flattened epithelium. Within this space a tuft of vascular tissue is often seen. This is called **Schiller-Duval body**. Eosinophilic, hyaline bodies containing alphafetoprotein and other proteins are also constant microscopic features.

It is highly malignant and spreads to the adjacent structures rapidly. It is usually solid and cut section shows gelatinous or hemorrhagic areas. It is composed of yolk sac endoderm and extra-embryonic mesoblasts. Association with dysgerminoma should be kept in mind.

**Treatment:** Surgical staging and unilateral salpingo-oophorectomy is generally the treatment of choice. All patients need subsequent chemotherapy. Total

hysterectomy and contralateral salpingo-oophorectomy do not improve the prognosis in any way.

**Chemotherapy:** Routine use of combination chemotherapy has improved the survival significantly. Different combination regimens (VAC, VPB and POMB-ACE) are used (see p. 516, 517). Combinations containing platinum-based compounds are associated with better response and survival.

**The tumor produces alphafetoprotein which is an useful marker** (serum level above 20  $\mu\text{g/mL}$ ) to monitor regression and detect recurrence.

## NON-GESTATIONAL OVARIAN CHORIOCARCINOMA



Ovarian choriocarcinoma may be gestational, arising from ovarian pregnancy or metastases from the uterine choriocarcinoma. It may be non-gestational arising from one element of a solid teratoma. Pure non-gestational choriocarcinoma of the ovary is extremely rare. Most patients present before 20 years of age. Isosexual precocious puberty (p. 51) is common (50%). It consists of both cytotrophoblasts and syncytiotrophoblasts and **secretes gonadotropins (hCG) which is utilized as a marker** in diagnosis and follow up.

Unlike gestational choriocarcinoma, it is not so sensitive to methotrexate. As such, surgery is the primary treatment to be followed by chemotherapy. Combination chemotherapy (MAC, BEP) have been used. Prognosis is poor.

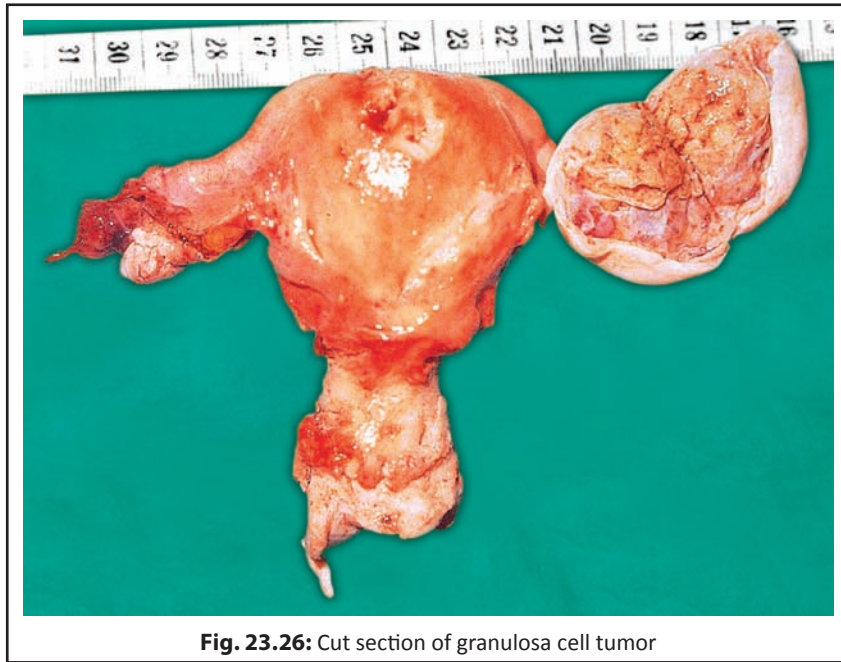
## GONADBLASTOMA

It is a rare ovarian tumor. It consists of germ cells and gonadal stromal cells. Dysgerminoma is present in 50 percent of cases. Patients often present with primary amenorrhea, virilism or genital abnormalities. Karyotype is usually 45,X or 46,XX/46,XY. It is bilateral in 30% of cases.

**Treatment** is surgical removal of the tumor and also the contralateral ovary. Prognosis is excellent.

## MIXED GERM CELL TUMORS

Presence of more than one germ cell element (at least two) is considered in this group. Dysgerminoma is the most common (70–80%) tissue element. Complete surgery followed by chemotherapy (VBP, MAC or VAC) is advised.



**Fig. 23.26:** Cut section of granulosa cell tumor

### Chemotherapy in Germ Cell Tumor

Combination chemotherapy has improved the survival following conservative surgery in malignant germ cell tumors of the ovary. Patients with stage-Ia disease need close follow up only. Following combination regimens have been used most commonly. BEP (bleomycin, etoposide and cisplatin), VBP (vinblastin, bleomycin and cisplatin) MAC (methotrexate, actinomycin-D and cyclophosphamide), VAC (vincristine, actinomycin-D and cyclophosphamide) and POMB-ACE (cisplatin, vincristine, methotrexate, bleomycin, actinomycin-D, cyclophosphamide and etoposide). For details see p. 516, 517.

Menstrual function, fertility and other endocrine functions have been found to be normal following use of these drugs.

### SEX CORD STROMAL TUMORS

- ◆ Granulosa cell tumors.
- ◆ Thecomas, fibromas.
- ◆ Sertoli-Leydig cell tumors (androblastoma).
- ◆ Gynandroblastoma (mixed).

Sex cord stromal tumors constitute 6–10 percent of all ovarian neoplasms. Peak incidence is over the

age of 50. As 15–30 percent of these tumors produce hormones, they are also known as '*functioning tumors*'.

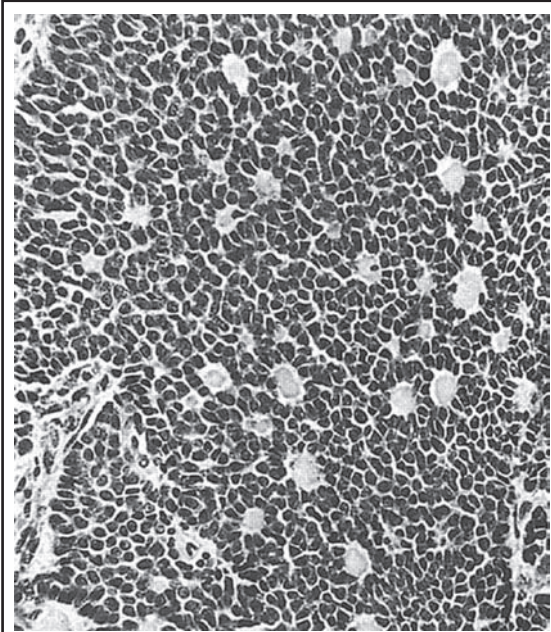
### GRANULOSA CELL TUMORS

Granulosa cell tumors constitute 2 percent of all ovarian neoplasms. The tumor originates from the 'rests' of primitive granulosa cells unused in folliculogenesis. **It is the commonest ovarian stromal tumor.**

It is bilateral only in 2 percent of cases and is a slow growing tumor. The size varies, so also the consistency — may be solid or cystic. **Cut section** is characteristically yellow or orange (Fig. 23.26) due to its lipid content.

### Microscopic Appearance (Fig. 23.27)

The cells are round or polygonal with granular eosinophilic cytoplasm with ill-defined borders. The tumor cell nuclei are variable in size but they are pale, usually grooved or folded and are called "**Coffee bean**" nuclei. Some cells are luteinized containing large polyhedral lipid cells. The cells are arranged in a number of architectural pattern but commonly in folliculoid type. The granulosa cells are arranged in small clusters around a central cavity. These structures are called **Call-Exner bodies and are pathognomonic of granulosa cell tumor.** The juvenile tumor has less number of Call-Exner bodies and less number of "Coffee bean" nuclei compared to the adult variety. The



**Fig. 23.27:** Histologic picture of granulosa cell tumor. Presence of Call-Exner bodies (microfollicular pattern) are diagnostic

tumor cells secrete inhibin and it is an useful marker for the disease (see p. 521).

As the tumor produces estrogen, there may be associated endometrial hyperplasia (50%). Unopposed estrogenic stimulation leads to development of endometrial carcinoma in about 5–10 percent of cases.

**Clinical features:** It occurs in all ages, 10 percent prior to puberty, 40 percent during childbearing period and 50 percent in postmenopausal women.

Apart from the non-specific features due to tumor mass, it produces **effects caused by hyperestrogenism which differs with ages.**

- ◆ Prior to puberty: Precocious puberty (p. 51).
- ◆ Childbearing period: Abnormal uterine bleeding.
- ◆ Postmenopausal: Bleeding (p. 559).

The features of precocious puberty revert back to normal after removal of the tumor. Patient may present with **acute abdomen** as these tumors have the propensity to rupture.

**Treatment:** Laparotomy and surgical staging is done (see p. 378). Unilateral salpingo-oophorectomy is the optimum treatment for children or women in the reproductive age.

Metastatic disease and recurrences have been treated with BEP (p. 516, 517) chemotherapeutic regimens. Overall prognosis is good. Life time follow up is essential as recurrence can occur as late as 30 years.

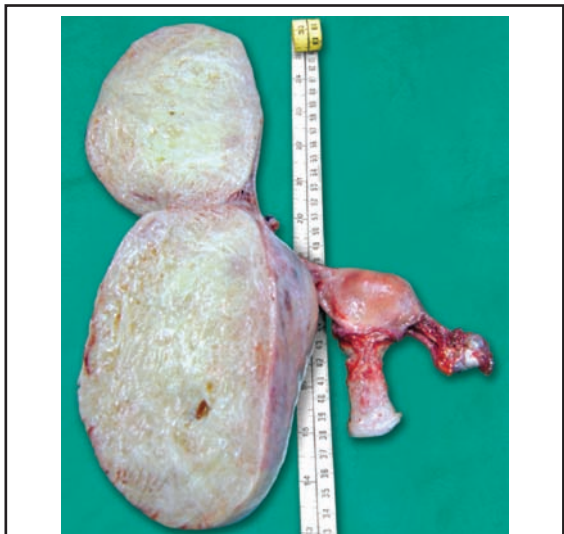## THECOMA

Thecoma is predominantly a lesion of postmenopausal age. It may occur as a distinct entity or mixed with granulosa cell tumor. External appearance looks like a fibroma. Cut surface shows islands of yellow tissue separated by grey fibrous septa. Microscopic picture reveals cells like that of cortical stroma with areas of granulosa cells.

Due to excess estrogen production, there is endometrial hyperplasia and often associated with endometrial carcinoma. It is responsible for postmenopausal bleeding. Rarely it may cause ascites or Meig's syndrome.

**Treatment** is surgical removal — total hysterectomy with bilateral salpingo-oophorectomy. In younger age group, conservative surgery may be employed considering the fact that it is mostly benign.

**Fibroma** in the ovary is usually observed in the postmenopausal women. It is derived from the stromal cells and are similar to thecomas. Less than 10% are bilateral. Meig's syndrome (Ascites, pleural effusion and ovarian fibroma) is seen in about 1% of cases (see p. 296, 652).



**Fig. 23.28:** Cut section of a theca cell tumour of the ovary

### SERTOLI-LEYDIG CELL TUMOR (ANDROBLASTOMA, ARRHENOBlastoma)

Sertoli-Leydig cell tumor is very rare and accounts for less than 0.5 percent of all ovarian tumors.

They probably arise from the male directed cell rests in the hilum of the ovary, from granulosa cells or from teratomas. The tumor produces predominantly androgens (80%) and, in some cases estrogen.

The tumors are small, usually unilateral (90%) and solid in consistency. Cut surface shows yellowish tinge with areas of hemorrhage and necrosis. Microscopic picture often resembles to various testicular cells such as Sertoli and Leydig cells.

**Clinical features:** The androgens produced by the tumor first lead to **defeminization** — atrophy of the breasts and uterus and amenorrhea followed by **masculinization (50%)**. This is evidenced by male type of distribution of hair, hoarseness of voice, breast atrophy, hirsutism, baldness and clitoral enlargement. Serum testosterone level is elevated.

**Treatment** is surgical removal of the tumor. The menstruation and fertility may return but the virilizing features fail to regress. Unilateral oophorectomy for younger age group is optimum. For older patients total hysterectomy with bilateral salpingo-oophorectomy is ideal. **Adjuvant therapy** is needed for poorly differentiated tumor. Combination chemotherapy (VAC or VBP) is needed for recurrent disease. Tumor removal results in rapid resolution

of most hormonal effects except deepening of voice and clitoromegaly.

### GYNANDROBLASTOMA

This is a very rare type of tumor. It contains both granulosa cell (estrogenic) or Sertoli-Leydig cell (androgenic) types. Usually it has got a benign course. Surgical removal is the optimum treatment.

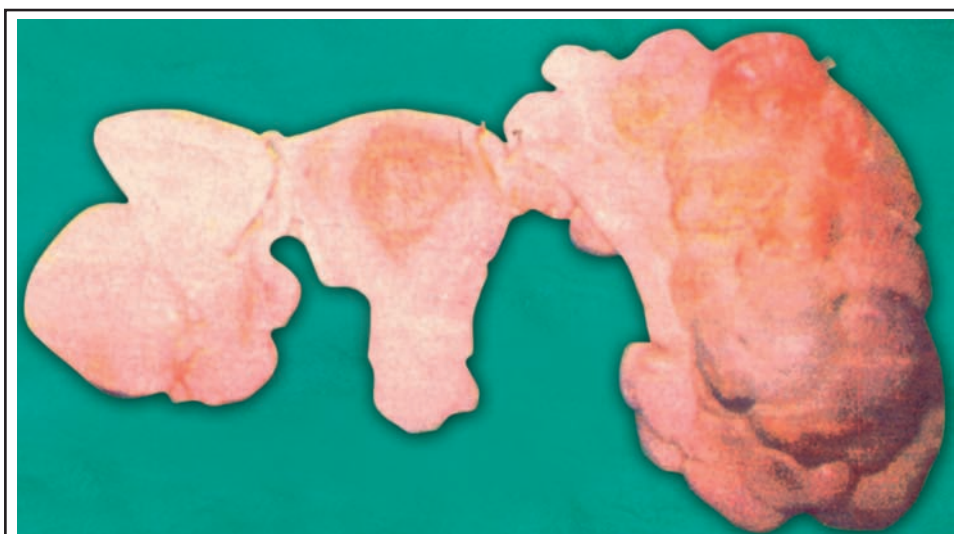### METASTATIC TUMORS OF THE OVARY

**Metastatic tumors of the ovary constitute about 5 percent of all ovarian tumors.**

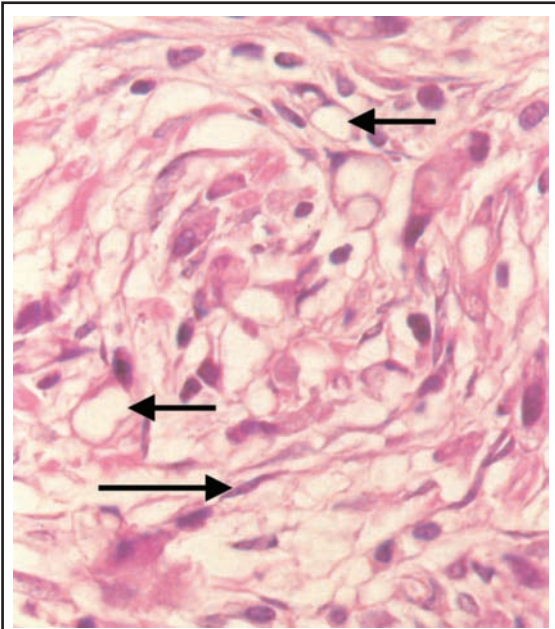
**The common primary sites** from where metastases to the ovaries occur are gastrointestinal tract (pylorus, colon and rarely small intestine), gallbladder, pancreas, breast and endometrial carcinoma.

The mode of spread from the primary growth is through retrograde lymphatics or by implantation from metastases within the peritoneal cavity. The malignant cells from the stomach reach the superior gastric group of lymph glands which also receive the lymphatics of the ovaries. Hematogenous spread is also there.

*These are usually bilateral, solid with irregular surfaces (Fig. 23.29). Peritoneal metastases are present, so also ascites. The omentum is involved and becomes solid.*



**Fig. 23.29:** Naked eye appearance of Krukenberg tumor (Presented by Dr. Sagar/Dulal Sinha)



**Fig. 23.30:** Histologic picture of Krukenberg tumor showing characteristic 'signet-ring' appearance. The signet-ring cells contain the eccentric nuclei and abundant pale cytoplasm.

**Typical:** Histologic picture same as that of primary one.

**Atypical:** The **atypical one is Krukenberg tumor** in which the histological picture differs from that of the primary one.

Metastatic tumors from the GI tract can be associated with sex hormone (estrogen and androgen) production. Patient may present with postmenopausal bleeding.

**Naked eye appearance:** The tumor is usually bilateral, solid with smooth surfaces and usually maintaining the shape of the ovary. They typically form rounded or reniform, firm white masses. Sometimes they are bosselated and may attain a big size. There is no tendency of adhesion (i.e. capsule remains intact) (Fig. 23.29).

The cut surfaces usually look yellow or white in color with cystic space at places due to degeneration. Cut surface has waxy consistency.

**Histologically,** the stroma is highly cellular. The mucin within epithelial cells compresses the nuclei to one pole, producing 'signet ring' appearance. The scattered '**signet ring' looking cells are characteristic of Krukenberg tumor (Fig. 23.30).**

**In most patients with Krukenberg's tumors, the prognosis is poor.** Median survival being less than a year. Rarely, no primary site can be identified and the Krukenberg's tumor may be a **primary tumor.**

## KEY POINTS

- In most of the developed countries, cancer of the breast tops the list in female malignancies, whereas in the developing countries including India, genital malignancies (cancer cervix) top the list.
- Vulval cancer usually occurs in postmenopausal women with median age of 60 years. Vulval cancer accounts for 3–5 percent of all genital malignancies.

The commonest site is labia majora followed by clitoris and labia minora. Ulcerative type is commoner than the hypertrophic type. In 90 percent, it is well-differentiated squamous cell carcinoma. The spread is predominantly by lymphatics both ipsilateral and contralateral (25%). Involvement of pelvic nodes bypassing the inguinal is less than 3 percent.

Causes of death are due to uremia, rupture of the femoral vessels and sepsis.

Microinvasive lesion of less than 1 mm requires wide local excision and follow up as metastasis to regional nodes are rare. Invasion of more than 1 mm requires radical vulvectomy with bilateral groin node dissection.

Frank invasive carcinoma should be dealt with by radical vulvectomy with bilateral inguofemoral lymphadenectomy. Pelvic lymphadenectomy is omitted in preference to radiation to the groin and pelvis – 4500 to 5000 cGy 4–6 weeks after operation. With negative groin nodes, the 5-year survival ranges from 90–100 percent; with positive groin nodes, the survival rate falls to 20–55 percent and with positive pelvic nodes, the survival rate is only 20 per cent.

Contd...

- Prognosis of vulvar carcinoma depends on many factors (p. 337). HPV positive younger patients tend to have a better prognosis.
- Melanomas comprise 5 percent of vulvar cancer and overall 5-year survival is about 50 percent. **Basal cell vulvar carcinoma** is treated by wide local excision.
- Primary carcinoma of vagina is rare and most vaginal cancers are metastatic. It constitutes 2% of gynecological cancers. The commonest site is in the upper-third of the posterior wall. The mean age is 55 years. Squamous cell carcinoma accounts for 90 percent of the cases. 5-year survival rate is about 40–45 percent.

Clear cell adenocarcinoma is seen in adolescent girls, who have had history of intrauterine exposure to diethyl stilboestrol. Radical hysterectomy, vaginectomy with pelvic lymphadenectomy is the surgery.

- Surgery (see p. 339) is the treatment of choice for upper vaginal, low stage tumor in younger patients. However, chemoradiation is used widely as a primary therapy. Ideally, 7000–7500 cGy is administered in less than 9 weeks.
- In most of the developing countries, including India, carcinoma of the cervix is the most common malignancy in females. It ranks first, the second being breast carcinoma. The site of lesion is predominantly ectocervix (80%). The commonest histologic type is squamous cell carcinoma (85–90%) and about 10–15 percent are adenocarcinomas.

Squamous cell carcinomas have a viral (HPV) and veneral association unlike that of adenocarcinomas.

The primary groups of lymph gland involvement are parametrial, internal iliac, obturator, external iliac and sacral nodes.

Preclinical invasive carcinoma is diagnosed by cytology, colposcopy and directed biopsy. If positive lesion is found, diagnostic conization and serial section has to be performed to establish the diagnosis. Definitive diagnosis of microinvasive carcinoma is made by cervical conization. The cone margins must be free of disease when conservative therapy is undertaken. Clinical presentation of early carcinoma includes menstrual abnormalities – intermenstrual bleeding or contact bleeding or excessive white discharge. Speculum examination reveals the lesion on the ectocervix which bleeds on friction.

Causes of death are uremia, hemorrhage, sepsis, cachexia and metastases to the lung.

Primary prevention includes identifying 'high risk' women, and 'high risk' males, prophylactic HPV vaccine, use of condom during early intercourse and removal of cervix during hysterectomy. Secondary prevention involves screening program and identifying the precancerous lesions or invasive lesion at its treatable stage.

- The prognosis of carcinoma cervix depends on many factors (p. 342) of which stage of the disease is important. Cancer cervix is a locally invasive tumor. It spreads primarily to pelvic tissues, then to pelvic and paraaortic lymph nodes. Rarely hematogenous spread to liver, lungs and bones may occur. Currently, radiation is combined with chemotherapy (chemoradiation) to optimize the results. Cisplatin 40 mg/m<sup>2</sup> weekly is used along with radiation (teletherapy and brachytherapy). Complications of radiotherapy (p. 508) may occur more than 1 year after therapy.

Microinvasive carcinoma when treated by total hysterectomy gives 5 year survival rate of almost 100%.

Radical hysterectomy can be performed upto stage IIA. This is specially used for a younger patient to preserve her ovarian function and to avoid vaginal fibrosis.

Survival outcome of treatment following surgery or radiation for stage IB/IIA is the same (85%).

Results of therapy in terms of 5-year survival is gratifying in early stages – 95 percent in stage Ia, reduced to 70 percent in stage II and 50 percent in stage III and 20 percent in stage IV (see Table 23.11). HPV positive younger patients have better prognosis.

Contd...

Contd...

Radical trachelectomy can be done in young women to preserve fertility as an alternative to radical hysterectomy. The disease must be in early stage (IA<sub>2</sub> or small IB<sub>1</sub> ≤ 2 cm). A therapeutic lymphadenectomy is also performed.

- Leg pain along the distribution of sciatic nerve and unilateral leg swelling are suggestive of pelvic recurrence of carcinoma cervix.
- The incidence of stump carcinoma is about 1 percent. The 5-year survival rate is 30–60 percent.
- For women with carcinoma cervix during pregnancy, survival rate is not different stage for stage when compared with the non-pregnant state.
- **Carcinoma body** ranks third amongst genital malignancies next to cervix and ovary. In USA, it is the leading site of genital malignancies followed by ovary and cervix. 75 percent are postmenopausal with the median age of 60. Nulliparity is associated in 30 percent.

Endometrial cancer can be estrogen dependent (type-1) and non-estrogen dependent (type II).

Women with Lynch syndrome have 40–60 percent lifetime risk of endometrial cancer (see p. 371).

- Use of combined oral contraceptive is a known protective factor whereas chronic unopposed estrogen stimulation is a known predisposing factor for endometrial carcinoma (see Tables 23.13, 22.8).

Corpus cancer syndrome encompasses obesity (BMI > 30), hypertension and diabetes. Fibroid is associated in 30 percent. Endometrial hyperplasia precedes carcinoma in 25 percent. The commonest histological type is adenocarcinoma. The pelvic and/or paraaortic glands are involved in about 10 percent in Stage I.

Postmenopausal bleeding is the predominant feature (75%). In premenopausal women, irregular bleeding is too often related. Once suspected, hysteroscopy and endometrial biopsy or fractional curettage is to be done, not only to diagnose but also to determine the extent of the lesion. The important primary prevention includes restriction of injudicious use of estrogen after menopause in nonhysterectomized women.

Secondary prevention includes screening of 'high risk' women at least in menopausal period and liberal hysterectomy in pre-malignant lesions of the corpus.

Mainstay in the treatment of carcinoma body is total abdominal hysterectomy and bilateral salpingo-oophorectomy with pelvic and paraaortic lymph node sampling. In stage II, radical hysterectomy has to be done. Adjuvant radiation is considered depending on the surgical stage of the disease, myometrial invasion and histologic grade (p. 359).

- Primary radiotherapy is the treatment in surgically risk patients and in advanced stages.
- Multimodality approach (chemo and radiation therapy) is used in advanced and recurrent cases or in metastatic lesions.
- Progestogens are widely used in well-differentiated carcinoma with adequate estrogen and progesterone receptors. Antiestrogen, tamoxifen is often used along with progestogens to improve the result.
- Prognosis of endometrial cancer depends on many factors (Table 23.15) of which depth of myometrial invasion and tumor grade are the most important ones. Younger women with endometrial cancer have a better prognosis when compared with the older women.
- Gestational trophoblastic neoplasia (GTN) encompasses persistent hydatidiform mole, invasive mole, choriocarcinoma and placental site trophoblastic tumor.
- The incidence of GTN is about 1 in 5,000 pregnancies in Oriental countries and 1 in 50,000 in Europe and North America. Fifty percent occur after molar pregnancy, 25 percent after abortion and ectopic and 25 percent after normal pregnancy. Nonmetastatic lesions develop in 15 percent and metastatic lesions develop in about 4 percent of patients after molar evacuation.

Contd...

Contd...

- Trophoblastic cells normally regress within 3 weeks following delivery. Women treated for GTN should not become pregnant for 6–12 months after the treatment. This helps to assess the level of  $\beta$ -hCG and treatment response. Diagnosis of postmolar GTN is made when the hCG level plateaus for 3 or more consecutive weeks or re-elevates.
- The invasive mole is diagnosed on laparotomy and on histology showing hyperplastic trophoblastic cells maintaining villous structures without evidences of muscle necrosis. In choriocarcinoma, the hyperplastic trophoblastic column of cells invades the muscles. There are evidences of hemorrhage and muscle necrosis. The villous pattern is lost.  
The commonest site of metastases is lung, followed by anterior vaginal wall, brain and liver.
- Recurrence rate of GTN following treatment (hCG level reached normal) is 5 percent for metastatic good prognosis cases and is 1–2 percent for nonmetastatic cases (see Table 23.17).
- Primary surgery has got limited place. Hysterectomy is indicated in women aged more than 35 years to improve the efficacy of chemotherapy or to control intractable bleeding. Total hysterectomy is to be done on day 3 of a course of chemotherapy.
- There is no adverse effect on subsequent pregnancy, if it occurs after 1 year of chemotherapy. The damaged cells are likely to be washed by this time. Pregnancy should be confirmed by USG early and serum hCG should be measured 6 weeks after delivery to exclude persistent GTN.
- Prophylactic chemotherapy can prevent uterine invasion and metastasis. But it is given selectively.
- Low-risk GTN cases (see Table 23.17) are usually treated by single-agent chemotherapy. Whereas high-risk metastatic cases are treated with multiple-agent chemotherapy (see p. 366). Non-metastatic and low-risk metastatic GTN cases are completely curable by chemotherapy.
- Uterine sarcoma comprise less than 5 percent of uterine malignancies. The commonest site of uterine sarcoma is the intramural part.
- The commonest mode of spread is blood borne. Total hysterectomy with bilateral salpingo-oophorectomy is the surgery. This is followed by multiagent chemotherapy and external pelvic radiation. Mitotic figure is an important prognostic factor for leiomyosarcoma of the uterus. Patients with mitotic rate of less than 5/10 HPF behave as a benign lesion but mitotic rate of more than 10 per 10 HPF are frankly malignant and have got worst prognosis.
- Sarcoma botryoides is a special type of mixed mesodermal tumor arising from the cervix. The child, before the age of 8, may be affected. Multimodality approach (multiagent chemotherapy with surgical removal and occasionally radiation) gives better result.
- Primary carcinoma of the fallopian tube is rarest (< 1%) gynecological malignancy. It is mostly unilateral (80%). Associated hematosalpinx is often present. Classic triad of adnexal mass, intermittent profuse watery discharge (hydrops tubae profluens) and vaginal bleeding is considered pathognomonic for tubal carcinoma. USG/Laparoscopy is suggestive and biopsy is confirmatory. Persistent postmenopausal bleeding and/or positive vaginal cytology for adenocarcinoma, in the absence of endometrial carcinoma, the diagnosis of tubal carcinoma should be considered.
- Total hysterectomy with bilateral salpingo-oophorectomy along with omentectomy is done. This is followed by platinum based combination chemotherapy as the adjuvant treatment. The prognosis is not good.  
Secondary carcinoma (metastatic) is common (90%), the primary sites are from ovary, uterus, breast or gastrointestinal tract.

Contd...



Contd...

- There is wide geographical variation in the incidence of ovarian malignancy. Incidence is high in Scandinavian countries and USA, low in Asian countries (India, Japan).
- Serous cystadenomas are the most common epithelial tumors. Serous adenocarcinomas have the worst prognosis of epithelial adenocarcinomas.
- Twenty percent of ovarian neoplasms are malignant. Malignant epithelial tumors constitute about 90 percent of all primary ovarian carcinomas. The primary mode of spread of epithelial ovarian carcinoma is transcoelomic and it spreads to the visceral and parietal peritoneum, diaphragm and to the retroperitoneal nodes. Most ovarian carcinomas are diagnosed in stages III or IV.
- Endometrioid carcinoma is associated with endometrial carcinoma in 20 percent and ovarian-endometriosis in 10 percent cases.
- The common primary sites of metastatic ovarian malignancies are gastrointestinal tract, gallbladder, breast and endometrial carcinoma. The tumor may be typical or atypical (Krukenberg). The primary sites of Krukenberg are stomach, large bowel and breast. The spread to the ovaries is by retrograde lymphatics. Histologically, it is confirmed by presence of 'signet ring' looking cells.
- Patients with familial cancer syndrome (Lynch type I and II) have a higher risk of developing epithelial ovarian cancer. Mutations of BRCA 1 gene (17 q) and BRCA II gene (13 q) have been observed. Inherited ovarian malignancies account for about 5 percent of epithelial ovarian cancers (see p. 371).
- The efficacy of screening procedure is not well-documented. However, periodic internal examination supplemented by transvaginal color Doppler sonography to note the ovarian volume, blood flow and estimation of CA-125 in 'high risk' population, can reveal the lesion at the early stage. Gene mutation study for detection of genetic inheritance is not currently recommended.

High-risk women are : family history of ovarian, endometrial or breast carcinoma, history of removal of ovarian or breast neoplasm, presence of pelvic tumor in adolescent and perimenopausal women and postmenopausal palpable ovary (volume > 8 cm<sup>3</sup>).

Protective factors for ovarian epithelial adenocarcinomas are: combined oral contraceptives, pregnancy, tubal ligation, hysterectomy and breastfeeding.

Ovarian enlargement less than 8 cm in diameter in a menstruating women is most commonly functional.

Surgery is the keystone in the primary treatment of ovarian malignancy. The aims are staging of the disease and to perform maximum surgical removal.

The ideal definitive surgery is total hysterectomy with bilateral salpingo-oophorectomy with infracolic omentectomy with pelvic and paraaortic lymph node sampling. In exceptional cases, conservative surgery of unilateral salpingo-oophorectomy is justified.

Debulking surgery with residual tumor nodules < 1 cm confers better survival advantage even in advanced stage disease. CT, MRI and PET are effective for detecting residual tumor and the retroperitoneal nodes.

Second look surgery either by laparoscopy or laparotomy is employed either after 12 courses of chemotherapy or after 1 year of primary therapy.

The 5-year survival rate for patients with borderline epithelial ovarian cancer (grade 0) is close to 100 percent (p. 302). For other stages see Table 23.28.

Chemotherapy is being widely used following cytoreductive surgery to improve the result in terms of survival.

Platinum-based compounds (cisplatin, carboplatin), either alone or in combination with taxane, prolong the survival rate. Taxane derivatives (paclitaxel, docetaxel) are effective in cisplatin resistant ovarian cancer. Treatment with carboplatin and paclitaxel for 3–6 cycles is desirable for most patients.

Contd...

Contd...

Neo-adjuvant chemotherapy is an alternative mode of chemotherapy when preoperative disease assessment is such that optimal cytoreduction is not possible (p. 380).

The ovarian antigen CA-125 is useful to monitor the patient during chemotherapy and for follow up.

The prognosis of epithelial ovarian carcinoma depends on many factors (see p. 381). Over-expression of oncogene (HER-2/neu) has been associated with poor prognosis.

- Germ cell tumors occur in young women. They are the second most common type of ovarian neoplasm. Most common germ cell tumor is the benign cystic teratoma (dermoid). It is bilateral in 10–15 percent cases.
- Dysgerminoma is the most common malignant germ cell tumor. It is bilateral in 10 percent cases. The tumor is highly sensitive to radiation. Multiagent chemotherapy (ectoposide, platinum with or without bleomycin) results in complete remission.
- Fibroma is the most common benign solid ovarian tumor.
- Endodermal sinus tumor is highly malignant occurring at a median age of 19. Alpha fetoprotein is the tumor marker. Treatment is surgery followed by chemotherapy.
- Non-gestational ovarian choriocarcinoma is highly malignant. hCG is the tumor marker. It is not responsive to chemotherapy. The treatment is surgery followed by chemotherapy.
- Multi-agent chemotherapy (BEP, VAC, VBP, CAP) has improved the survival rate as well as childbearing function in patients with malignant germ cell tumors.
- Granulosa cell tumor produces estrogen and may be associated with endometrial hyperplasia or endometrial carcinoma. It occurs 10 percent prior to puberty and 40 percent in postmenopausal period. It produces precocious puberty and postmenopausal bleeding. Thecoma is predominantly postmenopausal. There is excess estrogen production.
- Sertoli-Leydig cell tumor (previously called arrhenoblastoma) is very rare. It arises from the male directed cell rests in the hilum of the ovary, from granulosa cells or from teratomas. The tumor produces androgens (80%) and in some cases estrogen.

# Urinary Problems in Gynecology

## ANATOMY OF VESICourethRAL UNIT

The bladder and urethra should be considered as a single unit with two major functions—storage of urine and voiding of urine.

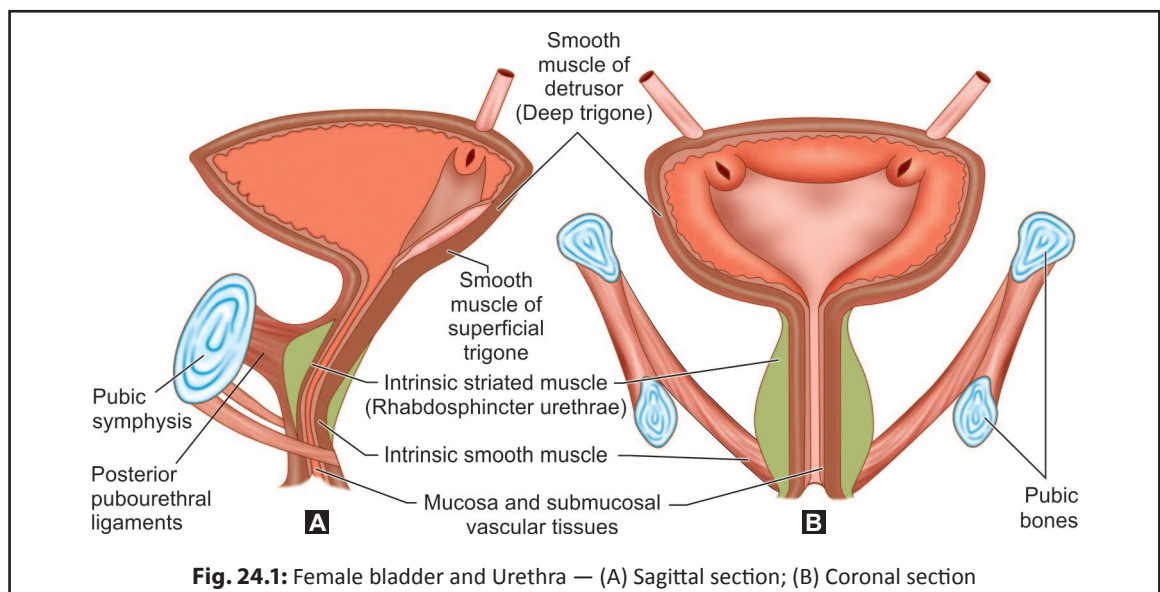
Though the two organs are anatomically separate entities but integrated with complex functional interplay.

The descriptive anatomy of the urinary bladder and urethra has been described in Chapter 1. **The anatomic and physiologic peculiarities involved in storage and voiding of urine are to be discussed here.**

## BLADDER

The bladder muscles — called detrusor consist of three layers of muscles (Fig. 24.1).

- ◆ **Outer longitudinal**—The muscles course downwards from the fundus to bladder neck. At the level of bladder neck, it forms a sling. With this arrangement, it forms an active and dominant role in both storage and voiding.
- ◆ **Middle circular**—It is more prominent in the lower part of the bladder.
- ◆ **Inner longitudinal**— It courses downwards from the fundus of the bladder and continues in the form of spirals upto the midurethra.



**Fig. 24.1:** Female bladder and Urethra — (A) Sagittal section; (B) Coronal section

Recent studies, however, suggest that there is frequent interchange of fibers between the bundles and the separate layers are not distinctly defined.

From a functional point of view, the detrusor appears to contract as a single syncytial mass. The detrusor muscles are shown to contain significant amount of acetylcholinesterase.

### Trigone

The smooth muscle has got two distinct layers. The deeper one is similar to detrusor. The superficial layer is relatively thin. Traced distally, it fades out in the proximal urethra. It is devoid of acetylcholinesterase but have more cholinergic nerve supply.

### Bladder neck

The muscle bundles are largely oblique or longitudinal. They appear to have little or no sphincteric action.

## URETHRA

From the functional point of view, the anatomic length of the urethra is divided into three parts.

**Proximal urethra:** It is weakest part of the urethra. Inner longitudinal muscle of the detrusor fades out in this part of the urethra. It fails to withstand the rise of intravesical or intra-abdominal pressure.

### Midurethra (Fig. 24.1)

This is the strongest part of the urethra. This part has got an additional support by the intrinsic striated muscle (rhabdosphincter urethrae). This muscle encircles the whole urethra and is composed predominantly of skeletal muscle with nerve supply from parasympathetic division of autonomic nerves. This rhabdosphincter is further enforced in the upper part by levator ani muscles (extrinsic muscles) being separated from it by a distinct connective tissue septum. The extrinsic periurethral muscle (levator ani) is supplied by the perineal branch of pudendal nerve. The intrinsic striated muscles (slow twitch fibers) is responsible for **urethral closure at rest**. The extrinsic periurethral striated muscles (first twitch fibers) provide additional **support to urethra on stress**.

**Distal urethra:** This part is a passive conduit and is surrounded by collagen tissue. In fact, the entire urethra is rich in elastic and collagen fibers.

**Pubourethral ligaments** and condensed endopelvic fascia are found to contain smooth muscle fibers. They work together to maintain the normal anatomic support and prevent hypermobility of bladder neck and urethra.

### SUBMUCOUS LAYER OF THE URETHRA

Submucous layer is the vascular layer which by its plasticity helps in urethral compression.

Two venous plexi are identified in the submucous coat. A distal one which varies little with age and a proximal one beneath the bladder neck which undergoes marked changes with age. In the reproductive period, these vessels give a cavernous appearance to the submucosa which disappears in the postmenopausal period. **This urethral vascular system plays a significant role in the maintenance of resting urethral pressure.**

### MUCOUS LAYER OF THE URETHRA

Mucosa is arranged in longitudinal folds that allow apposition and distension.

### Support to bladder neck and urethra

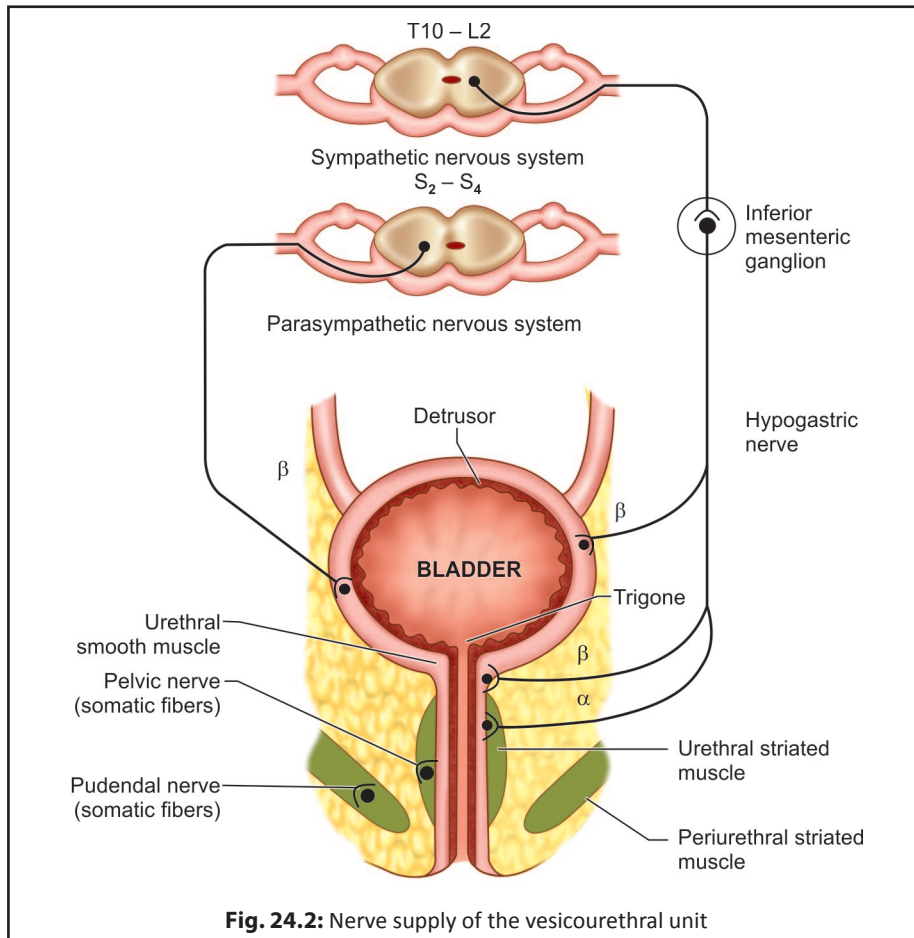
Support is maintained by intrinsic and extrinsic factors.

**Intrinsic factors:** (i) Intrinsic rhabdosphincter urethrae (Fig. 24.1). (ii) Urethral submucosal venous plexus (cavernous plexus). (iii) Urethral smooth muscles. (iv) Sympathetic activity to maintain urethral tone by  $\alpha$ -adrenergic receptors. (v) Estrogen to increase collagen connective tissue.

**Extrinsic factors:** (i) Contraction of pubococcygeus part of levator ani muscle; (ii) Pubourethral ligaments and condensed endopelvic fascia with smooth muscle fibres; (iii) Exercise to increase collagen turnover and also to maintain strength of levator ani.

## NERVE SUPPLY OF THE VESICourethRAL UNIT (Fig. 24.2)

**AUTONOMIC:** Parasympathetic nerves originating from  $S_{2-4}$  stimulate detrusor contractions through the release of acetylcholine (cholinergic nerve fibers). Preganglionic sympathetic fibers arising from  $T_{10}-L_2$  are also cholinergic but the postganglionic fibers innervating both the bladder and urethra act through the release of norepinephrine (adrenergic nerve fibers).  $\beta$ -adrenergic fibers terminate mainly in the bladder and  $\alpha$ -adrenergic mostly in the urethra. The former component relaxes both the bladder and urethra and latter one contracts only the urethra.  **$\alpha$ -receptors are located mainly in the bladder base and are responsible for detrusor contraction.**



**Fig. 24.2:** Nerve supply of the vesicourethral unit

**$\beta$  receptors are located mainly on the fundus of the bladder and cause detrusor relaxation.**

The sympathetic is concerned mainly with the filling and storage phase of micturition. Parasympathetic supply (acetylcholine) is responsible for detrusor contraction and normal voiding.

### SOMATIC

The somatic supply to the striated muscle of urethra is through the pudendal nerve. The rhabdosphincter is supplied by pelvic splanchnic nerves traveling with the parasympathetic fibers. Extrinsic periurethral striated muscle is supplied by the motor fibers of the pudendal nerves.

### PHYSIOLOGY OF MICTURITION

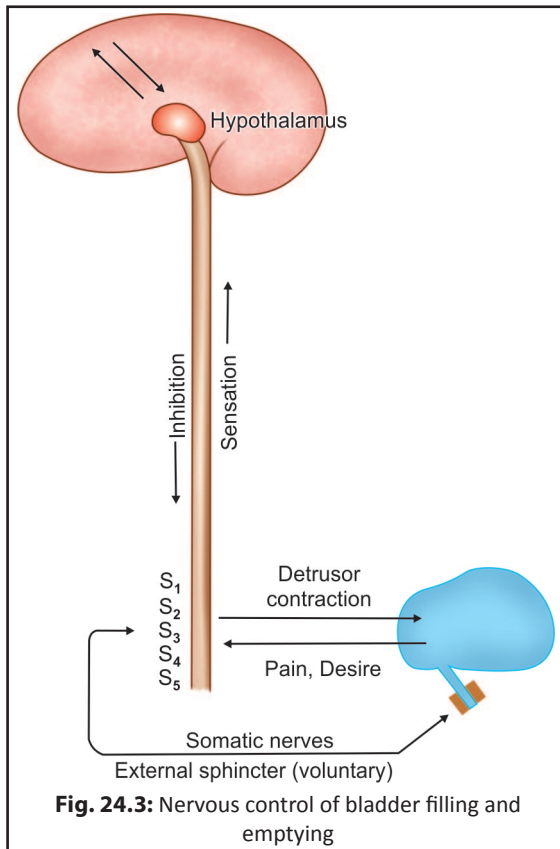
The bladder and urethra should be considered as a single unit with two main functions:

- Storage of urine
- Voiding of urine

**STORAGE PHASE:** The urine comes into the bladder drop by drop through the ureteric openings. As the bladder fills, the walls stretch to maintain a constant muscle tone. The bladder usually fills at the rate of 0.5–5 ml/min. from the ureters. The intravesical pressure is raised to remain at almost steady level of about 10 cm of water even with a volume of about 500 ml.

**The intravesical pressure is kept lower** than that of the urethra by delicately coordinated relaxation of detrusor muscle. **This is possible through number of mechanisms.**

- ◆ Proximal urethral musculature acts like a sphincter by maintaining tonic contraction.
- ◆ Stretching of the detrusor reflexly contracts the sphincteric muscles of the bladder neck.
- ◆ Inhibition of the cholinergic system responsible for detrusor contraction operating from the spinal centers.



- ◆ Stimulation of  $\beta$ -adrenergic results in further relaxation of the detrusor and  $\alpha$ -adrenergic dominance leads to contraction of smooth muscles round the bladder neck (internal sphincter).
- ◆ The external sphincter mechanism consists of periurethral muscle fibers which are of “slow

twitch” variety innervated by the pelvic efferent nerves. The other component of the external sphincter derived from the levator ani, composed of fibres of “first twitch” variety innervated by the perineal branch of pudendal nerve.

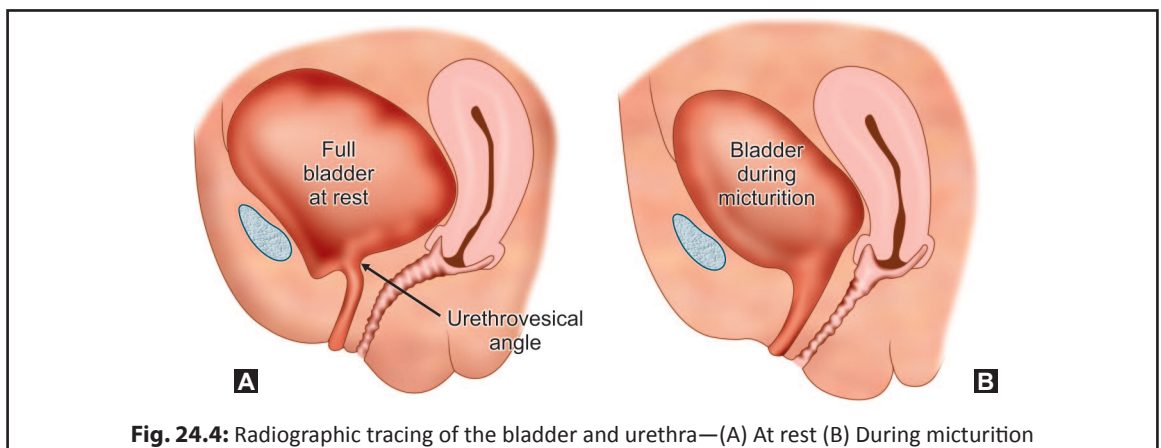
- ◆ The external sphincter mechanism contributes the second line guard assisting the first line guard provided by the internal sphincter of the bladder neck.

**VOIDING PHASE:** When the volume of the bladder reaches about 250 ml, a sensation of bladder filling is perceived. A desire to void is reached, not by increased intravesical pressure but by stimulation of stretch receptors in the bladder wall.

The sensation passes up the spinal roots  $S_2$ ,  $S_3$  and  $S_4$  and in untrained bladder (children), there sets in motion a reflex which automatically contracts the detrusor and results in voiding.

**But in the trained adults**, this urge can be suppressed especially if the time or place is not convenient. Because in adults, the reflex spinal arc is under control of the hypothalamus and higher areas of the brain (anterior part of the frontal lobes). Cerebral control of micturition is complex but is predominantly controlled by pontine center. Action of detrusor can therefore, be voluntarily inhibited (Fig. 24.3).

When the time or the place is convenient, the higher centers via the hypothalamus no longer inhibit the detrusor and the bladder changes from its passive to active role. The detrusor contracts **to raise the intravesical pressure to 30–50 cm of water**. The pressure is further raised to about 100 cm of water by voluntary contraction of the abdominal muscles.



### The series of chronologic events to follow in the process of micturition are:

The diaphragm is fixed; the abdominal muscles are contracted and the pelvic floor is relaxed.



Immediately following this or possibly as a consequence of them, there is drop of intraurethral pressure. This drop is due to skeletal muscle relaxation and sympathetic blockade. Bladder base descends with obliteration of posterior urethro-vesical angle (normal 100°) (Fig. 24.4).



Detrusor contraction starts.



Funneling of the bladder neck and upper urethra, i.e. dilatation of the urethra from above down.



Urine leaks into the upper urethra.



External urethral sphincter opens voluntarily or is overwhelmed by the raised intravesical pressure.



Voiding



At the end of micturition, the proximal urethra contracts from the distal end to the urethrovesical junction, milking back the last drop of urine into the bladder.



The anatomy of the base and posterior urethro-vesical angle is restored.



Finally, the external sphincter closes.

## URINARY CONTINENCE

### MECHANISM OF URINARY CONTINENCE

The mechanism responsible for maintenance of urinary continence in the females is still ill-understood.

Normally, **intraurethral pressure at rest and with stress is much higher (20–50 cm of water) than the intravesical pressure (10 cm of water).**

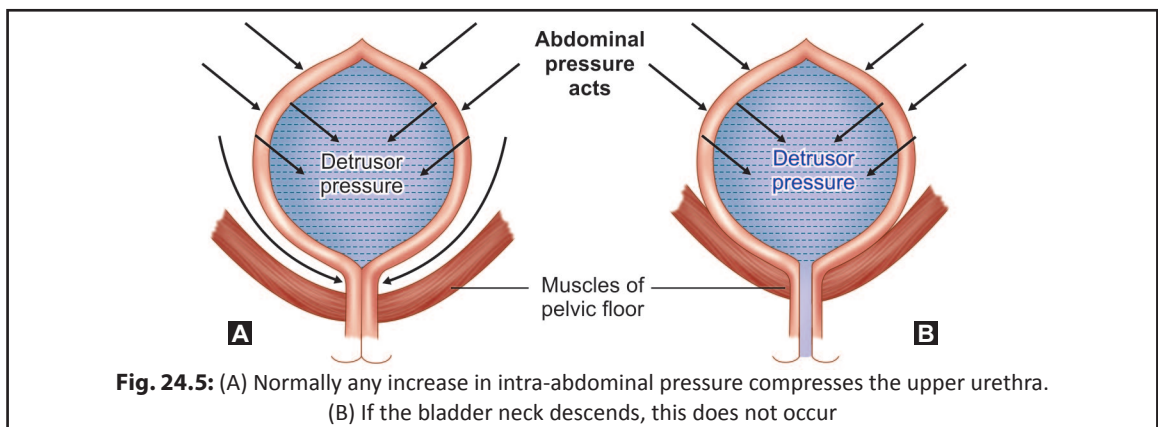
The intraurethral pressure at rest is maintained by the following:

- ◆ Apposition of the longitudinal mucosal folds.
- ◆ Submucosal vascular plexus (hermetic seal).
- ◆ Abundant deposition of collagen and elastic tissues throughout the circumference of the urethra.
- ◆ Tonic contraction of the smooth muscles in the proximal urethra and bladder neck.
- ◆ Rhabdosphincter in the midurethra and levator ani muscles.

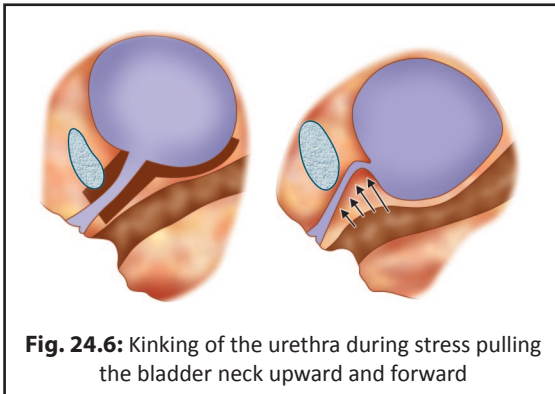
*Approximately, one-third of the resting urethral pressure is due to rhabdosphincter effects, one-third to smooth muscle effects and one-third to its vascular plexus.*

**During stress**, with rise of intra-abdominal pressure, the escape of urine is prevented by the additional factors:

- (i) Centripetal force of intra-abdominal pressure transmitted to the proximal urethra which occurs as long as the bladder neck remains above the pelvic diaphragm (Fig. 24.5).



**Fig. 24.5:** (A) Normally any increase in intra-abdominal pressure compresses the upper urethra. (B) If the bladder neck descends, this does not occur



**Fig. 24.6:** Kinking of the urethra during stress pulling the bladder neck upward and forward

- (ii) Reflex contraction of the urethral striated sphincter and periurethral striated musculature during stress.
- (iii) Kinking of the urethra due to:
- ◆ **Hammock like attachment** of pubo-cervical fascia with urethra, vagina and laterally to the arcus tendineus fascia give stability to urethra. During rise in intra-abdominal pressure, normally the urethra is compressed against the anterior vaginal wall.
  - ◆ **Bladder base rocks** downward and backward.
  - ◆ **Bladder neck** is pulled upward and forward behind the symphysis pubis due to preferential better support to the posterior wall of the urethra than to the base of the bladder given by the pubocervical fascia (Fig. 24.6).

## URINARY INCONTINENCE

**Urinary incontinence is defined** as objectively demonstrable involuntary loss of urine so as to cause hygienic and/or social inconvenience for day to day activity.

<b>Table 24.1</b> <b>Classification of urinary incontinence</b>	
<b>Urethral</b>	<b>Extra urethral</b>
<ul style="list-style-type: none"> <li>• Urethral sphincter incompetence (GSI)</li> <li>• Detrusor overactivity (DO)</li> <li>• Mixed (GSI and DO)</li> <li>• Overflow incontinence (acute and chronic)</li> <li>• Functional and others (UTI)</li> <li>• Congenital (epispadias)</li> </ul>	<ul style="list-style-type: none"> <li>Acquired               <ul style="list-style-type: none"> <li>• Fistulae (see p. 417)</li> <li>• Vesical</li> <li>• Urethral</li> <li>• Ureteral</li> </ul> </li> <li>Congenital               <ul style="list-style-type: none"> <li>• Ectopic ureter and others</li> </ul> </li> </ul>

**Pathophysiology of Urinary Incontinence**—Basic pathology of incontinence is the rise of intravesical pressure over that of maximum urethral pressure. It may be due to mechanical injury to the supports of the bladder neck following childbirth, trauma (surgery), or due to ageing. Overactivity of the detrusor muscles, may also be associated (see p. 407).

**Stress urinary incontinence (SUI)** is defined as involuntary escape of urine from the external urinary meatus due to sudden rise in intra-abdominal pressure. The term, ‘urethral sphincter incompetence’ seems to be appropriate as it signifies the basic pathology (Table 24.1).

## GENUINE STRESS INCONTINENCE (GSI)

**DEFINITION:** Genuine stress incontinence (GSI) is defined, according to the international continence society (ICS) as involuntary urethral loss of urine when the intravesical pressure exceeds the maximum urethral pressure **in the absence of detrusor activity**. The diagnosis of GSI should be made following urodynamic assessment only.

**INCIDENCE:** The reported incidence in the Western countries is as high as 40 percent in association with prolapse. In about 5 percent, the symptoms may be annoying.

**ETIOPATHOGENESIS:** GSI is strictly an anatomic problem. In the normal continent woman, the bladder neck and the proximal urethra are intra-abdominal and above the pelvic floor in standing position. The urethral pressure exceeds the intravesical pressure.

**Urethral sphincter incompetence is principally due to:**

- (i) Hypermobility of urethra due to distortion of the normal urethrovesical anatomy.
- ◆ Descent of the bladder neck and proximal urethra which normally lies above the urogenital diaphragm, hinders rise of intraurethral pressure during straining (Fig. 24.5).
- (ii) Lowered urethral pressure—Lowered intra-urethral pressure at rest below the intravesical pressure.

**Risk factors for stress urinary incontinence:**

- ◆ **Developmental weakness** of the supporting structures maintaining the bladder neck and



proximal urethra in position. There may be genetic variations in collagen and other connective tissues which normally maintain anatomic and physiologic aspect of the vesicourethral unit.

- ▶ **Childbirth trauma** causing damage of the pelvic floor and pubocervical fascia. Denervation of the smooth and striated components of the sphincter mechanism also operates. **The injury is more common in gynecoid and least in android pelvis.**
- ▶ **Pregnancy**—It is probably functional in nature and related to high level of progesterone.
- ▶ **Postmenopausal**—Estrogen deficiency leads to atrophy of the supporting structures along with diminished periurethral vascular resistance.
- ▶ **Trauma**—Injury to symphysis pubis due to fracture or following symphysiotomy.
- ▶ **Following surgery** like anterior colporrhaphy, local repair of VVF or bladder neck surgery, there may be fibrosis of the urethra and urethral musculature.
- ▶ **Age**—increasing age.
- ▶ **Obesity (BMI  $\geq$  30).**

### MORBID ANATOMIC CHANGES

**In GSI, the main defects are:**

- ◆ Intrinsic sphincter dysfunction.
- ◆ Bladder base becomes flat and lies in line with the posterior wall of the proximal urethra.
- ◆ Descent of the proximal urethra.

The net effect of these changes is to lower the intraurethral pressure as in early stage of micturition. Thus, even a small rise of intravesical pressure during stress, allows the urine to escape out.

*GSI is the ultimate symptom of varying severity due to anatomic urethral hypermobility (80%) and/or intrinsic sphincter deficiency (20%).*

### CLINICAL FEATURES

**Patient profile:** The patients are usually parous, may be postmenopausal. Often the complaints date back to the last childbirth or some vaginal plastic operation. Sometimes the symptoms may be combined with frequency or urge incontinence. The patient may be obese.

**Symptoms:** The only symptom is escape of urine with coughing, sneezing or laughing. **The loss of urine has got the following features:**

- Brief and coincides precisely to the period of raised intra-abdominal pressure.
- Unassociated with a desire to pass urine.
- Rarely, occurs in supine position or during sleep.
- Patients are fully aware of it.
- The amount of loss is small.

Details of medical history (e.g. diabetes, chronic pulmonary disease, neurological disease), surgical history (spine or genitourinary tract), current medications (sedatives, antipsychotics) must be noted. Because these have direct bearing on urinary incontinence.

**Local examination:** Pelvic examination should be done with the bladder full.

- Some degree of pelvic relaxation with cystocele or cystourethrocele is usually evident.
- Stress test—When the patient is asked to cough, a few drops of urine are seen escaping from the external urethral meatus. If the escape is not detected in supine position, the examination is to be conducted in standing position.
- Q-tip test—The Q-tip test has been tried to predict SUI. A sterile (lubricated with 2% xylocaine jelly) cotton tipped swab is introduced to the level of bladder neck through the urethra. Then the patient is asked to sit and cough (Valsalva). If there is marked upward elevation ( $>30^\circ$ ) of the cotton tipped swab, urethra is considered hypermobile. Unfortunately, the test is imprecise to the diagnosis of SUI and currently not used.

**TABLE 24.2** DIFFERENCE IN CLINICAL PRESENTATION

<b>Stress Incontinence</b>	<b>Urge Incontinence (sensory)</b>	<b>Detrusor Instability</b>
<ul style="list-style-type: none"> <li>• Leakage of urine coincides with stress</li> <li>• No prior urge to void</li> <li>• Amount — small</li> <li>• Patient — fully aware of it</li> <li>• Micturition — normal</li> </ul>	<ul style="list-style-type: none"> <li>• Unable to control the escape of urine, once there is urge to void</li> <li>• Amount — large</li> <li>• Patient — aware of the urge</li> <li>• Urgency and frequency</li> </ul>	<ul style="list-style-type: none"> <li>• The incontinence may occur abruptly even without a full bladder</li> <li>• Amount — large</li> <li>• Patient — not aware of it</li> <li>• Frequency and nocturia</li> </ul>

**DIFFERENTIAL DIAGNOSIS:** Sometimes, there may be clinical confusion with other forms of incontinence such as urge or detrusor instability. The differentiating features are tabulated in Table 24.2.

### SPECIAL INVESTIGATIONS (TABLE 24.4)

The investigations aims at:

- To confirm the diagnosis
- To rule out associated pathology.

**Midstream urine examination**—This should be a routine prior to urodynamic studies to avoid risk of flaring up the infection during invasive procedures. Any woman with a urine dipstick test positive for both leucocytes and nitrites should have a midstream urine specimen for culture and sensitivity. Hematuria, if present, must be thoroughly evaluated with malignant cell cytology, cystourethroscopy and intravenous urography (IVU).

**Pad test**—An one hour extended pad test is recommended in cases when the clinical stress test is negative.

The patient wears a preweighed sanitary pad, drinks about 500 ml of water and rests for 15 minutes. She then performs exercises like walking or climbing stairs for 30 minutes. This is to be followed by provocative exercises such as bending, jumping, coughing, etc. for another 15 minutes. After a period of hour, the sanitary pad is removed and weighed. **An increase in weight by 1 g is considered as significant loss.**

**Frequency volume chart (urinary diary)**—Patient is asked to record her fluid intake, output, episodes of leakage in relation to time and activity. It should be recorded at least for 3 days. This diary gives an idea about daily urine output, number of voids per day and functional bladder capacity.

**Residual urine:** The woman is asked to void. A catheter is inserted in the bladder within the next 10 minutes to measure the remaining urine in the bladder. Normally residual urine should be < 50 mL. Large amount of residual urine indicates urinary retention (inadequate bladder emptying). Residual volume measurement by ultrasonography is also fairly accurate.

**Urodynamic study:** If the stress incontinence is the only symptom, there may not be any need for detailed urodynamic studies. **However, the indications of urodynamic study are**—(i) presence of mixed

symptomatology (GSI and OAB), (ii) associated frequency/nocturia/voiding difficulties, (iii) associated neuro-pathy or (iv) previous failed surgery.

### Uroflowmetry

The procedure is simple. The time period of total voiding is recorded by a stop watch and the amount of urine is estimated. **The normal flow rate is 15–25 ml/sec.** If the flow rate drops to less than 10 mL/sec, it indicates atonic bladder or urethral obstruction which can be confirmed by cystometry. The residual urine is to be estimated. Flowmeters can be used to produce a graphic record.

Low peak flow rate (< 15 mL/sec) associated with increased detrusor pressure (> 50 cm H<sub>2</sub>O) with prolonged voiding time indicates outflow obstruction.

**In stress incontinence,** urinary flow rate is normal with nil or insignificant residual urine.

If the uroflowmetry is normal, the next step is to submit the patient to cystometry to exclude detrusor instability or urge incontinence.

### Cystometry (Filling and Voiding Cystometry)

**Cystometry** evaluates the change in the bladder during filling and voiding (Table 24.3) to show the pressure volume relationship.

**TABLE 24.3** NORMAL FINDINGS IN CYSTOMETRY

• Residual volume	... 0–50 ml
• First sensation of urination	... 150–200 ml
• Capacity	... 400–600 ml
• Intravesical pressure on filling and standing	... 0–15 cm H <sub>2</sub> O
• Absence of systolic detrusor contraction	
• No leakage on coughing	
• Able to interrupt the urine flow on command	
• Maximum detrusor pressure during voiding	... < 50 cm H <sub>2</sub> O
• Peak urinary flow rate	... > 15 mL/sec.

**Principle**—Pressure catheters with electronic microtip transducer are used. One pressure catheter is introduced into the bladder. An additional catheter is placed in the bladder to fill it up. Another rectal or vaginal pressure catheter is introduced to measure the intra-abdominal pressure. Measurements of total intravesical pressure ( $P_{ves}$ ), intra-abdominal pressure ( $P_{abd}$ ) and true detrusor pressure ( $P_{det}$ ) are done. Rectal pressure ( $P_{abd}$ ) is subtracted from total intravesical pressure ( $P_{ves}$ ) to obtain true detrusor pressure ( $P_{det}$ ).

**Technique**—Patient sits on the study coach. Normal saline is infused inside the bladder through the filling catheter at the rate of 50–100 ml/min. Continuous recording of fluid volume infused and pressure change is done. Patient may be asked for standing, coughing or heel bouncing, for provocation. During voiding cystometry, filling catheter is removed. Total volume voided, urine flow rate and pressure ( $P_{abd}$ ,  $P_{ves}$  and  $P_{det}$ ) are recorded. Urge incontinence during filling cystometry indicates detrusor instability. Ambulatory urodynamic studies are thought to be more reliable.

In GSI, the cystometric evaluation is normal. The values are abnormal in detrusor instability and sensory urge incontinence.

**Abnormal cystometry:** (i) Urine leaks on coughing. No rise in detrusor pressure → GSI. (ii) Detrusor contractions during filling phase → Overactive bladder.

**Ambulatory monitoring** using microtip pressure transducers (twin channel) is found to increase the detection of overactive bladder. This test is more physiological.

### Urethral pressure profiles

For a continent woman urethral pressure must be higher than the bladder pressure. Urethral pressure profile test is performed with a special catheter having microtip pressure transducers, which is slowly pulled down from the bladder (filled with 250 ml of normal saline) along the urethra to outside. The transducer measures the intravesical and urethral pressure while it is pulled down. This pressure profile is represented as a curve called urethral pressure profile. Maximum urethral closure pressure is obtained by subtracting intravesical pressure from maximum urethral pressure. Unfortunately correlation between urethral pressure and severity of incontinence is poor.

#### Abnormalities are:

- Functional length of the urethra is decreased usually well below 3cm.
- Peak urethral pressure decreases both in supine and erect position.
- During strain, there is **significant lowering of the urethral closure pressure compared to intravesical pressure. This is pathognomonic of GSI.**

**Leak-point pressure test:** It gives an idea about sphincteric strength.

**Method:** Patient is asked to strain (Valsalva maneuver) when the bladder is filled up to a reasonable volume (200 mL)

to increase intravesical pressure. The minimum pressure (cm  $H_2O$ ) at which leakage is observed is recorded as ‘Valsalva (abdominal) leak-point pressure’. If no leakage is observed even at the highest pressure exerted (cm  $H_2O$ ), it is recorded as “no leakage”. It reflects maximum urethral closure pressure.

**Urethral sphincter dysfunction** is common in elderly women. Intrinsic sphincter deficiency (ISD) and urethral hypermobility often co-existent. ISD is defined when maximum urethral closure pressure is  $\leq 20$  cm  $H_2O$ . These women are benefitted with some obstructive procedures (see p.....) rather than traditional incontinence surgery.

**Cystoscopy and urethroscopy** — are not done as a routine but can be performed in selected cases. The common indications are (i) any history of hematuria; (ii) suspected neoplasm; (iii) suspected fistula; (iv) history of urgency and frequency to rule out interstitial cystitis and reduced bladder capacity.

**TABLE 24.4**    **DIAGNOSIS OF GSI**

- ♦ Clinical stress test—positive.
- ♦ Pad test—positive.
- ♦ Midstream urine analysis—normal.
- ♦ Urinary diary (volume frequency chart).
- ♦ Uroflowmetry—normal.
- ♦ Cystometry—normal.
- ♦ Significant lowering of urethral closure pressure during strain.
- ♦ Leak-point pressure (Valsalva) test—positive.
- ♦ Cystourethroscopy—negative finding.
- ♦ Videocystourethrography—bladder neck funneling.
- ♦ Transvaginal endosonography—altered anatomical relationship (descent) of urethrovesical junction and bladder base.

**Videocystourethrography (VCU)**—It is not a routine procedure. Special indications are (i) history of failure of previous surgery and (ii) to exclude diverticula and sacculation. Contrast media (35% urograffin) is used. Anatomical relationship of bladder neck, urethra and bladder base are assessed. Similar information can be obtained from transvaginal endosonography. MRI is superior for women with post-void dribble.

**Intravenous urography (IVU) and computed tomography urogram**—are not a routine procedure. **Indications are** (i) patient with hematuria, neuropathic bladder; (ii) to rule out congenital anomalies, calculi or fistulae.

**Transvaginal endosonography** is widely used to assess the anatomy of bladder neck, urethra, bladder wall thickness. Rectal, perineal and recently intra-urethral probes with three dimensional images are more informative.

### GRADE OF GSI (CLINICAL)

- Grade I** : Incontinence on cough or sneeze;  
**Grade II** : With mild exercise;  
**Grade III** : Even with change of posture.

### TREATMENT: ■ Preventive ■ Definitive

**Preventive:** Prevention includes avoidance of repeated childbirth trauma and delay in second stage of labor. Management of obesity (normal BMI), diabetes, chronic pulmonary and neurological diseases are the essential steps in prevention.

**Definitive:** The treatment aims at:

- Restoration of the function of the muscles of the urethrovesical junction.
- Strengthening the support of the urethra.

#### ♦ Conservative ♦ Surgical

### Conservative

To improve the tone of the pelvic floor muscles:

- Pelvic floor muscle exercise (supervised)—Basic principle is to strengthen the muscular part of rhabdosphincter and pelvic floor muscle. This will bring back the urethral pressure. Physiotherapy will not, however, strengthen the involuntary muscles of the bladder base and proximal urethra for which surgery is required.

The pelvic floor muscle training are in the form of drawing up the anus and tightening the vagina for stopping micturition. This should be done about 100 times a day for several months.

**The suitable cases are**—GSI of minor degree in cases of recent delivery having poor pelvic muscular tone.

- Use of vaginal devices: Pessaries, bladder neck support prosthesis.
- Use of vaginal cone with weight ranging from 20–100 g.
- Electrical stimulation—activation of the pelvic floor muscles by stimulation of pudendal nerves.
- Diet control in obese patient.

### Drugs

**Estrogen**—It may be useful in postmenopausal patient (p. 63).

**Sympathomimetic drugs ( $\alpha$ -adrenergic drugs)**— $\alpha$ -adrenergic drug improves the tone of urethra and bladder neck and thereby symptoms are improved. Imipramine 10–25 mg, orally twice daily or Ephedrine 15–30 mg, orally twice daily is effective. The periurethral levator ani muscles having both the type-I (slow-twitch) and type-II (fast-twitch) fibers are responsible for maintaining continence against sudden increased abdominal pressure.

**Paraurethral implants**—Implants using Teflon increase the functional length of the urethra. Periurethral injection of GAX collagen (glutaraldehyde cross-linked bovine collagen) is effective in GSI of minor degree. It prevents premature bladder neck opening.

### Surgery—The principles of surgery are:

- Restoration of normal anatomy to maintain bladder neck and proximal urethra as intra-abdominal structures. So that it lies within the abdominal pressure zone (Fig. 24.5).
- Strengthening the support of bladder neck and proximal urethra. This prevents the funnelling of vesicourethral junction in response to raised intravesical pressure.
- To increase the functional urethral length.

### The objectives of surgery are:

- To elevate the bladder neck so that it lies within the abdominal pressure zone (Fig. 24.5).
- To support the vesicourethral junction and to prevent its funneling in response to raised intravesical pressure.

Surgery for GSI varies widely. Procedures could be vaginal (anterior colporrhaphy) or abdominal (elevation of the bladder neck) or combined (endoscopic bladder neck suspension or sling procedures). No one single procedure can be ideal for all women. Individualization should be done depending on her age, severity of symptoms and ultimately the experience of the surgeon. Ideally all patients must be reviewed on the basis of her clinical presentation and urodynamic features.

### Kelly's cystourethroplasty (Howard Kelly-1914) (Fig. 24.7)

This is the common surgical procedure employed in GSI with success.

The technique consists of meticulous exposure of the urethra and the bladder neck vaginally. This is followed by plicating the pubocervical fascia with vertical mattress

sutures using ‘O’ catgut or Vicryl along the proximal urethra and bladder neck. These sutures will strengthen the urethral pressure and assist elevation of the bladder neck.

**Advantages are**—(i) simple procedure; (ii) less time is required; (iii) correction of co-existent cystocele; (iv) specially suited for women who are elderly and medically unfit for prolonged surgery.

**Disadvantage**—Long-term success rate is low (50–60%).

### ■ Retropubic Cystourethropexy (Colposuspension)

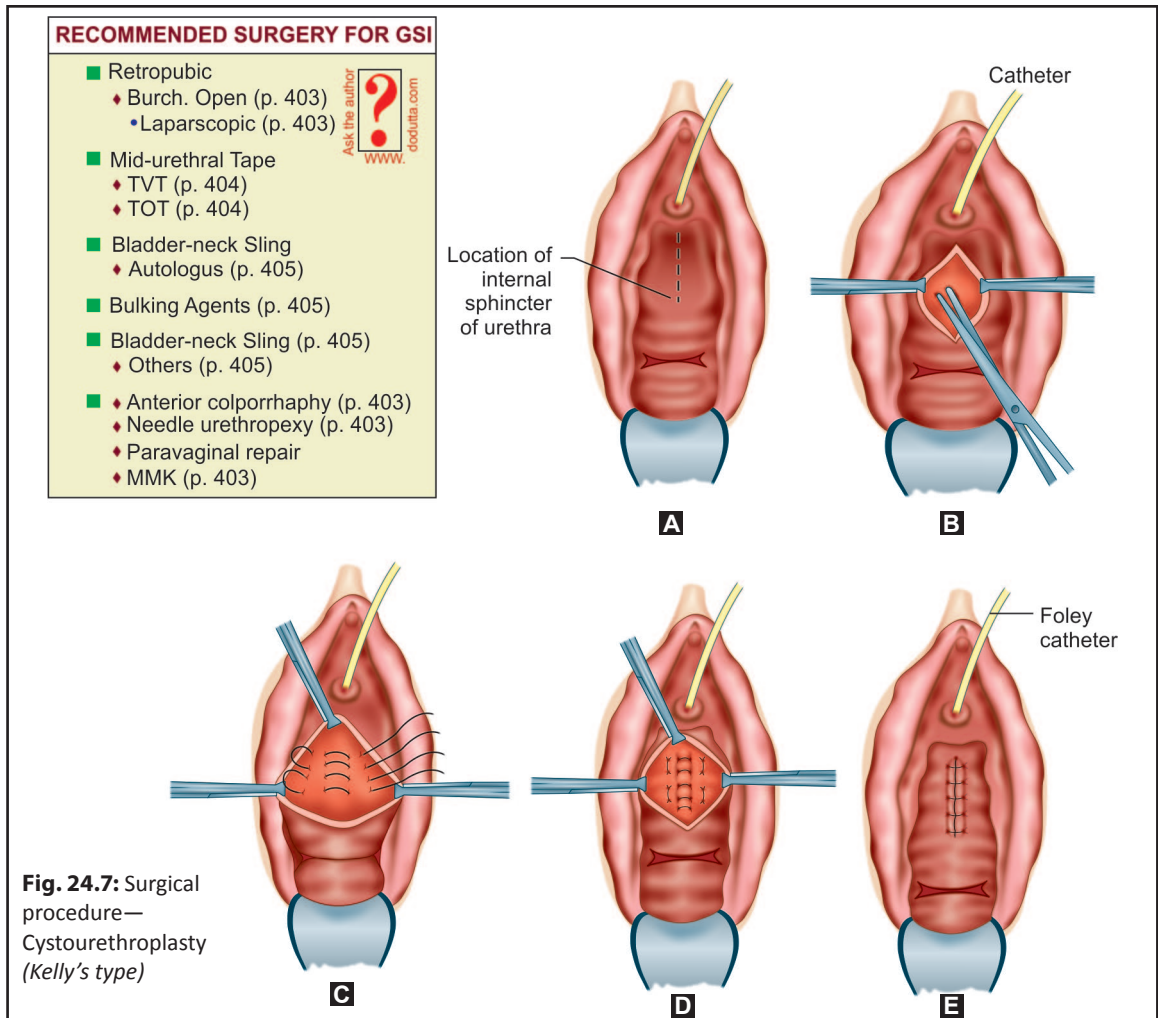
Principle of all these operations is to restore the normal anatomy (elevation) of the urethrovesical junction and to prevent the hypermobility of bladder

neck. Long-term (5 years) success rate for retropubic cystourethropexy is 80–90 percent.

There are several modifications of this operation. This procedure is performed suprapubically (through low abdominal incision) to reach the space of Retzius.

(a) In *Burch (1961) colposuspension* is considered the gold standard for GSI. The same endopelvic fascia and/or the lateral vaginal fornix is sutured to the ipsilateral iliopectineal ligament [Cooper’s ligament, Figs 24.8A]. Vaginal vault mobility is essential. Mild cystocele is corrected with this procedure.

**Laparoscopic bladder-neck suspension** has been done exactly by the same way as that of an open Burch. Success rate is similar to open method.



(b) *Marshall-Marchetti-Krantz (MMK 1949)*—The principle is to achieve elevation of the urethrovesical junction. Paraurethral and paravesical endopelvic fascia are stitched to the periosteum at the back of the symphysis pubis [Fig. 24.9A(b)].

**Complications are:** (i) hemorrhage during dissection of the space (ii) urethra and bladder neck injury due to injudicious placement of sutures; (iii) osteitis pubis (MMK procedure) (iv) voiding difficulty (v) detrusor instability (vi) enterocele formation (vii) VVF; (viii) failure and recurrence.

### Procedure

Dorsolithotomy position of the patient is made and urological drape is used. This helps the surgeon to operate with fingers in the vagina when required. Foley's catheter (18–20 size) is inserted. Dissection of bladder neck and upper urethra is done. Suture material used is either polyglycolic or ethibond. 3–4 sutures are placed on each side at 0.5 cm apart. Hemostasis is checked and sutures are tied. Drainage at the retropubic space is left and suprapubic catheter is inserted.

(c) *Endoscopic bladder-neck suspension (colposuspension)*—This procedure is simple and takes little time (Fig. 24.8B). There are various modifications of this operation following original description by **Pereyra** later on by **Raz** and **Stamey**. This procedure suspends the paraurethral and paravesical tissue on either side of bladder-neck to the rectus sheath. Bladder-neck region is dissected, through the vagina. A small suprapubic incision is made. Sutures are passed between vagina and anterior abdominal wall with a special needle under cystoscopic guidance. It primarily corrects the anatomic hypermobility of the bladder-

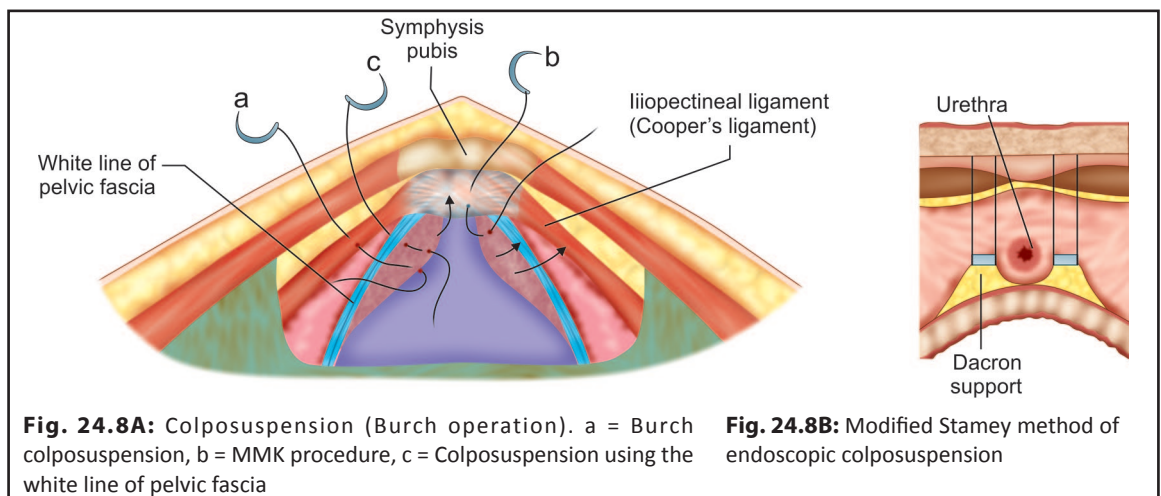
neck and urethra. Long-term success rate is around 50 percent. It is specially suited for elderly women.

### ■ Tension-free Midurethral Tape Procedures

◆ **Tension-free Vaginal Tape (TVT)**. It was devised by Petros (1993) and Ulmstem (1996). A marlex or Goretex tape is passed vaginally in a 'U' shape manner, under the midurethra to the either side with specially designed needles (Fig. 24.10). The needles are passed along the back of the pubic bone to the skin incision one on either side of the midline. Cystoscopy is done at the end of the procedure. Dissection is minimal and the tape is not sutured to any structure (tension-free). This acts by improving the midurethral support. TVT increases urethral coaptation by kinking the urethra during increased intra-abdominal pressure. This is less invasive and operative time is short. Common complications are: injury to bladder, retropubic hematoma, sling erosion and overactive bladder. Success rate is about 80–90 percent at 3 years.

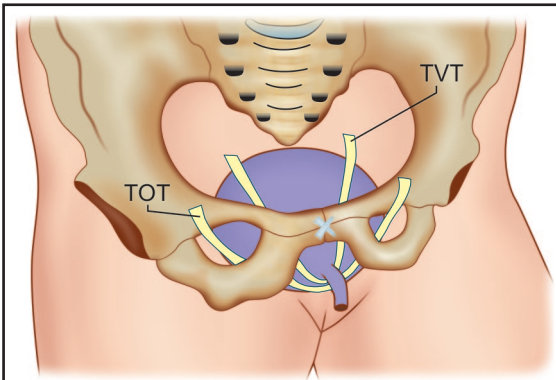
### ◆ Transobturator Tape (TOT)—Fig. 24.9

It is a minimally invasive procedure designed by Delorme (2001) to support the urethra as a hammock. A 2 cm incision is made in the vagina over the mid urethra. A tunnel is created out to the obturator foramen on either side. A multifilament microporous polypropylene tape is fed through the trocar which passes from the thighfold through the obturator foramen from outside to inside along the tunnel. It is finally brought round the vaginal incision. The procedure is repeated on the other side and the tape is left tension-free under the midurethra. It acts similar to



**Fig. 24.8A:** Colposuspension (Burch operation). a = Burch colposuspension, b = MMK procedure, c = Colposuspension using the white line of pelvic fascia

**Fig. 24.8B:** Modified Stamey method of endoscopic colposuspension



**Fig. 24.9:** Vaginal tape procedures showing retropubic and transobturator placement (TVT and TOT). The tunnels are seen for each procedure. The tape is left under midurethra without any tension to support it as a hammock

a natural hammock supporting the urethra. As it avoids the retropubic space, complications are less. It can be performed under the local anesthetic. There is no need to perform cystoscopy in TOT procedure. Success rate is similar to that of TVT. The same procedure can be performed from inside to outside (*de Laval-2003*).

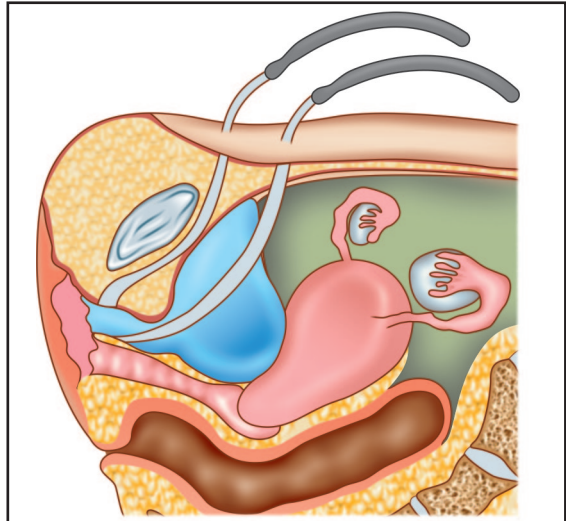
TVT and TOT procedures are commended as **Grade A** based on evidence level (see Box p. 403). Hospital stay, operation time are less. **Complications are:** Post-operative delayed voiding, urinary retention and infection may occur. Mesh erosion is a delayed complication.

#### ■ Sling procedure

These are not used as a primary procedure but may be employed for complicated cases of sphincter incompetence (failed surgery, reduced vaginal capacity and mobility). **Sling operations work by compressing the urethra at the urethrovesical junction.** The materials used for sling are— (i) organic, (autogenous)—rectus sheath (Aldridge procedure), fascia lata or (ii) inorganic—silastic, marlex, goretex. Combined approach, vaginal and abdominal (retropubic space) is made. Sling is passed around the bladder neck and is fixed to rectus sheath under **minimal tension to act as a hammock.** Overall success rate is 70 percent. **Disadvantages are** voiding difficulties, detrusor instability and sling erosion.

#### ■ Urethral bulking agents

Women having intrinsic sphincter deficiency (ISD) are treated with periurethral bulking agents. Selected



**Fig. 24.10:** TVT procedure with needles in position. The tape is left tension-free under the urethra

women with comorbid conditions that precludes anesthesia are specially suited. Commonly used **bulking agents are:** bovine collagen, teflon, calcium hydroxyapatite or polyacrylamide hydrogel. They are injected transurethral or periurethral under cystoscopic guidance. These agents work with an obstructive effect at the level of bladder neck. Compared to surgical procedures, results are for a short period only.

■ **Salvage procedures** are suggested where all other procedures have failed hopelessly. Only a small percentage of woman will need this.

#### The procedures are:

- ◆ Implantation of artificial sphincter.
- ◆ Urinary diversion.

### URGE INCONTINENCE

**INCIDENCE:** Urge incontinence due to detrusor overactivity (DO) is the **second common cause of urinary incontinence in an adult female**, the first being the GSI. However, in the elderly group, DO is commonest. DO is associated with GSI in about 10–15 percent of cases when urodynamic studies are done. Overall incidence of DO is 10 percent. It may be:

- Motor urge incontinence (overactive bladder)
- Sensory urge incontinence.

## OVERACTIVE BLADDER

### (Detrusor overactivity)

#### DEFINITION

An overactive bladder (OAB) is defined by the International Continence Society as “one that is shown objectively to contract spontaneously or on provocation during the filling phase while the patient is attempting to inhibit micturition”. Among the elderly women, overactive bladder is the commonest cause of urinary incontinence. Overall prevalence is 12–15% in women aged 40 years or more.

**ETIOLOGY:** The condition is largely functional and psycho-somatic in origin. The patient may be of emotionally labile type or passing through a phase of anxiety, stress. Sometimes, a hypertonic detrusor is even stimulated by bodily movements like getting up from sitting or lying position. **The causative factors are:**

- ◆ Idiopathic—majority.
- ◆ Psychosomatic.
- ◆ Following surgery for incontinence.
- ◆ Detrusor hyper-reflexia (neurogenic)—Multiple sclerosis, spinal injuries, early parkinsonism, diabetic neuropathy, cerebrovascular accident, etc.

**Detrusor overactivity** is basically due to acetylcholine induced stimulation of detrusor muscarinic receptors.

**PATHOPHYSIOLOGY:** The pathophysiology is obscure. There may be increased alpha-adrenergic activities causing increased detrusor contraction. The identical situation occurs in initiating an event of normal micturition—relaxation of urethral sphincter mechanism followed by contraction of detrusor muscle. Therefore it is thought that inappropriate detrusor contraction results when there is passage of urine into the proximal urethra due to incompetence of the bladder neck. Incompetent bladder neck → urine in proximal urethra → detrusor overactivity → incontinence. This occurs despite the effort of the individual to inhibit them. Other explanation is change in the detrusor smooth muscle property (due to atherosclerosis or neuropathy) that leads to inappropriate detrusor overactivity. The involuntary contraction occurs at any bladder volumes—either spontaneously or on provocation. There is preceding drop in urethral pressure.

**SYMPTOMS:** There is involuntary loss of urine without any prior urge to urinate. **Most common symptoms are urgency, frequency (>8 times/day),**

**TABLE 24.5 DRUGS USED IN OVERACTIVE BLADDER**

Nature	Drugs with dosage	Specially used to relieve	Common side effects	Contra-indications
Anti-cholinergic, Musculotropic relaxants	Oxybutynin chloride 5 mg PO thrice daily/ transdermal patch 3.9 mg twice/week.	<ul style="list-style-type: none"> <li>• Frequency</li> <li>• Urgency</li> </ul>	Dry mouth and skin, constipation, blurred vision	<ul style="list-style-type: none"> <li>• Glaucoma</li> <li>• Myasthenia gravis</li> <li>• Intestinal obstruction</li> <li>• Ulcerative colitis</li> <li>• Urinary retention</li> </ul>
Anti-muscarinic (Detrusor selective)	Tolterodine 1–2 mg, PO, BID	<ul style="list-style-type: none"> <li>• Frequency</li> <li>• Urgency</li> </ul>	— Do —	
Anti-muscarinic (Detrusor selective)	Solifenacin 5–10 mg, PO daily	<ul style="list-style-type: none"> <li>• Frequency</li> <li>• Urgency</li> </ul>	— Do — flatulence, chest pain	
Tricyclic (Antidepressants) • antimuscarinic • antihistaminic	Imipramine hydrochloride 50 mg at night.	Nocturia	Sedation, blurred vision, constipation	Coronary artery disease, hypertension.
Synthetic antidiuretic hormone analogue	DDAVP (Desamino deoxy arginine vasopressin) Intranasally 20–40 µg at night	Nocturnal enuresis	Fluid retention, hyponatremia. Rhinitis, Nausea.	Cardiac insufficiency.



TABLE 24.6 COMMON CAUSES OF URGENCY, URGE INCONTINENCE AND FREQUENCY OF MICTURITION	
<i>Gynecological</i>	<ul style="list-style-type: none"> <li>• Genitourinary prolapse</li> <li>• GSI</li> <li>• Menopause (tissue atrophy due to estrogen deficiency)</li> <li>• Pelvic mass</li> <li>• Pregnancy</li> </ul>
<i>Urological</i>	<ul style="list-style-type: none"> <li>• Urinary tract infection</li> <li>• Detrusor overactivity</li> <li>• Urethral syndrome</li> <li>• Interstitial cystitis</li> </ul>
<i>Medical</i>	<ul style="list-style-type: none"> <li>• Diabetes</li> <li>• Neurological lesions (multiple sclerosis, Alzheimer's disease)</li> <li>• Diuretic therapy</li> </ul>
<i>Psychological and idiopathic</i>	

**nocturia (>once/night) and bed wetting.** It should be remembered that the entity is too often associated with genuine stress incontinence (Table 24.7).

### SPECIAL INVESTIGATIONS

- Maintenance of urinary diary** (frequency volume chart see p. 401) for 4 days.
- A careful neurological examination** is made to exclude neurological disorders. One has to look for perineal sensation, pelvic muscle tone and bulbocavernous reflex to know the integrity of the sacral reflex S<sub>2,4</sub> (gentle clitoral stroke should produce anal sphincter contraction). Cranial nerves are examined.
- Midstream examination** of urine for culture and sensitivity test.
- Uroflowmetry:** In idiopathic group, the flow rate is high and the voiding time is short.
- Cystometry:**
  - Urge to pass urine is provoked at a much lower bladder filling of 100–175 mL of water.
  - True detrusor pressure increases by more than 15 cm of water during bladder filling with 200 ml of fluid.
- Cystourethroscopy:** This is to exclude the associated local pathology. The findings are normal or coarse trabeculation and diverticulae of bladder may be seen. Bladder capacity is reduced.

**Videocystourethrography (p. 401)** may reveal bladder trabeculation, diverticulae, vesicoureteric reflux.

### TREATMENT

#### General measures

- ◆ Psychosomatic problems should be treated by psychotherapy.
- ◆ Other medical problems (neurological, diabetes) should be properly attended.

#### Behavioral therapy

- ◆ To limit the intake of fluid to 1 liter/day.
- ◆ To reduce tea and coffee.
- ◆ Drugs – diuretics may be stopped if possible.
- ◆ Bladder retraining.

**When combined with stress incontinence, unstable bladder is to be treated first** before proceeding to surgical correction for stress incontinence.

Failed surgical treatment of stress incontinence is to be evaluated for the presence of unstable bladder.

**Bladder retraining:** This is useful in idiopathic group. This can be achieved by bladder drill, biofeedback or hypnotherapy.

**In bladder drill,** the patient is instructed to void by the clock at progressively increasing intervals over a 6-week time period. The initial response is quite good but the failure rate is high. Simultaneous antimuscarinic drug therapy improves the result. The drill is, however, not useful where neurologic disease is responsible for unstable bladder.

**Drug therapy:** Aims are to—(i) Inhibit bladder contractility, (ii) Increase bladder neck and urethral resistance.

The drugs (Table 24.5) have mostly got anticholinergic properties, thereby minimizes detrusor irritability. When administered along with bladder retraining, there is improvement of results.

**The other drugs used are:** Tospium chloride (atropine derivative with antimuscarinic effects) and Propiverine (anticholinergic and calcium channel blocker). Both are effective with less side effects.

In addition, the peri or postmenopausal women are often helped by estrogen therapy. It has shown to raise the sensory threshold.

**Intravesical therapy:** Capsaicin is a neurotoxin and is obtained from red chillies. Intravesical use

of capsaicin in 30% alcohol improve symptoms in patients with neurogenic detrusor over activity (multiple sclerosis).

**Other agents used are:** Resiniferatoxin is more potent than **Capsaicin** and less side effects of pain and burning). **Botulinum toxin** is a neurotoxin found to effective in intractable detrusor over activity.

**Surgery:** In intractable cases not relieved by drugs or bladder irritability due to neurologic disease, surgery may be of help. This is in the form of denervation (to interrupt the nervous pathways), augmentation cystoplasty (to increase bladder capacity) or urinary diversion (ideal conduit).

### SENSORY URGE INCONTINENCE (TABLE 24.7)

It is the involuntary leakage of urine per urethra accompanied by or immediately preceded by urgency.

Sensory urge incontinence is unassociated with detrusor contraction until urination is initiated. This occurs in a stable bladder and without any anatomic descent of urethra and bladder neck (Fig. 24.5).

**Mixed incontinence** of stress and urge may be present. Urodynamic studies are indicated in such a case (p. 400). In such a situation, symptoms are prioritized. Treatment is initiated towards the predominant symptoms. Conservative management should be tried first. However, in many women (50–60%), urge symptoms are improved after mid-urethral sling procedure (p.404).

### PAINFUL BLADDER SYNDROME (PBS)

It is a chronic inflammatory condition resulting in painful voiding. According to the International Continence Society (2002), **PBS is defined** as the

**TABLE 24.7** CLINICAL PRESENTATION AND DIAGNOSIS OF GSI AND URGE INCONTINENCE (SENSORY AND MOTOR)

	Stress	Urge incontinence (sensory)	Overactive bladder (OAB)
Definition	Involuntary escape of urine when intravesical pressure exceeds maximum urethral pressure in the absence of detrusor activity.	Unable to control the escape of urine once there is urge to void.	Leakage of urine due to detrusor over activity during the filling phase while the patient tries to inhibit it.
<b>Clinical presentation</b>			
• Stress prior to leakage	Always present	Nil	Nil
• Urge prior to leakage	Nil	Present	Present except in neurologic disease
• Awareness	Present	Present	Not present
• Control of loss	Can control	Can control with adequate encouragement	Cannot control despite strong encouragement
• Amount	Small	Large	Large
Midstream urine examination	Not informative	Evidences of infection	Usually non-informative
Uroflowmetry	Normal	Normal	High in idiopathic group
Cystometry	During strain, there is significant lowering of the urethral pressure. (Urethral pressure profile)	Normal	<ul style="list-style-type: none"> <li>• Urge to pass urine is provoked at much lower bladder filling.</li> <li>• Detrusor pressure is increased during filling.</li> </ul>
Cystourethroscopy	Normal	Offending factor present (Table 24.6)	Diminished bladder capacity
Lateral cystourethrography	Funneling of the proximal urethra.	Normal	Normal

presence of suprapubic pain related to bladder filling associated with other symptoms like frequency, in the absence of urinary tract infection or other pathology. Therefore urgency and pain are the two important diagnostic criteria of painful bladder syndrome. PBS is more prevalent in women than in men. **Interstitial cystitis**, is considered within the spectrum of PBS.

**Pathophysiology** is not known. The probable causes are: allergic, autoimmune, infective, toxins or leaky urothelium secondary to poor glycosaminoglycan layer.

**SYMPTOMS:** The clinical presentation varies widely. Symptoms include urgency, frequency, pelvic and lower urinary tract pain, dyspareunia and urinary incontinence.

**DIAGNOSIS:** PBS is a diagnosis of exclusion. On cystoscopy bladder frequently appears normal. On distension, petechial hemorrhages with oozing of blood from the surface is often seen. The differential diagnosis includes cystitis, trigonitis, tuberculosis, overactive bladder (OAB), bladder stones, or cancer, diverticula, and urogenital atrophy due to estrogen deficiency.

**TREATMENT:** As the diagnosis of PBS is difficult, treatment is directed to control the symptoms mainly.

Usually multiple interventions are done. Behavioral therapy, pelvic floor physical therapy, medications including hormones and bladder instillation are the treatment options.

- ◆ **Diet:** Alcohol, spices, citrus and caffeinated drinks are avoided as they are found to increase bladder inflammation and pain.
- ◆ **Drugs:** Urinary tract analgesics like hyoscyamine, phenyl salicylate may reduce urethral irritation. Pentosan Polysulphate, (100 mg tid) decreases urothelial permeability.
- ◆ **Surgery:** Bladder instillation therapy—with agents like steroids, sodium bicarbonate, botulinum toxin and dimethyl sulfoxide (DMSO), heparin has been found to be helpful. They need to be repeated weekly for a minimum of 6 weeks.
- **Hydrodistension:** Cystoscopy and hydrodistension of bladder is used in refractory cases of PBS. Glomerulations (petechial hemorrhages) may be seen in the bladder mucosa after hydrodistension.
- ◆ **Other treatments:** Tricyclic antidepressants, antihistamines, transcutaneous electrical nerve stimulation (TENS) antihistamines and acupuncture have been tried as neuromodulation.

## OVERFLOW INCONTINENCE

This occurs as a result of prolonged and neglected retention. Its mechanism is probably the over-distension of the bladder pulls open the internal sphincter. There may be compensatory detrusor hypertrophy.

The causes of overflow incontinence are the same as retention of urine which will be mentioned later in the chapter.

**URODYNAMIC FINDINGS:** **Uroflowmetry** reveals low flow rate and significant residual urine.

**Cystometry** reveals large capacity of the bladder and no rise of detrusor pressure during voiding.

**TREATMENT:** Surgical treatment of obstruction, if any, has to be done.

In cases of non-obstructive group, continuous catheter drainage is required. Intermittent clamping of the catheter is to be done prior to its removal. Following removal of the catheter, the residual urine has to be measured. It should not be more than 100 mL, preferably 50 mL. If more than 100 mL, the continuous drainage is reinstated.

## VOIDING DISORDER

**DEFINITION:** Difficulty in emptying the bladder is due to dysfunction of effective detrusor contraction and/or urethral sphincter mechanism. Anuria must be excluded. Normally for complete emptying of bladder, pelvic floor muscle (levator ani) and urethral sphincter (intrinsic rhabdosphincter) must relax and at the same time the detrusor must contract. Voiding difficulties may lead to **retention of urine** either **acute** (*inability to void more than 12 hours without catheterisation*) or **chronic** (*inability to empty the bladder more than 50 percent of its volume*).

## RETENTION OF URINE

### Causes

1. **Postoperative**—the commonest cause of retention in gynecology. This may occur following any operation on the vagina or perineum.

### The factors operating are:

- Obstructive due to postoperative edema in the neighborhood of the stitch line.
- Reflex spasm of bladder sphincters specially following anterior colporrhaphy.
- Reflex spasm of the levators following peri-neorrhaphy.

- Postoperative vaginal packing so often given following vaginal plastic operations.

**Following radical operation:**

- Denervation of the nerve supply of the bladder which travels from S<sub>2,3,4</sub> in the parametrium. This especially happens in Wertheim's operation, where extensive dissection of the parametrium is carried out.

**2. Obstructive conditions intrinsic to the urethra**

- Cicatricial stenosis following operations for repair of a urethrovaginal fistula or caruncle.
- Urethral angulation in cases with big cystocele.
- Bladder neck obstruction in postmenopausal women.
- After sling operation for stress incontinence.
- Cancer of the urethra, bladder neck, vulva, paraurethral cyst and tumor.

**3. Bladder detrusor may fail to contract**

- *Diseases*—multiple sclerosis (detrusor-sphincter dyssynergia), Parkinson's disease, neuropathy.
- *Drugs*—epidural anesthesia antidepressant, ganglion blockers.
- *Psychogenic*—hysteria, fear, modesty or shyness.

**4. Spasm of external sphincter**

- Nervousness and embarrassment or unaccustomed position.
- Perineal injuries due to operation.
- Urethritis.

**5. Gynecological causes (Table 24.8)**

A pelvic tumor or a mass in the pelvis may produce retention of urine. The diagnosis is usually made by giving attention to associated symptoms.

Retention is caused by the tumor interfering with the opening of internal sphincter of the urethra.

**Investigations** should be designed on the basis of etiology. Neurological examination should done as a routine.

**MANAGEMENT**—The treatment aims at:

- ◆ To relieve the symptom
- ◆ To treat the primary cause, when present.

**Acute retention:** Catheterization is to be done by using an autoclaved soft rubber catheter. Due aseptic precautions are to be taken as described in chapter 9 (p. 109).

If the patient fails to pass urine normally again after 8 hours, a self-retaining catheter is to be introduced for continuous drainage for at least 24–48 hours.

**Chronic retention:** In cases of chronic retention with marked over-distension of the bladder, it is better to put a self-retaining catheter, sooner the better. The number of days, it is to be kept, depends on the regaining of the bladder tone. This is determined by the amount of residual urine. Under no circumstances, the residual urine should exceed 100 mL, preferably below 50 ml.

## URINARY TRACT INFECTIONS

About 20 percent of all women have urinary tract infections (UTI) during their lifetime. The cases are often overlooked or ignored when the manifestations

**TABLE 24.8** GYNECOLOGICAL PATHOLOGY CAUSING RETENTION OF URINE

<i>Period of life</i>	<i>Associated disorders</i>	<i>Provisional diagnosis</i>
<b>Postmenarchal</b>	<b>Primary amenorrhea</b>	<b>Cryptomenorrhea (see p. 450)</b>
<b>Childbearing period</b>	Short period of secondary amenorrhea Menorrhagia	Retroverted gravid uterus (p. 200) Uterine fibroid impacted in POD (p. 286)
	No menstrual abnormality Irregular bleeding with pain Irregular bleeding with fever	Impacted ovarian tumor, cervical or broad ligament fibroid Pelvic hematocele Pelvic abscess (p. 175)

are minor. Moreover, in cases of asymptomatic bacteriuria, the infection remains in the urinary tract for a long period of time only to flare up to produce pyelonephritis in significant cases. As such, due attention should be paid even in asymptomatic patients having significant bacteriuria.

**PREVALENCE:** The prevalence of UTI upto 11 years is about 1 percent for boys and 3 percent for girls. In older girls, there is 10-fold increase in incidence as compared to boys. However, around 55 years the incidence in men and women is almost equal. The incidence of asymptomatic bacteriuria in female is about 4 percent. In pregnancy, it rises to 10 per cent.

TABLE 24.9

#### PROTECTIVE MECHANISMS AGAINST UTI

- ♦ Vulval apposition
- ♦ Apposition of the urethral mucosal folds
- ♦ Role of rhabdosphincter and pelvic floor muscles in maintaining urethral tone
- ♦ Inflow of urine from kidneys
- ♦ Protective bladder mucosa—presence of glycosaminoglycan layer prevent 'leaky' urothelium.
- ♦ Periodic voiding.

#### Factors for increased UTI in females:

- Short urethra (4 cm).
- Close proximity of the external urethral meatus to the areas (vulva and lower-third of vagina) contaminated heavily with bacteria.
- Sexual intercourse.
- Catheterization.

#### Aggravating factors during pregnancy are:

**Stasis of urine** in bladder → multiplication of bacteria → influx of the infected urine into the ureters and renal pelvis due to laxity of the vesicoureteral sphincters due to edema.

**ORGANISMS:** The commonest organism is *Escherichia coli* which is present in about 80–90 percent cases. Others are *Pseudomonas*, *Klebsiella*, *Proteus*, *Enterococci*, *Staphylococcus*, etc.

#### PREDISPOSING FACTORS

- **The lower urethra is colonized** with bacteria early in life but the bacteria are non-pathogenic. The protective effect of estrogen is also lacking.

- **Sexual intercourse** increases the ascent of the organisms from the lower urethra into the bladder.
- **Full bladder**—Provided bladder is kept empty completely and regularly, there is least chance of UTI. But certain circumstances favor atonicity of the bladder and urinary stasis as in pregnancy, puerperium and following major pelvic surgery or pelvic tumors producing outflow tract obstruction.
- **Catheterization**—This is probably the commonest cause of introducing the organisms from the lower urethra into the bladder whatever meticulous aseptic technique being taken. It has been observed that an indwelling catheter kept for 24 hours will produce bacteriuria in 50 percent and if left for 4 days will lead to bacteriuria in 100 percent of cases.
- **Hypoestrogenic state** as in postmenopausal women—when defence of the bladder and urethral mucosa is diminished.
- **Immunocompromising disorders** like diabetes mellitus, HIV.

#### ROUTES OF INFECTION

##### • Ascending • Hematogenous • Lymphatic

**Ascending**—is the commonest route of infection. The organisms from the anorectal region, lower vagina and vulva gain access to the urethra and thence to the bladder and kidneys.

**Hematogenous**—spread involving the kidneys is from the intestine or septic tonsils or other septic foci.

**Lymphatic**—spread is either from the adjacent ascending colon or genital organs (cervicitis). The kidneys may be affected from the bladder through periureteral lymphatics.

#### CLINICAL PRESENTATIONS

##### Asymptomatic Bacteriuria

**The term asymptomatic bacteriuria is used when a bacterial count of the same species over  $10^5$ /mL** in midstream specimen of urine on two occasions is detected without symptom of urinary infection. Counts less than  $10^5$ /mL indicate contamination of urine from the urethra or external genitalia. Nearly 30 percent of women with asymptomatic bacteriuria develop symptoms of UTI at a later date, if left untreated.

The entity is found related with high incidence of urinary tract abnormality—congenital or acquired. The woman runs a greater risk of developing chronic renal lesion later in life.

### Lower urinary tract infection

**Urethritis:** The symptoms include dysuria, frequency and urgency of micturition. Pain is typically scalding during the act of micturition. Urethra is tender on palpation. Often, pus may be squeezed out from the urethra.

Apart from clean catch midstream urine for culture, the expressed pus should be submitted for Gram stain for intracellular diplococci suggestive of gonorrhoea and culture for *Chlamydia* and *Neisseria gonorrhoeae*.

**Urethral syndrome:** It is a chronic non-specific form of urethritis probably due to urethral hypersensitivity. Infection should be excluded. The symptoms include dysuria, frequency, nocturia and urgency of micturition. Urethroscopy reveals reddened, chronically inflamed urethral mucosa and spasm of the bladder-neck. Benzodiazepines, Amitriptyline. Antibiotics (doxycycline) and estrogen replacement therapy give short-term relief. Progressive urethral dilatation has been the treatment of choice. Cryosurgery has been found to be effective to relieve the symptoms.

**Cystitis:** Cystitis is the most common of the urinary tract infections.

Symptoms include dysuria, frequency and urgency of micturition and pain. It produces painful micturition especially at the end of the act. There may be suprapubic tenderness and may have constitutional upset.

**Investigations:** Midstream clean catch urine for microscopic examination, culture and drug sensitivity is to be done in every case.

Microscopic examination usually reveals plenty of pus cells and occasional red blood cells. The culture will detect the organism within 24 hours and it usually exceeds  $10^5$ /mL of urine.

**Sterile pyuria** (negative culture in presence of plenty of pus cells) alerts the possibility of tubercular infection. In suspected tuberculosis, at least three early morning urine specimens have to be collected and cultured.

**The presence of red blood cells in the absence of pus cells** or negative culture suggests pathology other than infection.

Apart from midstream urine, other methods of collection of urine are—suprapubic needle aspiration and urethral catheterization.

**Pyelitis:** Symptoms include acute aching pain over the loins and fever with chills and rigor. There is frequency of micturition and dysuria. There may be anorexia, nausea or vomiting.

The patient looks ill with dry tongue. The pulse rate is proportionate with temperature. There is varying degrees of loin tenderness.

**Investigations:** Midstream urine examination reveals plenty of pus cells and red blood corpuscles. Culture will detect the organism.

- Blood examination shows leucocytosis; urea and creatinine level may be raised.

In chronic or recurrent urinary tract infections, more extended investigative protocols such as intravenous pyelography and cystoscopy is indicated.

### PREVENTION

The following guidelines are prescribed in an attempt to prevent infection to lower urinary tract.

- **To maintain proper perineal hygiene.** This consists of cleansing the vulvar region at least daily, wiping the rectum away from the urethra.
- **Prophylaxis of the coital infection**—To void urine immediately following coitus. A single dose of nitrofurantoin 50 mg following coital act is an effective means of prophylaxis. This is helpful in women who have history of postcoital exacerbation of infection.
- **Catheter infection**—Whatever aseptic measures are taken, use of catheter favors introduction of infection. Catheter should preferably be avoided.
- **Bacteriological monitoring** of urine should be done, periodically and after removal, when an indwelling catheter is used for a long time
- Plenty of fluid intake should be encouraged.

### Management principles :

- ◆ To isolate the organism and drug sensitivity, if time permits prior to antimicrobial therapy.
- ◆ To administer effective drug for an adequate length of time (7–10 days).
- ◆ To prevent reinfection.
- **General measures:** Plenty of water to drink (3–4 liters a day) for proper hydration.
- **Antimicrobial agents:** Appropriate antibiotic to be started for an adequate length of time (7–10 days).

**One negative culture two weeks after the course of therapy is considered cure.**

■ **Prevention of reinfection:** Presence of any organic pathology is to be treated. Outflow tract obstruction, if present, may have to be dilated.

In reinfection, the appropriate drug is to be continued for at least 2 weeks. This is to be followed by nitrofurantoin 50 mg or norfloxacin 400 mg daily for 4–6 months.

## DYSURIA

**DEFINITION:** Dysuria or difficulty in passing urine is a common symptom in gynecology. The difficulty may be painful—or merely mechanical.

### CAUSES :

#### Mechanical factors:

- All the factors leading to retention of urine are usually preceded by dysuria (p. 411).
- Uterine prolapse with big cystocele.

#### Factors for Painful Micturition:

■ **Causes in the bladder:** The bladder lesions include—cystitis due to infection with *Esch. coli* or tuberculosis, stone, radiation drug induced (cyclophosphamide), eosinophilic or due to papilloma or carcinoma.

Cystitis or other lesions in the bladder cause painful micturition especially at the end of the act.

- **Causes in the urethra:** Here, the pain is scalding during the act. Urethral lesions responsible are—urethritis due to specific or non-specific organisms, tender caruncle, prolapse of urethral mucosa, kraurosis, urethral carcinoma, etc.
- **Trauma** during catheterization, operation or due to trauma of the external urethral meatus during coitus “honeymoon cystitis”.
- **Postoperative** causes of dysuria may be due to:
  - Cystitis or urethritis
  - Precipitated by catheterization
  - Trauma around the bladder neck and urethra.

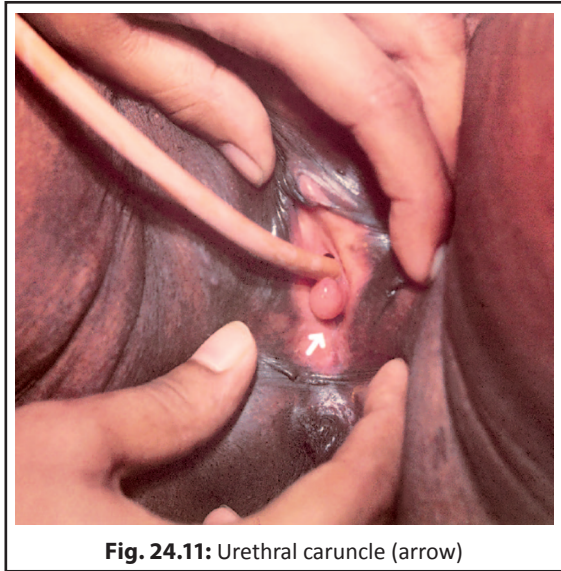
## FREQUENCY OF URINATION

See p. 407, Table 24.6.

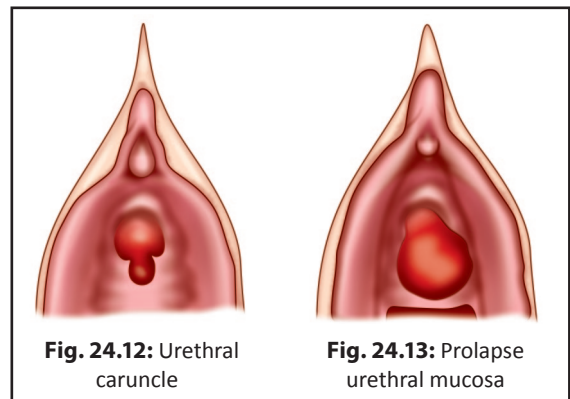
## URETHRAL CARUNCLE

(Figs 24.11 and 24.12)

**DEFINITION:** It is a benign lesion of the urethra, clinically characterized by a pedunculated, reddish-looking mass protruding out of the external urethral meatus.



**Fig. 24.11:** Urethral caruncle (arrow)



**Fig. 24.12:** Urethral caruncle

**Fig. 24.13:** Prolapse urethral mucosa

**PATHOGENESIS:** It is presumably infective in origin and usually confined to postmenopausal women. It is usually single and arises from the posterior wall of the urethra.

**Naked eye:** The size is small, usually not exceeding 0.5 cm. It looks reddish (Fig. 24.11).

**Microscopic appearance:** It consists of vascularized granulation tissue covered by transitional or stratified squamous epithelium. **Three types are described** —granulomatous, angiomatous and papillomatous depending upon the histologic appearance.

**CLINICAL FEATURES:** The patients are usually postmenopausal.

**Symptoms:**

- Irregular bleeding per vaginum.
- Urinary complaints such as painful micturition, frequency or even retention.
- Dyspareunia.

**Signs:** A small angry red-looking, pea-shaped mass protruding out of the external urethral meatus. It may be tender or bleeds to touch.

**Differential Diagnosis**

The lesion is often confused with prolapse of the urethral mucosa and urethral malignancy (Fig. 24.13).

**TREATMENT**

Excision biopsy is the definitive surgery. The raw area may be sutured or cauterized. Continuous bladder drainage is required for a few days.

**KEY POINTS**

- ▶ The sympathetic supply to the bladder is concerned mainly with the filling and storage of urine. The parasympathetic is important for normal voiding.
- ▶ Parasympathetic nervous system (acetylcholine receptor) activate detrusor contraction. Sympathetic system in bladder ( $\beta$  receptor) causes relaxation and in the urethra ( $\alpha$  receptor) causes contraction.
- ▶ Urethral sphincters for continence are (i) intrinsic rhabdosphincter urethrae (containing slow twitch fibers) and extrinsic sphincter of levator ani (containing both slow and fast twitch fibers).
- ▶ Intrinsic urethral sphincter maintains urethral closure at rest, where as extrinsic sphincter maintain urethral closure during stress (cough, sneeze).
- ▶ Normally urethral closure pressure is maintained effectively. Any rise in intra-abdominal pressure transmitted equally to the bladder and the proximal urethra. This mechanism maintains the pressure gradient [see Figs. 24.5(a) and (b)].
- ▶ Approximately one-third of the resting urethral pressure is due to rhabdosphincter effects, one-third to smooth muscle effects and one-third to submucous vascular plexus of the urethra.
- ▶ The intravesical pressure is about 10 cm of water and is much lower than the urethral pressure (20–50 cm of water).
- ▶ Normally first sensation of urination is felt at 150–200 mL of bladder volume and functional bladder capacity is 400–600 mL.
- ▶ Continence is a state of balance between urethral closure pressure versus detrusor contraction pressure.
- ▶ Urinary incontinence is either urethral or extraurethral in origin (see Table 24.1).
- ▶ Nearly 30 percent of women suffer from some degree of urinary incontinence during their life time.
- ▶ GSI is defined as involuntary urethral loss of urine when intravesical pressure exceeds the maximum urethral pressure in the absence of the detrusor activity.
- ▶ Genuine stress incontinence (GSI) is due to anatomic hypermobility of bladder-neck and urethra (80%) and also due to urethral intrinsic sphincteric incompetence (20%).
- ▶ GSI is often confused with urge incontinence (sensory) and detrusor instability (motor) (Tables 24.2 and 24.7). During strain, there is significant lowering of the urethral closure pressure. This is pathognomonic of GSI.

*Contd...*



*Contd...*

- Thorough urodynamic investigations are essential in certain conditions (see p. 400) to get maximum benefit of treatment. However, it is not recommended as a routine neither it is to be done before any conservative treatment.
- Patient with urodynamic features of both GSI and OAB, OAB is to be treated prior to continence surgery.
- UTI must be treated before any urodynamic investigation. A urine dipstick test is done for all women with UI. Women with urine tests positive for both leucocytes and nitrites should have a midstream urine specimen for culture and sensitivity.
- IVU, cystourethroscopy or videocystourethrography should not be performed as a routine investigation.
- USG (transvaginal, perineal or intraurethral) is becoming more informative (see p. 402) in assessing a patient with urinary symptoms.
- Cystometry confirms the diagnosis of DO but GSI is a diagnosis of exclusion.
- Vaginal delivery causes damage to anatomical supports of the bladder neck, urethra and the pelvic floor nerves. It is an important cause for genitourinary prolapse and GSI.
- Individualization of a patient for a particular type of incontinence surgery is essential. Important deciding factors are (i) severity of symptoms, (ii) patient's age, (iii) associated complications, (iv) experience of the surgeon.
- The objectives of the surgical treatment are to elevate the bladder-neck along with proximal urethra and to support the vesicourethral junction to prevent funneling during stress. Surgical treatment of GSI vary depending on an individual patient (p. 403).
- Approximate success rate (5 years) for individual procedure is: cystourethroplasty 50–60 percent; cystourethropexy (MMK) 80–90 percent, Burch 85–90 percent, endoscopic bladder neck suspension 50 percent.
- In TVT procedure a macroporous tape made of polypropylene is placed U-shaped under the midurethra, lying tension-free (see p. 404). Overall cure rate of this procedure is 84–90 percent. Injury to the bladder (during trocar insertion), hemorrhage in the retropubic space, tape rejection or erosion are the complications.
- TOT is a simple procedure where a polypropylene macroporous tape is placed under the mid-urethra. The tape passes through the obturator foramen either from outside in (TOT) or from inside-out (TVT-O). It maintains the natural suspension of the urethra. As it avoids the retropubic space, the complications are less. It can be done under local anesthetic. Success rate is similar to that of TVT (p. 404).
- Recommended surgical procedures for GSI as based on evidence are as mentioned in p. 403.
- Detrusor overactivity is defined as an unstable bladder, objectively to contract spontaneously or on provocation during the filling phase while the patient is attempting to inhibit it. It is the second common cause of urinary incontinence in adult female, the first being GSI. It is the most common cause in elderly women. The diagnosis is based on urodynamic assessment.
- Intrinsic urethral sphincter dysfunction is best treated by periurethral collagen injection, a sling procedure or by an artificial sphincter.
- The etiology of overactive bladder (OAB) is largely functional and psychosomatic in origin. True detrusor pressure increases by more than 15 cm of water during bladder filling even with 100-175 mL of fluid.
- Overactive bladder (OAB) is a symptomatic diagnosis whereas detrusor overactivity is a diagnosis confirmed on cystometry. OAB has got spontaneous remissions and exacerbations.
- Bladder retraining, behavioral therapy and anticholinergic drugs (p. 407) are effective to control symptoms of OAB on majority of patients. Dosage of anticholinergic drugs need to be increased gradually to a level as to produce side effects (Table 24.5). Anticholinergic agents decrease detrusor activity.

*Contd...*

Contd...

- Oxybutynin should be the first choice for women with OAB or mixed UI if bladder training is ineffective. When oxybutynin is not tolerated, darifenacin, solifenacin, tolterodine, trospium or transdermal formulation of oxybutynin is considered.
  - PBS (p. 408) is a chronic inflammatory condition associated with urgency and painful voiding. It is a diagnosis of exclusion. Urinary tract infection must be ruled out. It is associated with altered epithelial permeability, mast cell activation and upregulation of sensory afferent nerves. Treatment is directed to control the symptoms. Diet and drugs (to control inflammation), surgery and neuromodulation therapy are the options.
  - Sensory urge incontinence is usually associated with infection or foreign body. The treatment is by appropriate antibiotic therapy and HRT in postmenopausal women.
  - Important causes of urgency, urge incontinence and frequency of micturition are gynecological, urological or medical disorders (Table 24.6).
  - There is increased risk of UTI in females than in males (see p. 394). The commonest organism is *Escherichia coli*.
  - Recurrent UTI need to be investigated with cystoscopy and intravenous urography. In a chronic case, following an appropriate drug therapy for 2 weeks, nitrofurantoin 50 mg or norfloxacin 400 mg daily bed time for 3–4 months is to be continued.
  - Urethral syndrome is a chronic form of painful micturition due to urethral hypersensitivity in the absence of UTI.
  - Negative culture in presence of plenty of pus cells alerts to the possibility of tubercular infection.
  - The presence of red blood cells in the absence of pus cells or negative culture suggests pathology other than infection.
  - Apart from midstream urine, other methods of collection of urine are suprapubic needle aspiration and urethral catheterization.
  - Voiding disorders are defined as difficulty in emptying bladder due to dysfunction of effective detrusor contraction and/or sphincter mechanism.
  - Low peak flow rate (< 15 mL/sec) associated with increased detrusor pressure (> 50 cm of H<sub>2</sub>O), with prolonged voiding time indicates outflow obstruction.
  - Retention of urine may be acute (inability to void over 12 hours without catheterization) or chronic (inability to empty bladder more than 50% of its volume). Desire to void is felt at a bladder volume of 150–200 mL and functional bladder capacity is 400–500 mL.
  - Common causes of retention of urine in gynecology are : postoperative, retroverted gravid uterus, impacted uterine fibroid or ovarian tumor in the POD, cervical fibroid or cryptomenorrhea.
- Investigations and management (p. 410) for retention of urine should be designed according to the etiology (Table 24.8).
- Urethral caruncle is a benign lesion arising from posterior wall of the urethra. It is commonly seen in postmenopausal women. Histologically it may be granulomatous, angiomatous or papillomatous in type. Excision biopsy is the definitive surgery.

# Genital Fistulae

## GENITOURINARY FISTULA

### DEFINITION

A fistula is an abnormal communication between two or more epithelial surfaces. **Genitourinary fistula** is an abnormal communication between the urinary and genital tract either acquired or congenital with involuntary escape of urine into the vagina.

The incidence is estimated to be approximately 0.2–1 percent among gynecological admissions in referral hospitals of the developing countries. The incidence is however, much less in the affluent countries.

**TYPES:** The communication may occur between the bladder, urethra or ureter and genital tract.

### Following are the Types of Fistula (Fig. 25.1)

#### Bladder

- ◆ Vesicovaginal (commonest)
- ◆ Vesicourethrovaginal
- ◆ Vesicouterine
- ◆ Vesicocervical.

#### Urethra

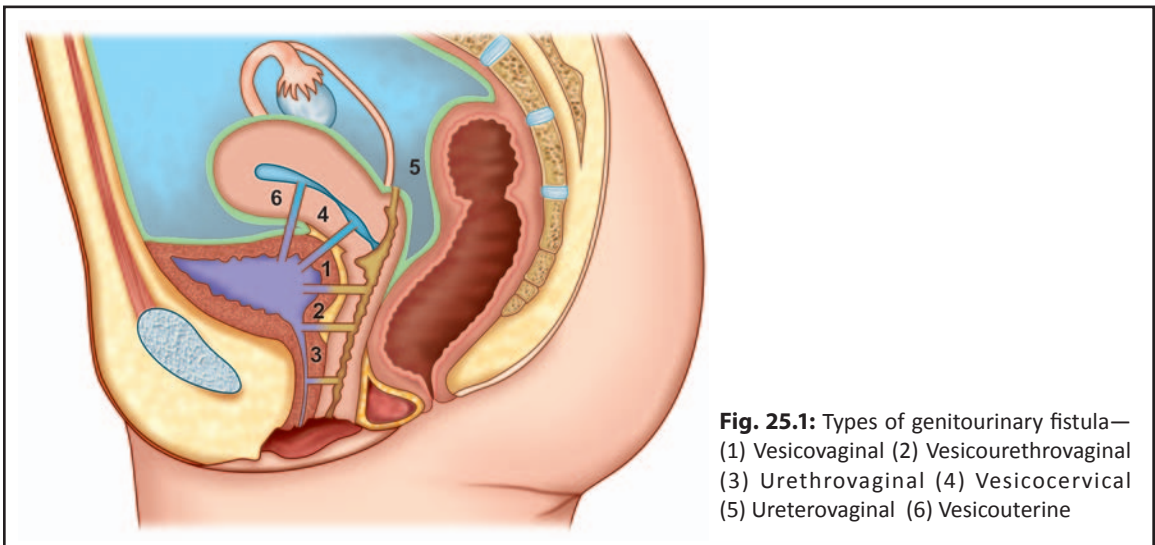
- ◆ Urethrovaginal.

#### Ureter

- ◆ Ureterovaginal
- ◆ Ureterouterine
- ◆ Ureterocervical.

### VESICOVAGINAL FISTULA (VVF)

**DEFINITION:** There is communication between the bladder and the vagina and the urine escapes into the vagina causing true incontinence (Fig. 25.2). **This is the commonest type of genitourinary fistula.**



**Fig. 25.1:** Types of genitourinary fistula— (1) Vesicovaginal (2) Vesicourethrovaginal (3) Urethrovaginal (4) Vesicocervical (5) Ureterovaginal (6) Vesicouterine

**CAUSES: • Obstetrical • Gynecological**

**Obstetrical:** In the developing countries, the commonest cause is obstetrical and constitutes about 80–90 percent of cases, as opposed to only 5–15 percent in the developed countries. The fistula may be due to ischemia or following trauma.

**Ischemic:** It results from prolonged compression effect on the bladder base between the head and symphysis pubis in **obstructed labor** → ischemic necrosis → infection → sloughing → fistula. **Thus, it takes few days (3–5) following delivery to produce such type of fistula.**

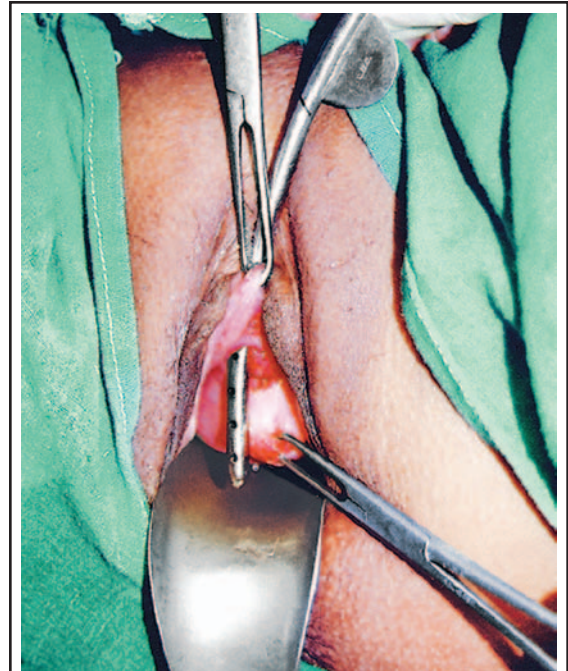
**Traumatic:** This may be caused by:

- ♦ **Instrumental vaginal delivery** such as **destructive operations** or **forceps** specially with Kielland. The injury may also be inflicted by the **bony spicule** of the fetal skull in **craniotomy operation**.
- ♦ **Abdominal operations** such as hysterectomy for rupture uterus or Cesarean section specially a repeat one or for cesarean hysterectomy. The injury may be direct or ischemic following a part of the bladder wall being caught in the suture.

**This type of direct traumatic fistula usually follows soon after delivery.**

**Gynecological:** Although a rarity in the developing countries, it is the commonest type met in the developed ones and accounts for more than 80 percent of fistulae.

- **Operative injury** likely to produce fistula includes operations like anterior colporrhaphy, abdominal hysterectomy for benign or malignant lesions or removal of Gartner's cyst.
- **Traumatic**—The anterior vaginal wall and the bladder may be injured following fall on a pointed object, by a stick used for criminal abortion, following fracture of pelvic bones or due to retained and forgotten pessary.
- **Malignancy**—Advanced carcinoma of the cervix, vagina or bladder may produce fistula by direct spread.
- **Radiation**—There may be ischemic necrosis by endarteritis obliterans due to radiation effect, when the carcinoma cervix is treated by radiation. Apart from overdose or malapplication, it may occur even with accurate therapy. It takes usually long time (1–2 years) to produce such fistula.



**Fig. 25.2:** Midvaginal obstetric fistula (VVF). It was of moderate size to allow a metal catheter which is clearly visible [By courtesy Dr. P. Mukherjee, Professor, Dept of G&O, IPGME&R, Kolkata]

- **Infective**—Chronic granulomatous lesions such as vaginal tuberculosis, lymphogranuloma venereum, schistosomiasis or actinomycosis may produce fistula.

**Thus, the fistula tract may be lined by** fibrous, granulation tissue, infective extension or malignant cells.

**TYPES: Fistula may be classified as**—(i) Simple (Healthy tissues with good access) or (ii) Complicated (tissue loss, scarring, difficult access, associated with RVF).

**Depending upon the site of the fistula,** it may be:

- **Juxtacervical (close to the cervix)**—The communication is between the supratriangular region of the bladder and the vagina (vault fistula).
- **Midvaginal**—The communication is between the base (trigone) of the bladder and vagina.
- **Juxtaurethral**—The communication is between the neck of the bladder and vagina (may involve the upper urethra as well).

- **Subsymphyseal**—Circumferential loss of tissue in the region of bladder neck and urethra. The fistula margin is fixed to the bone.

### CLINICAL FEATURES

**Patient profile:** In the developing countries, obstetrical fistula being common, the patients are usually young primiparous with history of difficult labor or instrumental delivery in recent past. In others, it is related with the relevant events.

### Symptoms

- Continuous escape of urine per vaginum (true incontinence) is the classic symptom. The patient has got no urge to pass urine. However, if the fistula is small, the escape of urine occurs in certain positions and the patient can also pass urine normally. Such history has got a positive correlation with the related events mentioned in the etiology.

Leakage of urine following surgical injury occurs from the first postoperative day whereas in obstetric fistulae symptoms may take 7–14 days to appear urethral fistulae that are situated high up, often presents with features of stress incontinence.

Women with vesicocervical or vesicouterine fistulae may hold urine at the level of the uterine isthmus and may remain continent. But they complain of cyclical hematuria at the time of menstruation (menouria). Sometimes women may complain of intermittent leakage of urine.

- There is associated pruritus vulvae.

### Signs: *Vulval Inspection*

- Escape of watery discharge per vaginum of ammoniacal smell is characteristic.
- Evidences of sodden and excoriation of the vulval skin.
- Varying degrees of perineal tear may be present.

**Internal examination:** If the fistula is big enough, its position, size and tissues at the margins are to be noted.

At times, there may be varying degrees of vaginal atresia so as to make the fistula inaccessible.

**Speculum examination:** A Sims' speculum in Sims' position gives a good view of the anterior vaginal wall when the vagina becomes ballooned up by air because of negative suction.

- The size, site and number of fistula.
- Often, the bladder mucosa may be visibly prolapsed through a big fistula (Fig. 25.2).
- A tiny fistula is evidenced by a puckered area of vaginal mucosa.

### Associated clinical features that may be present in cases of such fistula are:

- Secondary amenorrhea of hypothalamic origin (Menstruation resumes following successful repair).
- Foot-drop due to prolonged compression of the sacral nerve roots by the fetal head during labor.
- Complete perineal tear or rectovaginal fistula.

### CONFIRMATION OF DIAGNOSIS

The diagnosis is most often made from the typical history and local examination. But, sometimes confusion arises in a case of tiny fistula for which additional methods are to be employed (Table 25.2).

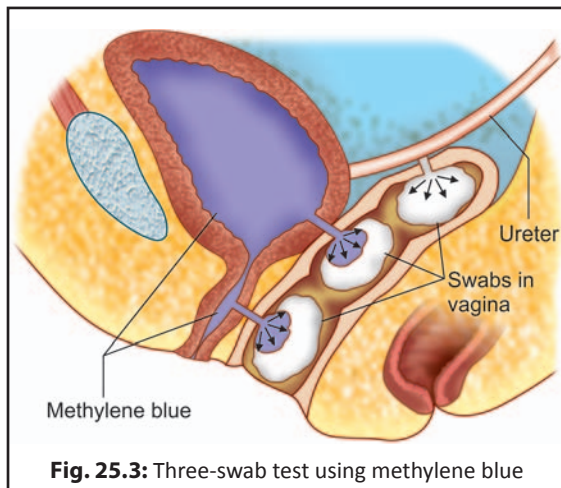
**The confused clinical conditions are** stress incontinence, ureterovaginal and urethrovaginal fistula.

To confirm the diagnosis, following are helpful:

- EUA is needed for better evaluation.
- The patient is placed in Sims' or knee chest position and while examining the anterior vaginal wall, bubbles of air are seen through the small tiny fistula when the woman coughs.
- **Dye test**—A speculum is introduced and the anterior vaginal wall is swabbed dry. When the methylene blue solution is introduced into the bladder by a catheter, the dye will be seen coming out through the opening.
- A metal catheter passed through the external urethral meatus into the bladder when comes out through the fistula not only confirms the VVF but ensures patency of the urethra.
- **Three-swab test**—The three-swab test not only confirms the VVF but also differentiates it from ureterovaginal and urethrovaginal fistula.

### Procedure of Three Swab Test (Fig. 25.3)

Three cotton swabs are placed in the vagina—one at the vault, one at the middle and one just above the introitus. The methylene blue is instilled into the bladder through a rubber catheter and the patient is asked to walk for about 5 minutes. She is then asked



**Fig. 25.3:** Three-swab test using methylene blue

to lie down and the swabs are removed for inspection (Table 25.1).

**TABLE 25.1** THREE-SWAB TEST

Observation	Inference
Upper most swab soaked with urine but unstained with dye. The lower two fistula swabs remain dry	Ureterovaginal fistula
Upper and lower swabs remain dry but the middle swab stained with dye	Vesicovaginal fistula
The upper two swabs remain dry but the lower swab stained with dye	Urethrovaginal fistula

**TABLE 25.2** SUMMARY IN CLINICAL DIAGNOSIS

Big fistula	<ul style="list-style-type: none"> <li>• Visible fistula tract</li> <li>• Obvious escape of urine</li> </ul>
Tiny fistula	<ul style="list-style-type: none"> <li>• Dye test</li> <li>• In knee-chest position escape of bubbles of air when the patient coughs</li> <li>• Three-swab test</li> </ul>
Confusion in diagnosis	<ul style="list-style-type: none"> <li>• Cystoscopy</li> </ul>

## INVESTIGATIONS

### Imaging studies

- **Intravenous urography:** For the diagnosis of ureterovaginal fistula.
- **Retrograde pyelography:** For the diagnosis of exact site of ureterovaginal fistula.
- **Cystography:** Not done in cases with VVF. It may be done in a complex fistula or vesicouterine fistula where uterine cavity (lateral view) may be seen.
- **Sinography** (Fistulography) for intestinogenital fistula.
- **Hysterosalpingography** (Lateral view) for diagnosis of vesicouterine fistula when there is history of hematuria (Youssef's Syndrome).
- **Ultrasound, CT and MRI** are done for evaluation of complex fistulae. Where involvement of ureter or intestines are there.
- **Endoscopy studies:** Cystourethroscopy is not routinely done. The added information are: Exact level and location of the fistula and its relationship to ureteric orifices and bladder neck.
- **Examination under anesthesia** is helpful for identification of small fistulae. A metallic probe may be used for exploration (see Fig. 25.2).

## TREATMENT OF OLD VVF

### ◆ Preventive ◆ Operative

**PREVENTIVE:** Obstetric fistula in the developing world can be prevented with safe motherhood initiative (**WHO-1987**). Women with obstetric VVF is considered as a 'near-miss' maternal death. Gynecological fistula—can be prevented with better anticipation and improved surgical skill.

### The following guidelines are prescribed:

- ◆ Adequate antenatal care is to be extended to screen out 'at risk' mothers likely to develop obstructed labor.
- ◆ Anticipation, early detection (partograph) and ideal approach in the method of delivery in relieving the obstruction.

- ◆ Continuous bladder drainage for a variable period of about 5–7 days following delivery either vaginally or abdominally in a case of longstanding obstructed labor.
- ◆ Care to be taken to avoid injury to the bladder during pelvic surgery—obstetrical or gynecological.

**Immediate management:** Once the diagnosis is made, continuous catheterization for 6–8 weeks is maintained. This may help spontaneous closure of the fistula tract. Unobstructed outflow tract helps epithelialization, provided the tissue damage is minimum. The management of genitourinary fistula needs a team approach both by the gynecologists, nursing staff and the urologists. **These socially ostracized women need realistic counseling. Other-wise treatment failure may cause further devastation.**

**OPERATIVE:** local repair of the fistula is the surgery of choice.

- Preoperative assessment
- Preoperative preparations
- Definitive surgery.

### Preoperative Assessment

- Fistula status—Assessment is done as regards the site, size, number, mobility and status of the margins of the fistula.
- Urethral involvement is assessed by introducing a metal catheter through external urethral meatus into the bladder.
- To ascertain the position of the ureteric openings in relation to a big fistula, cystoscopy is indicated. The patient is placed in knee-chest position when the bladder becomes distended with air (Kelly's air cystoscopy).
- **To exclude associated rectovaginal fistula or complete perineal tear.**
- Complete hemogram and urea, creatinine (renal function) estimation are done.

### Preoperative Preparations

- As the patients are usually from poor socio-economic status, and socially ostracized the improvement of the general condition is essential prior to surgery.

- Local infection in the vulva should be treated by application of silicone barrier cream or glycerine.
- Urinary infection, if any, should be corrected beforehand. It is difficult to collect urine for culture and sensitivity. It is preferable to collect urine for the same from the indwelling catheter kept following the surgical repair. Preoperative collection is best to be done through ureteric catheterization. Urine collected through vaginal speculum will not serve the purpose because of contamination. It is advised to start urinary antiseptics at least 3–5 days prior to surgery.

### Definitive surgery—(Old obstetric VVF).

#### Time

The ideal time of surgery is after 3 months following delivery. By this time, the general condition improves and local tissues are likely to be free from infection. Further delay is likely to produce more fibrosis and unnecessary prolongs the misery of the patient. Early repair may compromise the success.

Surgical fistula if recognized within 24 hours, immediate repair may be done provided it is small. Otherwise it should be repaired after 10–12 weeks. Radiation fistulae should be repaired after 12 months.

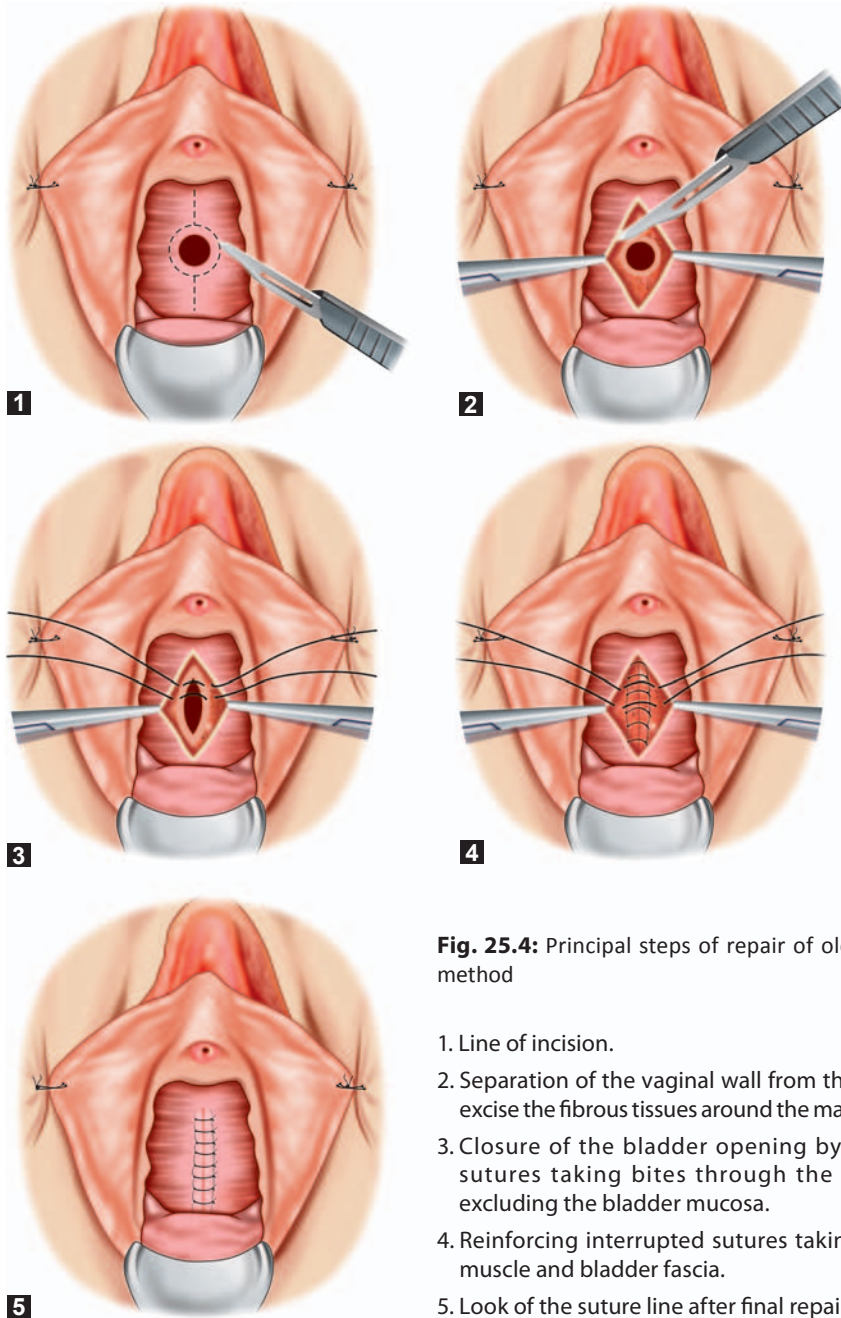
**Route of repair:** It mostly depends upon the access to the fistula site and the tissue mobility of the vagina. Either the abdominal or vaginal route may be approached according to the choice and expertise of the surgeon.

**Suture materials:** Polygalactin (Vicryl) 2-0 suture material is preferred for both the bladder and vagina. Polydioxanone (PDS) 4-0 on a 13 mm round bodied needle is used for the ureter. 3-0 PDS on a 30 mm round bodied needle is used for bowel surgery.

**Local repair by flap splitting method** is the preferred surgery (see Fig. 25.4, Step 1–5).

#### Principles of surgery

- Perfect asepsis and good exposure of the fistula.
- Excision (minimal) of the scar tissue round the margins.
- Mobilization of the bladder wall from the vagina.
- Suturing the bladder wall without tension in two layers.



**Fig. 25.4:** Principal steps of repair of old VVF by flap method

1. Line of incision.
2. Separation of the vaginal wall from the bladder. To excise the fibrous tissues around the margin of fistula.
3. Closure of the bladder opening by interrupted sutures taking bites through the muscle wall excluding the bladder mucosa.
4. Reinforcing interrupted sutures taking superficial muscle and bladder fascia.
5. Look of the suture line after final repair.



**First layer** is with polygalactin (Vicryl) 2-0 suture (p. 645) on a 30 mm needle is preferred. Interrupted stitches (3 mm apart) excluding the bladder mucosa are done.

**Second layer** is with interrupted sutures using the same suture material taking the muscle and fascial layer of the bladder wall, burying the first suture line.

- Apposition of the vaginal wall by interrupted sutures using same suture material No. 'O' (Fig. 25.4).
- Closure must be water-tight and is tested by dye instillation into the bladder at the end of the operation.
- To maintain continuous bladder drainage by an indwelling catheter (see Fig. 37.6).

### Saucerization (Paring and Suturing)

This operation was originally devised by **James Marion Sims (1852) of USA**. He used to repair (see Fig. 36.2) the fistula in **Sims' position** (see p. 103) exposing the fistula with **Sims' speculum** and after paring the margins, **sutured the fistula with silver wire**. Saucerization is the closure of a small fistula using interrupted stitches without dissection of bladder from the vagina. This may be employed in a very small fistula using Vicryl (2-0).

**Latzko technique** is used to repair a VVF that develops following total hysterectomy operation. Principle of this operation is to produce **partial colpocleisis (obliteration of the vagina around the fistula)**. This procedure is suitable for a fistula which is small and high in the vagina.

### Principal steps

- Vaginal mucosa is dissected off the bladder wall around the fistula site.
- The fistula tract is excised.
- Bladder mucosal edges are approximated with interrupted sutures (2-0 Vicryl).
- Two additional suture layers are used to appose the muscle and fascia.
- Vaginal mucosa is closed by interrupted sutures using same suture material. Continuous bladder drainage by indwelling catheter is maintained for 10–14 days.

### Modifications of Vaginal Operations (Table 25.3)

- ◆ Ureteric openings close to the margins.  
To introduce ureteric catheter prior to repair to prevent inclusion of the ureteric opening in suture.
- ◆ Involvement of the bladder neck.  
Suprapubic or vaginal cystostomy prior hand as temporary urinary diversion to keep the repair area free from getting wet.
- ◆ Associated with CPT or RVF.  
To repair the VVF first followed by repair of the CPT or RVF in the same sitting.

**Use of graft:** Repair of a big fistula may need inter position of tissue grafts to fill space and with new blood supply. Different tissues may be used.

**Martius graft:** Bulbocavernous muscle and labial fat pedicle graft is used for big bladder neck fistula.

**Other tissues used are** Gracillis muscle, omental pedicle graft (transperitoneal approach) or peritoneal flap.

### SPECIAL POSTOPERATIVE CARE

- ◆ Urinary antiseptics either given at random or appropriate to the sensitivity report.
- ◆ Continuous blood drainage for about 10–14 days.
- ◆ The patient is advised to pass urine frequently (say 1 hourly) following removal of catheter. The interval is gradually increased.
- ◆ Nursing care for fluid balance, urine output and to detect any catheter block.

### Advice during Discharge

- To pass urine more frequently.
- To avoid intercourse for at least 3 months.
- To defer pregnancy for at least 1 year.
- If conception occurs, to report to the hospital and must have mandatory antenatal check up and hospital delivery. **A successful repair should have an abdominal delivery.**

**If repair fails, local repair should again be attempted after 3 months.** The fistula may become

smaller when the second attempt may be successful. In cases of repeated failures, before declaring the case as irreparable, it is preferable to have a second opinion or to consult an urologic surgeon. This might avert the last resort to go for urinary diversion — implantation of ureters into the pelvic colon or ileal bladder (preferred).

CRITERIA FOR SUCCESSFUL REPAIR (WHO 2006)		
Criteria	Good prognosis	Uncertain prognosis
No. of fistula	Single	Multiple
Site	Vesicovaginal fistula (VVF)	Rectovaginal fistula (RVF), Mixed (VVF and RVF)
Size	<4 cm	>4 cm
Urethral involvement	Absent	Present
Vaginal scarring	Absent	Present
Tissue loss	Minimal	Extensive
Ureter involvement	Ureters are draining inside the bladder, not into the vagina	Ureters are draining into the vagina
Circumferential defect (urethra separated from the bladder)	Absent	Present

TABLE 25.3

## OTHER ROUTES OF REPAIR OF BLADDER FISTULA

- ▶ **Transperitoneal**—Vesicouterine fistula; ureteric fistula
- ▶ **Transvesical** — High and fixed fistulae (extraperitoneal) at the vault : inaccessible by vaginal route
- ▶ **Transperitoneal or transvesical** approach is preferred when the fistula margins are close to the ureteral orifices. This is done for proper dissection and to avoid injury to the ureter. This approach is also used when ureteroneocystostomy is done or omental graft is used.

### Principles in the Management of Gynecological VVF

- **Detected during operation:** To repair immediately in two layers.
- **Detected in the postoperative period:** To put an indwelling catheter for about 10–14 days. If fails, repair is to be done after 3 months.
- **Malignant or postradiation fistula:** Any of the following may relieve the symptoms—(1) Ileal bladder, (2) Anterior exenteration, (3) Colpocelesis.
- **Infective fistula:** Eradication of the specific infection be done first followed by local repair.

### URETHROVAGINAL FISTULA

#### Causes

- Part or whole of the urethra is involved along with bladder. The causes are the same as those of VVF.
- Small isolated urethrovaginal fistula is caused by:
  - Injury inflicted during anterior colporrhaphy, urethroplasty, suspension or sling operation for stress incontinence.
  - Residual fistula left behind following repair of vesicourethrovaginal fistula.

**Diagnosis:** The patient has got urge to pass urine but the urine dribbles out into the vagina during the act of micturition. A sound or a metal catheter passed through the external urethral meatus when comes out through the communicating urethrovaginal opening confirms the diagnosis. In cases of confusion in diagnosis with VVF or ureterovaginal fistula, three swab test (mentioned earlier) may be employed.

**Treatment:** Surgical repair in two layers followed by continuous bladder drainage as outlined in repair of VVF is satisfactory. Prior suprapubic or vaginal cystostomy ensures better success. In cases of complete destruction of the urethra, reconstruction of urethra is to be performed.

**Success rate** of VVF repair following first operation is about 60 to 98 percent. Failure rate is 10 percent and in 10 percent cases there is post fistula stress incontinence. Success rate decreases with increasing number of previous unsuccessful attempts.

## URETERIC INJURY IN GYNECOLOGIC SURGERY

Ureteric injury through rare has got considerable morbidity. It is an important cause for litigation.

### Causes: ■ Acquired ■ Congenital

**Acquired:** This is common and usually follows trauma during pelvic surgery. Although commonly associated with difficult surgery like abdominal hysterectomy in cervical fibroid, broad ligament fibroid, endometriosis, ovarian malignancy or radical hysterectomy, it may be injured even in apparently simple hysterectomy—abdominal or vaginal (rare).

**Congenital:** The aberrant ureter may open into the vault of vagina, uterus or into urethra.

## INJURY TO THE URETER DURING GYNECOLOGICAL SURGERY

Because of close anatomical association between ureter and genital organs, ureteric injury is not uncommon during gynecological surgery. Overall incidence is 0.5–1 percent of all pelvic operations. About 75 percent of ureteral injury result from gynecological operations and 75 percent of them occur following abdominal gynecological procedures.

### Important anatomical locations where ureteric injury is more common.

- ◆ At the level of infundibulopelvic ligament—where ureter runs parallel to ovarian vessels at the same place. Ureter forms the posterior boundary of ovarian fossa. Any inflammatory or malignant processes will involve the ureter.
- ◆ Deep in the pelvis, below the level of ischial spine, where ureter lies lateral to the peritoneum of uterosacral ligament.
- ◆ At the level of internal cervical os, 1.5 cm lateral to the cervix where uterine artery crosses the ureter from above.
- ◆ Over the anterior vaginal fornix, within the ureteric tunnel of cardinal ligament (tunnel of Wertheim) where it turns anteriorly and medially to enter the bladder.
- ◆ Where it traverses through the musculature of bladder (intravesical part).

- ◆ Any congenital malformation (duplex ureter) makes it more vulnerable to injury at any of these sites.

### Nature of Ureteral Injury

Severity of ureteric injury may be any of the following types:

- ◆ Simple kinking or angulation—causing obstruction.
- ◆ Ischemic injury resulting from trauma to ureteric sheath endangering its blood supply.
- ◆ Ligature incorporation.
- ◆ Crushing injury by clamps followed by necrosis.
- ◆ Transection—either partial or complete.
- ◆ Segmental resection either accidental or planned.
- ◆ Thermal injury during minimally invasive surgical procedure when diathermy (monopolar or bipolar) or laser energy is used (see p. 612).
- ◆ Injury by staplers during Laparoscopic surgery.

### Gynecological Operations and Ureteric Injury

Risk of injury is more where pelvic anatomy is distorted due to presence of any pelvic pathology. Common pathological conditions are:

- ◆ Cervical fibroid or low corporeal fibroid (p. 284)
- ◆ Broad ligament tumor (p. 602).
- ◆ Pelvic endometriosis (p. 304).
- ◆ Gynecological malignancy (p. 576).
- ◆ Pelvic hematoma.
- ◆ Tubo-ovarian mass, pelvic adhesions.
- ◆ Reapplication of a clamp to the pedicle of uterine artery following its initial slip.
- ◆ Presacral neuronectomy (endoscopic).
- ◆ Ovarian remnant (see p. 559)—when needs removal.
- ◆ Radical hysterectomy (p. 605).
- ◆ Vaginal hysterectomy (rare) (p. 217).
- ◆ Colposuspension (p. 403).
- ◆ LAVH (p. 617).

**Diagnosis:** Signs and symptoms are subtle and often overlooked. Fever, flank pain, hematuria, abdominal distension, urine leakage (vaginally), peritonitis,

ileus and retroperitoneal urinoma should raise the suspicion.

- a. *Escape of urine through vagina* following the operative procedure is suspicious.
- b. The patient has got *urge to pass urine and can pass urine normally*.
- c. *Three swab test* differentiates it from VVF (Table 25.1).
- d. *Intravenous indigo carmine test*—if the urine in the vagina is unstained following three-swab test, indigo carmine is injected intravenously. If urine becomes blue (generally within 4–5 minutes) the diagnosis of ureterovaginal fistula is established.
- e. *Cystoscopy*—Should be performed to determine the side of ureterovaginal fistula. There is no spurt of urine from the ureteric orifice of the affected side.
- f. When a *ureteric catheter* is passed under cystoscopic guidance, obstruction is met when the catheter tip reaches the site of injury.
- g. *Excretory urography (IVU)* confirms the side and site of fistula. The tract of ureterovaginal fistula is also outlined.
- h. *Renal ultrasound* is a noninvasive method. Hydronephrosis and retroperitoneal urinomas when seen, are helpful to the diagnosis (ureteral ligation).
- i. *Computed tomography (CT)* showing contrast extravasation is the most consistent to the diagnosis.

Peroperative detection of ureteral laceration can be made by seeing the leakage of dye at the site, following intravenous injection of indigocarmine. When the ureter is ligated or kinked, gradually increasing ureteric dilatation will be noticed, instead of dye leakage.

## MANAGEMENT OF URETERIC INJURY

### ■ Preventive ■ Operative

#### PREVENTIVE MEASURES

A thorough knowledge of pelvic anatomy is essential. Where there is any doubt, the following measures may be of help, if taken either during preoperative or intraoperative period.

- ◆ **Intravenous urography** (preoperative)—is helpful in certain situation (e.g. pelvic tumors), to ascertain the course of the ureters. Any congenital abnormality is also revealed.
- ◆ **Placement of ureteral catheters** (preoperative or intraoperative) to facilitate detection and dissection of ureters. Unfortunately in a fibrotic pelvic condition (endometriosis) palpation may be difficult.
- ◆ **Direct visualization and/or palpation of ureters** throughout its pelvic course wherever possible.
- ◆ **Uriglow**—ureteric catheters within built incorporated light source for better localization has been tried.
- ◆ **Adequate exposure of pelvic organs** is a must. Inadequate incision leads to inadequate exposure and dissection. This may lead to blind clamping or suturing.
- ◆ **Meticulous care during dissection**—not to damage the sheath of ureter so that longitudinal vessels are not destroyed.
- ◆ **To follow the important axiom of surgery**—any important structure at risk of inadvertent injury must be carefully dissected and adequately exposed.
- ◆ **To avoid blind clamping** of blood vessels.

#### OPERATIVE

Management of ureteric injury depends on the following factors—(a) Time of detection: intraoperative or postoperative (b) Type and severity of injury (c) Anatomical level (d) Mobility of the ureter and bladder (e) Pathology leading to ureter injury (f) Patient's general condition and prognosis.

#### Principles of Ureteric Repair

- Not to damage the ureteric sheath and its blood supply during dissection.
- Ureteric mobilization and tension-free anastomosis.
- Watertight closure with polydioxanone (PDS) 4-0 on a 13 mm needle is used.
- Sent with a ureteric catheter.
- Passive drain at the anastomotic site to prevent urine accumulation.

### Management When Injury Is Recognized During Operation

**Ureteral sheath denudation:** No intervention, rarely ureteral stenting (double J or Pig tail), if a long segment is involved.

**Ureteral kinking (due to closely placed sutures):** Immediate removal of suture.

**Ureteral ligation:** Deligation immediately → assessment of viability by blood flow and ureteral peristalsis. Ureteral stenting may be needed if any doubt.

**Ureteral crushing (clamp injury):** Remove the clamp → check the viability → ureteral stenting → extraperitoneal drainage at the site is placed.

### URETERIC TRANSECTION

**Partial:** Primary repair over ureteral stent.

**Complete:** (i) In the middle-third → end-to-end anastomosis over an ureteral stent (uretero-ureterostomy) following adequate mobilization of both the segments. Otherwise (complicated) ureteroileal interposition is done. (ii) In the lower-third → ureteroneocystostomy with psoas hitch over an ureteral stent.

**Thermal injury** resection and management according to the length of transection.

**Ureteric implantation** into the bladder (ureteroneocystostomy) must be done without any tension. High mobilization of bladder is needed and bladder dome is sutured to the psoas muscle on that side (**psoas hitch**). To prevent vesicoureteric reflux, ureter is implanted through submucosal tunnel in the posterior wall of the bladder.

**Bladder flap procedure** (modified Boari-Ockerblad) is an alternative when the ureter is short or the injury is at the level of pelvic brim. An obliquely placed bladder flap is outlined. The flap is rolled into a tube and the ureter is reimplanted in the submucosal tunnel without tension.

Alternatively **ureteroileoneocystostomy** would be done.

**Thermal injury:** Depending upon the severity it may need resection and management according to transection.

### Complications Following Repair of Ureteric Injury

(i) Stricture. (ii) Infection. (iii) Ureteric obstruction. (iv) Reflux of urine. (v) Stent or Boari flap complications.

### RECTOVAGINAL FISTULA

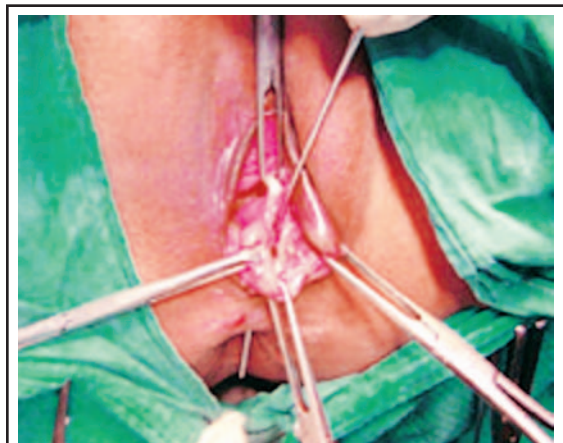**DEFINITION:** Abnormal communication between the rectum and vagina with involuntary escape of flatus and/or feces into the vagina is called rectovaginal fistula (RVF) (see Fig. 25.5).

**CAUSES:** • Acquired • Congenital

#### Acquired

#### Obstetrical

- Incomplete healing or unrepaired recent CPT is the commonest cause of RVF.
- Obstructed labor—The rectum is protected by peritoneum of pouch of Douglas in its upper-third, by the perineal body in the lower-third and by the curved sacrum in the middle-third. However, if the sacrum is flat, during obstructed labor the compression effect produces pressure necrosis → infection → sloughing → fistula.



**Fig. 25.5:** Rectovaginal fistula (RVF) following traumatic forceps delivery. It was of moderate size so as to pass a metal probe through the vagina and it is clearly seen to come out through the anus

- c. Instrumental injury inflicted during destructive operation.

### Gynecological

- a. Following incomplete healing of repair of old CPT (commonest).
- b. Trauma inflicted inadvertently and remains unrecognized in operations like—perineorrhaphy, repair of enterocele, vaginal tubectomy, posterior colpotomy to drain the pelvic abscess, reconstruction of vagina, etc.
- c. Fall on a sharp pointed object.
- d. Malignancy of the vagina (common), cervix or bowel.
- e. Radiation.
- f. Lymphogranuloma venereum or tuberculosis of the vagina.
- g. Diverticulitis of the sigmoid colon → abscess → bursts into the vagina.
- h. Inflammatory bowel disease: Crohn's disease involving the anal canal or lower rectum.

**Congenital:** The anal canal may open into the vestibule or in the vagina.

### DIAGNOSIS

- Involuntary escape of flatus and/or feces into the vagina. If the fistula is small, there is incontinence of flatus and loose stool only but not of hard stool.
- Rectovaginal examination reveals the site and size of the fistula.
- Confirmation may be done by a probe passing through the vagina into the rectum. If necessary, methylene blue dye is introduced into the rectum which is seen escaping out through the fistula into the vagina. Examination under anesthesia

may be conducted to facilitate clinical diagnosis (Fig. 25.5).

### INVESTIGATIONS

- Barium enema.
- Barium meal and follow through may be needed to confirm the site of intestinal fistula.

**Sigmoidoscopy and proctoscopy** are helpful for the diagnosis of inflammatory bowel disease or for taking biopsy of fistula edge.

### TREATMENT: ♦ Preventive ♦ Definitive

**Preventive:** Preventive aspects include good intranatal care, identification of CPT and its effective repair. Consciousness about the possible injury of the rectum in gynecologic surgery mentioned and its effective and appropriate surgery minimize the incidence of fistula.

### Definitive surgery includes:

- ♦ Situated low down—to make it a complete perineal tear and repair it as that of CPT.
- ♦ Situated in the middle-third—repair by flap method.

**Repair by flap method**—Repair is commonly done transvaginally. The scar-margin is excised. Vaginal wall separated from the underlying rectal wall. This wide tissue mobilization helps repair without any tension. Repair is done in layers. Suture material used is polydioxanone (PDS) 3–0 on a 30 mm needle. Pre- and postoperative bowel management are similar to that in repair of CPT.

- ♦ Situated high up—Preliminary colostomy → local repair after 3 weeks → closure of colostomy after 3 weeks.
- ♦ The preoperative preparations of one stage vaginal repair are like those mentioned in repair of CPT.

**KEY POINTS**

- ▶ The incidence of genitourinary fistula ranges between 0.2–1 percent among gynecological admissions of the developing countries. Vesicovaginal fistula is the commonest one.
- ▶ The majority (80–90%) is obstetrical following ischemia due to obstructed labor (p. 418). In the developed countries, the fistula is mostly gynecological (80%).
- ▶ The fistula is best revealed in Sims' position using Sims' speculum (Sims' triad p. 423). In tiny fistula, diagnosis is made by three swab test. The test also differentiates it from ureterovaginal fistula. Investigations (p. 403) are needed to diagnose it exactly.

Local repair by flap splitting method between 3 months following delivery is the preferred surgery. Continuous bladder drainage for 10–14 days following surgery should be a must (p. 406). Special postoperative care is essential for success (see p. 423). If repair fails, local repair should be attempted after 3 months. In traumatic fistula, specially gynecological, the repair should be done immediately during primary surgery. However, if detected in the postoperative period, the continuous bladder drainage is to be kept for about 10–14 days failing which repair is to be done after 3 months. There are some favorable factors for successful repair (Table on p. 424).

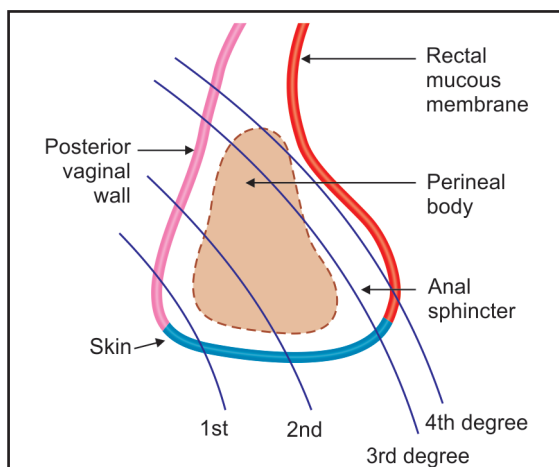
- ▶ Ureterovaginal fistula is common following difficult abdominal hysterectomy for cervical or broad ligament fibroid, endometriosis, ovarian malignancy or radical hysterectomy (see p. 425). It may also occur following vaginal hysterectomy or otherwise, in a case of simple hysterectomy. There are some anatomical locations as well as pelvic pathologies where ureteric injury is more likely (see p. 425). Nature of ureteric injury may vary from kinking to complete transection. Three swab test differentiates it from a tiny VVF (p. 403). Further investigations are needed to confirm the diagnosis and also to know the side and site of injury (see p. 408). End-to-end anastomosis during surgery or ureteroneocystostomy is the preferred surgery in late cases.
- ▶ Rectovaginal fistula is common following incomplete healing or unrepaired recent complete perineal tear. Other cause of RVF are obstetric, gynecological or congenital (p. 427).
- ▶ Diagnosis (p. 428) is important as regard the site and size of fistula.
- ▶ Definitive surgery for RVF may be as that of a repair of a CPT or by flap method or repair with prior colostomy (p. 428).

# Genital Tract Injuries

## INTRODUCTION

The genital tract and the adjacent pelvic organs are subjected to strain of vaginal delivery either spontaneous or assisted. The injury is more in areas of inadequate antenatal and intranatal care. The patients may have full recovery from the injuries but a substantial number may produce permanent legacies which lead to major gynecologic problems. The following are some of such major obstetric legacies (Table 26.1).

All are dealt in appropriate chapters; only the severe form of perineal injuries—i.e. old complete perineal tear will be dealt within this chapter. It has to be borne in mind that with improved antenatal and intranatal care, majority of the complications could be prevented. It is thus appropriately considered that obstetrics is a branch of preventive medicine.



**Fig. 26.1:** Diagrammatic representation showing different degrees of perineal tear (from author's Textbook of Obstetrics)

**TABLE 26.1**

### OBSTETRIC LEGACIES LEADING TO GROSS GYNECOLOGIC PROBLEMS

- ◆ Genital prolapse
- ◆ Perineal injuries including complete perineal tear
- ◆ Genitourinary and rectovaginal fistula
- ◆ Tender perineal and vaginal scar
- ◆ Backache
- ◆ Eversion cervix with cervicitis
- ◆ Ill health and chronic debilitating state

## OLD COMPLETE PERINEAL TEAR (CPT)

### DEFINITION

Tear of the perineal body involving the sphincter ani externus with or without involvement of the anorectal mucosa is called **complete perineal tear**. It is called old when passed beyond an arbitrary period of 3 months following the injury (Fig. 26.1).

### CLASSIFICATION OF PERINEAL TEARS (RCOG-2007)

Grade	Features
<i>First degree</i>	Laceration of vaginal epithelium or perineal skin
<i>Second degree</i>	Involvement of the perineal body but not the anal sphincter
<i>Third degree</i>	Disruption of the anal sphincter complex (both external and internal)
<i>Fourth degree</i>	Injury to the anal sphincter complex with tear of the anal epithelium



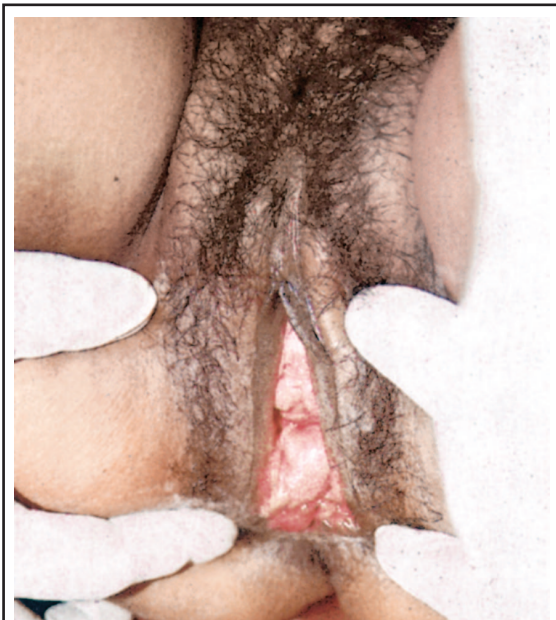**ETIOLOGY**

## ◆ Obstetrical ◆ Gynecological

**Obstetrical:** Perineal injury (3° and 4°) results from **over stretching** or **sudden stretching** of the perineum during child birth. It is more common when the perineum is **inelastic**.

**RISK FACTORS FOR THIRD DEGREE TEARS (RCOG–2007)**

- ◆ Primigravida
- ◆ Big baby (> 3 kg)
- ◆ Face to pubis delivery
- ◆ Midline episiotomy
- ◆ Forceps delivery
- ◆ Outlet contraction with narrow pubic arch
- ◆ Shoulder dystocia
- ◆ Precipitate labor
- ◆ Scar in the perineum
- ◆ Prolonged second stage



**Fig. 26.2:** Old complete perineal tear. Note the absence of perineum and the pinkish vaginal mucosa is continuous with reddish rectal mucosa

**Gynecological:** Direct injury on the perineum by fall may lead to trauma on the perineum to the extent of CPT.

**TABLE 26.2 STRUCTURES TORN IN CPT**

- Posterior vaginal wall or perineal skin
- Perineal muscles
- Perineal body
- Anal sphincter complex
- Varying degrees of anorectal mucous membrane

**CLINICAL FEATURES: Patient profile**

Patients are usually primiparous with a history suggestive of inadequate care during childbirth.

**Symptoms**— The chief complaints are:

- Inability to hold the flatus and feces. While incontinence of flatus is invariable, that of feces depends on the extent of damage of the external anal sphincter. If the damage is slight, there is incontinence of only loose stool but if the damage is severe, there is incontinence of hard stool as well.
- Soreness over the perianal region is due to constant irritation by the stool. It is often surprising that, the condition may remain asymptomatic for many years and only discovered accidentally during pelvic examination. Overactivity of the levator ani makes the patient continent with the stool; the incontinence of flatus being ignored.

**Signs**— *Inspection of the perineum reveals:*

- There is absence of perineum. Vaginal and rectal mucous membranes are found to be continuous, only separated by a bridge of fibrous tissue (**rectal mucosa is reddish and the vaginal one is pinkish in color**) (Fig. 26.2).
- Visible dimple on the skin on either side of the fused mucosa may be present. These represent the retracted torn ends of the sphincter ani externus which have got subcutaneous attachment.

Radial wrinkling of the skin is present only on the posterior aspect of the anal opening.

**Palpation:** There is absence of the sphincteric grip evidenced when a finger is introduced into the rectum. The anal canal is separated from the vagina only by a septum.

It is surprising that in spite of deficit of the perineum, there is no prolapse. This is because of over-activity of the levator ani muscle. If prolapse is found along with CPT, it is more likely pre-existing.

**DIFFERENTIAL DIAGNOSIS:** A rectovaginal fistula situated low down may at times be confused with complete perineal tear. This is especially in cases where overlying skin remains intact. **Rectovaginal fistula causes more inconvenience to the patient than CPT.**

**TREATMENT:** ■ Preventive ■ Operative

**Preventive:** Proper conduct in the second stage of labor taking due care of the perineum when it is likely to be damaged is the effective step to prevent undue lacerations (Table 26.3).

**The prevention of the perineal injuries in normal delivery includes:**

- ◆ More attention should be paid not to the perineum but to the controlled delivery of the head.
- ◆ Delivery by early extension is to be avoided. Flexion of the head is to be maintained till the sub-occiput comes under the symphysis pubis so that lesser suboccipitofrontal (10 cm) diameter emerges out of the introitus.
- ◆ Spontaneous forcible delivery of the head is to be avoided by assuring the patient not to bear down during contractions, pressing on the head and the perineum by the palms and giving inhalation analgesics, if available.
- ◆ To deliver the head in between contractions.
- ◆ To perform timely episiotomy (when needed).
- ◆ To take care during delivery of the shoulders as the wider bisacromial diameter (12 cm) emerges out of the introitus.

**TABLE 26.3**

**PROPHYLAXIS TO PERINEAL INJURIES DURING DELIVERY**

- ▶ Delivery of the head by early extension is to be avoided
- ▶ Controlled delivery of the flexed head in between uterine contractions
- ▶ Timely and judicious mediolateral episiotomy especially in primigravidae, occipitoposterior, face, breech or forceps delivery

**Operative:** The definitive surgery is repair of the **anal sphincter complex (sphincteroplasty) with restoration of the perineal body (perineorrhaphy).**

This should preferably be done between 3–6 months following the injury. The best time of repair is, however, within 24 hours of the injury.

By 3 months time, the local infection subsides, general condition of the patient improves and the baby can be kept at home. If kept more than 6 months, there is more fibrosis on the margins and unnecessary prolonged inconvenience to the patient.

**Preoperative investigations:** There is no special preoperative investigation except the stool should be examined for evidence of intestinal infestations like hookworm, Ascaris or *E. histolytica*, which are rampant in the tropical countries. Their presence needs eradication prior to surgery.

**Preoperative preparations**

- The patient is admitted at least 3 days prior to surgery.
- The patient should have low residual diet consisting of milk, bread, lime-whey for 2 days prior to surgery.
- Intestinal antiseptics are prescribed starting from 2 days prior to surgery. Any one of the drugs may be given—neomycin 250 mg thrice daily, erythromycin 500 mg thrice daily, metronidazole 400 mg thrice daily.
- Enema and bowel wash are given daily, for two days prior to operation. The idea is to clear the lower bowel. Enema should not be given in the morning of the operation.

**Principles of surgery (Warren Flap method)**

- An inverted V-shaped incision is made on the posterior vaginal mucosa [Fig. 26.3(1)].
- Mobilization of the rectal wall from the overlying vaginal wall.
- Mobilization of the torn ends of the sphincter ani externus.
- Suturing of the rectal wall in two layers.
- Approximation of the torn ends of the sphincters by interrupted sutures.
- Apposition of the musculofascial structures of the perineal body by 2–3 interrupted sutures.
- Apposition of the vaginal wall and skin of the perineum by interrupted sutures.

**Steps of Operation (Fig. 26.3)**

**Preliminaries:** As in anterior colporrhaphy.

**Actual steps:****Mobilization of the rectum and anal sphincter**

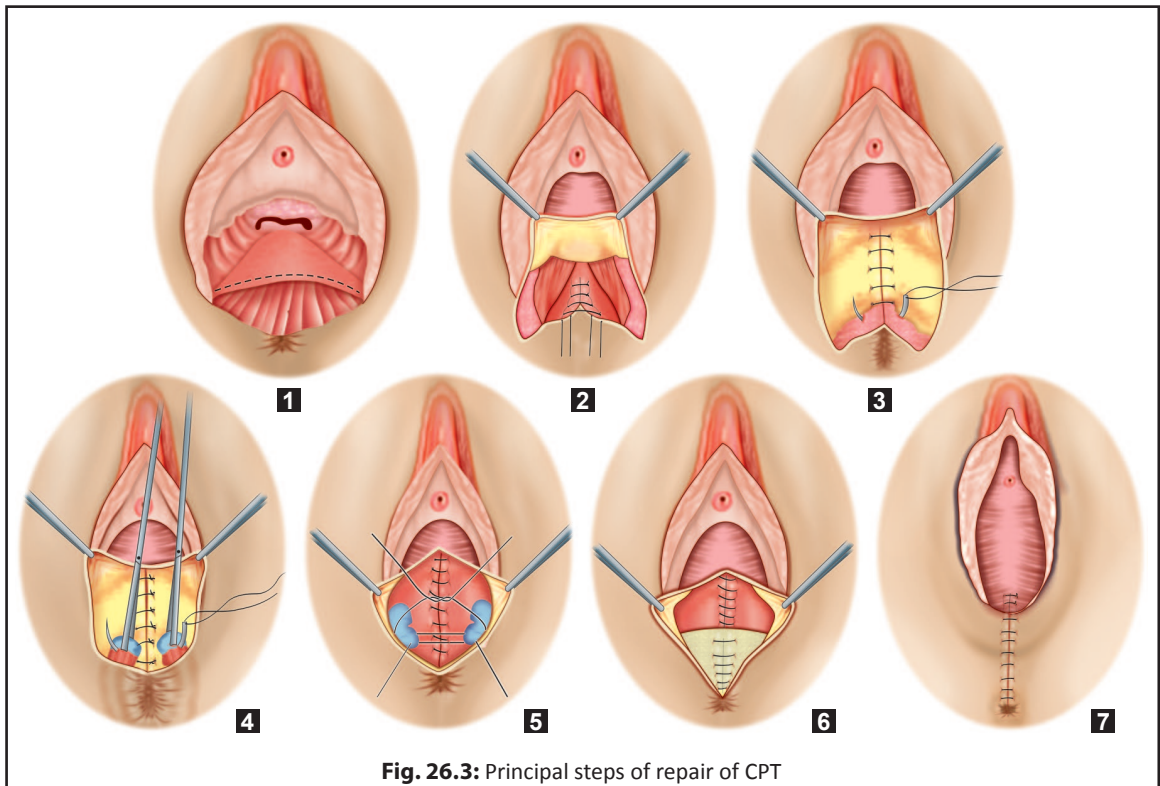
- Two Allis tissue forceps are placed on either side of the fused rectovaginal mucosa and are retracted laterally by the assistant.
- An inverted V-shaped incision is made over the fused mucosa extending from one end to the other. [Fig. 26.3(1)].
- Two Allis forceps are placed on either side on the lower end of the labium minus.
- Incision over the fused mucosa is extended upwards from each end up to the lower end of the labium minus.
- The posterior vaginal wall is dissected off from the rectum and the rectum is well-mobilized. [Fig. 26.3(2)].
- Two more Allis forceps are placed beyond the skin dimple on either side. Incision is made from each end of the fused mucosa downwards over the skin dimple (site of torn end of the sphincter ani externus).

The incision lines now look almost to the letter 'H'.

- Torn end of the anal sphincter of each side is held by Allis forceps and is well-mobilized. [Fig. 26.3(4)].

**Repair:** Prior to repair, the scar tissue on the rectal margins is to be excised.

- The rectal wall is sutured by interrupted sutures using polydioxanone (PDS) 3-0 on 30 mm needle starting from the apex. The knots are placed inside the lumen. [Fig. 26.3(2)].
- The pararectal fascia is approximated over the first layer by interrupted sutures using the same suture materials. [Fig. 26.3(3)].
- **Sphincteroplasty:** The torn ends of the sphincter ani externus are approximated in front of the repaired rectum by a figure of eight suture using polydioxanone (PDS) No. '2-0'. This is enforced by one or two interrupted sutures. [Figs 26.3(4) and 26.3(5)]. Results of repair of EAS either by an overlapping or an end-to-end approximation method, are the same.
- Redundant portion of the vaginal mucosa is excised.
- Two or three interrupted sutures are placed through the fibromuscular tissues of the perineal body using Vicryl No. '0' [Fig. 26.3(6)].
- The rest of the steps are like that of perineorrhaphy.



**Fig. 26.3:** Principal steps of repair of CPT

### Special Postoperative Care

- ◆ Non-residual diet is given from 3rd day onwards; the full diet is given on 6th day.
- ◆ Bowel should not be moved for about 4-5 days.
- ◆ Lactulose 10 mL twice daily beginning on the second day and increasing the dose upto 30 mL on the 3rd day is a satisfactory regimen to soften the stool.
- ◆ If the patient fails to pass stool and is having discomfort, compound enema (olive oil or liquid paraffin, glycerine and normal saline, each 4 oz) may be given by a rubber catheter.
- ◆ Antibiotics (cefuroxime 1.5 and metronidazole 500 mg – IV) are used to cover the perioperative period.
- ◆ Intestinal antiseptics should be continued for about 5 days (see above).

### Advice on discharge

- ◆ Stool is kept soft using a laxative at bed time.
- ◆ Contraceptive practice to postpone pregnancy.
- ◆ To review the woman after 6 weeks of repair.
- ◆ To have antenatal check up when she is pregnant and a mandatory hospital delivery. **In future vaginal delivery, liberal mediolateral episiotomy may be done.**
- ◆ Women who are symptomatic or have abnormal endoanal USG and/or manometry after repair should be **delivered by elective cesarean section.**

### Complications of Repair Operations

- ◆ Complete dehiscence.
- ◆ Incomplete dehiscence leading to rectovaginal fistula.
- ◆ Difficulty in defecation because of too much tightening of the sphincter.
- ◆ Dyspareunia.
- ◆ Persistence of incontinence of flatus or feces. Endoanal USG or anorectal manometry is to be done to detect any residual defects (20-30%).

## COITAL INJURIES

The following are the nature of coital injuries :

- Minor hemorrhage due to tearing of the hymen or bruising of the vagina or urethra may occur at defloration. No treatment is usually required.

- Severe hemorrhage may occur, if the tear spreads to involve the vestibule or the region of the clitoris. Lacerations of the anterior vaginal wall may occur usually following rape.
- Very rarely, rupture of the vault of the vagina may occur to expose the peritoneal cavity. This usually occurs in—(a) rape, (b) very young girls, (c) postmenopausal atrophy and (d) following vaginal/abdominal hysterectomy. Bowels and omentum may prolapse through the ruptured vault and cause shock and peritonitis.

**Management:** Small tears need no treatment; only pressure application is enough. Larger lacerations have to be repaired. If the vault has ruptured, it is preferable to perform laparotomy and repair the vault and to tackle any associated pathology.

## RAPE VICTIMS

The victims may be of any age groups—pre-menarchal, childbearing or even postmenopausal. The very young, mentally and physically handicapped and the very old are the common victims.

### FORENSIC CONSIDERATIONS

- The medicolegal issues should be seriously considered even if the victim does not wish to report the case or press for prosecution.
- Rape is a legal diagnosis. The medical evidences and examinations are of value only to the court.
- Referral may be through police hospital doctor or by self referral.
- The physician should examine her as early as possible following rape.
- Due consent is to be taken from the victim and the examination is made in presence of a third party or chaperone. Confidentiality is to be maintained.
- Detailed statement from the victim, examination findings are recorded. Collected materials are labeled properly and should be submitted for expert examination.
- Sperm are rarely detected in the vagina later than 72 hours and motile sperm later than 4 hours. Rarely non-motile sperm may be present in vagina even after 12-20 hours of the attack. It should be

borne in mind while interpreting the findings that about 10 percent adult males are azoospermic or oligospermic. It is also observed that in one-third, sperm are not ejaculated in the vagina and millions are vasectomized and that many rape victims douche before reporting for examination.

### MANAGEMENT — Management aims at:

- Examination with clinical and evidential protocols.
- To treat any local injury
- To perform appropriate tests
- To prevent infection and STD
- To prevent pregnancy (emergency contraception)
- Medicolegal procedure
- To provide emotional support to the victim.

### MEDICOLEGAL PROCEDURES AND DOCUMENTATION

- ◆ To document history in detail.
- ◆ To examine her thoroughly (genital/non-genital) and to note the injuries.
- ◆ To collect the clothings, hair samples by combing pubic hair and finger nail scrapings.
- ◆ To collect samples for sperm, acid phosphatase from the affected site (vagina, rectum, pharynx). Photographs of injuries are taken for forensic evidence.
- ◆ To send specimens to forensic authorities with record.

**Local injuries:** The injuries may be in the form of bruises, lacerations around the neck, buttocks or vulva. Extensive lacerations in the area of hymen, vagina, urethra, even the vaginal vault may be there. There may be major injuries especially in young virgins or premenarchal girls. The injuries should be repaired under general anesthesia. In premenarchal girls, to increase the vaginal defense, small dose of estrogen is given orally daily for two weeks (0.01 mg ethinyl estradiol).

### To prevent infection and STD

Infection may be genital as well as extragenital (pharynx). **Rape victim runs the risk of infection with gonorrhea, syphilis, chlamydia, trichomonas, HIV, Hepatitis B and others (see chapter 11).** Blood for serological test for syphilis and cervical

and urethral smear for *gonococcus* are to be collected for bacteriological study. Cultures of cervical mucus should also be done for microbiological study.

Since about 6 weeks must elapse after exposure before the serology becomes positive, a positive test at the first visit indicates that the victim has already been exposed. If negative, the test is to be repeated after 6 weeks. Drugs commonly used for the prevention of STD are given in the Table 26.4.

TABLE 26.4

### DRUGS USED FOR PREVENTION OF INFECTION AND STD

- ◆ Ceftriaxone 250 mg IM is given—single dose.  
Plus
- ◆ Doxycycline 100 mg orally two times a day for 7 days.

**To prevent pregnancy:** Due care is to be taken to prevent pregnancy. **This is, however, not applicable** in premenarchal girls, in women protected by ‘pills’ or IUD or permanent sterilization. If the patient is at risk of pregnancy, emergency contraception is advised (see p. 492).

**Medicolegal procedures:** Details of history and examination especially the injuries are documented. All clothings and undergarments are collected and labeled properly. Smears of vaginal secretions are made to document the presence of sperm, acid phosphatase and for DNA typing. Collected swabs are refrigerated until they are processed. Pubic hair combings is done to obtain pubic hair of the assaulter. Finger nail scrapings are obtained for DNA typing of the perpetrator.

**To provide emotional support:** To treat the psychic trauma (rape trauma syndrome), which usually lasts for a variable period—sympathetic handling, assurance, tranquilizers, and anti-depressant drugs are of help.

The acute phase lasts for hours to days. The victim may present with features of fear, depression, guilt, sleeplessness and eating disorders.

The late phase or the reorganization phase consists of nightmares, flash backs or phobias. It may last for months to years. The victim is allowed to express her feelings, anxieties and fears. She should be reassured as far as possible. Other healthcare personnel may

be involved to counsel her if needed. Follow-up visit should be planned within 4–6 weeks before she is discharged.

**Follow up** — The follow up should be arranged in 1–4 weeks. The protocols to be maintained are :

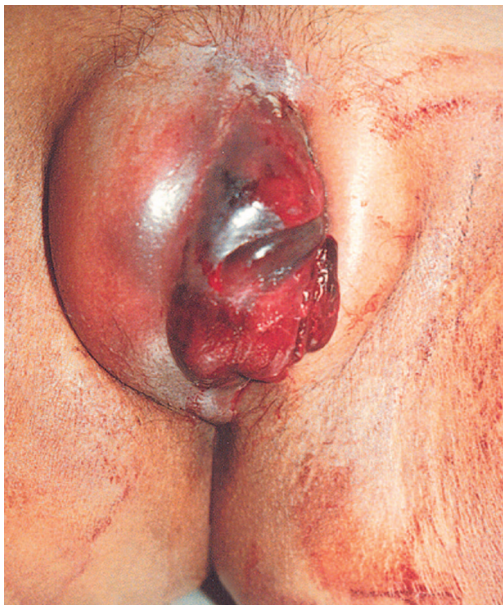- Serological test for syphilis.
- Test of cure by culture for gonorrhoea.
- Urine test for pregnancy, if suspected.
- Reassurance and support.

## DIRECT TRAUMA

Accident, as falling astride on any sharp or pointed object, is not uncommon specially in young girls. It may produce bruising of the vulva or at times give rise to vulval hematoma (Fig. 26.4).

Major accident may involve fracture of pelvic of bones causing injuries to pelvic viscera like bladder or rectum apart from vagina. There may be supravulvar hematoma.

Even, fall on a sharp object may produce the above picture or perforate the vaginal wall with injury of the surrounding viscera.



**Fig. 26.4:** A 17-year-old-girl suffered extensive vulval hematoma following a fall on a chair

**Management:** Assessment of the general condition and the nature and extent of the injuries inflicted should be done first. Small vulval hematoma, if not spreading may be left alone but if it is a big one or spreading, along with resuscitative measures, the hematoma is to be tackled under general anesthesia.

This includes scooping of the blood clots after giving an incision, secure hemostasis and obliteration of the dead space by interrupted mattress sutures.

In supravulvar hematoma or in cases of suspected gut injuries, laparotomy is indicated and appropriate measures taken.

## FOREIGN BODIES

Various types of foreign bodies may be placed either in the vagina or uterus and retained for a prolonged period often unnoticed by the patient. The articles so placed are either introduced by the patient or at times by a physician. Such articles are of varying nature, to mention only a few of them.

### In the vagina

- ◆ Coins, toys, small stones either introduced out of curiosity by children or perversion in adults.
- ◆ Forgotten menstrual tampon or diaphragm, cervical cap or condom used as contraceptives.
- ◆ Articles introduced to procure abortion.
- ◆ Packs, swabs or dressings.
- ◆ Forgotten pessary.

### In the uterus

- ◆ Retained IUCD for a long time.
- ◆ Old gauze packs.
- ◆ Articles inserted for procuring abortion.

**Effects:** The effects depend upon the nature of the foreign body, duration of its existence and amount of tissue damage.

Any material left inside invites infection. This especially happens in rubber goods, foreign bodies, swabs or gauze packs. There is foul smelling discharge.

Retained and forgotten pessary may cause vaginitis, sloughing and ulceration. It may produce vesicovaginal fistula and may be a precursor of vaginal carcinoma. **Prolonged retention of IUD may cause** menorrhagia, irregular bleeding and if left even

in postmenopausal period, may produce pyometra or postmenopausal bleeding.

**Management:** Once diagnosed, the foreign body is to be removed. In children, it may not be easy and it is better to expose the vagina under general anesthesia using aural or nasal speculum.

## INSTRUMENTAL INJURIES

Uterine injury in gynecologic conditions is rather uncommon compared to pregnant uterus. However, injuries do happen with all types of instruments used in cervical dilatation and uterine curettage operation.

Cervical injuries may be inflicted by the vulsellum or by a dilator especially in nulliparous cervix. There may be at times brisk hemorrhage. **Late sequela includes cervical incompetency.**

Body of the uterus is commonly injured by sound, dilator or curette or during insertion of IUD. Apart from inadvertent injuries, the likely susceptible conditions are:

- ◆ Small and soft uterus during lactation
- ◆ Postmenopausal uterus
- ◆ Infected uterus
- ◆ Pyometra
- ◆ Malignancy.

**Dangers:** There may not be any appreciable alteration of the general condition and the condition is left unnoticed. But it may be associated with:

- ◆ Brisk hemorrhage either intraperitoneal or revealed.
- ◆ Spreading infection (peritonitis).
- ◆ Injury to the gut.

**Management:** Once diagnosis is made, the operative procedure is to be stopped. Further management depends on:

- ◆ Type of instrument causing injury
- ◆ Pathology in the uterus
- ◆ Effect on the patient.

### Non-infective/non-malignant

**Observation:** Pulse and blood pressure are to be observed periodically and to administer antibiotics. Evidences of peritonitis are to be looked for. Laparoscopy can give a good guide for observation or interference.

### Interference

- ◆ Deteriorating general condition
- ◆ Suspected gut injury
- ◆ Features of developing peritonitis.

### Infective/malignant

- ◆ In infective uterus, there is chance of spreading peritonitis. Observation may be done under cover of antibiotics but if unresponsive, laparotomy is preferred.
- ◆ In malignancy or pyometra, laparotomy and definitive surgery have to be seriously considered.

## KEY POINTS

- Obstetric legacies leading to gross gynecologic problems include—genital prolapse, perineal injuries, fistula, backache, chronic cervicitis and ill health. Gross injury to the perineum is mostly due to mismanaged second stage of labor.
- In complete perineal tear, there is absence of perineum and the vaginal and rectal mucous membranes are found to be continuous.
- The definitive surgery is sphincteroplasty and perineorrhaphy. The best time is within 24 hours of injury and in late cases after 3 months. Bowel preparations are to be done prior to surgery.
- Minor hemorrhage due to tearing of the hymen is the commonest coital injury. Severe injury results from rape in very young girls or postmenopausal atrophy.

Contd...

*Contd...*

- ▶ Rape is a legal diagnosis. Due consent is to be taken from the victim and the examination is made in presence of a third party or chaperone. **Management of rape victims aims at**—treatment of the local injuries, prevention of infection and STD, prevention of pregnancy, medicolegal procedures and emotional support to the victim (see p. 435). Emergency contraception is advised if the victim is at risk of pregnancy (Chapter 29, p. 492).
- ▶ Direct injury to the vulva may at times produces hematoma which requires resuscitation and exploration under general anesthesia. **Foreign bodies** —placed in the vagina for a prolonged period are pessary and diaphragm or cervical cap used as contraceptives. IUD may be forgotten and retained for a prolonged period in the uterus. Once diagnosed, the foreign bodies are to be removed.
- ▶ Uterine injury in gynecologic surgery is relatively uncommon compared to pregnant uterus. Interference is indicated in deteriorating general condition, suspected gut injury and with the features of developing peritonitis. In infective or malignant condition, laparotomy is seriously to be thought of.



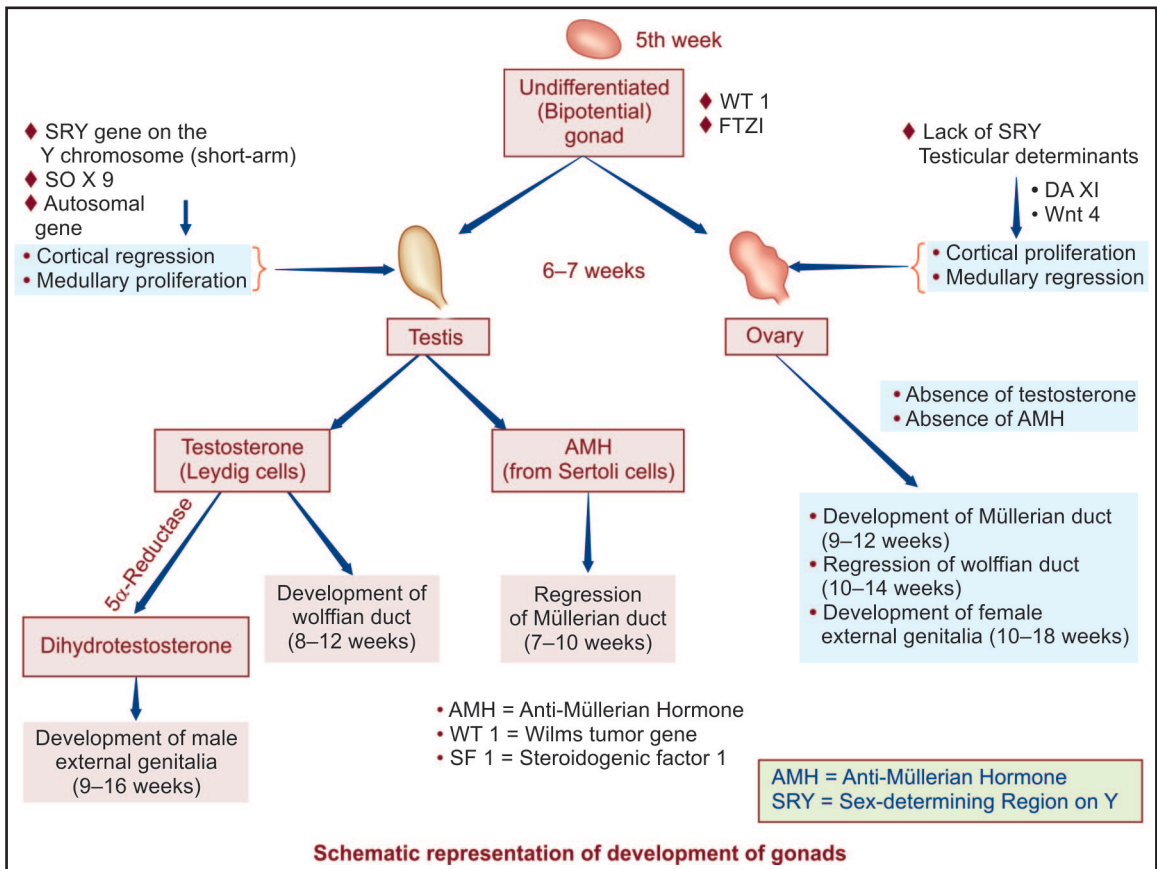
## Intersex

### DEFINITION

Intersexuality may be defined as the presence of both male and female external and or internal genital organs in the same individual causing confusion in the diagnosis of true sex. The incidence is about 2 per 1,000.

### EMBRYOLOGICAL CONSIDERATION

The development of the gonads and the genitalia has been described in Chapter 3. Only its schematic representation is depicted below.



## DETERMINATION OF SEX

In determining the sex, the following factors are to be considered—(1) Genetic sex, (2) Chromosomal sex, (3) External and internal anatomic sex, (4) Gonadal sex, (5) Hormonal sex, (6) Psychologic sex, (7) Sex of rearing.

In the newborn, the diagnosis of the apparent sex is determined by the appearance of the external genital organs. In the adolescence, however, in addition to the appearance of external genitalia, sex of rearing, psychogenic sex and the appearance of secondary sex characters should be taken into consideration.

## NOMENCLATURE

- ◆ Female intersex or female pseudohermaphrodite—An association of female gonads with male external genitalia.
- ◆ Male intersex or male pseudohermaphrodite—An association of male gonads with female external genitalia.
- ◆ True hermaphrodite—An individual possessing both ovaries and testes with ambiguity of genital organs.

## ETIOLOGY, CLINICAL PRESENTATION AND DIAGNOSIS

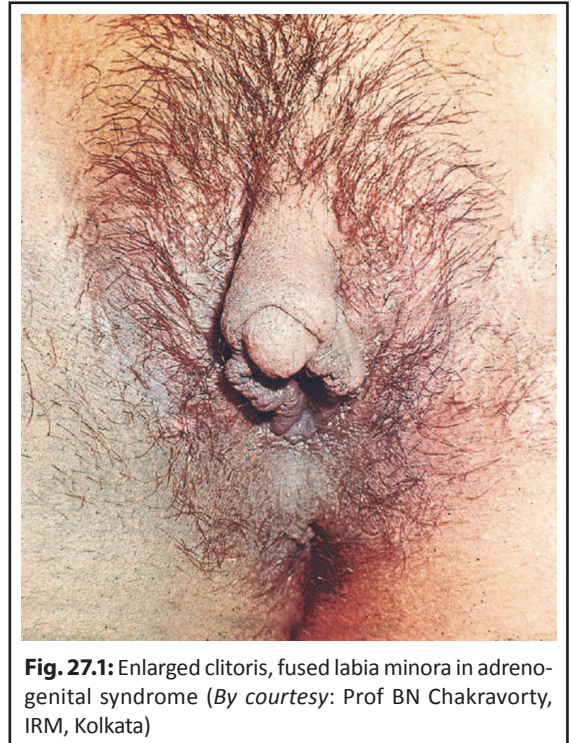
- Female intersex.
- Disorders of gonadal development.
- Male intersex.
- True hermaphroditism.

### FEMALE INTERSEX

#### (A) ADRENOGENITAL SYNDROME (CONGENITAL ADRENAL HYPERPLASIA) (FIG. 27.1)

##### Etiology

It is an autosomal recessive disorder. It is due to inborn error of adrenal steroid metabolism, commonly due to 21-hydroxylase (95%) and rarely due to 11-hydroxylase or 3 $\beta$  hydroxy steroid dehydrogenase deficiency. There is lack of cortisol production resulting in excess of ACTH production from the pituitary. ACTH in turn, stimulates the adrenal to produce excess androgens with virilization of female offspring. Associated aldosterone deficiency may lead to excess salt depletion. There is often history of affection of sibling. The girls are potentially fertile.



**Fig. 27.1:** Enlarged clitoris, fused labia minora in adrenogenital syndrome (By courtesy: Prof BN Chakravorty, IRM, Kolkata)

##### Clinical presentation

Ambiguity of sex at birth—Cases of ambiguity of sex detected at birth are due to adrenogenital syndrome unless proved otherwise.

- ◆ Hirsutism and amenorrhea may be the presenting features around puberty in milder form.

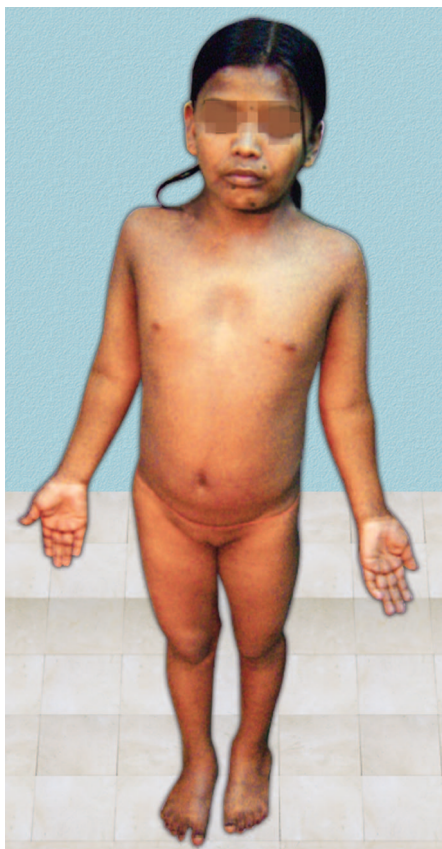##### Diagnosis at birth

The suspected anatomic abnormalities include:

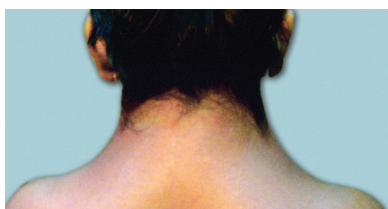- ◆ An enlarged clitoris (Fig. 27.1).
- ◆ Presence of penile urethra or hypospadias.
- ◆ Associated metabolic abnormality—salt wasting (hyponatremia, hyperkalemia) and hypotension may be present.
- ◆ Fusion of the labia minora.
- ◆ The presence of any one or more of the above features necessitates further investigations for confirmation of an early diagnosis.

##### Investigations

- ◆ Sonographic evaluation of internal genitalia shows presence of uterus, fallopian tubes, and vagina. The gonads are ovaries.
- ◆ Sex chromatin study reveals positive Barr body.

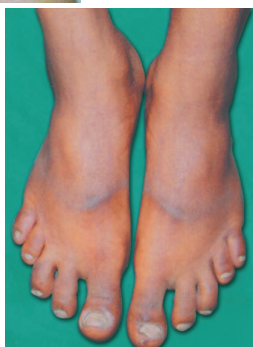

**Fig. 27.2A:** 17 Years old girl with Turner's syndrome (45, X). Characteristic somatic abnormalities seen are: short stature (130 cm), shield chest, widely apart nipples, cubitus vulgus, short neck and absent secondary sex characters.



**Fig. 27.2B:** The same girl with webbing of the neck and low hair line

**Fig. 27.2C:** Deformity of the metatarsal bones in Turner's syndrome [By courtesy: Dr. S. Chaudhury, Assoc. Professor, Department of Obstetrics and Gynecology, NRS Medical College, Kolkata]



- ▶ Karyotype is 46, XX.
- ▶ Serum estimation
  - 17 hydroxy-progesterone (17 OHP) is elevated to beyond 800 ng/dL.
  - Electrolyte values are estimated to check the possibility of their depletion and producing “salt losing syndrome” (sodium and chloride—low, potassium—raised).
- Urinary excretion of pregnanetriol and 17 Ketosteroids are markedly elevated.

### (B) MASCULINIZATION DUE TO INCREASED ANDROGEN IN MATERNAL CIRCULATION

Drug induced androgenicity is very rare nowadays. Progestogens used in early pregnancy complication has too often been implicated. But, the newer progestogens have got least adverse effect. Danazol used in endometriosis may produce virilization in female offsprings, if continued during accidental pregnancy. Rarely, the androgen source may be adrenal tumor, androgen secreting tumor or Cushing's syndrome of the mother.

There may be confusion in diagnosis of sex at birth. The history of intake of androgenic drug is often present. The source of excess androgen can be detected by appropriate investigations. To rule out adrenogenital syndrome, serum 17 hydroxy-progesterone is to be measured. **This is not elevated in any of the conditions mentioned.**

## DISORDERS OF GONADAL DEVELOPMENT

### Gonadal Dysgenesis

The term is employed for patients with female habits in whom the gonads are imperfectly developed.

It is due to cytogenetic abnormality. The germ cells either fail to develop or fail to reach the gonads. The gonads are represented by white streaks without any germ cell.

## TURNER'S SYNDROME (Henry Turner, 1938)

The cases usually present as primary amenorrhea with delayed secondary sex characters.

The syndrome is characterized by short stature (height < 150 cm), webbing of the neck, cubitus valgus, broad shield chest, low hair line on the neck, lymphedema, short fourth metatarsals and poor

development of secondary sex characters. They are mentally retarded and often associated with coarctation of aorta (Figs 27.2A and B).

Cardiac (coarctation of aorta). Renal anomalies (horseshoe kidneys) and multiglandular autoimmune disorders are common. 45X is the commonest chromosomal abnormality and 99% of fetuses are aborted.

Vagina, uterus and fallopian tubes are present. The uterus is small but is responsive to exogenous estrogen. Gonads are 'streaks' (fibrous tissue) without any follicle nor any potentiality to produce hormone (chromosomally incompetent ovarian failure). Associated autoimmune disorders like Hashimoto's thyroiditis, Addison's disease, hypothyroidism are common:

**Investigations:** Confirmation of the clinical diagnosis is by the following.

- Sex chromatin study is negative.
- Karyotype is 45, XO.
- Serum  $E_2$  is very low.
- Serum FSH and LH are elevated.
- Autoantibodies may be present (see p. 463, Ch. 28).

Thus, there is hypergonadotrophic hypogonadism state.

**Mosaic variety:** In mosaic variety, the classic

features of Turner are absent. The individual is of normal height. Ovaries are 'streaks' with few follicles. Occasionally, menstruation can occur for few cycles until the follicles are exhausted. Pregnancy has also been recorded.

- Sex chromatin is doubtful.
- Karyotype is 46, XX/45, XO.

#### Structural abnormality of X chromosome

Deletion of genetic material from short arm of 'X' chromosome leads to somatic features of Turner's syndrome (short stature). Loss of the long arm near the centromere leads to primary amenorrhea.

#### PURE GONADAL DYSGENESIS OR GONADAL AGENESIS

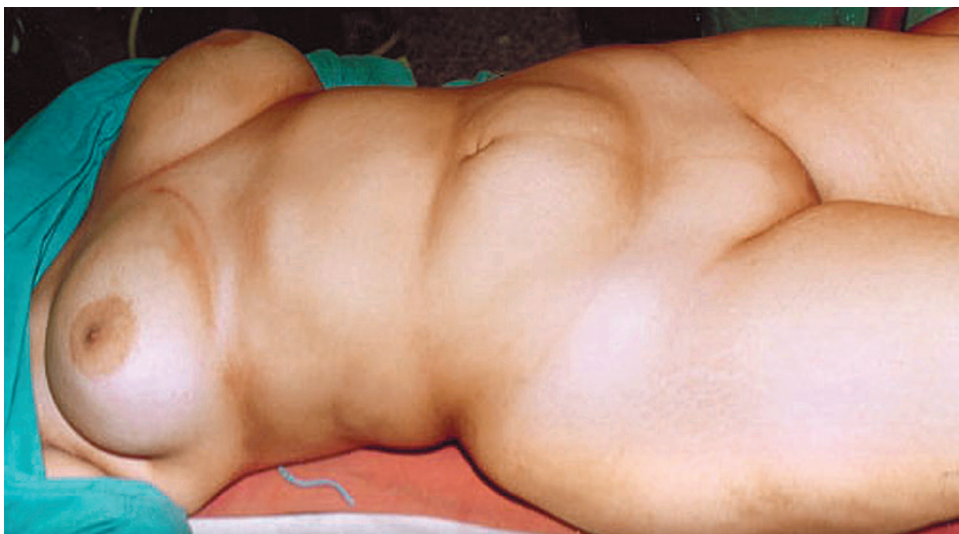The patients usually present as primary amenorrhea with delayed development of secondary sex characters.

**The stature is average.**

The vagina, uterus, and tubes are present although infantile. Gonads are bilateral 'streaks' without any potentiality to produce hormones. The uterus is, however, sensitive to exogenous estrogen.

**As these patients have got no gonads, a female phenotype is expected regardless of the chromosomal complement.**

- ♦ Sex chromatin is doubtful.
- ♦ Karyotype is either 46, XX or 46, XY.



**Fig. 27.3:** A case of androgen insensitivity syndrome. Breasts are well-developed, absent pubic hair  
[By courtesy: Prof BN Chakravorty, IRM, Kolkata]

### MIXED GONADAL DYSGENESIS

Some present with the problem of ambiguous external genitalia at birth. Usually, the patients come around puberty for features of masculinization or primary amenorrhea.

There are features of partial masculinization of the external genitalia. The gonad of one side is testis and on the other side a 'streak'.

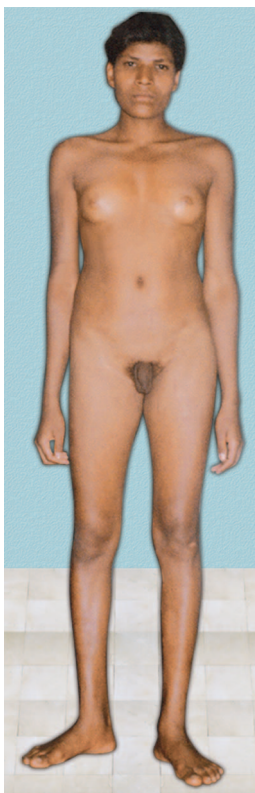The karyotype is usually 45, XO/46, XY.

### MALE INTERSEX

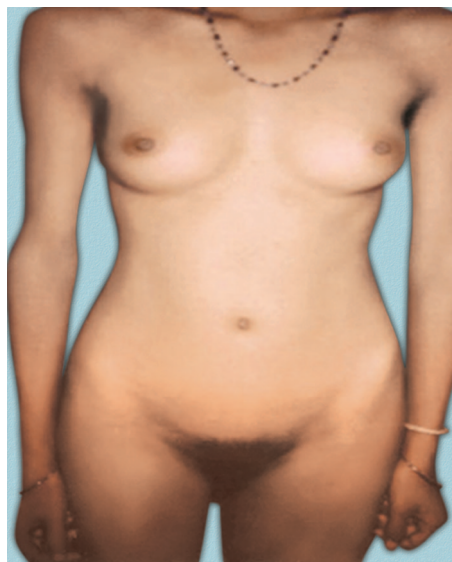#### ANDROGEN INSENSITIVITY SYNDROME (TESTICULAR FEMINIZATION)

The condition is inherited as a X-linked recessive gene. The underlying pathology is the inability of the endorgans to respond to androgens. Either, there is lack of androgen cytosol receptor or the receptor is defective (mutated).

- The cases are rarely diagnosed prior to puberty.



**Fig. 27.4:** A case of Klinefelter's syndrome having gynecomastias [By courtesy: Dr B Ghosh, Burnpur]

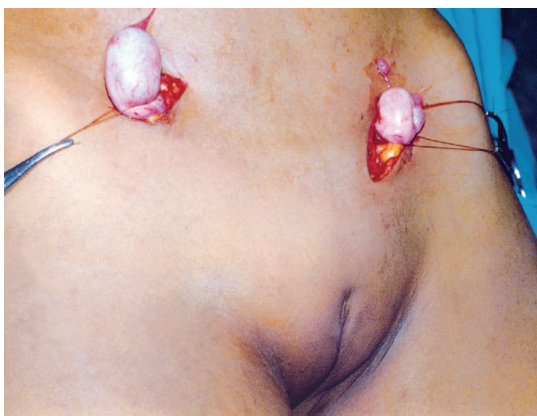


**Fig. 27.5:** A case of sex reversal 47, XXY female Klinefelter [By courtesy: Prof BN Chakravorty, IRM, Kolkata]

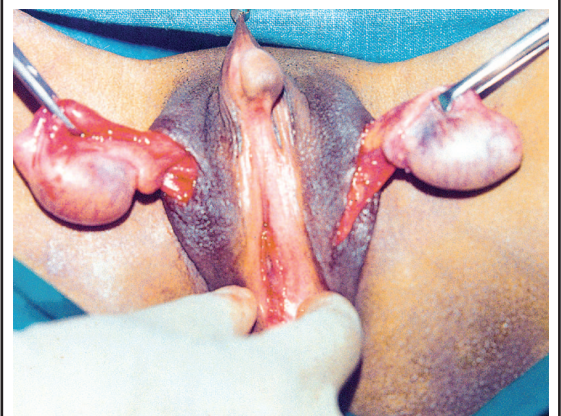
- Usually presents with primary amenorrhea and or infertility.
- They are phenotypically and psychologically female.
- Breast development is adequate (Fig. 27.3).
- The nipples are small with pale areola.
- There is eunuchoidal tendency (long arms, big hands and feet).
- Absent or sparse axillary and pubic hair (Fig. 27.3).
- External genitalia looks female.
- Vagina is short and blind (Fig. 27.7). The upper two-thirds of vagina, uterus and tubes are absent due to the effect of AMH. The gonads (Sertoli cells) secrete AMH (Anti-Müllerian hormone).
- Gonads (testes) are either placed in the labia, or inguinal canal or intra-abdominal (Figs 27.6 and 27.7).

#### Investigations

- Sex chromatin is negative.
- **Karyotype is 46, XY.**
- Serum testosterone is within average for normal males.
- Serum E2 level is high normal for males.
- Serum LH level is normal or slightly elevated.
- Confirmation of diagnosis is by gonadal biopsy.



**Fig. 27.6:** Testicular feminization—bilateral inguinal gonads [By courtesy: Prof BN Chakravorty, IRM, Kolkata]



**Fig. 27.7:** Bilateral labial gonads (testes) and short blind vagina in testicular feminization [By courtesy: Prof BN Chakravorty, IRM, Kolkata]

### Gonadal biopsy

- Seminiferous tubules are small, hyalinized.
- Spermatogenesis is absent.
- Leydig cells and Sertoli cells are normal.

### KLINFELTER'S SYNDROME

The patients are eunuchoid in build, infertile with small penis, testis and varying degrees of gynecomastias (Fig. 27.4). The features at times become confusing when first seen in adolescence (Fig. 27.5).

- Sex chromatin is positive.
- Karyotype is XXY or XXXY.
- Genitalia—small and infantile. Genital ducts are Wolffian.
- Serum gonadotrophins are elevated.

Cases of sex reversal 47, XXY female Klinefelter have been recorded (Fig. 27.5). Breasts are well-developed and secondary sexual characters are female (Fig. 27.5).

### TRUE HERMAPHRODITISM

The condition is common among Bantu tribes in southern part of Africa.

The entity is due to chromosomal defect and genetic cause.

### Types

Both the testicular and ovarian tissues are present in an individual in different combinations.

- Ovotestis on each side (commonest).
- Testis on one side, ovary on the other.
- Testis or ovary on one side and ovotestis on the other.

It is probable that fertilization by a sperm carrying one 'X' chromosome, which contains some male determining material from 'Y' gives rise to this condition.

- The common presentation is ambiguity of external genitalia.
- The internal structures depend on the degree of differentiation of the associated gonad on that side.
- 75% develop gynecomastia and nearly 50% menstruate.

### Investigations

- Sex chromatin is usually positive.
- Karyotype is usually 46, XX (70%), rest are 46, XY and rarely mosaic XX/XY.
- Confirmation of diagnosis is by gonadal biopsy.

### DIAGNOSIS OF INTERSEX

**At birth:** Most cases of ambiguous genitalia detected at birth are due to either congenital adrenal hyperplasia (21-hydroxylase deficiency) or to androgenic drugs administered to the mother in early pregnancy.

**At puberty:** Most cases presented at puberty are late manifestations of congenital adrenal hyperplasia, those of gonadal dysgenesis and rarely male intersex (testicular feminization). In these conditions, the child is reared up as girl and she is brought to the clinician either for poor development of secondary sex characters or for primary amenorrhea with or without hirsutism.

**Diagnosis of Ambiguous Genitalia:** It is a major diagnostic problem. Combined approach by endocrinologist, geneticist, neonatologist, psychiatrist and urologist is needed.

#### Thorough Physical Examination to note:

- ♦ Life-threatening conditions with features of vomiting, dehydration, diarrhea, or shock must be excluded (adrenal failure).
- ♦ Height and secondary sexual characters.

- ♦ Presence of vagina or urogenital sinus.
- ♦ Length of phallus: In a normal newborn clitoris measures < 1 cm and penis is < 2.5 cm, in length.
- ♦ Urethral meatus: Opening into perineal area or into urogenital sinus or hypospadias is noted.
- ♦ Labioscrotal folds: Degree of fusion is noted.
- ♦ Location of gonads: Gonads may be felt in the inguinal or in the labial region.

The diagnostic features are described in the Table 27.2.

A normal looking girl with primary amenorrhea who have normal breast development but no uterus may be either a case of M-R-K-H syndrome (see p. 454) or testicular feminisation syndrome (see p. 443). The diagnostic features are given in Table 27.1.

## MANAGEMENT OF INTERSEX

### BASIC GUIDELINES

Gender assignment rests on—(i) projected appearance of genitalia after puberty, (ii) penile length and (iii) prospect of future fertility.

- ♦ It is always better to diagnose the correct nature of intersex at birth or as early as possible. This is essential not only to correct the underlying disorders promptly but also to avoid the adverse psychological effect on the child and the family.
- ♦ If the diagnosis remains uncertain or the corrective surgery is deferred for the future, the baby should be reared up as female.

**(1) Management of adrenogenital syndrome:** Hydrocortisone 10–20 mg/m<sup>2</sup> body surface area per day is given to suppress the excess ACTH secretion. Mineralocorticoid (flurocortisone) is also given in cases with 21-hydroxylase deficiency. Cases with salt loss must be replaced carefully. Thereafter, a long-term therapy with corticosteroid is essential to suppress the adrenocortical hyperfunction.

Once the neonate is stable, surgery to reduce the enlarged clitoris (reduction clitoroplasty) may be done. Reconstructive surgery includes clitoroplasty and vaginoplasty. Timing of surgery is debated. However, it is recommended to perform vaginoplasty with the onset of puberty. However, the reproductive potentiality remains unaffected, if treated early. **Prenatal diagnosis** is possible with chorion villus sampling at early weeks (9–12) of pregnancy using DNA probes. 17-OHP

TABLE 27.1

#### DIFFERENTIATION OF A NORMAL LOOKING GIRL PRESENTING WITH PRIMARY AMENORRHEA HAVING NORMAL BREAST DEVELOPMENT BUT ABSENT UTERUS

Characters	Androgen insensitivity syndrome	Müllerian agenesis (M-R-K-H syndrome)
1. Sexual hair (pubic and axillary)	Absent or sparse	Normal female
2. Primary amenorrhea	Present	Present
3. Vagina	Short and blind	Absent
4. Clitoris	Enlarged	Normal female
5. Gonads:		
• Structure	Testes	Ovary
• Location	Inguinal, labial or abdominal	Abdominal
6. Breasts	Developed	Developed
7. Serum testosterone level	Slightly elevated	Normal female
8. Müllerian system	Absent	Absent or rudimentary
9. Wolffian system	Absent	Absent
10. Karyotype	46, XY	46, XX
11. Associated anomalies	Rare	Skeletal 12% and urological (renal) 47%

level in the amniotic fluid (amniocentesis) is elevated. Prenatal therapy with dexamethasone or termination of pregnancy is the option.

- (2) **In cases of gonadal dysgenesis**, karyotyping should be done. The presence of 'Y' chromatin necessitates removal of the gonads as there is chance of dysgerminoma, seminoma or gonadoblastoma in such gonads. Substitution therapy using cyclic estrogen and progesterone will help to develop secondary sex characters.

### Turner's syndrome

- ◆ Exogenous growth hormone (GH) can increase the height.
- ◆ Low dose estrogen (conjugated estrogen 0.625 mg) orally daily for 25 days with progestin (medroxyprogesterone acetate 5 mg daily) for last 10 days is started after 13 years of age.

- (3) **In cases of androgen insensitive syndrome**, the individual should be reared up as a girl. The ectopic gonads (testes) are to be removed (Figs 27.6 and 27.7) as the risks of gonadal malignancy (gonadoblastoma or dysgerminoma) are high (5–10%). Vaginoplasty is done after the growth is completed (16–18 years) with development of secondary sex characters. After gonadectomy, long-term estrogen replacement therapy should be prescribed for its effect on vaginal epithelium, osteoporosis and cardiovascular system (see p. 456).

Appropriate counseling is done. It may be psychologically traumatic to disclose the diagnosis either to the patient or to the parents. They should be told that as the gonads are abnormal and they should be removed.

- (4) **In rare variety of true hermaphrodite**, the change of sex depends on sex of rearing, psychological and the anatomic sex. The genitalia inconsistent with sex assignment should be surgically removed or modified. In general, it is possible to change the external genitalia from male to female but not from female to male. Management depends upon the phenotype. The gonads are to be removed to be followed by substitution therapy.

### UTERINE HERNIA SYNDROME

In this condition uterus and tubes are found in an inguinal hernia sac. Gonads are testes and are undescended. The affected individual is a male with 46, XY karyotype. This is due to failure of AMH function or secretion.

### TESTICULAR REGRESSION SYNDROME (SWYER SYNDROME)

- ◆ The individual presents with primary amenorrhea.
- ◆ External genitalia are female.
- ◆ Internal genital organs are female.
- ◆ Secondary sexual characters are absent.
- ◆ Karyotype 46, XY.
- ◆ Gonads are fibrous due to failure of development or regression.

It is thought to be due to mutation in SRY gene at the Y chromosome. Gonadectomy is recommended. Estrogen and progestin therapy is given for development of secondary sex characters.

**TABLE 27.2** ENTITY, CLINICAL PRESENTATION AND DIAGNOSIS OF INTERSEX

Entity	Clinical presentation	Diagnostic criteria
Adrenogenital syndrome	– Ambiguity of sex at birth	<ul style="list-style-type: none"> <li>– Sonographic evaluation of internal genital organs</li> <li>– Karyotype 46, XX</li> <li>– Serum 17 hydroxy-progesterone ↑</li> <li>– Urinary pregnanetriol ↑ &gt; 5 µg/100 ml</li> </ul>
—do— (mild form)	– Virilism and amenorrhea at puberty	<ul style="list-style-type: none"> <li>– Karyotype 46, XX</li> <li>– Serum 17 hydroxy-progesterone ↑</li> </ul>
Masculinization due to androgen excess in maternal circulation	– Ambiguity of sex at birth	<ul style="list-style-type: none"> <li>– History of drug intake</li> <li>– Karyotype 46, XX</li> <li>– Serum 17 hydroxy-progesterone —normal.</li> </ul>



**TABLE 27.2** ENTITY, CLINICAL PRESENTATION AND DIAGNOSIS OF INTERSEX *Contd. from previous page*

Entity	Clinical presentation	Diagnostic criteria
Gonadal dysgenesis ♦ Turner's syndrome	<ul style="list-style-type: none"> <li>- Primary amenorrhea</li> <li>- Poor secondary sex characters</li> <li>- Short stature</li> <li>- Webbing of neck</li> <li>- Cubitus valgus</li> <li>- Genitalia underdeveloped</li> </ul>	<ul style="list-style-type: none"> <li>- Sex chromatin 45, XO</li> <li>- Bilateral 'streak' gonads</li> <li>- Serum: E2 ↓ and FSH ↑</li> </ul>
Mosaic Turner	<ul style="list-style-type: none"> <li>- Primary/secondary amenorrhea</li> <li>- Average height</li> <li>- Poor secondary sex characters</li> <li>- Genitalia underdeveloped</li> </ul>	<ul style="list-style-type: none"> <li>- Sex chromatin 45, XO/46, XX</li> <li>- Bilateral 'streak' gonads</li> </ul>
♦ Pure gonadal dysgenesis	<ul style="list-style-type: none"> <li>- Primary amenorrhea</li> <li>- Delayed secondary sex characters</li> <li>- Average height</li> <li>- Genitalia underdeveloped</li> </ul>	<ul style="list-style-type: none"> <li>- Sex chromatin—46, XX or 46, XY</li> <li>- Bilateral 'streak' gonads</li> </ul>
♦ Mixed gonadal dysgenesis	<ul style="list-style-type: none"> <li>• At birth:               <ul style="list-style-type: none"> <li>- Ambiguity of sex</li> </ul> </li> <li>• At puberty:               <ul style="list-style-type: none"> <li>- Virilism with amenorrhea</li> <li>- External genitalia—partial masculinization</li> </ul> </li> </ul> <p>Internal genitalia may be unilateral Müllerian development</p>	<ul style="list-style-type: none"> <li>- Karyotype — 45 XO/46 XY</li> <li>- Gonads—testis on one side and on the other side a 'streak'</li> </ul>
Testicular feminization	<ul style="list-style-type: none"> <li>- Primary amenorrhea</li> <li>- Infertility</li> <li>- Phenotypically female</li> <li>- Breast development—good</li> <li>- External genitalia—female</li> </ul>	<ul style="list-style-type: none"> <li>- Axillary and pubic hair scanty or absent</li> <li>- Short, blind vagina</li> <li>- Gonads—Labial, inguinal or abdominal</li> <li>- Karyotype—46, XY</li> <li>- Gonads are testes</li> </ul>
Klinefelter's syndrome	<ul style="list-style-type: none"> <li>- Eunuchoid</li> <li>- Infertility (azoospermia)</li> <li>- Gynecomastia</li> </ul>	<ul style="list-style-type: none"> <li>- External genitalia—male</li> <li>- Genital ducts—Wolffian</li> <li>- Gonads—testes (small)</li> <li>- Sex chromatin—positive</li> <li>- Karyotype—47 XXY</li> </ul>
True hermaphroditism	<ul style="list-style-type: none"> <li>- Ambiguity of sex at different phase of early life</li> <li>- Amenorrhea</li> </ul>	<ul style="list-style-type: none"> <li>- Karyotype is usually 46, XX; may be 46, XY or 46, XX or 46, XX/46, XY</li> <li>- Gonadal biopsy is confirmatory</li> <li>- Common—ovotestes</li> </ul>

## KEY POINTS

- ▶ The incidence of intersex is about 2 per 1,000.
- ▶ Female intersex is association of female gonads with male external genitalia.
- ▶ Male intersex is association of male gonads with female external genitalia.
- ▶ True hermaphrodite is an individual possessing both ovaries and testes with ambiguity of genital organs.
- ▶ Female intersex is due to congenital adrenal hyperplasia (commonest) or due to increased androgen in maternal circulation.

Ambiguity of sex at birth is due to adrenogenital syndrome unless proved otherwise. The entity is confirmed by elevated serum 17 hydroxyprogesterone and urinary pregnanetriol with karyotype 46, XX. Prenatal diagnosis can be made by CVS or amniocentesis using DNA probe.

- ▶ Disorders of gonadal development include—gonadal dysgenesis, gonadal agenesis and mixed gonadal dysgenesis.
  - Turner's syndrome is the commonest variety of gonadal dysgenesis. The individual is short (< 60"), absence of secondary sex characters with webbing of the neck and having 'streak' gonads. Karyotype is 45, XO with low serum E2 and elevated serum FSH. There may be mosaic Turner with karyotype—46, XX/45 XO. In pure gonadal dysgenesis, the karyotype is either 46, XX or 46, XY. In mixed gonadal dysgenesis, the karyotype is usually 45, XO or 46, XY.
- ▶ About one-third of women with gonadal dysgenesis have major cardiovascular or renal abnormalities. Individuals with gonadal dysgenesis should have karyotyping done to determine the presence of Y chromosome.
- ▶ Male intersex (Testicular feminization) is rarely diagnosed prior to puberty. The patient is phenotypically female with short blind vagina and gonads (testes) are in the labia or inguinal canal or intra-abdominal. Sex chromatin is negative. Karyotype is 46, XY. Confirmation is by gonadal biopsy (structures of testis). Gonadal estrogen secretion induces normal pubertal feminization and breast development.
 

In Klinefelter's syndrome, the sex chromatin is positive and the karyotype is XXY or XXXY. Serum gonadotropin is elevated.
- ▶ In true hermaphrodite, ovotestis is the commonest presentation. Sex chromatin is positive. Karyotype is usually 46, XX or 46, XY. Confirmation is by gonadal biopsy.
- ▶ A normal looking girl with primary amenorrhea, who has normal breast development but absent uterus, may be either a case of Mayer-Rokitansky-Küster-Hauser syndrome or androgen insensitivity syndrome (p. 445, Table 27.1).

- ▶ Gonadal dysgenesis and uterovaginal anomalies are the common causes of primary amenorrhea.

### ▶ Management of intersex

- Congenital adrenogenital syndrome should be treated energetically by hydrocortisone or dexamethasone. Apart from reduction clitoroplasty, the corrective surgery should be deferred till puberty (see p. 445).
- Cases of gonadal dysgenesis should be treated by substitution therapy with estrogen and progestogen. In presence of 'Y' chromosome, gonadectomy should be done to prevent malignancy.
- In testicular feminization, gonadectomy is to be done after the development of secondary sex characters (puberty) to be followed by estrogen supplementation therapy (see p. 446).
- In true hermaphrodite, the genitalia inconsistent with sex assignment should be surgically removed or modified (see p. 446).

# Amenorrhea

## DEFINITION

Amenorrhea literally means absence of menstruation. It is a symptom and not a disease.

**There are at least five basic factors** involved in the onset and continuation of normal menstruation. These are:

- Normal female chromosomal pattern (46XX).
- Coordinated hypothalamopituitary ovarian axis.
- Anatomical presence and patency of the outflow tract.
- Responsive endometrium.
- Active support of thyroid and adrenal glands.

## CLINICAL TYPES

For descriptive purposes, the following types are conveniently described (vide scheme below). This will help the clinicians to sort out the clinico-pathological entity.

## PHYSIOLOGICAL



### Before Puberty

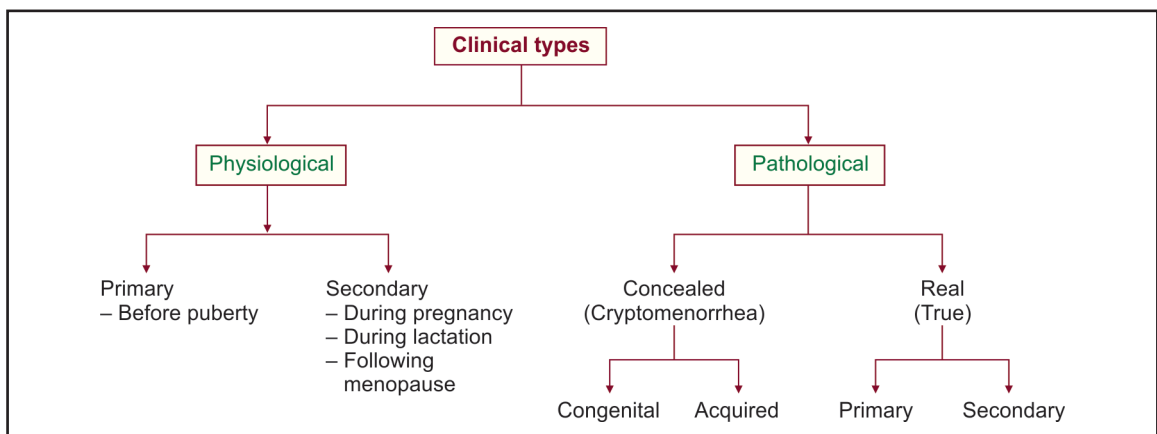
The pituitary gonadotropins are not adequate enough to stimulate the ovarian follicles for effective steroidogenesis → estrogen levels are not sufficient enough to cause bleeding from the endometrium.

### During Pregnancy

Large amount of estrogens and chorionic gonadotropins secreted from the trophoblasts suppress the pituitary gonadotropins → no maturation of the ovarian follicles.

### During Lactation

High level of prolactin → inhibits ovarian response to FSH → no follicular growth → hypoestrogenic state → no menstruation. If the patient does not breastfeed her baby, the menstruation returns by 6th week following delivery in about 40 percent and by 12th



week in 80 percent of cases. If the patient breastfeeds her baby, the menstruation may be suspended in about 70 percent until the baby stops breast-feeding.

### Following Menopause

No more responsive follicles are available in the ovaries for the gonadotropins to act. As a result, there is cessation of estrogen production from the ovaries with elevation of pituitary gonadotropins.

## PATHOLOGICAL

### CRYPTOMENORRHEA

In cryptomenorrhea, there is periodic shedding of the endometrium and bleeding but the menstrual blood fails to come out from the genital tract due to obstruction in the passage.

### CAUSES

#### ◆ Congenital ◆ Acquired

#### Congenital

- ▶ Imperforate hymen
- ▶ Transverse vaginal septum
- ▶ Atresia of upper-third of vagina and cervix.

Morbid pathological changes, clinical features and treatment of the congenital etiology have been described in the Chapter 4.

#### Acquired

- ▶ Stenosis of the cervix following amputation, deep cauterization and conization.
- ▶ Secondary vaginal atresia following neglected and difficult vaginal delivery.

**PATHOLOGY:** There is only accumulation of blood in the uterine cavity resulting in hematometra. In neglected cases, the blood may enter the tubes whose fimbrial ends get blocked resulting in distension of the tubes by blood → hematosalpinx.

**CLINICAL FEATURES:** The patients with history of any of the etiological factors mentioned earlier, complain of:

- ▲ Amenorrhea dated back from the events.
- ▲ Periodic pain lower abdomen.

Pelvic examination reveals the offending lesion either in the vagina or cervix. The uterus is symmetrically enlarged.

### TREATMENT

Simple dilatation of the cervix so as to drain the collected blood is enough. In cases of secondary atresia of the vagina, reconstructive surgery is to be performed, to maintain the patency.

### SUMMARY OF CRYPTOMENORRHEA

**Cryptomenorrhea** is a condition where the menstrual blood fails to come out from the genital tract due to obstruction in the passage.

#### Causes

**The commonest cause** is congenital due to imperforate hymen. The acquired cause is rare due to cervical stenosis following amputation, conization or deep cauterization.

#### Pathophysiology

If the site of obstruction is low down in the vagina, the accumulated blood results in hematocolpos → hematometra → hematosalpinx. If the obstruction is at the cervix, it will produce hematometra → hematosalpinx. **Hematocolpos produces marked elongation of the urethra → retention of urine.**

#### Clinical features

The patient aged about 13–15 (congenital type) complains of periodic pain lower abdomen. Hematocolpos is usually associated with urinary problems to the extent of retention of urine. Abdominal examination reveals a uniform globular mass in the hypogastrium. Vulval inspection reveals the bulging hymen. Rectal examination confirms the fullness of the vagina and uterine mass.

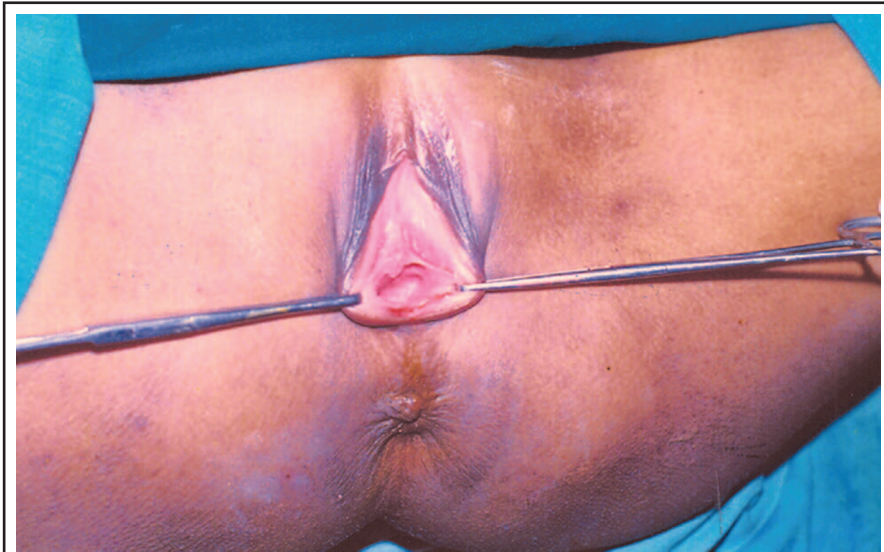#### Management

- (i) Cruciate incision of the hymen and drainage of blood (see Fig. 4.4).
- (ii) Dilatation of the cervix in stenosis.

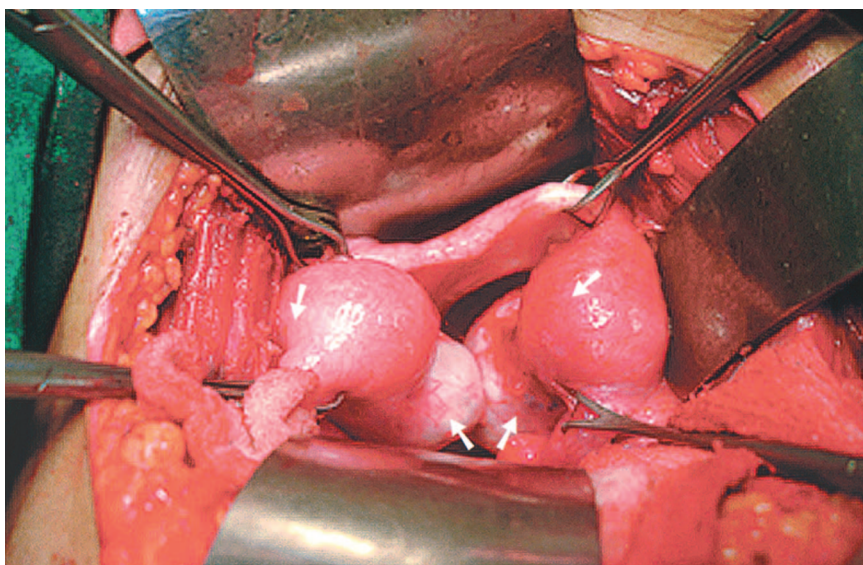
### PRIMARY AMENORRHEA

**DEFINITION:** A young girl who has not yet menstruated by her 16 years of age is having primary amenorrhea rather than delayed menarche. The normal upper age limit for menarche is 15 years.

In view of lower mean age of menarche, currently a cut off value at 14 years (in the absence of secondary sexual characters) and 16 years (regardless of the presence of secondary sexual characters) is being considered.



**Fig. 28.1:** Complete absence of vagina [By courtesy: Prof KM Gun]



**Fig. 28.2:** Müllerian agenesis with small uterine knobs one on either side (down arrow). Normal ovaries are seen (up arrow). Cervix and vagina were absent in this case [By courtesy: Dr PK Biswas, Professor, Department of Obstetrics and Gynecology, CNMCH, Kolkata]

**CAUSES:** The causes of primary amenorrhea are grouped as follows:

#### A. Hypogonadotropic hypogonadism

- (i) *Delayed puberty* — delayed GnRH pulse reactivation.
- (ii) *Hypothalamic and pituitary dysfunction* — Gonadotropin deficiency due to stress, weight loss, excessive exercise, anorexia nervosa, chronic disease (tuberculosis).
- (iii) *Kallmann's syndrome* — inadequate GnRH pulse secretion — reduced FSH and LH (see p. 464).
- (iv) *Central nervous system tumors* — craniopharyngioma → reduced GnRH secretion → reduced FSH and LH.

### B. Hypergonadotropic hypogonadism

- (i) *Primary ovarian failure* (see p. 463).
- (ii) *Resistant ovarian syndrome* (see p. 463).
- (iii) *Galactosemia*: Due to premature ovarian failure (see p. 464).
- (iv) *Enzyme deficiency (17  $\alpha$  hydroxylase deficiency)* — characterized by  $\downarrow$  cortisol and  $\uparrow$  ACTH,  $\uparrow$  mineralocorticoids production. There is hypertension with hypernatremia and hypokalemia. The individual may be 46 XX or 46 XY with primary amenorrhea and no secondary sexual characters.
- (v) *Others* — Gonadotropin receptor mutations – rarely FSH and/or LH levels are high as the respective receptor may be absent or mutated.

### C. Abnormal chromosomal pattern

- Turner's syndrome (45 X) (Figs 27.2A and B).
- Various mosaic states 45 X/46 XX.
- Pure gonadal dysgenesis (46 XX or 46 XY) — Phenotypically female with streak gonads. Stature is average with some secondary sexual characters.
- Androgen insensitivity syndrome (Testicular feminization syndrome), 46 XY (see Fig. 27.3).
- Partial deletions of the X chromosome (46 XX).

When part of one X chromosome is missing — deletion of long arm of X chromosome ( $Xq^-$ ) leads to streak gonads and amenorrhea but no somatic abnormalities. Deletion of short arm of X chromosome ( $Xp^-$ ) usually leads to somatic features similar to Turner's syndrome.

### D. Developmental defect of genital tract

- Imperforate hymen (Fig. 4.2).
- Transverse vaginal septum.
- Atresia upper-third of vagina and cervix (Fig. 4.5).
- Complete absence of vagina (Fig. 28.1).
- Absence of uterus in MRKH syndrome (Fig. 28.2 and Table 27.1).

### E. Dysfunction of thyroid and adrenal cortex

- Adrenogenital syndrome (Figs 27.1 and 32.1).
- Cretinism.

### F. Metabolic disorders

- Juvenile diabetes.

### G. Systemic illness

- Malnutrition, anemia

- Weight loss
- Tuberculosis.

### H. Unresponsive endometrium

- Congenital
  - Uterine synechiae (tubercular).

## INVESTIGATIONS

The basic disorders responsible for primary amenorrhea almost always have some specific clinical manifestations. The diagnosis and management of cryptomenorrhea of congenital variety has already been described in chapter 4. **Only the true primary amenorrhea is dealt with here.**

### When to start investigation?

The following guidelines may be of help:

- (i) No period by 16 years of age in the presence of normal secondary sex characters.
- (ii) No period by the age of 14 in the absence of growth or development of secondary sex characters.

However, the formula may not be applicable in all cases. A patient may come with typical features suggestive of Turner and there is no point to defer the investigation or a patient of 14 with absence of vagina should not be told to come after 2 years for investigation. Even in primary amenorrhea, the possibility of pregnancy should be kept in mind, as pregnancy can occur even prior to menarche. **The investigation protocols can be grouped as:**

## HISTORY, CLINICAL EXAMINATION, SPECIAL INVESTIGATIONS

### History

Certain types of primary amenorrhea are of heredo-familial in nature. Delayed menarche or androgen insensitivity syndrome often runs in family, the later one is often found in multiple sibs of the same family and their maternal aunts.

**Medical diseases:** Genital tuberculosis or diabetes though rare, may be responsible for primary amenorrhea. Such type of amenorrhea is usually associated with hypogonadism.

**Other features:** Abnormal loss or gain in weight within short span of time is suggestive of some metabolic disorders.

### Clinical Examination

With few exceptions, the physical signs are so apparent that the clinical diagnosis of etiological factors of primary amenorrhea does not seem to be

difficult. The diagnosis of some common causes based on clinical examinations are tabulated in Table 28.1.

**TABLE 28.1** DIAGNOSIS OF PRIMARY AMENORRHEA BASED ON CLINICAL EXAMINATIONS

Physical appearance	External genitalia	Internal genitalia	Probable diagnosis
<ul style="list-style-type: none"> <li>◆ Secondary sex characters</li> <li>◆ Stature</li> </ul>			
<ul style="list-style-type: none"> <li>– Normal breast development</li> <li>– Normal sexual hair</li> <li>– Average stature</li> </ul>	– Normal	<ul style="list-style-type: none"> <li>– Absence of vagina</li> <li>– Absent uterus</li> </ul>	<ul style="list-style-type: none"> <li>• Müllerian agenesis (Mayer-Rokitansky-Küster-Hauser syndrome)</li> </ul>
—do—	—do—	– Normal	<ul style="list-style-type: none"> <li>• Unresponsive endometrium — receptor defect (Rare)</li> <li>• Uterine synechiae (Rare)</li> </ul>
<ul style="list-style-type: none"> <li>– Poor breast development</li> <li>– Scanty pubic hair</li> <li>– Average stature</li> </ul>	– Underdeveloped	– Underdeveloped (vaginal rugosity absent)	<ul style="list-style-type: none"> <li>• Hypogonadotropic — hypogonadism</li> </ul>
– Tall and lanky	—do—	—do—	• Primary ovarian failure
<ul style="list-style-type: none"> <li>– Poor secondary sex characters</li> <li>– Stature — short</li> <li>– Webbing of the neck and cubitus valgus present</li> <li>– Congenital malformations of cardiac, renal or great vessels (coarctation of aorta)</li> <li>– Phenotypically female</li> <li>– Average height</li> <li>– Delayed secondary sex characters</li> </ul>	—do—	—do— 'Streak' gonads	• Turner's syndrome
	Normal	Bilateral 'streak' gonads	• Pure gonadal dysgenesis
<ul style="list-style-type: none"> <li>– Normal breast development without areolar pigmentation</li> <li>– Scanty pubic and axillary hair</li> <li>– Average stature</li> </ul>	– Labial or inguinal gonads (Figs 27.6 and 27.7)	<ul style="list-style-type: none"> <li>– Short blind vagina</li> <li>– Absence of uterus</li> </ul>	• Androgen insensitivity syndrome
<ul style="list-style-type: none"> <li>– Normal phenotypically female</li> <li>– Average stature</li> </ul>	<ul style="list-style-type: none"> <li>– Labial fusion</li> <li>– Enlargement of clitoris</li> </ul>	– Normal	• Adrenogenital syndrome (Late onset)
<ul style="list-style-type: none"> <li>– Features of (Hypogonadotropic hypogonadism)</li> <li>◆ Short stature</li> <li>◆ Mental retardation</li> <li>◆ Obesity, retinitis pigmentosa</li> </ul>	– Underdeveloped	– Underdeveloped	<ul style="list-style-type: none"> <li>• Cretinism due to hypothyroidism</li> <li>• Hypothalamo-pituitary dysfunction (rare) <ul style="list-style-type: none"> <li>– Kallmann syndrome</li> <li>– Prader-Labhardt-Willi syndrome</li> <li>– Laurence-Moon-Bardet-Biedl syndrome (rare)</li> </ul> </li> </ul>

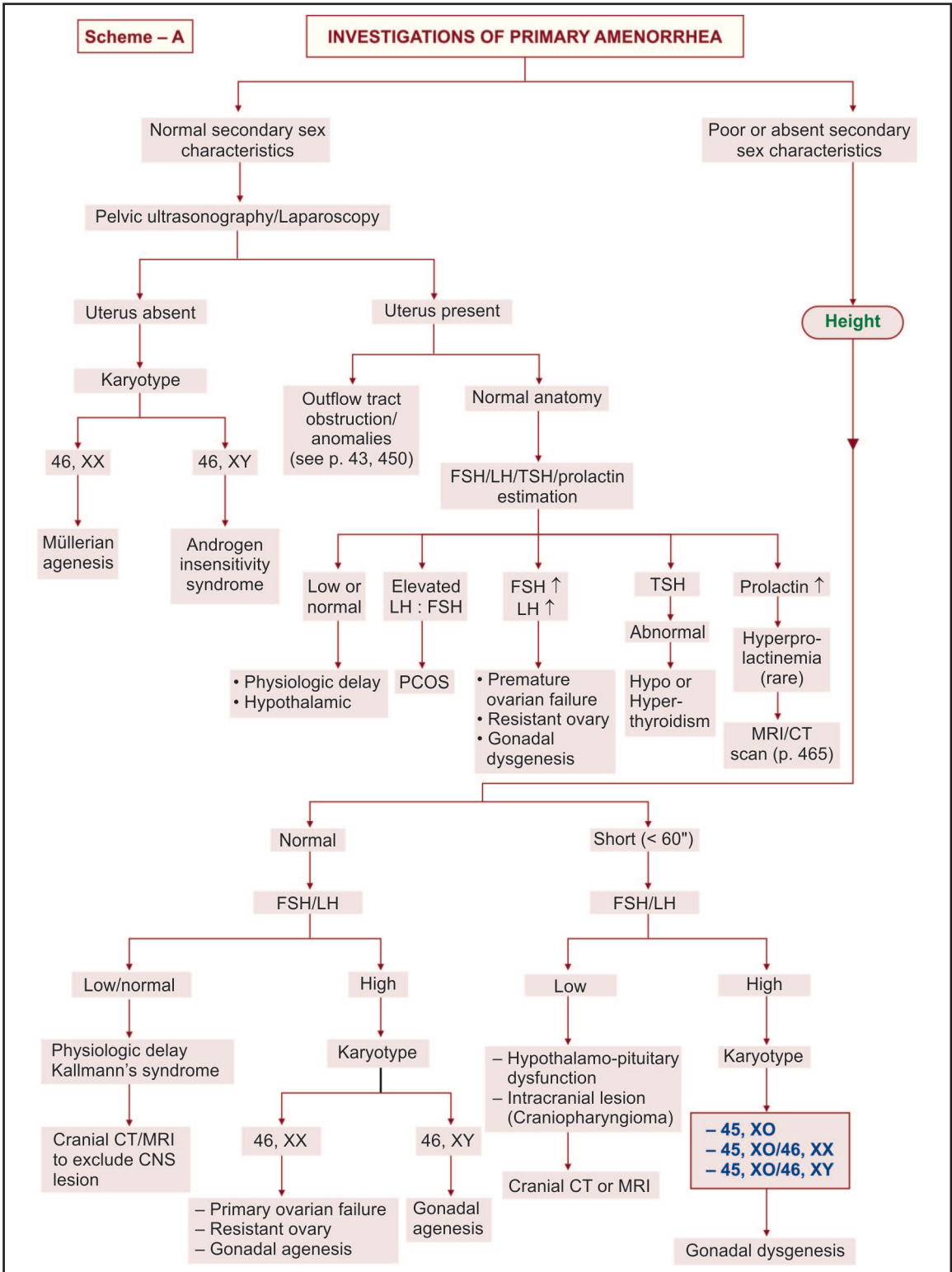
TABLE 28.2

## SPECIAL INVESTIGATIONS IN A CASE OF PRIMARY AMENORRHEA TO CORROBORATE CLINICAL DIAGNOSIS

Probable diagnosis	Investigations	Findings
Müllerian agenesis (Mayer-Rokitansky–Küster–Hauser syndrome)	<ul style="list-style-type: none"> <li>– Ultrasonography</li> <li>– Laparoscopy</li> <li>– Karyotype</li> <li>– IVP</li> </ul>	Uterus — absent Tubes — present Ovaries — normal 46, XX Urinary tract abnormalities (30%)
Unresponsive endometrium	*– Progesterone challenge test – HSG/Hysteroscopy – Hormonal studies	Negative Normal uterine cavity Normal
Uterine synechiae	<ul style="list-style-type: none"> <li>– Progesterone challenge test</li> <li>– HSG</li> <li>– Hysteroscopy</li> </ul>	Negative Honeycomb appearance Direct visualization
Tubercular (see p. 137)	<ul style="list-style-type: none"> <li>– Blood — ESR</li> <li>– X-ray — Chest</li> <li>– Mantoux test</li> <li>– Endometrial biopsy</li> </ul>	Raised May have positive finding Positive (usually) Positive lesion may be detected
Hypogonadotropic – hypogonadism	<ul style="list-style-type: none"> <li>– Progesterone challenge test</li> <li>– Serum gonadotropins</li> <li>– Serum estradiol</li> </ul>	Negative Low < 5 mIU/mL Low (< 20 pg/mL)
Primary ovarian failure (see p. 444)	<ul style="list-style-type: none"> <li>– Karyotype</li> <li>– Serum estradiol</li> <li>– Serum gonadotropins</li> <li>– Ovarian biopsy (ovaries — small/ streak) ovarian biopsy is not essential for diagnosis</li> </ul>	46, XX Low (< 20 pg/mL) Elevated > 40 mIU/mL (i) Afollicular (common), (ii) follicular or (iii) autoimmune (lymphocytic infiltration) type. Follicles are present in resistant ovarian syndrome
Turner (p. 422)	<ul style="list-style-type: none"> <li>– Laparoscopy</li> <li>– Serum gonadotropins</li> <li>– Karyotype</li> </ul>	‘Streak’ gonads High 45, XO or 45, XO/46, XX
Androgen insensitivity syndrome (p. 424)	<ul style="list-style-type: none"> <li>– Laparoscopy</li> <li>– Serum testosterone</li> <li>– Karyotype</li> <li>– Gonadal biopsy</li> </ul>	Uterus — absent Tubes — absent Equal to normal males 46, XY Testicular structure
Adrenogenital syndrome (p. 421)	<ul style="list-style-type: none"> <li>– Karyotype</li> <li>– Serum 17 hydroxy-progesterone</li> <li>– Urinary pregnanetriol</li> </ul>	46, XX Elevated (> 8 ng/mL) Elevated
Thyroid dysfunction (Hypo)	<ul style="list-style-type: none"> <li>– Serum TSH</li> <li>– T<sub>3</sub>, T<sub>4</sub></li> </ul>	Elevated Lowered
Diabetes	<ul style="list-style-type: none"> <li>– Blood sugar</li> </ul>	Elevated

**\*The test is performed by administering injection Progesterone in oil 75 mg IM or Tablet Medroxyprogesterone 10 mg daily or micronized progesterone 200 mg daily for 10 days. Withdrawal bleeding usually occurs within 10 days, if the test is positive**





### Special investigations

The investigation should be restricted for corroboration of clinical diagnosis and in cases where clinical diagnosis remains disputed. The appropriate investigation protocol is tabulated in the Table 28.2.

### MANAGEMENT

The scope of therapeutic success in the management of primary amenorrhea is very limited.

### DEVELOPMENT ANOMALIES

#### Complete agenesis of vagina

Vaginal reconstruction is the accepted form of treatment. The principle of vaginal reconstruction is to create an avascular space between the bladder and rectum. The patency is to be maintained by a mould and graft. **The commonly used materials for graft** are skin or amniotic membranes. The result are quite satisfactory so far as the coital act is concerned. **The ideal time of operation** is prior to or soon after marriage.

### CHROMOSOMAL ABNORMALITIES

In Turner or other types of gonadal dysgenesis, short-term use of combination of estrogen and progesterone is indicated at least for development of breasts (see p. 446). **The gonads of XY gonadal dysgenesis should be removed** for its increased development of seminoma or dysgerminoma (see p. 446).

**In androgen insensitivity syndrome, the ectopic gonads are to be removed** after the secondary sex characters are well-developed, because they may turn to malignancy. Substitution therapy after gonadectomy is indicated to maintain the secondary sex characters. Hormone replacement therapy with conjugated equine estrogen (premarin 0.625 mg daily) is adequate (see p. 446).

### HYPOTHALAMOPITUITARY OVARIAN AXIS DEFECT

Patients with delayed puberty, following exclusion of other causes, should be counselled and reassured. Otherwise puberty may be induced using oral estrogen and progestin therapy when there is severe delay.

Gross defects in the form of adiposogenital dystrophy or pituitary dwarfism are not amenable to

any form of therapy. In mild disorders, it is possible to induce ovulation and menstruation either by treatment with gonadotropins or with GnRH analogs. Individuals with isolated gonadotropin deficiency (Kallmann's syndrome) can be treated for induction of menstruation or ovulation. Pulsatile administration of GnRH is used for induction of ovulation. Estrogen and progestin therapy is given for menstruation.

Hypothalamic-pituitary tumors (craniopharyngioma) may need surgical excision or radiotherapy. Team approach involving a gynecologist, an endocrinologist, a neurosurgeon and a radiotherapist is ideal.

### THYROID AND ADRENAL DYSFUNCTION

Gross thyroid hypoplasia (cretinism) does not respond to thyroid replacement therapy. However, mild hypothyroidism may have good result with replacement therapy. Adrenogenital syndrome with enlarged clitoris should be treated by surgical removal of clitoris (clitoroplasty) as early as possible to avoid psychological problems. Corticosteroid therapy should be continued for a prolonged period.

Corticosteroid replacement therapy is given for 17  $\alpha$  hydroxylase deficiency state.

**Prolactinomas** need to be treated with dopamine agonists (see p. 464).

### METABOLIC AND NUTRITIONAL

Diabetes and tuberculosis are to be treated by antidiabetic and antitubercular drug respectively. Correction of anemia and improvement of nutrition status may resume menstruation. Correction of malabsorption, weight loss stress and chronic diseases are to be done when indicated.

### UNRESPONSIVE ENDOMETRIUM

Uterine synechiae of tubercular origin should be treated by antitubercular drugs supplemented by adhesiolysis and intrauterine contraceptive device (IUCD) insertion. Hysteroscopic (see p. 621) release of adhesions using scissors or electrocautery can be done. To prevent recurrence of adhesion formation, high dose estrogen and progestin therapy is given monthly for withdrawal bleed. There is no known treatment as yet for congenital unresponsive endometrium (receptor defect).

## SECONDARY AMENORRHEA

### DEFINITION

It is the absence of menstruation for 6 months or more in a woman in whom normal menstruation has been established.

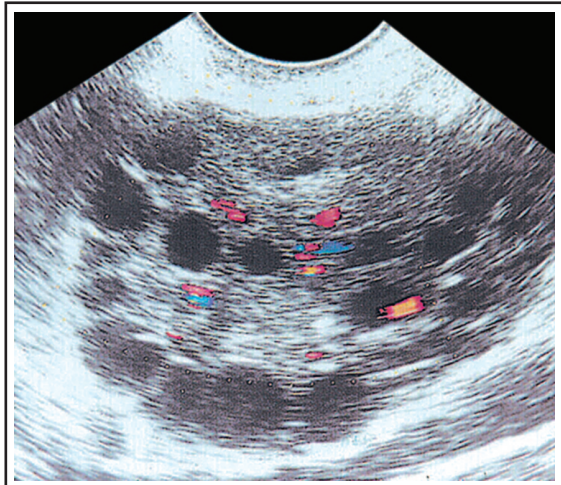
The physiological causes and cryptomenorrhea has been described earlier in the chapter. Only the true secondary amenorrhea will be discussed here.

**Etiology:** The causes of true secondary amenorrhea with the possible mechanism are outlined in Table 28.3.

### CLINICAL FEATURES AND DIAGNOSIS

#### ■ Uterine factors

**Tubercular endometritis:** The family history or past history of tuberculosis in the patient herself may or may not be present. Physical and pelvic examination



**Fig 28.3:** Color Doppler (TV) scan showing numerous small cysts with increased ovarian stroma and vascularity — typical of PCOS

**TABLE 28.3** ETIOPATHOGENESIS OF SECONDARY AMENORRHEA

Etiology	Mechanism
<b>Uterine factors</b>	
• Tubercular endometritis	— Destruction of the endometrium or inhibition of ovarian function by tubercular toxin
• Postradiation	— Destruction of the endometrium
• Synechiae	— Intrauterine adhesions → viscerocortical reflex → amenorrhea
• Surgical removal	— Ablation of endometrium by laser, resectoscope (see p. 595)
<b>Ovarian factors</b>	
• Polycystic ovarian syndrome	— Tonically elevated LH → Increased androgen production from the theca (PCOS) cells and stroma of the ovaries → Decrease SHBG → increased unbound estrogens and androgens → Pituitary sensitivity to GnRH is increased → Preferential increased production of LH, decreased production of FSH due to inhibin. Disturbed adrenal function is also implicated in androgen excess. A state of hyperandrogenism produces amenorrhea by its antiestrogenic action
• Premature ovarian failure	— Absence of follicle or accelerated rate of depletion of follicles in the ovaries
• Resistant ovarian syndrome (Savage's syndrome)	— Follicles are present but are resistant to gonadotropins (defect in FSH receptor)
• Hyperestrogenic state	— The estrogen level remains high and there is no fluctuation
– Persistent follicles in metropathia	As such, so long as endometrial support is not lost, amenorrhea continues
– Feminizing tumor of the ovary (Granulosa cell tumor)	

*Table 28.3 contd. next page*

<ul style="list-style-type: none"> <li>• Masculinizing tumor of the ovary (Sertoli-Leydig cell tumor)</li> <li>• Hypo-estrogenic state               <ul style="list-style-type: none"> <li>– Ablation of the ovaries</li> <li>– Pelvic radiation</li> </ul> </li> </ul>	<ul style="list-style-type: none"> <li>— Androgen excess opposes the effect of estrogen on the endometrium (p. 386)</li> <li>— Removal of the site of production of estrogens</li> <li>— Makes the ovaries unresponsive to gonadotropins</li> </ul>
<p><b>Pituitary factors</b></p> <ul style="list-style-type: none"> <li>• Adenoma (Prolactinoma)</li> <li>• Cushing's disease</li> <li>• Acromegaly</li> </ul>	<ul style="list-style-type: none"> <li>— Microadenoma usually associated with hyperprolactinemia. It either inhibits ovarian steroidogenesis directly or inhibits pituitary gonadotropin release (see p. 464).</li> </ul>
<ul style="list-style-type: none"> <li>• Sheehan's syndrome</li> <li>• Simmond's disease (unrelated to pregnancy)</li> </ul>	<ul style="list-style-type: none"> <li>— There is partial or complete destruction of the pituitary by ischemia caused by venous thrombosis following severe postpartum hemorrhage and shock. The principal hormones affected are growth hormone, gonadotropins, TSH, adrenocorticotropins and prolactin</li> </ul>
<p><b>Hypothalamic factors</b></p> <ul style="list-style-type: none"> <li>• Psychogenic shock, stress, anorexia nervosa, strenuous exercise, pseudocyesis, etc.</li> </ul>	<ul style="list-style-type: none"> <li>— Inhibit the release of GnRH or affect dopamine metabolism. There is low level of estrogen and LH but FSH level remains normal (see below)</li> </ul>
<ul style="list-style-type: none"> <li>• Congenital malformation</li> <li>• Trauma : Accidents, surgery or radiotherapy</li> <li>• Infection : Tubercular or sarcoid granulomas</li> <li>• Tumors : Craniopharyngioma, meningioma</li> </ul>	<ul style="list-style-type: none"> <li>— Lead to hypogonadotropic hypogonadism. There may be hyperprolactinemia due to altered dopamine inhibition. Tumors of the hypothalamus or pituitary need surgical excision or radiotherapy. Management needs a team approach including a neurosurgeon, a radiotherapist and an endocrinologist</li> </ul>
<p><b>Adrenal factors</b></p> <ul style="list-style-type: none"> <li>• Adrenal tumor or hyperplasia</li> <li>• Cushing syndrome</li> </ul>	<ul style="list-style-type: none"> <li>— Androgen excess opposes the effect of estrogen on the endometrium</li> <li>—do— —do—</li> </ul>
<p><b>Thyroid factors</b></p> <ul style="list-style-type: none"> <li>• Hypothyroid state</li> </ul>	<ul style="list-style-type: none"> <li>— Raised TSH and hyperprolactinemia by direct action of TRH on the galactophore cells in the pituitary</li> </ul>
<p><b>General disease</b></p> <ul style="list-style-type: none"> <li>• Malnutrition, tuberculosis, chronic nephritis, diabetes, etc.</li> </ul>	<ul style="list-style-type: none"> <li>— Probably affecting the hypothalamopituitary ovarian axis</li> </ul>
<p><b>Iatrogenic</b></p> <ul style="list-style-type: none"> <li>• Contraceptive pills (post pill amenorrhea)</li> <li>• Psychotropic phenothiazine derivative drugs</li> <li>• Antihypertensive drugs like reserpine or dopamine antagonists</li> </ul>	<ul style="list-style-type: none"> <li>— Suppression of GnRH release</li> <li>— Dopamine receptor blocking agents raise the prolactin level</li> <li>— Dopamine depleting agents raise the prolactin level</li> </ul>

**TABLE 28.4 COMMON CAUSES OF SECONDARY AMENORRHEA**

Hypothalamus	Pituitary	Ovary	Uterine	Systemic
<ul style="list-style-type: none"> <li>• <b>Stress</b></li> <li>• Post pill</li> <li>• Sudden change in weight—either too much loss or too much gain</li> <li>• Psychotropic and anti-hypertensive drugs</li> </ul>	<ul style="list-style-type: none"> <li>• Adenoma</li> <li>• Sheehan's</li> </ul>	<ul style="list-style-type: none"> <li>• <b>PCOS</b></li> <li>• <b>Premature ovarian failure</b></li> </ul>	<ul style="list-style-type: none"> <li>• Synechiae</li> </ul>	<ul style="list-style-type: none"> <li>• Malnutrition</li> <li>• <b>Hypothyroid state</b></li> <li>• Diabetes</li> </ul>

may not be informative. The diagnosis is often accidentally made following diagnostic curettage or at laparotomy or laparoscopy.

### UTERINE SYNECHIAE (SYN: ASHERMAN'S SYNDROME)

There is formation of adhesions following post-abortual and puerperal curettage and also following diagnostic curettage in dysfunctional uterine bleeding. Rarely, it follows tubercular endometritis. Menstrual abnormalities include hypomenorrhea, oligomenorrhea or amenorrhea. Progesterone challenge test is negative. Hysterosalpingography shows honeycomb appearance (Fig. 37.72). Hysteroscopy reveals the extent of adhesions directly.

### Ovarian Factors

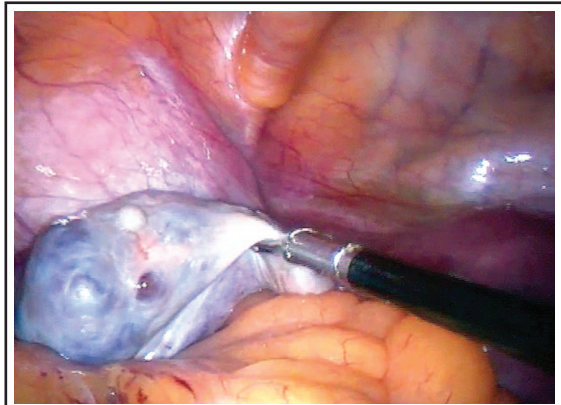
#### ◆ POLYCYSTIC OVARIAN SYNDROME (PCOS)

Polycystic ovarian syndrome (PCOS) was originally described in 1935 by Stein and Leventhal as a syndrome manifested by amenorrhea, hirsutism and obesity associated with enlarged polycystic ovaries.

This heterogenous disorder is characterized by excessive androgen production by the ovaries mainly. **PCOS is a multifactorial and polygenic condition.** *Diagnosis is based upon the presence of any two of the following three criteria* (ASRM/ESHRE, 2003).

- ◆ Oligo and/or anovulation.
  - ◆ Hyperandrogenism (clinical and/or biochemical).
  - ◆ Polycystic ovaries.
- Other etiologies (CAH, thyroid dysfunction, hyperprolactinemia, Cushing syndrome) are to be excluded. The incidence varies between 0.5–4 percent, more common amongst infertile women. It is prevalent in young reproductive age group (20–30%). Polycystic ovary may be seen in about 20% of normal women.

**Pathology:** Typically, the ovaries are enlarged. Ovarian volume is increased  $\geq 10 \text{ cm}^3$ . Stroma is increased. The capsule is thickened and pearly white in color. Presence of multiple ( $\geq 12$ ) follicular cysts measuring about 2–9 mm in diameter are crowded around the cortex (Fig. 28.4).



**Fig 28.4:** Laparoscopic view of polycystic changes (PCOS) of the ovary. Multiple small peripheral cysts are seen on the ovarian surface

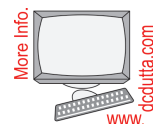**Histologically**, there is thickening of tunica albuginea. The cysts are follicles at varying stages of maturation and atresia. There is theca cell hypertrophy (stromal hyperthecosis). Patient may present with features of diabetes mellitus (insulin resistance).

**Clinical features:** The patient complains of increasing obesity (abdominal – 50%), menstrual abnormalities (70%) in the form of oligomenorrhea, amenorrhea or DUB and infertility. Presence of hirsutism and acne (Fig. 28.5) are the important features (70%). Virilism is rare.

**Acanthosis nigricans** is characterized by specific skin changes due to insulin resistance. The skin is thickened and pigmented (grey brown). Commonly affected sites are nape of the neck, inner thighs, groin and axilla (see Fig. 28.6).

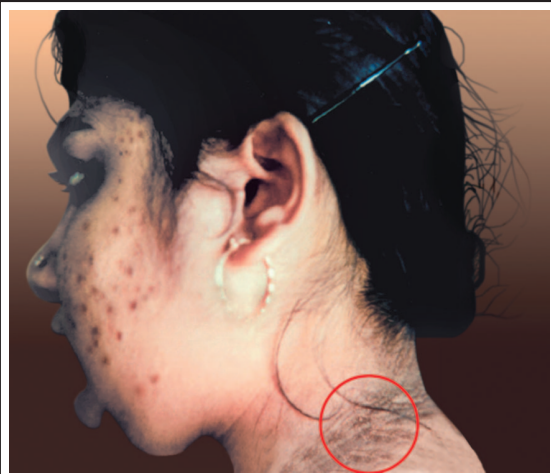**HAIR-AN syndrome** in patients with PCOS is characterized by hyperandrogenism, insulin resistance and acanthosis nigricans.

Internal examination reveals bilateral enlarged cystic ovaries which may not be revealed due to obesity.



### Investigations

- ◆ Sonography — Transvaginal sonography is specially useful in obese patient. Ovaries are enlarged in volume ( $\geq 10 \text{ cm}^3$ ). Increased number ( $> 12$ ) of peripherally arranged cysts (2–9 mm) are seen (Fig. 28.3).



**Fig. 28.5:** Hirsutism, acne, acanthosis nigricans in PCOS  
[Courtesy: Prof BN Chakravorty, IRM, Kolkata]

- ♦ Serum values:
  - LH level is elevated and/or the ratio LH: FSH is  $> 2:1$ .
  - Raised level of estradiol and estrone — The estrone level is markedly elevated.
  - SHBG level is reduced.
  - Hyperandrogenism—mainly from the ovary but less from the adrenals. Andro-stenedione is raised.
  - Raised serum testosterone ( $> 150$  ng/dL) and DHEA-S may be marginally elevated.
  - **Insulin Resistance (IR):** Raised fasting insulin levels  $> 25$   $\mu$ IU/mL and fasting glucose/insulin ratio  $< 4.5$  suggests IR (50%). Levels of serum insulin response  $> 300$   $\mu$ IU/mL at 2 hours postglucose (75 gm) load, suggests severe IR.
- ♦ Laparoscopy — Bilateral polycystic ovaries are characteristic of PCOS (Fig. 28.4).

### Pathophysiology

Exact pathophysiology of PCOS is not clearly understood. It may be discussed under the following heads (scheme-6):

- (a) Hypothalamic — pituitary compartment abnormality.
- (b) Androgen excess (p. 571).

- (c) Anovulation.
- (d) Obesity and insulin resistance.
- (e) Long-term consequences.

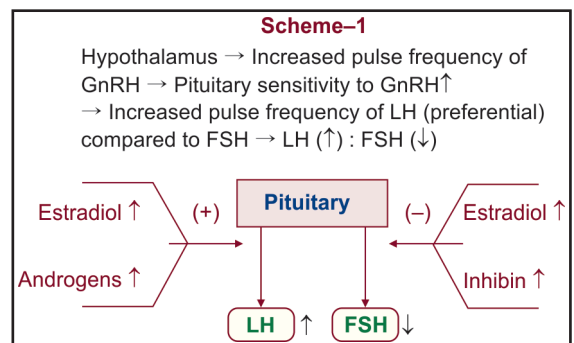
### HYPOTHALAMIC-PITUITARY COMPARTMENT IN PCOS

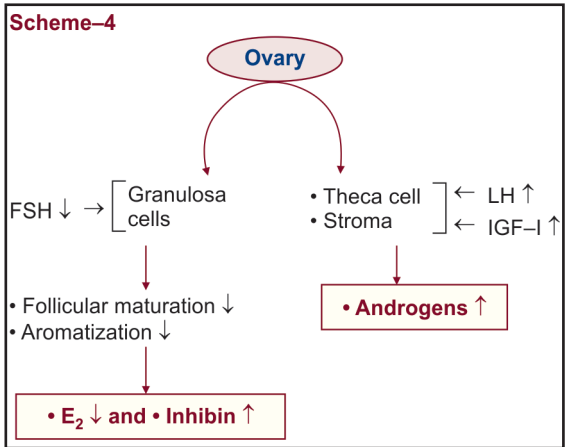
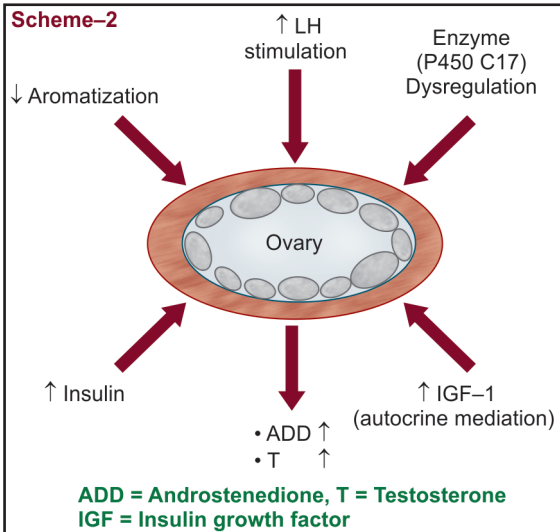
- ♦ Increased pulse frequency of GnRH leads to increased pulse frequency of LH. **Leptin** (a peptide, secreted by fat cells and by the ovarian follicle), insulin resistance and hyperandrogenemia are responsible for this.
- ♦ GnRH is preferential to LH rather than FSH.
- ♦ Increased pulse frequency and amplitude of LH results in tonically elevated level of LH.
- ♦ FSH level is not increased. This is mainly due to the negative feedback effect of chronically elevated estrogen and the follicular inhibin.
- ♦ Increased free estradiol due to reduced sex hormone binding globulin (SHBG) bears positive feedback relationship to LH.
- ♦ The LH: FSH ratio is increased.

### ANDROGEN EXCESS

Abnormal regulation of the androgen forming enzyme (P450 C 17) is thought to be the main cause for **excess production of androgens from the ovaries** and adrenals. The principal sources of androgens are (A) Ovary (B) Adrenal (C) Systemic metabolic alteration.

- A. **Ovary** produces excess androgens due to —
  - (i) stimulation of theca cells by high LH
  - (ii) P450 C17 enzyme hyperfunction
  - (iii) defective aromatization of androgens to estrogen
  - (iv) stimulation of theca cells by IGF-1 (insulin growth factor-1) (See scheme-2).

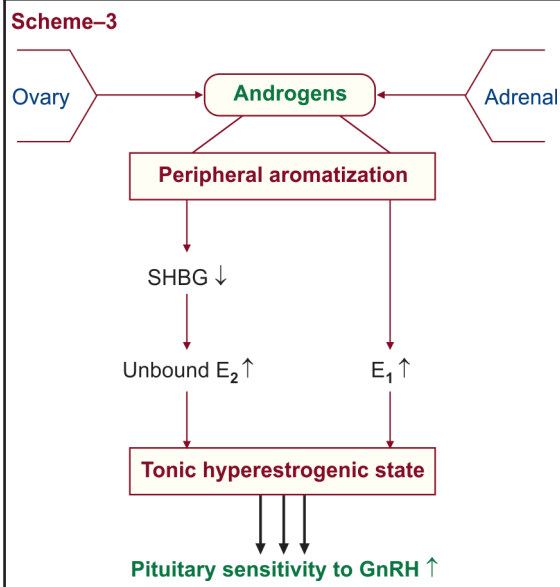




synthesis of SHBG, resulting in more free level of androgens.

**Features suggestive of insulin resistance are:** BMI > 25 kg/m<sup>2</sup>, Acanthosis nigricans and waist to hip ratio > 0.85.

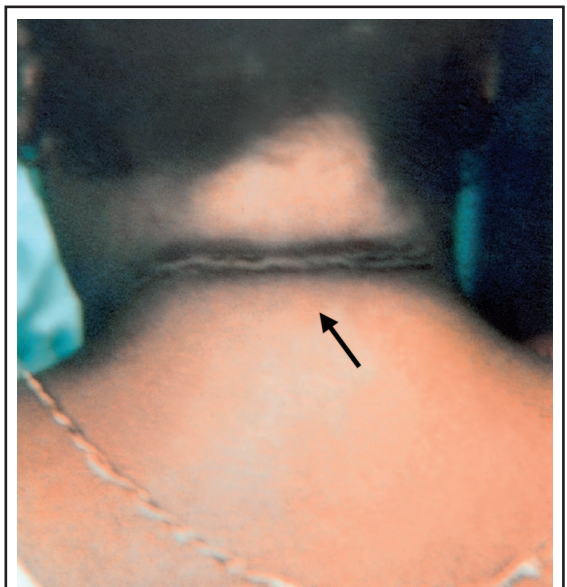- (ii) **Hyperprolactinemia:** In about 20% cases, there may be mild elevation of prolactin level due to increased pulsitivity of GnRH or due to dopamine deficiency or both. The prolactin further stimulates adrenal androgen production.



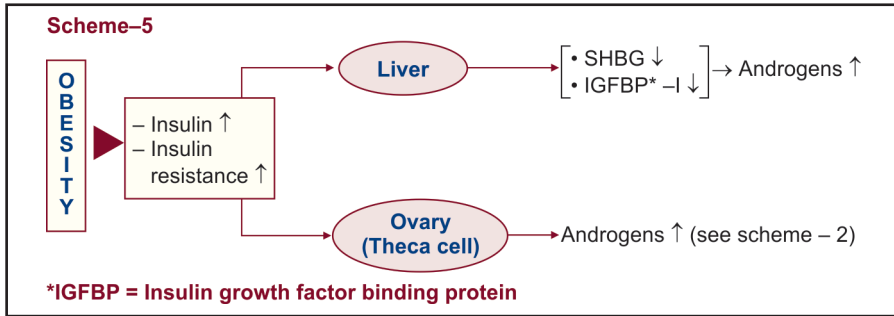
- B. **Adrenals** are stimulated to produce excess androgens by (i) stress (ii) P450 C17 enzyme hyperfunction (iii) associated high prolactin level (20%).

C. **Systemic metabolic alteration**

- (i) **Hyperinsulinemia causes:** (a) Stimulation of theca cells to produce more androgens. (b) Insulin results in more free IGF-1. By autocrine action, IGF-1 stimulates theca cells to produce more androgens. (c) Insulin inhibits hepatic



**Fig. 28.6:** Acanthosis nigricans in PCOS  
[Courtesy: Prof BN Chakravorty, IRM, Kolkata]



Whatever may be the etiology, the endocrinologic effects of PCOS produce a vicious cycle of events as shown in the scheme-6.

**Anovulation:** Because of low FSH level, follicular growth is arrested at different phases of maturation (2–10 mm diameter). The net effect is diminished estradiol and increased inhibin production. **Due to elevated LH**, there is hypertrophy of theca cells and more androgens are produced either from theca cells or stroma.

There is defective FSH induced aromatization of androgens to estrogens.

Follicular microenvironment is therefore more androgenic rather than estrogenic.

Unless there is estrogenic follicular microenvironment, follicular growth, maturation and ovulation cannot occur. There is huge number of atretic follicles that contribute to increased ovarian stroma (hyperthecosis). LH level is tonically elevated without any surge. LH surge is essential for ovulation to occur.

**O B E S I T Y AND I N S U L I N R E S I S T A N C E**

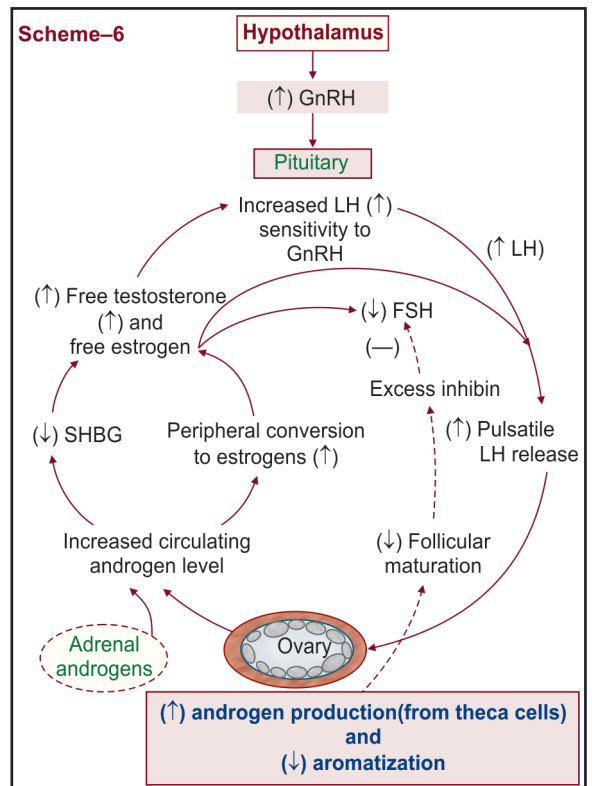
**Obesity** (central) is recognized as an important contributory factor. Apart from excess production of androgens, obesity is also associated with reduced SHBG. It also induces insulin resistance and hyperinsulinemia which in turn increases the gonadal androgen production. PCOS is thought to have a dominant mode of inheritance as about 50% of first degree relatives have PCOS.

Etiology of insulin resistance is unknown. Mutations of the insulin receptor gene in the peripheral target tissues and reduced tyrosine autophosphorylation of the insulin receptor, is currently thought to be an important cause. Increased central body fat leads to android obesity.

**Long-term consequences in a patient suffering from PCOS includes:** The **excess androgens** (mainly androstenedione) either from the ovaries or adrenals are peripherally aromatized to estrone (E<sub>1</sub>). There is concomitant **diminished SHBG**. **Cumulative excess unbound E<sub>2</sub> and estrone results in a tonic hyperestrogenic state**. There is endometrial hyperplasia.

**P O S S I B L E L A T E S E Q U E L A E O F P C O S**

- ♦ Obese women (BMI > 30) are at increased risk of developing **diabetes mellitus (15%)** due to insulin resistance.





- ◆ Risk of developing **endometrial carcinoma** due to persistently elevated level of estrogens. Estrogen effects are not opposed by progesterone because of chronic anovulatory state.
- ◆ Risk of **hypertension and cardiovascular disease** as dyslipidemia ( $\downarrow$ HDL,  $\uparrow$ triglycerides,  $\uparrow$ LDL) is the most common metabolic abnormality in women with PCOS.
- ◆ Obstructive **sleep apnea**.

**Treatment:** See p. 470.

### ◆ PREMATURE OVARIAN INSUFFICIENCY

Premature ovarian insufficiency (failure) is defined when ovarian failure occurs **before the age of forty**. It occurs in about 1% of the female population. During intrauterine life either there is failure of germ cell migration or there may be normal germ cell migration but an accelerated rate of germ cell depletion (apoptosis) due to various reasons (see below). This results in either no follicle or only few follicles left behind in the ovary by the time they reach puberty.

#### Causes of Premature Ovarian Failure

- **Genetic:** (i) Turner's syndrome (45X0), (45X/46XX), (ii) Gonadal dysgenesis 46XX, 46XY, (iii) Trisomy 18 and 13, (iv) X-chromosome deletion, translocation.
- **Autoimmune:** (i) Autoantibodies: antinuclear antibodies (ANA), Lupus anticoagulant, (ii) Polyglandular autoimmune syndrome (antibodies against thyroid, parathyroid, adrenal, islet cells of pancreas).
- **Infections:** Mumps, tuberculosis.
- **Iatrogenic:** Radiation therapy, Chemotherapy (cyclophosphamide), Surgery.
- **Metabolic:** Galactosemia, 17 $\alpha$  hydroxylase deficiency. In galactosemia, the enzyme galactose-1-phosphate uridyl transferase is absent. Follicles are destroyed to the toxic effects of galactose.
- **Environmental:** Smoking.
- **FSH receptor** absent or postreceptor defect (Savage's syndrome).

#### ➤ Idiopathic

#### Diagnosis/Investigations

- History of amenorrhea in less than 35 years of age.
- Serum gonadotropin level (FSH  $>$  40 mIU/mL) is high.

- Serum E<sub>2</sub> level is low ( $<$  20 pg/mL).
- Karyotype abnormality (see above).
- Organ specific humoral antibody (antithyroid commonest).
- Ovarian biopsy (afollicular, follicular and autoimmune variety) is not essential to the diagnosis. In autoimmune variety, there is perifollicular lymphocyte infiltration. In **resistant ovarian syndrome**, follicles are present. FSH receptor is either absent or defective.
- Patient presents with amenorrhea — primary (25%) or secondary (75%). Features of hypoestrogenic state like hot flushes, vaginal dryness, dyspareunia and psychological symptoms are there (see p. 57).
- The possibility of autoimmune disorders should be considered below the age of 35. For this, antithyroid antibodies, rheumatoid factor and antinuclear antibodies should be measured.
- In younger patients (age below 30) karyotype is to be done to rule out chromosomal abnormality.
- Management see p. 471.

### ◆ MASCULINIZING OVARIAN TUMOR (see p. 386)

There are features of gradual defeminization followed by appearance of masculinizing features such as hoarseness of voice, hirsutism and enlargement of clitoris. Abdominal and pelvic examinations reveal an adnexal tumor; the exact nature is confirmed by biopsy. Serum testosterone level is elevated to  $>$  2 ng per mL while DHEAS level is normal.

### HYPOTHALAMIC (FACTORS) AMENORRHEA

Hypothalamic dysfunction is one of the major causes of true secondary amenorrhea. There is often history suggestive of **stress, exercise, rapid gain or loss of weight**.

### WEIGHT RELATED AMENORRHEA

Female athletes, runners, ballet dancers are under constant stress and performing strenuous exercise. They have high level of corticotropin releasing hormone (CRH). The levels of ACTH cortisol and endogenous opioids are high. Leptin levels are low. CRH directly inhibits GnRH secretion via raised endogenous opioids. They are more likely to

develop amenorrhea due to **decrease in GnRH pulse frequency**. According to body weight hypothesis, body weight should be above critical level to achieve menarche and regular menstruation. To achieve menarche, body fat should reach 17 percent of the body weight. And for regularity of menstruation body fat should be maintained at least at 22 percent. Reduction of body fat by about one-third will result in menstrual abnormality. Menstruation becomes irregular when the BMI is  $< 19 \text{ kg/m}^2$ .

These subjects are hypoestrogenic and have got elevated prolactin and cortisol level. Leptin level is found low.

### ANOREXIA NERVOSA

It is a state of self-imposed starvation. This is a psychosexual problem where the patient suffers from the illusion of excessive body fat and distorted body image. Patient denies food and is markedly under weight. Amenorrhea is the rule. Constipation is common. Release of GnRH is affected. **FSH and LH levels are low, cortisol level is high**. This may be a life-threatening disorder.

**Obesity**—Obese women so often suffer from irregular menstrual bleeding. Excess number of fat cells in obese women, convert peripheral androgens to estrogen (aromatization). There is also low level of sex-hormone binding globulin, which helps free androgens to be converted to estrone. Obesity with polycystic ovarian disease can cause oligomenorrhea or amenorrhea (see p. 459).

### KALLMANN'S SYNDROME

Embryologically GnRH neurones develop in the ectodermal olfactory placode before they migrate finally to the hypothalamus. GnRH neurones are absent due to partial or complete agenesis of olfactory bulb (olfactogenital dysplasia). This disorder is characterized by hypogonadotropic hypogonadism, anosmia and color blindness. There may be associated cleft lip and palate. Patients present with primary amenorrhea. Mode of inheritance is due to a variety of genetic mutations in the KAL gene (X linked) or as an autosomal dominant or recessive fashion. Menstruation can be induced with combined estrogen

and progestin therapy. Induction of ovulation is successful with exogenous gonadotropins.

### PITUITARY FACTORS

**Adenoma:** In adenoma either micro or macro, there is usually associated inappropriate lactation (galactorrhea p. 576), secondary amenorrhea and infertility. There may be headache with disturbed vision.

Serum prolactin level is raised beyond 100 ng/mL. X-ray sella turcica may reveal space occupying lesion. CT or MRI scan is more informative.

### HYPERPROLACTINEMIA AND AMENORRHEA

Prolactin inhibits GnRH pulse secretion. Gonadotropin levels are suppressed. Hyperprolactinemia inhibits ovarian steroidogenesis. Hyperprolactinemia causes secondary amenorrhea in about 30% of women. **There is anovulation and hypogonadotropic hypogonadism.**

### PITUITARY ADENOMA (PROLACTINOMA)

Prolactin is a protein hormone having 199 amino acids with a molecular weight of 23,000 daltons. Prolactin has got various forms, called as “little” or (monomer), “big” (dimer) or “big big” (multimeric) prolactin (glycosylated form) respectively. Little prolactin (90%) has got more biological activity. Prolactin is synthesized and released primarily by the lactotrophs located in the anterior pituitary gland. **Extrapituitary sites of PRL production include** decidua, endometrium, lungs, etc. Prolactin secretion from the anterior pituitary is under the inhibitory control of dopamine. Dopamine is produced in the arcuate nucleus of the hypothalamus and is released in the portal hypophyseal vessels. Hyperprolactinemia is commonly due to pituitary adenomas (microadenoma or macroadenoma). There are other various causes of hyperprolactinemia (see Table 33.17). Normal plasma level of prolactin is 1–20 ng/mL.

### CAUSES OF HYPERPROLACTINEMIA

#### A. Physiological

- Stress and exercise (raised endogenous opioids)
- Pregnancy

- Stimulation of nipples
- Sleep
- Idiopathic

### B. Hypothalamus and pituitary

- Craniopharyngioma
- Tuberculosis
- Hypothyroidism
- Multiple endocrine disorder (Cushing's syndrome, Acromegaly)
- Pituitary adenomas (Prolactinomas)
- Resection of pituitary stalk

### C. Drugs

- |   |   |                                |
|---|---|--------------------------------|
| <ul style="list-style-type: none"> <li>• Phenothiazines</li> <li>• Metoclopramide</li> <li>• Methyldopa</li> <li>• Reserpine</li> <li>• Antidepressants</li> <li>• Estrogens</li> </ul> | } | (↓) Decreased hypothalamic PIF |
|---|---|--------------------------------|

### D. Others

- |   |   |                              |
|---|---|------------------------------|
| <ul style="list-style-type: none"> <li>• Renal failure</li> <li>• Cirrhosis of liver</li> </ul> | } | (↓) Decreased PRL clearance  |
| <ul style="list-style-type: none"> <li>• PCOS</li> <li>• Idiopathic</li> </ul>                  | } | (↑) Increased PRL production |

## DIAGNOSIS OF PITUITARY ADENOMAS

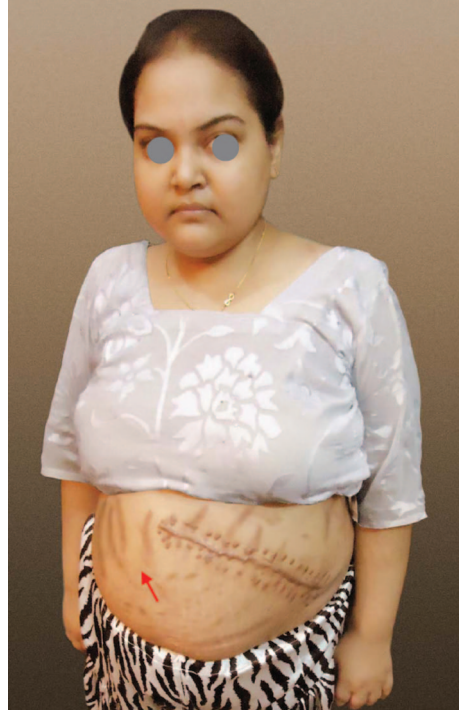Prolactin level is more than 100 ng/mL is often associated with prolactinoma. Most of the adenomas are microadenoma (diameter less than 1 cm). "Coned down" and lateral views of the sella turcica by radiography can detect gross abnormalities, calcification of tumor. Microadenomas rarely progress to macroadenomas. Computerized tomography (CT) is helpful for macroadenomas. Magnetic resonance imaging (MRI) with better resolution is superior to CT. MRI has no radiation risk (p. 118).

Visual field examination is essential to detect any compression effect on the optic nerves.

**Treatment:** See p. 471.

## SHEEHAN'S SYNDROME

There is history of severe postpartum hemorrhage, shock or severe infection. Depending upon the degree



**Fig. 28.7:** 19 year old girl, BMI 36, presented with frontal balding, amenorrhea, central obesity and purple abdominal striae (arrow). Investigations including CECT confirmed the diagnosis Cushing's Syndrome (non-ACTH dependent) due to adrenal adenoma (left). Abdominal scar of operation seen

of anterior pituitary necrosis, the features vary. **The common manifestations are** failing lactation, loss of pubic and axillary hair, lethargy, hypotension, secondary amenorrhea and atrophy of the breasts and genitalia. Gonadotropin level is low, so also  $T_3$ ,  $T_4$  and cortisol. The hormones affected in order of frequency are, growth hormone (GH), prolactin, gonadotropins (FSH and LH), TSH and ACTH. Hyponatremia may be present (30%). The syndrome may develop slowly over 8–10 years time.

**Management:** Replacement therapy with appropriate hormones including corticosteroid and thyroid are needed. Fertility can be achieved in these women with hMG and hCG. Clomiphene is ineffective.

## ADRENAL TUMOR OR HYPERPLASIA

There is secondary amenorrhea, infertility, acne and features of defeminization followed by virilization

(hoarseness of voice, hirsutism and enlargement of clitoris). In both the conditions there is excess production of androgens. Serum level of DHEA-S correlate well with daily urinary 17 KS excretion. **Rise of serum DHEA-S and urinary 17 ketosteroid levels are suppressed with dexamethasone 2 mg daily for 2 days in adrenal hyperplasia but not in tumor.** For confirmation of the diagnosis of tumor, IVP, MRI, CT scan or sonography is helpful.

Level of serum testosterone > 200 ng/dL is suggestive of an ovarian androgen secreting tumor. Whereas level of (DHEA-S) > 800 µg/dL is suggestive of an adrenal tumor. Urinary 17 ketosteroid excretion is high in a case with adrenal tumor. Ovarian neoplasm could be diagnosed with ultrasonographic examination (Endovaginal or abdominal).

**Late onset congenital adrenal hyperplasia** (CAH) is due to enzyme defect (21 hydroxylase, 11β hydrolase or 3β hydroxy steroid dehydrogenase) and leads to excess androgen production. But there is relative decrease in cortisol production. 21 hydroxylase deficiency is most common (90%). It is an autosomal recessive disorder.

Serum (morning sample) level of 17 hydroxyprogesterone 17 OHP > 800 ng/dL is diagnostic of 21 hydroxylase deficiency. Level of serum 17 OHP < 200 ng/dL virtually rules out the diagnosis of CAH. There is significant rise in 17 OHP level following ACTH stimulation test.

**Cushing's syndrome:** Cushing first described the syndrome in 1932. Androgens are formed as intermediate products in the synthesis of cortisol. The elevated cortisol level found in Cushing's syndrome encompasses two distinct pathologic entities.

- Cushing disease (ACTH dependent).
- Adrenal tumor (ACTH independent).

**In Cushing disease,** there is excess production of ACTH from the anterior pituitary or from ectopic sites. Basophil adenoma (microadenoma) is present in about 75 percent of cases. The increased ACTH causes hyperstimulation of adrenal cortex leading to its hyperplasia which in turn leads to excess production of cortisol and androgens.

**ACTH independent causes** (adrenal adenoma or cancer) may be iatrogenic (high dose corticosteroid therapy) or adrenal tumor.

**The cause of adrenal mischief** is cortisol secreting adenoma which produces excess cortisol. The androgen production is usually less but may be markedly elevated in presence of adrenal carcinoma.

**Symptoms include** weakness, oligomenorrhea, amenorrhea, acne and hirsutism. Virilism is rare. **Signs include** — moon facies, centripetal obesity and abdominal striae (Fig. 28.7).

The syndrome is often associated with hypertension, osteoporosis and insulin dependent diabetes.

**The screening test consists of** dexamethasone (1 mg) ingested at 11 pm and serum cortisol obtained at 8 am the following day. **Level less than 5 µg/100 mL essentially rules out the Cushing's syndrome.** Value of 24 hour urinary free cortisol > 250 µg is diagnostic of Cushing's syndrome. Serum ACTH is elevated in Cushing disease but not in adrenal tumor. CT or MRI can detect adrenal tumor.

## THYROID DYSFUNCTION

Both hypo- and hyperthyroid states may produce secondary amenorrhea and anovulation, the former is common. Serum TSH is raised, while T<sub>3</sub> and T<sub>4</sub> values are lowered in hypothyroid state. In subclinical hypothyroid state, while serum TSH is elevated but T<sub>4</sub> is normal. Serum prolactin may be raised even beyond 20 ng/mL in hypothyroid state. This is due to increased sensitivity of prolactin secreting cells of anterior pituitary to TRH.

## POSTPILL AMENORRHEA

It is observed in less than 1% of the women following the use of combined oral contraceptive pills. The association is more coincidental rather than causal. Fertility rate is normal following discontinuation of the drug. Spontaneous resumption of menstruation occurs in majority of cases after a varying period. Otherwise such amenorrhea should be investigated as in other cases of secondary amenorrhea.

## GENERAL DISEASE

Malnutrition, tuberculosis both pulmonary and pelvic, diabetes and chronic nephritis are all implicated. Their diagnostic criteria vary accordingly. Straight X-ray chest in pulmonary tuberculosis, blood sugar in diabetes, urine analysis and blood urea in chronic nephritis are helpful to substantiate the diagnosis.

**Scheme-B**

**Investigations of secondary amenorrhea**

- Exclude pregnancy
- Estimation — serum TSH, Prolactin
- X-ray/CT/MRI — Sella turcica

**Normal**

**TSH ↑, PRL ↑, Abnormal sella**

- Hypothyroidism
- Pituitary adenoma

**Progesterone challenge test**

Withdrawal bleeding present

- HPO axis intact

- Adequate endogenous E<sub>2</sub>
- Serum E<sub>2</sub> (> 30 pg/mL)

- FSH/LH estimation
- LH > 10 mIU/mL
  - or
  - LH : FSH > 3

Pelvic USG

PCOS

Withdrawal bleeding absent

- Loss of progesterone receptor
- Diseased endometrium

**Estrogen-progesterone challenge test**

No bleeding

- Nonfunctioning endometrium
- Uterine synechiae

HSG or hysteroscopy

To confirm/rule out Synechiae

Bleeding occurs

- Endometrium — responsive
- E<sub>2</sub> production — low (< 30 pg/mL)

**Estimation of FSH/LH**

High

FSH > 40 mIU/mL

- Ovarian failure
- Resistant ovarian syndrome

Age < 30 years

Karyotype

Low/normal

LH < 5 mIU/mL

Hypothalamic or pituitary lesion/dysfunction

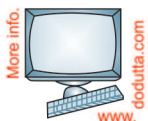**GnRH dynamic test**

Positive

Hypothalamic

Negative

Pituitary



## INVESTIGATIONS

### Investigation aims at

- ◆ To diagnose or confirm the offending factor.
- ◆ To guide the management protocol either to restore menstruation and or fertility.

In secondary amenorrhea, there is altered coordinated function of the hypothalamopituitary ovarian axis by some pathology. As such, it is not easy in most cases to pinpoint the diagnosis only by clinical examination. However, meticulous history taking and clinical examinations are mandatory. Laboratory investigations either to diagnose or to confirm the clinical diagnosis are mostly needed. These are specially helpful for formulation of management protocols either to restore menstruation or fertility.

It should be emphasized that **pregnancy must be excluded** prior hand irrespective of the status of the women — married, unmarried, widow, divorced or separated.

With the etiological factors in mind, one should proceed for investigations.

### Detailed History

Enquiry should be made about:

- (i) Mode of onset — whether sudden or gradual preceded by hypomenorrhea or oligomenorrhea.
- (ii) Sudden change in environment, emotional stress, psychogenic shock, or eating disorder (anorexia nervosa).
- (iii) Sudden change in weight—loss or gain.
- (iv) Intake of psychotropic or antihypertensive drugs like reserpine or methyl dopa. Intake of oral ‘pills’ or its recent withdrawal. History of radiotherapy and chemotherapy or surgery.
- (v) Appearance of abnormal manifestations either coinciding or preceding the amenorrhea, such as:
  - (a) Acne, hirsutism (excessive growth of hair in normal and abnormal sites in female) or change in voice.
  - (b) Inappropriate lactation (galactorrhea) — abnormal secretion of milk unrelated to pregnancy and lactation.
  - (c) Headache or visual disturbances.
  - (d) Hot flushes and vaginal dryness.

- (vi) Obstetric history — overzealous curettage leading to synechiae.
  - (a) Cesarean section may be extended to hysterectomy of which the patient may be unaware.
  - (b) Severe postpartum hemorrhage, or shock or infection.
  - (c) Postpartum or postabortal uterine curettage.
  - (d) Prolonged lactation — The patient may be amenorrheic since childbirth or she may have one or two periods, followed by amenorrhea. Even though the patient states that she is not breastfeeding her baby, a patient enquiry may reveal that she is putting the baby to the breast at night. This is sufficient to make the patient remain amenorrheic.
- (vii) Medical history of tuberculosis (pulmonary or extrapulmonary), diabetes, chronic nephritis or overt hypothyroid state should be enquired.
- (viii) Family history — Premature menopause often runs in the family (mother or sisters).

### General examination

The following features are to be noted:

- i. Nutritional status.
- ii. Extreme emaciation or marked obesity.
- iii. Presence of acne or hirsutism.
- iv. Discharge of milk from the breasts.

### Abdominal examination

- i. Presence of striae associated with obesity may be related to Cushing disease.
- ii. A mass in the lower abdomen.

### Pelvic examination

- i. Enlargement of clitoris.
- ii. Adnexal mass suggestive of tubercular tubo-ovarian mass or ovarian tumor.

With the above methods, either a probable diagnosis is made or no abnormality is detected to account for amenorrhea. **The latter group is much more common and these are investigated as outlined below.**

Even though there is no inappropriate galactorrhea, serum prolactin, TSH estimations and X-ray sella turcica are mandatory. **If these are normal, the following protocols are followed:**

**Step – I**

Progesterone challenge test is employed. **If withdrawal bleeding occurs, it proves—** (i) The intact hypothalamic-pituitary ovarian axis and (ii) There is adequate endogenous estrogens (serum  $E_2$  level more than 40 pg/mL) to promote progesterone receptors in the endometrium, (iii) Anatomically patent outflow tract and (iv) Endometrium is responsive.

Estimation of serum testosterone, prolactin TSH, oral GTT and fasting lipid profile should be done in a case of PCOS.

**If withdrawal bleeding fails to occur, it signifies—**

(i) lack of progesterone receptors in the endometrium or (ii) diseased endometrium. To differentiate between the two, one is to proceed to step II.

**Step – II**

Estrogen–progesterone challenge test — Ethinyl estradiol 0.02 mg or conjugated equine estrogen 1.25 mg is to be taken daily for 25 days. Medroxyprogesterone acetate 10 mg daily is added from day 15–25. Alternately, one course of oral contraceptive pill is given and to observe whether withdrawal bleeding occurs or not.

**If there is no bleeding,** it signifies local endometrial lesion such as uterine synechiae. This is to be confirmed by **HSG or hysteroscopy**.

**If withdrawal bleeding occurs,** it indicates the presence of responsive endometrium but the endogenous estrogen production is inadequate. As such, to determine whether the underlying defect lies in the ovary or in the pituitary, one is to proceed to step III.

**Step – III**

Estimation of serum gonadotropins is to be done. If the level of serum FSH is more than 40 mIU/mL, the case is one of premature ovarian failure or resistant ovarian syndrome. Ovarian biopsy is not recommended to confirm the diagnosis or to differentiate the two entities.

If, however, the level of FSH is either normal or low, it signifies pituitary dysfunction. Whether the disturbed pituitary function is primary or secondary to hypothalamus, one should proceed to step IV.

**Step – IV**

**GnRH dynamic test—** If with GnRH administration, there is rise of pituitary gonadotropins, it is probably a case of hypothalamic dysfunction. In cases of primary pituitary disorder, there will be no rise of gonadotropins. The result is however inconclusive.

If possible, pituitary tumor have to be excluded by X-ray sella turcica, CT or MRI, scan even though the prolactin level is normal.

**MANAGEMENT****I. NO ABNORMALITY DETECTED**

- ♦ The patient is not anxious about amenorrhea and or fertility. No treatment is required. Only assurance is given and too often, menstruation resumes within a year or so.
- ♦ The patient is anxious for amenorrhea but not for fertility.
  - (i) With normal endogenous estrogen: Oral combined steroidal contraceptives are prescribed and to be continued for at least three cycles.
  - (ii) With low endogenous estrogen: Ethinyl estradiol 0.02 mg or conjugated equine estrogen 1.25 mg daily is to be taken for 25 days. Medroxyprogesterone acetate 10 mg daily is added from day 16–25.
- ♦ The patient is anxious for fertility.

Husband's semen analysis in primary infertility and the tubal factor of the women are to be evaluated prior to induction of ovulation either using clomiphene or gonadotropins (details in ch. 15).

**II. CASES WITH DETECTABLE CAUSE**

- (i) **Anxiety and stress** — may be corrected by assurance and psychotherapy.
- (ii) **Systemic illness and malnutrition:** To improve the health status and appropriate therapy for systemic illness.
- (iii) **Exercise induced** amenorrhea is cured with limitation of activity and appropriate diet.

**III. POLYCYSTIC OVARIAN SYNDROME (PCOS)**

**Management of PCOS needs** individualization of the patient. It depends on her presenting symptoms, like

menstrual disorder, infertility, obesity, hirsutism or combined symptoms. Patient counseling is important. **Treatment is primarily targeted to correct the biochemical abnormalities** (Table 28.5).

TABLE 28.5

**BIOCHEMICAL ABNORMALITIES ASSOCIATED WITH PCOS**

– Hyperandrogenemia	– Hyperprolactinaemia
– Hyperinsulinaemia	– Insulin resistance
– Hyperlipidaemia	– Hypersecretion of LH
– High serum oestrogens (Oestradiol, oestrone)	– Low serum SHBG
– Androgenic follicular microenvironment	– Low FSH
	– Low serum progesterone

**Weight reduction** in obese patients is the first line of treatment. Body mass index (BMI) < 25 improves menstrual disorders, infertility, impaired glucose intolerance (insulin resistance), hyperandrogenemia (hirsutism, acne) and obesity. Weight reduction (2–5%) improves the metabolic syndrome and reproductive function (read below).

**Fertility not desired**
**Management of hyperandrogenemia (p. 575)**

- ◆ **Combined oral contraceptive pills** are effective. Progestin suppresses LH and estrogen improves SHBG, reducing free testosterone level. Newer progestins (desogestrel) are best suited (Table 29.8).
- ◆ **Hirsutism** is due to anovulation, high androgen and insulin levels, decreased hepatic SHBG production and also due to genetic sensitivity of hair follicles to androgens. Correction of metabolic syndrome (Table 28.6), improves it. **Antiandrogens** (cyproterone acetate, spironolactone, flutamide) may be used (p. 538, 575).

■ **Metabolic syndrome:** (Table 28.6) Hyperinsulinemia (insulin resistance) causes hyperandrogenemia (p. 461). Insulin resistance is associated with diabetes mellitus, central obesity, dyslipidemia and hypertension. **Metformin**, increases insulin sensitivity, decreases weight and BMI and reduces LDL cholesterol, blood pressure and the risk of developing diabetes.

TABLE 28.6

**METABOLIC SYNDROME (DIAGNOSTIC CRITERIA)**

- ◆ Triglyceride levels  $\geq$  150 mg/dL
- ◆ HDL-cholesterol < 50 mg/dL
- ◆ Blood pressure  $\geq$  130/80 mm Hg
- ◆ Fasting glucose  $\geq$  100 mg/dL
- ◆ Abdominal (waste circumference) obesity > 88 cm

**Presence of three abnormal findings out of the five**

■ **Hyperinsulinemia** contributes hyperandrogenemia in women with PCOS: Hyperinsulinemia increases the risk of dyslipidemia, cardiovascular disease and diabetes mellitus. Insulin resistance is the principal abnormality to cause metabolic syndrome (see Table 28.6).

**Metformin** (see p. 244) is used as an oral insulin sensitizing agent (see below).

**Endometrial hyperplasia** causes abnormal uterine bleeding. Chronic anovulation, hyperestrogenemia, obesity and hyperinsulinemia cause endometrial hyperplasia even endometrial cancer. Endometrial biopsy may have to be done.

Combined oral contraceptives is the treatment of choice to prevent endometrial hyperplasia and abnormal bleeding.

**Patient desires pregnancy**

**Chronic anovulation is the common cause of infertility.** Improvement of metabolic syndrome is essential.

■ **Ovulation induction** is usually achieved by clomiphene citrate following correction of other biochemical abnormalities (Table 28.5). In unresponsive cases, pure FSH or HMG along with hCG may be administered backed up with monitoring facilities (see ch. 16).

**Insulin sensitizers:** Women with PCOS and hyperinsulinemia with BMI > 25, ovulate satisfactorily when clomiphene is combined with metformin.

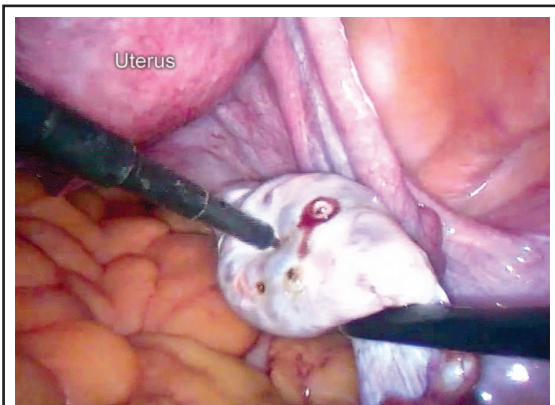
**Metformin** improves metabolic syndrome by reducing all the parameters: weight, BMI (hyperinsulinemia, hyperandrogenism), blood pressure and lipid abnormalities. 500 mg thrice daily is found to correct the biochemical abnormalities. Pioglitazone and rosiglitazone are also being used in cases, resistant to metformin.



■ **Surgery (Fig. 28.8):** Laparoscopic ovarian drilling (LOD) is done for cases found resistant to medical therapy (see p. 602). It has replaced the conventional wedge resection of the ovaries (see p. 601). Pregnancy rates following ovarian diathermy are higher. **Bariatric surgery** (p. 249) may be indicated in some PCOS women who are morbidly obese.

#### IV. HYPERPROLACTINEMIA, INAPPROPRIATE GALACTORRHEA

**Treatment — Medical:** Bromocriptine (lysergic acid derivative) a dopamine agonist is the drug first choice. Common side effects are: giddiness, nausea, vomiting, headache, constipation and orthostatic hypotension. **Cabergoline** is a selective dopamine agonist. It has less side effects, greater potency and longer duration of action. It is given 0.25 mg or 0.5 mg once or twice weekly. There is shrinkage of the tumor with therapy. Prolactin levels usually decrease within 2–3 weeks of treatment. Menses, ovulation and fertility return when prolactin level returns to normal. **Cabergoline can be continued safely in pregnancy when required as it is not teratogenic.** **Surgery** is considered when there is failure of medical therapy. **Transnasal — trans-sphenoidal adenectomy is done. Complications of surgery are:** meningitis, diabetes insipidus, leakage of CSF and recurrence. Radiation therapy is not commonly preferred (see also p. 549). Radiation therapy is used for large macroadenomas and for cases with large residual tumor after surgery.



**Fig. 28.8:** Laparoscopic ovarian drilling using diathermy

**Risk:** Panhypopituitarism may develop following radiation therapy.

#### V. PREMATURE OVARIAN FAILURE

- To prevent or to minimize postmenopausal health hazards, HRT should be judiciously employed (see p. 61).
- In proved cases of autoimmune disorders, corticosteroids may be of help.
- Fertility potentiality is far and remote. However, induction of ovulation may be hopefully tried in presence of follicle. This may be achieved by administration of sequential estrogen and progesterone or by use of GnRH agonist, followed by administration of gonadotropins for ovulation induction.
- Spontaneous recovery and pregnancy have been reported in an occasional case of premature ovarian failure.
- IVF with donor's oocyte with total replacement of hormones can increase the chance of pregnancy.
- In the presence of 'Y' chromosome, gonadectomy is to be done to avoid malignancy.

#### VI. ADRENAL DISORDERS

**Treatment of Cushing's Disease:** Pituitary tumor is treated by trans-sphenoidal resection or by external beam radiation. Excess cortisol due to adrenal tumor is cured by simple adrenalectomy. Many patients need medical therapy either before or after surgery to maintain normal cortisol level. Mitotane (adrenocorticolytic drug) may be used to produce medical adrenalectomy. Enzyme inhibitors like amnioglutethimide or metyrapone has been used to block excess cortisol production. Ketoconazole inhibits adrenal steroid biosynthesis. It is also used for long-term benefit.

**Adult onset adrenal hyperplasia —** Dexamethasone replacement therapy is given. A dose of 0.25–0.5 mg may be adequate. Periodic serum cortisol level is to be checked and is maintained at  $> 2 \mu\text{g/dL}$  and serum 17 OHP should be between 400 and 1200 ng/dL.

**VII. HYPOTHYROID STATE** should be treated by thyroxine.

**VIII. HYPERANDROGENIC STATE —** Suppression of hyperandrogenism can be achieved using oral

contraceptives, glucocorticoids or antiandrogen preparations (details in Tables 33.14 and 33.16).

**IX. UTERINE SYNECHIAE** — Adhesiolysis followed by insertion of IUD is effective. Addition of oral contraceptive pills for three months may help in regeneration of the endometrium. There may be recurrence in about 30 percent of cases.

**X. OVARIAN TUMOR** — Appropriate surgery is done (see p. 300, 378).

**XI. ANOREXIA NERVOSA** needs multidisciplinary approach. Behavioral therapy, psychiatric consultation are helpful. Hospitalization may be needed in severe cases.

## RESULTS

The following conclusions are made about the fate of the patients having amenorrhea.

**In primary amenorrhea, more investigations are often done to find out the cause with minimal effect.** In fact, in most of the cases where menstruation occurs are the young girls whose menarche is delayed in onset.

**In secondary amenorrhea, with comparative fewer investigations, the result is satisfactory.** But the percentage of cures falls steeply as the duration of amenorrhea lengthens. However, with or without treatment, spontaneous resumption of menstruation occurs in about 60 percent cases of secondary amenorrhea of more than one year's duration.

## KEY POINTS

- Amenorrhea is physiological before puberty, during pregnancy and lactation and following menopause.
- Most common cause of amenorrhea in a woman of reproductive age is pregnancy.
- Regular menstruation indicates cyclical ovarian function in response to intact HPO axis. On the other hand amenorrhea and oligomenorrhea indicates ovarian, endometrial and/or HPO axis dysfunction.
- The most common cause of secondary amenorrhea (pathological) is hypothalamic dysfunction.
- Commonest cause of cryptomenorrhea is imperforate hymen. The symptoms include periodic lower abdominal pain and occasional retention of urine. The treatment is cruciate incision of the hymen and drainage of blood (see p. 42).
- Common causes of primary amenorrhea are gonadol failure, abnormal chromosomal pattern, development defect of genital tract and disturbed function of the hypothalamopituitaryovarian axis.

As such detailed history, clinical examination and specific investigations most often clinch the diagnosis of primary amenorrhea (see Tables 28.1 and 28.2 and Scheme-A).

- Women with primary amenorrhea due to hypogonadotropic hypogonadism should have CT scan to rule out CNS lesion. Karyotyping is not needed.

The scope of therapeutic success in the management of primary amenorrhea is very limited.

XY gonads should be removed for its increased risk of malignancy. Substitution estrogen therapy should be prescribed for the development and maintenance of secondary sex characters.

- Amenorrheic patients may belong to any of the four groups : (i) hypergonadotropic hypogonadism (p. 452); (ii) hypogonadotropic hypogonadism (p. 451); (iii) hyperprolactinemia (p. 464) or (iv) normogonadotropic anovulation (p. 459).
- Hypothalamic hypogonadism is associated with reduced FSH and LH. There is no follicular growth and estradiol production (p. 451).
- Common causes of secondary amenorrhea are hypothalamic dysfunction, PCOS, stress, premature ovarian failure and hypothyroid state (see Table 28.3). PCOS is the most common endocrine disorder in women (20–25%).

Contd...

- Individuals with gonadal dysgenesis and X chromosomal abnormality are less than 150 cm in height.
- Majority of women with PCOS have android obesity (BMI > 25), elevated levels of biologically active LH. About 40 percent of women with PCOS have hyperinsulinemia and impaired glucose tolerance and androgen excess (p. 459).
- PCOS is a heterogeneous condition. Presence of two out of the three following criteria is essential to define PCOS (ESHRE/ASRM): (1) Oligo- and/or anovulation. (2) Hyperandrogenism (clinical or biochemical). (3) Polycystic ovaries.
- In polycystic ovarian syndrome (PCOS), there is excess androgen production by the ovaries. Typically, the ovaries are enlarged, capsule is thickened with multiple cysts along with hypertrophy of theca cells (stromal hyperthecosis) (p. 459).
- Management of PCOS needs patient individualization (see p. 469). Weight reduction is an important step. Correction of hyperandrogenemia (p. 470), hyperprolactinemia (p. 471), hyperinsulinemia and elevated LH levels (see p. 470) are the others. Metformin ameliorates the biochemical abnormalities. Ovulation induction has higher success when clomiphene is combined with metformin (insulin sensitizing agent). In refractory cases, laparoscopic ovarian drilling or laser vaporization of multiple cysts of the ovaries is better than wedge resection (p. 471).
- About 50 percent of women with PCOS have insulin resistance and impaired glucose tolerance. Metabolic syndrome (p. 470) is improved by metformin. Hyperandrogenism is managed by COCs or by other drugs (p. 470).
- Long-term risk of PCOS patients, if left untreated includes, diabetes mellitus, dyslipidemia, hypertension and endometrial carcinoma, obstructive sleep apnea (p. 462, 463).
- Common causes of uterine synechiae are tubercular endometritis, overzealous postabortal or puerperal curettage (p. 459).
- Level of serum FSH can differentiate hypogonadotropic hypogonadism from estrogen deficiency due to ovarian failure (p. 463).
- Serum FSH level > 40 mIU/mL, establishes the diagnosis of ovarian failure or hypergonadotropic hypogonadism (p. 463).
- Women with müllerian abnormalities have associated renal abnormalities in about one-third of cases.
- When uterine bleeding fails to occur after progestin therapy, level of endogenous estradiol is below 40 pg/mL (p. 467).
- When withdrawal bleeding occurs following progestin challenge test, it suggests: (i) intact hypothalamopituitary ovarian axis, (ii) serum E<sub>2</sub> level is more than 40 pg/mL, (iii) outflow tract is present and is patent anatomically and (iv) endometrium is responsive.
- The triad for diagnosis of premature ovarian failure include amenorrhea, raised gonadotropins and low serum estradiol. Karyotype should be done for younger (< 30 years) age group. Serum antibodies are positive in autoimmune variety. Ovarian biopsy is not essential to the diagnosis (p. 463).
- Serum level (morning sample) of 17-OHP when > 8 ng/mL establishes the diagnosis of late onset congenital adrenal hyperplasia.
- Abnormal secretion of GnRH results in amenorrhea is about 30 percent of women. Stress induced amenorrhea is due to increased level of opioids ( $\beta$  endorphin) in CNS, causing interference of GnRH release. Increased leptin level is associated with hypothalamic amenorrhea.
- Hypothalamic dysfunction (severe weight loss, stress, exercise) results in decreased GnRH secretion. There is decreased gonadotropin secretion and ovulation resulting in hypogonadotropic state.

Contd...

Contd...

- ▶ Weight loss when 15 percent below the ideal body weight can cause amenorrhea due to hypothalamic dysfunction.
- ▶ Exercise induced amenorrhea is also due to reduced GnRH pulse secretion, resulting in decreased LH pulses.
- ▶ Hyperprolactinemia is associated with anovulation, amenorrhea or galactorrhea. Causes of hyperprolactinemia are many (see p. 464). Most common cause of mildly raised prolactin level is stress. Majority of women with hyperprolactinemia, amenorrhea and galactorrhea will have prolactinoma. Most microadenomas (< 1 cm in diameter) do not enlarge with time. Bromocriptine shrinks 80–90 percent of macroadenomas. Most common side effects of bromocriptine therapy are nausea, vomiting and orthostatic hypotension. Cabergoline is more effective and is better tolerated.
- ▶ MRI is the best diagnostic modality for pituitary adenomas or empty sella syndrome.
- ▶ Hyperprolactinemia is present in 15 percent of all anovulatory women. Nearly 60 percent of all women with galactorrhea have hyperprolactinemia. Nearly 90 percent of women with galactorrhea and amenorrhea have hyperprolactinemia. About 5 percent of women with hyperprolactinemia have hypothyroidism (p. 445).

Bromocriptine treatment returns prolactin level to normal in 90 percent, induces ovulation in 80 percent and cures galactorrhea in 60 percent of cases (p. 471).

Combined oral contraceptives do not stimulate the growth of prolactin secreting microadenomas.

- ▶ Pregnancy induced by bromocriptine is not associated with an increased risk of congenital malformation or multiple pregnancy (p. 471).
- ▶ Surgical treatment of prolactinomas is done when there is failure of medical treatment but long-term recurrence rate is about 20 percent (p. 471).
- ▶ In masculinizing ovarian tumor, serum testosterone is elevated to > 2 ng/mL while DHEA–S is normal. Elevated DHEA–S reflects adrenal androgen excess (p. 544). Serum levels of DHEA–S correlate well with daily urinary 17 KS excretion.
- ▶ In Sheehan's syndrome, there is failing lactation, loss of pubic and axillary hair, secondary amenorrhea and atrophy of the breasts. Hormones affected in order of frequency are GH, FSH, LH, TSH and ACTH.

In Cushing disease, there is excess production of ACTH leading to excess secretion of cortisol and androgen production. The symptoms of Cushing syndrome include weakness, amenorrhea, acne and hirsutism; signs include moon facies, centripetal obesity and abdominal striae.

The diagnosis of a case of secondary amenorrhea is difficult to make out from the clinical examination (scheme – B). Pregnancy must be excluded prior hand. Even though, there is no galactorrhea, serum prolactin, TSH estimation and X-ray sella turcica are mandatory as the first step of investigation. When no abnormality is detected and the patient is not anxious about amenorrhea and or fertility, no treatment is required (p. 469).

In primary amenorrhea, more investigations are often done to find out the cause with minimal effect. In secondary amenorrhea, with comparative fewer investigations, the result is satisfactory (p. 472).

# Contraception

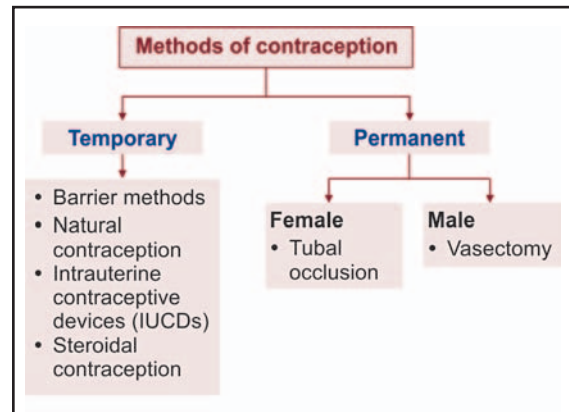
## INTRODUCTION

Rapid population growth (96% in developing countries) is a critical issue worldwide. Family planning matters save women's lives preventing unintended pregnancies. **Slower population growth conserves resources, improves health and living standards.**

**Benefits of fertility control** are interrelated. Benefits are: Improved quality of life, better health, less physical and emotional stress of life, better education, job and economic opportunities. Benefits are enjoyed by the couple, the children, other family members, the community and the country.

**Contraception and fertility control are not synonymous.** Fertility control includes both fertility inhibition (contraception) and fertility stimulation. While the fertility stimulation is related to the problem of the infertile couples, **the term contraception includes all measures, temporary or permanent, designed to prevent pregnancy due to the coital act.**

**Ideal contraceptive methods should fulfil the following criteria** — widely acceptable, inexpensive,



simple to use, safe, highly effective and requiring minimal motivation, maintenance and supervision. No one single universally acceptable method has yet been discovered.

## METHODS OF CONTRACEPTION

The various methods of contraception are schematically depicted above.

TABLE 29.1

METHODS OF CONTRACEPTION USED BY WOMEN OF REPRODUCTIVE AGE (15–49) IN DIFFERENT COUNTRIES

Country (year)	METHODS USED (PER CENT)							
	Sterilization		COC	IUD	Barrier	Implant/ Injectable	Others	Any method
	F	M						
India (2005–2006)	37	1	3	2	7	0.1	15	59
Bangladesh (1999–2000)	7	1	23	1	4	7	10	53
UK (2007–2008)	7	10	18	7	24	5	12	98
Sri Lanka (2006–2007)	16.9	0.7	7.9	6.3	5.5	15.3	15.2	68

## TEMPORARY

**Temporary methods are commonly used to postpone or to space births.** However, the methods are also frequently being used by the couples even though they have got strong desire for no more children (Table 29.2).

## BARRIER METHODS

These methods prevent sperm deposition in the vagina or prevent sperm penetration through the cervical canal. The objective is achieved by mechanical devices or by chemical means which produce sperm immobilization, or by combined means. The following are used (Box 1).

Box No : 1

### ♦ Mechanical

Male — Condom  
Female — Condom, diaphragm, cervical cap

### ♦ Chemical

(Vaginal contraceptives)  
Creams — Delfen (nonoxynol-9, 12.5 %)  
Jelly — Koromex, Volpar paste  
Foam tablets—Aerosol foams, Chlorimin T or Contab, Sponge (Today)

### ♦ Combination

Combined use of mechanical and chemical

**CONDOM (MALE):** Condoms are made of polyurethane or latex. Polyurethane condoms are thinner and suitable to those who are sensitive to latex rubber. It is the most widely practised method used by the male. In India, one particular brand (latex) is widely marketed as 'Nirodh'. The efficacy of condoms can be augmented by improving the quality of the products and by adding spermicidal agents during its use. **Protection against sexually transmitted disease is an additional advantage.** Occasionally, the partner may be allergic to latex.

**The method is suitable for couples** who want to space their families and who have contraindications to the use of oral contraceptive or IUD. These are also suitable to those who have infrequent sexual intercourse.

**Female condom (Femidom) (Fig. 29.1A):** It is a pouch made of polyurethane which lines the vagina and also the external genitalia. It is 17 cm in length with one flexible polyurethane ring at each end. Inner ring at the closed end is smaller compared to

TABLE 29.2

## FAILURE RATE OF CONTRACEPTIVE METHODS IN FIRST 12 MONTHS OF USE

Methods	Pregnancy rate per 100 women years (approx.)
No method	85
Natural (calendar, temperature, mucus)	25
Withdrawal	27
Lactational amenorrhea	2
Condom (male)	15
Condom (female)	21
Diaphragm	16
<b>IUCD :</b>	
CuT 380A	0.8
LNG 20	0.1
Combined oral pill	0.1
Progestin only pill	1
DMPA and NET injectables	0.3
Norplant	0.05
Implanon	0.01
Vasectomy	0.15
Tubectomy	0.15

*Failure rate is further less when methods are used correctly and consistently*

the outer ring. Inner ring is inserted at the apex of the vagina and the outer ring remains outside. It gives protection against sexually transmitted disease and pelvic inflammatory disease. It is expensive. Multiple uses can be made with washing, drying and with lubrication. Failure rate is about 5–21/HWY.

**Use of condom:** (1) As an elective contraceptive method (2) As an interim form of contraception during pill use, following vasectomy operation (see later) and if an IUD is thought lost until a new IUD can be fitted; (3) During the treatment of trichomonal vaginitis of the wife, the husband should use it during the course

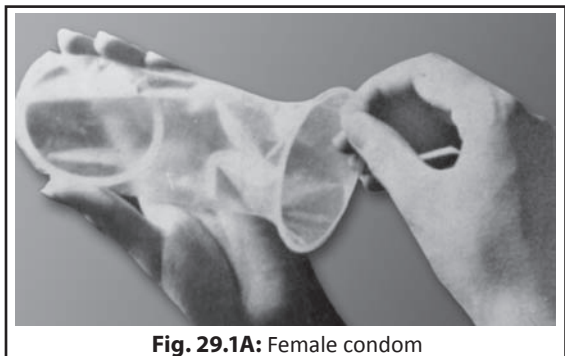



Fig. 29.1A: Female condom

TABLE 29.3 : CONDOM

TABLE 29.3 : CONDOM	
<b>Advantages</b>	
<ol style="list-style-type: none"> <li>Cheaper with no contraindications</li> <li>No side effects</li> <li>Easy to carry, simple to use and disposable</li> <li>Protection against sexually transmitted diseases, e.g. gonorrhea, chlamydia, HPV and HIV</li> <li>Protection against pelvic inflammatory diseases</li> <li>Reduces the incidence of tubal infertility and ectopic pregnancy</li> <li>Protection against cervical cell abnormalities</li> <li>Useful where the coital act is infrequent and irregular</li> </ol>	
	<b>Disadvantages</b>
	<ol style="list-style-type: none"> <li>May accidentally break or slip off during coitus</li> <li>Inadequate sexual pleasure</li> <li>Allergic reaction (Latex)</li> <li>To discard after one coital act</li> <li>Failure rate — 15 (HWY)</li> </ol>
<p><b>Precautions:</b> (i) To use a fresh condom for every act of coitus. (ii) To cover the penis with condom prior to genital contact. (iii) Create a reservoir at the tip. (iv) To withdraw while the penis is still erect. (v) To grasp the base of the condom during withdrawal.</p>	

of treatment irrespective of contraceptive practice; (4) Immunological infertility — male partner to use for 3 months. For other **non-contraceptive benefits** (see Table 29.3).

### Diaphragm (Table 29.4 and Fig. 29.1B)

It is an intravaginal device made of latex with flexible metal or spring ring at the margin. Its diameter varies from 5–10 cm. It requires a medical or paramedical personnel to measure the size of the device. The distance between the tip of the middle finger placed in the posterior fornix and the point over the finger

below the symphysis pubis gives the approximate diameter of the diaphragm. Diaphragm should completely cover the cervix. As it cannot effectively prevent ascent of the sperms alongside the margin of the device, additional chemical spermicidal agent should be placed on the superior surface of the device during insertion, so that it remains in contact with the cervix. **The device is introduced up to 3 hours before intercourse and is to be kept for at least 6 hours after the last coital act.** Ill fitting and accidental displacement during intercourse increase the failure rate.

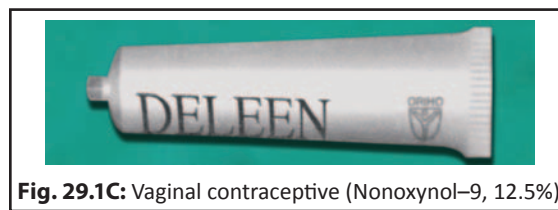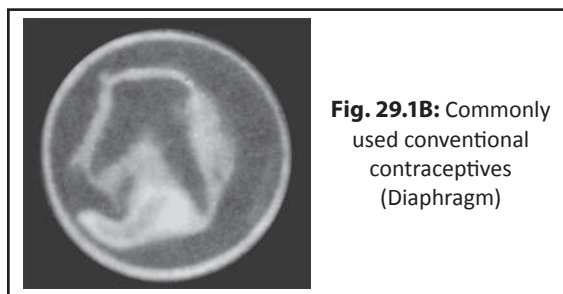


TABLE 29.4 : DIAPHRAGM

Advantages	Disadvantages
<ul style="list-style-type: none"> <li>Cheap</li> <li>Can be used repeatedly for a long time</li> <li>Reduces PID/STIs to some extent</li> <li>Protects against cervical precancer and cancer</li> </ul>	<ul style="list-style-type: none"> <li>Requires help of a doctor or paramedical person to measure the size required</li> <li>Risk of vaginal irritation, abrasion and urinary tract infection are there</li> <li>Not suitable for women with uterine prolapse</li> </ul>
	<div style="border: 1px solid black; padding: 5px; display: inline-block;">Failure rate—16 (HWY)</div>

**TABLE 29.5 FERTILITY AWARENESS METHODS (RHYTHM METHOD)**

Advantages	Disadvantages
<ul style="list-style-type: none"> <li>No cost</li> <li>Lack of side effects</li> </ul> <div style="border: 1px solid black; padding: 5px; width: fit-content; margin-top: 10px;"> <i>Failure rate—20-30 (HWY)</i> </div>	<ul style="list-style-type: none"> <li>Difficult to calculate the safe period reliably</li> <li>Needs several months training to use these methods</li> <li>Compulsory abstinence from sexual act during certain periods</li> <li>Not applicable during lactational amenorrhea or when the periods are irregular</li> </ul>

### Vaginal Contraceptives (Fig. 29.1C)

**Spermicides:** Spermicides are available as vaginal foams, gels, creams, tablets and suppositories. Usually, they contain **surfactants like nonoxynol-9, octoxynol or benzalkonium chloride**. These agents mostly cause sperm immobilization. **The cream or jelly** is introduced high in the vagina with the help of the applicator soon before coitus. **Foam tablets** (1–2) are to be introduced high in the vagina at least 5 minutes prior to intercourse. In isolation, it is not effective (18–29 HWY), but enhances the efficacy of condom or diaphragm when used along with it. There may be occasional local allergic manifestations either in the vagina or vulva.

**Vaginal contraceptive sponge (Today):** It is made of polyurethane impregnated with 1 g of nonoxynol-9 as a spermicide. Nonoxynol-9 acts as a surfactant which either immobilizes or kills sperm. **It releases spermicide during coitus, absorbs ejaculate and blocks the entrance to the cervical canal. The sponge should not be removed for 6 hours after intercourse. Its failure rate (HWY) is about — Parous women: 32-20, Nulliparous 16-9.** Currently it is observed that nonoxynol-9 is not effective in preventing cervical gonorrhea, chlamydia or HIV infection. Moreover, it produces lesions in the genital tract when used frequently. Those lesions are associated with increased risk of HIV transmission.

**Fertility Awareness Method (Table 29.5):** Fertility Awareness Method requires partner's cooperation. The woman should know the fertile time of her menstrual cycle.

**Rhythm Method:** This is the only method approved by the Roman Catholic Church. **The method is based on identification of the fertile period of a cycle and to abstain from sexual intercourse during that period.** This requires partner's cooperation. The methods to determine the approximate time of ovulation and the fertile period include — (a) recording of previous menstrual cycles (**calendar rhythm**) (b) noting the basal body temperature chart (**temperature rhythm**) and (c) noting excessive mucoid vaginal discharge (**mucus rhythm**). **The users of the calendar method** obtain the period of abstinence from calculations based on the previous twelve menstrual cycle records. **The first unsafe day is obtained** by subtracting 20 days from the length of the shortest cycle and **last unsafe day** by deducting 10 days from the longest cycle. **Users of temperature rhythm** require abstinence until the third day of the rise of temperature. **Users of mucus rhythm** require abstinence on all days of noticeable mucus and for 3 days thereafter.

**Coitus Interruptus (withdrawal) (Table 29.6):** It is the oldest and probably the most widely accepted contraceptive method used by man. **It necessitates withdrawal of penis shortly before ejaculation.**

**TABLE 29.6 COITUS INTERRUPTUS**

Advantages	Disadvantages
<ul style="list-style-type: none"> <li>No appliance is required</li> <li>No cost</li> </ul> <div style="border: 1px solid black; padding: 5px; width: fit-content; margin-top: 10px;"> <i>Failure rate — 20 (HWY)</i> </div>	<ul style="list-style-type: none"> <li>Requires sufficient self-control by the man</li> <li>The woman may develop anxiety neurosis, vaginismus or pelvic congestion</li> <li>Chance of pregnancy is more:               <ol style="list-style-type: none"> <li>Precoital secretion may contain sperm</li> <li>Accidental chance of sperm deposition into the vagina</li> </ol> </li> </ul>



It requires sufficient self-control by the man so that withdrawal of penis precedes ejaculation.

**Breastfeeding, Lactational amenorrhea (LAM):** Prolonged and sustained breastfeeding offers a natural protection of pregnancy. This is more effective in women who are **amenorrheic than those who are menstruating**. The risk of pregnancy to a woman who is fully breastfeeding and amenorrheic is **less than 2 percent in the first 6 months**. Otherwise, the **failure rate** is high (1–10%). Thus during breastfeeding, additional contraceptive support should be given by condom, IUCD or injectable steroids where available to provide complete contraception.

When the women is **full breastfeeding**, a contraceptive method should be used in the **3rd postpartum month and with partial or no breastfeeding, she should use it in the 3rd postpartum week**.

**Fertility awareness based methods are:** (1) **Natural contraception** (Rhythm method, Coitus interruptus and Lactational amenorrhea method) (2) **Barrier method** (Condoms, diaphragm and spermicides).

## INTRAUTERINE CONTRACEPTIVE DEVICES (IUCDs)

The intrauterine device have been used throughout the world. During the last couple of decades, however, there has been a significant improvement in its design

and content. The idea is to obtain maximum efficacy without increasing the adverse effects. **The device is classified as open**, when it has got no circumscribed aperture of more than 5 mm so that a loop of intestine or omentum cannot enter and become strangulated if, accidentally, the device perforates through the uterus into the peritoneal cavity. Lippes loop, Cu T, Cu 7, Multiload and Progestasert are examples of open devices. **If closed devices**, like Grafenberg ring and Birnberg bow, accidentally enter the abdominal cavity, they have the potential of causing strangulation of the gut; and hence are obsolete. **The device may be non-medicated** as Lippes loop or **medicated (bioactive)** by incorporating a metal copper, in devices like Cu T-200, Cu T-380A, Multiload-250, Multiload-375 (Fig. 29.2).

**Hormone containing IUD** either releasing progesterone (progestasert) or levonorgestrel (LNG-IUS) has also been introduced. Nowadays the following medicated intrauterine contraceptive devices are in use:

• Cu T 200	• Multiload 250	• Multiload 375
• Cu T 380A	• LNG – IUS	• GyneFix

### Description of the Devices (Fig. 29.2)

**Copper T 200**— The widely used medicated device is Copper T 200 B. It carries 215 sq mm surface area of fine copper wire wounded round the vertical

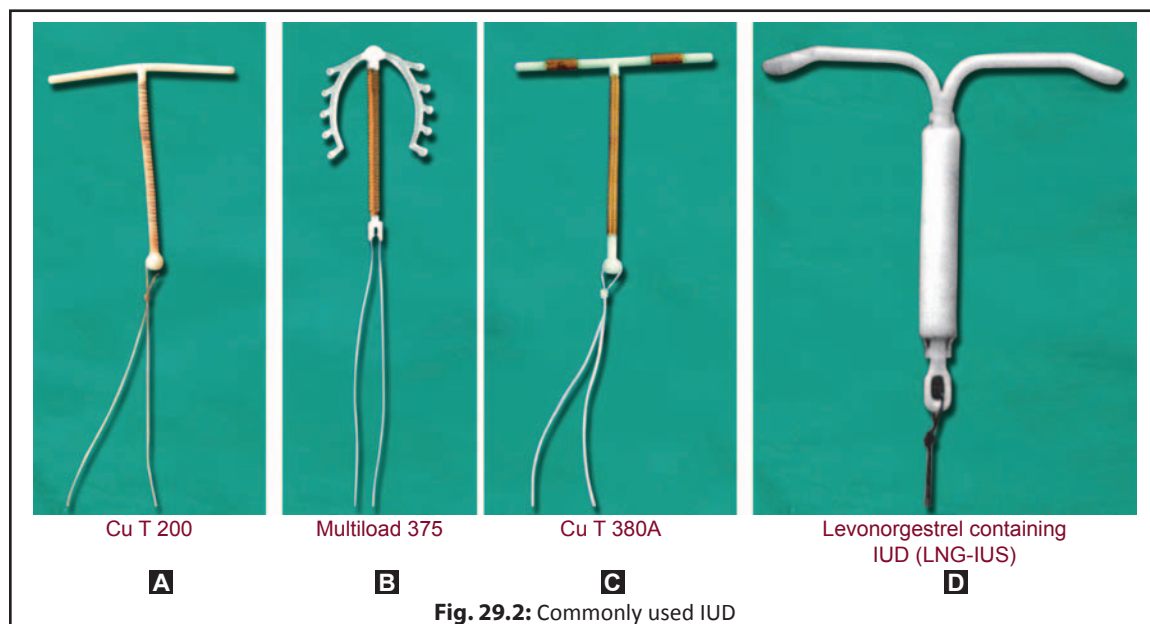


Fig. 29.2: Commonly used IUD

stem of the device. Stem of the T-shaped device is made of a polyethylene frame. It has a polyethylene monofilament tied at the end of the vertical stem. These two threads are used for detection and removal. In spite of the copper being radiopaque, additional barium sulfate is incorporated in the device. The device contains 124 mg of copper. The copper is lost at the rate of about 50 µg per 24 hours during a period of one year. It is supplied inside a sterilized sealed packet. **The device is to be removed after 4 years. Cu T 200 carries 200 sq mm surface area of wire containing 120 mg of copper and is removed after 3 years. Apart from the use of Cu T as a contraceptive, it is used following synaecolysis:**

**Cu T 380A** — Cu T 380A carries total 380 mm<sup>2</sup> surface area of copper wire wound around the stem (314 mm<sup>2</sup>) and each copper sleeve on the horizontal arms (33 mm<sup>2</sup>). The frame contains barium sulfate and is radiopaque. Replacement is every 10 years.

**Multiload Cu 250** — The device emits 60–100 µg of copper per day during a period of one year. **The device is to be replaced every 3 years.**

**Multiload-375** — The device is available in a sterilized sealed packet with an applicator. There is no introducer and no plunger. It has 375 mm<sup>2</sup> surface area of copper wire wound around its vertical stem. Replacement is every 5 years (Fig. 29.2).

**Levonorgestrel intrauterine system (LNG-IUS) (Fig. 29.2D)** — This is a T-shaped device, with polydimethylsiloxane membrane around the stem which acts as a steroid reservoir. Total amount of levonorgestrel is 52 mg and is released at the rate 20 µg/day. This device is to be replaced every 7 years. Its efficacy is comparable to sterilization. It has many non-contraceptive benefits also (p. 484).

**Progestasert** — It is a progesterone (38 mg) containing IUD. Progestasert is no longer manufactured.

**Lippes Loop** — It is a non-medicated open intrauterine device. It is no longer used in India.

**Mode of action:** Mechanism of antifertility effect of all the IUDs is not yet clear. They act predominantly in the uterine cavity and do not inhibit ovulation. Probable factors are:

- ◆ **Biochemical and histological changes in the endometrium** — There is a nonspecific inflammatory reaction along with biochemical changes in the endometrium which have got gametotoxic and spermicidal property. Lysosomal disintegration from

the macrophages attached to the device liberates prostaglandins, which are toxic to spermatozoa. Macrophages cause phagocytosis of spermatozoa.

- ◆ **There may be increased tubal motility** which prevent fertilization of the ovum.
- ◆ **Endometrial inflammatory response** decreases sperm transport and impedes the ability of sperm to fertilize the ovum.
- ◆ **Copper devices** — Ionized copper has got an additional local antifertility effect by **preventing blastocyst implantation through enzymatic interference**. Copper initiates the release of cytokines which are cytotoxic. Serum copper level is not increased. It seems that the progressive calcium deposition in the device prevents copper diffusion, if kept for longer period.
- ◆ **Levonorgestrel-IUS (Mirena)** — It induces strong and uniform suppression of endometrium. Cervical mucus becomes very scanty. Anovulation and insufficient luteal phase activity has also been mentioned. Serum progesterone level is not increased.

#### **Contraindications for Insertion of IUCD:**

- (1) Presence of pelvic infection current or within 3 months;
- (2) Undiagnosed genital tract bleeding;
- (3) Suspected pregnancy;
- (4) Distortion of the shape of the uterine cavity as in fibroid or congenital uterine-malformation;
- (5) Severe dysmenorrhea;
- (6) Past history of ectopic pregnancy;
- (7) Within 6 weeks following cesarean section;
- (8) STIs — Current or within 3 months;
- (9) Trophoblastic disease;
- (10) Significant immunosuppression. **Additionally for CuT** are: (11) Wilson disease and (12) Copper allergy. For LNG-IUS are: (13) Hepatic tumor or hepatocellular disease (active); (14) Current breast cancer and (15) Severe arterial disease.

#### **Time of Insertion**

- (a) **Interval** (When the insertion is made in the interconceptional period beyond 6 weeks following childbirth or abortion) — **It is preferable to insert 2–3 days after the period is over.** But it can be inserted any time during the cycle even during menstrual phase which has certain advantages (open cervical canal, distended uterine cavity, less cramp). However, during **lactational amenorrhea**, it can be inserted at any time.
- (b) **Postabortal** — Immediately following termination of pregnancy by suction evacuation or D and E, or following spontaneous abortion, the device may be inserted. The additional advantage of

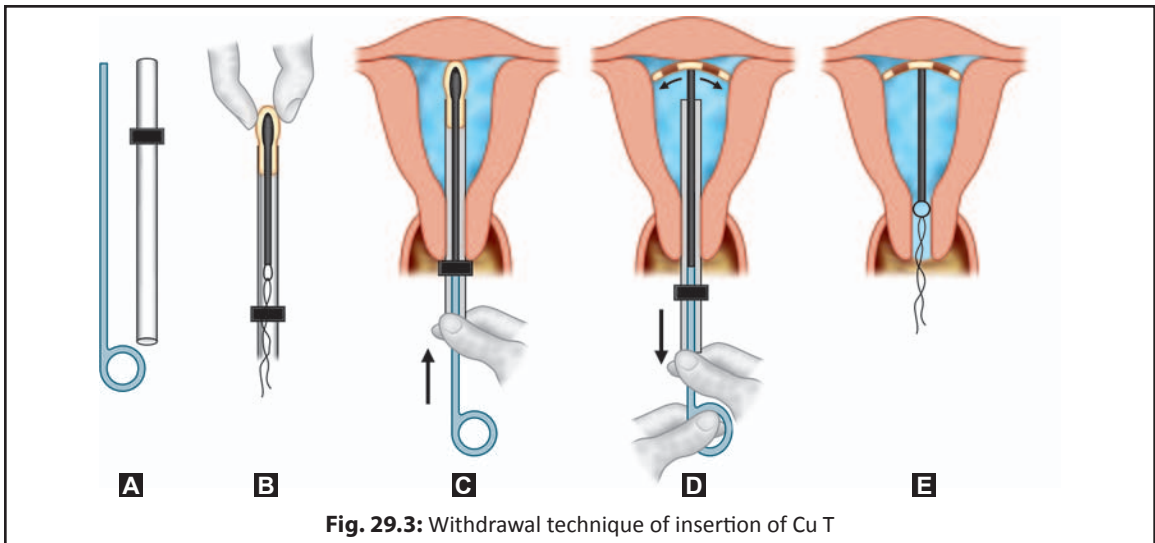


Fig. 29.3: Withdrawal technique of insertion of Cu T

preventing uterine synechia can help in motivation for insertion.

- (c) **Postpartum** — Insertion of the device can be done before the patients are discharged from the hospital. Because of high rate of expulsion, it is preferable to withhold insertion for 6 weeks when the uterus will be involuted to near normal size.
- (d) **Postplacental delivery** — Insertion immediately following delivery of the placenta could be done. But the expulsion rate is high.

### Methods of Insertion (Figs 29.3 and 29.4)

■ Cu T 200 ■ Cu T 380A

#### (A) Preliminaries

(1) History taking and examinations (general and pelvic) to exclude any contraindication of insertion. (2) Patient is informed about the various problems, the device is shown to her and consent is obtained. (3) **The insertion is done in the outpatient department**, taking aseptic precautions

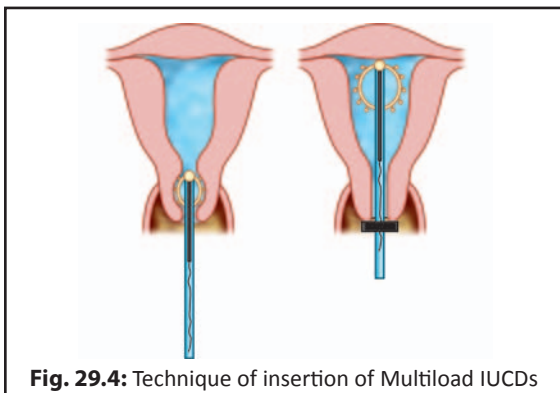


Fig. 29.4: Technique of insertion of Multiload IUCDs

without sedation or anesthesia. To reduce cramping pain Ibuprofen (NSAID) may be given (200–400 mg) 30 minutes before insertion. (4) **Placement of the device inside the inserter** — The device is taken out from the sealed packet. The thread, the vertical stem and then the horizontal stem folded to the vertical stem are introduced through the distal end of the inserter. The device is now ready for introduction. **“No touch” insertion method is preferred** (see below).

#### (B) Actual steps

(1) The patient empties her bladder and is placed in lithotomy position. Uterine size and position are ascertained by pelvic examination. (2) Posterior vaginal speculum is introduced and the vagina and cervix are cleansed by antiseptic lotion. (3) The anterior lip of the cervix is grasped by Allis forceps. A sound is passed through the cervical canal to note the position of the uterus and the length of the uterine cavity. The appropriate length of the inserter is adjusted depending on the length of the uterine cavity. (4) The inserter with the device placed inside is then introduced through the cervical canal right up to the fundus and after positioning it by the guard, the inserter is withdrawn keeping the plunger in position. **Thus, the device is not pushed out of the tube but held in place by the plunger while the inserter is withdrawn (withdrawal technique in Figure 29.3).** (5) The excess of the nylon thread beyond 2–3 cm from the external os is cut. Then the Allis forceps and the posterior vaginal speculum are taken off.

**“No-touch” insertion technique** includes: (i) Loading the IUD in the inserter without opening the sterile package. The loaded inserter is now taken out of the package without touching the distal end. (ii) Not

to touch the vaginal wall and the speculum while introducing the loaded IUD inserter through the cervical canal.

**Multiload Cu 250: Multiload 375**—The applicator with the device is just to be taken out of the sealed packet in a ‘no-touch’ method and **the same is pushed through the cervical canal up to the fundus of the uterus**. The applicator is then withdrawn (Fig. 29.4).

**LNG-IUS:** The arms of the device are released in the uterine cavity about 2 cm below the fundus. The details of insertion is to be followed as in the instruction package (Fig. 29.2D).

### Instructions to the Patient

The possible symptoms of pain and slight vaginal bleeding should be explained. The patient should be advised to feel the thread periodically by the finger. The patient is checked after 1 month and then annually.

### Complications

**Immediate:** ♦ **Cramp like pain** — It is transient but at times, severe and usually lasts for  $\frac{1}{2}$  to 1 hour. It is relieved by analgesic or antispasmodic drugs.

♦ **Syncopal attack**—Pain and syncopal attack are more often found in nulliparous or when the device is large enough to distend the uterine cavity.

♦ **Partial or complete perforation** — It is due to faulty technique of insertion but liable to be met with in lactational period when the uterus remains small and soft.

### Remote:

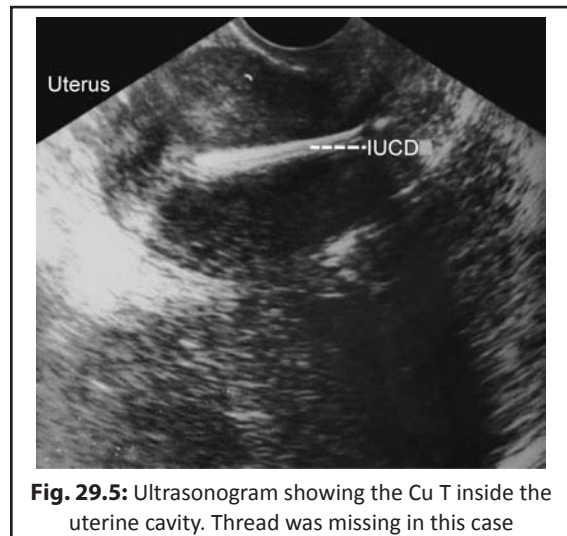
♦ **Pain** — The pain is more or less proportionate to the degree of myometrial distension. A proper size of the device may minimize the pain.

♦ **Abnormal menstrual bleeding**—The excessive bleeding involves increased menstrual blood loss, prolongation of duration of period and intermenstrual bleeding. The patient may become anemic and is of concern in one who is already anemic. Iron supplement is advocated. Tranexamic acid may be given for short-term relief. **Menstrual loss is much less with the use of third generation IUDs** (see p. 484).

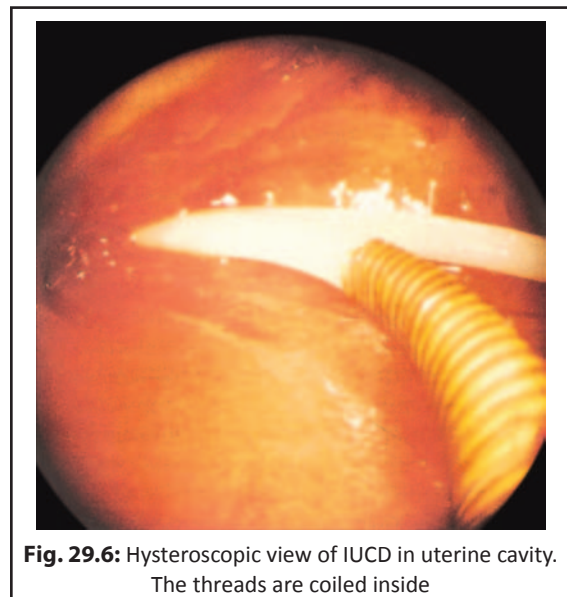
♦ **Pelvic infection (PID)**—The risk of developing PID is 2–10 times greater amongst IUD users. The risk is more in the first 3 weeks. Infection with chlamydia and rarely with actinomyces are seen. Newer IUDs reduce the risk (see p. 484).

**Pain, abnormal uterine bleeding and PID are the principal factors related to its discontinuation (10–15%).**

♦ **Spontaneous expulsion**—Usually occurs within a few months following insertion, more commonly during the period, at times unnoticed by the patient. Failure to palpate the thread which could be felt before, is an urgent ground to report to the physician. **The expulsion rate is about 5 percent.** The rate is, however, more following postabortal or puerperal insertions. The expulsion rate is markedly reduced in the successive years. Another device of appropriate size may be reintroduced and this is likely to be retained. **The newer IUDs have got less expulsion rate (see p. 484).**



**Fig. 29.5:** Ultrasonogram showing the Cu T inside the uterine cavity. Thread was missing in this case



**Fig. 29.6:** Hysteroscopic view of IUCD in uterine cavity. The threads are coiled inside

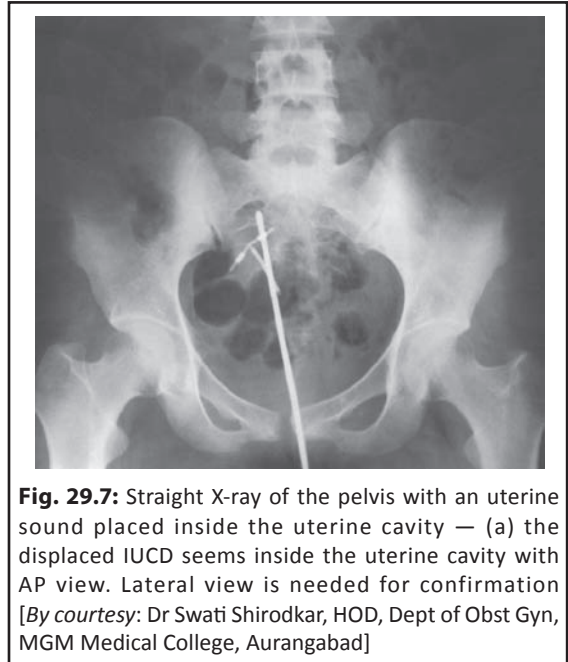
- ◆ **Perforation of the uterus**—The incidence of uterine perforation is about 1 in 1000 insertions. Most perforations occur at the time of insertion but the migration may also occur following initial partial perforation with subsequent myometrial contraction. **It is however less common when the device is introduced by the withdrawal technique.**

**Diagnosis:** Non-visibility of the thread through the external os and the appearance of pelvic symptoms after a long asymptomatic period are suspicious. **Negative findings on exploration** of the uterine cavity by a probe is suggestive. **Ultrasonography** can detect the IUD in abdominal cavity and is better than radiography. **Straight X-ray**, anteroposterior and lateral view, following introduction of a radiopaque probe (uterine sound) into the uterine cavity is conclusive. The device is found away from the opaque shadow placed in the uterine cavity, if it has perforated the uterine wall (Fig. 29.7).

**Management: Lippes loop**—As it is an open device made of inert material, it will cause no harm if left in the peritoneal cavity. Adhesions and intestinal injury are unlikely. But for psychological reason or otherwise, **it is better to remove it by laparoscopy or by laparotomy.**

**Copper device** — A copper bearing device induces an intense local inflammatory reaction with adhesions with the surrounding structures. Thus, as soon as the diagnosis is made, it is to be removed by laparoscopy or laparotomy.

- ◆ **Pregnancy** — The pregnancy rate with the device *in situ* is about 2 per 100 women years of use. Lowest pregnancy rates are observed with Cu T 380A (0.8–HWY) and LNG-IUS



**Fig. 29.7:** Straight X-ray of the pelvis with an uterine sound placed inside the uterine cavity — (a) the displaced IUCD seems inside the uterine cavity with AP view. Lateral view is needed for confirmation [By courtesy: Dr Swati Shirodkar, HOD, Dept of Obst Gyn, MGM Medical College, Aurangabad]

(0.2–HWY). Should pregnancy occur with a device *in situ*, there is risk of ectopic pregnancy (0.02percent). IUD can thus prevent an uterine but not an ectopic pregnancy. Third generation of IUDs like Cu T 380 A and LNG-IUS **give some amount of protection against an ectopic pregnancy.**

**Management: If the thread is visible** through the cervix it is best to remove the device. This will minimize such complications as abortion, preterm labor sepsis and low birth weight baby. **However, if the thread is not visible** it is better to leave it alone after counseling with the patient about the risks involved

**TABLE 29.7 IUD (CU DEVICES AND HORMONE RELEASING IUDS)**

Advantages	Disadvantages
1. Inexpensive : Cu T-distributed free of cost through Government channel	1. Require motivation
2. Simplicity in techniques of insertion and most cost effective of all methods	2. Limitation in its use
3. Prolonged contraceptive protection after insertion (5–10 years) and suitable for the rural population of developing countries	3. Adverse local reactions manifested by menstrual abnormalities, PID, pelvic pain and heavy periods. Beside effects are less with third generation of IUDs
4. Systemic side effects are nil. Suitable for hypertensives, breastfeeding women and epileptics	4. Risk of ectopic pregnancy.
5. Reversibility to fertility is prompt after removal	Failure rate — 0.1–2 (H W Y)

in continuing pregnancy. The device is expected to be expelled spontaneously with the delivery of the afterbirths. There is no conclusive evidence of increased risk of fetal anomalies with copper devices.

**Indications for removal:** (1) Persistent excessive regular or irregular uterine bleeding (2) Flaring up of salpingitis (3) Perforation of the uterus (4) IUD has come out of place (partial expulsion) (5) Pregnancy occurring with the device *in situ* (6) Woman desirous of a baby (7) Missing thread (8) One year after menopause (9) When effective lifespan of the device is over.

**IUD removal** is simple and can be done at any time. It is done by pulling the strings gently and slowly with a forceps.

**Missing Thread: The thread may not be visible through the cervical os due to** — (a) Thread coiled inside; (b) Thread torn through; (c) Device expelled outside unnoticed by the patient; (d) Device perforated the uterine wall and is lying in the peritoneal cavity; (e) Device pulled up by the growing uterus in pregnancy.

**Methods of identification:** Pregnancy is to be excluded first —

1. **Ultrasonography** can detect the IUD either within the uterine cavity or in the peritoneal cavity (if perforated). It is preferred to radiography (Fig. 29.5).
2. **Hysteroscopy** can be used for direct visualization of the uterine cavity and it could be removed simultaneously (Fig. 29.6).
3. **Sounding** the uterine cavity by a probe (Fig. 29.7).
4. If negative, **straight X-ray** after introducing radiopaque probe (uterine sound) into the uterine cavity. This will not only reveal the presence or absence of the device but also its existence outside the uterine cavity (Fig. 29.7).

### Removal

**A. Device inside the uterine cavity:** It can be removed by any of the following methods mentioned below:

- (i) Especially designed blunt hook (Fig. 37.41).
- (ii) Artery forceps (Fig. 37.28)
- (iii) Uterine curette (Fig. 37.13)
- (iv) Hysteroscopically under direct vision (Fig. 29.6).

**B. Outside the uterus but inside the abdominal cavity:** (i) Laparoscopy (ii) Laparotomy (rarely).

**Advantages of third generation of IUDs** (Cu T 380A, Multiload 375 and Levonorgestrel IUS) *over the others.*

(1) Higher efficacy with lowest pregnancy rate (less than one per 100 women years). (2) Longer duration of action (5–10 years). (3) Low expulsion rate and fewer indications for medical removal. (4) Risk of ectopic pregnancy is significantly reduced (Cu T 380A and LNG-IUS: 0.02 HWY). (5) Risk of PID is reduced, anemia is improved. (6) **Non-contraceptive benefits especially with LNG-IUD:** (i) **Significant reduction** in menstrual blood loss, Menorrhagia, Dysmenorrhea and Premenstrual Tension Syndrome (PMS). (ii) It can be used **in the treatment of** Endometrial hyperplasia, adenomyosis, endometriosis, uterine leiomyomas and endometrial cancer. (iii) It can be used **as an alternative to** hysterectomy for menorrhagia, DUB. (iv) It provides excellent benefits of **Hormone Replacement Therapy** (HRT) when used over the transition years of reproduction to perimenopause. (Fibroplant p. 502).

### Disadvantages of third Generation of IUDs

- Expensive.
- LNG-IUS is not available through government channel in India currently.
- Amenorrhea (5%) is a cause of its discontinuation.
- Malpositioning with long duration of use may cause pregnancy (failure) or expulsion.

## SUMMARY OF IUD

Intrauterine contraceptive device is a widely acceptable reversible method of contraception for spacing of births. Amongst many, either a copper impregnated device like Cu T, multiload or a hormone releasing device like LNG-IUS is commonly used. **Its mode of action** is not clear. Probably, it produces nonspecific biochemical and histological changes in the endometrium and ionized copper has got spermolytic and gametotoxic effects. LNG-IUS induces uniform suppression of endometrium and produces very scanty cervical mucus. **It should not be used in newly married women or when any pelvic pathology is present.** The device can be introduced in the interval period or following abortion or following childbirth. The introduction is an outdoor procedure and can be done even by a trained paramedical personnel without anesthesia. The technique employed is either “push-out” in Lippes loop or “withdrawal” in Cu T. **The immediate complications** include cramp-like pains or even syncopal attacks. **The delayed complications** include pelvic pain, menstrual irregularities, expulsion of the IUD or even

perforation of the uterus. Complications are much less with third generation of IUDs. **The indications of its removal are**, missing threads, persistent pelvic pain, menorrhagia, pregnancy, displacement of the device and flaring up of pelvic infection. While Cu T 200 should be removed after 3–4 years, multiload 375 is replaced after 5 years, Cu T 380A after 10 years and LNG-IUS after 5 years. **The failure rate is** about 0.5–2 per HWY. Copper device can also be used as postcoital contraception and following synecholysis.

## STEROIDAL CONTRACEPTIONS

Enovid (norethynodrel 10 mg and menestranol 0.15 mg) was used in the first contraceptive field trial in Puerto Rico in 1956 by Pincus and his colleagues. Intensive pharmacological research and clinical trials were conducted during the following years to minimize the adverse effects of estrogen without reducing the contraceptive efficacy, resulted in lowering the dose of estrogen to a minimum of 20 µg or even 15 µg in the tablet.

## COMBINED ORAL CONTRACEPTIVES (PILLS)

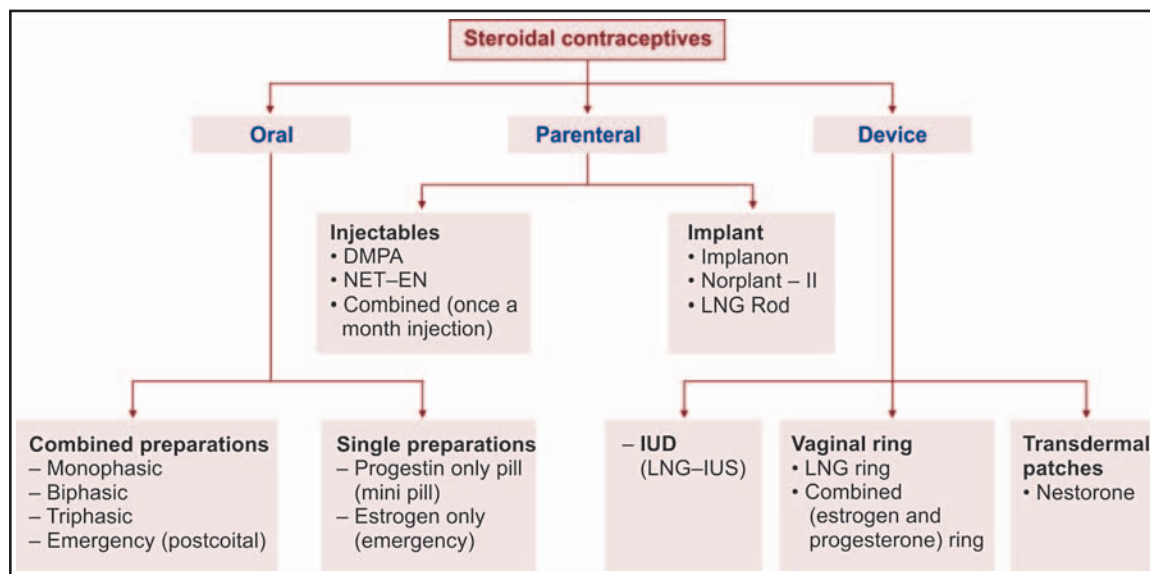
The combined oral steroidal contraceptives is the most effective reversible method of contraception. In the combination pill, **the commonly used progestins are either levonorgestrel or norethisterone or desogestrel and the estrogens are principally confined to either ethinyl-estradiol or menestranol** (3 methylether of ethinyl-estradiol). Currently ‘lipid friendly’, **third**

**generation progestins**, namely desogestrel, gestodene, norgestimate are available. Some of the preparations available in the market are mentioned in the Table 29.8. Only Mala-N is distributed through government channel free of cost.

**4th generation: Drospirenone** which is an analogue of spironolactone is used as progestin. It has antiandrogenic and antimineralocorticoid action. It causes retention of K<sup>+</sup>.

**Mode of action:** The probable mechanism of contraception are:

- ◆ **Inhibition of ovulation** — Both the hormones synergistically act on the hypothalamopituitary axis. The release of gonadotropin releasing hormones from the hypothalamus is prevented through a negative feedback mechanism. There is thus no peak release of FSH and LH from the anterior pituitary. So follicular growth is either not initiated or if initiated, recruitment does not occur.
- ◆ **Producing static endometrial hypoplasia**— There is stromal edema, decidual reaction and regression of the glands making endometrium nonreceptive to the embryo.
- ◆ **Alteration of the character of the cervical mucus** (thick, viscid and scanty) so as to prevent sperm penetration.
- ◆ **Probably interferes** with tubal motility and alters tubal transport. Thus, even though accidental breakthrough ovulation occurs, the other mechanisms prevent conception.



**TABLE 29.8 SOME OF THE ORAL CONTRACEPTIVES AND THEIR COMPOSITION**

Commercial names	Composition		No. of tablets
	Progestins (mg)	Estrogen ( $\mu\text{g}$ )	
1. Mala N (Govt of India)	Levonorgestrel 0.15	Ethinyl estradiol 30	21 + 7 iron tablets
2. Mala-D	Levonorgestrel 0.15	—do—	21 + 7 iron tablets
3. Loette (Wyeth)	Desogestrel 0.15	Ethinyl estradiol 20	21
4. Yasmin (Schering)	Drospirenone 3 mg (p. 531)	Ethinyl estradiol 30	21

Depending on the amount of ethinyl estradiol (E) and the types of progestin (P) used, pills are defined as: **1st generation** — with E 50  $\mu\text{g}$  or more; **2nd generation** — with E 20–35  $\mu\text{g}$  and P as levonorgestrel or norgestimate; **3rd generation** — with E 20–30  $\mu\text{g}$  and P as desogestrel or gestodene; **4th generation** — E as third generation, with P as drospirenone, dienogest or nomegestrol. Low dose pills have E less than 50  $\mu\text{g}$ .

**Estrogen** inhibits FSH rise and prevents follicular growth. It is also useful for better cycle control and to prevent breakthrough bleeding.

**Progestin:** Anovulatory effect is primarily by inhibiting LH surge. **It is also helpful to counteract the adverse effects of estrogen on the endometrium** (endometrial hyperplasia and heavy withdrawal bleeding). It is also responsible for changes in the cervical mucus (vide supra).

**Selection of the patient: History and general examination** should be thorough, taking special care to screen cases for contraindications (headache, migraine). Examination of the breasts for any nodules, weight and blood pressure are to be noted.

**Pelvic examination** to exclude cervical pathology, is mandatory. Pregnancy must be excluded. **Cervical cytology** to exclude abnormal cells, is to be done. Thus, any woman of reproductive age group without any systemic disease and contraindications listed, is a suitable candidate for combined pill therapy. Growth and development of the pubertal and sexually active girls are not affected by the use of “pill”.

**How to prescribe a pill: INSTRUCTION: New users** should normally start their pill packet **on day one of their cycle**. One tablet is to be taken daily preferably at bed time for consecutive 21 days. It is continued for 21 days and then have a 7 days break, with this routine there is contraceptive protection from the first pill. Next pack should be started on the eighth day, irrespective of bleeding (same day of the week, the pill finished). **Thus, a simple regime of “3 weeks on and 1 week off” is to be followed.** Packing of 28 tablets, there should be no break

between packs. Seven of the pills are dummies and contain either iron or vitamin preparations. However, a woman can start the pill up to day 5 of the bleeding. In that case she is advised to use a condom for the next 7 days. The pill should be started on the day after abortion. Following childbirth in non-lactating woman, it is started after 3 weeks and in lactating woman it is to be withheld for 6 months (see later in the chapter).

**FOLLOW-UP:** The patient should be examined after 3 months, then after 6 months and then yearly. **The patient above the age 35 should be checked more frequently.** At each visit, any adverse symptoms are to be noted. Examination of the breasts, weight and blood pressure recording and pelvic examination including cervical cytology, are to be done and compared with the previous records.

**MISSED PILLS:** Normally there is return of pituitary and ovarian follicular activity during the pill-free interval (PFI) of 7 days. Breakthrough ovulation may occur in about 20 percent cases during the time. Lengthening of PFI due to omissions, malabsorption, or vomiting either at the start or at the end of a packet, increases the risk of breakthrough ovulation and therefore pregnancy.

**Management:** When a woman forgets to take **one pill** (late up to 24 hours), she should take the missed pill at once and continue the rest as schedule. There is nothing to worry.

When she **misses two pills** in the first week (days 1–7), she should take 2 pills on each of the next 2 days and then continue the rest as schedule. Extra precaution has to be taken for next 7 days either by using a condom or by avoiding sex.



If 2 pills are missed in the third week (days 15–21) or if more than two active pills are missed at any time, another form of contraception should be used as back up for next 7 days as mentioned above. She should start the next pack without a break.

If she misses any of the **7 inactive pills** (in a 28-day pack only) she should throw away the missed pills. She should take the remaining pills one a day and start the new pack as usual.

**Drug interactions:** Effectiveness of some drugs (Aspirin, oral anticoagulants, oral hypoglycemics) are decreased and that for some other drugs (beta blockers, corticosteroids, diazepam, aminophylline) are increased by oral contraceptives.

**ADDITIONAL CONTRACEPTION:** To ensure cent percent efficacy, additional mechanical contraceptives (usually condom) are to be used in the following circumstances :

- (1) **When broad spectrum antibiotics like** ampicillin, amoxicillin, tetracycline, doxycycline are used — as they impair the absorption of ethinyl estradiol.
- (2) When enzyme inducing drugs are used, e.g. (a) barbiturates (b) all antiepileptic drugs except sodium valproate and clonazepam (c) rifampicin (d) ketoconazole (e) griseofulvin (f) ritonavir (g) nevirapine—under such circumstances high dose preparations (ethinyl estradiol of 50 µg or more) are to be used to counter balance the increased liver metabolism.

**INDICATIONS FOR WITHDRAWAL:** While the majority tolerates the combined pill, in some susceptible individuals, gross adverse symptoms develop which necessitate its withdrawal. **The indications for withdrawal of the pill are—** (1) Severe migraine; (2) Visual or speech disturbances; (3) Sudden chest pain; (4) Unexplained fainting attack

#### MEDICAL ELIGIBILITY CRITERIA FOR CONTRACEPTIVE USE (WHO/FRM/FPP—1996)

##### COMBINED ORAL CONTRACEPTIVES (COCs)

INDICATIONS OF COCs	CONTRAINDICATIONS OF COCs	
No restriction of use (WHO Category–1)	Relative (WHO Category–2 and 3)	Absolute (WHO Category–4)
<ul style="list-style-type: none"> <li>Age : Menarche to 40 years</li> <li>Postabortion</li> <li>Anemia (iron deficiency, Malaria)</li> <li>HIV or AIDS (additional to condom use)</li> <li>GTN following normal hCG level</li> <li>History of ectopic pregnancy</li> <li>Endometriosis, Uterine fibroid, Ovarian or endometrial cancer</li> <li>Dysmenorrhea, DUB</li> <li>PID</li> <li>Epilepsy</li> <li>Thyroid disease</li> <li>Varicose veins</li> <li>Tuberculosis</li> <li>Benign breast disease</li> </ul>	<p><b>A. WHO Category–2 : (Advantages outweigh the risks)</b></p> <ul style="list-style-type: none"> <li>Age ≥ 40 years</li> <li>Smoker &lt; 35 years</li> <li>History of jaundice</li> <li>Mild hypertension</li> <li>Gallbladder disease</li> <li>Diabetes</li> <li>Sickle cell disease</li> <li>Headache</li> <li>Cancer cervix or CIN</li> </ul> <p><b>B. WHO Category–3 : (Risks outweigh the advantages)</b></p> <ul style="list-style-type: none"> <li>Unexplained vaginal bleeding</li> <li>Hyperlipidemia</li> <li>Liver tumors (Benign)</li> <li>Breastfeeding (postpartum 6 weeks to 6 months)</li> <li>Heavy smoker (&gt; 20 cigarettes/day)</li> <li>Past breast cancer</li> </ul>	<p><b>(A) Circulatory diseases (Past or present)</b></p> <ul style="list-style-type: none"> <li>Arterial or venous thrombosis</li> <li>Severe hypertension</li> <li>History of stroke</li> <li>Heart disease: valvular, Ischemic</li> <li>Diabetes with vascular complications</li> <li>Migraine with focal neurologic symptoms</li> </ul> <p><b>(B) Diseases of the liver</b></p> <ul style="list-style-type: none"> <li>Active liver disease</li> <li>Liver adenoma, carcinoma</li> </ul> <p><b>(C) Others</b></p> <ul style="list-style-type: none"> <li>Pregnancy</li> <li>Breastfeeding (postpartum 6 weeks)</li> <li>Major surgery or prolonged immobilization</li> <li>Estrogen dependent neoplasms, e.g. breast cancer</li> </ul>

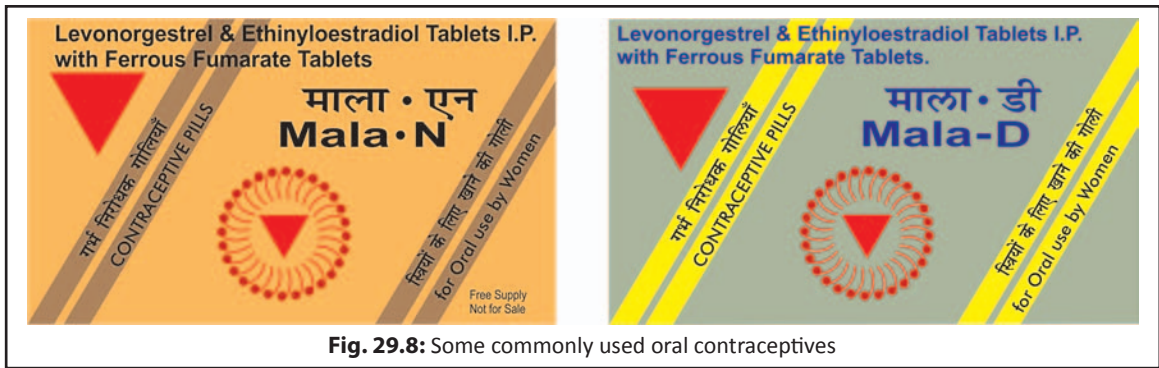


Fig. 29.8: Some commonly used oral contraceptives

or acute vertigo; (5) Severe cramps and pains in legs; (6) Excessive weight gain; (7) Severe depression; (8) Prior to surgery (it should be withheld for at least 6 weeks to minimize postoperative vascular complications) and (9) Patient wanting pregnancy.

**Continuous or extended use of COCs:** It can be used by women who prefer to bleed at an interval of 60–80 days (3–4 times a year). For extended use of pills, the woman should take the active pills from pill pack and immediately start the next pack of active pills. The pills should be continued for 60–80 days, then a withdrawal bleed is allowed. Formulations with 84 active pills followed by 7 placebo pills are being made. This results in a “seasonal” withdrawal bleed at an interval of 4 months. Any monophasic pill may be used in this manner.

Pill regimen with 24 active pills followed by 4 placebo pills results in menses at a 28 days interval with lesser bleeding both in amount and days. Failure rate is also less.

**How long can the pill be continued?** Potential benefits of pills are greater when compared to risks, in a well-selected individual. A woman who does not smoke

and has no other risk factor for cardiovascular disease, may continue the pill (with careful monitoring) until the age of fifty years. This offers the dual advantages of effective contraception and hormone replacement therapy. However, for spacing of births, use of 3 to 5 years is considered enough and safe.

### General and Metabolic Effects of Combined Oral Contraceptives

The combined preparations containing estrogen and progestin have got a wide range of metabolic activities which affect almost all the systems of the body. The changes are almost similar to those of pregnancy and almost completely revert back to normal after the drug is withdrawn. **The effects are related either to the estrogen (OGN) or to the progestin (PGN) or to both (OGN + PGN) of the compounds.**

## BENEFITS OF COMBINED ORAL CONTRACEPTIVES (COCs)

- (a) **Contraceptive benefits:** (i) Protection against unwanted pregnancy (failure rate – 0.1 per 100 women year) (ii) Convenient to use (iii) Not

TABLE 29.9 COMBINED PREPARATIONS

Advantages	Disadvantages
<ol style="list-style-type: none"> <li>Highly effective</li> <li>Good cycle control</li> <li>Well-tolerated in majority</li> <li>Additional non-contraceptive — benefits are many (see above)</li> <li>Low dose pill with 'lipid friendly' progestins further reduces the risk</li> <li>Reversibility rate is prompt</li> </ol>	<ol style="list-style-type: none"> <li>Requires education and motivation</li> <li>Limitation in its use (see above)</li> <li>Requires initial check up and periodic supervision</li> <li>Inconvenience caused in its use due to daily schedule</li> <li>Risk of drug interactions (p. 487)</li> <li>Costly but free supply through government channel (Mala-N)</li> </ol>
	<div style="border: 1px solid black; padding: 5px; display: inline-block;">Failure rate—0.1 (HWY)</div>

intercourse related (iv) Reversibility (v) Improving maternal and child health care.

- (b) **Non-contraceptive benefits:** *Improvement of menstrual abnormalities*—(1) Regulation of menstrual cycle (2) Reduction of dysmenorrhea (40%) (3) Reduction of menorrhagia (50%) (4) Reduction of premenstrual tension syndrome (PMS) (5) Reduction of Mittelschmerz's syndrome (6) Protection against iron-deficiency anemia. **Protection against health disorders** — (7) Pelvic inflammatory disease (thick cervical mucus) (8) Ectopic pregnancy (9) Endometriosis (10) Fibroid uterus (11) Hirsutism and acne (12) Functional ovarian cysts (13) Benign breast disease (14) Osteopenia and postmenopausal osteoporotic fractures (15) Autoimmune disorders of thyroid (16) Rheumatoid arthritis. **Prevention of malignancies**—(17) Endometrial cancer (50%) (18) Epithelial ovarian cancer (50%) (19) Colorectal cancer (40%).

## ADVERSE EFFECTS OF COMBINED ORAL CONTRACEPTIVES

The minor complications or ailments are —

- **Nausea, vomiting, headache (OGN) and leg cramps (PGN)**—These are transient and often subside following continuous use for 2–3 cycles.
- **Mastalgia (OGN + PGN)** — Heaviness or even tenderness in the breast is often transient.
- **Weight gain (PGN)** — Though progestins have got an anabolic effect due to its chemical relation to testosterone, use of low dose COCs does not cause any increase in weight.
- **Chloasma (OGN) and acne (PGN)** are annoying for cosmetic reasons. Low dose oral contraceptives improves acne as levonorgestrel preparations are less androgenic.
- **Menstrual abnormalities**—(a) **Breakthrough bleeding (BTB)** is commonly due to subthreshold blood level of hormones. Other causes of breakthrough bleeding in pill takers are (i) disturbance of drug absorption — diarrhea, vomiting (ii) use of enzyme inducing drugs (mentioned earlier), missing pills, use of low dose pills (iii) pregnancy complications (miscarriage) (iv) diseases—cervical ectopy or carcinoma. Usually, it settles after 3–4 cycles when there is no other specific cause for BTB. Exogenous estrogen (conjugated estrogen 1.25 mg or estradiol 2 mg) given daily for 7 days can control the bleeding. Doubling up

the active pills for 2–3 days, or until bleeding stops, is helpful. A pill containing higher dose of estrogen, with different progestin could be helpful. BTB is not associated with any increased failure rate. (b) **Hypomenorrhea (PGN)** — It is of little significance although disturbing to the patient. It is due to the local endometrial changes. (c) **Menorrhagia (OGN)** — It is usually pre-existing and use of compounds with progestin preponderance is helpful. (d) **Amenorrhea (OGN or PGN)** — Post pill amenorrhea of more than 6 months duration occurs in less than 1 percent cases. The association is casual not causal. It is usually more in women with pre-existing functional menstrual disorders. Spontaneous resumption of menstruation occurs in majority of cases. A refractory case ( $\geq 12$  months) should be investigated as a case of secondary amenorrhea.

- **Libido:** Libido may be diminished (PGN) probably due to dryness of the vagina. More often, it may either remain static or at times, may even increase due to loss of fear of pregnancy.
- **Leucorrhoea:** It may be due to excessive cervical mucus secretion (OGN) or due to increased preponderance of monilial infection (OGN + PGN).

*The major complications are:*

- **Depression:** Low dose estrogen preparations are not associated with depression.
- **Hypertension (OGN):** Current low dose COC<sub>s</sub> rarely cause significant hypertension. Pre-existing hypertension is likely to be aggravated. Changes are seen only in systolic but not in diastolic blood pressure. The effect on blood pressure is thought to involve the renin-angiotensin system. There is marked increase in plasma angiotensinogen. The changes however reverse back to normal 3–6 months after stoppage of pill.
- **Vascular complications (OGN):** (a) **Venous thromboembolism (VTE)** — The overall risk is to the extent of 3–4 times more than the non-users. Pre-existing hypertension, diabetes, obesity thrombophilias (inherited or acquired) and elderly patient (over 35 especially with smoking habits) are some of the important risk factors. Ethinyl estradiol used with a dose of 20  $\mu\text{g}$  in the pill markedly reduce the incidence.

Current studies estimate the annual number of nonfatal VTE per 100,000 users as: no COC use = 5, second generation COC = 15, COC containing desogestrel and gestodene = 30, pregnancy = 60.

The absolute risk is very small compared to pregnancy. The risk of death from VTE due to COCs is extremely low at 1–5 per million per year. The most important risk factor is genetic thrombophilia (factor V Leiden mutation). This is rare in Asians (0.4%) compared to Caucasian (5%). (b) Arterial thrombosis — **The high risk factors for myocardial infarction and stroke (ischemic and hemorrhagic) are hypertension, smoking habit, age over 35 and diabetes.** Women with multiple risk factors for cardiovascular disease generally should not use COCs.

- **Cholestatic jaundice**—Susceptibility is increased in women with previous history of idiopathic recurrent jaundice in pregnancy or hepatitis.
- **Neoplasia (OGN)**—Combined oral contraceptives (COCs) **reduce the risk of epithelial ovarian (50% ↓) and endometrial (50% ↓) carcinoma.** This protective effect persists for 10–15 years even after stopping the method following a use of 6 months to 1 year. No major association has been established between breast carcinoma and low dose COC use. Conclusions regarding association of COC and cervical carcinoma are not definite. However, pill users should have regular HPV DNA and **cervical cytology screening. No increased risk of hepatocellular adenomas** have been found with low dose preparations. It gives protection against benign cystic breast disease and cystic ovaries.

**GENERAL METABOLIC EFFECTS:**

- **Carbohydrate (PGN):** Progestins impair glucose tolerance promoting insulin resistance and hyperglycemia. This was observed in preparations containing 150 µg or more levonorgestrel. Low dose COCs have no effect on insulin, HbA<sub>1c</sub>, and fasting glucose levels.
- **Protein (OGN):** Estrogen has got some stimulatory effect on the hepatic secretion of many proteins. The level of sex hormone binding globulin (SHBG) is increased.
- **Lipid (OGN):** Plasma lipids and lipoproteins are increased. Total cholesterol and triglycerides are increased. Low dose estrogen increases HDL cholesterol and decreases LDL cholesterol thereby exerts its protective effect against atherosclerosis. Progestins however decrease HDL cholesterol and increase LDL cholesterol thereby promote heart disease. Preparations with more selective, lipid friendly and third generation progestins namely desogestrel, gestodene or norgestimate, HDL level is somewhat elevated. However, most changes are within the normal range and not clinically relevant.

- **Vitamins and minerals:** Vitamin B<sub>6</sub>, B<sub>12</sub>, folic acid, calcium, manganese, zinc and ascorbic acid levels are decreased while vitamins A and K levels are increased.

**EFFECTS ON ORGANS:**

- ♦ **Hypothalamopituitary axis:** Both FSH and LH levels remain low as found in early proliferative phase and remain throughout the cycle at such static low level.
- ♦ **Ovary:** Ovarian function remains quiescent with occasional evidence of breakthrough ovulation. There is evidence of fibrosis, progressive wastage of unripe ova with advancing age without evidence of corpus luteum. The endogenous hormones remain static at a low level.
- ♦ **Endometrium (PGN)**—Stromal edema, decidual reaction and glandular exhaustion out of depletion of glycogen are more or less constant findings.

- ♦ **Cervix (PGN + OGN)**—Increased glandular hyperplasia and downgrowth of the endocervical epithelium beyond the squamocolumnar junction gives the appearance of an ectopy. Relative risk of cervical cancer with COC use is 1.1. It may be due to the persistent exposure of the pill users to HPV infection or due to their more sexual activity.
- ♦ **Uterus (OGN)**—Uterus may be slightly enlarged. Low dose COCs do not usually increase the size of a pre-existing fibroid. COCs can reduce the amount of menstrual bleeding.
- ♦ **Vagina (PGN)**—Cyto hormonal study reflects the picture of early luteal phase.
- ♦ **Other organs:**
  - Liver* — The liver functions are depressed.
  - Gastrointestinal tract* — There is increased incidence of mesenteric vein thrombosis.
  - Urinary* — There is increased incidence of urinary tract infection but is probably related to increase in sexual activity.

**EFFECTS ON REPRODUCTION:**

- ♦ **Ovulation returns within 3 months of withdrawal of the drug in 90 percent cases.**
- ♦ **Risk to fetus:** When COC is taken during early pregnancy inadvertently there is no greater risk of significant congenital anomaly. Risk of congenital abnormality in general is 2–3 percent.
- ♦ **Lactation (OGN + PGN):** Lactation is probably affected by a reduction in the milk production and also by alteration of the quality of the milk (reduction of protein and fat content). Moreover, significant amount of the steroids are ingested by the infant, the effects are as yet unknown. Mini-pill is a better alternative for the breastfeeders.

**TRIPHASIC FORMULATIONS OF COMBINED ORAL PILLS:** In these preparations, the hormonal doses of each compound vary over the course of the cycle. Minimum doses are provided for contraceptive effect in the early part of the cycle and slightly higher doses later in the cycle to prevent breakthrough bleeding. **It is an attempt to minimize undesirable side effects on lipid metabolism.** This is due to low total amount of steroids and the balanced estrogen-progestogen relationship.

Triphasic tablets (Shering-AG) — First 6 tablets contain 0.05 mg levonorgestrel and 30 mg of ethinyl estradiol; next 5 tablets contain 0.075 mg levonorgestrel and

40 mg ethinyl estradiol; the last 10 tablets contain 0.125 mg levonorgestrel and 30 mg ethinyl estradiol. It has to be taken like conventional ‘pills’.

## PROGESTIN ONLY CONTRACEPTION (POP/MINI PILL)

POP is devoid of any estrogen compound. It contains very low dose of a progestin in any one of the following form — Levonorgestrel 75 µg, norethisterone 350 µg, desogestrel 75 µg, lynestrenol 500 µg or norgestrel 30 µg. **It has to be taken daily from the first day of the cycle.**

**Mechanism of action:** It works mainly by making cervical mucus thick and viscous, thereby prevents sperm penetration. Endometrium becomes atrophic, so blastocyst implantation is also hindered. In about 2 percent of cases ovulation is inhibited and 50 percent women ovulate normally.

**How to prescribe mini pill:** The first pill has to be taken on the first day of the cycle and then continuously. It has to be taken **regularly and at the same time of the day.** There must be no break between the packs.

**Delay in intake** for more than 3 hours, the woman should have missed pill immediately and the next one as schedule. Extra precaution has to be taken for next 2 days (see above).

**Advantages:** (1) Side effects attributed to estrogen in the combined pill are totally eliminated (2) No adverse effect on lactation and hence can be suitably prescribed in lactating women and as such it is often called “Lactation Pill” (3) Easy to take as there is no “On and Off” regime (4) It may be prescribed in patient having (medical disorders) hypertension, fibroid, diabetes, epilepsy, smoking and history of thromboembolism (5) Reduces the risk of PID and endometrial cancer.

**Disadvantages:** (1) There may be acne, mastalgia, headache, breakthrough bleeding, or at times amenorrhea in about 20–30 percent cases (2) All the side effects, attributed to progestins may be evident (3) Simple cysts of the ovary may be seen, but they do not require any surgery (4) Failure rate is about

0.5–2 per 100 women years of use. Failure is more in young compared to women over 40. Women using drugs that induce liver microsomal enzymes to alter a metabolism (mentioned above) should avoid this method of contraception.

**Contraindications:** (i) Pregnancy (ii) unexplained vaginal bleeding (iii) recent breast cancer (iv) arterial disease. (v) thromboembolic disease.

## INJECTABLE PROGESTINS

The preparations commonly used are depomedroxy progesterone acetate (DMPA) and norethisterone enanthate (NET-EN). Both are administered intramuscularly (deltoid or gluteus muscle) within 5 days of the cycle. The injection should be deep, Z-tract technique and the site not to be massaged. DMPA in a dose of 150 mg every three months (WHO 4 months) or 300 mg every six months; NET-EN in a dose of 200 mg given at two-monthly intervals.

**Depo-Sub Q provera 104**, contains 104 mg of DMPA. It is given subcutaneously over the anterior thigh or abdomen. It suppresses ovulation for 3 months as it is absorbed more slowly.

**Mechanism of action:** (1) Inhibition of ovulation — by suppressing the mid cycle LH peak (2) cervical mucus becomes thick and viscid thereby prevents sperm penetration (3) Endometrium is atrophic preventing blastocyst implantation.

**Advantages:** (1) It eliminates regular medication as imposed by oral pill (2) It can be used safely during lactation. It probably increases the milk secretion without altering its composition (3) No estrogen related side effects (4) Menstrual symptoms, e.g. menorrhagia, dysmenorrhea are reduced (5) Protective against endometrial cancer (6) Can be used as an interim contraception before vasectomy becomes effective (7) Reduction in PID, endometriosis, ectopic pregnancy and ovarian cancer. **The non-contraceptive benefits:** DMPA reduces the risk of—salpingitis, endometrial cancer, iron deficiency anemia, sickle cell problems and endometriosis.



**Fig. 29.9:** Single implant rod — Implanon

**Disadvantages:** **Failure rate** for DMPA – (0–0.3) (HWY). There is chance of irregular bleeding and occasional phase of amenorrhea. Return of fertility after their discontinuation is usually delayed for several months (4–8 months). However, with NET-EN the return of fertility is quicker. Loss of bone mineral density (reversible) has been observed with long-term use of depot provera. Overweight, insulin resistant women may develop diabetes. **Other side effects are:** weight gain and headache.

**Contraindications:** Women with high risk factors for osteoporosis and the others are same as in POP (see above).

## IMPLANT

**Implanon** is a progestin only delivery system containing 3 Ketodesogestrel (etonorgestrel). It is a long-term (up to 3 years) reversible contraception. It consists of a single closed capsule (made of polydimethyl siloxane 40 mm × 2 mm) and contains 68 mg of etonorgestrel (ENG). It releases the hormone about 60 mcg, gradually reduced to 30 mcg per day over 3 years. Implanon does not cause decrease in bone mineral density (Fig. 29.9).

**Mechanism of action:** It inhibits ovulation in 90 percent of the cycles for the first year. It has got its supplementary effect on endometrium (atrophy) and cervical mucus (thick) as well.

**Insertion:** The capsule is inserted subdermally, in the inner aspect of the nondominant arm, 6–8 cm above the elbow fold. It is inserted between biceps and triceps muscles. Preloaded sterile applicator is available. No incision is required. Removal is done by making a 2 mm incision at the tip of the implant and pushing the rod until it pops out. It is done under local anesthetic. It is ideally inserted within D 5 of a menstrual cycle, immediately after abortion and 3 weeks after postpartum.

**Removal:** Implanon should be removed within 3 years of insertion. Loss of contraceptive action is immediate.

**Advantages** are the same as with DMPA. Others are (i) Highly effective for long-term use and rapidly

reversible. (ii) Suited for women who have completed their family but do not desire permanent sterilization.

**Efficacy of implanon** is extremely high with Pearl indices of 0.01. This safe and effective method is considered as ‘reversible sterilization’. **Drawbacks:** Frequent irregular menstrual bleeding, spotting and amenorrhea are common. Difficulty in removal is felt occasionally. **Contraindications** are similar to POP (see above).

**NORPLANT-II (Jadelle):** Two rods of 4 cm long with diameter of 2.5 mm is used. Each rod contains 75 mg of levonorgesterel. It releases 50 mcg of levonorgestrel per day. Contraceptive efficacy is similar to combined pills. Failure rate is 0.06 per 100 women years. It is used for 3 years. The rods are easier to insert and remove.

## EMERGENCY CONTRACEPTION (EC) (SYN: POSTCOITAL CONTRACEPTION)

- Hormones
- Anti-progesterone
- IUD
- Others

**Indications of emergency contraception:** Unprotected intercourse, condom rupture, missed pill, delay in taking POP for more than 3 hours, sexual assault or rape and first time intercourse, as known to be always unplanned. Risk of pregnancy following a single act of unprotected coitus around the time of ovulation is 8 percent.

### Hormones (Table 29.10)

**Morning-after Pill:** This is not true contraception, but has rightly been called interception, preventing conception in case of accidental unprotected exposure around the time of ovulation. **Drugs commonly used:** levonorgestrel (see below), ethinyl-estradiol 2.5 mg. The drug is taken orally twice daily for 5 days, beginning soon after the exposure but not later than 72 hours.

**Levonorgestrel (E. Pills)** 0.75 mg, two doses given at 12 hours interval, is very successful and without any side effects. The two tablets (1.50 mg) can be taken as a single dose also.

**TABLE 29.10** EMERGENCY CONTRACEPTIVES

Drug	Dose	Pregnancy rate (%)
Levonorgestrel	0.75 mg stat and after 12 hours	0–1
Ethinyl estradiol 50 µg + Norgestrel 0.25 mg	2 tab stat and 2 after 12 hours	0–2
Ethinyl estradiol	2.5 mg BD × 5 days	0–0.6
Mifepristone	100 mg single dose	0–0.6
Copper IUDs (Gold standard)	Insertion within 5 days	0–0.1
Ulipristal acetate	30 mg PO	0–1

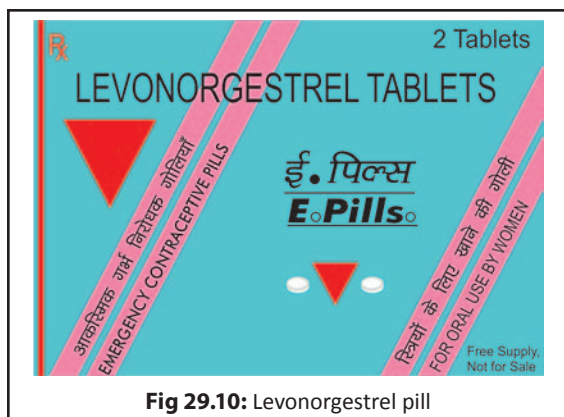


Fig 29.10: Levonorgestrel pill

The first dose should be taken within 72 hours (see Fig. 29.10).

**No fetal adverse effects has been observed when there is failure of emergency contraception.** However, induced abortion should be offered to the patient, if the method fails.

**Mode of action:** The exact mechanism of action remains unclear. The following are the possibilities:

- ◆ Ovulation is either prevented or delayed when the drug is taken in the beginning of the cycle.
- ◆ Fertilization is interfered.
- ◆ Implantation is prevented (except E. Pills) as the endometrium is rendered unfavorable.
- ◆ Interferes with the function of corpus luteum or may cause luteolysis.

**Drawbacks:** Nausea and vomiting are much more intense with estrogen use. Antiemetic (meclizine) should be prescribed.

**Copper IUD:** Introduction of a copper IUD within a maximum period of 5 days can prevent conception following accidental unprotected exposure. This prevents implantation. Failure rate is about 0–1 percent. **It is the gold standard method to be opened to all women for EC.**

Postcoital contraception is only employed as an emergency measure and is not effective if used as a regular method of contraception.

**Combined hormonal regimen (Yuzpe method)** is equally effective. Two tablets of Ovral (0.25 mg levonorgestrel and 50 µg ethinyl estradiol) should be taken as early as possible after coitus (< 72 hours) and two more tablets are to be taken 12 hours later.

Oral antiemetic (10 mg metoclopramide) may be taken 1 hour before each dose to reduce the problem of nausea and vomiting.

**Anti-progesterone:** Anti-progesterone (RU 486-Mifepristone) binds competitively to progesterone receptors and nullifies the effect of endogenous progesterone.

**Dose:** A single dose of 100 mg is to be taken within 17 days of intercourse. Implantation is prevented due to its

anti-progesterone effect. Pregnancy rate is 0–0.6 percent.

**Ulipristal acetate** as an EC is as effective as levonorgestrel. A single dose 30 mg, to be taken orally as soon as possible or within 120 hours of coitus. It acts by suppressing follicular and endometrial growth. It delays ovulation and inhibits implantation. It should not be prescribed in women with severe hepatic dysfunction nor with severe asthma.

## SUMMARY OF ORAL CONTRACEPTIVES

- ◆ **Combined pills**      ◆ **Triphasic pill**
- ◆ **Emergency (postcoital) contraception**
- ◆ **Mini pill**

**Conventional combined preparations**—The widely used oral contraceptives consist of tablets containing estrogen and progestin compounds. It is the most effective and reversible method of contraception. Each tablet usually contains 30 mg of ethinyl estradiol and 1 mg of norethisterone or 0.3 mg norgestrel. **It has got trigger action**—(a) inhibition of ovulation, (b) production of static endometrial hypoplasia and (c) alteration of the character of the cervical mucus. **Its use is absolutely contraindicated in cases** with circulatory diseases, liver diseases, severe migraine and estrogen dependent tumor. The pill should be started from the day one of a cycle and continued as “3 weeks on and 1 week off” regime. Periodic check up is essential especially when prescribed in women above the age of 35. **The pill should be withdrawn** if complications arise such as severe migraine, chest pain, visual disturbances, etc.

**The beneficial effects are** relief of dysmenorrhea, premenstrual tension, endometriosis, acne, hirsutism and lesser chance of ectopic and PID. It gives protection against ovarian and endometrial carcinomas.

**The minor side effects are**—nausea, vomiting, break-through bleeding, mastalgia, leg cramp, weight gain, hypomenorrhea or amenorrhea. The major complications are rare and include depression, hypertension and thromboembolic manifestations. The failure rate is about 0.1 per HWY.

- ◆ **Triphasic pill**—It has got lesser amount of steroids than the conventional monophasic tablets. There is lesser effect on lipid metabolism.
- ◆ **Emergency**—Following rape or accidental exposure, either levonorgestrel, 0.75 mg two doses at 12 hours interval or two tablets of the COC preparations are to be taken soon after coitus and two more tablets after 12 hours are quite effective in preventing conception. The first dose should be taken within 72 hours.
- ◆ **Mini pill**—The pill contains low doses of progestin—norgestrel 30 mg, levonorgestrel 75 µg or desogestrel 75 µg. It should be taken daily and can be safely prescribed during lactation. It is best suited where estrogen is contraindicated.

## STERILIZATION

Permanent surgical contraception, also called voluntary sterilization, is a surgical method whereby the reproductive function of an individual male or female is purposefully and permanently destroyed. **The operation done on male is vasectomy and that on the female is tubal occlusion, or tubectomy.**

### Couple Counseling

Couple must be counseled adequately before any permanent procedure is undertaken. Individual procedure must be discussed in terms of benefits, risks, side effects, failure rate and reversibility.

### VASECTOMY (Fig. 29.11)

It is a permanent sterilization operation done in the male where a segment of vas deferens of both the sides are resected and the cut ends are ligated.

**Advantages:** (1) The operative technique is simple and can be performed by one with minimal training (2) The operation can be done as an outdoor procedure

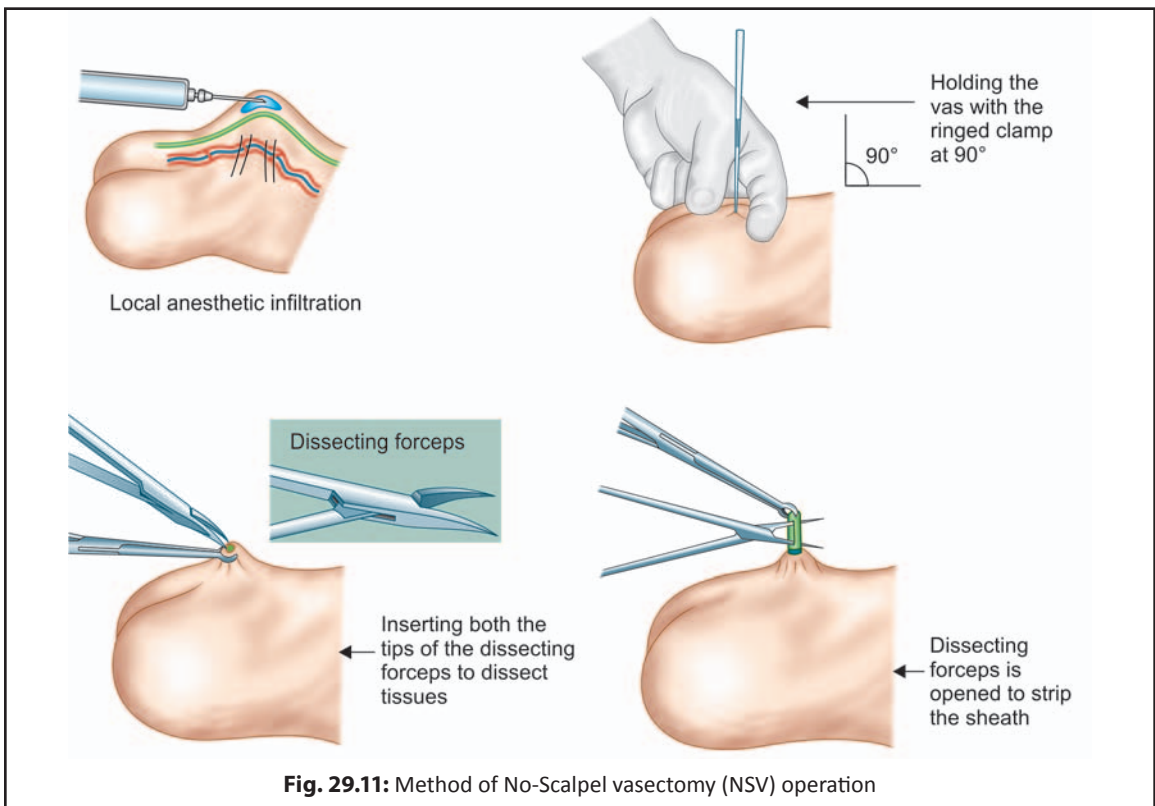
or in a mass camp even in remote villages (3) Complications—immediate or late are fewer (4) Failure rate is minimal—0.15 percent and there is a fair chance of success of reversal anastomosis operation (70–80%) (5) The overall expenditure is minimal in terms of equipment, hospital stay and doctor's training.

**Drawbacks:** (1) Additional contraceptive protection is needed for about 2–3 months following operations, i.e. till the semen becomes free of sperm (2) Frigidity or impotency when occurs is mostly psychological.

**Selection of candidates: Sexually active and psychologically adjusted husband having the desired number of children is an ideal one.**

**No-Scalpel Vasectomy (NSV):** It is commonly done at present in India. It was popularized by Dr Li Shun Qiang of China in 1991.

**Technique: Written consent of the person is taken following counseling.** The operation is done as an outdoor procedure or in the camp. The local area is shaved and cleaned with povidone-iodine lotion. Full surgical asepsis





has to be maintained during operation. Procedure is done under local anesthetic.

The vas is palpated with three fingers of the left hand; index and thumb in front and the middle behind. This is done at the level midway between the top of the testis and the base of the penis. The vas is grasped with a ringed clamp applied perpendicularly on the skin overlying the vas. The skin is punctured with the sharp pointed end of the medial blade of a dissecting forceps. The puncture point is enlarged by spreading the tissues (dartos muscle and spermatic fascia) inserting both the tips of the dissecting forceps. The vas is elevated with the dissecting forceps and in hold with the ringed clamp. At least 1 cm of length of vas is made free and mobilized. The vas is ligated at two places 1 cm apart by No. '00' chromic catgut and the segment of the vas in between the ligatures is resected out. Division of the vas should be accompanied by fascial interposition or diathermy. This reduces the failure rate. Hemostasis is secured. No skin suturing is needed. Wound dressing is done and a small pressure bandage is applied. The same procedure is repeated on the other side. A scrotal suspensory bandage is worn. The patient is allowed to go home after  $\frac{1}{2}$  an hour. Histological examination of the excised segment of the vas should be done for confirmation if the surgeon is in any doubt.

**Advices:** Antibiotic (Injection Penidure LA 6 IM) is administered as a routine and an analgesic is prescribed. Heavy work or cycling is restricted for about 2 weeks, while usual activities can be resumed forthwith. For check up, the patient should report back after 1 week, or earlier, if complication arises. **Additional contraceptive should be used for 3-4 months.**

**NVS** takes less time, helps faster recovery due to less tissue injury. Complications are significantly less. However, it needs training on the part of the surgeon.

**Precaution: The man does not become sterile soon after the operation** as the semen is stored in the distal part of the vas channels for a varying period of about 3 months. **It requires about 20 ejaculations to empty the stored semen.** Semen should be examined either by one test after 16 weeks or by two tests at 12 and 16 weeks after vasectomy and if the two consecutive semen analyses show absence of spermatozoa, the man is declared as sterile. Till then, additional contraceptive (condom or DMPA to wife) should be advised.

**Complications:** Complications of NSV are significantly less.

♦ **Immediate** — (1) Wound sepsis which may lead to scrotal cellulitis or abscess; (2) Scrotal hematoma.

♦ **Remote**—(1) Frigidity or impotency—It is mostly psychological in origin. (2) Sperm granuloma is due to inflammatory reaction to sperm leakage. This can be prevented by cauterization or fulguration of the cut ends. (3) Chronic intrascrotal pain and discomfort (post-vasectomy syndrome) may be due to scar tissue formation, or tubular distension of the epididymis. (4) There is no increase in testicular cancer or heart disease. Risk of prostate cancer is considered two have no causal association. (5) Spontaneous recanalization (1 in 2000) is rare.

#### Other Methods to block the Vas

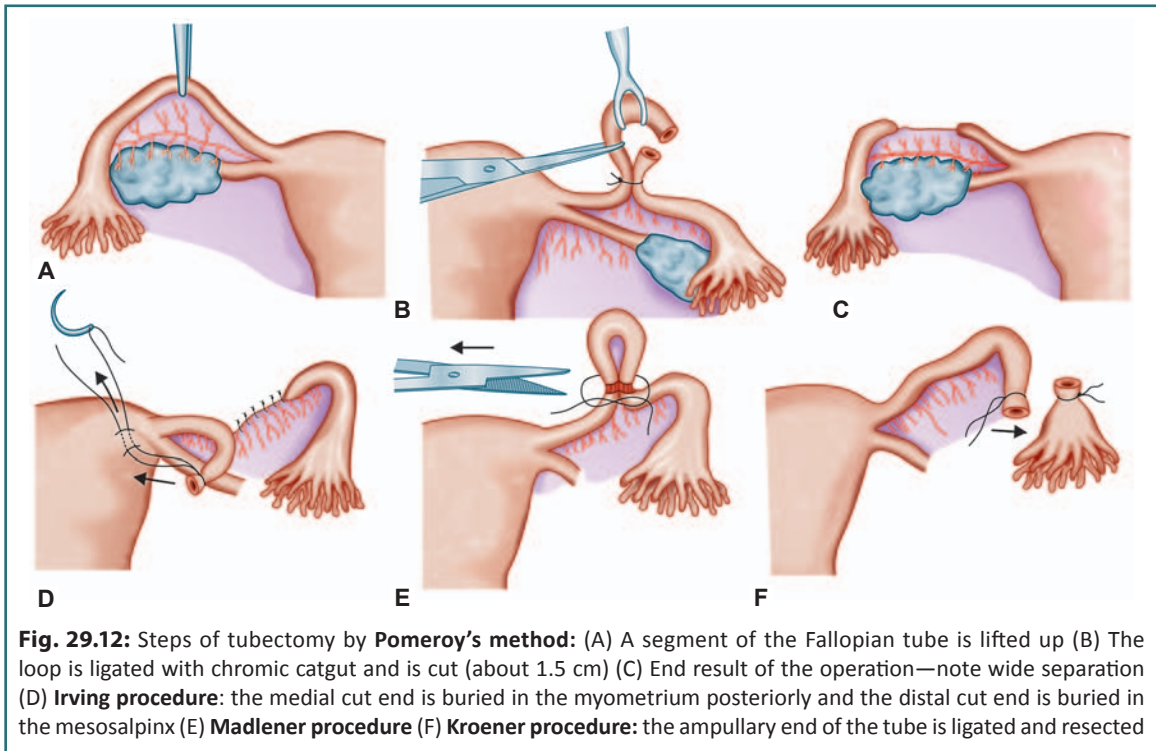
- A. **Electrocoagulation** may be used to encourage scar tissue formation.
- B. **Fascial interposition** following ligation, excision and cautery. This is done to prevent recanalization

## FEMALE STERILIZATION

Occlusion of the fallopian tubes in some form is the underlying principle to achieve female sterilization. It is the most popular method of terminal contraception all over the world.

**Indications:** (1) **Family planning purposes:** This is the principal indication in most of the developing countries. (2) **Socioeconomic:** An individual is adopted to accept the method after having the desired number of children. (3) **Medicosurgical indications (therapeutic):** Medical diseases such as heart disease, diabetes, chronic renal disease, hypertension are likely to worsen, if repeated pregnancies occur and hence sterilization is advisable. During third time repeat cesarean section or repair of prolapse operation, to avoid the risks involved in the future childbirth process, sterilization operation should be seriously considered.

**Time of Operation:** (1) **During puerperium (puerperal):** If the patient is otherwise healthy, the operation can be done 24–48 hours following delivery. Its chief advantage is technical simplicity. Hospital stay and rest at home following delivery are enough to help the patient to recover simultaneously from the two events, i.e. delivery and operation. (2) **Interval:** The operation is done beyond 3 months following delivery or abortion. **The ideal time of operation is following the menstrual period in the proliferative phase.** (3) **Concurrent with MTP:** Sterilization is performed along with termination of pregnancy. This is mostly done especially in the urban centers.



**Fig. 29.12:** Steps of tubectomy by **Pomeroy's method:** (A) A segment of the Fallopian tube is lifted up (B) The loop is ligated with chromic catgut and is cut (about 1.5 cm) (C) End result of the operation—note wide separation (D) **Irving procedure:** the medial cut end is buried in the myometrium posteriorly and the distal cut end is buried in the mesosalpinx (E) **Madlener procedure** (F) **Kroener procedure:** the ampullary end of the tube is ligated and resected

**Methods of female sterilization:** Occlusion by resection of a segment of both the fallopian tubes (commonly called Tubectomy) is the widely accepted procedure. Currently, occlusion of the tubes with rings or clips or electrocoagulation using a laparoscope is gaining popularity. Hysterectomy during the childbearing period has got an incidental sterilization effect but should not be done for sterilization purpose.

**Tubectomy (Figs 29.12 and 29.14):** It is an operation where resection of a segment of both the fallopian tubes is done to achieve permanent sterilization. The approach may be:

### (1) Abdominal (2) Vaginal

#### (1) Abdominal:

##### (A) Conventional (B) Minilaparotomy

#### Conventional (Laparotomy)—Steps:

♦ **Anesthesia:** The operation can be done under general or spinal or local anesthesia. **In mass camp, local anesthesia is preferable.** In case of local anesthesia, premedication with Inj. Morphine 15 mg or Inj. Pethidine 100 mg with Phenergan 50 mg IM is to be administered at least 30–45 min prior to surgery. The incisional area is infiltrated with 1 percent lignocaine.

♦ **Incision:** **In puerperal cases,** where the uterus is felt per abdomen, the incision is made two fingers breadth (1") below the fundal height and in interval cases, the incision is made 2 fingers breadth above the symphysis pubis. The incision may be either midline or paramedian or transverse. The abdomen is opened by the usual procedure.

♦ **Delivery of the tube:** The index finger is introduced through the incision. The finger is passed across the posterior surface of the uterus and then to the posterior leaf of the broad ligament from where the tube is hooked out. **The tube is identified by** the fimbrial end and mesosalpinx containing utero-ovarian anastomotic vessels.

♦ **Techniques — (Fig. 29.12):** (a) **Pomeroy's:** A loop is made by holding the tube by an Allis forceps in such a way that the major part of the loop consists mainly of isthmus and part of the ampullary part of the tube (at the junction of proximal and middle third). Through an avascular area in the mesosalpinx, a needle threaded with No. '0' chromic catgut is passed and both the limbs of the loop are firmly tied together. About 1–1.5 cm of the segment of the loop distal to the ligature is excised. The tube is so excised as to leave behind about 1.5 cm of intact tube adjacent to uterus. **Segment of the loop removed is to be inspected to be sure that the**

**wall has not been partially resected and to send it for histology.** The same procedure is repeated on the other side. Because of the absorption of the absorbable ligature, the cut ends become independently sealed off and are separated after a few weeks.

**Advantages:** It is easy, safe and very effective in spite of the simplicity of the technique. The failure rate is 0.1–0.5 percent. The cut ends become independently sealed off and retract widely from each other (Fig. 29.12C).

(b) **Uchida technique**—A saline solution is injected subserosally in the mid portion of the tube to create a bleb. The serous coat is incised along the antimesenteric border to expose the muscular tube. The tube is ligated with No. 0 chromic catgut on either side and about 3–5 cm of the tube is resected off. The ligated proximal stump is allowed to retract beneath the serous coat. The serous coat is closed with a fine suture in such a way that the proximal stump is buried but the distal stump is open to the peritoneal cavity. No failure in this method has been observed so far.

(c) **Irving method** — The tube is ligated on either side and mid portion of the tube (between the ties) is excised. The free medial end of the tube is then turned back and buried into the posterior uterine wall creating a myometrial tunnel (Fig. 29.12D).

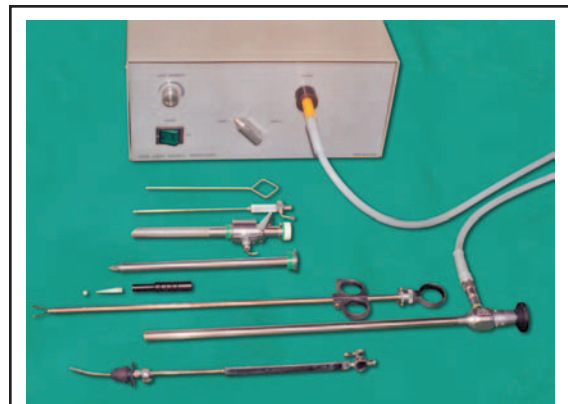
(d) **Madlener technique** (Fig. 29.12E)—It is the easiest method. The loop of the tube is crushed with an artery forceps. The crushed area is tied with black silk. **The loop is not excised.** The failure rate is very high to the extent of 7 percent and hence, it is abandoned in preference to the Pomeroy's technique.

(e) **Kroener** method of fimbriectomy is not a common procedure (Fig. 29.12F).

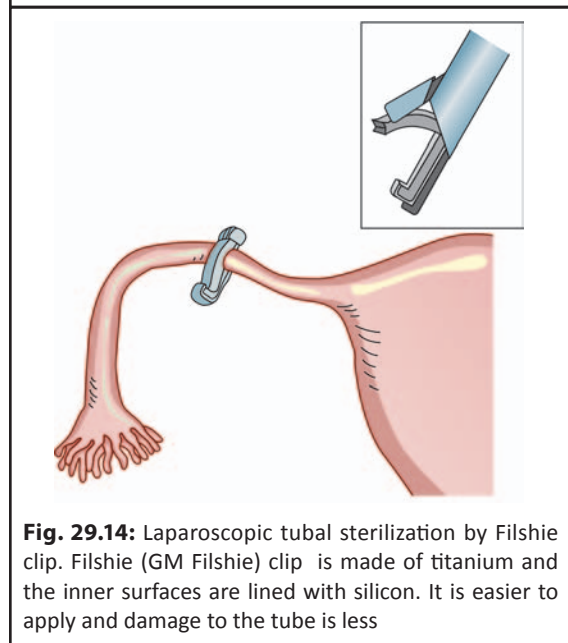
The abdomen is closed in layers. Antibiotics are given routinely in the postoperative period. The abdominal stitches are removed on the 5th day and the patient is discharged. However, if the patient has satisfactory postoperative progress, she may be discharged after 48 hours. The stitches may be removed in the outpatient department.

**MINILAPAROTOMY (MINI-LAP):** When the tubectomy is done through a small abdominal incision along with some device, the procedure is called mini-lap. It has been popularized by Uchida of Japan ever since 1961.

**Steps:** (1) Anesthesia — Always under local anesthesia (2) Plan of incision — As described in conventional method but the incision should be  $\frac{1}{2}$ "– $\frac{3}{4}$ " (3) Specially designed retractor may be introduced after the abdomen is opened. (4) Uterus is elevated or pushed to one side or the other by the elevator that has already been introduced transvaginally into the uterine cavity. This helps manipulation of the tube in bringing it close to the incisional area, when it is seized by artery forceps. (5) The appropriate technique of tubectomy



**Fig. 29.13:** Laparoscopic instruments for tubal sterilization



**Fig. 29.14:** Laparoscopic tubal sterilization by Filshie clip. Filshie (GM Filshie) clip is made of titanium and the inner surfaces are lined with silicon. It is easier to apply and damage to the tube is less

is performed on one side and then repeated on the other side. (6) The peritoneum is closed by purse string suture.

Once conversant with the technique, it can be performed with satisfaction to the patient. It also benefits the organization (turn over of the patient per bed is more than that in the conventional method). The patient is usually discharged within 24–48 hours.

**Vaginal Ligation:** Tubectomy through the vaginal route may be done along with vaginal plastic operation or in isolation. When done in isolation, **the approach to the tube is through posterior colpotomy.** Surgeon needs additional skill of vaginal surgery. Interval cases (uterus < 12 weeks) are most suited. It is done under general or spinal anesthesia. It takes longer time. Laparotomy may sometimes be needed

due to difficulties. **Complications are:** hemorrhage, broad ligament hematoma and rarely rectal injury. Dyspareunia may be a late complication. **Advantage:** Short hospital stay, convenient in obese women. Its limitation and relative merits and demerits are given in Table 29.12.

## LAPAROSCOPIC STERILIZATION

Laparoscopy is the commonly employed method of endoscopic sterilization (Figs 29.14, 35.8). It is gradually becoming more popular—especially, in the camps. The procedure is mostly done under local anesthesia. The operation is done in the interval period, concurrent with vaginal termination of pregnancy or 6 weeks following delivery. It should not be done within 6 weeks following delivery.

The procedure can be done either with single puncture or double puncture technique. The tubes are occluded either by a **silastic ring** (silicone rubber with 5 percent barium sulfate) devised by **Fallope** or by **Filshie clip** is made of titanium lined with silicone rubber. Only 4 mm of the tube is destroyed. Failure rate is 0.1 percent. **Hulka-Clemens Spring Clip** is also used. **Electrosurgical methods**—Dessicates the tissue by heating. Unipolar or bipolar method of tubal coagulation is used. Bipolar cautery is safer than unipolar one but it has higher failure rates (2.1 percent). Laser photocoagulation is not popular because of high recanalization rate.

### Principal steps (Single puncture technique)

**Premedication** — Pethidine hydrochloride 75–100 mg with phenergan 25 mg and atropine sulfate 0.65 mg are given intramuscularly about half an hour prior to operation.

**Local anesthesia**—Taking usual aseptic precautions about 10 mL of 1 percent lignocaine hydrochloride is to be infiltrated at the puncture site (just below the umbilicus) down up to the peritoneum.

**Position of the patient**—The patient is placed in lithotomy position. The operating table is tilted to approximately 15 degrees of Trendelenburg position. Usual aseptic precaution is taken as in abdominal and vaginal operations. The bladder should be fully emptied by a metal catheter. Pelvic examination is done methodically. An uterine manipulator is introduced through the cervical canal for manipulation for visualization of tubes and uterus at a later step.

**Producing pneumoperitoneum**—A small skin incision (1.25 cm) is made just below the umbilicus. The Verres needle is introduced through the incision with 45° angulation into the peritoneal cavity. The abdomen is inflated with about 2 liters of gas (carbon dioxide or nitrous oxide or room air or oxygen). Choice of gas depends upon the method of sterilization.

**Introduction of the trocar and laparoscope with ring loaded applicator**—Two silastic rings are loaded one after the other on the applicator with the help of a loader and pusher. The trocar with cannula is introduced through the incision previously made with a twisting movement. The trocar is removed and the laparoscope together with ring applicator is inserted through the cannula (Fig. 29.14).

**TABLE 29.11 FEMALE STERILIZATION**

	Abdominal approach	Vaginal approach
Surgeon	Can be performed by any one conversant with surgery	Can be done only by a surgeon conversant with vaginal plastic operation
Time of operation	Can be done at any time, puerperal or interval	Interval period is most suited May be done in other times, provided the uterus is smaller than 12 weeks
Contraindication	Practically — nil than 12 weeks size	Associated TO mass, uterus—more
Anesthesia	Can be done under local anesthesia	General or spinal anesthesia is usually needed
Complication during operation	Easy to tackle	Difficult at times and laparotomy may be necessary
Duration of operation	Shorter time	Longer time
Complications : <i>Immediate</i>	Few Wound infection, peritonitis—rare	Few Hemorrhage, revealed or broad ligament hematoma, injury to the rectum
<i>Late</i>	Incisional hernia, failure rate—less	Dyspareunia, failure rate—more
Hospital stay	Longer—5–6 days Shorter with mini-lap (24–48 hours)	Shorter—24–48 hours

**TABLE 29.12** MINI-LAP VIS-A-VIS LAPAROSCOPIC STERILIZATION

	<b>Mini-lap</b>	<b>Laparoscopic sterilization</b>
1. Cost	Minimal maintenance.	Expensive, requires adequate maintenance.
2. Personnel	Any medical personnel with surgical skill.	Should only be performed by persons with special training.
3. Selection of time	Any time — Puerperium, Interval, with MTP.	Should not be done within 6 weeks of delivery or with enlarged uterus.
4. Contraindication	Practically none. Can be done in conditions contraindicated for laparoscopy.	Lung lesions, organic heart diseases, intra-abdominal adhesions, extreme obesity.
5. Complication life-threatening	Minimal but usually not.	Minimal but at times fatal.
6. Hospital stay	3–5 days.	3–4 hours.
7. Failure rate	0.1–0.3%	0.2–0.6%
8. Reversibility	Difficult due to adhesions and reduced remnant tubal length.	Easier and effective. Only 4 mm of the tube is destroyed with the Filshie clip (see p. 581, and Figure 35.14).

The ring loaded applicator approaches one side of the tube and grasps **at the junction of the proximal and middle third of the tube**. A loop of the tube (2.5 cm) is lifted up, drawn into the cylinder of the applicator and the ring is slipped into the base of the loop under direct vision. The procedure is to be repeated on the other side (Fig. 29.14).

**Removal of the laparoscope:** After viewing that the rings are properly placed in position, the tubal loops looking white and there is no intraperitoneal bleeding, the laparoscope is removed. The gas or air is deflated from the abdominal cavity. The abdominal wound is sutured by a single chromic catgut suture.

### COMMENTS ON METHODS OF FEMALE STERILIZATION

In the third world countries, mini-lap remains the mainstay in the National Family Planning Program as a method of permanent sterilization. It is safe, has wider applicability, is less expensive and has got a less failure rate compared to laparoscopic sterilization. However, for a quick turn over in an organized mass camp, laparoscopic sterilization offers a promising success (Table 29.11).

### HAZARDS OF TUBAL STERILIZATION

**Immediate:** These are related to general anesthesia and to the particular method used in sterilization. The related complications have already been discussed (Tables 29.11 and 29.12).

**Remote:** (1) Specific for the approach and (2) Related to the sterilization.

(A) The remote complications specific for the approach of the operation, abdominal or vaginal have already been described. (B) The complications related to sterilization can be grouped into: (a) **General complications:** These include occasional obesity, psychological upset. (b) **Gynecological:** (1) Chronic pelvic pain. (2) Congestive dysmenorrhea. (3) Menstrual abnormalities in the form of menorrhagia, hypomenorrhea or irregular periods. Pelvic pain, menorrhagia along with cystic ovaries **constitute a postligation syndrome**. It may be vascular in origin. However, the incidence, can be minimized, if the blood vessels adjacent to the mesosalpinx are not unduly disturbed. (4) Alteration in libido.

**Failure rate:** The overall failure rate in tubal sterilization is about 0.7 percent, **the Pomeroy's technique being the lowest 0.1–0.5 percent**, in contrast to the Madlener's, being 1.5–7 percent. The failure rate is increased when it is done during hysterotomy or during cesarean section. Failure rates of laparoscopic sterilization depend upon the individual method (electrocoagulation: unipolar 0.75%, bipolar 2.1%, Fallope ring 1.7%; Filshie clip 0.1percent). Failure may be due to **fistula formation or due to spontaneous reanastomosis**.

**Mortality following tubal sterilization** is estimated to be 72 per 100,000 for all methods. Laparoscopic procedures carried the mortality rate of 5–10 per 100,000 compared to 7 per 100,000 for puerperal ligations.

**Reversibility:** Informed consent must be obtained after **adequate counseling**. Couple must understand the permanency of the procedure, its occasional failure rate the risks and side effects and its alternatives. Unfortunately, regret is not uncommon. Microsurgical techniques give excellent result for tubal reanastomosis. Pregnancy rates after reversal are high (80 percent) following use of clips and rings. Reversal of vasectomy with restoration of vas patency is possible up to 90 percent of cases. But pregnancy rate is low (50 percent).

## CONTRACEPTIVE COUNSELING AND PRESCRIPTION

Pregnancy carries an overall maternal mortality around 400 per 100,000 total births in the developing countries and the same in the developed countries is less than 10. Whereas annual number of deaths per 100,000 exposed to pill is 1.3 and with that of IUDs is 1. The risks of death from automobile driving is 1 in 6000 per year. Contraception usually carries less risk compared to pregnancy. **Importantly benefits of contraceptive use outweigh the risks of pregnancy.**

No one single universally acceptable method has yet been discovered. The individual should have the liberty to choose any of the currently available well-tested method, which may even vary at each phase in her reproductive life. If one compares the risks and benefits of any contraceptive, it is observed that more deaths occur as a result of unplanned pregnancies than from the hazards of any modern contraceptive method (excluding "Pill" users over 35 who smoke).

**Important factors for the selection** of any contraceptive method for an individual are: relative safety, effectiveness, side effects and willingness to use the method correctly and consistently. The other factors to consider are the frequency of coitus, the need of lactation and prevention of STIs. Acceptability is probably the most critical factor in the effectiveness of a contraceptive method. Couple (client) should be helped to make an informed choice. A clear account of the risks and the benefits for an individual method is given. Regular follow-up and compliance with the instructions are to be ensured. It is also essential that an informed (verbal) consent is obtained and recorded.

**Sterilization counseling** includes a discussion of the following issues: (1) Desire of the individual partner (male/female). (2) Procedure selection.

(3) Failure rate. (4) Risks and side effects. (5) Issue of reversibility. Reversal is more likely to be successful after laparoscopic clips compared to laparotomy procedures. However, the risks of ectopic pregnancy is there. (6) Options for alternative long active (equally effective) reversible methods (Implants, CuT 380A) should be given.

**Prescription:** Conventional contraceptives can be safely prescribed during the entire reproductive period as elective choice or as an alternative to 'Pill' or IUD if they are contraindicated or unacceptable to the couple. As such only the advice regarding the use of 'Pill' or IUD during different phases of reproductive life is discussed.

**Adolescent girls:** Low dose combined pills are most effective for the sexually active adolescents. It is the contraceptive of choice. However, DMPA or norplant may be an alternative when accepted.

**Newly married couple:** Provided there is not enough justification to prove early fertility, a highly effective and acceptable contraceptive should be prescribed. IUD may not be prescribed. As such 'Pill' is recommended provided there is no contraindication. Apart from effective contraception 'Pill' has got many noncontraceptive benefits as well (p. 574).

### Spacing of Births

#### ◆ Postabortal ◆ Postpartum ◆ Interval

**Postabortal:** The contraceptive practice should be started soon following the abortion process is completed. 'Pill' is the ideal; IUD is an alternative.

#### **Postpartum:** • Nonlactating • Lactating

**Nonlactating**—Contraceptive practice should be started after 3 weeks. 'Pill' is good; IUD is an equally effective alternative. Injectable depomedroxy progesterone acetate could be used as it is devoid of any estrogen related side effects. Implanon (etonorgestrel) may be prescribed.

**Lactating**—In fully lactating women (5–6 feeds and spending about 60 minutes in 24 hours), the contraceptive practice may be safely withheld for 10 weeks postpartum. For doubtful adverse effects of steroids on lactation and on the babies through the ingested milk, **'Pill' is better withheld. Minipill or injectable steroids** is ideal. Alternatively, IUD can be inserted.

**Interval:** Below the age of 35, she can have her choice to either 'Pill' or IUD following adequate counseling. In women above the age of 35 especially who are smokers, IUD should be inserted in preference to 'Pill'. Injectables (DMPA) or implant (Implanon) where available is the other alternative.

**To stop future pregnancies:** The decision to advise permanent sterilization should be judiciously given especially to the under-privileged women in the face of high perinatal and infant mortality rate. The cases are to be individualized. However, a two-child formula is usually recommended and as such, a couple having two children who have been fully immunized can have permanent sterilization (husband or wife). If the couple is not motivated to undergo the sterilization operation, any of the temporary methods is to be prescribed till the end of the reproductive period of the wife. Women who have completed their family but do not desire for permanent sterilization, may use IUD (CU T 380A) or implant if accepted.

**Older women:** Contraception should be prescribed to avoid unplanned pregnancy. Low dose pills can be continued till menopause (with monitoring) in the low-risk group. Progestin only pill, injectable progestin, LNG-IUS are the other alternatives. Barrier methods and vaginal spermicides can be used either as a primary or back up method. Usually, fertility is reduced after 40 years of age.

**Women at risk of STIs** need dual protection against pregnancy and STIs. They should use condom with spermicides or use another contraceptive method in conjunction with condom.

**Women using enzyme inducers** are advised to take COCs having more than usual dosage (see p. 488) or other method of contraception (injectables, IUDs). **Emergency contraception (postcoital contraception)** when required as emergency, POP, IUD or other methods can be used (p. 492).

## ONGOING TRIALS AND SELECTIVE AVAILABILITY

The following are used on trial basis or are available in selected countries:

**Female:** ■ **Centchroman (SAHELI)**—*Ormeloxifene* is a research product of Central Drug Research Institute of Lucknow, India. It is a non-steroidal compound with potent anti-estrogenic and weak-estrogenic properties. It is taken orally (30 mg) twice a week for first 3 months then once a week. It works primarily by preventing implantation of fertilized ovum. It does not inhibit ovulation.

Side effects are few. It is avoided in polycystic ovarian disease, with liver and kidney diseases and in tuberculosis. There may be a tendency of oligomenorrhea. The failure rate is about 1–4 per 100 women years of use. Failure rate is less with increased doses. It is devoid of any significant adverse metabolic effect. This may also be used as an emergency contraceptive. It is sold in the market against prescription only and not over the counter.

**Non-contraceptive use:** Because of its potent anti-estrogenic activity, centchroman is being currently tried in the management of dysfunctional uterine bleeding, endometrial hyperplasia, endometriosis and breast cancer. It is used as hormone replacement therapy (HRT), because of its weak estrogenic property.

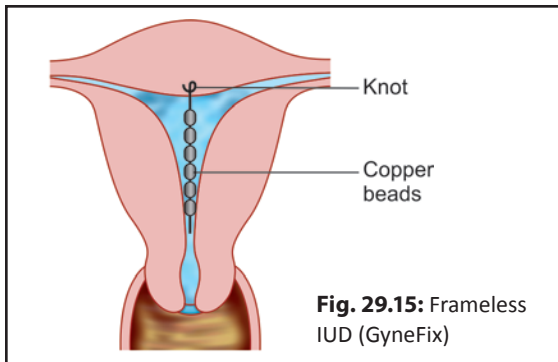
■ **Combined injectable contraceptives (CICs)**—Both estrogen and progestin are combined in these monthly injectables. Preparations available are: DMPA 25 mg with estradiol cypionate 5 mg (Cyclofem) and NET-EN 50 mg with estradiol valerate 5 mg (Mesigyna). Estrogen has been incorporated to improve the menstrual cycle. Use of “natural” estrogens in CICs has got favorable impact on lipid metabolism and cardiovascular effects compared to synthetic estrogen used injection COCs. It is given within first 5 days of menstruation. Next injection should be on the same date of each month (4 week schedule). Fertility return is quick.

**Drawbacks**—(i) Irregular or prolonged menstrual bleeding, (ii) Not suitable for nursing mothers.

■ **Transdermal patch : Nestorone (newer progestin)**—When used as a cream to the skin provides effective contraception. **Patch** delivers 150 µg of norelgestromin (progestin) and 20 µg ethinyl estradiol daily. It has an area of 20 cm<sup>2</sup> (4.5 × 4.5 cm). The patch is used weekly for 3 weeks and one week off for withdrawal bleeding. It is well-tolerated, safe and effective. **Drawbacks:** Patch detachment, skin reaction and high failure in overweight women (> 90 kg). It is applied over the buttocks, upper and outer arm, or lower abdomen but not over the breasts. Failure rate is 1.2 per 100 women years. Patch failure rate is high in woman weighing ≥ 90 kg.

■ **Vaginal ring**—Containing levonorgestrel covered by silastic tubing have been introduced. They are 5 and 6 cm in diameter. The vaginal ring delivers levonorgestrel (20 µg/day) to maintain a constant blood level like norplant. The rings are replaced by 90 days. Pregnancy rate is 3 per 100 woman years. This method is under woman’s control.

■ **Combined ring**—Soft, transparent ethylene vinyl ring (Nuva Ring) releases ethinyl estradiol (15 µg) and etonorgestrel (metabolite of desogestrel) 120 µg daily over a period of 21 days. The ring is inserted on the first day of menses and is worn for 3 weeks. The ring must be reinserted within the next 3 hours, if removed for any reason, vaginal route use avoids GI absorption, first pass liver metabolism and has lowest systemic estrogenic side effects. It is then removed and after 1 week (after the withdrawal bleed) a new ring is inserted. It acts by inhibiting ovulation. Pearl index is 0.65 and cycle control is good. The ring (54 mm diameter and 4 mm



thick) is inserted within 5 days of menses. Side effects are, headache, leucorrhea, vaginitis and expulsion.

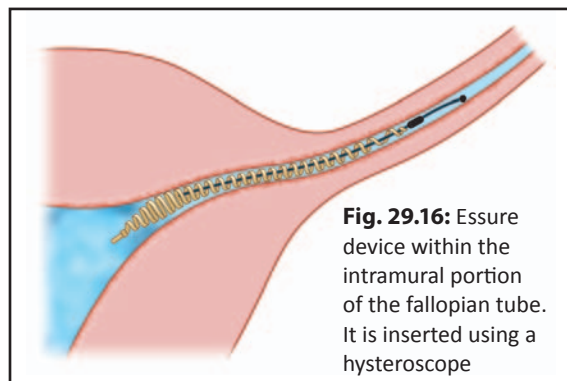
- **Uniplant** is a single rod implant, containing 55 mg of norgestrel (newer progestin) with a release rate of 100 µg per day. It provides contraception for one year.
- **Biodegradable implants** are under study. **Capronor** (single capsule) releases levonorgestrel from the polymer E-caprolactone at a rate 10 times faster than from silastic. The longer capsule contains 26 mg of levonorgestrel and inhibits ovulation in about 50 percent of cycles. Contraceptive efficacy is comparable to norplant. The capsule begins to disappear after 12 months.
- **Injectable contraceptive (biodegradable)** in the form of microspheres using Copolymer (Lactide-glycolide) have been studied. Hormone currently used in the microsphere (0.06 – 0.1 mm diameter) is either norethindrone or norethindrone combined with ethinyl estradiol. Injection is given over the gluteal muscle. Unlike implant, microspheres cannot be removed once injected.
- **LHRH** agonist (buserelin) and antagonist (cetorelix) acts by preventing the pituitary response to the endogenous GnRH. They have the potential to arrest follicular growth and endometrial development. Unwanted side effects (loss of libido and hot flushes) are avoided using add-back therapy. Long term effects are not known as yet.
- **Newer IUDs**—A **frameless IUD (GyneFix)** is made of six copper beads (330 mm<sup>2</sup> of Cu) on a monofilament polypropylene thread. The upper and lower beads are crimped onto the thread. The thread is knotted at one end which is embedded into the fundal myometrium to a depth of 1 cm. This anchors the device at the fundus. **The advantages** of the device (Fig. 29.15) over the framed ones are significantly reduced risk of expulsion, dysmenorrhea, bleeding and infection. Threadless

(Butterfly) IUD is also found promising to reduce the risk of side effects (infection). It can be removed with a hook when required. This device is especially suited for nulligravid women.

- **Fibro plant (LNG):** Similar to Mirena (see p. 480), a smaller version of Levonorgestrel system is currently being tested. Its small size is suitable for the perimenopausal women in whom the uterus shrinks. It releases LNG at the rate of 14 mcg/day. It is also used as a HRT for postmenopausal women.

#### ■ TRANSCERVICAL STERILIZATION

- ◆ **Quinacrine pellet**, 252 mg is inserted on two occasions one month apart into the uterine cavity transcervically through a hysteroscope during the proliferative phase. It is repeated in the next cycle. It acts as a sclerosing agent. Pregnancy rate is 2–3 per 100 woman years. Long term results are awaited.
- ◆ **Essure** is a 4 cm long, 2 mm diameter, microcoil (spring like device) made of nickel-titanium steel alloy coil within which lie polyethylene terephthalate fibers (Fig. 29.16). It is inserted into each fallopian tube transcervically using a hysteroscope. The tube is blocked permanently when scar tissue grows into the device. To ensure proper placement and total occlusion of assure a hysterosalpingogram is done three months after. Its success rate is similar to surgical sterilization (99.74%). For the first 3 months the woman needs to use a temporary contraceptive method in addition, till the scar tissue is formed.
- ◆ **Adiana** is a combined procedure. Controlled thermal damage to the proximal tubal epithelium is done by radiofrequency energy. The procedure is done through a hysteroscope. A soft silicane pellete (smaller than the grain of a rice) is implanted at the site to stimulate tissue





growth for permanent blockage. Hysterosalpingography is done after 3 months for confirmation. Failure rate is about 1.1 percent.

### Male contraception methods

**Testosterone** or a combination of testosterone and progestin (monthly injection or implant) is found to suppress sperm production. Testosterone undecanoate is used and found successful.

- ◆ **GnRH analogues** produce a decline in sperm density, sperm mobility and a decrease in testosterone level. The marked loss of libido makes it unacceptable.

Add-back therapy (testosterone) is used to overcome the side effects.

- ◆ **Gossypol:** It has been discovered in China; an extract from cotton seed. It acts directly on the seminiferous tubules inhibiting spermatogenesis. The side effects are: fatigue, decreased libido and delayed recovery of sperm count. The serious side effects are hypokalemic paralysis and cardiac arrhythmias.

**Intra Vas Device (IVD):** Two plugs are implanted in each vas to block sperm transport through the vas deferens. Plugs could be removed to make it a reversible procedure. Its contraceptive effectiveness is being studied.

## KEY POINTS

- **Barrier methods** of contraception include condom, diaphragm and vaginal contraceptives (chemicals and sponge today).
- **Natural contraception includes**—rhythm method, coitus interruptus and breastfeeding (p. 478).
- **Conventional contraceptive methods** include use of condom, vaginal diaphragm, spermicidals and rhythm method.
- **The introduction of IUD** is an OPD procedure without anesthesia taking full aseptic precautions. ‘No touch’ insertion technique is preferred (p. 481).
- **The contraindications** of insertion of IUD are nulliparity, PID, suspected pregnancy, DUB or suspicious cervix (p. 480). The pregnancy rate is about 0.5–2 HWY. There is risk of ectopic pregnancy 1–2 percent. Third generation IUDs have minimal side effects and lowest pregnancy rate (p. 484).  
**Immediate complications** include pain, syncopal attack and uterine perforation. **Remote complications** include—pain, abnormal uterine bleeding, pelvic infection, spontaneous expulsion or even perforation of the uterus (p. 482).
- Indications of **removal of IUD are**—excessive uterine bleeding, flaring up of pelvic infection, uterine perforation, pregnancy, missing thread and patient desirous of a baby (p. 484).
- Apart from contraception, the IUD is used as an interception and following synechiolysis.
- The **replacement time** for CuT 200 B is 4 years, multiload 250—3 years, CuT 380A—10 years, multiload 375—5 years and LNG–IUS is 5 years.
- LNG-IUS has got many **health benefits** (see p. 484). It is a very safe and effective method for prolonged use.
- **Combined oral contraceptives** are very reliable apart from their many other health benefits (see Page 488).
- **Absolute contraindications** of oral pills (p. 487), major side effects (p. 489) and indications of withdrawal of pills (p. 487) have been discussed.
- The **newer low dose pills** with more specific and “lipid friendly” progestins reduce the health risk further.
- **Drospirenone** containing COC is useful in treating PMS (p. 182), PMDD (p. 182). It should not be used in women with renal, adrenal or hepatic dysfunction.

Contd...

- A woman who does not smoke and has no other risk factor for cardiovascular disease, may continue the pill (with careful monitoring) until the age of 50.
- **Low dose progestin pill (mini pill)** is advantageous in lactating women, as it has got no adverse effect on breast milk. It can be used as a suitable alternative where estrogen is contraindicated (p. 491).
- **Overall safety of DMPA** is clearly greater than COC. Norplant and Implanon are safe and effective for long-term use. Both are considered as 'reversible sterilization' (p. 491).
- **Emergency contraception** includes hormones, IUD and antiprogesterone (RU-486). Within 72 hours, hormonal preparations are effective; within 5 days, IUD is effective and Ru 486 should be taken within day 27 of cycle irrespective of the day and number of intercourse (p. 492).
- **Centchroman** in a nonsteroidal antiestrogenic compound used as once a week contraceptive pill. It acts by preventing the implantation of the fertilized ovum (p. 501).
- A man is not sterilized immediately after vasectomy. As such, additional condom should be advised for at least 3 months (p. 495).
- **No scalpel vasectomy (NSV)** is done under local anesthetic making a tiny puncture over the stretched skin of the vas (p. 494). It has fewer complications. Both the NSV and scalpel vasectomy (SV) are safe.
- Globally, tubal sterilization is the most common method (20 percent) of contraception followed by IUDs (15%), oral contraceptives (8 percent) and condoms (5 percent).
- **Female sterilization** operation can be done during puerperium, in interval period or concurrent with MTP (p. 495). Hysteroscopic methods of sterilization include insertion of quinacrine pellet and Essure (microcoil), p. 502.
- Apart from conventional or mini-lap abdominal method, **laparoscopic sterilization** is very popular and effective (p. 498).
- Contraceptive prescription should be on an **individual basis**. In an individual, method may vary according to her phase of reproductive life. **Teenage girls, older women** and **sex workers** should also be protected (p. 500, 501).
- It is hard to predict contraceptive trends in the immediate future as the results of contraceptive research are still unclear about the risks and benefits.

# Radiotherapy, Chemotherapy, Immunotherapy and Genetherapy in Gynecology

## INTRODUCTION

Radiotherapy and chemotherapy are the important modalities of therapy for human cancers apart from surgery. Bias towards any particular one is unscientific. They may have a curative role (e.g. radiotherapy in carcinoma cervix and chemotherapy in gestational trophoblastic neoplasia) when used as a primary therapy. **Multidisciplinary approach** is needed for the treatment of some malignancies to improve the outcome. Radiotherapy and or chemotherapy should be considered even for palliation of incapacitating symptoms when cure may not be achieved. The basic principles of radiotherapy and chemotherapy in relation to gynecologic malignancies have been discussed in the chapter. Current understanding in immunotherapy and genetherapy have also been highlighted.

## RADIOTHERAPY

**Radiobiology of normal tissues:** The effects of radiation on tissues are generally of two types:

**A.** Loss of mature functional cells by apoptosis (programmed cell death). This usually occurs within 24 hours of radiation. **B.** Loss of cellular reproductive capacity. The severity depends upon the total dose of radiation, length of time over which radiotherapy is delivered and the radiosensitivity of the particular cell types. Usually lost cells are replaced by proliferation of surviving stem cells or progenitor cells.

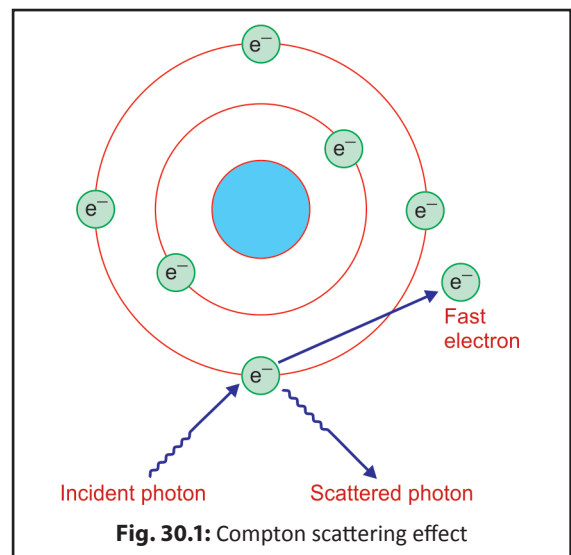
**Ionizing radiation used for therapy may be—**

(i) Electromagnetic radiation (ii) Particulate radiation.

**Electromagnetic radiation:** This consists of quanta of energy and wavelength (photon radiation). They are of two types—X-rays and gamma rays. These

electromagnetic waves travel in discrete bundles called 'Photons'.

- **Gamma rays** are produced spontaneously as a result of decay of the **atomic nucleus** of some radio-active isotopes.  $^{60}\text{Cobalt}$  or  $^{192}\text{Iridium}$  is a source of  $\gamma$ -rays.
- **X-rays** are produced **outside the atomic nucleus**. When fast-moving electrons approach the fields around the nuclei of atoms of a target material (tungsten), they are deflected from their path. The energy thus emitted in the form of electromagnetic radiation (photons) is X-rays. Machines such as betatron (circular fashion) and linear accelerator (linear fashion) can accelerate electrons with high kinetic energy. Therefore, X-rays generated by these machines are very high in energy.



**Fig. 30.1:** Compton scattering effect

- ◆ **X-rays and gamma rays** are collectively called photons. When photons interact with matter (tissue), three effects are observed: (i) photoelectric effect, (ii) Compton scattering and (iii) pair production. In human radiation therapy, **Compton scattering** is the major interaction of photons with tissue (see Fig. 30.1). X-rays and gamma rays have shorter wavelength and high frequency. They have high kinetic energy. X-rays and gamma rays possess considerable power of tissue penetration depending on the photon energy and the density of the matter through which they pass. The photon energy produced from radioactive cobalt is 1.2 million electron volts (MeV). External photon beam radiation is usually derived from a linear accelerator (p. 507).
- ◆ **Isotopes** are atoms of an element with same number of protons but different number of neutrons at its nuclear core. Isotopes are stable or unstable. Unstable isotopes try to attain stability by ejection of particles. This process often produces ionizing radiation with emission of alpha and beta particles and gamma rays.
- ◆ **Atoms** normally exist in neutral state. As such, the total number of positively charged particles at the nucleus (proton) and negatively charged particles at the orbit (electron) are equal.
- ◆ **Radioactive nuclei particles** give off alpha and beta particles and gamma rays.
- ◆ **Radium 226**, cesium 137, Gold 198, Iodine 125, Cobalt 60, Iridium 192 are used as radioactive sources for therapeutic purpose (Table 30.1).
- ◆ **Radioactive substances** are encapsulated to absorb alpha and beta particles leaving gamma rays to attain therapeutic purpose.
- ◆ **Oxygen enhancement ratio (OER):** The ratio of radiation dose required for a given level of cell killing under hypoxic condition compared with the dose needed in air.
- ◆ **Inverse square law:** Dose of radiation at a particular point varies inversely proportional to the square of the distance from the source of radiation.

**Particulate radiation:** This consists of atomic subparticles such as electrons, protons and neutrons. Only electrons ( $\beta$ -rays) are used in radiotherapy.

## TECHNIQUES OF RADIATION THERAPY

**BRACHYTHERAPY:** It gives a very high dose of radiation where the source of radiation is placed within, or close to the tumor. The application may be (i) Intracavitary (ii) Interstitial or (iii) Surface (skin). Damage to normal tissues is less as there is rapid fall-off of radiation around the source (inverse square law).

**Intracavitary:** The devices for brachytherapy consist of hollow stem (intrauterine tandem), which is placed within the uterine cavity (Fig. 30.2). Especially designed devices used for vaginal placements are called vaginal ovoids or colpostats.

TABLE 30.1

RADIOACTIVE ISOTOPES USED IN GYNECOLOGICAL MALIGNANCIES

Element isotope	Energy (MeV)	Half-life	Clinical use
Cesium 137 ( $^{137}\text{Cs}$ )	0.514	30 yrs	Intracavitary implants (temporary)
Radium 226 ( $^{226}\text{Ra}$ )	3.26	1600 yrs	Historical
Cobalt 60 ( $^{60}\text{Co}$ )	1.173	5.3 yrs	
Iridium 192 ( $^{192}\text{Ir}$ )	0.38	74.2 days	Interstitial implant (temporary)
Iodine 125 ( $^{125}\text{I}$ )	0.028	60.2 days	Interstitial implant (permanent)
Phosphorus 32 ( $^{32}\text{P}$ )	None	14.3 days	Intracavitary (permanent)

**Interstitial** form of brachytherapy consists of placement of radioactive sources (needles, wires or seeds) within the tissues. Commonly used sources are Iridium-192 ( $^{192}\text{Ir}$ ), Cesium-137 ( $^{137}\text{Cs}$ ) and Cobalt 60 ( $^{60}\text{Co}$ ). Small volume of tumor, as in early cases of vaginal carcinoma, can be treated with the method. Normal tissues are spared from radiation injury.

**Intraperitoneal** instillation ( $^{32}\text{P}$ ) is another mode of local therapy.

**After loading technique:** It is a modern development of brachytherapy to prevent radiation complications to the personnel. A mock insertion of applicators is performed and an X-ray is taken to note their exact

position. After loading technique may be manual or by remote control. Later on, live radioactive sources are introduced by remote control in identical manner. Remote after loading system uses Selectron ( $^{137}\text{Cs}$ ) or high dose Selectron ( $^{60}\text{Co}$ ). Remote control systems allow complete protection of staff from radiation exposure.

**Brachytherapy** can be either low dose rate (LDR) or a high dose rate (HDR) system. LDR require hospital admission and deliver dose at about 50-100 cGy/hour. HDR systems are commonly done as outpatient basis. The dose rate delivered is at 100 cGy/minute.

**Advantages:** (a) Localized high radiation dose to a small tumor volume with high local control. Radiation dose in the surrounding normal tissues is less as there is sharp fall-off according to inverse square law (see above).

**Disadvantages:** (a) Large tumors are usually unsuitable unless used following EBRT and/or chemotherapy. (b) Risks of exposure to medical and nursing personnel due to gamma rays.

### EXTERNAL BEAM RADIOTHERAPY (EBRT)

EBRT or teletherapy is the treatment with beams of ionizing radiation produced from a source external to the patient. Superficial tumors may be treated with X-rays of low energy in the range of 80-300 KV. Deeper-seated tumors are usually treated using mega-voltage photons.

Cobalt 60 is the common teletherapy source for EBRT, the other one is cesium 137. External radiation therapy is used to treat large volumes (tumor, lymph nodes, parametrium) of tumor (see p. 350). It is designed to deliver a uniform radiation dose to the tumor volume without 'hot' (excess dose) or 'cold' (under dose) spots. Accurate tumor localization and volume measurement are essential. Greater the tumor volume, higher the radiation dose required.

### INSTILLATION OF RADIOISOTOPES INTO THE PERITONEAL OR PLEURAL CAVITY

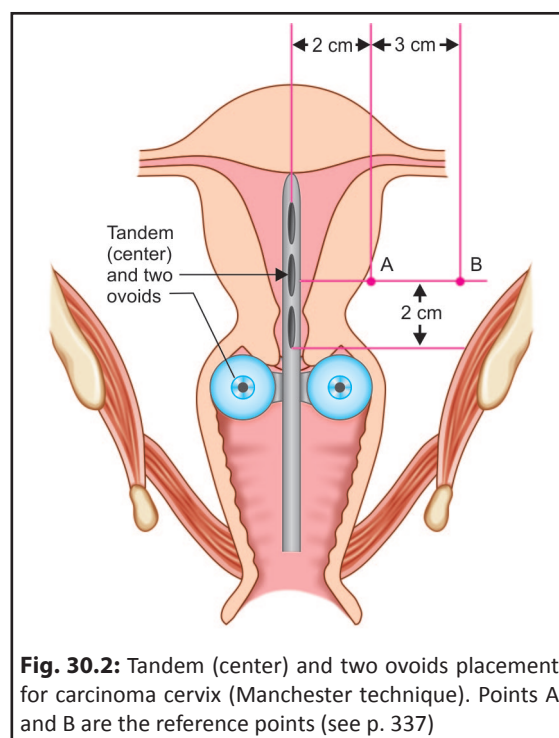
Radioactive isotopes of either gold or phosphorus, linked to carrier colloids, are commonly used in ovarian cancer. This can give radiation only to a depth of 4-8 mm. Radioactive chromic phosphate ( $^{32}\text{P}$ ) emits pure  $\beta$ -rays and has got longer half-life (14.3 days) and deeper penetration (8 mm) power compared

to radio gold ( $^{198}\text{Au}$ ). Small volume of tumor in the peritoneal or pleural cavity is treated with solution of radioisotopes.

**Palliative radiotherapy** is aimed to achieve quick symptom control. It may have little or no impact on the survival outcome of the patient. Lowest dose of therapy is preferred so that normal tissue damage is avoided.

### MEASUREMENT OF RADIATION

**Radiation absorption dose (Gray)** is the unit used to measure the amount of energy absorbed per unit mass of tissue. **One gray (Gy)** is equivalent to 1 Joule/kg which is equivalent to 100 rads. Currently, the term **centigray (cGy)** is used. One cGy is equivalent to one rad. Amount of radiation the patient receives is calculated by **dosimetry**. Homogeneous irradiation of tissues is desirable (Fig. 30.3). Primary tumor should receive high dose. Brachytherapy and teletherapy should be combined to provide adequate irradiation to the primary tumor as well as the pelvic lymph nodes and the parametrium (Fig. 30.2).



**Fig. 30.2:** Tandem (center) and two ovoids placement for carcinoma cervix (Manchester technique). Points A and B are the reference points (see p. 337)

## BIOLOGICAL EFFECTS OF RADIATION (RADIOBIOLOGY)

Radiation has got two modes of action:

- (1) **Direct action:** Where the radiation is absorbed, it causes damage to DNA directly. This is the predominant mechanism of action of particulate radiation (neutrons).
- (2) **Indirect action:** Where the radiation interact with other substances ( $H_2O$ ) in the cell to produce free radicals ( $OH^-$ ) which in turn damage the DNA.

Radiation, depending on the dose and time of exposure may cause (a) gene mutation (b) abnormal cell mitosis and (c) derangement of reproductive ability of the cell—"progeria".

Compton effect produces fast electrons (Fig. 30.1) by dislodging orbital electrons of tissues, through which they pass. This fast electron ionizes molecules along its path. There is production of free hydrogen atoms, free hydroxyl radicals and  $H_2O_2$ . These ionized molecules

react with proteins, enzymes and nucleic acids resulting in structural and functional alteration of a cell.

**The target for radiation injury** is DNA. Ultimately, there is limited cell mitosis and mitotic cell death. There is cytoplasmic vacuolation and fragmentation. Ionizing radiation also produces damage to nuclear and plasma membranes.

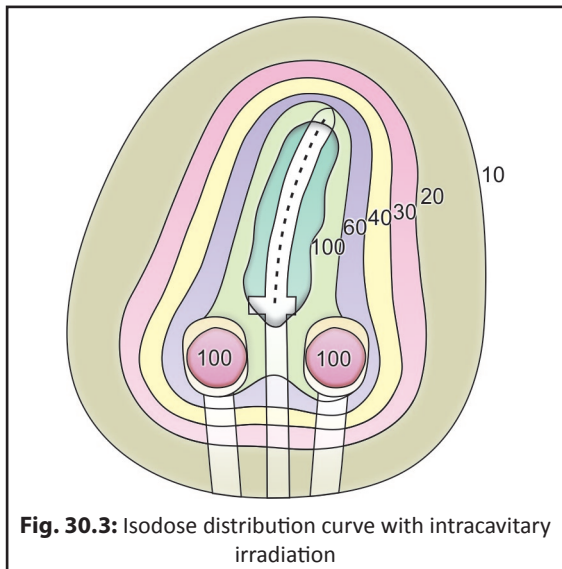
This **effect of ionizing radiation** is common for both the normal and neoplastic tissues, encountered in the radiation path. Radiation complications are mainly due to interaction with the normal tissues (Table 30.2). When the radiation effect to a cell is sublethal, cellular DNA may undergo repair and the cell survives. Lethal effect kills the cell.

### Radiation dose

According to the "**inverse square law**" there is reduction of radiation at a distance from the source in brachytherapy. This protects the normal tissues (see isodose distribution curve, Fig. 30.3).

**TABLE 30.2 RADIATION REACTIONS AND THEIR MANAGEMENT**

<b>Early:</b>	
Anorexia, nausea, vomiting, lassitude or even fever	♦ Antiemetics (see p. 519)     ♦ Antihistaminics
Diarrhea (radiation enteritis)	Intravenous fluid therapy to correct electrolyte imbalance
Leukopenia and thrombocytopenia, anemia	Hematinics, blood transfusion, G-CSF
Intestinal reaction such as enteritis, colitis, proctitis	Anti-spasmodics, analgesics, antidiarrheal agents
Urinary—cystitis, pyelitis, hematuria	Urinary antiseptics and analgesics
Skin reaction such as peeling often found in moist area of the vulva. This is almost absent in megavoltage radiotherapy	♦ To keep the area dry ♦ Application of 1 percent aqueous gentian violet
<b>Late (due to vasculitis and fibrosis):</b>	
Atrophic changes of vulval skin and vaginal stricture	Markedly minimized with megavoltage therapy
Radiation fibrosis	Often confused with recurrence of growth
Pathological fracture due to osteoporosis	Usual treatment for fracture. There is no problem in union
Intestine—stricture, bleeding per rectum, perforation, obstruction	Appropriate therapy
Malabsorption syndrome with megaloblastic anemia	Administration of folic acid
Proctosigmoiditis	Steroid enemas, antidiarrheal agents
<b>Fistula:</b>	
Vesicovaginal or rectovaginal Usually occurs 1-2 years following primary therapy	♦ Difficult to treat locally ♦ Colpocleisis may be an alternative
Ovary	Radiation damage, menopausal symptoms



**Fig. 30.3:** Isodose distribution curve with intracavitary irradiation

**A planning computer** calculates the field sizes, the dose from each field and the angles of the treatment machine. High energy machines spare the skin and deliver more radiation below the skin surface. Linear accelerators which deliver X-rays of 4-8 Mev are used currently. Treatment is carried out in a especially protected room. During the treatment time, the patient should be alone and she is supervised using a television camera. Safety precautions of radiation are maintained.

**Radiocurability** is the elimination of tumor at the primary or metastatic site due to a direct effect of radiation.

**Radiosensitivity** means the response of the tumor to irradiation. Radiosensitivity is measured in terms of loss of cellular proliferative capacity due to the damage to DNA. Accumulation of sublethal injury following repeat radiation leads to ultimate DNA damage and cell death. **Radiosensitivity depends on several factors:**

- ◆ **Tissue hypoxia**—higher the hypoxic fraction of cells, the less (2-3 times) is the radiation response. Hypoxic cells are more resistant to radiation compared to toxic cells.
- ◆ **Proportion of mitotic (clonogenic) cells**—clonogenic cells are more radiosensitive.
- ◆ **Cell cycle**—mitotic cells (M phase) and G2 cells are more radiosensitive compared to late S-phase cells (see Fig. 30.4).

- ◆ **Tumor specificity**—certain tumors (dysgerminomas) are more radiosensitive than the others.
- ◆ **Tumor volume**—smaller the tumor volume → lesser the hypoxic cells → less the radiation dose better the radiation response.

Lesser the photon wavelength more is the penetrating power and energy of ionizing radiation. Supervoltage and megavoltage radiation ( $^{60}\text{Co}$ ,  $^{137}\text{Cs}$ ,  $^{226}\text{Ra}$ , betatron, linear accelerator) have the following advantages over the orthovoltage one. They have higher energy of radiation, less skin injury, less lateral scattering and more tissue penetration at a greater depth. They are suitable for the deep seated tumors (e.g. carcinomas of the cervix and endometrium).

**Fractionation** is the division of a total dose of external beam radiotherapy into small (daily) doses. Thus it spares normal tissue damage preferentially. External beam radiotherapy is usually fractionated and is given once daily for five times a week. A dose of 180-220 cGy per fraction is used. This is based on the ability of the cells to accumulate and repair the sublethal injury. Tumor tissue takes longer time to recover from radiation damage compared to normal tissue. Fractionation allows **normal tissue** (intestinal mucosa, bone marrow) to repair sublethal injury (sparing effect). On the other hand irradiation results in accumulation of sublethal damage and ultimate loss of reproductive capacity in **tumor tissue**.

**Radiation dose prescription** should include the total dose, number of fractions with dose and time for each fraction (e.g. 40 Gy in 20 fractions given five times weekly can be given in 4 weeks at 2 Gy per fraction).

### ADVANCES IN RADIATION THERAPY

**High linear energy transfer:** X-rays and  $\gamma$ -rays are less effective against hypoxic cells compared to oxygenated cells. **Fast neutrons** or negative  $\pi$  mesons (pions) or protons are very effective against the hypoxic cells. **Fast neutron** beam for radiotherapy are generated by the cyclotron and the D-T generator. The neutron is emitted with an energy of 14-16 Mev.

**Negative  $\pi$  mesons** (pions) with energies between 40 and 70 Mev have a depth range in tissue of about 6-13 cm. It has high biologic effectiveness and a low dependance on oxygen.

**Electron beam:** High energy electron beams are produced by many linear accelerators. Electrons lose energy rapidly

as they travel in tissues. It has limited tissue penetration. Transcervical electron irradiation can be used for control of hemorrhage in cases with bleeding cervical carcinoma.

**Photons** have suitable tissue penetration property and can be used for deep seated cancers. It has skin sparing effect. Beam characteristics facilitate beam matching and crossfire treatment plans.

## RADIOPOTENTIATORS AND HYPOXIC CELL SENSITIZERS

Compared to well-oxygenated cells, hypoxic cells require about three times the radiation dose, to obtain the same proportion of cell kill. Hypoxic cell can be sensitized to ionizing radiation to improve the **Oxygen Enhancement Ratio (OER)** by different chemical compounds.

Number of chemotherapeutic agents have been found to potentiate the radiation effect and also to sensitize the hypoxic cells (Table 30.3). Exact mechanism is not well-understood. Use of hyperbaric oxygen to increase radiosensitivity is of doubtful benefit. Moreover this technique is cumbersome.

Chemotherapeutic agents	Others
♦ Cisplatin	• Misonidazole
♦ Paclitaxel	• Metronidazole
♦ Gemcitabine	• Tumor necrosis factor (TNF)
♦ Doxorubicin	• Interferon • Acyclovir

**Intraoperative radiation** of large fraction of 1500-2500 cGy are delivered directly to the area selected. Periaortic node irradiation (biopsy proven) at the time of staging laparotomy is possible.

**Hyperthermia** is found helpful as an active anti-neoplastic agent and a significant radiosensitizer.

## NEW TECHNOLOGY FOR RADIATION THERAPY

**Three-dimensional conformal radiation therapy (3D CRT)** uses imaging modalities (CT, MRI and PET scanning). Beam placement using a CT simulation is used. 3D conformal therapy can shape the beam to conform to the target. This can help to arrange the

beams to maximize dose to the tumor and minimize dose to normal tissues.

**Intensity modulated radiation therapy (IMRT):** IMRT uses the power of computers to shape and perform thousands of iterations of planning to maximize the tumor dose and to minimize normal tissue dose. Both 3D CRT and IMRT use small collimator “leaves” to shape the beam finely. These “leaves” are mobile and can vary the beam intensity. It allows irregular shapes (tumor) to be treated and has the benefit of reduced radiation to normal tissues (bowel, bladder).

Tomotherapy and cone-beam CT may allow more precise localization of beam and verification of dose delivered.

**Stereotactic radiotherapy** and Gamma-Knife radiation are similar to IMRT and 3D CRT to allow precise high dose delivery of external radiation. Stereotactic radiation uses a modification of linear accelerator.

## TREATMENT FIELD FOR CARCINOMA CERVIX

**Superior border**—between L<sub>4</sub> and L<sub>5</sub> to include the common iliac nodes. **Inferior border**—at the inferior margin of obturator foramen to include the obturator nodes. **Lateral borders**—1 cm lateral to the margins of the bony pelvis.

**Lead compensators** are used in the path of external beam radiation to prevent overdose to the central portion of the pelvis, which has received high dosage from brachytherapy.

## RADIOTHERAPY IN EPITHELIAL OVARIAN CARCINOMA

Role of postoperative radiotherapy in the management of epithelial ovarian carcinoma is no longer favored. Chemotherapy has replaced radiotherapy both for the management of early and advanced disease. However it may be used in the following cases who fail to respond with chemotherapy.

- (i) Metastatic deposits over the peritoneal surfaces.
- (ii) Lymph node metastasis.
- (iii) Palliation for painful recurrences in the pelvis or bone.

**Moving strip technique** is used to irradiate whole of abdomen. Presence of residual disease following debulking procedures in a case of ovarian carcinoma is treated with this technique. Whole abdomen is divided into contiguous strips of 2.5 cm wide area. Each strip is irradiated from front and back over 2 days and the field is gradually moved up.



Cobalt 60 machine is generally used and a total tumor dose of 2600 to 2800 cGy is delivered. Pelvic boost of 2000 to 3000 cGy is given additionally. Kidneys and right lobe of liver are shielded with lead to reduce the dose to these organs. **Bulky residual disease (> 2 cm) is not suitable for radiotherapy.**

Use of radiotherapy for individual organ malignancy—see respective chapters.

**Radiation reactions and their management**—see Table 30.2. **Contraindications of radiotherapy**—see page 348.

## CHEMOTHERAPY

### GENERAL CONSIDERATIONS

Mustard gas used in World War I, was found to have tremendous effect on bone marrow suppression. This led to the concept of cytotoxic chemotherapy in the treatment of human cancer.

Use of cytotoxic chemotherapy has got the following objectives:

- ▶ Complete remission of the tumor
- ▶ Partial remission (30 percent) with improvement of median survival
- ▶ To prevent recurrence of the tumor
- ▶ To alleviate the symptoms, so as to improve the quality of life (palliation).

Effective chemotherapy is designed to kill selectively the malignant cells without producing serious

irreversible harm to normal cells. The substances as yet available, damage both cancerous and normal tissues but in contradistinction to normal tissues, cancerous tissues cannot recover from the insult.

## CELL KINETICS

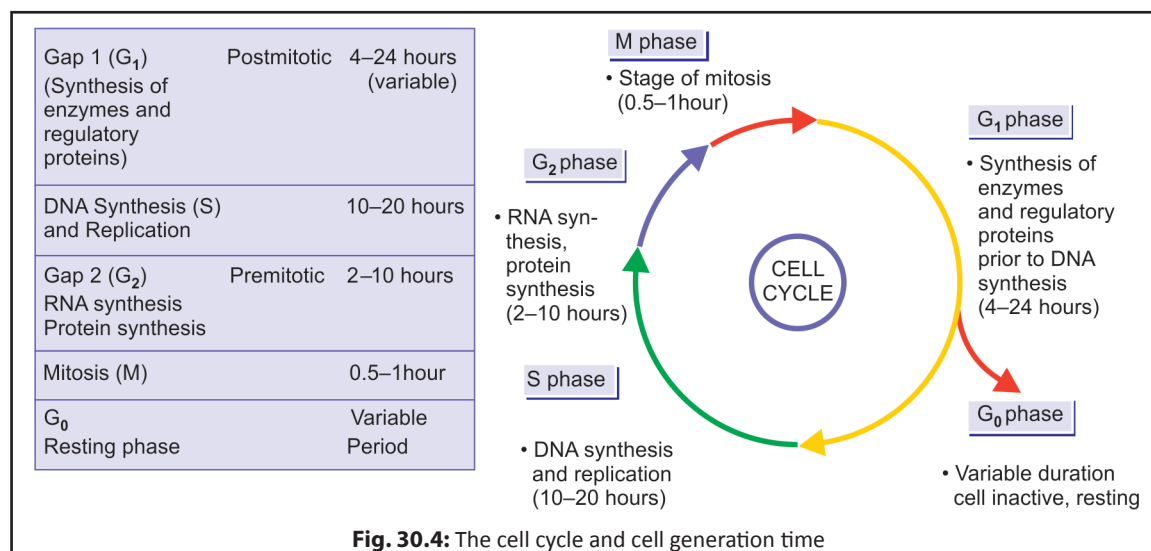
**Cell cycle time** denotes the amount of time needed by a proliferating cell to progress through the cell cycle and produce a new daughter cell. Cell cycle times vary widely (12-217 hours) but are relatively constant for a specific tumor type.

**Normal cells** have the inherent capacity to multiply and this is controlled by various internal and external forces. There is also constant and balanced cell loss. Normal cells may be classified as:

- ▶ **Proliferating cells** (bone marrow, intestinal mucosa)—undergo constant cell division.
- ▶ **Quiescent cells** (liver)—can proliferate under special conditions (injury), otherwise they are in quiescent phase.
- ▶ **Static cells** (neurons)—rarely proliferate.

**Cancer cells** undergo uncontrolled and excessive proliferation compared to cell loss. Speed of cell division is the same compared to a normal cell.

**Doubling time** of human tumor is defined as the time taken by a tumor mass to double its size. Doubling time varies depending upon the specific type of the tumor. Tumor growth depends on growth fraction and



**Fig. 30.4:** The cell cycle and cell generation time

cell death. **Growth fraction** is the number of cells in the tumor mass that are actively involved in the phase of cell division.

**Gompertzian growth** states that when a tumor volume increases in size, its mass doubling time becomes progressively longer.

**Cell cycle:** There are four phases of cell cycle. These are  $G_1$ , S,  $G_2$  and M (Fig. 30.4). The duration of the cycle from M phase to M phase is called **generation time**. Tumor cells do not have faster generation time. Normal tissues have huge number of cells in the  $G_0$  phase (out of cycle), in contrast to tumor cells, where more cells are in the active phase of cell division.

Cell cycle concept is very important for cancer chemotherapy. Dividing tumor cells are most sensitive to cytotoxic agents whereas cells in the  $G_0$  are relatively insensitive (Fig. 30.4).

**VARIETIES OF MALIGNANCY:** The credibility of the use of cancerolytic drugs depends upon the fact that in all malignancies, dissemination occurs at some stage of the disease and local treatment may not suffice. Proper understanding of cell cycle has evolved legitimate synergistic combinations of drugs with better cancer killing potentialities and less side effects (Fig. 30.3).

**Broadly speaking, chemotherapeutic drugs are of two varieties** depending on the basis of their cell cycle specificity (Fig. 30.4):

(a) Cell cycle specific agents which act on proliferating cells only (Table 30.4).

(b) Cell cycle non-specific agents which destroy both resting and cycling cells (Table 30.4).

It is observed that antitumor agents kill a **constant fraction** of cells (rather than a constant number) with each course of therapy. This is called **log kill hypothesis**. Intermittent courses of therapy are found useful to destroy more tumor cells. With this concept of cellular kinetics combination chemotherapy has been initiated.

## PRINCIPLES

- Rapidly growing tumors are more amenable than slow growing tumors.
- A constant fraction of neoplastic cells are killed with each dose of cytotoxic drug.
- Effect of drugs depends on:
  - ◆ Tumor mass and growth rate.
  - ◆ Sensitivity of resting phase cells.
  - ◆ Immunocompetence of host cells.
  - ◆ Type and dose schedule of agents.

**TABLE 30.4 DRUG ACTIVITY IN THE CELL CYCLE**

Cell cycle	Non-specific	Cyclophosphamide, Cisplatin, Carboplatin
Cell cycle	Specific:	
	On $G_1$	Actinomycin D
	On S phase	Methotrexate 5 FU Doxorubicin
	On $G_2$	Bleomycin, Etoposide
	On M phase	Vinblastine, Vincristine Taxanes
$G_0$		Nitrosoureas (BCNU, CCNU)

- High dose intermittent course of chemotherapy may result in high cell kill and optimal destruction of the tumor (dose intensity).
- Combination agent chemotherapy is superior to single agent therapy for the treatment of most malignancies.
- Drugs combined, should have synergistic effect, different mechanism of action and different spectrum of toxicity. This will enhance the tumor cell kill and minimize the risk of drug resistance.
- Drug dose is adjusted according to the tolerance of the patient. Before starting any chemotherapy, pretreatment evaluation should be done (see p. 514).

## SINGLE AGENT VERSUS COMBINATION AGENTS

- ◆ Combined chemotherapeutic agents attack different phases of cell cycle (synergistic effect), so reduces the tumor volume effectively.
- ◆ Use of combination (cell cycle specific and cell cycle non-specific) chemotherapy enhances tumor cell kill compared to single drug therapy.

- ◆ Because of toxicity, drug dose and duration of therapy cannot be increased when single agent chemotherapy is used.
- ◆ Emergence of drug resistance is more with single agent therapy.

### Combination chemotherapy

The following principles are to be maintained in selecting the combination of drugs:

- All drugs in the combination should have shown activity as single agents.
- Cell cycle specificity of the drugs should differ.
- Drugs with different mechanisms should be combined rather than drugs with similar action.

#### MECHANISMS OF DRUG RESISTANCE

- (i) Increased repair of DNA
- (ii) Decrease in cellular drug uptake
- (iii) Increased level of target enzyme to make the cell immune to the drug
- (iv) Increase in drug degradation
- (v) Spontaneous tumor cell mutations

### CLASSIFICATION OF CYTOTOXIC DRUGS

Classification is based principally on structural similarity and mechanism of action:

- A. Alkylating agents:** These drugs transfer their alkyl radical to nucleic acids. **They prevent cell division by cross-linking the DNA strands. They produce single and double stranded DNA break.** Cyclophosphamide inhibits DNA synthesis in addition. These are cell cycle non-specific agents (CCNS). These are most suitable for use in bulky slow growing tumors. These are often called radiomimetic drugs as they share some effects of radiation.

#### Examples:

Cyclophosphamide (endoxan), Ifosfamide, Melphalan, Thiotepa.

**Platinum agents:** Cisplatin, carboplatin, oxaliplatin.

- B. Antimetabolites** act by inhibiting essential metabolic processes that are required for synthesis of purines, pyrimidines and nucleic acids.

#### Examples:

- ◆ Methotrexate—Folic acid antagonist, prevents reduction of folic acid to folinic acid by inhibiting the enzyme dihydrofolate reductase.
- ◆ 5-Fluorouracil—Pyrimidine analogue, blocks thymidine synthesis and prevents DNA replication.
- ◆ 6-Mercaptopurine—Purine derivatives—competitive attachment to enzymatic catalytic site.
- ◆ **Gemcitabine** (2', 2' – fluorodeoxy cytabidine) is a new agent used against ovarian, breast and cervical carcinoma.

- C. Antibiotics:** These are cell cycle non-specific agents. They prevent DNA replication, causes single and double stranded DNA break, e.g. actinomycin D, bleomycin, doxorubicin, mitomycin C.

- D. Plant Derivatives and Taxanes:** These are cell cycle specific agents. They act as spindle poison and cause arrest of mitosis at metaphase. Vincristine and vinblastin (from plant *Vinca rosea*).

**Taxanes** are obtained from the bark of pacific yew tree (*Taxus brevifolia*). Important members of this group are paclitaxel (taxol) and docetaxol (synthetic). **Taxanes** act to disturb the normal assembly, disassembly and stabilization of microtubules. **The camptothecin analogs** (topotecan and irinotecan) inhibit topoisomerase-1, thereby causes single stranded DNA break.

**Other plant derivatives:** Etoposide.

- E. Hormones:** The drugs induce regression of a hormone responsive tumor and also increase anabolic processes.

**Progesterone** preparations, e.g. hydroxyprogesterone caproate, medroxyprogesterone acetate, megestrol acetate.

**Antiestrogen**—tamoxifen acts by competitive receptor binding—thus helpful in estrogen dependent tumors.

**F. Miscellaneous:**

- ◆ Hexamethylamine—acts like antimetabolite.
- ◆ Hydroxyurea—increases radiosensitivity of malignant tissue.

**G. Biological:** Interferon, Müllerian inhibiting factor—they act by improving the host immune defense.

**TOXICITY:** The toxic reactions depend on the type of drug used, the method of administration, its dosage and general condition of the patient. The toxic reactions are tabulated in Table 30.5.

**ROUTE OF ADMINISTRATION**

**Oral:** Alkylating drugs are mainly used orally. The intermittent therapy allows recovery of normal cells.

**Parenteral:** Administration (intravenous – commonly, intra-arterial) at interval of 1-4 weeks allows bone marrow to recover.

**Intraperitoneal:** Systemic administration is more effective. Drug penetration will be only 3-6 cells deep.

**Objectives of chemotherapy:** (i) as a primary treatment of cancer, (ii) as an adjunct to radiation therapy, (iii) as a neoadjuvant therapy, used for advanced disease following which additional treatment is planned, (iv) by direct instillation (intrapentoneal chemotherapy).

**Means to Assess the Response of Chemotherapy:** (i) clinical and physical examination, (ii) assessing by imaging studies, e.g. CT or MRI, (iii) serial measurement of specific tumor markers (i.e. CA 125 for epithelial ovarian cancer,  $\beta$ -hCG for GTN), (iv) detection of hyper metabolic state by PET (p. 119).

**Response evaluation criteria in solid tumors:** (i) CR (complete response): Disappearance of all target lesions. (ii) PR (partial response): 30 percent decrease in greatest diameter of tumor. (iii) PD (progressive disease): 20 percent increase in greatest diameter of tumor. (iv) SD (stable disease): Small change that do not meet the above criteria.

**PRETREATMENT EVALUATION:** Chemotherapeutic agents are highly toxic to the erythropoietic system, bone marrow in particular. The drugs are mostly metabolized in the liver and are excreted through the kidneys. The patients are also immunocompromised and as such, any source of infection is to be treated.

**Pretreatment evaluation of all the important organ function is of paramount importance.**

- Hematological—complete hemogram and platelet count ( $> 100,000$ ).
- Serum—electrolytes.
- Renal functions—serum urea, uric acid, creatinine and creatinine clearance (especially when cisplatin is used).
- Liver functions—serum proteins, liver enzymes, bilirubin.
- Cardiac function—baseline ECG and ventricular ejection fraction when cardiotoxic drug (doxorubicin) is used.
- Pulmonary function—when bleomycin is used.
- Throat swab, urine for culture and sensitivity.

**CALCULATION OF DOSE:** The dose of a chemotherapeutic agent is usually calculated as square meter of body surface area. It provides a better measure of potential toxicity than body weight. **The surface area closely reflects cardiac output and blood flow.** There is minimal change of surface area during entire course of therapy compared to body weight. Nomogram is used for calculating body surface area of adults (p. 665).

**USE OF DRUGS:** A schematic presentation of commonly used chemotherapy agents, type of neoplasm their average dosage, route of therapy, toxicity and precaution of use is made in Table 30.5, 30.6 and 30.7. It should be noted that this schedule is flexible and treatment must be individualized according to patient.

It is imperative that all cases undergoing chemotherapy should be monitored. This process should include recognition of evidences of retrogression of the disease by changes in clinical, biophysical and biochemical markers. Hematological profile must be checked at regular intervals (see above). The systemic changes should reach just short of irreversible toxicity for optimum benefit. **Minor complications like nausea, vomiting, alopecia, glossitis should not preclude full treatment protocol.** The benefits are to be weighed against toxic effects. Explaining the situation clearly helps in patient compliance and improves ultimate result.

**TABLE 30.5 TOXIC EFFECTS OF THE CYTOTOXIC DRUGS AND THEIR MANAGEMENT**

Tissue or organ affected	Toxic effects and drugs	Management
Gastrointestinal	Nausea, vomiting, oral ulceration, stomatitis, necrotizing enterocolitis, diarrhea (cisplatin, methotrexate, paclitaxel, docetaxel, etoposide)	Antiemetics used for emetogenic chemotherapy <ul style="list-style-type: none"> <li>• Dexamethasone 20 mg IV</li> <li>• Ondansetron 8 mg IV every 4 hours 2–3 doses</li> <li>• Metoclopramide 80–120 mg IV every 3–4 hours</li> </ul>
Hair roots	Alopecia (paclitaxel, cyclophosphamide)	Generally reversible
Hematological (bone-marrow)	Anemia, granulocytopenia, thrombocytopenia. The danger level being: Hb percent < 8 gm percent, leukocyte count < 3,000/cumm and platelet count < 20,000/cumm (paclitaxel, etoposide, carboplatin)	Blood transfusion, platelet transfusion, drug dose may be modified. Granulocyte Colony-stimulating factor (G-CSF) and granulocyte macrophase colony-stimulating factor (GM-CSF) have been used (250 µg/M <sup>2</sup> , subcutaneously) for myelostimulation
Skin	Dermatitis, pigmentation (bleomycin), extravasation, skin necrosis (actinomycin D, doxorubicin)	For extravasation and skin necrosis—removal of intravenous line, local infiltration of corticosteroids, ice pack therapy
Cardiac	Cardiomyopathy, arrhythmias, endocardial fibrosis (doxorubicin, cyclophosphamide), Toxic myocarditis (Paclitaxel)	Discontinuation of drug, drug and dose modification, to consult cardiologist
Liver	Hepatitis, elevated transaminases and bilirubin (Methotrexate)	Discontinuation of drug, drug and dose modification
Lungs	Fibrosis (Bleomycin, alkylating agents doxorubicin)	Pulmonary function tests, to stop therapy, steroids may be helpful
Nervous system	Neurotoxicity, ototoxicity, peripheral neuropathy (Cisplatin, Ifosfamide)	Vitamin B complex, pyridoxine therapy, drug and dose modification
Urinary system	Renal failure, azotemia (Cisplatin), hemorrhagic cystitis (Cyclophosphamide, Ifosfamide), red urine (doxorubicin)	Prehydration and mannitol induced diuresis before therapy, avoid simultaneous use of nephrotoxic drugs (aminoglycosides). <b>Mesna</b> is used for hemorrhagic cystitis due to cyclophosphamide or ifosfamide
Immune system	Suppression of cellular and humoral immunity, loss of host defense mechanism	Usually reversible
Metabolic	Hyperkalemia, hyperuricemia, hypocalcemia — due to rapid tumor lysis. Hyponatremia — due to inappropriate ADH secretion	Estimation of serum electrolytes and appropriate correction
Surgical wound	Delayed healing	
Gonads	Infertility, amenorrhea, premature ovarian failure	Patient counseling.
Embryo	Teratogenic effect, congenital malformations	Patient counseling, to assess risk and benefit
Second malignancies	Due to mutagenic effect – leukemia (melphalan)	

TABLE 30.6 : COMMONLY USED CHEMOTHERAPEUTIC AGENTS, USE, TOXICITY AND PRECAUTIONS

Drugs	Dosage and route of therapy	Type of neoplasm	Toxicity (important)	Precaution
<ul style="list-style-type: none"> <li>■ <b>Alkylating agent</b></li> <li>◆ Cyclophosphamide (Endoxan)</li> </ul>	750–1,000 mg/M <sup>2</sup> of body surface/IV. Single dose every 3 weeks 50–110 mg/M <sup>2</sup> by mouth (PO)	<ul style="list-style-type: none"> <li>■ <b>Carcinoma</b></li> <li>• Ovary</li> <li>• Endometrium</li> <li>• Cervix</li> <li>• Fallopian tube</li> </ul>	Bone marrow depression (BD) alopecia, cystitis	Adequate fluid intake
◆ Ifosfamide (Ifex)	7–10 gm/M <sup>2</sup> IV over 3–5 days, to be repeated every 3–4 weeks	<ul style="list-style-type: none"> <li>■ <b>Carcinoma and sarcoma of</b></li> <li>• Ovary</li> <li>• Cervix</li> <li>• Endometrium</li> </ul>	BD, alopecia, cystitis	Uroprotectant (mesna p.....)
<ul style="list-style-type: none"> <li>◆ Cisplatin (cis-diamine dichloroplatinum)</li> <li>◆ Carboplatin</li> </ul>	50–75 mg/M <sup>2</sup> IV every 1–3 weeks —usually 4–6 such 300–400 mg/M <sup>2</sup> IV. Repeat every 3–4 weeks for 6 courses	<ul style="list-style-type: none"> <li>• Ovary</li> <li>• Endometrium</li> <li>• Cervix</li> </ul>	Nephrotoxicity, neurotoxicity, myelosuppression, thrombocytopenia	Adequate prehydration, monitor renal function
◆ Oxaliplatin	59–130 mg/M <sup>2</sup> IV over 2 hours, every 3 weeks	• Ovary	Myelosuppression, peripheral neuropathy	Contraindicated in hepatic and renal dysfunction
◆ Melphalan (Alkeran)	0.2 mg/kg/day orally × 5 days. Repeat after 4–6 weeks	<ul style="list-style-type: none"> <li>• Cervix</li> <li>• Ovary</li> <li>• Endometrium</li> <li>• Fallopian tube</li> </ul>	BD	—
◆ Chlorambucil (Leukeran)	0.1–0.2 mg/kg of body weight orally/day for 4–6 weeks	<ul style="list-style-type: none"> <li>• Cervix</li> <li>• Ovary</li> <li>• Endometrium</li> <li>• Fallopian tube</li> </ul>	BD	Adequate fluid intake
<ul style="list-style-type: none"> <li>■ <b>Antimetabolites</b></li> <li>◆ Methotrexate</li> </ul>	10–30 mg/day PO × 5 days 240 mg/M <sup>2</sup> IV with leucovorin rescue	<ul style="list-style-type: none"> <li>■ <b>Choriocarcinoma</b></li> <li>■ <b>Carcinoma</b></li> <li>• Ovary</li> <li>• Cervix</li> </ul>	BD, megaloblastic anemia, stomatitis, vomiting, alopecia, hepatic/pulmonary fibrosis	Adequate renal function and urine output to maintain
◆ 5-Fluorouracil (5-Fu)	10–15 mg/kg/day IV × 5 days. Repeat after 3–4 weeks. 10–15 mg/kg IV weekly, maximum up to 1 gram	<ul style="list-style-type: none"> <li>■ <b>Carcinoma</b></li> <li>• Ovary</li> <li>• Endometrium</li> </ul>	BMD, diarrhea, stomatitis, alopecia	Dose reduction with compromised renal, hepatic or bone marrow function
◆ Gemcitabine	800–1000 mg/M <sup>2</sup> IV weekly every 3 weeks	<ul style="list-style-type: none"> <li>■ <b>Carcinoma</b></li> <li>• Breast</li> <li>• Ovary</li> <li>• Leiomyosarcoma of uterus</li> </ul>	Myelosuppression	None

Contd...

TABLE 30.6 : COMMONLY USED CHEMOTHERAPEUTIC AGENTS, USE, TOXICITY AND PRECAUTIONS

Drugs	Dosage and route of therapy	Type of neoplasm	Toxicity	Precaution
<ul style="list-style-type: none"> <li>■ <b>Antibiotics</b></li> <li>◆ Actinomycin D</li> </ul>	0.5 mg/M <sup>2</sup> /IV/weekly, repeat 3–4 weeks or 0.5 mg/M <sup>2</sup> /IV daily × 5 days 15 mcg/kg/day IV or 0.5 mg/day for 5 days	<ul style="list-style-type: none"> <li>• Embryonal rhabdomyosarcoma, choriocarcinoma, ovarian germ cell tumors.</li> <li>• Cancer cervix</li> </ul>	BD, stomatitis; hyperpigmentation in areas of irradiation	Dose adjustment in liver disease and ↓ bone marrow function
◆ Mitomycin C	8 mg/M <sup>2</sup> /IV every 3 weeks.	• Cancer cervix	Neutropenia, thrombocytopenia, oral ulceration	Prevention of extravasation
◆ Doxorubicin (Adriamycin)	50 mg/M <sup>2</sup> /IV weekly. Repeat every 3–4 weeks	<ul style="list-style-type: none"> <li>■ Adenocarcinoma</li> <li>• Endometrium</li> <li>• Ovary</li> <li>• Vagina</li> <li>• Tube</li> <li>■ Uterine Sarcoma</li> </ul>	BD, alopecia, cardiac toxicity myopathy, stomatitis	Avoid in significant heart disease, ECG monitoring
◆ Bleomycin	10–12 mg/M <sup>2</sup> /IV/IM weekly	<ul style="list-style-type: none"> <li>• Squamous cell cancer of skin, vulva, cervix</li> <li>• Choriocarcinoma, germ cell and sex cord stromal tumors of ovary</li> </ul>	<b>Skin:</b> Hyperpigmentation, ulceration, alopecia. <b>Pulmonary:</b> Pneumonitis, fibrosis, dyspnea	Avoid in renal or pulmonary disease
<ul style="list-style-type: none"> <li>■ <b>Plant derived</b></li> <li>◆ Vincristine (Oncovin)</li> <li>◆ Vinblastine (Velban)</li> <li>◆ Etoposide (Etopodophyllotoxin)</li> </ul>	0.4–1.4 mg/M <sup>2</sup> IV weekly  5–6 mg/M <sup>2</sup> IV every 1–2 weeks  100 mg/M <sup>2</sup> IV on days — 1, 3 and 5 repeat every 3–4 weeks	<ul style="list-style-type: none"> <li>• Uterine sarcoma</li> <li>• Ovarian germ cell tumor</li> <li>• Choriocarcinoma</li> <li>• GTN</li> <li>• Germ cell tumors</li> </ul>	Paresthesia, weakness, loss of reflexes, foot drop, BMD, reticulocytopenia, alopecia, hoarseness, anemia BD, neutropenia, alopecia, peripheral neuropathy depression, weakness Leukopenia, thrombocytopenia, alopecia, headache, fever	Avoid extravasation, dose adjustment with liver disease Avoid extravasation, dose adjustment with liver disease Dose reduction up to 50 percent to prevent toxicity
<ul style="list-style-type: none"> <li>■ <b>Taxanes</b></li> <li>◆ Paclitaxel (taxol)</li> <li>◆ Docetaxel</li> </ul>	135–250 mg/M <sup>2</sup> IV over 3 hours every 3–4 weeks 60–100 mg/M <sup>2</sup> IV over 1 hour every 3–4 weeks	<ul style="list-style-type: none"> <li>■ Carcinoma</li> <li>• Ovary</li> <li>• Endometrium</li> <li>• Cervix</li> <li>■ Ovarian carcinoma</li> </ul>	BD, dyspnea, hypotension, cardiotoxicity, alopecia, stomatitis Myelosuppression, mucositis, alopecia	Cardiac monitoring Premedication with steroids
<ul style="list-style-type: none"> <li>■ <b>Camptothecin analogues</b></li> <li>◆ Topotecan</li> </ul>	1.5 mg/M <sup>2</sup> IV/day for 5 days; 4 mg/M <sup>2</sup> IV on D1, D8 every 3 weeks	<ul style="list-style-type: none"> <li>• Ovary</li> <li>• Cervix</li> </ul>	BD	To guard against neutropenia

**TABLE 30.6 OTHER CHEMOTHERAPEUTIC AGENTS: USE, TOXICITY AND PRECAUTIONS**

- **Hormones**
  - ◆ 17- $\alpha$ -Hydroxyprogesterone caproate (1 g IM twice a week for 1 year).
  - ◆ Medroxyprogesterone acetate (Depoprovera) (400–800 mg orally/IM weekly for 1 year).
  - ◆ Megestrol acetate (Megace) (40–120 mg tablet oral/day for 1 year).
    - **Type of neoplasm:** *Carcinoma* • Endometrium
    - **Toxicity:** • Hepatic dysfunction • Alopecia      ➤ **Precaution:** Monitor liver function
- **Anti-estrogen:** ◆ Tamoxifen (10-20 mg twice daily orally)
  - **Type of neoplasm:** *Carcinoma* • Breast • Endometrium
  - **Toxicity:** Hot flushes, pruritus vulvae, vaginal bleeding      ➤ **Precaution:** None.
- ◆ Leuprolide (Lupron) (1 mg daily SC)
  - **Type of neoplasm:** *Carcinoma* : • Endometrium
  - **Toxicity:** Antiestrogen effects      ➤ **Precaution:** Addback therapy (p. 527).
- **Miscellaneous** ◆ Hydroxyurea (80 mg/kg PO every 3 days or 20-30 mg/kg/day).
  - **Type of neoplasm:** *Carcinoma:* cervix (with radiotherapy).
  - **Toxicity:** BMD, megaloblastic anemia, stomatitis, alopecia, diarrhea
  - **Precaution:** Dose reduction in bone marrow and renal dysfunction

**TABLE 30.7 CHEMOTHERAPY IN GYNAECOLOGY**

Type of neoplasm	Indication (remarks)	Chemotherapy used
Squamous cell carcinoma of cervix	<ul style="list-style-type: none"> <li>• Adjuvant chemotherapy in combination with radiation (see p.....).</li> <li>• Neoadjuvant chemotherapy (see p.....).</li> <li>• Palliation in recurrences</li> </ul>	Various combinations are tried <ul style="list-style-type: none"> <li>• Bleomycin/vincristine/Doxorubicin/vinblastine.</li> <li>• Cisplatin, actinomycin D, ifosfamide</li> <li>• Mitomycin, hydroxyurea—to increase radiosensitivity</li> </ul>
Squamous cell carcinoma of <b>vulva</b> and <b>vagina</b>	In advanced or recurrence as palliation	<ul style="list-style-type: none"> <li>• Bleomycin</li> </ul>
<b>Endometrial carcinoma</b>	As a routine or in late cases	Progestational agents, Ifosfamide, Doxorubicin, Cisplatin, Tamoxifen, Leuprolide
<b>Endometrial sarcoma</b>	As an alternative to radiotherapy	Doxorubicin and Cyclophosphamide, VAC, Progesterone, Ifosfamide
<b>Tubal carcinoma</b>	Late cases	Doxorubicin/Melphalan/Cyclophosphamide
<b>Ovarian tumors</b> Epithelial carcinoma	<ul style="list-style-type: none"> <li>• Stage 1A: May be used as a routine following surgery to improve the result</li> <li>• Advanced stage</li> <li>• Palliative chemotherapy</li> <li>• Gradually replacing radiotherapy</li> </ul>	Single or multiple drug therapy: Cisplatin or carboplatin (less toxic), taxol, melphalan, thiotepa, chlorambucil, hexamethyl melamine, cyclophosphamide and adriamycin/ (CAP or CP), gemcitabine. Usually multiple drug therapy: <ul style="list-style-type: none"> <li>• Taxol and carboplatin</li> <li>• Adriamycin and cyclophosphamide</li> <li>• Adriamycin, cyclophosphamide and cisplatin</li> </ul>

Table 30.7 contd. next page



**TABLE 30.7** CHEMOTHERAPY IN GYNAECOLOGY *Continued from previous page*

Type of neoplasm	Indication (remarks)	Chemotherapy used
Gonadal stromal tumor: • Granulosa cell tumor • Secondary metastatic	Alternative to post-operative radiotherapy —do—	• Vincristine + Adriamycin + Cyclophosphamide ( <b>VAC</b> ) • Bleomycin + Etoposide + Cisplatin ( <b>BEP</b> ) Depends upon the primary lesion
<b>Germ cell tumor</b> • Dysgerminoma  • Endodermal sinus cell tumor, Embryonal carcinoma  • Choriocarcinoma • Malignant immature teratoma, Polyembryoma	Radiotherapy preferred  • Highly malignant • chemotherapy preferred  —do—	<i>Combination agents:</i> Vinblastin, bleomycin and cisplatin ( <b>VBP</b> ) can be used for <b>successful treatment and preservation of fertility</b>  <i>Combination of drugs is used:</i> • POMB-ACE = Vincristine, Methotrexate, Bleomycin, Cisplatin, Etoposide, Actinomycin D, Cyclophosphamide • VAC therapy/BEP therapy/VBP therapy • Methotrexate/Actinomycin • Vincristine/Adriamycin/Cyclophosphamide • Cisplatin/Adriamycin/Cyclophosphamide
<b>a. Hydatidiform mole</b>	As a prophylactic therapy in selected cases	• Methotrexate 5 days at every 14 days till $\beta$ subunit becomes negative, thereafter 3 such • Actinomycin D—5 days every 14 days till $\beta$ subunit becomes negative • Three courses thereafter
<b>b. GTN</b>	Mainstay in the management of GTN—nonmetastatic and metastatic groups.	Described in Chapter 23. p. 362.
Chemotherapy for intraperitoneal small volume residual disease (<1-2 cm) and/or malignant effusions		Intraperitoneal instillation of cisplatin, cyclophosphamide or paclitaxel

**Use of antiemetics:** Nausea and vomiting are the most common side effects. It is due to stimulation of chemoreceptor trigger zone which secretes neurotransmitters (serotonin, dopamine and histamine) to activate the vomiting center.

Ondansetron (5 HT<sub>3</sub> receptor antagonist), dexamethasone and metoclopramide are commonly used.

**TABLE 30.8** FORMALITIES MAINTAINED IN SYSTEMIC CHEMOTHERAPY

- ◆ Drugs used in combination should not be mixed together
- ◆ The infusion set should be flushed with normal saline between the administration of each drug
- ◆ To avoid sclerosis of the vein, the drugs should be washed through with normal saline
- ◆ Extravasation should be avoided
- ◆ Antiemetics should be given before start of therapy

## IMMUNOTHERAPY

The following considerations have led to the idea that host immune response can prevent tumor growth :

- ◆ Immune suppressed patients are more likely to develop malignant disease.
- ◆ Therapy with monoclonal antibodies is found to destroy tumor cells, which is due to antibody dependent cellular cytotoxicity.
- ◆ Natural killer (NK) cells (lymphoid cells) and lymphokine-activated killer (LAK) cells together with IL-2 TNF, IFN can cause tumor cell destruction (adoptive immunotherapy).

**CYTOKINES AND CANCER THERAPY:** Cytokines are polypeptides secreted by different cells like, monocytes, macrophages, T cells and tumor cells. Cytokines are pleiotropic. Their functions include

regulation of cell immune activity (interferons, interleukins), hematopoiesis (colony stimulating factor), and cytotoxic activity (interleukins and tumor necrosis factor). **The overall cytotoxic mechanism are:** (a) stimulation of NK cells and macrophages (b) antiangiogenic effects and (c) inhibition of expression of oncogenes (HER-2/neu). They also increase the sensitivity of tumor cells to cytotoxic drugs.

### PRINCIPLES OF IMMUNOTHERAPY

- ◆ Tumor mass must be reduced to a minimum ( $< 10^8$  cells) by radical surgery, chemotherapy or radiation before immunotherapy.
- ◆ Immunotherapeutic approach should be a combined one.
- ◆ Any single agent therapy is often ineffective.
- ◆ Immunotherapy is more effective against tumors that are highly antigenic.

### Modulation of Immune System (Biological Response Modifiers)

Approaches to augment the immune response to human tumor include :

**Active immunotherapy** (to induce host immune response).

- Biological immunostimulants—administration of BCG (*Bacille Calmette-Guérin*), *C parvum* (*Corynebacterium parvum*).
- Chemical immunostimulants—levamisole, cimetidine.
- Cytokines, interferons (IFN), interleukins (IL-2), tumor necrosis factor (TNF).
- Chemotherapeutic drugs—cisplatin, doxorubicin.

**Passive immunotherapy** (immunologically active substances are directly transferred to the host).

- Cytokines: Interferon, TNF.
- LAK cells: Together with IL-2.
- Monoclonal antibodies.
- Activated macrophages: Interferon.

Immunotherapy has its limitations. Immune response enhancement leading to rejection of tumor can occur when the following conditions are fulfilled :

- Biological response modifiers are in direct contact with tumors.
- Tumor bulk is minimal.
- Blood supply is good.
- Monoclonal antibodies to be conjugated with agents (chemotherapy drugs, toxins, interferon) for precise delivery to tumor cells.

## GENETICS AND GYNECOLOGIC MALIGNANCY

Familial cancer of the breast, ovary, colon, endometrium and other sites have been observed in the female members of afflicted families. Well-defined cancer family syndromes with autosomal dominant inheritance pattern have been described (see p. 371). When life-time risk of ovarian cancer in the population as a whole is 1.4 percent, it is about 5 percent when one first degree relative is affected and it rises to 7 percent when two or more first degree relatives are affected.

Genetic basis of ovarian and breast malignancy have been explained with the mutation of the BRCA-1 gene on chromosome 17q and BRCA-2 gene on chromosome 13 q. Three types of genes (oncogenes, tumor suppressor genes and mutator genes) are involved with malignant change. Point mutation, deletion and insertion are the important changes observed in malignancy.

**Oncogenes** are dominant whereas **tumor suppressor genes (p.53)** are recessive in function at cellular level. Oncogenes activate cell proliferation to malignant behavior whereas tumor suppressor genes (BRCA-1) restrain cell growth. However, majority of ovarian cancers are not associated with familial predisposition. Familial cancer account for less than 5 percent of all cases of ovarian cancer. Familial cancers have an early age of onset.

**Early detection of cancer** may be possible by detecting mutated copies of a gene products (P53, HER-2/neu K-ras), using polymerase or ligase chain reaction. Several oncogene products (her-2/neu, K-ras, C-myc, P21), tumor suppressor gene products (P53, P16, PRB) are currently being investigated as independent **prognostic markers**.

**Oncogenes** regulate cell growth in a positive fashion. Oncogenes include transforming genes of viruses and normal cellular genes that are activated by mutations to promote cell growth to a partly malignant behavior. It needs one mutational events for its gain of function (Dominant).

**Tumor suppressor gene** (antioncogene)—Suppresses cellular growth, proliferation and malignant phenotype. It needs two mutational events (point mutation, deletions) for its loss of function (recessive).

Study for detection of gene mutation is mainly restricted to research purpose only.

Common tumor suppressor genes and their chromosome location are :

RB1 (13q), p 53 (17 p), BRCA1 (17q), BRCA2 (13q), WT1 (11q)

Loss of cell apoptosis due to gene mutation may lead to cancer.

**Mismatch repair genes (total six)** work in concert to repair DNA damage that occur in the course of a normal cell division. Germ line mutations in mismatch repair genes is responsible for many hereditary cancers (colorectal, endometrial and uroepithelial).

**Telomerase:** Reactivation of telomerase activity to restore telomere sequences is absent in a normal cell. Cells having significant telomerase activity become immortal and turn into cancer cells.

**Gene therapy**—The effects of **oncogene function** can be transformed by two approaches. One attempt is to remove the oncogene product or to block its function. Alternatively, one can use antisense oligonucleotides in an attempt to block the production of oncogene by preventing the transcription of chromosomal DNA to RNA. Antisense oligonucleotide can be administered systemically. Cytokine gene transfer to tumor cells stimulates a systemic immune response and destroy tumor cells. Cells are engineered to produce cytokines including interleukines 2,4,5 and 6, TNF and others. Clinical trials are in progress in patients with squamous cell carcinoma, ovarian epithelial cell carcinoma with this technology.

**In cervical carcinoma**, recurrent loss of heterozygosity (LOH) is identified. Besides this, integration of viral (HPV 18, 16) DNA in chromosome (8, 12) is frequently observed (see p. 322).

**Ovarian cancer**—Point mutations of the P-53 (17P) gene are the most frequent genetic alteration. Loss of heterozygosity (LOH) on chromosome 17q has been noted.

Cytokines provide stimulatory signals important for T cell activation. Such cytokine milieu can be enhanced by local injection at the tumor site to promote the acquisition of cellular immunity. Tumor cells are genetically engineered to produce molecule of interest (IL-2, 4, 5, 6, MF-CSF, TNF) and are used as vaccines. Trials are in progress with this technology to prevent squamous cell cancer, colon cancer, ovarian epithelial cancer and lung cancer.

## TUMOR MARKERS

A tumor marker is a substance that is selectively produced by the neoplastic tissue. It is then released into the blood where from it can be detected.

Ideal tumor marker should fulfil the following criteria :

**TABLE 30.9** COMMONLY USED GYNECOLOGICAL TUMOR MARKERS

Marker	Tissue of origin of cancer
Human chorionic gonadotropin (hCG)	Trophoblastic and some germ cell tumor (dysgerminoma, embryonal carcinoma)
Alpha fetoprotein (AFP)	Germ cell tumor (endodermal sinus tumor)
CA 125	Ovarian epithelial tumor, endometrial adenocarcinoma
Carcinoembryonic antigen (CEA)	Ovarian (serous, endometrioid), cervical carcinoma (squamous cell)
Tumor associated glycoprotein – 72 (TAG-72)	Ovarian epithelial tumor
Macrophage colony stimulating factor (M-CSF)	Ovarian epithelial tumor
Squamous cell carcinoma antigen (SCC)	Carcinoma cervix, vulval and vaginal squamous cell carcinoma
Lactic dehydrogenase (LDH)	Ovarian germ cell tumors (dysgerminoma)
CA 15–3, OVX 1, OVX 2 HER – 2/neu (oncogene product) HE 4	Ovarian epithelial carcinoma
Galactosyltransferase associated with tumor (GAT)	To differentiate ovarian cancer from endometriosis
Estrogen Progesterone Testosterone	Gonadal stromal tumors.
Inhibin	Granulosa cell tumor

- ◆ It should be produced only by the tumor cells.
- ◆ It should be specific.
- ◆ Its measurement either in the blood or urine should be sensitive enough to detect microscopic or subclinical disease.
- ◆ Tumor markers are used to monitor the response of therapy. Ideally the antigen (tumor marker) level should represent the tumor volume correctly. Progressive rise in marker value indicates ineffective chemotherapy.
- ◆ The assay should be inexpensive and acceptable.

The tumor marker should not only indicate the presence but also the site of tumor origin.

**Tumor marker is useful in screening, diagnosis and management of a case and for follow-up.** However, the detection of tumor marker is seldom made before the cell population becomes  $10^{10}$ .

The role of serum CA-125 in the evaluation of disease (ovarian carcinoma) progression and regression is invaluable. Similarly, serum  $\beta$ -hCG is useful in the diagnosis, management and follow up of cases with GTN. A list of tumor markers is given in Table 30.9.

## KEY POINTS

- Electromagnetic radiation is a form of energy that has no mass or charge. It travels with the speed of light. For therapeutic purpose, radium and cesium are commonly used.
- Effect of radiation at a point varies inversely as the square of the distance from the source (Inverse Square Law).
- **Brachytherapy** is the common form of radiation therapy especially when the tumor volume is small. After-loading technique is the modern development. Teletherapy is used to deliver to homogeneous radiation dose to a large volume of tumor.

Rad is the absorbed dose. Recently, the unit gray (Joule/kg) is used. One centigray (cGy) is equivalent to one rad.

- Biological effects of radiation are due to fast electron, that ionizes molecules to produce free radicals. Target for radiation injury is DNA. Tumor tissue recovers from radiation damage more slowly compared to normal tissue. Each delivered radiation dose kills a constant fraction of human cells. Oxygen can cause radiation induced DNA damage permanent.

Radiocurability of a tumor depends upon the biological behavior of the cells. It is not identical to radiosensitivity which depends several factors (see p. 509).

There may be localized or systemic radiation reactions for which appropriate therapy is needed. Early reaction is curable but the late reactions produce severe morbidity. Radiation reaction commonly affects GI tract, bone marrow and bladder (see p. 508).

- The cell replication cycle consists of M (mitosis), G1 (RNA and protein synthesis), S (DNA synthesis) and G2 (RNA and protein synthesis) phases. Cells, not in the replication cycle, are in G0 phase (p. 511). Diving tumor cells (M phase) are most sensitive to cytotoxic agents. Radiation acts on cells primarily in M phase.
- Large tumors have smaller growth fractions and longer mass doubling time. Cytotoxic agents act on various phases of the cell cycle. They primarily affect rapidly proliferating cells. Rapidly growing tumors are more curable to treatment. Drugs commonly used are alkylating agents, antimetabolites, antibiotics, plant alkaloids, and hormones. Toxic effects varies from slight to more severe one, even to the extent of death (p. 515, 516).
- Cisplatin is more nephrotoxic and myelosuppressive compared to carboplatin. Doxorubicin is cardiotoxic. Bleomycin is associated with pulmonary toxicity. Vincristine and cisplatin cause peripheral neurotoxicity. Alopecia can occur with any chemotherapy. Taxol (paclitaxel and docetaxel) is a powerful antineoplastic agent that disrupts microtubule function (polymerization) (see p. 513).

*Contd..*

- Combination therapy is preferred. It gives a synergistic effect by acting at different cell sites and reduces the development of drug resistance (see p. 513).
- Multiple chemotherapeutic agents have been used to kill cancer cells. They have also been used to sensitize cells to radiation. Chemoradiation improves outcome especially with squamous cell cancers.
- Pretreatment evaluation and proper monitoring during therapy are mandatory to prevent or minimize the toxicity (see p. 514). Growth factors or granulocyte colony-stimulating factor are used to prevent hemorrhagic toxicity of chemotherapy.
- Immunotherapy in malignancy—is being explored recently. Cytokines (polypeptides) have antitumor and immune stimulating effects. Augmentation of immune system is achieved by active (interferon, IL-2) and passive (LAK cells) immunotherapy.
- Tumor markers indicate the presence and also the site of tumor origin. It is useful in screening, diagnosis and management of cases and also for follow up. Gynecological tumor markers in common use are—hCG in trophoblastic tumor, AFP in germ cell tumor, CA-125 in ovarian epithelial tumor and SCC in carcinoma cervix. HER-2/neu, an oncogene product is used for epithelial ovarian cancer (see p. 522).
- Familial cancer (breast, ovary, colon) is explained on the basis of genes (oncogene, tumor suppressor gene and mutator gene). Point mutation, deletion and insertion are the important changes. Gene therapy to the tissues at risk by insertion of normal copies of genes is a way forward.

# Hormones in Gynecological Practice

## NOMENCLATURES

- **Hormones**    ■ **Factors**    ■ **Analogues**
- **Agonists**    ■ **Antagonists**

**Hormones:** Hormone is a substance that is produced in a special tissue and released into the blood stream. Hormones travel to **distant cells** to have its desired effects.

**Factors:** Factors are substances that modulate cell function and proliferation by acting upon the cell membrane receptors. They act locally (unlike the hormones) by autocrine and paracrine mechanism.

**Analogues:** An analogue is a synthetic substance with a structure mostly similar to a natural one but differing from it in certain component. It may have agonist and/or antagonist function at the cellular level. GnRH analog acts as an agonist (upregulation) initially but on chronic therapy, it antagonises (downregulation) the pituitary GnRH receptors.

**Agonists:** Agonist is a substance that has increased affinity for cell receptors and it stimulates the cellular physiological response.

**Antagonists:** An antagonist tends to nullify the action of another substance binding on its receptor without eliciting a biological response. There is a blockage of receptor response. Tamoxifen blocks estrogen receptor whereas mifepristone blocks progesterone receptors.

Because of relative lack of receptor specificity, an antagonist for one class of hormone can have an antagonistic effect on another class of hormone.

Antagonists may have adverse effects apart from the intended use.

## CELLULAR FUNCTION

A cell function is modulated by any of the three ways:

**Endocrine** when a hormone in circulation (blood or lymph) regulates the function of a cell at a distant site.

**Paracrine** function is when a regulating substance diffuses from one cell to a contiguous cell (intercellular) and modulates the cell function. Insulin-like growth factor-II (IGF-II) is produced by the theca cells of ovary. It stimulates granulosa cell proliferation when it diffuses to it.

**Autocrine** function is explained when a regulating substance produced by a cell act upon the receptor on the same cell. It modulates the function of the same cell (intracellular). IGF-II is said to have autocrine function when it is produced by and acts on luteinized granulosa cells.



## INTRODUCTION

Considerable advancement has been made in the understanding of chemistry and pharmacology of new compounds that modulate and influence the function of many endogenous hormones. Once the structure of natural hormones is defined, it becomes possible to synthesize not only the hormones themselves, but also their agonists or antagonists. **These substances can be used:**

- ◆ To diagnose the functional integrity of endocrine control systems.
- ◆ To replace the hormone deficiency state.
- ◆ To modify the abnormal function of the endocrine system.
- ◆ To alter the normal function to gain objectives.

While, many natural hormones are not easily available in adequate quantities, with advanced technology, many such products are manufactured by synthetic, semisynthetic or hybridization.

## HYPOTHALAMIC HORMONES

**GnRH** (see p. 67): ➔ **Diagnostic** ➔ **Therapeutic**

**Diagnostic:** The GnRH stimulation test is used to differentiate an amenorrhea of pituitary or hypothalamic in origin (p. 469).

An intravenous dose of GnRH 50–100 µg is given to stimulate pituitary. The maximal response is observed at 15–30 minutes for LH and 30–60 minutes for FSH. **The absence of response usually denotes pituitary fault.** However, the result may not be unequivocal and as such, requires cautious interpretation.

**Therapeutic:** The pulsatile nature of hypothalamic GnRH in the control of gonadotropin secretion affords a physiological basis for the **activation of pituitary gonadal axis.**

**Induction of ovulation: It is suitable in cases with idiopathic hypogonadotropic hypogonadism** who have failed to respond with clomiphene. Pulsatile administration of GnRH (2.5 to 20 µg/pulse) at a constant interval (60–90 min) induces ovulation effectively. GnRH therapy results follicular growth and development similar to a normal cycle. In hypothalamic causes of anovulation, GnRH is most effective. For intravenous route, portable minipump is used. For subcutaneous route high dose (20 µg) is needed. **The main advantages of pulsatile administration are** lower incidence of hyperstimulation syndrome and multiple pregnancy when compared to hMG.

**Other uses through activation of Pituitary-Gonadal Axis:**

- **Delayed puberty**—to activate the pituitary gonadal axis (p. 54).
- **Functional hypothalamic amenorrhea** (p. 515) to stimulate HPO axis for ovarian follicular development.
- **Cryptorchidism.**

**GnRH ANALOGUES** (agonists and antagonists) have been synthesized by substitution of amino acids at different positions of GnRH molecule. This is done to overcome the short half-life, as well as to alter the functions of GnRH (see p. 67). **GnRH agonists have longer half lives (3–8 hours) and greater potencies (15–200 times).**

- **GnRH agonist** is produced when there is substitution of amino acids at sixth and tenth positions (see Fig. 7.1A, p. 67). This makes GnRH more stable with increased receptor affinity.

**Mode of action:** Initially there is stimulation of anterior pituitary resulting in increased secretion of FSH and LH (**upregulation**). This is called **flare effect**. After 1–3 weeks, there is profound suppression of secretion (**downregulation**) due to loss of pituitary GnRH receptor sensitivity. This leads to a fall in pituitary gonadotropic hormones—LH and FSH and consequently the gonadal secretion (hypogonadotropic hypogonadal state). **The net effect is production of medical hypophysectomy.**

**Mode of administration:** It can be used by intranasal and subcutaneous route and the biodegradable implants last for a month (see Table 31.1).

TABLE 31.1	COMMON PREPARATIONS AVAILABLE WITH THEIR DOSE AND ROUTE OF ADMINISTRATION	
Preparation	Dose	Route
Buserelin (Superfact)	300–600 µg daily 200–500 µg daily	Intranasal subcutaneous
Nafarelin	400–800 µg daily	Intranasal
Goserelin (Zoladex)	3.6 mg every 28 days	Subcutaneous implant
Leuprorelin acetate	3.75 mg every 28 days	Subcutaneous or intramuscular
Triptorelin (Decapeptyl)	3 mg every 28 days	Intramuscular

### Use of GnRH analogues

#### 1. **Controlled Ovarian Hyperstimulation in *in vitro* fertilization**

Suppression of endogenous pituitary gonadotropin secretion by downregulation with GnRH analogues followed by administration of hMG or FSH allows good quality stimulation with superovulation. The problems of suboptimal response and premature luteinization due to endogenous LH surge are thus avoided. This will allow significantly higher number of oocyte retrieval and significant improvement in pregnancy rate. This induction of ovulation protocol allows the clinicians to make convenient administration of hCG

and oocyte collection. It is preferable to support the luteal phase with hCG.

**Protocol:** Two types of protocols are commonly used with probably of equal efficacy (p. 252).

**Long protocol**—The GnRH analogues are given from 21st day of previous cycle to desensitize the pituitary (LH level < 5 mIU/ml and  $E_2$  < 30 pg/ml or when USG fails to detect follicle) before the hMG or FSH is given.

**The benefits include** less need of cycle monitoring, high pregnancy and livebirth rates.

**Short protocol**—The hMG or FSH is given soon after administration of GnRH agonists on day 2 and before the pituitary is desensitized. **The advantages of short protocol** are the economy and convenience, using for a short period of time.

## 2. **Induction of ovulation with higher baseline LH in PCOS**

In refractory cases of ovulation induction, especially in patient with PCO, when the endogenous LH level is high, GnRH analogues offer a good success with long protocol regimen. It is used in the IVF cycles (p. 252).

## 3. **Endometriosis**—By producing medical hypophysectomy and thereby, a hypoestrogenic state, it produces atrophy of the ectopic endometrium.

**GnRH agonists are very effective in relieving the pain and reducing adhesion formation.**

## 4. **Fibroid**—By producing hypoestrogenic state, they will produce shrinkage of the tumor by about 60 percent after 3–6 months treatment. But the size comes back to previous state after the drug is withdrawn. The drug cannot replace surgery. Blood loss during operation is less but surgical dissection may be difficult due to softening of the myoma. **GnRH antagonist** (depot cetrorelix) pre-operative treatment has faster response (14 days) and is equally effective (see p. 281).

## 5. **Precocious puberty (p. 51)**—In only constitutional variety, to inhibit the premature activation of hypothalamopituitary gonadal axis, the analogues are safe and highly effective. It also slows down the process of skeleton maturation and will stabilize or cause regression of the secondary sex characteristics.

**Dose**—100 µg intranasally twice daily for 6 months or until the chronological ages are matched (see ch. 5).

## 6. **Hirsutism**—In the idiopathic group, by suppressing the pituitary gonadal axis, the excess hair growth can be arrested with the use of GnRH analogues (see p. 575).

**Dose**—Nafarelin 100 µg per day subcutaneously will decrease the serum level of total and free testosterone and there is clinical improvement of hirsutism.

However, the improvement is only limited during the period of drug therapy and is in no way better than the use of ‘pill’.

## 7. **DUB**—During the time, the patient waiting for operation or during the period to improve the anemic state (see p. 191).

## 8. **Premenstrual syndrome (PMS/PMDD)**

It is used for diagnostic as well as therapeutic purpose.

For diagnostic purpose, a depot preparation is administered for 3 months. Relief of symptoms confirm the diagnosis (see p. 182). For therapy, buserelin 400 µg is given intranasally daily or 50 µg/day subcutaneous injection up to 6 months.

Symptoms due to hypoestrogenism is a problem. Add-back therapy may be needed (see below).

## 9. **Advanced breast carcinoma** in premenopausal women (hormone dependent).

## 10. **Contraception**—Used for ovulation inhibition and suppression of spermatogenesis (Female) (male) (see Chapter 29).

**Used in male**—(i) GnRH analogues produce a decline in sperm density, sperm mobility and testosterone level. The marked loss of libido makes it unacceptable. Currently, use of GnRH antagonist along with testosterone (add-back therapy) is found to overcome the problem (see p. 542). (ii) Prostatic cancer (hormone dependent).

**Used in female**—GnRH analogues act by preventing the pituitary response to endogenous GnRH. Buserelin is given intranasally with daily doses of 300–600 µg over 3–6 months (see Table 31.1). **Add-back therapy** is effective to prevent the hypoestrogenic symptoms (see below).

## 11. **Endometrial resection/ablation**—Prior to endometrial resection, GnRH analogues are used to suppress the endometrial growth (see p. 621).



■ **GnRH Antagonists** (see Table 31.2).

### Hazards of GnRH Analogues

Side effects are predominantly due to hypogonadotropic and hypoestrogenic state. The important **side effects are** hot flushes, vaginal dryness, dyspareunia, headache and depression (menopause-like symptoms, see ch. 6). Acne, muscle pain, back pain, dry skin are also noted. There is decrease in both, the trabecular (lumbar spine) and cortical (femoral neck) bone mineral density (osteoporosis) when used for more than 6 months. They do not produce significant changes in lipid metabolism. For long-term use, GnRH analogues have been used with low-dose estrogen and progestin (**add-back therapy**) to minimize the side effects. **Add-back therapy** consists of low dose combined estrogen (conjugated estrogen 0.625 mg) and progestin (medroxy progesterone 2.5 mg) therapy regimens daily. **Add-back therapy prevents bone loss and other side effects.**

**GnRH antagonist:** Synthesized by modification of amino acids at positions 1, 2, 3, 6 and 10 (Ganirelix, Cetorelix). Minimum effective dose to prevent premature LH surge is 0.25 mg SC. **The important properties of GnRH agonist and antagonist are given in Table 31.2.**

TABLE 31.2

GnRH Agonist	GnRH Antagonist
1. Suppression of endogenous LH surge	1. Suppression of endogenous LH surge
2. Initial flare effect	2. Immediate suppression of gonadotropins
3. Duration of treatment—long	3. Short
4. Estrogen deficiency symptoms—present	4. Absent
5. Need of gonadotropin stimulation—dose and duration—more	5. Less
6. Pituitary function recovery—slow	6. Quick recovery following therapy
7. Risk of OHSS—present	7. Less OHSS (see p. 529)
8. Expensive	8. Less expensive

## GONADOTROPINS

The use of gonadotropins in clinical use lies on the principle that gonadotropic hormones act on the ovaries to induce ovulation. **The gonadotropins, used widely today, are derived from urine obtained from postmenopausal women.** Human gonadotropin can also be obtained from extract of cadaveric pituitary glands. Human pituitary gonadotropin (hPG) is predominantly FSH. It is not easily available.

The most commonly used commercial preparation is human menopausal gonadotropins (hMG). One ampoule of hMG (pergonal) contains LH activity of 75 IU and FSH activity of 75 IU. Purified FSH (Metrodin–75 IU/ampoule) is available with minimum LH. Recently, a highly purified preparation of human FSH (Metrodin HP) has been made available (Serono). This is extracted from hMG using anti-hCG antibodies to cause absorption of LH on to gel columns. Metrodin HP can be administered subcutaneously. Recombinant FSH (Gonal F, Recagon) is now available. It is administered by subcutaneous route.

hCG (human chorionic gonadotropin) is known to have a biological action like LH surge and is available in ampoules with 1000–5000 IU (pregnyl, profasi). **It is obtained from urine of pregnant women.** Recombinant gonadotropins (FSH, LH and hCG) are used for ovarian stimulation according to the need of individual woman and to optimize oocyte quality and cycle fecundity.

### Limitations

- It is expensive.
- It should only be used with back-up facilities for monitoring the response by BBT, cervical mucus study, supplemented by serial serum estradiol estimation and sonographic measurement of follicular enlargement (see ch. 16). As such, its use is limited only in women with ovarian reserve (p. 528).

### Indications

- Anovulatory infertility where other factors (tubal, uterine, male) have been excluded.
- Induction of superovulation in assisted reproduction (see p. 252).

- hCG is administered for luteal phase support especially when GnRH agonist is used.
- Treatment of male infertility (hypogonadotropic hypogonadism) (see p. 242).
- Treatment of cryptorchism.
- Hypogonadotropic hypogonadism (WHO Group-I, p. 258) with or without amenorrhea.
- Failed clomiphene induction especially in patients with polycystic ovaries syndrome (PCOS).
- Unexplained infertility.

### Contraindications

- High level of endogenous FSH, indicating ovarian failure (see p. 463, 469).
- Overt thyroid or adrenal dysfunction.
- Pituitary tumor.
- Indeterminate uterine bleeding.

### Treatment Protocol

The drug dose schedule should be individualized to get the best result. As a rule, a higher dose is required in cases of secondary amenorrhea due to pituitary failure and a smaller dose may be required in ovulatory failure or corpus luteal insufficiency. Metrodin containing only FSH, is suitable in PCOS.

Women with hypogonadotropic hypogonadism should be treated with hMG (FSH and LH). Treatment with hMG begins following spontaneous menses or induced withdrawal bleeding. A daily dose of 1–2 ampoules of hMG is given intramuscularly for at least 5 days and continued thereafter, with the same dose or an increasing dose with cervical mucus study,  $E_2$  estimation and sonographic (transvaginal) folliculometry at interval of 2–3 days or earlier until the preovulatory follicular diameter measures 18–20 mm (see p. 252, 253). The hMG is then discontinued and after 24 hours, hCG is given intramuscularly for ovulation. The dose of hCG is 5000 IU for induction of ovulation. The patient is advised to have sexual intercourse on a number of occasions over the next 36–72 hours.

In some cases, for adequate ovarian follicular growth, high doses of FSH (4–6 ampoules per day) may be needed.

**High responders** are those women who have exaggerated response in follicular development. The diagnostic features are : enlarged ovaries with

large number of follicles, elevated serum estradiol (> 3000 pg/ml).

### Management options

#### A. Coasting:

- ◆ To continue GnRH agonist.
- ◆ No gonadotropin stimulation.
- ◆ To give hCG once estradiol level is within the normal range (see above).

**B. Oocyte retrieval and fertilization**—freezing all embryos and no transfer to avoid ovarian hyperstimulation syndrome.

**C. To delay** embryo transfer until the symptoms subside.

**D. To cancel** the treatment cycle.

These women have good prognosis in subsequent cycles.

**Poor responders** are those women who develop fewer follicle (<3) and have serum estradiol <500 pg/ml in spite of high doses of gonadotropins.

### Management options

- ◆ To use higher doses of gonadotropin stimulation.
- ◆ To decrease the doses of GnRH agonist.
- ◆ To use GnRH antagonist instead of long-acting agonist.

These women have relatively poor prognosis.

**Results of gonadotropin use:** Cumulative pregnancy rate is about 90 percent after 6 cycles treatment. Spontaneous miscarriage rate is high (20%). Risk of ectopic pregnancy is high. Multiple pregnancy rate is between 10–30 percent. Majority are twins. There is no increased incidence of congenital malformation of the fetus.

**OVARIAN RESERVE:** Means the quantity as well as quality of follicles present in the ovary. The total number of oocytes declines with the age of a woman since her birth (see p. 82). Inhibin B secreted by the competent follicles, exerts negative feedback on pituitary FSH secretion (see p. 75). With the progressive fall in follicle number as with age, inhibin B level is reduced. There is rise in FSH level even in the early follicular phase.

**Detection of diminished ovarian reserve (DOR):** **Tests for detection of DOR** can identify the women who are likely to have poor response with

gonadotropin and lower pregnancy rate. (i) Levels of cycle D3 serum FSH > 10–15 IU/L. (ii) Levels of D3 serum estradiol > 60–80 pg/ml. (iii) Clomiphene citrate challenge test: Levels of D3 serum FSH and estradiol are measured. The women is given clomiphene citrate (100 mg daily from D5–D9). Serum levels of FSH is measured again on D10 and elevated values of serum FSH (more than 2 SD of the mean) are obtained. (iv) Levels of cycle D3 serum anti-Müllerian Hormone (AMH)—low (0.2–0.7 ng/ml). (v) Levels of basal serum inhibin B—low (< 40 pg/ml). However, it is not a reliable measure. (vi) **Antral Follicle Count (AFC)**: Total number of antral follicles (measuring 2–10 mm) in both the ovaries using TVS is proportional to the number of primordial follicles present in the ovaries. So a low AFC indicates poor ovarian reserve. A woman in her reproductive age, usually have 20–150 growing follicles in the ovaries at any time. (vii) **Ovarian Volume Measurement (OVM)**: Ovarian volume decreases with progressive follicular loss. Poor ovarian reserve indicates poor outcome with IVF.

CRITERIA FOR SEVERITY OF OHSS	
Severity	Clinical features
Mild (10–20%)	<ul style="list-style-type: none"> <li>Abdominal bloating, mild pain</li> <li>Ovarian size &lt; 8 cm</li> </ul>
Moderate (5–10%)	<ul style="list-style-type: none"> <li>Nausea, vomiting, diarrhea</li> <li>USG evidence of ascites</li> <li>Ovarian size 8–12 cm</li> </ul>
Severe (1–2%)	<ul style="list-style-type: none"> <li>Clinical ascites, sometimes hydrothorax</li> <li>ARDS</li> <li>Hemoconcentration (Hematocrit &gt; 45%, WBC count &gt; 15000/ml)</li> <li>Oliguria with normal serum creatinine</li> <li>Liver dysfunction</li> <li>Anasarca</li> <li>Ovarian size &gt; 12 cm</li> </ul>
Critical (rare)	<ul style="list-style-type: none"> <li>Tense ascities</li> <li>Hematocrit &gt; 55%</li> <li>WBC count &gt; 25000/ml</li> <li>Oliguria with elevated serum creatinine</li> <li>Renal failure</li> <li>Thromboembolic phenomenon</li> <li>Ovarian size &gt; 12 cm.</li> </ul>

### Hazards of Ovulation Induction (p. 255)

#### OVARIAN HYPERSTIMULATION SYNDROME (OHSS)

The OHSS is characterized by multiple follicular development and ovarian enlargement following hCG stimulation. It occurs mostly with the conception cycle. The clinical features appear about 3–6 days after the ovulating dose of hCG is administered. It is an iatrogenic and potentially a life-threatening complication of superovulation.

**Risk factors for OHSS are:** Young age < 30 years, PCOS, Serum  $E_2$  > 2500 pg/ml, rapidly rising serum  $E_2$  levels (> 75% rise from previous day), ovarian ‘necklace sign’ on USG (multiple small follicles), hCG administration and multiple pregnancy.

**Pathophysiology** is poorly understood. Increased capillary permeability leads to leakage of fluid from the peritoneal and ovarian surfaces. Variety of chemical mediators like cytokines, vascular epidermal growth factor (VEGF), prorenin, renin and nitric oxide (NO) system are thought to be stimulated with hCG administration.

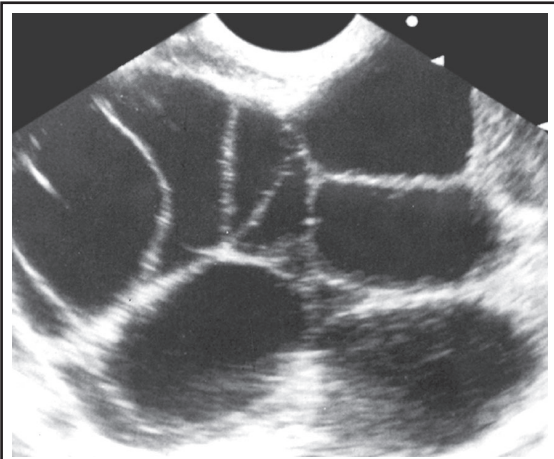
**Prevention**—Complete prevention may not be possible but severity can be reduced. The important steps to be taken are:

- ◆ Use of GnRH antagonists for pituitary down-regulation.
- ◆ Low starting dose of gonadotropins in high-risk women.
- ◆ Metformin cotreatment during gonadotropin stimulation in women with PCOS.
- ◆ Close monitoring of the superovulation cycles using TVS and serum estradiol estimation (see p. 252).
- ◆ To withhold ovulatory dose of hCG in susceptible cases and to cancel the cycle or to delay the dose of hCG injection (coasting).
- ◆ Follicular aspiration after hCG administration and cryopreservation of oocytes or embryos for future use may reduce the severity of symptoms (coasting and cryopreservation).
- ◆ Aspiration of immature oocytes and *in vitro* maturation (IVM) are done. Subsequently ICSI is performed on IVM oocytes and embryos are transferred to the hormonally prepared uterus.
- ◆ Progesterone should be used for luteal phase support (see p. 253) instead of hCG.

**Management of OHSS** is mainly supportive.

Moderate and severe cases are to be admitted.

- ◆ To monitor complete hemogram, LFTs, RFTs, electrolytes, coagulation profile, ECG and urine output.



**Fig. 31.1:** Ultrasonographic view of ovarian hyperstimulation syndrome. Enlargement of the ovary with multiple follicles

- ◆ Chest X-ray (shielding the pelvis), monitoring of O<sub>2</sub> saturation is needed when there is respiratory compromise.
- ◆ TVS is to be done to assess ovarian volume and ascites.
- ◆ Oral fluid is continued to prevent hemoconcentration and to maintain renal perfusion. Normal saline 150 ml/hr IV is given when hematocrit is >45 percent.
- ◆ To relieve respiratory distress, abdominal paracentesis may be done under USG guidance.
- ◆ Human albumin (50 ml of 25%) may be administered to correct hypovolemia. It may be repeated.
- ◆ Pain is controlled with paracetamol or pethidine.
- ◆ Intensive care management is needed for specific complications like renal failure.
- ◆ Surgery is rarely indicated.

### ANTI-GONADOTROPINS

Commonly used drugs ◆ Danazol ◆ Gestrinone

◆ **DANAZOL:** Danazol is an isoxazol derivative of 17-alpha ethinyl testosterone. It has got both androgenic and anabolic properties. **It is strictly anti-gonadotropin but acts as an androgen agonist.**

**Mode of action:** The mechanism of action is complex and includes the following:

- ◆ Acting on the hypothalamopituitary gonadal axis → depression of frequency of GnRH pulses → suppression of pituitary FSH and LH

surge. There is, however, no change in the basal gonadotropin level. Due to this reason the word “pseudomenopause” seems misnomer; while the estrogen level is reduced but **unlike menopause, the gonadotropins remain static in base levels.**

- ◆ Reduces the liver synthesis of SHBG and as such, free testosterone is increased which in turn has got direct action on endometrial atrophy.
- ◆ Acts directly on the ovaries, inhibiting the enzymes responsible for steroidogenesis. Estrogen level is low.
- ◆ Binds with steroid receptors on the endometrium and also in the ectopic endometrial sites
- ◆ Immunologic effects of danazol include decrease in serum immunoglobulins, interleukin-1 and TNF production. This effect helps in the regression of endometriosis.

**The net result is production of an hypoestrogenic state.**

**Precautions:** It should be commenced in the early follicular phase of the menstrual cycle. **Barrier method of contraception** should be used to avoid being administered during early pregnancy following accidental ovulation. There is chance of virilization of the female offspring. **It is contraindicated in liver disease.**

**Dose:** Depending upon the indication (Table 31.3) and response, the dose varies from 200–800 mg daily orally.

**TABLE 31.3 INDICATIONS OF DANAZOL**

■ Endometriosis	■ Precocious puberty
■ DUB	■ PMS/PMDD (see p. 183)
■ Symptomatic fibroid	■ Benign fibrocystic disease of the breasts (breast pain)
■ Prior to hysteroscopic endometrial ablation, to make the endometrium thin	

**Side effects (Table 31.4):** The side effects are mostly related to hypoestrogenic and androgenic activity. However, most of these effects revert back to normal soon following stoppage of the therapy. It is recommended that the patient should discontinue the treatment, if they develop hirsutism or hoarseness of voice.

**TABLE 31.4** SIDE EFFECTS OF DANAZOL

Hypoestrogenic	Androgenic	Metabolic
<ul style="list-style-type: none"> <li>➤ Diminished breast size</li> <li>➤ Decreased libido</li> <li>➤ Atrophic vaginitis</li> <li>➤ Hot flushes</li> </ul>	<ul style="list-style-type: none"> <li>➤ Acne</li> <li>➤ Edema</li> <li>➤ Hirsutism</li> <li>➤ Deepening of voice (irreversible)</li> </ul>	<ul style="list-style-type: none"> <li>➤ Oily skin</li> <li>➤ Weight gain</li> <li>➤ Elevation of LDL, total cholesterol</li> <li>➤ Reduction of HDL</li> <li>➤ Decrease in TBG and total thyroxine level</li> </ul>

**GESTRINONE:** Gestrinone is a derivative of 19-norethisterone. It is an androgen-agonist and progesterone agonist-antagonist. It markedly reduces SHBG levels and thus increases the free testosterone. It reduces the secretion of FSH and LH. It has a much longer half-life and the dose required to produce equivalent results, is much smaller than danazol.

**Dose:** 2.5 mg twice weekly starting on first day of cycle with second dose 3 days later, repeated on same two days preferably at same time each week.

Side effects are the same to those of danazol but usually less marked.

## GONADAL HORMONES

There are three gonadal steroid hormones. These are estrogen, progesterone and androgen.

### Mechanism of Action

Steroid sex hormones are well-absorbed through the skin and the gut. While most are subjected to extensive hepatic metabolic inactivation, there is some enterohepatic recirculation especially of estrogens and this may be interrupted by diarrhea to cause loss of efficacy. The sex hormones are transported in the blood non-specifically by albumin and specifically by SHBG.

Steroid hormone receptors are complex proteins inside the target cell. The steroid penetrates the cell membrane and mediates action via receptors within the nucleus (see Fig. 7.4).

## ESTROGENS

Natural estrogens are 18-carbon atom steroids. Estradiol is the most active natural estrogen in human uses.

**PREPARATIONS AVAILABLE:** • Natural • Synthetic

**Natural:** (a) It is available in the form of water soluble conjugated estrogen as Premarin (Equine conjugated

estrogen). It is obtained from the urine of pregnant mares. It is available as tablets 0.3 mg, 0.625 mg and 1.25 mg and as injection of 20 mg ampoules for IM or IV injection. (b) Estrogen valerate used for priming the endometrium in donor oocyte program (vide Ch. 16).

**Synthetic:** Oral      Injectable      Cream/Gel  
Pessary      Implant      Patch

**Oral:** This is the best route for synthetic preparations.

- ◆ Ethinyl estradiol (Lynoral) 0.01 mg and 0.05 mg daily is commonly used.
- ◆ Estradiol valerate 1–2 mg.
- ◆ Mestranol — 0.05 mg.
- ◆ Estriol succinate (Evalon) — 1–2 mg.

**Injectable:** • Estradiol ester as progynon depot (Schering) – 10 mg ampoule. • Estradiol benzoate or dipropionate – 1 mg and 5 mg ampoule.

**Cream:** • Vaginal cream—dienestrol (0.1 mg/gm), Estriol (1 mg/gm). • Percutaneous cream—delivers 3 mg of estradiol in each daily 5 gm applicator of cream.

**Gel:** Estradiol gel 1 mg to be applied once daily over the skin of the lower trunk.

**Pessary:** Dienestrol or diethyl stilbestrol pessary.

**Implants:** • Subcutaneous implants of 50 mg and 100 mg of 17 $\beta$  estradiol effect lasts for 6 months.

**Transdermal patch:** It contains 3.2 mg of 17 $\beta$  estradiol releasing about 50  $\mu$ g of estradiol in 24 hours. It should be applied below the waist line and changed twice a week.

## THERAPY

- Replacement therapy
- Pharmacotherapy

### Replacement therapy

**Hypo-ovarian function:** Estrogen daily  $\times$  21 days followed by norethisterone or medroxyprogesterone 5 mg  $\times$  last 10 days (see p. 446).

### Menopausal symptoms

- a. Cyclic or continuous therapy in the form of estradiol or conjugated estrogens.
- b. Postmenopausal hormone replacement therapy (HRT) in a symptomatic women (p. 62).
  - ◆ To reduce vasomotor symptoms.
  - ◆ To prevent osteoporosis.
  - ◆ To prevent cardiovascular disease.

It is administered either cyclic or continuous. Progestogen should be added to reduce endometrial carcinoma. However, in hysterectomized individuals, progestogen is not added. **It is especially indicated** in premature ovarian failure, gonadal dysgenesis and in surgical menopause (details in ch. 5).

**Pharmacotherapy:** The estrogen is most commonly used along with progestogen and as such, the use of the combined therapy is discussed later on. **The indications of only the estrogen therapy are mentioned here.**

**Oral contraception:** While the combined estrogen and progestogen preparations are widely used throughout the globe, estrogen in isolation is only used as postcoital contraception (details in ch. 29).

**Vaginitis:** Senile or atrophic vaginitis—either vaginal cream or oral estrogens may be equally effective (see ch. 5).

**Vulvovaginitis** in childhood, foreign body in the vagina or sexual assault—low dose of oral estrogen or vaginal cream helps in increasing the vaginal defence and hastens recovery (p. 543).

**Intersex state: In Turner's syndrome (45, XO)** or gonadal dysgenesis (46, XY), estrogen therapy is helpful for the growth and development of the secondary sex characters (see ch. 27).

In **androgen insensitivity syndrome (46, XY)**, after gonadectomy supplementary estrogen therapy is indicated to prevent regression of the breast development, osteoporosis and cardiovascular complications (see ch. 27).

The estrogen is used cyclically as ethinyl estradiol 0.01 mg twice daily for 25 days. However, in prolonged use, progestogen in the form of medroxyprogesterone acetate 10 mg daily is added

from day 16–25, to minimize the adverse effects of estrogen. Alternatively, a combined oral 'pill' may be prescribed.

**DUB:** The estrogen in pharmacological doses causes rapid growth of endometrium. As such, acute bleeding can be stopped by oral conjugated estrogen in a dose of 10 mg a day. The bleeding usually stops within 24 hours. Alternatively, 25 mg may be given intravenously every 4 hours for 3 doses (see p. 192).

**Delayed puberty:** If the breast development fails to start even at the age of 14, 10 µg of estrogen daily may be of help. In cases of irregular bleeding or when the breast development is well-advanced, progestogens may be added (ch. 5).

**Cervical mucus hostility:** To improve the quality of the cervical mucus in infertility, low dose of estrogen (ethinyl estradiol 0.01 mg) may be given cyclically, from day 1–14.

### An adjunct with clomiphene therapy

In cases of hypoestrogenic state with hypomenorrhea, small dose of estrogen is of help to improve the quality of the cervical mucus.

**Stress incontinence (GSI)** in postmenopausal women to improve the tone of collagen tissue (see p. 403).

**Comments:** Oral route with preparations of ethinyl estradiol is widely used because of its efficacy, low cost and minimal intolerance. Vaginal cream used in atrophic vaginitis has got its local and systemic effects.

TABLE 31.5

### CONTRAINDICATIONS OF ESTROGEN THERAPY (see P. 62)

- ◆ History of venous thromboembolism
- ◆ Active liver disease
- ◆ Severe hypertension
- ◆ Organic heart disease
- ◆ Estrogen dependent tumor (breast)

Intramuscular administration of progynon depot 10 mg at interval of one month is helpful as a prophylaxis against postmenopausal symptoms, following hysterectomy with bilateral salpingo-oophorectomy in premenopausal women.

**Adverse effects—Minor ailments are:**

- Nausea, vomiting
- Breast tenderness
- Breakthrough bleeding
- Weight gain

**Major effects include:** Increased incidence of endometrial carcinoma, thromboembolism, cerebral thrombosis and hemorrhage.

To minimize breakthrough bleeding and prevent endometrial carcinomas and vascular complications, progestogens should be combined with estrogen therapy.

**ANTIESTROGEN**

- Clomiphene
- Aromatase inhibitors
- Tamoxifen

**CLOMIPHENE**

Clomiphene citrate is a non-steroid triphenylethylene compound with a structure similar to that of stilbestrol. The commercially available form is a mixture of two isomers, enclomiphene—a potent anti-estrogen and zuclophene, a weak antiestrogen.

**Mode of action:** In the hypothalamus, clomiphene citrate binds to estrogen receptors, occupies the nuclear site for a long time (weeks). The negative feedback of endogenous estrogen is thus prevented. The frequency of pulsatile GnRH secretion is thereby increased which in turn results in rise of pulse frequency of both LH and FSH. Antiestrogenic effects are observed at the level of cervix and endometrium.

**Indications**

- Anovulatory infertility where other factors have been excluded.
- Induction of ovulation—The ideal case is one of normogonadotropic-normoprolactinemic disorders of ovulation.
- Assisted reproductive techniques in producing superovulation.
- Male infertility with defective spermatogenesis due to hypogonadotropic-hypogonadism.

**Mode of administration:** See p. 244.

**Adjuvant drugs:** Adjuvant drugs are used when there is failure with clomiphene therapy (p. 244).

**Contraindications:**

- ◆ Patients who are hypogonadotropic and hypoestrogenic.
- ◆ Presence of cystic ovaries.

**Side effects:** These include visual disturbances, headache, hot flushes, breast tenderness, abdominal discomfort, loss of hair, rashes and ovarian enlargement and multiple pregnancy. Hyperstimulation syndrome (see p. 529) is less likely.

**Results:** While successful induction can be achieved by 90 percent, pregnancy rate is about 50 percent. The **reduced pregnancy rate may be due to its** antiestrogenic effect on endometrium cervical mucus and the oocyte. There may be the presence of other factors for infertility including luteal phase defect and LUF (see p. 237). Chance of multiple pregnancy ranges 0–5 percent.

**AROMATASE INHIBITORS**

It inhibits the **enzyme aromatase** in the granulosa cells of ovarian follicles (p. 74, 75). It suppresses estrogen synthesis.

Letrozole 2.5 mg given from D<sub>3</sub> to D<sub>7</sub> increases the release of gonadotropins from the pituitary and stimulates development of ovarian follicle. Intraovarian androgens are increased which increase FSH sensitivity. As opposed to clomiphene, it has no peripheral antiestrogenic effects on the endometrium and the cervical mucus. Half-life of letrozole is 45 hours. Letrozole is used either as a firstline therapy (alternative to clomiphene) or in clomiphene-resistant women (p. 245) with anovulatory infertility. Pregnancy rates are comparable or better than that of clomiphene. Multiple pregnancy rates are low (monofollicular development). No increased risk of fetal congenital malformations has been observed with letrozole.

**Anastrozole**, another aromatase inhibitor is found to be effective in reducing the growth of pelvic endometriosis and in pain relief.

Aromatase inhibitors are primarily used for the treatment of breast cancer in postmenopausal women.

**TAMOXIFEN (SERMs) see p.61**

Tamoxifen is similar to clomiphene both structurally and functionally. It has got both estrogen antagonist and agonist effects.

- ◆ It is a competitive inhibitor to estrogen at the receptor site. Antiestrogenic function of raloxifene is more selective in uterus and breasts.
- ◆ It decreases antithrombin III and increases the sex hormone-binding globulin (SHBG) level (agonist action). Venous thromboembolism is increased.
- ◆ It can be used for induction of ovulation in doses of 20 mg per day for 5 days, in cases of intolerance to clomiphene.
- ◆ It is widely used for the treatment of benign breast diseases.
- ◆ In postmenopausal breast carcinoma, it is given in doses of 10 mg twice daily for 2 years as an adjuvant therapy. It is effective both in estrogen receptor positive and negative cases.
- ◆ In recurrent endometrial carcinoma, it inhibits the binding of estradiol to the estrogen receptor. Tamoxifen increases the progesterone receptors. A dose of 20–40 mg per day has been used. Low grade tumors and hormone receptor positive tumors have got better response.
- ◆ Raloxifene (p. 61) therapy (60 mg a day) is effective in regression of endometriosis.

**PROGESTERONE**

Progesterone is a natural hormone (C-21 steroid) produced mainly by the theca lutein cells of the corpus luteum. It is also secreted by the adrenal cortex in small amount. During pregnancy, placenta is the main source. Progesterone produces secretory changes in an estrogen primed endometrium. Natural progesterones are rapidly metabolized and inactivated when administered by the oral route and as such, it is to be used parenterally. During the last few decades, a number of compounds were synthesized having the properties of progesterone and could be given in tablet form. **These are called** progestational agents, gestagens, progestogens or progestins. Classification of progestogens and their grades of progestational activity are given in Tables 31.6 and 31.7.

**Uses:** ◆ Diagnostic ◆ Therapeutic

**Diagnostic**

**Progesterone challenge test:** In the investigation of pathological amenorrhea, this test is employed. If withdrawal bleeding occurs, it proves (i) intact hypothalamopituitary ovarian axis, (ii) there is adequate endogenous estrogen (>40 pg/ml), (iii) the endometrium is responsive and (iv) the uterovaginal canal is patent. The individual is likely to respond to ovulation induction drugs (p. 469).

**Dose:** Medroxyprogesterone acetate 10 mg daily for 5 days is given orally.

**Therapeutic indications**

**Contraception:** Combined preparations of estrogen and progestogen are widely used as contraceptive pill (see ch. 29). Uses of only progestogens as contraception are:

- ◆ Minipill (oral).
- ◆ Levonorgestrel: Emergency contraception (p. 492).
- ◆ Depomedroxyprogesterone acetate (DMPA) (injectable).
- ◆ Norethisterone enanthate: NET-EN (injectable).
- ◆ Implant (norplant subdermally) (p. 492).
- ◆ Vaginal ring containing levonorgestrel.
- ◆ LNG-IUS—containing L-norgestrel (p. 480).

**Dysfunctional Uterine Bleeding (DUB)**

Progestogen administration will cause secretory changes in the endometrium. Thus, it is very active in cases of anovulatory than in an ovulatory DUB. The therapy is ideal in puberty, adolescent and those approaching menopause.

To stop bleeding, norethisterone or norethisterone acetate 5 mg thrice daily is quite effective. To regulate the cycle, the same preparation is used from D<sub>5</sub>-D<sub>25</sub> or from D<sub>15</sub>-D<sub>25</sub> of cycle.

**Mode of action:** Progesterone decreases synthesis of estrogen receptors in the endometrium.

- ◆ It converts estradiol to less potent estrone through enzymatic action.



**TABLE 31.6 CLASSIFICATION OF PROGESTOGENS**

Progesterone Derivative	Progesterone Content
<b>I. Progesterone</b>	Natural progesterone
<b>II. Pregnane progestogens</b> They do not alter carbohydrate metabolism	<ul style="list-style-type: none"> <li>• 17a hydroxy progesterone caproate</li> <li>• Medroxyprogesterone acetate</li> <li>• Chlormanidone acetate</li> <li>• Cyproterone acetate</li> </ul>
<b>III. Norpregnane progestogens</b>	<ul style="list-style-type: none"> <li>• Nomegestrol acetate</li> <li>• Gestonorone caproate</li> </ul>
<b>IV. Stereoisomer of progesterone: Retroprogesterone</b> They do not inhibit ovulation	<ul style="list-style-type: none"> <li>• Dydrogesterone</li> </ul>
<b>V. 19 norprogesterone derivatives (norpregnanes)</b>	<ul style="list-style-type: none"> <li>• Demegestone</li> <li>• Promegestone</li> <li>• Nestorone</li> <li>• Trimegestone</li> </ul>
<b>VI. Alkyl derivatives of 19 nortestosterone</b> <b>A. Estrone steroids</b> They alter carbohydrate metabolism slightly. Metabolically, they are converted into norethisterone <b>B. Gonane steroids</b> They have excellent contraceptive efficacy and cycle control. Side effects are less. They are more potent than the estrone steroids	<ul style="list-style-type: none"> <li>• Norethisterone</li> <li>• Norethisterone acetate</li> <li>• Norethynodrel</li> <li>• Ethynodiol diacetate</li> <li>• Lynestrenol</li> <li>• Norgestrel</li> <li>• Levonorgestrel</li> <li>• Desogestrel</li> <li>• Etonogestrel (3 ketodesogestrel)</li> <li>• Gestodine</li> <li>• Norgestimate</li> <li>• Norelgestromin</li> <li>• Dienogest</li> </ul>
<b>VII. Spironolactone derivatives</b>	<ul style="list-style-type: none"> <li>• Drospirenone</li> </ul>
<b>VIII. Unsaturated 19 norsteroid</b>	<ul style="list-style-type: none"> <li>• Gestrinone</li> </ul>

**TABLE 31.7 METABOLIC EFFECTS OF PROGESTOGENS AND THEIR GRADES OF PROGESTATIONAL ACTIVITY**

Progestogens	Progestational activity	Androgenic activity	Antiandrogenic activity	Levels of SHBG ↓
1. Progesterone	1	-	+	-
2. Cyproterone acetate	4	-	+++	-
3. Medroxyprogesterone	4	+	-	+
4. Norethisterone	4	+	-	-
5. Norgestimate	4	+	-	-
6. Drospirenone	4	-	+	-
7. Dienogest	4	-	+	-
8. Nomegestrol	5	-	+	-
9. Levonorgestrel	6	++	-	++
10. Desogestrel	8	+	-	-
11. Gestodene	9	+	-	+
12. Nestorone	10	-	-	-
13. Trimegestone	10	-	+	?

Progestational activity is graded 1–10; considering progesterone as 1, 10 being the most potent  
SHBG = sex hormone binding globulin;  
(-) = no effect  
(+) = effect  
(++) = strong effect  
(+++)= very strong effect

- ◆ It inhibits mitotic activity of the endometrial cells.
- ◆ It induces the enzyme estradiol dehydrogenase—which degrades estradiol in the endometrium.
- ◆ Over all progesterone acts as an antiestrogen on the endometrium.

**Endometriosis:** The use of progestogens induces a hyperprogestogenic hypoestrogenic state. Progestogens cause decidualization of endometrial tissue. There will be atrophy of the glands, fibrosis and atrophy of the ectopic endometrial tissues.

The drugs commonly used are medroxyprogesterone acetate or dydrogesterone or derivatives of 19-norethisterone.

**Dose:** Norethisterone 5 mg or medroxyprogesterone 10 mg twice or thrice daily and continued for 6–9 months. The patient remains amenorrheic.

Alternatively, intramuscular injection of medroxyprogesterone acetate 100 mg every 2 weeks for 4 doses and then 200 mg every month for 4 doses will produce amenorrhea. This is suitable in cases of older women who have completed family.

**Dysmenorrhea:** Dydrogesterone 5 mg starting from day 5 for 20 days, relieves dysmenorrhea probably by inhibiting uterine contractions. The ovulation is not suppressed. Use of LNG-IUD and progestin implant (implanon) is found to be effective in cases with pelvic endometriosis or adenomyosis.

**Luteal phase defect (LPD) (see p. 247):** In a proven case, daily intramuscular injection of 12.5 mg progesterone in oil, beginning 2–3 days after the ovulation until menstruation occurs or if conception has taken place, until 10–12 weeks of gestation. Micronized progesterone 100 mg thrice daily can be administered either vaginally or orally. Vaginal suppositories 25 mg twice daily starting 2–3 days after the BBT rise is equally effective.

### Endometrial Hyperplasia and Endometrial Carcinoma

Its role in endometrial carcinoma depends on the number of steroid receptors on the tumor. **Well-differentiated grade I endometrial carcinoma has got the highest number of receptors.** These cases are suitable for progestogen therapy. Recurrent endometrial carcinoma having good steroid receptor status is also suitable.

**Dose:** 17 $\alpha$  hydroxyprogesterone caproate 1000 mg IM daily for 1 week, weekly for 3 months and thereafter at interval of 2 weeks for 1 year. Alternatively, medroxyprogesterone acetate 400 mg IM, weekly for 3 months and then every 2 weeks for 1 year.

**Premenstrual syndrome (see p. 185):** Controversy exists with the hypothesis that progesterone deficiency may be the cause. So progestogens have been tried to relieve the symptoms. Dydrogesterone 5 mg twice daily from day 5 for 20 days in each cycle for 3–6 cycles may be tried.

**Luteal support:** It is usually given on the day after oocyte retrieval for ART (see p. 251). Progesterone is used in any of these forms. • Progesterone in oil 50 mg IM daily. • Vaginal suppository 200 mg twice daily or • Micronized progesterone orally 200 mg twice daily. It is usually continued for about 14 days (see p. 252).

**Postponement of menstruation:** In order to postpone the menstruation, norethisterone preparation 5 mg tab thrice daily is to be taken at least 3 days prior to the expected date of menstruation. This should be continued till such time when the patient wishes to have her period. The period usually starts after 48–72 hours. **This should not be taken casually, as it may disturb the menstrual pattern.** There is no contraceptive protection during the period of intake of medicine.

**Hormone replacement therapy (HRT):** Progestins are combined with estrogen as an HRT for

**TABLE 31.8** SIDE EFFECT OF PROGESTOGENS

- Nausea—subsides gradually
  - Leg cramps
  - Mastalgia
  - Weight gain due to salt and water retention
  - Acne
  - Scanty periods
  - Loss of libido
  - Virilism
- } due to androgenic progestins
- Headaches—migraines should be excluded
  - Depression and mood changes—may be due to low level of pyridoxin as progestins alter the tryptophan metabolism.
  - Lipid profile—increase in LDL and decrease in HDL level.

postmenopausal woman whose uterus is present. This prevents endometrial hyperplasia. Progestins can be used cyclically for last 12–14 days of the cycle or continuously with estrogen (see p. 61).

### COMBINED PREPARATIONS (ESTROGEN AND PROGESTOGEN)

#### ■ Diagnostic ■ Therapeutic

**Diagnostic:** The combined preparations may be used as estrogen-progesterone challenge test in amenorrhea to exclude uterine pathology. **If bleeding fails to occur, it suggests uterine synechia.**

#### Therapeutic

- ◆ Contraception — The commonest and widely use of combined preparations is in the field of fertility control (details in ch. 29).
- ◆ Dysfunctional uterine bleeding (p. 191)
- ◆ Endometriosis (p. 310)
- ◆ Dysmenorrhea (p. 180)
- ◆ Postponement of period (p. 95)
- ◆ Premenstrual syndrome (p. 185)
- ◆ Idiopathic hirsutism—cyclic therapy of combined preparations containing 50 µg of ethinyl estradiol together with new progestin is more effective (see p. 575).
- ◆ Hormone replacement therapy (HRT) see p. 61.

### ANTI-PROGESTERONE

#### MIFEPRISTONE (RU 486)

It is a competitive antagonist of progesterone and glucocorticoid receptors. It is a derivative of 19-nortestosterone. It binds competitively to progesterone receptors and nullifies the effect of endogenous progesterone. As a result, there is an increased release of prostaglandins from the endometrium, resulting in menstrual bleeding or termination of early pregnancy.

Three important biochemical characters of RU 486 are **high affinity for progesterone receptors, long half life and active metabolites.**

#### Uses: Therapeutic abortion

It is an effective abortifacient upto 7 weeks. Combination of prostaglandins as vaginal pessary 48 hours after RU 486, increases its efficacy.

**Dose:** Tab 200 mg (1 tab = 200 mg) orally, followed 48 hours later by misoprostol 400 µg (PGE<sub>1</sub>) oral or 800 µg vaginal pessary. Success rate is 95–100 percent.

#### Emergency contraception

A single dose of 10 mg is to be taken on 27th day of the cycle irrespective of the day and number of intercourse. Efficiency is 95–100 percent.

**Induction of labor**—Mifepristone has been used for cervical ripening. It is given orally.

**Uterine fibroids**—Shrinkage of uterine leiomyoma has been observed following mifepristone therapy (25–50 mg daily) (see p. 280).

**Ectopic pregnancy**—Injection of mifepristone into the ectopic pregnancy (unruptured sac) is used as a medical management.

**Cushing's syndrome**—as it blocks the glucocorticoid receptors.

**Side effects:** Minor side effects are nausea, vomiting, headache and cramp. There is risk of ongoing pregnancy (failure of medical induction of abortion) in about 1 percent of cases. Evacuation of the uterus should be done for such a failure. Long-term use causes endometrial hyperplasia.

#### Contraindications:

- ◆ Age > 35 years
- ◆ Heavy smoker.
- ◆ Adrenal insufficiency
- ◆ Corticosteroid therapy

### ANDROGENS

In a female, androgen (testosterone) sources are adrenal cortex (25%), ovaries (25%) and in adipose tissues from peripheral conversion (50%). Most of the androgens are metabolized in the liver and are excreted as 17 ketosteroid. About **80 percent** of circulating testosterone is bound to **SHBG**, **19 percent to albumin** and **remaining 1 percent is free**. In adult female, blood testosterone level is around 20–80 ng/dl. Testosterone is converted to dihydrotestosterone within the target cell by the action of 5α reductase and then combines with the specific receptors and is transported to the nucleus.

Androgens are partly anabolic and effect sebum formation and are implicated in acne during adolescence. Testosterone, particularly, influences the growth of hair on face and body.

### Therapeutic Aspect

Androgens are not active by oral route. Methyl testosterone is used as sublingual tablets to bypass the enterohepatic circulation. **Its use in clinical practice is now a rarity.** In females, not more than 200 mg should be given in one cycle. In some sensitive women, even smaller doses may cause hirsutism and hoarseness of voice.

It may be used in cases of frigidity and premenstrual syndrome either orally or as an implant. In postmenopausal or perimenopausal woman, androgens are combined with estrogen to improve libido.

Its use in male infertility has been discussed in ch.16. Testosterone derivatives like danazol (isoxasole derivative of 17  $\alpha$ -ethinyl testosterone), gestrinone (19-nortestosterone derivative) are used in different clinical situations (see p. 311).

Anabolic hormones are androgenic steroids. These are of limited use for ill health and during convalescence. The preparations available are nonadrolone phenylproprionate (Durabolin) 25 mg IM per week or decadurabolin 25 mg IM at interval of 3–4 weeks.

### ANTI-ANDROGENS

- Cyproterone acetate    ■ Spironolactone
- Flutamide                ■ Finasteride

**CYPROTERONE ACETATE:** Cyproterone acetate is an anti-androgenic progestogen (17 OHP). **It inhibits gonadotropin secretion and also acts as a competitive androgen receptor antagonist.** It decreases 5 $\alpha$ -reductase activity and reduces LH secretion. It induces hepatic enzymes and increases the metabolic clearance of plasma androgens. It also acts as a potent progestogen having agonist effects on progesterone receptors.

**Use:** It is used in the idiopathic hirsutism or hyperandrogenic state (see p. 577).

**Dose:** Cyproterone acetate 2 mg is most frequently used in combination with ethinyl estradiol.

Available preparation (COCs) containing cyproterone acetate 2 mg and ethinyl estradiol 35  $\mu$ g may be given from day 5 for 21 days.

Treatment is to be continued for at least 6 months.

**Side effects are**—weight gain, loss of libido, mastalgia.

### SPIRONOLACTONE

**It is an androgen receptor antagonist. It is an antialdosterone diuretic. It also inhibits androgen biosynthesis from ovary and adrenal.**

- ◆ Inhibits 5 $\alpha$ -reductase activity.
- ◆ It competes with androgen at the receptor sites.

**Dose:** The dose varies from 25–150 mg per day. This may produce hyponatremia and hyperkalemia for which initial monitoring of serum potassium and creatinine is necessary at doses above 100 mg per day.

**Important side effects are:** Menstrual irregularity (DUB), fatigue, diuresis and electrolyte imbalance (hyperkalemia).

**Flutamide** is a **nonsteroidal androgen receptor antagonist.** It blocks the androgen receptor sites. Dose of 250 mg daily for 6 months is optimum. **Important side effects are** dry skin, decreased libido and hepatotoxicity.

**Finasteride** inhibits 5 $\alpha$ -reductase activity. A dose of 5 mg daily is effective for hirsutism without any side effects.

**Ketoconazole** inhibits the enzyme for androgen synthesis. A dose of 200 mg daily is adequate to reduce the level of androgens.

**Dexamethasone** and for other anti-androgens (see p. 575).

### ADRENOCORTICAL HORMONES

- Diagnostic    ■ Therapeutic

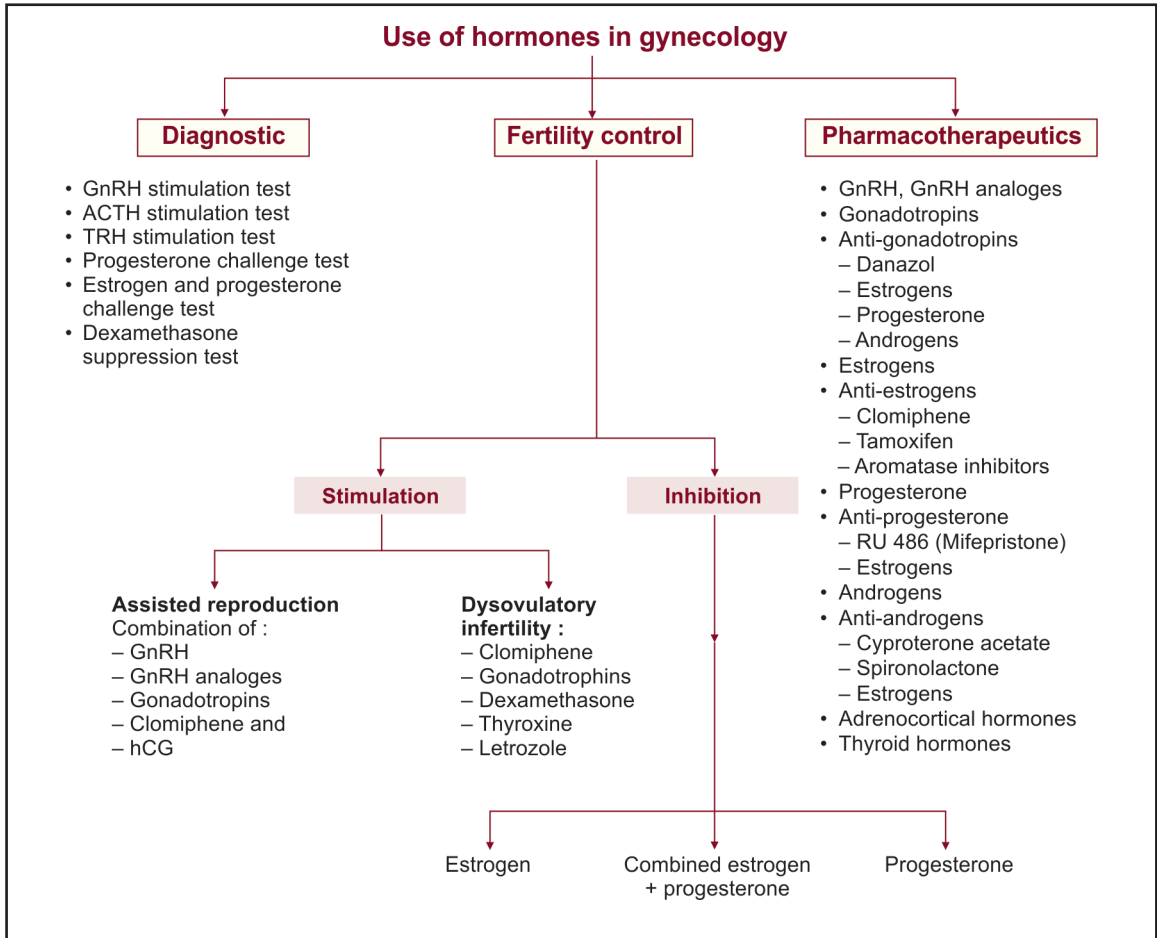
**DIAGNOSTIC: Dexamethasone suppression test**

#### Principle

A base level plasma cortisol is estimated at 8 a.m.

Dexamethasone 1 mg orally is given at 11 p.m.

Plasma cortisol level is estimated in the following morning at 8 a.m.



In normal individual, the cortisol levels are suppressed below 1.8  $\mu\text{g}/\text{dl}$ , but in Cushing's syndrome, the cortisol levels fall but do not go below 10  $\mu\text{g}/100\text{ ml}$ .

## THERAPEUTIC

Dexamethasone is used mostly in hyperandrogenic state.

- ◆ **Hirsutism**—Dexamethasone 0.25–0.75 mg tab daily at bedtime effectively suppresses ACTH. It is used for at least a period of 6–12 months. It should be withheld in obese patient.
- ◆ **Adrenal hyperplasia**—Dexamethasone 0.5–0.75 mg in divided doses.

- ◆ **Polycystic ovary**—Along with combined estrogen and progestogen preparations (oral pill), dexamethasone 0.25–0.5 mg is given at bed time.
- ◆ **As an adjuvant therapy** with clomiphene citrate in induction of ovulation with elevated LH.
- ◆ **Pubertal menorrhagia** due to idiopathic thrombocytopenic purpura.
- ◆ **Hydrotubation** along with antibiotics, in cases of partial tubal obstruction due to adhesions or following tubal anastomosis.
- ◆ **Intraperitoneal instillation** may be done to minimize adhesions during pelvic surgery, especially tubal microsurgery.
- ◆ **Local antipruritic cream.**

## THYROID HORMONE

**Hypothyroidism** is often associated with menorrhagia or oligomenorrhea and amenorrhea. It is

associated with recurrent miscarriage and subfertility. After the diagnosis is established by RIA of TSH, T<sub>4</sub> and T<sub>3</sub>, substitution therapy with eltroxin is given orally as per the need (see p. 243).

### KEY POINTS

- GnRH stimulation is used to differentiate an amenorrhea of pituitary or hypothalamic in origin. The absence of response usually denotes pituitary fault.
- For induction of ovulation, GnRH is effective in cases of idiopathic hypogonadotropic hypogonadism.
- **GnRH analogues** (agonists and antagonists) have been synthesized by substitution of amino acids at different position of GnRH molecule (p. 525). GnRH antagonists has got some advantages over GnRH agonist (Table 31.2).
- The GnRH analogues stop the normal pattern of GnRH secretion leading to loss of pituitary GnRH receptors and thereby down regulation. This leads to fall in pituitary gonadotropins and consequently the gonadal secretion. The net effect is of medical hypophysectomy.
- GnRH analogues are used for superovulation in IVF program and in therapeutic considerations to all conditions related to high estrogen level such as precocious puberty, endometriosis, fibroid, DUB, breast carcinoma and the alike. In achieving superovulation, either a long protocol or a short protocol regimen is followed under proper monitoring.
- Gonadotropic hormones act on the ovaries to induce ovulation. Both FSH and LH (Pergonal) or pure FSH (Metrodin) are available and are obtained from the urine of postmenopausal women. hCG is obtained from the urine of pregnant women.

Gonadotropins are expensive and require close monitoring not only for induction of ovulation but also to prevent hyperstimulation syndrome. The induction of ovulation with gonadotropins is indicated in hypogonadotropic hypogonadism with or without amenorrhea and in failed clomiphene, in patients with PCOS.

There is increased incidence of multiple pregnancy (20–30%) and hyperstimulation syndrome (1–20%).

- Ovarian hyperstimulation syndrome usually appears about 3–6 days after the ovulating dose of hCG.

Increased vascular permeability due to VEGF and activation of NO system, leads to leakage of fluid from peritoneal and ovarian surfaces. OHSS may be mild (10–20%), moderate (5–10%) or severe (1–2%) (p. 529).

In severe cases, correction of hypovolemia, electrolyte imbalance, metabolic acidosis and blood coagulopathy have to be done. Intensive care monitoring may be needed for a few (p. 529, 530).

- **Ovarian reserve** means the quantity as well as quality of the follicles present in the ovary. There are tests to determine the ovarian reserve. Poor ovarian reserve indicates poor outcome following stimulation of ovulation (p. 528).
- Danazol is strictly an anti-gonadotropin but acts as an androgen agonist. Its use is wide like that of GnRH analogues. It should be started in the early follicular phase and barrier methods of contraception should be used. The side effects are due to hypoestrogenic, androgenic and metabolic changes (see Table 31.4). The drug should be discontinued, if the patient develops hirsutism or hoarseness of voice.
- Gestrinone is an androgen agonist and progesterone agonist-antagonist. The dose is 2.5 mg twice or thrice a week. Side effects are like those of danazol but less marked.

*Contd...*

Contd...

- The sex hormones are transported in the blood nonspecifically by albumin and specifically by SHBG.  
Cell nucleus is the principle site of action of the steroids as opposed to the cell membranes of gonadotropins.  
Estrogens are used as replacement therapy (HRT) in postmenopausal women even in otherwise symptom-free cases to prevent osteoporosis and cardiovascular disease.
- Clomiphene is antiestrogenic. In the hypothalamus, it binds to the estrogen receptors preventing the negative feedback effect of endogenous estrogens to GnRH resulting in more synthesis of gonadotropins.
- Tamoxifen is also an anti-estrogen and is widely used in benign breast disease. Raloxifen is a more selective antiestrogen.
- **Letrozole** is a specific aromatase inhibitor. It inhibits the enzyme aromatase to suppress synthesis of estrogen. It enhances the secretion of pituitary FSH for the growth and development of follicles. It is used for induction of ovulation in women with anovulatory infertility.
- **Progestogens** are classified according to their structural derivatives and progestogen content (Table 31.6). They are also classified according to their metabolic effects and also with the grades of progestational activity (Table 31.7).
- Progestogens are used as diagnostic test to evaluate the cause of amenorrhea. In presence of withdrawal bleeding, it signifies intact hypothalamo-pituitary ovarian axis and there is endogenous estrogen production.
- Combined estrogen and progestogen preparations are commonly used as oral contraceptives.
- Ru 486 is anti-progesterone and is effective in termination of early pregnancy.
- The source of androgens in female are adrenal, ovary and peripheral adipose tissues. The blood level of testosterone in female is less than 1 ng/mL. Virilization is usually associated with testosterone level > 2 ng/mL.
- Cyproterone, spironolactone, flutamide and finasteride are antiandrogens. These are used in idiopathic hirsutism and hyperandrogenic state (p. 575).
- Dexamethasone suppression test is of help to differentiate Cushing's syndrome (adrenal tumor) from Cushing's disease (increased pituitary secretion of ACTH); level of plasma cortisol  $\leq 5 \mu\text{g/dL}$  largely excludes Cushing's syndrome.

# Gynecologic Problems from Birth to Adolescence

## INTRODUCTION

Those who are familiar with adult gynecology are often confused and embarrassed to deal with gynecologic problems of pediatric and adolescent group. The problems are peculiar to this particular period.

Pediatric and adolescent gynecology encompasses gynecologic diseases of children from birth to adolescence. It covers a spectrum of gynecological problems including congenital anomalies, problems due to infection (vulvovaginitis), precocious development, menstrual abnormalities and neoplasm. To prevent the problems of teenage pregnancy and sexually transmitted infections, contraceptive counseling has a place. Children are mostly accompanied by the parents for the problems.

For descriptive purpose, the entire span from birth to adolescence is arbitrarily divided into three phases. Each phase has got distinct problems of its own.

- ◆ Neonates, toddlers and infants <5 years.
- ◆ Premenarchal 5–11 years.
- ◆ Perimenarchal to adolescence 12–18 years.

**Gynecologists need specific communication skill considering the psychological and developmental milestones of the girl child and the adolescent.**

## NEONATES, TODDLERS AND INFANTS

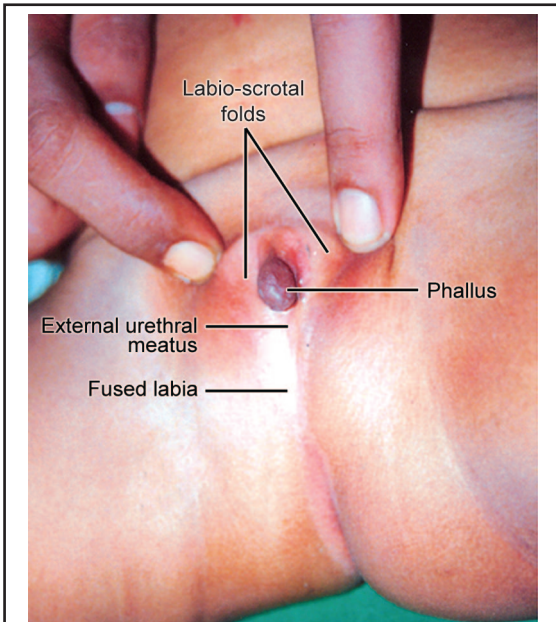
### CLITORAL ENLARGEMENT

**Causes:** Not infrequently, female babies are born with slightly enlarged clitoris. There is usually no evidence

**TABLE 32.1 COMMON CLINICAL PROBLEMS IN DIFFERENT PERIODS**

Period	Common problems
<b>&lt; 5 years</b> (Neonates, toddlers and infants)	<ul style="list-style-type: none"> <li>◆ Diagnosis of sex at birth (Clitoral enlargement)</li> <li>◆ Genital crisis</li> <li>◆ Labial adhesions</li> <li>◆ Imperforate hymen               <ul style="list-style-type: none"> <li>– Hydro or mucocolpos</li> </ul> </li> <li>◆ Ectopic anus</li> <li>◆ Nipple discharge</li> </ul>
<b>5–11 years</b> (Premenarchal)	<ul style="list-style-type: none"> <li>◆ Vulvovaginitis in childhood</li> <li>◆ Abnormal vaginal discharge</li> <li>◆ Vaginal bleeding</li> <li>◆ Precocious puberty (see p. 51)</li> <li>◆ Trauma to the genital tract (Ch. 26)</li> <li>◆ White lesion of the vulva (Ch. 17)</li> <li>◆ Neoplasm (Ch. 23)</li> </ul>
<b>12–18 years</b> (Perimenarchal to adolescence)	<ul style="list-style-type: none"> <li>◆ Menstrual abnormalities (see p. 54)</li> <li>◆ Delayed puberty (see p. 54)</li> <li>◆ Hirsutism (see p. 571)</li> <li>◆ Neoplasm (Ch. 23)</li> <li>◆ Primary amenorrhea (p. 450)</li> <li>◆ Leucorrhoea (see p. 551)</li> <li>◆ Congenital anomalies of the vagina (vaginal anomalies (see p. 41) and uterine anomalies (see p. 44).</li> <li>◆ Intersex (see p. 439)</li> <li>◆ Miscellaneous problems</li> </ul>





**Fig. 32.1:** Newborn baby with enlarged phallus due to adrenogenital syndrome causing confusion in the diagnosis of sex

of intrauterine androgen stimulation of the child. Careful history taking reveals development of some degree of masculinizing features of the mother during pregnancy, probably due to increased adrenocortical activity (Fig. 32.1).

Rarely, the enlargement may be one of the manifestations of intersexuality of type, female pseudohermaphrodite. This may cause confusion in the determination of sex at birth. The details have been mentioned in Chapter 27 (Fig. 27.1).

**Management:** In the idiopathic group, no treatment is required. However, an apparently female child with enlarged phallus and impalpable gonads requires at least estimation of serum 17-OHP, urinary 17 ketosteroid and chromosomal analysis to rule out congenital adrenal hyperplasia (see p. 440) (Fig. 32.1).

**GENITAL CRISIS:** It includes spectrum of disorders noticed within few days of birth. It is due to the effect of passive estrogenic stimulation, which has passed across the placenta from the mother. The presence of the estrogen so obtained produces changes in the endometrium and other target tissues such as breasts and cervical glands.

**Bleeding per vaginum:** It usually occurs within 10 days following birth; mostly blood stained but, at times, frank bleeding. This is due to decline in level of estrogen, which is unable to support the endometrium, resulting in withdrawal bleeding. There is no cause for concern.

**Enlarged breasts:** Due to effect of maternal estrogen and progesterone, there may be some development of duct and alveolar system of the breasts. Withdrawal of hormonal suppression of prolactin leads to discharge from the nipple called 'witch's milk'. No treatment is required; only assurance is enough.

**Neonatal leucorrhea:** This is due to excessive secretion of cervical mucus from the hypertrophied cervical glands under the influence of estrogen.

**Labial adhesion (Adhesive vulvitis)** is the condition when the Labia minora have adhered together.

**Causes:** Commonly, it is due to mild infection of the vulva which is favoured by lack of local defense due to absence of estrogen. There is denudation of the surface epithelium of the labia minora → adhesions.

The adhesions of the labia minora start from behind forward leaving a small opening at the foremost tip through which urine escapes out.

Rarely, it may be a manifestation of minor form of masculinization following maternal intake of androgen during pregnancy.

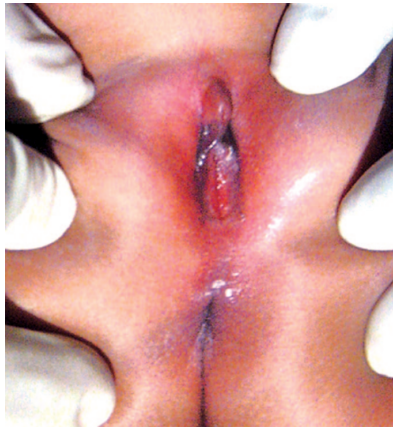**Diagnosis:** The condition usually appears within 2–3 years of birth. The mother usually, anxious about the entity, brings to the notice of the physician for not visualizing the vaginal opening. The adhesions may cause difficulty in micturition or periodic attacks of urinary tract infection. There may be inflammation of the vestibule and vagina.

Examination reveals adhesions of labia minora obliterating the vaginal opening and, at times, even the external urethral meatus (Fig. 32.2A). A thin vertical line in midplane is pathognomonic for this adhesive vulvitis.

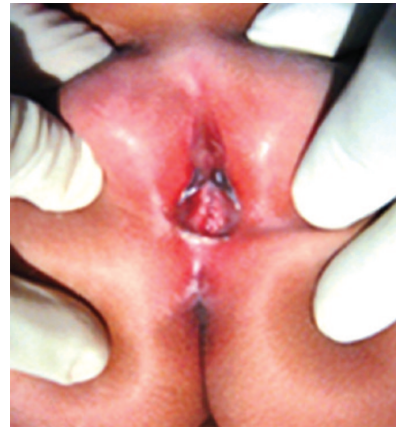Confusion arises with:

- ✦ Imperforate hymen
- ✦ Agenesis of vagina    ✦ Intersex.

In imperforate hymen and agenesis of vagina, the labia minora and external urethral meatus are clearly visible. In intersexuality, there is usually associated clitoral enlargement (see p. 440).



**Fig. 32.2A:** Labial adhesions in a 1½-year-old girl



**Fig. 32.2B:** Separation of adhesions by fingers. Local application of estrogen ointment is also helpful

**Treatment:** Separation of the adhesions using fingers or by a probe is almost always effective (Fig. 32.2B). The raw area is treated with topical application of estrogen or any other antibiotic ointment to prevent reagglutination. Good perineal hygiene should be maintained.

There is a tendency of recurrence. If it does, in spite of repeated separations, it is better to await spontaneous cure at puberty because of high-level endogenous estrogen.

### MUCO OR HYDROCOLPOS

**Pathophysiology:** There is imperforate hymen or a transverse vaginal septum just above the hymen. Due to excess estrogen stimulation acquired *in utero* from the mother, there is increased secretion of mucus or watery discharge from the cervical and uterine glands. If a large quantity of fluid is collected in the vagina, it produces hydro or mucocolpos. It may rarely be big enough to produce an abdominal swelling.

This is rarely met beyond 1 year of age because the uterine and vaginal transudation is not produced in sufficient quantity beyond that age.

Later on, the candidate may be the subject of hematocolpos → hematometra.

### Clinical features

There are usually some urinary problems to the extent of retention of urine. Variable degrees of pain in lower abdomen are a constant feature.

Abdominal examination reveals a lower abdominal lump. Distended bladder makes the lump apparently bigger.

Vulval inspection reveals a tense bulge of the obstructing membrane which looks shiny. Rectal examination confirms the vaginal bulge.

**Treatment:** Cruciate incision is enough to drain the pent-up mucus. Antibiotic is given. Head end is to be raised.

**OVARIAN ENLARGEMENT:** After the withdrawal of maternal estrogen, there is transient elevation of gonadotropins in neonates. This influence of elevated gonadotropins can stimulate to produce ovarian follicular cysts. These usually regress spontaneously. As such, the cysts need no surgery unless complicated.

**ECTOPIC ANUS:** The anal canal may open either in the vestibule or in the vagina. The details have been described in Chapter 4.

### PREMENARCHAL

**VULVOVAGINITIS:** The premenarchal girls are especially vulnerable to vaginal infection because of:

- ◆ Lack of or very low level of circulatory estrogen → lack of stratification of vaginal epithelium → lack of glycogen and absence of Doderlein's bacillus → no acid formation → vaginal pH remains high, around 7.
- ◆ Inadequate perineal hygiene.
- ◆ Lack of protective pubic hair and fatty pads of labia majora.

As the vaginal infection is almost always associated with vulvitis, the terminology of **vulvovaginitis** is appropriate.

**Causes:** The infection may be due to nonspecific or specific organisms.

I. The nonspecific organisms (common)

The infection is *polymicrobial* in nature and it is difficult to pinpoint any particular one responsible for infection. The organisms are, however, of low virulence.

II. Specific

■ Nongonococcal (common)

- *Streptococcus*
- *Chlamydia trachomatis*
- *E. coli*
- *Gardnerella vaginalis*
- *Candida albicans*
- *Trichomonas vaginalis*

■ *Gonococcus*

III. Foreign body

IV. Threadworm infestation

V. Following systemic illness

- Viral infection like measles, chickenpox
- Juvenile diabetes
- Herpes simplex

VI. Following antibiotic therapy

VII. Skin conditions

- Lichen sclerosus
- Psoriasis
- Eczema

**Sources of infection**

- ◆ Direct contact with infected person.
- ◆ Indirect from foreign body, infected towel or bath tub and intestinal infestation.
- ◆ Associated juvenile diabetes or antibiotic therapy favors monilial infection.

**Symptoms**

- Vaginal discharge: Purulent or blood-stained in the presence of foreign body.
- Pruritus or soreness in external genitalia.
- Painful urination.
- Vaginal bleeding.

**Signs:** Vulva becomes edematous and red or even ulcerated. Vaginal inspection using aural speculum reveals congested epithelium with pent-up discharge.

The offending foreign body may be detected. The examination may be done under anesthesia. It should be remembered that the vaginal epithelium in young girls looks red. **Rectal examination** is often helpful to detect the foreign body.

**Investigations:**

- Examination under anesthesia
- **Vaginoscopy** is needed to visualize the upper vagina for bleeding, foreign body or neoplasm. Specially designed speculum (Huffman Graves) is inserted into the vagina. For better visualization, water cystoscope (to wash away secretions, debris or blood) or laparoscope (8 mm) may be used.

Bacteriological examination of the discharge either by gram stain or hanging drop preparation or culture, to identify the causative organism (see p. 166).

- Smear from the anal area for detection of pin or threadworm.
- Stool examination may reveal the threadworm.
- Blood examination for estimation of sugar in suspected cases of juvenile diabetes.
- Urine for protein, sugar and culture study.

**Treatment:** As the cause remains obscure in majority, the principles to be followed are:

- **Vulvar hygiene**—Proper wiping will reduce rectal flora in the vulvovaginal area.
  - Sitz baths are very helpful in relieving symptoms (baking soda in water).
  - Scrubbing the vulvar area is avoided.
  - To keep the local area dry.
  - To wear cotton undergarments.

**Medication**

- To reduce the overgrowth of pathogenic bacteria, Amoxicillin 20–40 mg/kg/day in 3 divided doses is effective.
- In refractory cases, estrogen locally as cream twice daily for 3 weeks is effective to improve the vaginal defense and to promote healing.

**Specific therapy**

- Trichomoniasis is treated by metronidazole (100 mg thrice daily for 10 days).
- Monilial infection is treated by local application of clotrimazole 1 percent cream.

- For gonococcal vaginitis (see p. 147).
- Associated systemic illness should be treated by intramuscular antibiotic therapy.
- Foreign body is to be removed followed by use of estrogen therapy.
- Helminth is eradicated by oral use of Albendazole.

**LEUCORRHEA (See P. 551):** As the puberty approaches, there may be excessive white discharge per vaginum. It is nonoffensive and nonirritant. It is due to excessive production of mucus from the cervical glands and increased transudation from the vaginal epithelium.

**NEOPLASM:** The neoplastic conditions encountered during this period are usually ovarian in origin and rarely from the cervix and vagina. The ovarian neoplasms (see p. 383) are malignant in about 25 percent. Germ cell tumors are common (70%). Granulosa cell tumor is estrogen-producing tumor and may cause precocious puberty. Mixed germ cell tumor is highly malignant and dysgerminoma is intermediary in position, provided the capsule remains intact. The benign tumors are cystic teratoma (30%) and epithelial tumors (see p. 291, 293).

**Sarcoma botryoides:** It should be remembered that the entity is most often present as early as 2 years of age (see p. 369).

**VAGINAL BLEEDING—Common causes are:**

- Precocious puberty/Isolated menarche.
- Foreign body in the vagina.
- Trauma/Infection.
- Sexual abuse.
- Neoplastic conditions (mentioned earlier).
- Leech bite.
- Prolapse of the urethral mucosa.

**Leech bite:** This is more prevalent in tropics where pond bath is quite common. The bleeding may, at times, be brisk and requires varying amount of blood transfusion. Bleeding usually stops spontaneously but may, at times, require hemostatic suture.

**Prolapse of the urethral mucosa:** it presents as a vascular swelling surrounding the external urethral meatus which bleeds easily. Prolapse may be partial or complete (entire 360° urethra). Treatment is conservative. Local application of estrogen cream is found helpful. Surgery is needed rarely when necrosis is present.

## POSTMENARCHAL TO ADOLESCENCE

### ADOLESCENCE

The period of life beginning with the appearance of secondary sex characters and terminating with cessation of somatic growth is described as adolescence. **The problems during the period are:**

- ◆ Menstrual disorders.
- ◆ Delayed puberty (see p. 54).
- ◆ Delayed manifestations of intersex.
- ◆ Hirsutism.
- ◆ Leucorrhoea.
- ◆ Neoplasm.

**MENSTRUAL DISORDERS:** The neurohormonal mechanism essential for maintenance of normal menstruation takes some time (usually 2–3 years) to come to a normal balance. Till then, various types of menstrual abnormalities may occur, causing concern to the young girls or their parents (see p. 54).

### Common Causes of Menstrual Irregularity

#### A. Hypothalamic-Pituitary-Ovarian (HPO) axis dysfunction

- ◆ Dysfunctional uterine bleeding (see p. 54)
- ◆ Stress (see p. 463)
- ◆ Obesity (see p. 573)

#### B. Endocrinopathies

- ◆ Thyroid dysfunction (see p. 456)
- ◆ PCOS (see p. 459)
- ◆ Prolactinoma (see p. 464)
- ◆ CAH (see p. 466)

### Other Causes of Abnormal Vaginal Bleeding

#### C. Inflammatory

- ◆ Vulvovaginitis
- ◆ Endometritis
- ◆ PID

**D. Traumatic**

- ◆ Foreign body
- ◆ Sexual abuse
- ◆ Drug effects

**E. Others**

- ◆ Pregnancy (abortion problems)
- ◆ Bleeding disorders (Idiopathic thrombocytopenic purpura, see p. 185).
- ◆ Local—Polyps, neoplasms (see p. 285).

**Management:** Improvement of general health and assurance are enough in majority. It is expected that after a certain period of time, the menstrual cycles become normal with the onset of regular ovulation.

The unresponsive or problematic cases have been dealt with in appropriate chapters.

**DELAYED MANIFESTATIONS OF INTERSEX:** While majority of cases of intersex are diagnosed at birth, there are cases where the diagnosis is only revealed after puberty. These are:

- ◆ Mild degrees of congenital adrenal hyperplasia (see p. 440) with late manifestations of postpubertal hyperandrogenism (Fig. 33.4).
- ◆ Gonadal dysgenesis (see p. 441).
- ◆ Androgen insensitivity syndrome (see p. 443).

**HIRSUTISM:** Hirsutism is one of the manifestations of hyperandrogenism and often causes problems to the young girls. One should not forget to elicit iatrogenic cause of hirsutism following intake of androgenic steroids, corticosteroid or synthetic progestogens. The causes and management of hirsutism are discussed in p. 544.

**LEUCORRHEA:** Excessive normal vaginal secretion in this period may be due to:

- ◆ Relative hyperoestrogenic phase.
- ◆ Malnutrition and ill health.
- ◆ Congenital ectopy (erosion).
- ◆ Sexual excitement or masturbation.
- ◆ Vaginal adenosis.

**VAGINAL ADENOSIS:** Vaginal adenosis is present in about 30–50% of the teenagers who had DES exposure *in utero*. This is a benign condition. In these

girls, the junction between the müllerian ducts and the sino-vaginal bulb may not be sharply demarcated. As the Müllerian elements invade the sino-vaginal bulb, remnants may remain as areas of adenosis in adult vagina. The columnar epithelium of the endocervix extends onto the ectocervix and also variable part of the vaginal fornices. There is thus copious vaginal secretion from the columnar epithelium. The pathology regresses spontaneously in due course of time. Rarely, it may progress to clear cell carcinoma (see p. 339).

**Congenital ectopy** producing copious discharge should be cauterized. In others, assurance and improvement of general condition cure the state.

Infective discharge during the period may be due to:

- ✎ Nonspecific infection following unhygienic use of menstrual pads or foreign body in the vagina.
- ✎ Specific infections such as *Trichomonas vaginalis* or monilial infection.
- ✎ New growths from the vagina or cervix.

The investigations and management have been mentioned earlier in this chapter.

**NEOPLASM: Ovarian**—Functional cysts which are rare in premenarchal period are quite common during this period. They are usually 6–8 cm in diameters and usually regress within 3–6 months. These are usually follicular cysts.

**Commonest neoplastic cyst** during this period is cystic teratoma (dermoid cyst). The others, though rare, are benign epithelial tumors, dysgerminoma, mixed germ cell tumor or androblastoma. **Germ cell tumors constitute 50–75 percent of all ovarian neoplasms in this age group (see p. 381).**

The patients usually come late with symptoms. Common symptoms are lump in the lower abdomen, acute pain abdomen or, at times, with retention of urine.

**Diagnosis:** The diagnosis is made by abdominal, bimanual vaginal or rectal examination. Ultrasound is an invaluable tool in the diagnosis of ovarian mass. CT, MRI may be needed in few cases of pelvic mass with uncertain diagnosis. Pre-operative work-up needs tumor markers estimation (serum CA 125,

$\alpha$  fetoprotein, hCG, inhibition, CEA and testosterone) in these adolescent girls.

**Treatment:** A suspected functional cyst (6–8 cm) may be observed for 3–6 months. Unilocular functional cysts usually resolve spontaneously. Surgical therapy is needed in cases where there are symptoms, masses that fail to resolve or masses with solid or multilocular appearance on ultrasound.

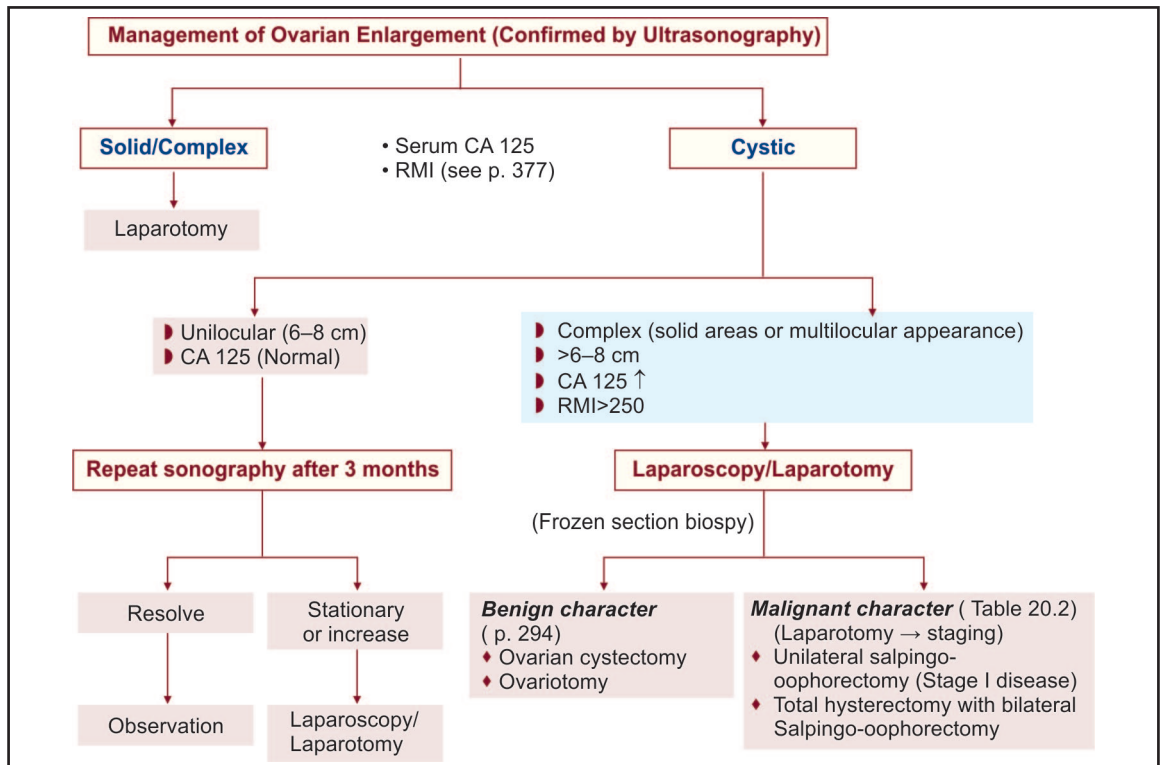
**Laparoscopy** is usually done when an adnexal mass appears to be benign. However, prompt **laparotomy should be done when there are evidences of malignancy.**

**The surgery is usually conservative** (ovariotomy or ovarian cystectomy) considering her future fertility and endocrine functions. Adolescent groups usually have borderline epithelial or germ cell tumors. In such a situation, the affected ovary is removed and a formal staging is done (fertility sparing surgery). Unilateral salpingo-oophorectomy is justified for most young girls with stage-I (Stage IA or IB) (see p. 380), Grade

TABLE 32.2	COMMON CAUSES OF LUMP IN LOWER ABDOMEN
<5 years	— Hydro or mucocolpos
	— Retention urine due to vulvovaginitis
5–11 years	— Pelvic neoplasm
	— Pregnancy
	— Retention of urine
12–18 years	— Ovarian tumor
	— Hematometra
	— Encysted peritonitis

1 or 2 disease. Germ cell tumors are highly responsive to chemotherapy (see p. 384). However, if the capsule is ruptured, radical surgery, i.e. total hysterectomy with bilateral salpingo-oophorectomy is to be done followed by radiotherapy or chemotherapy.

A problem may arise when an apparently cystic epithelial benign ovarian tumor is removed, which ultimately proves malignant histologically. In such cases, in consultation with an oncologist,



chemotherapy followed by relaparotomy and removal of uterus with contralateral tube and ovary may be done. This should be followed by chemotherapy.

Alternatively, the patient may be treated with chemotherapy alone with follow-up.

**Uterus**—Sarcoma botryoides (see p. 369).

**Vagina**—Clear cell adenocarcinoma of the vagina (see p. 339).

### SEXUALLY TRANSMITTED DISEASES (STDs)

STDs are increasing among the adolescents. The younger the age of first intercourse, the higher the risk for STDs. *Chlamydia* infection, though most common, other infections are HPV (see p. 323), HIV (see p. 153), Gonorrhea (see p. 147), Hepatitis B, Syphilis (see p. 148) and others (see Ch. 11). Impact on health due to STD complications include: cervical metaplasia, PID and its consequences (see p. 132).

Major problems faced with the management of adolescent STDs are denial of history and symptoms. Fear and social embarrassment cause delay or, at times, incomplete treatment.

#### Treatment

Sex education among the adolescent girls, practice of safer sex and maintenance of perineal hygiene are essential. Proper use of condoms protects STDs.

**Treatment of STDs** among the adolescents is the same that for the adults (see p. 148).

### MISCELLANEOUS PROBLEMS

**ACNE:** This is of concern due to cosmetic reason. The cause is due to excess androgen secretion by the adrenals. Assurance is enough. No treatment is required. It passes off spontaneously.

**OBESITY:** Obesity is best assessed by calculating body mass index (BMI). BMI is expressed (see p. 666) as weight (kg) divided by the height squared ( $M^2$ ). Ideal BMI should be between 20 and 24. BMI 25 or more is called over weight, Whereas BMI 30 or more is considered obese. Obesity increases the risk of cardiovascular (e.g. hypertension) and metabolic (e.g. diabetes) diseases (see p. 573).

Usually, it is due to overeating and constitutional. Rarely, it may be due to hypofunction of pituitary or manifestation of Cushing's syndrome or PCOS (see p. 459) even at a younger age.

**ABNORMAL HEIGHT:** Apart from constitutional as found in premenarchal period, **abnormal tallness** is due to:

- ◆ Hypersecretion of the growth hormone from the anterior pituitary. This may be due to pituitary eosinophilic adenoma resulting in gigantism. The treatment is excision of the pituitary adenoma. If the features are well-established, it is, however irreversible.
- ◆ Primary ovarian failure—There is lack of endogenous estrogen → delayed closure of the epiphysis of long bones. There is associated unopposed action of the growth hormone from the anterior pituitary resulting in linear growth of the long bones (see p. 463).

### KEY POINTS

- Undue clitoral enlargement seen at birth may be due to intersexuality. It requires at least estimation of 17-OHP, 17 ketosteroid and chromosomal analysis. Levels of 17-OHP >800 ng/dL are virtually diagnostic of congenital adrenal hyperplasia (21-hydroxylase deficiency).
- Genital crisis is due to hyperestrogenic state and includes bleeding per vaginum, enlarged breasts and neonatal leucorrhoea (see p. 543).
- Labial fusion is commonly due to infection and rarely a feature of intersexuality. Separation of the adhesions is effective using fingers or a probe (see p. 543).

Contd...

- ▶ Muco or hydrocolpos is usually found within 1 year of age and results from imperforate hymen.
- ▶ The childhood vulvovaginitis is mainly due to poor perineal hygiene. Vulvovaginitis in premenarchal period is mostly due to non-specific organisms and occasionally to specific gonococcal infection. Bacteriological examination should be carried out from the discharge prior to therapy.
- ▶ Ovarian follicular cysts are common in adolescent girls and are usually self-limiting. An ovarian enlargement more than 5 cm needs to be investigated.
- ▶ The neoplasm in premenarchal period is usually ovarian and, in about 25 percent, it is malignant. The common type is germ cell tumor (benign cystic teratoma, dysgerminoma, mixed germ cell tumor). The others are granulosa cell tumor or epithelial tumors. The benign tumors are epithelial tumors.
- ▶ Sarcoma botryoides is most often observed before the age of 8 (see p. 369).
- ▶ In a tall girl—to achieve arrest of bone growth, estrogen therapy for 3–6 months may be effective.
- ▶ The menstrual disorders in adolescent period are usually self-limiting and the hormones should not be used injudiciously. Assurance and improvement of health are enough in majority.
- ▶ Vaginal adenosis is present in about 30–50 percent and is a benign lesion. Rarely, it progresses to clear cell carcinoma.
- ▶ Commonest ovarian neoplasm in adolescence is benign cystic teratoma (see p. 293).
- ▶ STDs are increasing among the adolescents. Sex education, use of condoms and treatment of STDs are essential (see p. 549).
- ▶ Obesity is best assessed by calculating body mass index (BMI) (p. 666).



# Special Topics

## ABNORMAL VAGINAL DISCHARGE

### INTRODUCTION

Abnormal vaginal discharge is a frequent complaint of women seen in the gynecologic clinic. The discharge may range from what is called excess of normal to one which is a part of wide spectrum of ailments. It may be blood-stained or contaminated with urine or stool, all of which are however excluded from the discussion made below.

**Characteristics of normal vaginal fluid:** It is watery, white in color, nonodorous with pH around 4.0. Microscopically, it contains squamous epithelial cells and a few bacteria. Lacto-bacilli (Doderlein bacilli, p. 7), few gram-negative bacteria and anaerobes are present without any white or red blood cells.

**Causes of abnormal discharge** are schematically presented below in (Table 33.1):

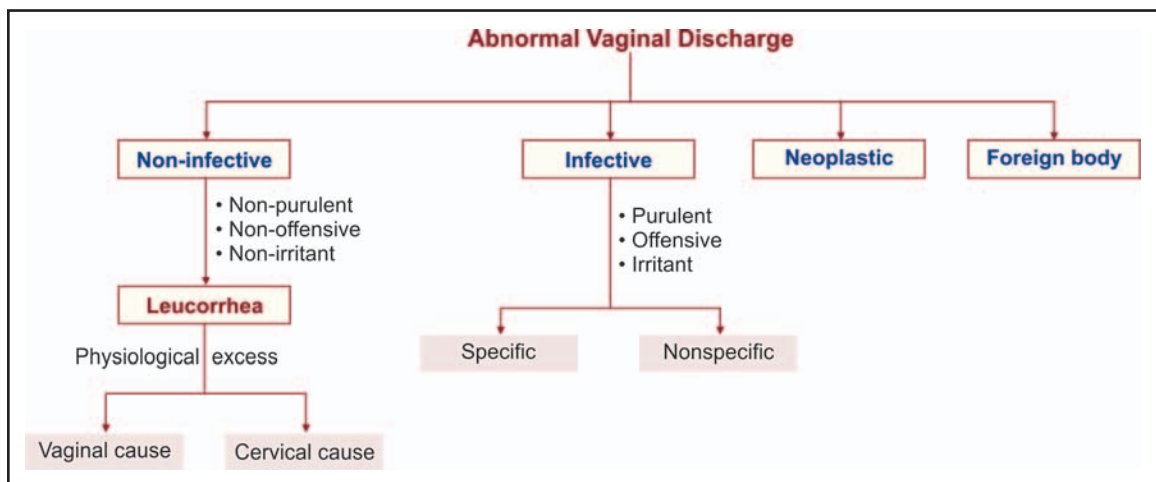
## LEUC(K)ORRHEA

### DEFINITION

**Leucorrhoea is strictly defined as an excessive normal vaginal discharge.** The symptom of excessive discharge is a subjective one with individual variation, while to declare it to be normal and not an infective one, requires clinical and laboratory investigations.

**The term leucorrhoea should fulfil the following criteria:**

- ◆ The excess secretion is evident from persistent vulval moistness or staining of the undergarments (brownish yellow on drying) or need to wear a vulval pad.
- ◆ It is nonpurulent and nonoffensive.
- ◆ It is nonirritant and never causes pruritus.



**PATHOPHYSIOLOGY—Normal Vaginal**

**Secretion:** The origin and nature of the normal vaginal secretion during the reproductive period has been described in page 6. However, a short resume is presented here.

The physiologic basis involved in normal vaginal secretion is dependent on the endogenous estrogen level. With the rising estrogen level, there is abundant secretory activity of the endocervical glands and the superficial vaginal epithelium becomes rich in glycogen (see p. 7, 126).

The mucoid secretion from the cervical glands is normally small in amount. The carbohydrate radicle of the glycoprotein mucin is split off and fermented into lactic acid. If however, the mucus is secreted in excess, it pours out at the vulva.

**The excessive secretion is due to:**

- Physiologic excess
- Cervical cause (cervical leucorrhoea)
- Vaginal cause (vaginal leucorrhoea)

**Physiologic excess:** The normal secretion is expected to increase in conditions when the estrogen levels become high. Such conditions are:

**During puberty**—Increased levels of endogenous estrogen lead to marked overgrowth of the endocervical epithelium which may encroach onto the ectocervix producing congenital ectopy (erosion) → increased secretion.

**During menstrual cycle**

- ◆ Around ovulation—Peak rise of estrogen → increase in secretory activity of the cervical glands.
- ◆ Premenstrual pelvic congestion and increased mucus secretion from the hypertrophied endometrial glands.

**Pregnancy**—There is hyperestrinism with increased vascularity. This leads to increased vaginal transudate and cervical gland secretion.

**During sexual excitement**, when there is abundant secretion from the Bartholin's glands.

**Cervical cause:** Non-infective cervical lesion may produce excessive secretion, which pours out at the vulva. Such lesions are—cervical ectopy, chronic cervicitis, mucous polyp and ectropion (cervical glands are exposed to the vagina).

**Vaginal cause:** Increased vaginal transudation occurs in conditions associated with increased pelvic congestion. The conditions are uterine prolapse, acquired retroverted uterus, chronic pelvic inflammation, 'pill' use and vaginal adenosis. Ill health is one of the important causes of excessive discharge. It produces excess exfoliation of the superficial cells.

**DIAGNOSIS** — See Box-I below.

**TREATMENT:** The following guidelines are prescribed to treat a case of leucorrhoea.

**Box – I: EVALUATION OF A PATIENT WITH VAGINAL DISCHARGE**

History	Physical examination	Investigations
<ul style="list-style-type: none"> <li>■ Symptoms</li> <li>◆ Discharge               <ul style="list-style-type: none"> <li>• Duration</li> <li>• Itching</li> <li>• Dysuria</li> <li>• Dyspareunia</li> <li>• Pelvic pain</li> </ul> </li> <li>◆ Contraception</li> <li>◆ Sexual behavior</li> <li>◆ Previous episodes</li> </ul>	<ul style="list-style-type: none"> <li>◆ Ill health</li> <li>◆ Poor nutrition</li> <li>◆ Abdominal examination               <ul style="list-style-type: none"> <li>• Tenderness</li> <li>• Mass</li> </ul> </li> <li>◆ Vulval inspection               <ul style="list-style-type: none"> <li>• Discharge-characters (see p. 166)</li> </ul> </li> <li>◆ Genital ulcers</li> <li>◆ Speculum examination               <ul style="list-style-type: none"> <li>• Pathology</li> <li>• Vagina</li> <li>• Cervix (ectopy)</li> <li>• Tenderness</li> </ul> </li> <li>◆ Pelvic examination               <ul style="list-style-type: none"> <li>• Tenderness</li> <li>• Pelvic mass</li> <li>• Foreign body</li> </ul> </li> </ul>	<ul style="list-style-type: none"> <li>■ Discharge</li> <li>◆ Wet film for               <ul style="list-style-type: none"> <li>• <i>T. vaginalis</i> (p. 163)</li> <li>• Clue cells (p. 152)</li> </ul> </li> <li>◆ KOH test               <ul style="list-style-type: none"> <li>• Whiff test (p. 151)</li> <li>• Fungus (p. 164)</li> </ul> </li> <li>◆ Discharge for gram staining</li> <li>◆ Pap smear (p. 164)</li> <li>◆ Urine for R/E, C/S</li> <li>◆ HIV serology (p. 154)</li> <li>◆ Blood tests when PID is suspected</li> </ul>

- ◆ Improvement of general health.
- ◆ Cervical factors require surgical treatment like electrocautery, cryosurgery or trachelorrhaphy.
- ◆ Pelvic lesions producing vaginal leucorrhea require appropriate therapy for the pathology.
- ◆ Pill users may have to stop ‘pill’ temporarily, if the symptom is very much annoying.
- ◆ Above all, local hygiene has to be maintained meticulously.
- ◆ Treatment for specific infection.

Period of life	Associated symptoms	Probable diagnosis
<b>Early neonatal</b>	Nil	Leucorrhea
<b>Period up to premenarchal</b>	Nil Offensive Vulval itching	• Ill-health • Foreign body • Threadworm
<b>Puberty</b>	Nil	Leucorrhea
<b>Reproductive period Non-pregnant</b> Related to menstrual cycle	Nil	Leucorrhea
Pill users	{ • Nil • Pruritus	• Leucorrhea • Moniliasis
Any time	{ • Nil • Pruritus • Offensive	• Ill health • Infective vaginitis • Neoplasm • Foreign body
During antibiotic therapy	Pruritus	Moniliasis
Diabetes	Pruritus	Moniliasis
<b>Pregnancy</b>	• Nil • Pruritus	• Leucorrhea • Vaginitis (Moniliasis)
<b>Postmeno-pausal</b>	• Nil • Pruritus/ diabetic • Offensive	• Senile vaginitis • Moniliasis • Pyometra • Neoplasm

**PRURITUS VULVAE:** About 10 percent of patients attending the gynecologic clinic complain of vulval itching.

**DEFINITION: Pruritus means sense of itching.** When it is confined to the vulva, it is called pruritus vulvae. It should not be confused with pain.

**MECHANISMS OF ITCHING:** The possible mechanisms of the repetitive ‘itch-scratch’ cycle are mediated through the following:

- ◆ Special sensory innervation of the area.
- ◆ Underlying vascular instability (greatly influenced by emotion) results in production of histamine-like substance → induction of itching.
- ◆ Aggravation at night because of:
  - Absence of distraction of mind.
  - Tired central nervous system.
  - Local warmth and lack of aeration.

**ETIOLOGY: Vaginal discharge**—The most common cause of pruritus vulvae is vaginal discharges either due to *Trichomonas vaginalis* or *Candida albicans* or both (see p. 163, 164).

**Local skin lesions**—The lesions may be either localized in the vulva or part of generalized lesions. Such lesions include — psoriasis, seborrheic dermatitis, intertrigo, etc.

#### Infections of the vulva

*Fungal*—*Candida* (p. 164).

*Viral*—Herpes genitalis, genital warts (p. 152, 157).

*Parasitic*—Threadworm may migrate to the area (especially in children), scabies, pediculosis (p. 158).

*STD*—Gonorrhoea, Trichomoniasis (p. 147, 163)

**Allergy or contact dermatitis**—Use of nylon undergarments or washing those with certain soaps or detergents, idiosyncrasy to chemical contraceptives or condom is often related.

#### Non-neoplastic epithelial disorders of the vulva (p. 259)

- ◆ Squamous hyperplasia (p. 262).
- ◆ Lichen sclerosus (p. 259).

#### Neoplastic epithelial disorders

- ◆ VIN (see p. 318).

- Paget's disease (p. 319).
- Invasive carcinoma of the vulva (p. 333).

### Pruritus vulvae due to some systemic diseases

- A. **Medical disorders:** Glycosuria (diabetes mellitus) causes local changes in the skin (raw beef color) and pruritus. It favors the growth of *Candida*. Others: Thyroid disorders, Chronic liver disease.
- B. **Dermatological causes:** Contact dermatitis, drug allergy.
- C. **Deficiency state:** Deficiencies of iron, folic acid, vitamin B<sub>12</sub> and vitamin A are all implicated.
- D. **Psychosomatic causes:** When no cause is detected, psychic factor is to be excluded. Mental anxiety or sexual frustration may be responsible for scratching.

### INVESTIGATIONS

It should be borne in mind that pruritus vulvae is a manifestation of some underlying pathology either located at the site or elsewhere in the body. **The investigations should include:**

**Detailed history regarding** — age of onset, intensity of itching, duration, associated vaginal discharge, contraceptive practice, relation with psychologic upset or neurosis, allergy to nylon, soap or particular detergents.

**General examination**—Thorough systemic examination is needed. Examination for diabetes mellitus, liver and thyroid disorders, hematological diseases are to be made.

**Local examination**—The extent of the lesion is to be noted.

### Special investigations

- Microscopic examination of the vaginal discharge or vulval scraping to detect *Candida* or *Trichomonas vaginalis*.
- Urine for sugar, protein and pus cells.
- Blood—Complete blood count, postprandial glucose. Detailed hematological workup (polycythemia, leucemia), thyroid profile, liver function and renal function tests are carried out.
- Stool—Ova, parasites and cysts are to be looked for.
- In long-standing cases (more than one year) especially with vulval epithelial disorders, **biopsy either random or colposcopic directed, is to be taken to note the type of skin changes and exclude malignancy.**

### TREATMENT: General principles

- ♦ Appropriate local hygiene is to be taken care of.
- ♦ To use loose fitting undergarments preferably made of cotton to keep the area aerated.

**TABLE 33.2 COMMON CAUSES OF VAGINITIS AND ABNORMAL VAGINAL DISCHARGE**

	Cause	Nature
<b>Infective</b>	<ul style="list-style-type: none"> <li>• Trichomonas vaginitis (p. 163)</li> <li>• Monilial vaginitis (p. 164)</li> <li>• Bacterial vaginosis (p. 151)</li> <li>• Cervicitis</li> </ul>	<ul style="list-style-type: none"> <li>• Frothy yellow discharge</li> <li>• Curdy white in flakes, pruritic</li> <li>• Gray-white, fishy odor and non-pruritic</li> <li>• Mucoïd discharge</li> </ul>
<b>Atrophic</b>	Postmenopausal	<ul style="list-style-type: none"> <li>• Discharge is not prominent</li> <li>• Irritation is prominent</li> </ul>
<b>Foreign body</b>	<ul style="list-style-type: none"> <li>• Forgotten pessary, tampon</li> <li>• Mechanical irritation</li> </ul>	Offensive, copious, purulent, often blood stained
<b>Chemical</b>	<ul style="list-style-type: none"> <li>• Douches, latex condoms, deodorants</li> <li>• Chemical irritation or allergy</li> </ul>	Soreness is pronounced than the discharge
<b>Excretions</b>	Contamination with urine or feces producing secondary vaginitis	Offensive discharge with pruritus
<b>Neoplasms</b>	Fibroid polyp or genital malignancy	Serosanguinous, often offensive

- ◆ To prevent the vicious cycle of ‘itch-scratch’.

Local application of antibiotics or clobetasol propionate 0.05 percent (p. 261) ointment may be helpful. If the skin is atrophic, estrogen or testosterone cream may be helpful.

- ◆ **To treat the specific etiological factor** causing pruritus by appropriate therapy—local or systemic.

**Surgery:** Surgery may be needed when biopsy confirms features of neoplasia (VIN or invasion).

## PELVIC PAIN

**Pain is an unpleasant sensory and emotional experience associated with actual or potential tissue damage.** Pelvic pain is a common symptom in gynecology. It may be present in **acute form** or **in chronic form**. It should be remembered that the pain is just a symptom of an underlying disorder. Whereas, it is often easy to find out the underlying cause of acute pain, it is often difficult to find out the cause of chronic pelvic pain. **Sensation of pain is found to depend on many factors in an individual: e.g. subjective feel, emotional status, genetic factors, experience, gender, pain threshold, anxiety and expectations. Women have a lower pain threshold and tolerance.**

## NEUROPHYSIOLOGY OF PAIN

Impulse generated due to depolarization of a peripheral nerve ending (Transduction) → Transmission of the nerve impulse → Modulation (control of impulse transmission to neurones by neurotransmitters) → perception of pain.

**TABLE 33.3 LOCALIZATION OF REFERRED PAIN**

Organs	Site of referred pain
Body of uterus	Hypogastrium, anterior and medial aspect of thighs
Fallopian tubes and ovaries	Above the mid-inguinal point
Cervix	Upper sacral region
Uterosacral ligament	Lower sacral region

Unlike somatic structures, which are well-represented in the cerebral cortex in terms of localization, visceral structures are poorly localized in the cerebral cortex. Thus, the pain arising from the pelvic organs is often localized not to the

organ but referred to the skin area supplied by the same spinal nerve. Various neuromodulators (prostaglandins, endorphins) and neurotransmitters (norepinephrine, serotonin) are involved to modify the pain sensation in the brain. Visceral pain may be due to distension, stretching, hypoxia, necrosis, chemical irritants or inflammation of the viscera. Pelvic pain may be splanchnic or referred. One finger ‘trigger point’ tenderness is suggestive of nerve entrapment (ilioinguinal). Similarly ‘ovarian point’ tenderness suggests pelvic congestion syndrome (p. 181).

**ACUTE PELVIC PAIN:** Acute pain is of short duration and generally the symptoms are proportionate to the extent of tissue damage. In chronic pelvic pain, the onset is insidious and the degree of pain is not proportionate to the extent of structural tissue damage.

Most often, the basic mechanism of acute pain is due to irritation of the peritoneum by either blood or infection. The causes of acute pelvic pain are given in Table 33.4.

**TABLE 33.4 CAUSES OF ACUTE PELVIC PAIN**

Mechanism	Clinical conditions
Hemoperitoneum—peritoneal irritation	<ul style="list-style-type: none"> <li>• Disturbed tubal pregnancy</li> <li>• Ruptured chocolate cyst</li> <li>• Ruptured corpus luteum or follicular cyst</li> </ul>
Infection—peritoneal irritation	Acute PID
Chemical irritation	Following HSG
Uterine cramp	Abortion
Vascular complication with neurologic involvement	Axial rotation of ovarian tumor pedicle
Visceral distension	<ul style="list-style-type: none"> <li>• Intracystic hemorrhage</li> <li>• Hyperstimulation syndrome</li> <li>• Hematometra or pyometra</li> </ul>
Non-gynecological	<ul style="list-style-type: none"> <li>• Appendicitis</li> <li>• UTI, Renal calculus</li> <li>• Intestinal obstruction</li> <li>• Rectus sheath hematoma</li> <li>• Mesenteric lymph adenitis</li> <li>• Pancreatitis</li> </ul>

**Diagnosis:** A meticulous history taking and examinations—systemic, abdominal and pelvic, most often clinch the diagnosis.

**Guidelines in clinical diagnosis:**

- Pain of gynecologic origin usually starts in the lower abdomen and then spreads to the entire abdomen.
- Pain preceded by amenorrhea is usually obstetrically related—**disturbed ectopic pregnancy should be kept in mind.**
- Anorexia, nausea and vomiting are usually correlated well with gastrointestinal mischief.
- Frequency of micturition, dysuria with or without fever point to the diagnosis of urinary tract infection.
- Fever with chills and rigor is most often associated with acute PID.
- Pain with syncopal attacks with collapse suggests intraperitoneal hemorrhage.
- Abdominopelvic lump along with more or less stable vital signs points towards complicated pelvic tumor.

**INVESTIGATIONS**

Basic investigations to substantiate the clinical diagnosis as when indicated include:

**Blood:** Complete hemogram is done. An increase in white cell count specially with a shift to left may indicate infection. Decreased hemoglobin level with low hematocrit value indicates hypovolemia.

**Midstream urine for microscopic examination and culture** is to be done to diagnose UTI. Presence of pus cells, bacteria and red blood cells suggests UTI.

**Urine for immunological test of pregnancy.** A positive test needs to be followed with serial  $\beta$  and hCG measurement, ultrasonography (TVS) to rule out ectopic pregnancy.

With these protocols, diagnosis is established in majority and for those remaining undiagnosed cases, the following are to be employed.

**X-ray abdomen**—(upright, supine and lateral decubitus film) is to be done to diagnose—intestinal obstruction or perforation. Perforation of air-filled viscus is evident by presence of free air under the

diaphragm. Free fluid suggests ruptured cyst. Calculus can be evident from X-ray.

**Sonography** (transvaginal) is helpful to detect pelvic mass or pregnancy—uterine or tubal.

TABLE 33.5	MANAGEMENT PROTOCOL
Definite diagnosis	<p><i>Immediate laparotomy</i></p> <ul style="list-style-type: none"> <li>• Hemoperitoneum</li> <li>• Rupture tubo-ovarian abscess</li> <li>• Twisted ovarian cyst (p. 298)</li> <li>• Acute surgical condition</li> </ul>
	<p><i>Institution of medical therapy</i></p> <ul style="list-style-type: none"> <li>• Urinary tract infection (p. 410)</li> <li>• Pelvic inflammatory disease (see p. 127)</li> <li>• Gastroenteritis</li> <li>• Hyperstimulation syndrome (see p. 529)</li> </ul>
Doubtful diagnosis	<ul style="list-style-type: none"> <li>• To be subjected to diagnostic sonography or laparoscopy</li> <li>• Observation</li> </ul>

**Laparoscopy** is helpful to visualize the pelvic pathology. Surprisingly, laparoscopic examination confirms the provisional clinical diagnosis in only 25 percent of the cases. In acute PID, aspiration of the tubal exudate is to be done for microbial study.

**Management:** The patients are most often critically ill. Intensive resuscitative or supportive measures are to be taken. The definitive treatment of some of the common events are formulated in Table 33.5.

**CHRONIC PELVIC PAIN: Chronic pelvic pain (CPP) is defined as the noncyclic pain (non-menstrual) of 6 months duration or more localized** to the pelvis, anterior abdominal wall below the pelvis or lower back, severe enough to cause functional disability that require medical or surgical treatment.

CPP is a common problem (10%) seen in the gynecologic outpatient. Approximately 20–30 percent of laparoscopies and 10 percent of all hysterectomies are done due to CPP.

**DIAGNOSIS:** While it is comparatively easy to diagnose the cyclic chronic pelvic pain, it is difficult at times to pinpoint the diagnosis of acyclic and the non-gynecologic group. However, meticulous history taking and thorough clinical examinations—abdominal and vaginal with the possibility in mind, are often enough to clinch the diagnosis.

<b>Cyclic</b>	<b>Acyclic</b>
<ul style="list-style-type: none"> <li>◆ <b>Intermenstrual pain</b> (Mittelschmerz)</li> <li>◆ <b>Dysmenorrhea</b> <ul style="list-style-type: none"> <li>– Spasmodic</li> <li>– Congestive</li> </ul> </li> <li>◆ <b>Premenstrual syndrome</b></li> <li>◆ <b>Pelvic congestion syndrome</b></li> <li>◆ <b>Endometriosis</b></li> <li>◆ <b>Adenomyosis</b></li> <li>◆ <b>Ovarian remnant syndrome</b></li> </ul>	<ul style="list-style-type: none"> <li>◆ Endometriosis, adenomyosis</li> <li>◆ PID</li> <li>◆ <b>Uterine displacement</b> <ul style="list-style-type: none"> <li>– Retroversion</li> <li>– Prolapse</li> </ul> </li> <li>◆ Uterine fibroid</li> <li>◆ Ovarian cyst <ul style="list-style-type: none"> <li>– Functional</li> <li>– Neoplastic</li> </ul> </li> <li>◆ Pelvic adhesions disease secondary to PID, endometriosis or postsurgical</li> <li>◆ IUD</li> <li>◆ Trapped or residual ovarian syndrome (see p. 559)</li> <li>◆ Idiopathic <ul style="list-style-type: none"> <li>– Pelvic varicosities</li> <li>– Psychosomatic</li> </ul> </li> </ul>

In confused state, without any detectable pelvic pathology to account for CPP, **the following guidelines are of help to arrive at the diagnosis.**

<b>Gastrointestinal</b>	<ul style="list-style-type: none"> <li>◆ Irritable bowel syndrome</li> <li>◆ Appendicitis</li> <li>◆ Constipation</li> <li>◆ Diverticulitis</li> </ul>
<b>Urological</b>	<ul style="list-style-type: none"> <li>◆ Interstitial cystitis (see p. 409)</li> <li>◆ Urethral syndrome (see p. 412)</li> <li>◆ Calculi</li> </ul>
<b>Orthopedic</b>	Diseases of the bones, ligaments, muscles of the lumbosacral region
<b>Neurological</b>	Nerve entrapment or compression
<b>Hernias</b>	Inguinal, femoral, obturator

◆ **Nerve entrapment pain** is localized to a particular point of the lower abdominal wall. This may be due to entrapment of ilioinguinal, iliohypo-

gastric or genitofemoral nerve. Local infiltration of bupivacaine 0.25 percent and relief of pain is a confirmatory test. It is therapeutic also. Surgical exploration and excision of the nerve is also recommended.

- ◆ **Pessary test**—In mobile retroverted uterus or slight degree of uterine descent, a pessary test may be employed. The pessary is inserted and kept for 3 months. If the symptoms are relieved, the diagnosis is certain and surgical correction is advisable.
- ◆ **Combined oral contraceptive pills**—Cases with functional ovarian cyst producing CPP are given cyclic OC for 3 months. The functional cyst is likely to regress with the relief of symptoms. The same therapeutic test can be employed to relieve the midmenstrual pain or primary dysmenorrhea by making the cycle anovular.
- ◆ **Transcutaneous electric nerve stimulation (TENS)** is helpful in cases by inhibiting the transmission of nerve impulse via unmyelinated fibers.
- ◆ **Cognitive and behavioral therapy (CBT)** to be given to patients as it has benefits.
- ◆ **Pain mapping** is useful especially in assessment of adhesions.
- ◆ **Patient having IUD** and pelvic pain should be cautiously interpreted. **The possibility of PID or ectopic pregnancy should be kept in mind.**
- ◆ **Non-gynecological disorders** as cause of CPP should be kept in mind (Table 33.7). These are mostly related with disorders of bowel (spastic colon, irritable bowel syndrome). Spasm or rigidity of muscles especially those of vertebral column suggests orthopedic, neurologic or rheumatic lesion.
- ◆ **CPP without any organic lesion**—The women are usually parous and perimenopausal. These cases may be attributed to pelvic congestion, or may be due to psychosomatic disturbances.
- ◆ **Pelvic congestion syndrome** (Taylor syndrome) is characterized by chronic pelvic pain, dyspareunia, abnormal uterine bleeding along with pelvic venous congestion. Diagnosis can be made by transuterine

venography, transvaginal color Doppler sonography (TV-CDS) or by laparoscopy. Congested pelvic veins are seen. **Therapeutic options are**: Medroxyprogesterone acetate 50 mg daily is found to be effective. GnRH agonist with estrogen add back therapy is also recommended. Hysterectomy and bilateral salpingo-oophorectomy is considered as the treatment of last resort for those who fail to respond with medical therapy.

#### ■ Ancillary aids in diagnosis

- **Blood**—Complete hemogram helpful in the diagnosis of infection.
- **Cervical and vaginal discharge** is subjected to hanging drop preparation, Gram stain and culture, both aerobic and anaerobic. This can give a clue in the diagnosis of PID.
- **Endometrial biopsy** to be done in suspected cases of genital tuberculosis (p. 140).
- **Sonography**—It is of value in diagnosis of tumor, either fibroid or ovarian. Transvaginal sonography (TVS) can detect adenomyosis and ovarian enlargement due to cysts. Color Doppler sonography (CDS) is helpful to detect ovarian torsion. Calculi in the urinary system can also be detected with sonography. It is also helpful in assessing the progress of the therapy in PID especially when laparoscopy is contraindicated or as an alternative to it.
- **Laparoscopy**—Laparoscopy is an invaluable diagnostic tool in the investigation of chronic pelvic pain. It has been found that about 50 percent of cases with normal clinical pelvic findings have got detectable abnormality on laparoscopy. Conversely, one-third of women with detectable clinical pathology are ultimately proven to have normal pelvis on laparoscopy.

**Its chief value is to detect minimal endometriosis and pelvic adhesions.** The negative finding also have got value—assures the clinician that no abnormality exists. This can relieve the patient's psychosomatic factor related with CPP.

- **X-rays** of lumbosacral region and hip joints helps to detect orthopedic lesions. CT scan or MRI have no place in the diagnosis of CPP except in malignant conditions.

#### TREATMENT: Principles

- ◆ To have a definite diagnosis of the underlying disorders.
- ◆ To establish the relationship between the pathology and the symptoms.
- ◆ To evaluate psychosomatic factors—cause or effect.
- ◆ **Multidisciplinary approach** involving a psychologist is ideal especially when no pathology could be detected.

**In detectable pathology:** Conservative or radical surgery is to be done to remove the offending pathology. Hysterectomy is ideal for women with pelvic endometriosis or adenomyosis, when she has completed child bearing.

#### Medical Management of Pain

- Assurance and sympathetic handling too often cure or ameliorate the pain.
- **NSAIDs:** Ibuprofen, Naproxen : COX-2 inhibitors (p. 182, 183) — Celecoxib, Ketorolac.
- **Neurolytic agents:** Tricyclic antidepressants— Amitriptyline, Imipramine, **Serotonin uptake inhibitors:** Sertraline, Fluoxetine, Paroxetine, **Ion channel Blockers:** Gabapentin, Carbamazepine.
- **Narcotics (under supervision):** Codeine, Methadone.
- **Others:** OC pills, progestogens, danazol or even GnRH analogues (see p. 525) is indicated in young patients with minimal endometriosis, spasmodic dysmenorrhea or midmenstrual pain.
- **Minimal invasive surgery** includes laser therapy in pelvic endometriosis or laparoscopic adhesiolysis. **Laparoscopic** presacral neurectomy (PSN) and uterine nerve ablation (LUNA) are considered for midline dysmenorrhea when conservative management has failed.
- **Surgery** like ventrosuspension, plication of round ligaments (p. 600) in deep dyspareunia or even presacral neurectomy may be employed.
- **Hysterectomy** should be contemplated judiciously in selected cases.
- **Intractable pain of malignant origin** — Apart from narcotic analgesics, PSN or LUNA may relieve pain for few months (see p. 353).



## TRAPPED (RESIDUAL) OVARIAN SYNDROME

The syndrome is characterized by chronic pelvic pain, deep dyspareunia and a fixed tender ovary felt at the vault of the vagina.

It may appear in 1–3 percent of all cases of hysterectomy with preservation of one or both the ovaries. **The pain is due to tension within the developing follicle of the ovary with periovarian adhesions. Pain may also be due to perioophoritis with a thickened ovarian capsule.** Ultrasonography (TVS) can detect characteristic ovarian enlargement.

The relief of pain may be achieved by ovarian suppression with hormones (high dose progestins, OC pills, danazol or GnRH agonists). Cure is by removal of the ovaries.

## OVARIAN REMNANT SYNDROME

The syndrome is defined as the persistence of the ovarian function even after an apparently bilateral oophorectomy. Oophorectomy becomes technically difficult during hysterectomy in cases with extensive endometriosis or pelvic inflammatory disease. **Pain is due to the remnant of ovarian cortical tissue, left behind (retroperitoneally) unintentionally following a difficult oophorectomy.**

**The presenting complaints are** chronic pelvic pain (cyclic), deep dyspareunia and persistence of symptoms of endometriosis. **Confirmation is done** by serum FSH levels in premenopausal range. Laparoscopic visualization of the remnant ovarian tissue is difficult because of adhesions. Vaginal ultrasound and MRI are helpful to the diagnosis.

Ovarian suppression as mentioned above may be used for diagnosis. Cure is effective by surgical removal. Careful dissection is needed as it is adjacent to the ureter in the retroperitoneal space.

## POSTMENOPAUSAL BLEEDING

### INTRODUCTION

**Bleeding per vagina following established menopause is called postmenopausal bleeding.**

The significance of postmenopausal bleeding, whatever slight it may be, should not be underestimated. **As many as one-third of the cases are due to malignancy.** The same importance is also given to those cases where normal menstruation continues even beyond the age of 55 years.

### CAUSES

The causes of postmenopausal bleeding are:

- Senile endometritis (p. 168).
- Atrophic endometrium.
- Endometrial hyperplasia (p. 329).
- Dysfunctional uterine bleeding.
- Genital malignancy.
  - Carcinoma of the cervix, endometrium, vagina, vulva and Fallopian tube.
  - Sarcoma uterus.
  - Granulosa cell tumor of the ovary.
- Uterine polyp.
- Tubercular endometritis.
- Cervical erosion and polyp.
- Senile vaginitis.
- Decubitus ulcer.
- Retained and forgotten foreign body such as pessary or IUCD.
- Withdrawal bleeding following estrogen intake.
- Urethral caruncle, polyp, prolapse mucosa or carcinoma.
- Unknown is about 25 percent. **The incidence however decreases with wider use of hysteroscopy.**

TABLE 33.8

### COMMON CAUSES OF POSTMENOPAUSAL BLEEDING

- |                       |                            |
|-----------------------|----------------------------|
| • Genital malignancy  | • Decubitus ulcer          |
| • DUB                 | • Urethral caruncle        |
| • Senile endometritis | • Retained pessary or IUCD |

### INVESTIGATIONS

Initial step is to establish the fact that it is vaginal bleeding and not bleeding per rectum or hematuria.

### Detailed history regarding

- Age of menopause.
- Menstrual pattern prior to menopause.
- Amount of bleeding, number of episodes.
- Sensation of something coming out of the introitus.
- Urinary problems like dysuria or frequency of urination.
- Intake of estrogen—Even if the history of intake is present, full investigations should be carried out to exclude malignancy.
- Family history of endometrial and/or ovarian carcinoma (first degree relative).

### General examination

Obesity and hypertension are often related to endometrial carcinoma.

**Enlarged** groin or supraclavicular lymph nodes may be palpated. Metastatic nodules in the anterior vaginal wall may be present. Breasts should be palpated because gynecological symptoms may be related to breast cancer (p. 387, 388).

**Per abdomen:** A lump in the lower abdomen may be due to pyometra or uterine sarcoma or adnexal mass.

### Inspection of the perineum

- ◆ If the uterus is outside the introitus, a decubitus ulcer may be detected (see p. 206).
- ◆ Careful inspection of vulva may reveal a growth. If it is present, biopsy is to be taken.

**Palpation:** To separate the labia for better inspection of the urethral meatus to find out any caruncle, polyp or mucosal prolapse.

**Speculum examination:** To note the condition of the cervix and the vault of the vagina.

- ◆ Any visible cervical growth → biopsy is to be taken for histology.
- ◆ Cervix apparently looking normal → cervical and endocervical smear to exclude dysplasia or CIN (p. 324).
- ◆ Aspiration cytology — for endometrial carcinoma.

**Pipelle endometrial sampling** can be done with a long and narrow plastic cannula (see Fig. 9.23). This is done as an OPD procedure during speculum examination. Adequate sample is obtained with this procedure and the tissue is subjected for histological examination.

### Bimanual examination

- ✦ Uterus may be normal, atrophic or enlarged due to pyometra or sarcoma.
- ✦ Adnexal mass (infective or ovarian) may be palpable.

### Special investigations

**Ultrasonography** transvaginal probe (TVS) is more accurate because of its proximity to the target tissue (endometrium). Endometrial thickness less than 5 mm indicates atrophy. On the other hand, thick polypoid endometrium (9–10 mm), irregular texture, fluid within the uterus require further evaluation (to exclude malignancy).

- ◆ **Saline infusion sonography** (SIS) is more accurate compared to sonography alone and biopsy is taken (see p. 118).
- ◆ **Hysteroscopic** evaluation and directed biopsy.
- ◆ **Endometrial biopsy** may be done using the Sharman curette as an outpatient basis.
- ◆ **Fractional curettage**, if the cervical cytology becomes negative (p. 356).
- ◆ **Endometrial biopsy** for diagnosis of endometrial carcinoma under guidance of sonohysterography or hysteroscopy has got the similar diagnostic accuracy.
- ◆ **Laparoscopy** in suspected cases of ovarian or adnexal mass.
- ◆ **CT and MRI** may be useful in selected cases of postmenopausal bleeding (p. 118).

**Detection of a benign lesion should not prevent further detailed investigations to rule out malignancy.**

### TREATMENT

- ◆ **If the cause is found**, the treatment is directed to it.
- ◆ **If no cause is detected** and there is only minimal bleeding once or twice, careful observation is mandatory, if conservatism is desired.
- ◆ **In cases of recurrences or continued bleeding** whatever may be the amount, it is better to proceed for laparotomy and to perform hysterectomy with bilateral salpingo-oophorectomy. Unexpectedly, one may find a pathology either in the ovary or Fallopian tube or else, an uterine polyp — benign or malignant may be evident in the removed uterus.

## LOW BACKACHE

Low backache is a frequent complaint of parous women in a gynecologic clinic. It may be the part of the gynecological complaints or the case may be referred by an orthopedic surgeon to exclude the pelvic pathology to account for the low backache.

**The reasons to refer are:**

- ❖ The low backache often dates back to childbirth process or gynecological operation.
- ❖ The symptoms often aggravate in relation to period.  
To establish a correlation between the low backache and gynecologic pathology, **the following facts are to be remembered.**
- ❖ As the posterior peritoneum is poorly innervated, the pain is dull and diffuse.
- ❖ Backache of pelvic origin never reaches beyond the 4th lumbar vertebra.
- ❖ The pain pointed by finger tip is not of gynecologic origin.

**Causes:** Common causes of backache of pelvic origin are:

### Uterine Displacement

- ♦ Prolapse—Uterine prolapse produces backache due to stretching of the ligaments supporting the uterus in position. If the ligaments are atrophic, there will be no pain. **Vaginal prolapse does not cause backache.**  
The pain in prolapse subsides when the patient is at rest and aggravates on standing.
- ♦ Retroversion—Retroverted uterus may produce backache only when it is fixed by inflammatory or endometriotic adhesions. **Mobile retroverted uterus does not produce backache.**

**Chronic pelvic infection:** Chronic PID producing adhesions and TO mass formation may be responsible for backache. There are associated menstrual abnormalities and dyspareunia. Chronic cervicitis produces backache by parametritis.

**Endometriosis:** Endometriosis involving the pelvic peritoneum, uterosacral ligament or rectovaginal septum produces backache and deep dyspareunia (see p. 307).

**Neoplasm:** **Benign neoplasm** like ovarian tumor or fibroid will not ordinarily produce backache. However, cervical or broad ligament fibroid can cause backache by producing pressure on the nerve routes over the sacrum.

**Pelvic malignancy** produces backache by involving the nerve roots, metastasis in the vertebrae or involving the lateral pelvic wall.

## BREAST IN GYNECOLOGY

Breast is one of the target organs for the various hormones, of particular estrogens, progesterone and prolactin. As such, many a breast related complaint or disease is associated with endocrine dysfunctions.

**Development:** The breast develops at 6–8 weeks from the “milk ridge” which is an **ectodermal thickening** that extends longitudinally from the axilla to groin. Pectoral part of the ridge persists and the rest regresses. In the 3rd month, a depression called “mammary pocket” appears in the center of the milk ridge. Solid buds grow from the mammary pocket into the underlying mesoderm at around the 5th month. During 7th to 9th month the solid buds degenerate and develop into acini. At birth the inverted nipples become everted by the growth of the underlying stroma. The connective tissue stroma is developed from the mesoderm.

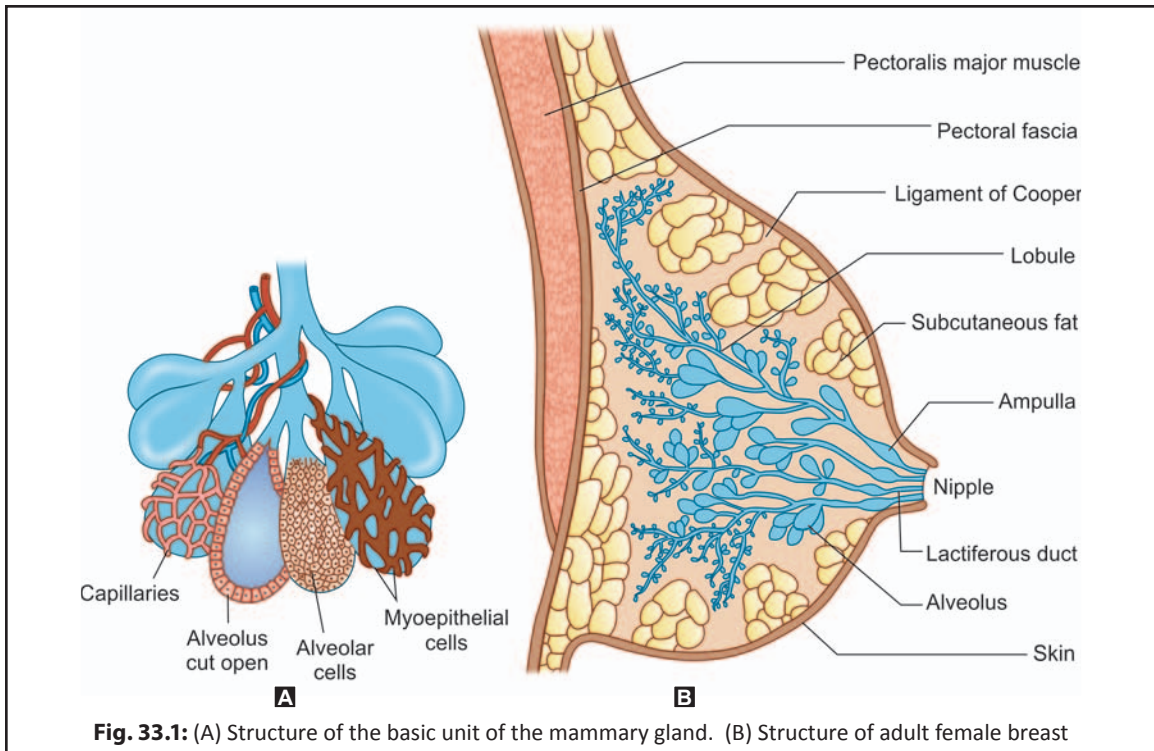
**At birth:** There is only nipple with system of ducts without alveoli. Due to maternal estrogen, the growth becomes exaggerated with occasional mucoid discharge (witch milk). The involution usually is completed by 1–2 weeks after birth.

**Puberty changes (see p. 49):** The breast duct growth is primarily stimulated by estrogen. The alveolar cells and sebaceous glands are stimulated by progesterone. The maturation of the breast components is accelerated by growth hormone, adrenal hormones, thyroid hormone, prolactin and insulin.

### ANATOMY OF THE ADULT BREAST

The breasts are bilateral glandular structures and in female, constitute accessory reproductive organs as the glands are concerned with lactation following childbirth.

The shape of the breast varies in women and also in different periods of life. It usually extends from the second to sixth rib in the midclavicular line. It lies in the subcutaneous tissue over the fascia covering the pectoralis major or even beyond that to lie over the serratus anterior and external oblique. An axillary prolongation (axillary



**Fig. 33.1:** (A) Structure of the basic unit of the mammary gland. (B) Structure of adult female breast

tail), if present, lies in the axillary fossa, sometimes deep to the deep fascia.

### STRUCTURES (NON-LACTATING BREASTS)

The areola is placed about the center of the breast and is pigmented. It is about 2.5 cm in diameter. There are numerous sebaceous glands over it. It contains few involuntary muscles. The nipple is a muscular projection covered by pigmented skin. It is vascular and surrounded by unstriped muscles which make it erectile. It accommodates about 15–20 lactiferous ducts and their openings. The whole breast is embedded in the subcutaneous fat. The fat is, however, absent beneath the nipple and areola. **The breast tissue is composed of lobes (15–20), glandular tissues, duct system and also fibrofatty tissues (Fig. 33.1).** For details see Dutta's Textbook of Obstetrics 7th Edition.

#### Blood supply: Arterial supply

- ♦ Lateral thoracic branches of the axillary artery.
- ♦ Internal mammary arteries.
- ♦ Intercostal arteries.

**Veins** — The veins follow the courses of the arteries.

#### Lymphatics:

- ♦ *Lateral hemisphere:* Anterior axillary nodes.
- ♦ *Upper convexity:* Infraclavicular group.

- ♦ *Medial convexity:* Mediastinal glands (cross connection between the two breasts). There is no contralateral drainage of lymph, until and unless there is ipsilateral obstruction.

- ♦ *Inferior convexity:* Mediastinal glands.

**Nerves**—The nerve supply is from fourth, fifth and sixth intercostal nerves.

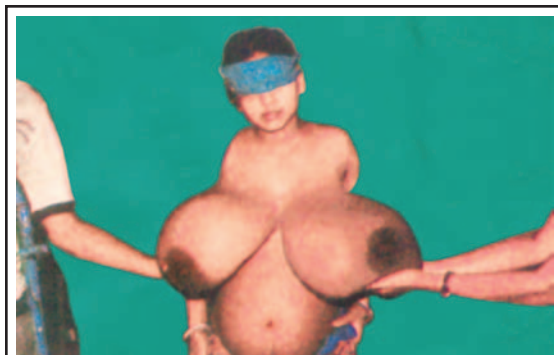**ANATOMICAL DEFECTS:** Small breasts (Hypoplasia)

This may be due to:

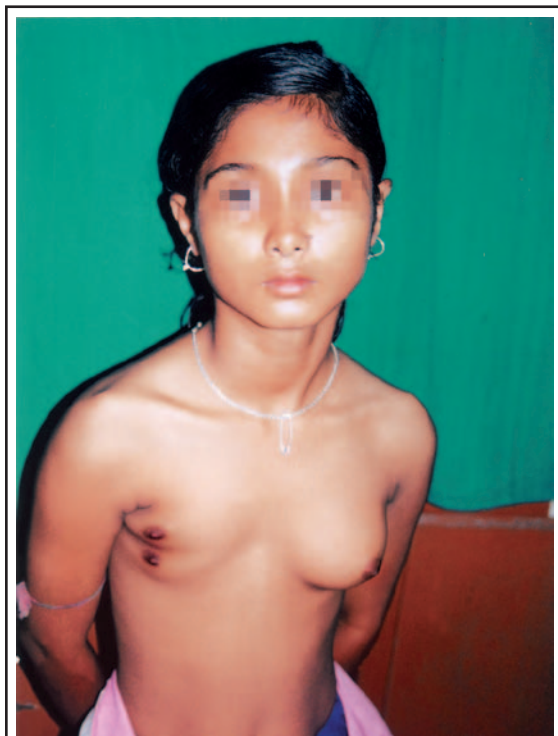- ♦ Non or under production of ovarian estrogens.
- ♦ Developmental defect in the breasts.

**In the former group**, reassurance and cyclic estrogen or combined estrogen-progestogen preparations may be of help, if continued for a prolonged period. **In the latter group**, if the menstrual function is normal, it is no good to give hormone. Improvement of general health and breast augmentation of the affected side may be done.

**Huge enlargement (Fig. 33.2):** Some enlargement occurs during pregnancy and the breasts become pendulous in parous women due to stretching of the fibrous septa. Rarely, the breasts become hugely



**Fig. 33.2:** Marked hypertrophy of the breasts  
(By Courtesy — Dr. N. Chowdhury)



**Fig. 33.3:** Asymmetry of the breasts  
with polythelia (accessory nipple)

enlarged. The glandular tissues are affected but not the nipple. This may cause neck, back and shoulder pain. Young women are embarrassed also. Treatment by reduction mammoplasty is justified after the age of 17.

**Asymmetry (Fig. 33.3):** During initial period of development, asymmetry is common. However, it

soon rectifies within couple of years of menarche. Left is slightly larger than the right. Sometimes, the asymmetry persists and causes concern to the patient. Plastic surgery to increase the size of the smaller breast can be done if she is affected psychologically.

**Accessory breasts (Fig. 33.3):** A breast (polymastia) or a part or a nipple (polythelia) may develop and tends to grow anywhere along a line extending from the axilla to the groin (milkline). **The most common site of extension is as a 'tail' into the axilla.** They can be the site of all diseases as found in a normal breast tissue. Excision may be needed because of discomfort, cosmesis or disease.

### DISEASES OF THE BREAST

- Mastalgia
  - ◆ Cyclic – premenstrual (see p. 182)
  - ◆ Noncyclic
  - ◆ Extra mammary
- Fibrocystic changes
- Fibroadenoma
- Carcinoma

**MASTALGIA (breast pain)** is a common problem for majority of women. Mastalgia may be true (from breast only) or referred (chest wall). True breast pain is associated with swelling and nodularity. Symptoms may be worse with menstruation or by use of exogenous hormones (COCs or HRTs).

**Diagnosis** is made from careful history taking, examination and mammography (women  $\geq$  35 years of age). About 5 percent of women with breast cancer present with breast pain.

**Management** is primarily aimed to exclude cancer. The woman should be reassured. Drugs and measures commonly used with proven benefits are :

- ◆ **Acetaminophen or NSAIDs**
- ◆ **Phyto-estrogens** (soya milk)
- ◆ **Reduction of dietary fat**
- ◆ **Tamoxifen** 10 mg daily during the luteal phase of the cycle or
- ◆ **Danazol** 100–200 mg daily
- ◆ **GnRH analogues** (see p. 525)

### FIBROCYSTIC BREAST DISEASE

Fibrocystic breast disease is the most common benign lesion. It is generally observed between 20–50 years of age.

The etiology is not known. It may be due to altered estrogen: progesterone ratio or relative decrease in progesterone or else, the breast tissues are more sensitive to prolactin. Stress factor may at times be related.

Histologically a fibrocystic mass is characterized by adenosis, fibrosis, ductal epithelial proliferation and papillomatosis. Two types are observed: localized and diffuse. Vast majority (70%) are nonproliferative lesions. Of the proliferative lesions only few (4%) present with cellular atypia where the risk of breast cancer is high (five-fold). Risk factors are nulliparity and delayed menopause.

The patients are usually premenopausal. The patient complains of breast pain present throughout the cycle but aggravated premenstrually (cyclic). The pain is either dull continuous or intermittent and severe.

Examination reveals affection of both the breasts; one is more than the other. On palpation, coarsely nodular areas resembling ill-defined lumps either localized or diffused, are felt. These are prominent in premenstrual phase.

The patients become anxious of malignancy and the physicians too are confused to negate it. **Careful palpation, mammography, ultrasound and aspiration biopsy is helpful to exclude malignancy.**

#### Treatment

- ◆ Assurance and re-examination at intervals.
- ◆ To wear a well fitting brassiere day and night.
- ◆ Acetaminophen or NSAIDs may be helpful.
- ◆ To reduce the intake of methylxanthines (coffee, tea, chocolates, caffeinated soda) and tobacco.
- ◆ Vitamin E 400 mg daily may be helpful.
- ◆ In refractory cases, any of the following may be tried:
  - Cyclic combined estrogen-progesterone preparations.
  - Danazol 200 mg daily in divided doses.
  - Bromocriptine—2.5–5 mg daily at bed time.
  - Surgery—rarely indicated.

**FIBROADENOMA: This is the most common benign tumor of the breast occurring among the younger (20–35 years) women.** It is symptomless being accidentally discovered by self palpation.

On palpation, an uniform, firm, mobile, painless and well-defined mass is felt. Commonly they are bilateral. Fibroadenoma with size > 5 cm is known as giant fibroadenoma. Histologically they have an epithelial and a stromal component. A young patient however, may be reviewed **6 monthly** as the risk of malignancy is less than 0.2 percent.

Surgical excision and biopsy is indicated only when the mass enlarges and or report of FNAB is inconclusive. Ultrasound guided cryoablation is a treatment option.

### BREAST CARCINOMA

Breast cancer is the most common (30%) of all cancers and is the second (next to lung cancer) common cause of cancer deaths in women. One out of 8 obstetric-gynecologic patients is likely to develop breast carcinoma at sometime during her adult life in USA and Western countries.

Obstetricians-gynecologists examine millions of patients on a regular basis. As such, they are expected to evaluate breast problems with a breast oriented history, physical examination, cytology and imaging studies for to formulate the management (Table 33.9).

**SCREENING FOR BREAST CANCER:** Breast carcinomas are generally without any symptoms to start with. Screening can detect breast cancer at an earlier stage (table 33.10). Ideally screening should be performed for all women from 40 years of age. Earlier detection improves the survival rate. Five-year survival is about 85 percent when axillary lymph nodes are not involved.

**Screening and diagnostic methods include:**

- Breast self examination.
- Clinical breast examination (CBE) by a physician
  - ◆ Inspection
  - ◆ Palpation.
- Breast imaging
  - ◆ Screening mammography.
  - ◆ Diagnostic mammography.

- ◆ Ultrasonography.
- ◆ Magnetic resonance imaging (MRI).
- ◆ Digital mammography, positron emission tomography.
- Breast biopsy
  - ◆ Fine needle aspiration biopsy (FNAB).
  - ◆ Stereotactic and ultrasound guided core biopsy.
  - ◆ Open biopsy:
    - Excisional biopsy
    - Incisional biopsy.

### ***Breast self examination (BSE)***

Breast self examination should be made into a habit, **certainly by the age of 20**. The examination should be made on a monthly basis following the menses as the breasts become less tender and less engorged.

The procedures (as described above) are demonstrated to the patient. Circular method of palpation is easy to do. **Inspection** should be done standing in front of a mirror in a well lit-room. The patient should **palpate her breasts** with the opposite hand both in sitting position and lying supine with a pillow beneath her back. Axillary and supraclavicular areas are to be palpated. The nipples should be compressed for any discharge. She is instructed to contact physician whenever there is any abnormal finding.

### **CLINICAL BREAST EXAMINATIONS (CBE)**

#### ***Inspection (see Fig. 9.1, chapter 9)***

Inspection is performed while the patient is sitting with arms relaxed by her sides. Both the breasts are observed for contour, symmetry, nipple positions, and any skin changes. Patient is asked to press her hands on her hips so as to contract the pectoralis major muscles. Skin dimpling and nipple retraction if any, may be obvious with this method.

#### ***Palpation (See Fig. 9.1 p. 101)***

Entire breast is palpated methodically by quadrant with the pads of the fingers (most sensitive) both in upright and in supine positions (see p. 101).

Generally, a malignant mass is felt firm, non-tender, fixed with ill-defined borders. Entire axilla and the supraclavicular areas are palpated for any lymph nodes. Nipple is compressed for any discharge.

CBE is best done during the first half of the menstrual cycle.

**TABLE 33.9**

### **HIGH RISK FACTORS FOR BREAST CARCINOMA**

- Early menarche
- Obesity
- Late age of first birth (>35 years)
- Never breastfed
- Atypical lobular hyperplasia
- Nipple discharge other than milk
- High dose breast or chest irradiation
- High dietary fat intake
- Estrogen replacement therapy
- Breast carcinoma in first degree relative (Mother, sister or daughter)
- Carcinoma in the other breast
- Previous cancer of endometrium, ovary, colon
- Inherited mutations of BRCA 1 and BRCA 2 genes
- Late menopause
- Nulliparity
- Alcohol consumption

**Genetic predisposition**—is high when there is mutation of the BRCA 1 (on chromosome 17 q) and/or BRCA 2 (on chromosome 13 q) genes. BRCA 1 and BRCA 2 are the tumor suppressor genes. Hereditary breast cancer is seen in younger women and is often bilateral. Around 5% of breast cancers are familial.

### **BREAST CANCER SCREENING GUIDELINES (ACOG-2000)**

<b>Age 20–39</b>	<b>Age 40–49</b>	<b>Age 50</b>
BSE monthly	BSE monthly	BSE monthly
CBE yearly	CBE yearly	CBE yearly
	MGY—every 1–2 yrs.	MGY yearly

### **BREAST IMAGING**

- **Mammography** (MGY) is the most effective screening method for detection of nonpalpable and minimally invasive breast cancer. However, it has a false negative rate of 10–15%. It should be combined with CBE and BSE. Two views, one mediolateral side view and the other craniocaudal view are to be taken for each breast.

Characteristic features suggestive of malignancy are—presence of a mass, asymmetric soft tissue densities and architectural distortion. Spiculated micro-calcifications especially clustering or

branching pattern are more suspicious but this is not a specific sign of malignancy. Radiation risks of mammography are negligible.

- **Digital mammography (DM)** is more accurate in younger women (< 50 years). DM can combine several images into 3D image (tomosynthesis) to reduce the false negative rate.

In the presence of any suspicious mass, one should always perform biopsy, irrespective of the mammographic findings.

- **Ultrasonography** is useful to differentiate a cystic lesion from a solid one. Solid masses with ill-defined borders and complex cystic lesions are considered suspicious. Ultrasound cannot detect microcalcifications. It also helps to take biopsy from a deep seated nonpalpable lesion.
- **MRI:** Interventional MRI can be used for MRI guided surgery. However, MRI has low specificity (37–97%) besides that it is time consuming and expensive. Therefore, MRI should be used combined with mammography USG and CBE to improve the detection rate.
- **PET** (see p. 119) has improved tumor detection rate. PET can differentiate malignant tissues from benign tissues and metastatic diseases. But it has reduced sensitivity for detection of masses < 1 cm.
- **Breast biopsy** is essential for the confirmation of diagnosis. Biopsy is generally done as an outpatient procedure.
- **Fine-needle aspiration cytology (FNAC)** is done for **cytologic evaluation** inserting a narrow gauge (22G) needle into a breast lesion. This is a simple and cheap procedure with no morbidity. Unfortunately false-negative diagnosis may be high (up to 20%) and it cannot differentiate a non-invasive carcinoma from an invasive one.
- **Core Needle Biopsy (CNB)** is done for histologic diagnosis. It is highly accurate (98%) and specific (100%) in confirming malignancy. CNB is performed under tactile, sterolactic or ultrasound guidance using local anesthesia. CNB can diagnose invasive cancer.
- **Triple test includes:** CBE, mammography and tissue sampling, when all components are benign the risk of breast cancer is low (< 1%). Whereas

if all are suggestive of cancer, the risk is high (99%). FNAC has a false negative rate of 20% and overall specificity is 98%.

TABLE 33.10

## CLINICAL FEATURES OF EARLY MALIGNANCY

- ◆ Non-tender lump in the breast (mostly located in the upper and outer quadrant).
- ◆ Non-milky nipple discharge specially bloody.
- ◆ Retraction of the nipple (previously everted).
- ◆ Indrawing of the overlying skin.
- ◆ Localized edema of the skin.
- ◆ Persistent erosion or crusting of the nipple (refractory to medication).

- **Open biopsy** is performed either as a primary procedure or when the results of FNAC are inconclusive. With excisional biopsy, the lesion is completely removed under local anesthesia. Incisional biopsy is done where only a portion of the mass is excised for confirmation of diagnosis.

**STAGING OF BREAST CANCER:** Breast cancer is staged clinically according to tumor size, regional lymph node involvement and distant metastasis (**TNM classification**). American Joint Committee on Cancer Staging (2003) reclassified the nodal status by number of involved lymph nodes, use of sentinel lymph node biopsy. Complete staging includes a thorough history, physical examination, bilateral mammography, pretreatment chest radiography, routine blood values, pathology slides with estrogen receptor, progesterone receptor and HER 2 status along with breast MRI.

Staging helps to compare the results of trials throughout the world. This is also helpful to develop uniform treatment regimens.

*For staging of breast cancer readers should consult any textbook of surgery.*

## NIPPLE DISCHARGE

A nipple discharge when spontaneous, persistent and unrelated to lactation is considered abnormal. Any significant nipple discharge must be thoroughly evaluated with the following information :



- ◆ Nature of discharge (milky, serous or bloody).
- ◆ Unilateral or bilateral.
- ◆ From a single duct or multiple ducts.
- ◆ Association of any mass in the breast.
- ◆ History of any drug intake (phenothiazines or oral contraceptives).
- ◆ Premenopausal or post menopausal.

**Nipple discharge** may be due to benign conditions or due to breast cancer (20%).

Color	Probable diagnosis
Milky	<ul style="list-style-type: none"> <li>• Physiologic (lactation)</li> <li>• Pregnancy</li> <li>• Oral contraceptives</li> <li>• Inappropriate (galactorrhea see p. 576)</li> </ul>
Bloody Sanguineous	<ul style="list-style-type: none"> <li>• Intraductal papilloma</li> <li>• Intraductal cancer</li> <li>• Malignancy • Duct ectasia</li> <li>• Fibrocystic disease</li> </ul>
Clear watery	<ul style="list-style-type: none"> <li>• Ductal cancer</li> </ul>
Green, Yellow	<ul style="list-style-type: none"> <li>• Ductal ectasia</li> </ul>
Purulent	<ul style="list-style-type: none"> <li>• Infective</li> </ul>
Serous or sticky	<ul style="list-style-type: none"> <li>• Fibrocystic disease</li> </ul>

**Diagnosis:** Careful history taking, clinical examination and, mammography should be done for woman aged 35 years. Ductoscopy to visualize the individual discharging duct and biopsy (micro-endoscopic) can be taken under local anesthesia.

### Treatment

The treatment of breast carcinoma is within the domain of general surgeon. As such, the interested readers are requested to consult Textbook of Surgery for therapeutic protocol of breast carcinoma.

## PSYCHOSEXUAL PROBLEMS

**Female sexual dysfunction** includes the different disorders: Loss of sexual desire, disorders of arousal, or inorgasmia and also painful intercourse.

**Loss of Libido** is loss of sexual desire. Loss of libido may be due to depression or it may develop from a traumatic event (e.g. rape, sexual abuse or bereavement) in the past. Several drugs can cause disorders of desire (antipsychotics, lithium, antihypertensives, beta blockers, oral contraceptives, phenytoin sodium, etc.).

**Treatment:** Psychosexual therapy is essential to deal with the underlying psychologic problems. Psychiatric consultation is needed when there is depressive symptoms. Sometimes replacement with a different contraceptive pill may improve the problem. Postmenopausal loss of libido may be improved by using androgen containing HRT.

## VAGINISMUS

**DEFINITION:** Vaginismus is defined as the psychogenically mediated involuntary spasm of the vaginal muscles including the levator ani muscles and/or the thigh adductor muscles. This results in inability of penetrative sexual intercourse.

**ETIOLOGY:** ◆ Primary ◆ Secondary

**Primary:** Nothing has entered into the woman's vagina ever. However, the vagina is normal anatomically and physiologically. The cause is mostly psychosexual in origin. There is often presence of a subconscious fear of sexual intercourse (sexual phobias).

**Secondary:** Vaginismus usually appear after childbirth or any other event in life. There is usually some local painful lesions. Such lesions include vulvitis, lacerations of the hymen, **tender scar on the perineum or narrow** vaginal introitus. The entity is usually transient and is relieved, when the cause is removed.

**CLINICAL PRESENTATION:** The woman with vaginismus avoids vaginal examination and smear. She might present with painful sexual intercourse or with infertility.

**DIAGNOSIS:** While diagnosis of the secondary one is not so difficult but to find out the cause of the primary one, examination under anesthesia may be required. If the two fingers can be easily introduced through the vaginal introitus, the caliber of the vagina is proved normal.

**TREATMENT:** ■ Primary ■ Secondary

- **Primary:** The following guidelines are prescribed:
- ◆ **Psychodynamic therapy:** Main causes of fear are removed. To educate and to gain confidence of the husband and wife. This may take time.
- ◆ **Behavioral therapy:** Dilatation of the vaginal introitus digitally followed by introduction of gradually increasing size of the dilators is to be done. Plastic vaginal trainers (Pseudopenises) with graduated sizes can help her to remove her fear. This will gain her confidence that her vagina is anatomically of normal caliber.
- ◆ **Vaginal dilators:** Daily introduction of the dilators (pseudopenises) for 1–2 weeks and to keep it inside for 10–15 minutes is enough before she is allowed to attempt coital act.
- ◆ **Surgery:** A classic case of vaginismus needs no surgery. However, surgery may be required, if the hymen is found tight — hymenectomy or Fenton’s operation (operation to enlarge the introitus), if the introitus is narrow (see chapter 34, p. 592).
- **Secondary:** The local lesion is to be treated medically or surgically.

**DYSPAREUNIA**

**DEFINITION:** Dyspareunia means that the coital act is difficult and or painful. A pareunia is inability to practice coitus. The two are most often interchangeable. Dyspareunia is the most common sexual dysfunction.

**ETIOLOGY:** ■ Male ■ Female

- **Male causes:** The following male factors are responsible:
  - Impotence.
  - Premature ejaculation.
  - Congenital anatomic defect of the penis.
  - Lack of technique of coital act.
- **Female causes:** Depending upon the site of pain, the dyspareunia may be either:
  - Superficial or entrance
  - Vaginal
  - Deep

**SUPERFICIAL:** Any lesion of the lower part of the labia minora or around the fourchette may be responsible.

**CAUSES OF SUPERFICIAL DYSPAREUNIA**

- |                          |                         |
|--------------------------|-------------------------|
| • Narrow introitus.      | • Vulval infection.     |
| • Tough hymen.           | • Urethral pathology.   |
| • Bartholin gland cysts. | • Vulvar vestibulitis   |
| • Tender perineal scar.  | • syndrome (see p. 567) |

**Vaginal:** Burning pain along the barrel of vagina either during or following intercourse is the presenting complaint. Common causes are:

- ◆ Vaginitis.
- ◆ Vaginal septum.
- ◆ Tender scar—following gynecologic operation or delivery.
- ◆ Secondary vaginal atresia.
- ◆ Tumor.
- ◆ Vaginal atrophy (menopause).

**Deep:** The patient experiences pain while the penis penetrates deep into the vagina. As the vagina is insensitive to pain, deep dyspareunia usually results from pathology of paravaginal tissues or other pelvic organs. Such lesions are:

- ◆ Endometriosis, especially on rectovaginal septum.
- ◆ Chronic cervicitis.
- ◆ Chronic PID.
- ◆ Retroverted uterus—mostly acquired and fixed.
- ◆ Prolapsed ovary in the pouch of Douglas.

**Treatment:** Treatment depends upon the cause. Too often, sex education of both the partners relieves the symptom.

The infective lesions of the vulva and or vagina are to be treated. Tender scar on the perineum or the vagina is to be excised. The treatment of vaginismus has been mentioned earlier.

**ABDOMINOPELVIC LUMP**

Pelvic and lower abdominal masses need differentiation as regard their origin (ovary, cervix, uterus) or from other organs (bowel, retroperitoneal tissues).

**This may occur at any age and are of different consistency (solid, cystic).** However, some tumors are common in a particular age group. These masses need to be diagnosed by clinical evaluation. Different investigations should be done as too often they have confusing presentation.

**FULL BLADDER:** It is an axiom that prior to gynecologic examination, bladder must be kept empty. Not only full bladder may be confused with some abdominopelvic pathology but empty bladder ensures better evaluation of pelvic findings on bimanual examination.

TABLE 33.12 COMMON CAUSES OF LOWER ABDOMINAL LUMP	
Toddlers (< 5 years)	<ul style="list-style-type: none"> <li>• Ovarian tumor</li> <li>• Mucocolpos</li> <li>• Full bladder</li> </ul>
5 years of age to puberty	<ul style="list-style-type: none"> <li>• Ovarian tumor</li> <li>• Full bladder</li> <li>• Hematocolpos</li> </ul>
Childbearing period	<ul style="list-style-type: none"> <li>• Pregnancy</li> <li>• Full bladder</li> <li>• Ovarian tumor</li> <li>• Fibroid</li> <li>• Adenomyosis</li> <li>• Chocolate cyst</li> <li>• TO mass</li> <li>• Pelvic hemocele</li> <li>• Pelvic abscess</li> <li>• Encysted peritonitis</li> <li>• Pseudocyst</li> </ul>
Postmenopausal	<ul style="list-style-type: none"> <li>• Ovarian tumor</li> <li>• Pyometra</li> <li>• Sarcoma uterus</li> </ul>

#### *Features of a full bladder*

- ♦ Strictly suprapubic, may even reach up to the umbilicus.
- ♦ Cystic or tense cystic.
- ♦ Margins—ill-defined.
- ♦ Tendency of urge for micturition on pressure.
- ♦ Disappears after catheterization.

**PREGNANCY:** Pregnancy with an uterine size of 16–18 weeks is most confusing. The confusion is accentuated with a history of oligomenorrhea, conception occurring during lactational amenorrhea or illegal pregnancy.

In fact, amenorrhea during childbearing period with a lump in the lower abdomen should be provisionally diagnosed as pregnancy unless proved otherwise.

**Differentiating features are discussed in p. 297.**

#### **OVARIAN TUMOR (Also See P. 291)**

##### *Features are:*

- Slow growing (takes months to grow).
- Menstrual history—unaffected.
- Feel—cystic, tense cystic or solid.
- Margins—well-defined but lower pole may not be reached.
- Ascites—may be present.
- Internal examination reveals:
  - The swelling is separated from the uterus.
- Sonography (see p. 296).

#### **FIBROID (see p. 272)**

##### *Features are:*

- Slow growing (takes years to grow).
- Menstrual history—menorrhagia.
- Feel—firm, may be cystic in cystic degeneration.
- Surface—nodular.
- Pregnancy features—absent.
- Internal examination reveals:
  - Swelling is uterine in origin.
  - Cervix—feels firm.
- Sonography (see p. 278).

#### **ADENOMYOSIS (see p. 314)**

- Usually associated with parous woman.
- Menorrhagia with increasing dysmenorrhea—congestive and persists even after the period.
- Lump—rarely more than 14–16 weeks.
- Uniform with well-defined margins.
- Soft and tender.
- PV examination reveals:
  - Swelling is uterine.
  - Cervix—firm, uterus—tender.
  - Associated pelvic endometriosis may be present.
  - Sonography (see p. 315). (For Differentiation of Fibroid Uterus and Adenomyosis see p. 660).

**ENCYSTED PERITONITIS (see details p. 298)**

- History of Koch's infection.
- Amenorrhea of longer duration may be present.
- Swelling—ill-defined margins.
- Feel—cystic.
- Internal examination reveals:
  - Uterus is separated from the cystic mass.
- X-ray chest—A lesion may be found.
- Mantoux test—may be positive.
- Sonography.

**PSEUDOCYESIS**

- Usually present in women having problem of infertility or approaching menopause with an intense desire to have a baby.
- History of amenorrhea.
- Abdominal examination reveals absence of positive signs of pregnancy.
- EUA — uterus of normal size.
- Sonography — empty uterus, absence of fetal echo.

**ADNEXAL MASS**

An adnexal mass refers to any mass occupying the region of the uterine appendages (adnexa). Major concern is the ovarian neoplasm (malignancy).

**COMMON ADNEXAL MASSES**

- |                          |                             |
|--------------------------|-----------------------------|
| ■ <b>Ovarian</b>         | ■ <b>Uterine</b>            |
| – Ovarian neoplasm       | – Myoma                     |
| – Ovarian cyst           | ■ <b>Gastrointestinal</b>   |
| – Endometriomas          | – Diverticulitis            |
| – Tubo-ovarian mass      | – Appendicular mass (Right) |
| ■ <b>Tubal pathology</b> | ■ <b>Genitourinary</b>      |
| – Ectopic pregnancy      | – Pelvic kidney             |
| – Hydrosalpinx           |                             |
| – Tubal neoplasms        |                             |

**Evaluation of an Adnexal Mass**

- A. **Clinical—(Bimanual pelvic) Examination** for its size, shape, consistency, mobility and tenderness.

- B. **Transvaginal ultrasonography**—Whether the cyst is simple or complex, internal echoes, nodularity. **Doppler ultrasound** to study blood flow and to measure RI and PI.
- C. **Computed tomography (CT)**—Contrast tomography can differentiate loop of bowel, dermoid cyst, myomas (Fig. 37.81B).
- D. **Magnetic resonance imaging (MRI)** is also helpful and it has no risk of ionizing radiation.
- E. **Positron emission tomography (PET)** is more sensitive in detecting metastatic disease.
- F. **Tumor markers**—Numerous tumor markers have been studied for the detection and follow-up of ovarian malignancy namely CA-125, CA-15-3, TAG-72, CA-19-9 (see p. 521).

**MANAGEMENT OF AN ADNEXAL MASS**

**Whenever any adnexal mass is diagnosed** the management will depend mainly on —(i) Nature of the mass. (ii) Age of the woman.

**Ovarian cysts in postmenopausal women**—Should be assessed for the risk of malignancy clinically and also using CA-125 and transvaginal sonography (TVS). **Important points on TVS for scoring are:** Multilocular cyst, presence of a solid areas; metastases; ascites and bilateral lesions (p. 293).

According to RMI (**Risk of Malignancy Index**) the women are triaged into **Low Risk**: RMI < 25. **Moderate Risk**: RMI 25-250 and **High Risk**: RMI > 250 (see p. 377).

**ACTUAL MANAGEMENT**

**Conservative management** is ideal for a simple, unilateral unilocular ovarian cyst, ≤ 8 cm with low RMI (<25) and normal serum CA-125. Such women are followed up with TVS at an interval of 4 months. 50 percent of such cysts resolve spontaneously.

**Surgical management:** Besides those as described above, all need some form of surgical treatment (Cyst aspiration, Laparoscopy and Laparotomy).

**Cyst aspiration** for cytologic examination to differentiate benign from malignant tumors is done. But in a postmenopausal women it is not recommended.

**Laparoscopic approach** should only be made with moderate risk women (RMI : 25–250).

**Cystectomy** for young women and oophorectomy for post-menopausal women is recommended. Such women should be counseled preoperatively that a full staging laparotomy may be needed if evidence of malignancy is seen.

**Laparotomy**—All ovarian cysts that are suspicious of malignancy especially in a postmenopausal women (RMI > 250), or with positive findings of laparoscopy, need a full staging laparotomy in a specialized center.

**Procedure includes:** Laparotomy (midline incision) → Peritoneal washings (for cytology) → Staging → Biopsies → TAH + BSO + Infracolic omentectomy (± selective pelvic and para-aortic lymphadenectomy). (RCOG 2006).

## HIRSUTISM

### NOMENCLATURE

**Hirsutism:** Hirsutism is the excessive growth of androgen dependent sexual hair (terminal hair) in facial and central part of the body that worries the patient (Fig. 33.4).



**Hypertrichosis:** Hypertrichosis connotes excessive growth of non-sexual (fetal lanugo type) hair.

**Hyperandrogenism:** Hyperandrogenism is a state of increased serum androgen level with or without any biological effect of hyperandrogenemia.

**Virilism:** Virilism is defined as the presence of any one or more of the following features—deepening of the voice, temporal balding, amenorrhea, enlargement of clitoris (clitoromegaly) and breast atrophy. It is a more severe form of androgen excess. Virilism may be due to adrenal hyperplasia or tumors of adrenal or ovary.

**In female major androgens are:** dehydroepiandrosterone sulphate (DHEA-S), dehydroepiandrosterone (DHEA), androstenedione, testosterone (T) and dihydrotestosterone (DHT). All androgenic activities are due to T and DHT.

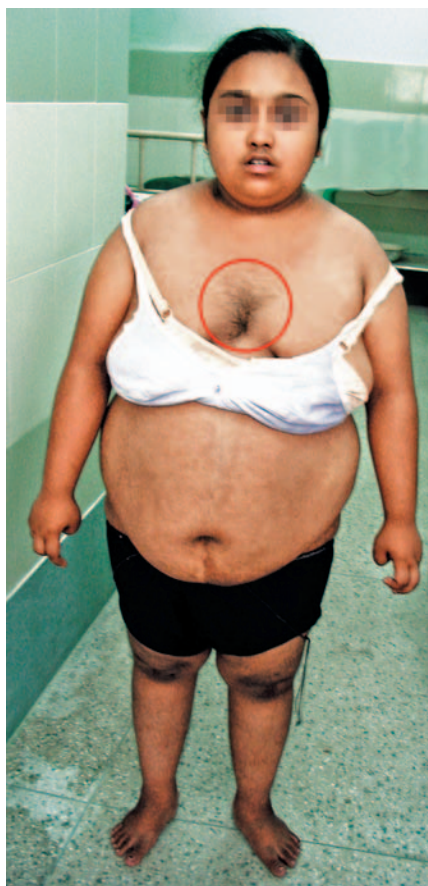### ANDROGEN SOURCES IN FEMALE

Testosterone is the second most potent androgen in circulation, the first one being dihydrotestosterone

(DHT). The daily production rate of testosterone in normal female is 0.2–0.3 mg.

Approximately, 50 percent of testosterone arises from peripheral conversion of prohormones, predominantly androstenedione. The principal sites of peripheral conversion are skin, muscle, fat, liver and lungs. The adrenal glands (z. reticularis and z. fasciculata) and ovaries (theca, stroma and granulosa) contribute approximately equal amounts (25%) to the circulatory levels of testosterone.

**Dehydroepiandrosterone sulphate (DHEA-S) arises exclusively from the adrenal glands** while about 50 percent of DHEA is secreted from the adrenals.



**Fig. 33.4:** 15 years, young obese (BMI : 34) girl with excessive growth of hair in a male distribution (face, chest and inter-mammary region)

Androstenedione arises from the adrenals and ovaries in equal amount.

The sources of androgens in normal female are schematically depicted below.

Most of testosterone (80%) in the circulation is bound to SHBG and is biologically inactive. About 19 percent is bound loosely with albumin and **only 1 percent of the testosterone remains free which is biologically active**. Normally total circulating testosterone level is 20–80 ng/dl.

To exert a biological effect, testosterone (T) is metabolically converted in target tissues to dihydrotestosterone (DHT) by the enzyme  $5\alpha$ -reductase. DHT is the most potent androgen to stimulate the hair follicles and sebaceous glands (pilosebaceous unit).  $3\alpha$ -androstane diol glucuronide ( $3\alpha$ -AG) is an important tissue metabolite of DHT.  $3\alpha$ -AG is thought to reflect the activity of the enzyme  $5\alpha$ -reductase at tissue level.

$T \rightarrow (5\alpha\text{-reductase}) \rightarrow DHT \rightarrow 3\alpha\text{-androstane diol } (3\alpha\text{-A}) \rightarrow 3\alpha\text{-androstane diol glucuronide } (3\alpha\text{-AG})$ .

Therefore, the biochemical marker for each androgen compartment is *different*. **For the ovary it is testosterone; for the adrenal gland it is DHEA-S and for the periphery it is  $3\alpha$ -AG**.


### ANDROGENS AND PILOSEBACEOUS UNIT

The pilosebaceous unit consists of sebaceous glands and hair follicles. Both are sensitive to androgens. The sebaceous glands are more sensitive to androgens than the hair follicles. Hyperstimulation of the sebaceous glands leads first to oily skin and subsequent infection results in acne.

The skin and hair follicle play an active role in serving as target organs for the androgens and also in producing androgens from circulatory prohormones.

### MECHANISM OF EXCESSIVE HAIR GROWTH

The stimulus for the excessive hair growth is testosterone. Testosterone binds to the androgen receptors in the hair follicle. This is followed by activation of the enzyme  $5\alpha$ -reductase. This will convert testosterone to most potent androgen—dihydrotestosterone (DHT) and androstenediol which stimulate proliferation and growth of terminal hair (anagen phase). Once the black terminal hair is produced,

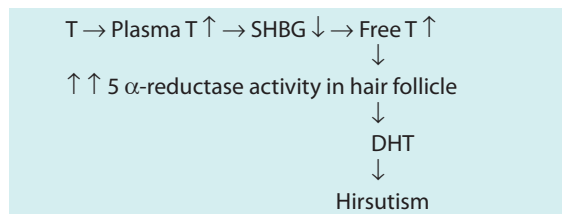


the changes persist even in the absence of a continuing androgen excess. Increased hair follicle stimulation and increased 5 $\alpha$ -reductase activity enable prohormones DHEA and androstenedione to be metabolized directly to DHT. **This latter phenomenon explains continued growth even if the initiating testosterone source has been removed.**

### PATHOPHYSIOLOGY OF HIRSUTISM

It involves combination of the following:

- Increased concentration of serum androgens—especially of testosterone.
- Decreased level of SHBG resulting in increased free testosterone (testosterone itself reduces SHBG level).
- Increased responsiveness of the target organ (skin) to the normal circulating androgens. This may be related to ethnic background. Oriental women have less number of hair follicles per unit area of skin compared to a Caucasian woman.
- Increased activity of 5 $\alpha$ -reductase which converts testosterone to DHT in the skin and hair follicles.



**Thus, the hair follicle becomes a secondary site of androgen metabolism at the expense of hair follicle stimulation and hirsutism.**

### CAUSES OF HIRSUTISM (Table 33.13)

Hirsutism may be associated with excess androgen production either from the ovaries or adrenals or excess stimulation of the endorgans, i.e. hair follicles. It represents one of the early manifestations in the spectrum of virilism. Whereas, virilism is almost always associated with hirsutism (except at birth) but hirsutism may not be associated with virilism. There may be racial or familial link. Increased hair growth is observed during puberty, pregnancy and following menopause.

**Obesity (android)—Insulin resistance and androgen excess.** Obesity (BMI >25) associated with distribution

**TABLE 33.13 CAUSES OF HYPERANDROGENISM**

- **Ovarian**
  - Polycystic ovarian syndrome (PCOS) (see p. 459)
  - Sertoli-Leydig cell tumor (see p. 386)
  - Hilus cell tumor
  - Lipoid cell tumor
  - Hyperthecosis – Luteoma of pregnancy
- **Adrenal**
  - Adrenal hyperplasia (congenital or late onset) (see p. 465)
  - Cushing's syndrome (see p. 466)
  - Adrenal tumor
- **Obesity (android)**
  - Insulin resistance and androgen excess (p. 460)
  - HAIR-AN syndrome (p. 459)
- **Exogenous (drug therapy)**
  - Androgens, anabolics, oral contraceptives, synthetic progestogens, danazol, phenytoin, diazoxide, cortisone, etc.
- **Postmenopause**
- **Pituitary tumor** — secreting
  - Excess ACTH (Cushing's diseases)
  - Excess growth hormone (acromegaly)
- **Idiopathic:** Increased sensitivity to androgens.

of fat primarily in the gluteal and femoral region is called **gynoid obesity**. Whereas in **android obesity**, fat distribution is in the trunk and abdominal region. Android obese women are often associated with hyperinsulinemia (insulin resistance), impaired glucose tolerance and excess androgen production (see p. 470).

Obesity (android) → (↑) insulin → abnormal glucose tolerance/diabetes mellitus → (↑) androgen production → (↓) SHBG → (↑) free T and E<sub>2</sub>.

### INVESTIGATIONS (Table 33.14)

The following guidelines are prescribed in an attempt to pinpoint the diagnosis.

- History of intake of an offending drugs producing androgenicity is to be excluded first.
  - Family history of excess hair growth is too often correlated.
  - **Mild hirsutes** are not infrequently found during puberty, pregnancy and postmenopause. **During postmenopausal period**, there is decreased SHBG, more amongst obese

patients, resulting in elevated testosterone (see above).

#### ■ **Physical examination includes:**

- ◆ **BMI calculation** ◆ Modified Ferriman – Gallway score for grading hirsutism.
- ◆ Others for: acne, acanthosis nigricans (p. 459), galactorrhea and clitoral size.
- ◆ **Hirsutism of rapid onset** and progressive in nature or symptoms of virilization, needs exclusion of a tumor (adrenal or ovarian). Serum DHEA-S > 700 µg/dl may rarely be seen with adrenal tumors.
- ◆ **Patients with primary amenorrhea** with or without virilism, require karyotyping to exclude ‘Y’ bearing dysgenetic gonads.
- ◆ Hirsutism of irrespective of age, requires evaluation for adrenal or ovarian tumor.
- ◆ High serum level of testosterone (> 150 ng/ml) is mostly associated with an androgen producing tumor. Serum level of DHEA-S correlate well with daily urinary 17–KS secretion. Further evaluation should be done with ultrasonography, CT or MRI (see Table 33.14).
- ◆ Mild hirsutism, young age, insidious onset, unassociated with virilization and having normal menstruation without any abnormal clinical finding usually point towards idiopathic or peripheral cause. Mild hirsutism with irregular menses may be due to PCOS. Oral OGTT may be done to detect insulin resistance.
- ◆ **Women with mild hirsutism** of long duration, regular menses, no virilization, require no investigation. **Moderate to severe hirsutism** needs serum total testosterone estimation (T). Raised serum T (> 150 ng/dl) needs thorough evaluation with TVS, adrenal CT for exclusion of tumors (adrenal, ovary). Serum T level < 150 ng/dl may be due to PCOS.
- ◆ **In Cushing’s disease**, because of increased ACTH secretion from the anterior pituitary, there is increased glucocorticoid and androgen secretion from the adrenals. The findings include hirsutism, menstrual abnormalities, centripetal obesity, abdominal striae, etc. If

the plasma cortisol level is < 1.8 µg/mL after overnight 1 mg dexamethasone suppression, Cushing’s syndrome can be ruled out.

- ◆ **Late onset congenital adrenal hyperplasia** is rarely associated with hirsutism. This is due to partial deficiency of 21-hydroxylase enzyme. Serum level of 17 α-hydroxy progesterone (17-OHP) is elevated both baseline and after stimulation of ACTH.

- *The diagnostic features of adrenal or ovarian causes are outlined in the Table 33.14.*

#### **MANAGEMENT PRINCIPLES OF HIRSUTISM**

- ◆ To remove the source of excess androgen.
- ◆ To suppress or neutralize the action of androgen.
- ◆ To remove the excess hair.

**Weight reduction**—is an important step of management. Weight loss is associated with reduction of hyperinsulinemia and androgen excess. Ideal body mass index (BMI) should not be more than 25 (see p. 573).

#### **Removal of the source**

- ◆ Adrenal or ovarian tumor should be surgically treated.
- ◆ Cushing’s disease can be treated by adrenalectomy, radiation to the pituitary or removal of ACTH producing tumor by transsphenoidal surgery.
- ◆ In iatrogenic cases, the offending drug (see Table 33.13) should be stopped.

#### **To suppress or neutralize the excess androgen action**

**The drugs used**—depending upon the site of production of excess androgens are:

- ◆ Combined steroidal contraceptive pill.
- ◆ Dexamethasone.
- ◆ Antiandrogens.

#### **CONTRACEPTIVE PILL**

##### **Mode of action**

- ◆ Suppression of LH secretion from the pituitary (progestin effect).
- ◆ Anti-androgen at the level of hair follicle.
- ◆ Elevation of SHBG (estrogen effect).



**TABLE 33.14** DIAGNOSTIC FEATURES FOR ADRENAL OR OVARIAN CAUSES OF HYPERANDROGENISM

ADRENAL		OVARIAN	
Hyperplasia	Tumor	Tumor	PCOS
Perimenarcheal (early onset) Insidious Hirsutes + Virilism ± MH – Amenorrhea (MH – Menstrual history)	Any age Rapid onset Hirsutes ++ Virilism + MH – Amenorrhea	Any age Rapid onset Hirsutes ++ Virilism + MH – Amenorrhea	Early reproductive Insidious Hirsutes ± Virilism — Nil MH – Oligomenorrhea or amenorrhea
<b>Hormone status</b> • 17 hydroxy progesterone ↑↑ (> 800 ng/dl) • DHEA-S • Testosterone (T) – Normal (< 0.8 ng/mL) • Dexamethasone suppression test : positive	<b>Hormone status</b> • DHEA-S ↑↑ (> 700 µg/100 mL) • T-normal or ↑ • Dexamethasone suppression test — negative • IVP • Sonography • CT scan • MRI (pituitary)	<b>Hormone status</b> • T ↑↑ (> 200 ng/100 mL) • DHEA-S Normal or ↑  • Sonography • Laparoscopy • Biopsy	<b>Hormone status</b> • LH : FSH-3 : 1 • T ↑ (≤ 150 ng/dl) • DHEA-S — may be ↑ • Insulin resistance (IR): Raised fasting serum insulin ↑ (> 25 µ IU/mL). Fasting glucose/insulin ratio : < 4.5 indicates insulin resistance. Sonography (see p. 459) Laparoscopy (see p. 460)

- ◆ Progestins in OC pills inhibits 5 α-reductase activity in the skin.
- ◆ Inhibits adrenal androgen secretion.

OC pills with **new progestins** (norgestimate, desogestrel, gestodine — see Ch. 29) have very little androgenic effects. They increase the level of SHBG. They reduce free testosterone level significantly.

**Case selection:** Pill is suitable in cases of PCOS or idiopathic group especially in young and unmarried where only ‘T’ is elevated (Table 33.15).

**Dexamethasone:** It acts by suppressing pituitary-adrenal axis. It is used in adrenal or mixed adrenal and ovarian hyperandrogenism.

The dose varies from 0.25–1 mg daily at bed time.

**GnRH agonists** are used to suppress selectively ovarian steroid production by inhibiting LH secretion from the pituitary. This is used only when other anti-androgens have failed to give a response.

## ANTI-ANDROGENS

**Cyproterone acetate** is a derivative of 17–OHP. **It inhibits gonadotropin secretion and interferes with androgen action on the target organs by competing for the androgen receptors.** It blocks the action of DHT and T at both the nucleus and cytosol receptor level.

It should be administered along with ethinyl-estradiol to prevent menstrual irregularities and ovulation. It is available as combined estrogen — progestin oral contraceptive (2 mg cyproterone acetate and 35 µg ethinyl estradiol).

Improvement of hirsutism is observed after 3 months of therapy. This regimen gives contraceptive benefit also. **Important side effects are:** nausea, fatigue, weight gain, loss of libido and mastalgia.

**Spirolactone — It is an aldosterone antagonist and acts as a potassium sparing diuretic.**

Anti-androgen effects of spironolactone are :

- ◆ It inhibits ovarian and adrenal androgen biosynthesis.

- ◆ It competes with DHT for the androgen receptors in the hair follicle.
- ◆ It inhibits 5  $\alpha$ -reductase activity directly.

100–200 mg is given daily and the maintenance dose is 25–50 mg daily.

**Important Side Effects are:** Menstrual irregularity, fatigue, hyperkalemia.

**Flutamide**—It is a nonsteroidal anti-androgen. It blocks the androgen receptors as well as it inhibits testosterone biosynthesis. Results are observed after 3 months of therapy. It is given in a dose of 100–200 mg daily. **Side effects are:** nausea, dry skin, headache and hepatotoxicity.

**Finasteride**— It inhibits 5  $\alpha$ -reductase activity. It improves hirsutism significantly without any side effects. Daily dose is 5 mg.

**Ketoconazole** — see p. 538.

**Insulin sensitizing drugs.** Women with insulin resistance (PCOS) are treated with metformin and thiazolidinediones (rosiglitazone). These drugs decrease circulating insulin and androgen levels.

**Glucocorticoids** are used to suppress endogenous ACTH secretion to suppress adrenal androgen levels in cases with CAH. But they are less effective. Spironolactone containing COC pills may be the next choice.

**Duration of therapy:** Response of all the drugs are slow. Drugs should be continued for at least 6 months. Anti-androgens inhibit the growth of new hair follicle but fails to remove the hair that is already present.

**Removal of hair:** The excess hair is to be removed by bleaching, twitching, epilation, waxing, lasers, shaving or electrolysis. Laser and pulsed light therapy destroy hair follicles. Skin pigmentation may occur. In electrolysis, individual hair follicle is destroyed. **Side effects are:** pain, scarring and pigmentation.

**Eflornithine** hydrochloride (13.9% cream) when used topically prevents hair growth by inhibiting the enzyme ornithine decarboxylase. This enzyme acts on the dermal papilla to stimulate hair growth. Treatment needs to be continued for a long time.

TABLE 33.15		HORMONE PROFILE AND DRUG THERAPY	
Hormone profile		Drugs	
Elevated T (Ovary)		Combined oral contraceptives (COCs containing drospirenone or desogestrel)	
Normal T and DHEA-S 3 $\alpha$ -AG $\uparrow$ (idiopathic)		Anti-androgens	
DHEA-S $\uparrow$ , normal T		Dexamethasone	

## GALACTORRHEA

**DEFINITION:** Galactorrhea is the secretion of a milky fluid which is inappropriate (unrelated to child birth). The secretion contains fat globules when examined under microscope and is confirmatory for milk. A high prolactin level is encountered in one-third of cases with idiopathic amenorrhea.

Prolactin (PRL) is the most important hormone involved in the **pathophysiology of amenorrhea and/or galactorrhea**. Prolactin is under tonic hypothalamic inhibitory control of prolactin inhibitory factor (PIF).

Prolactin inhibits GnRH pulse secretion. Gonadotropin levels are suppressed. Hyperprolactinemia inhibits ovarian steroidogenesis. Hyperprolactinemia ultimately results in hypogonadotropic hypogonadism, oligomenorrhea, amenorrhea, anovulation and many other clinical effects of hypoestrogenism.

TABLE 33.16		INDICATIONS OF PROLACTIN ASSAY	
<ul style="list-style-type: none"> <li>• Amenorrhea with or without galactorrhea</li> <li>• Galactorrhea with or without amenorrhea</li> <li>• Oligomenorrhea</li> <li>• Corpus luteum insufficiency</li> <li>• Unruptured luteinized follicle</li> <li>• Delayed puberty</li> <li>• Hirsutism</li> </ul>			

PRL levels should be estimated in all women with galactorrhea, oligomenorrhea or amenorrhea. TSH level should be measured to rule out primary hypothyroidism.

Prolactinoma is present in about 50 percent of women with hyperprolactinemia. Serum prolactin level when raised on repeat assay beyond 20 ng/mL, suggests evaluation of sella turcica (see p. 464). Level beyond 100 ng/mL is associated with high

incidence of prolactinoma. Most of the prolactinomas are microadenomas. **About 33 percent of women with high prolactin levels, have galactorrhea.** However, galactorrhea can be seen in women with normal serum prolactin. About 30 percent of women with galactorrhea have normal menses. Women with ‘big’ prolactin (see p. 464) may have normal menses with minimal or no galactorrhea.

For causes, diagnosis (Table 33.16) and management of hyperprolactinemia (see p. 464, 471, ch.28).

## KEY POINTS

- ▶ Leucorrhoea is defined strictly as an excessive normal vaginal discharge which stains the undergarment. It is nonpurulent, non-offensive and never causes pruritus.

The excess normal secretion occurs during puberty, menstrual cycle (around ovulation and premenstrual), pregnancy and sexual excitement. Abnormal vaginal discharge is mainly infective in origin (see Table 33.2).

Improvement of general health, sympathetic attitude towards ailments, local hygiene and appropriate therapy for the local ailments are enough to cure the state.

- ▶ Pruritus means sense of itching. It does not produce pain; nor there is any local tenderness.

Local skin lesions, vaginal discharge, allergy, intestinal worms or diabetes are some of the important causes. Appropriate therapy is to be instituted depending upon the factors involved. Vulvectomy is not the treatment to cure pruritus.

- ▶ The significance of postmenopausal bleeding should not be underestimated. About one-third of the cases are due to pelvic malignancy, the commonest being uterine (Table 33.8).

Apart from routine use of gynecological examination, the special investigations include cytology, transvaginal sonography, fractional curettage, hysteroscopic evaluation and/or laparoscopy. Even if no cause is detected, recurrence or persistent uterine bleeding dictates hysterectomy with bilateral salpingo-oophorectomy.

- ▶ Pain arising from the pelvic organs is often localized not to the organ but referred to the skin area supplied by the same spinal nerve (Table 33.3).

The basic mechanism of **acute pain** is due to irritation of the peritoneum by either blood or infection.

Apart from history and clinical examination, the investigations to pinpoint the diagnosis of acute pelvic pain include—examination of blood for hematocrit, midstream urine examination for UTI and urine for immunological test for pregnancy (Table 33.4). The diagnosis is established in most cases.

Management in cases of definite diagnosis includes either immediate laparotomy or institution of medical therapy. In doubtful cases, diagnostic laparoscopy and observation are of help (Table 33.5).

**Chronic pelvic pain (CPP)** is defined as six months or more of constant or intermittent pain (nonmenstrual pain) localized in the pelvis or lower back severe enough to cause functional disability or requiring medical or surgical treatment. CPP is often without any visible pathology (Table 33.6). Incidental detection of pathology may not be the cause of pain. Laparoscopy is done both for diagnostic and therapeutic purposes as “one-stop” procedure. In the absence of definite pathology, medical management of pain should be tried first.

Contd...

Medical treatment includes—analgesics, prostaglandin synthetase inhibitors, OC pills, progestogens, danazol or even GnRH analogues. Minimal surgery includes laser therapy in pelvic endometriosis and adhesiolysis endoscopically. Hysterectomy should be contemplated judiciously.

- ▶ **Trapped or residual ovarian syndrome** is manifested with chronic pelvic pain. The pain arises from the ovaries (preserved during hysterectomy) due to tension within the growing follicle or due to periovarian adhesions. The chronic pelvic pain in ovarian remnant syndrome is due to the remnant of ovarian cortical tissue, left behind unintentionally following a difficult oophorectomy.
- ▶ The backache pointed by fingertip is not of gynecologic origin. The pain in prolapse subsides when the patient is at rest and aggravates on standing. Mobile retroverted uterus does not produce backache.
- ▶ Breast carcinoma is one of the leading cause of death among female malignancies.

The screening includes—breast self-examination, clinical breast examination, imaging studies and breast biopsy (see p. 564). Baseline mammogram is to be done at 40 years. Mammography along with physical examination is to be done annually from the age of 40 and earlier in high risk group.

Irrespective of mammographic findings, presence of any suspicious mass suggests biopsy.

- ▶ FNAC is a rapid diagnostic method with high degree of accuracy. Ultrasound guided procedure allows the needle tip to reach the exact site.
- High risk factors for breast carcinoma are many (Table 33.9). Mutations in BRCA-1 and BRCA-2 genes (tumor suppressor genes) account for familial breast cancer (5%), which has an early age onset.
- ▶ Causes of bloody nipple discharge are (Table 33.11) malignancy, intraductal papilloma, fibrocystic disease and duct ectasia. Purulent discharge is due to infection and serous or sticky discharge is due to fibrocystic disease.
- ▶ Female sexual dysfunction includes different disorders (p. 565). Dyspareunia means that the coital act is difficult and or painful. Apeareunia is inability to practice coitus. Causes of deep dyspareunia are pelvic endometriosis, chronic cervicitis, chronic PID, fixed retroverted uterus or prolapsed ovary in the pouch of Douglas.
- ▶ Prior to gynecological examination, bladder must be kept empty. Full bladder should be excluded first in the differential diagnosis of abdominopelvic lump; similarly, pregnancy has to be excluded in childbearing period irrespective of the status of the women (Table 33.12)—married, unmarried, widow, divorced or separated.
- ▶ The principal sources of androgen in female are peripheral (50%), ovaries and adrenals (p. 572 – flow chart). Most of the testosterone (80%) in the circulation is bound to SHBG; 19 percent is bound with albumin and 1 percent remains free which is biologically active.

In the pilloseaceous unit, the testosterone is converted into potent dihydrotestosterone by the enzyme  $5\alpha$  reductase. Hirsutism may be associated with excess androgen production either from the ovaries or adrenals or excess stimulation of the hair follicles. Virilism is almost always associated with hirsutism except at birth but hirsutism may not be associated with virilism.

Causes of hirsutism may be in the adrenals, ovaries, exogenous drug therapy or idiopathic (Table 33.13).

In adrenal hyperplasia, 17-hydroxyprogesterone is elevated; in adrenal tumor, DHEA-S is elevated; in ovarian tumour, testosterone is elevated and in PCOS, LH : FSH ratio is increased. Dexamethasone suppression test is positive in adrenal hyperplasia but not in tumor. Sonography, CT scan, MRI, IVP and laparoscopy may be extended to exclude organic lesion (Table 33.14).

- ▶ For each major compartment of androgen source, one biochemical marker is used. Testosterone reflects ovarian, DHEA-S reflects adrenal gland and  $3\alpha$ -AG reflects peripheral tissue source (p. 570).

Contd...

Contd...

- Increased 5 $\alpha$ -reductase activity is seen in idiopathic hirsutism.
- Women with PCOS often suffer from android obesity (BMI > 25). Biochemical abnormalities observed in women with PCOS are: elevated levels of biologically active LH, hyperinsulinemia in 40 percent (insulin resistance), impaired glucose tolerance and excess circulating androgen (see Ch. 28).
- The most common cause of hirsutism is PCOS. Women with a serum testosterone level > 200 ng/dL needs investigations (DHEA-S, 17-OHP, USG, CT and MRI) to exclude tumors (ovary, adrenal) or CAH.
- Treatment of hirsutism depends on the source of excess androgen (see Table 33.15). Oral contraceptive therapy is instituted when serum testosterone is elevated (ovarian androgen). Dexamethasone is the drug of choice when DHEA-S is elevated (adrenal androgen). Antiandrogens (see p. 576) are used when neither is elevated (peripheral androgen). Most women (80%) with idiopathic hirsutism have elevated levels of 3 $\alpha$ -AG. The best treatment for such a woman is antiandrogen, spironolactone.
- Antiandrogens should be continued for a minimum of 3 months before any response is observed. This is due to the length of hair growth cycle. While the antiandrogen inhibits the growth of new hair follicle, it fails to remove the hair that is already present.
- Source of excess androgen may have to be removed surgically (see Table 33.14). Removal of hair is done by bleaching, twitching, epilation or electrolysis.
- Any medical management of hirsutism needs at least 6 months to get the benefits of therapy. This is because the life cycle of a hair follicle is 6 months.
- Women having mild hirsutism of long duration, regular menses, no virilization, require no investigations. They may be treated with COCs or COCs containing drospirenone or desogestrel.
- Prolactin is the most important hormone, involved in the pathophysiology of galactorrhea.
- Common causes are pituitary microadenoma (smaller than 10 mm), hypothalamic pathology, drug therapy (reserpine, OC, psychotropic agents, methyldopa, etc.) and primary hypothyroidism (see ch. 28). Serum prolactin level of > 100 ng/mL is too often associated with tumor (prolactinoma).
- Bromocriptine is the drug of choice for galactorrhea. Cabergoline is more effective and well tolerated compared to bromocriptine. Pregnancy following bromocriptine has got no teratogenic effect on the offspring. There is no increased incidence of multiple pregnancy.
- Most macroadenomas enlarge with time whereas most microadenomas do not. Bromocriptine shrinks 80% of macroadenomas. Surgical treatment of prolactinomas (transnasal-transsphenoidal excision) is done for women who fail to respond with medical treatment.
- Cabergoline is more effective and well tolerated compared to bromocriptine.
- An adnexal mass needs to be critically evaluated to formulate the management. Clinical examination, imaging studies, tumor markers and the genetic markers (p. 570) are helpful to distinguish a benign from a malignant tumor. An adnexal mass may be followed up or may need medical or surgical intervention depending upon its nature (benign or malignant), size and the patient's age.

# Operative Gynecology

## INTRODUCTION

**Perioperative management encompasses** the care in the pre, intra and postoperative periods. The decision to operate and whether it should be emergently or electively is also important.

The prime objective of this chapter is to make the readers familiar with the basic information about different aspects of practical gynecology. While the technical details may only concern the specialists, **the beginners should be familiar with the basic principles of operative gynecology.** The interested readers may go through the available textbooks of operative gynecology for further details.



## PREOPERATIVE PREPARATIONS

The ultimate objective of surgery is to cure the ailments and/or to arrive at a diagnosis, if it is done for diagnostic purpose.

Preoperative evaluation should include a detailed history (general, medical and surgical), a complete physical examination and laboratory investigations. BMI (see Chapter 9) is recorded for assessment of nutritional status. Past records of illness or surgery should be evaluated. An anesthesiologist should see the patient preoperatively. A physician or other specialists may be involved depending upon the patient's need. For any elective (planned) operation, the general condition of the patient must be improved, prior to operation any systemic disorder including anemia must be corrected.

## INVESTIGATIONS

**The objectives of preoperative investigations are:**

- ◆ To evaluate the health status of an individual who may be otherwise healthy.

- ◆ To provide a base line information in the event of any postoperative complication.
- ◆ To assess the severity of a pre-existing medical disorder that needs further attention.

The investigations should preferably be done prior to admission.

### Rationale for preoperative investigations

Any major gynecological surgery involves anesthesia, blood loss and disturbances in major organ function like cardiovascular and respiratory. The purpose of preoperative investigations is to assess the individual's physiological reserve and the ability to withstand the surgical stress.

### Routine investigations for major surgery

- **Blood**—Estimation of hemoglobin, hematocrit, total and differential leucocyte count, platelet count, blood group and cross matching are done. **Other blood tests:** Liver function, renal function, serum electrolytes, blood sugar in aged women or in complicated cases.
- **Urine**—Routine and microscopic analysis includes examination for protein, sugar, casts and pus cells. If the pus cells are more than 5 per high power field, culture sensitivity is required.
- **Chest X-ray (CXR) and ECG**—For an otherwise healthy individual below the age of 40, these are not essential. But women above 40 years of age should preferably have CXR, ECG and serum electrolytes analysis.

If there is any history of systemic disease, relevant investigations should be carried out accordingly. Relevant investigations (e.g. echocardiography, coagulation profile) should be done as indicated. Special investigations appropriate to some lesions such as VVF, malignancy have been mentioned in the concerned chapters.

To protect the surgical staff, screening for hepatitis B virus in high-risk group is necessary. The screening for HIV antibodies should be done following patient counseling and permission (see p. 155).

**Admission:** The patient is to be admitted on the day or 1–2 days prior to operation. Special cases need earlier admission. During this period, re-evaluation of the case and examination by anesthetist should be done.

**Preoperative work-up:** Enquiry should be made about the details of medical or surgical history: anemia, diabetes, hypertension, tuberculosis, urinary problems, kidney, liver disease, jaundice, asthma, malignant disease, drug allergy, corticosteroid therapy, any infection (HIV) or medication used are to be noted.

**Benefits of preoperative evaluation are:** (i) decrease surgical morbidity, (ii) reduce preoperative delay or cancelation of surgery, (iii) optimize base line health status, (iv) organize plan of anesthesia.

## PREOPERATIVE COUNSELING AND INFORMED CONSENT

Preoperative discussion between a doctor and a patient (guardian in case of minor), should be in general terms. It should remove patient's anxiety and fear for operation. Pamphlets are useful as only a few (30%) patients can recollect verbal discussions. **The following should be explained to her:**

- ▶ Diagnosis of the abnormality.
- ▶ Nature of the operation and its modifications depending on the findings during operation.
- ▶ The likelihood of success of surgery.
- ▶ The risks and complications of surgery.
- ▶ Alternative forms of treatment available.
- ▶ Informed consent must be in writing and in a prescribed proforma.
- ▶ Prognosis if the treatment is refused.
- ▶ Consent must be voluntary and without coercion.
- ▶ Consent form must be signed by the patient and the physician.

**Diet:** Light diet is given in the previous evening and nothing in the morning of the day of operation. Nothing by mouth for at least 8 hours before the

operation is ideal, so that the stomach is empty at the time of anesthesia.

**Preparation of the bowel:** A cleansing enema is commonly given in the evening before the operation day. Rigorous bowel preparation is not routinely required unless bowel surgery is expected. However, in cases where satisfactory bowel preparation is needed, osmotic oral purgation using polyethylene glycol solution (Macrogols) are used. Patient is asked to drink 1–2 liters of such mixtures. To avoid dehydration intravenous fluids may be needed.

**Night sedation:** To ensure good sleep at night prior to the day of operation, either diazepam 5–10 mg or alprazolam 0.25–0.5 mg tab is given at bed time.

**Local antiseptic care: Abdominal preparation—**Routine shaving of the operative area before surgery is not recommended. Hair clipping reduces the rate of wound infection. Cleaning of the operative area with soap and water is generally done by the patient. The surgically prepared area should extend from the inferior rib cage to the mid thigh. The abdomen is cleaned with a five minute scrub using povidone iodine solution before surgery.

**Vaginal operation—**The vaginal preparations include clipping of the pubic hair and up to middle of both the thighs. Presence of active vaginal or cervical infection requires eradication prior to surgery.

The perineum and the vulva are cleaned with Savlon using a sponge held in a sponge forceps (Fig. 37.15). The vagina is cleaned with povidone iodine solution. This solution is then flushed away with sterile water poured into the vagina. Then a sterile sponge on a sponge forceps is used to clean the vagina.

**Morning medication:** In consultation with anesthetist, sedative like diazepam 5–10 mg orally, is given about two hours prior to sending the patient to the operation theater. Inj. atropine sulfate 0.6 mg is usually (not as a routine) administered in the operation theater intravenously by the anesthetist.

**Other medications:** The patient is generally advised to take all regular medications on the morning of surgery with sips of water, unless contraindicated.

**Surgical site infection and prophylactic antibiotics:**

**Surgical infections** may occur within 30 days of operation. Source of infection may be the contami-

nated instruments, surgeon's hand, theater air or from patient's endogenous flora at the operation site. Other risk factors are: Patient's age, diabetes mellitus, immunosuppression, prolonged hospital stay or prolonged operation. **Prophylactic antibiotic** is aimed to maintain adequate tissue levels of antibiotics for the duration of operation. Its main **disadvantage** is the development of antibiotic resistance.

A broad spectrum antibiotic is selected to cover the common gram-positive, gram-negative and the anaerobic organisms. Generally, a third generation cephalosporin (ceftriaxone 1 g) is given by slow intravenous route on induction of anesthesia. Second dose is repeated after 12 hours. Inj. Metronidazole 500 µg IV 8 hourly is given to combat anaerobic infection.

**Thromboprophylaxis** is to be given to reduce the risk of venous thromboembolism (VTE). In major gynecological surgery, the risks of deep vein thrombosis and the pulmonary embolism (PE) are high. The risk of VTE are high particularly in patients with age >60 years, obesity (BMI >30 kg/M<sup>2</sup>), positive family/personal history, APL syndrome, severe infection, active cancer, prolonged immobility or thrombophilia. A patient should be adequately hydrated. Mechanical measures like compression stockings, intermittent pneumatic compression, leg exercises, early mobilization are recommended. Low molecular weight heparin or unfractionated heparin is used to reduce the risk of DVT and PE. However, there may be increased bleeding due to use of heparin.

### Preoperative work up in the operation table

- ◆ **IV infusion**—An infusion of Ringer's solution drip is started.
- ◆ **Anesthesia**—Local, regional or general anesthesia is administered with sole discretion of the anesthetist.
- ◆ **Position of the patient**—In abdominal operation, the position is dorsal, whereas in vaginal operation, it is lithotomy.
- ◆ **Antiseptic dressings: Bladder preparations:** For minor operations the patient voids before being taken to the operating room. For major operations, soft rubber catheter or Foley's catheter is inserted in operating table. In **vaginal operation**, metal catheter is used after draping and Foley's catheter is introduced at the end of the operation and (see Fig. 37.6).

- ◆ **Draping**—Proper draping is done prior to surgery using sterile linen, towel and leggings (in vaginal operation). Towel clips are used (see Fig. 37.40).

### FORMALITIES IN MINOR VAGINAL OPERATIONS

- ◆ Examination of the cardiovascular system.
- ◆ Blood examination for hemoglobin estimation and total and differential count.
- ◆ Urine examination for protein, sugar and pus cells.
- ◆ The patient is to be admitted in the morning of the day of operation.
- ◆ Oral feeding is to be withheld for at least 8 hours prior to surgery.
- ◆ Vulval cleaning is only done.
- ◆ The patient is asked to pass urine before entering the operation theater.
- ◆ Anesthesia.
- ◆ Lithotomy position (Fig. 9.3) Chapter 9.
- ◆ Antiseptic painting of the vulva and vagina.
- ◆ Draping.
- ◆ Examination under anesthesia.

**Day Surgery** includes selected surgical procedures where patients are admitted, operated and discharged **on the same day**. The operation should not be unduly complex or time consuming. Patients are screened before hand (see above). **Benefits of day surgery are:** (i) increased patient turn over, (ii) reduced hospital stay, (iii) reduced inpatient work load and (iv) reduced concomitant cost, (v) least disturbances of patient's daily work.

Assessment of suitability for day care surgery is important. After operation the patient should be seen both by the surgeon and the anesthetist. Before the discharge, follow up procedures, analgesia and availability of emergency services are explained to the patient.

### Common Gynecological Day Surgery Cases

- ◆ Dilatation and curettage.
- ◆ Termination of pregnancy (D and E).
- ◆ Biopsy procedures.
- ◆ Examination under anesthesia.
- ◆ Endoscopic procedures like (see ch. 35):
  - Diagnostic hysteroscopy, laparoscopy (p. 121)
  - Laparoscopic sterilization operation (p. 498)
  - Ovarian drilling diathermy (p. 471)



- Transcervical resection/ablation of endometrium. (p. 193)

## INTRAOPERATIVE CARE

### ■ Incisions

Most of the gynecological operations are done through transverse incisions.

- ◆ **Pfannenstiel incision** (muscle separating) is commonly used. • **The main advantages of transverse incision are**—(i) Rapid wound healing, (ii) Better postoperative convalescence, (iii) Superior cosmetic result, (iv) Good access to pelvic organs. Less incidence of postoperative complications, (v) Wound dehiscence and (vi) Incisional hernia.
- **Disadvantages are**—Incision is difficult to extend when exploration of the upper abdomen is needed. Other transverse incisions are:
  - ◆ **Cherney incision:** The rectus muscle is dissected from its insertion at the symphysis. During closure the rectus tendons are united to inferior portion of the rectus sheath with interrupted sutures.
  - ◆ **Maylard incision** is a true transverse muscle cutting incision. The inferior epigastric vessels are ligated before incising the rectus. The muscles are approximated during closure.
  - ◆ **Vertical (Median or Paramedian) incisions** give good access to whole of abdomen with excellent exposure. It spares all major nerves, vessels and muscles, as opposed to the transverse incision. It gives rapid entry to the abdominal cavity.
- **Disadvantages:** It lacks all the advantages of transverse incision.
- **DRAINS** are used to prevent any accumulation of blood, pus, lymph, bile or intestinal secretion. They are less commonly used in gynecological surgery when hemostasis is satisfactorily achieved. Early removal of drains is done to avoid infection and to improve mobilization. It is usually done by 2–3 days after surgery when drainage is < 100 mL in 24 hours.
- **CLOSURE OF PERITONEUM:** Traditionally closure of the pelvic and parietal peritoneum is done at the end of the operation to decrease adhesions. However, the current studies have shown that such closure increases adhesions

(RCOG—1998). Peritoneum rapidly spreads across any raw areas left after surgery and there is no need of peritoneal closure.

## POSTOPERATIVE CARE

**Postoperative Care:** Aims are: (i) Support to restore patient's physiological functions, (ii) Promote tissue healing, (iii) Prevention/management of complications. Good postoperative care team involves surgical team, nursing staff, physiotherapists and dieticians.

### Return from Operation Theater

**Immediate postoperative care**—On return from the theater the patient is taken to the recovery room or ward which is usually placed adjacent to the operation suite. Patient is accompanied by a responsible person—doctor or nursing staff. **The prerequisites prior to shifting are:**

- ◆ Vital signs such as pulse, respiration and blood pressure become steady.
- ◆ Patient recovers from anesthesia and is fully conscious.
- ◆ Anesthetist's consent should be available.
- ◆ Fluid balance and any bleeding from the surgical site are checked.

### In the Ward

#### First 24 hours (D–O)

**Placement in the bed:** The patient is gently placed on her side in the bed. This reduces the risk of inhalation of vomitus or mucus. If spinal anesthesia is given, the foot end is raised for about 12 hours.

**Observation:** The observation of the vital signs such as pulse, respiration and blood pressure is made half hourly in the initial period. The interval is gradually increased if these are found steady. Attention should be paid for any bleeding from the operated site.

**Fluid replacement:** Following any major operation fluid is replaced intravenously. The amount of fluid to be replaced is decided upon the following factors: intraoperative blood loss, operating time, urine output and the volume of fluid already replaced.

Blood transfusion, if needed is given during operation and soon after. **Blood transfusion should not be given unnecessarily.** Urine output of at least 30 mL/hour indicates adequate fluid replacement.



On an average, after replacement of the fluid loss at operation, additional 2–2.5 liters of fluid are infused. As there is sodium retention following major surgery, the replacement is by 5 percent dextrose in water along with 0.5 to 1 liter of Ringer's solution.

**Pain control:** Adequate pain control ensures deep breathing, adequate oxygenation, early mobilization, prompt wound healing, reduced pulmonary complication and less hospital stay. Liberal analgesics should be given to relieve pain and to ensure sleep. A sedative is prescribed at night. For this purpose, intramuscular injection of pethidine hydrochloride 100 mg or morphine sulfate 10 mg is administered at an interval of 6–8 hours. Nonsteroidal anti-inflammatory agents (Ketorolac) are also effective analgesics. In some centers, **patient controlled analgesia (PCA)** infusion pumps are used. Patient is instructed to use a preset dose (1 mg) of morphine without any overdosage. Nausea or vomiting may be prevented by simultaneous administration of metoclopramide 10 mg or ondansetron 4 mg IM/IV.

**Antibiotics:** Perioperative prophylactic antibiotics as mentioned in preoperative care are to be considered. Alternatively, routine postoperative antibiotics are prescribed. This should be administered parenterally for 48 hours followed by oral route for another 3 days.

**Bladder care:** Women having major gynecological surgery, usually a Foley's catheter is inserted before the operation. It keeps the bladder empty throughout and reduces the risk of any bladder injury. It helps to monitor urine output, reduces the risk of urinary retention and pain. Generally, it is removed on third postoperative day. Prolonged catheterization is associated with urinary tract infection. Catheter is kept for 7–10 days in patients having any injury to the bladder. Following removal of catheter, postoperative urinary retention is a common problem. This is due to pain, spasm of the pelvic floor muscles, tissues edema or following regional anesthesia. Residual urine is measured after micturition with ultrasound scan or by a catheter. Recatheterization should be done if the residual urine is >100 mL. Catheter may have to be kept for 24–48 hours.

**Mobilization:** The patient should be encouraged to move freely in bed and to lie in any posture comfortable to her. Deep breathing and movements of the legs and arms are encouraged to minimize

leg vein thrombosis and pulmonary embolism. It is advantageous to allow the patient to sit or to stand by the side of the bed by the evening. The patient can have sips of water to relieve the thirst.

### First postoperative day

**General care:** The patient is expected to look better and fresh. Vital signs are noted at least twice daily. Abdominal auscultation is done for appearance of peristaltic sounds. Enquiry is to be made about the passage of flatus. Vaginal plug (if any) is to be removed early in the morning. The patient is encouraged to stand or to walk few steps by the side of the bed and to sit on the bedside or on a chair. Deep breathing exercises and leg and arm movements while on bed are encouraged.

**Diet:** Oral feeding in the form of plain or electrolyte water is given in small but frequent intervals. With the appearance of bowel sounds or passage of flatus, full liquid diet is prescribed.

However, early postoperative feeding is safe. Early feeding (< 24 hours) does not cause any increase in paralytic ileus, vomiting or abdominal distension. Each case needs to be individualized.

**Sedative and analgesics:** Parenteral analgesics are gradually replaced with oral drugs (paracetamol, aspirin and NSAIDs) in combination.

### Second postoperative day

- The patient feels comfortable and looks fresh.
- She moves around in the room and goes to toilet.
- Light solid diet of patient's choice is given.
- Self-retaining catheter is removed.

### Third and fourth postoperative days

- Daily observation of vital signs twice daily is to be done as a routine.
- The diet is gradually brought to her normal.
- The bowels usually move normally, otherwise low enema or suppository may be given.

### Fifth and sixth postoperative days

The abdominal stitches are usually removed on the 5th day in transverse incision and on 6th day in vertical incision. **The stitches are to be removed in early morning with the patient in empty stomach.** The precaution is taken, so that emergency repair of the wound can be done, if burst abdomen occurs.

**Care of the perineum:** Following vaginal plastic operation, the perineal wound is dressed at least twice daily or following each act of micturition and defecation. The dressing is done with spirit and antibiotic powder or ointment. Local pain and edema may be relieved by hot compress with magnesium sulfate or infrared rays.

**DISCHARGE:** There is a trend towards shorter hospital stay these days. But complete recovery of all organ functions is needed before discharge. It may take 5–7 days when she is fit for discharge. **Written information** is given to the patient as regard the operative procedures.

While an uniform guideline is difficult to formulate, in an otherwise uneventful postoperative recovery, the patient may be discharged by 5–7 days following hysterectomy.

### Examination Prior to Discharge

#### Abdominal operation

- ◆ Abdominal wound is to be thoroughly checked for evidences of sepsis, hematoma or dehiscence.
- ◆ Vaginal discharge if any, is to be noted. If the discharge is offensive, gentle vaginal exploration by a finger should be done to exclude a foreign body (gauze piece).

#### Vaginal operation

- ◆ Perineal wound is checked to assess the state of healing.
- ◆ Vaginal exploration with a finger is useful to detect accidentally a retained and forgotten gauze piece.

### ADVICES GIVEN ON DISCHARGE

**Rest:** Light household work can be resumed after 3 weeks and outside or office works to be resumed after 4–6 weeks. While some resume their work earlier comfortably, others may find it difficult. However, minimally invasive surgery has got the advantage (p. 611).

**Coitus:** There is no fixed time bar. As soon as she is physically and psychologically fit, intercourse is permissible. However, it should not be resumed prior to the postoperative check up (i.e. 6 weeks) specially following vaginal plastic operation and hysterectomy.

Special instructions are mentioned in appropriate chapters.

**Follow-up** is usually after 6 weeks or earlier if some complications occur.

## GYNECOLOGICAL OPERATIONS

As mentioned in the introduction, **the technical details of the operation while concern to the specialists but the students should be acquainted with the principles involved.** Some considerations are however given in cases of minor operations. Such operations are common and some may have to do it following graduation during house officer job.

### DILATATION OF CERVIX

This is an operation to dilate the cervix. While in some cases, dilatation of the external os is enough but in majority, the entire canal including the internal os is to be dilated.

The dilatation is done by graduated cervical dilators (p. 631). When the internal os is to be dilated, prior introduction of uterine sound is mandatory to confirm the position of the uterus.

#### ■ INDICATIONS OF ONLY DILATATION ARE

- ◆ Prior to amputation of cervix (see p. 217, 218).
- ◆ Prior to hysteroscopy.
- ◆ Pyometra or hematometra (see p. 168).
- ◆ Prior to introduction of uterine curette and insertion of IUD, radium or laminaria tent.
- ◆ Spasmodic dysmenorrhea (see p. 180).

### DILATATION AND CURETTAGE

This is an operative procedure whereby dilatation of the cervical canal followed by uterine curettage is done. This is the most common gynecological operation done.

### INDICATIONS

#### INDICATIONS OF D AND C

<b>Diagnostic</b>	<ul style="list-style-type: none"> <li>• Infertility</li> <li>• DUB</li> <li>• Pathologic amenorrhoea</li> <li>• Endometrial tuberculosis</li> <li>• Endometrial carcinoma</li> <li>• Postmenopausal bleeding</li> <li>• Chorionepithelioma</li> </ul>
<b>Therapeutic</b>	<ul style="list-style-type: none"> <li>• DUB</li> <li>• Endometrial polyp</li> <li>• Removal of IUD</li> <li>• Incomplete abortion</li> </ul>
<b>Combined</b>	<ul style="list-style-type: none"> <li>• DUB</li> <li>• Endometrial polyp</li> </ul>

## STEPS OF OPERATION

- ▶ The patient is to empty the bladder prior to operation.
- ▶ The operation is done under general anesthesia or under diazepam sedation with or without paracervical block.
- ▶ She is placed in lithotomy position.
- ▶ Local antiseptic cleaning and draping done.
- ▶ Bimanual examination is performed.
- ▶ Posterior vaginal speculum is introduced.
- ▶ The anterior lip of the cervix is grasped with an Allis tissue forceps.
- ▶ An uterine sound is introduced to confirm the position and to note the length of the uterocervical canal.
- ▶ Cervical canal is dilated with graduated dilators.

Hawkin-Ambler dilator should be held in such a way that the knob is inside the palm and the index finger rests on the body of the instrument. The tip of the finger should be placed at a distance of about 3 cm (slightly more than the length of the cervical canal) from the tip of the instrument. The finger tip acts as a guard. The tip of the instrument should pass beyond the internal os evidenced by the fact that it is grasped by it and does not fall even when the support of the instrument is withdrawn. The tip of the dilator should be directed anteriorly or posteriorly according to the position of the uterus.

- ◆ When the dilator is introduced, the cervix is made steady by traction of the vulsellum.
- ◆ After the desired dilatation, the uterine cavity is curetted by an uterine curette either in clockwise or anticlockwise direction starting from the fundus down to internal os.

In benign lesion, sharp curette and in suspected malignancy, blunt curette is used.

The curette should be gentle but thorough. Vigorous curettage may damage the basal layer of the endometrium and uterine muscle.

- ◆ Vulsellum and the speculum are removed.
- ◆ The curetted material is **preserved in 10 percent formol-saline (normal saline in suspected tubercular endometritis), labeled properly and sent for histological examination.** Short history of the case and **first day of last menstrual period** specially in infertility cases and DUB should be positively mentioned.

**DISCHARGE:** After a short period of observation (say 3–4 hours) with passing off of the anesthetic effect, the patient may go home.

## COMPLICATIONS: ■ Immediate ■ Remote

**Immediate:** Although it is a minor operation, but complications do occur. Such complications are:

- ◆ Injury to the cervix
- ◆ Uterine perforation
- ◆ Injury to the gut
- ◆ Infection.

**Injury to the cervix:** The injury to the lip of cervix is caused by vulsellum bite or lateral tear by dilator. The bleeding from the vulsellum site is usually slight and stopped by gauze pressure or at best by a hemostatic suture.

**Management of lateral tear:** If slight, hemostasis is effective by intracervical or vaginal gauze plugging. The brisk hemorrhage is likely due to injury of the descending cervical artery and requires hemostatic sutures taking deep bite of the cervical tissue on the same side. If however, the tear extends upwards to involve the uterine artery, laparotomy has to be done along with resuscitative measures. Hemostasis is achieved by opening the anterior leaf of the broad ligament failing which ligation of the anterior division of the internal iliac artery may have to be done, if the uterus is to be preserved.

**Uterine perforation:** Uterus is perforated by uterine sound, or dilator or uterine curette. The perforation is more common in pregnant rather than non-pregnant uterus.

### Diagnosis is made by:

- ◆ Sudden loss of resistance.
- ◆ Passage of the instrument more than the length of the uterine cavity.
- ◆ Undue mobility of the instrument.
- ◆ Vaginal bleeding.

**Management:** Attempt to confirm the perforation by reintroducing the instrument is to be condemned. Once perforation is suspected, following guidelines are to be followed:

- To stop the operative procedure.
- To watch the pulse and blood pressure and vaginal bleeding.
- To formulate the definitive treatment.

**Non-infective/Non-malignant uterus**

- Small perforation by sound or small dilator
  - To watch the vital signs.
  - To administer antibiotics.
  - To discharge the patient after 24–48 hours, if abdomen is soft, vital signs (pulse, BP) are stable and no untoward effects are noticed.
- Perforation by large dilator or curette.

Usually the perforation is large and associated with varying degrees of internal hemorrhage. The gut may also be injured. As such laparotomy is justified. Repair of the rent or hysterectomy as the case may be is to be done. Associated gut injury is to be looked for and if found, to be tackled accordingly — repair or resection.

If laparoscopy facilities are available, it can be employed in all cases at the earliest. This will help to complete the operative process under its guidance if the perforation is small, to minimize the period of observation and to guide the urgency of laparotomy.

**Infective/Malignant uterus:** In suspected malignancy or in pyometra, prompt laparotomy is justified. This is to be followed by definitive surgery. However, if perforation occurs in potentially infected uterus of young woman, conservative treatment with antibiotics is justified and to watch for evidences of peritonitis.

**Remote complications:**

- ◆ Cervical incompetence due to injury to internal os. This may cause recurrent midtrimester abortion.
- ◆ Uterine synechiae due to injury to uterine muscle. This may cause secondary amenorrhea (see p. 459).

## DILATATION AND INSUFFLATION (D AND I)

This is an operation of dilatation of the cervix and introduction of air or CO<sub>2</sub> into the uterine cavity to know the patency of the fallopian tubes. It is also known as **Rubin test**.

**INDICATIONS:** To note the tubal patency in:

- Investigation for infertility.
- Following tuboplasty operation.

**It should be done** in the first half of the cycle (between 8–12th day) and **should not be done** in the presence of pelvic infection (see p. 131).

**STEPS**

- The steps up to cervical dilatation are similar to D and C operation.
- After the desired dilatation of the cervix, the insufflation cannula fitted with a ‘Y’ rubber tube is introduced into the cervical canal (Chapter 35).
- Although CO<sub>2</sub> is better but air is usually introduced. The pressure in the manometer is raised gradually by an assistant by pressing the rubber bulb. The rise of pressure in the manometer is watched by the operator. The assistant auscultates over the flanks for any hissing sound.

**A positive test is evidenced by:**

- A hissing sound is audible on the flank due to exit of air through the abdominal ostium.
- Drop in the manometer reading from 80–120 mm Hg.
- Patient complains of shoulder pain on sitting (due to irritation of the diaphragm by air and the pain sensation is carried by phrenic nerve).

**If the test is negative:**

- Air pressure can be raised gradually to a maximum 180 mm Hg without a fall.
- There is no hissing sound audible on the flanks.

If the test is negative, it may be repeated in the same sitting (thrice).

**False-positive** may be due to instrumental leakage or uterine perforation.

**False-negative** is due to uterotubal spasm which may be overcome with general anesthesia.

- After the test is completed, the cannula, vulsellum and the speculum are taken off.

**COMPLICATIONS: ■ Immediate ■ Remote**

**Immediate:** The complications due to the use of uterine sound and cervical dilators are those of D and C operation. **Special complications related to the operation include:**

- ◆ **Air embolism**—About 7–10 mL of air is enough to produce embolism. Chance of air embolism is abolished with the use of CO<sub>2</sub>.
- ◆ **Rupture of the tube**—If the tube is blocked and the pressure is raised beyond 200 mm Hg.
- ◆ **Flaring up of the pre-existing pelvic infection.**

**Remote:** ◆ Pelvic endometriosis.

## HYSTEOSALPINGOGRAPHY (HSG)

HSG is an operative procedure used to assess the **interior anatomy of the uterus and tube including tubal patency**. It is a radiographic study and a contrast media is used.

### INDICATIONS

- ◆ Assessment of tubal patency in the investigation of infertility or following tuboplasty operation (p. 238).
- ◆ Detection of uterine malformations (unicornuate, bicornuate, septate uterus (p. 45).
- ◆ Diagnosis of cervical incompetence (p. 45).
- ◆ Detection of translocated IUD whether lying inside or outside the uterine cavity (p. 482).
- ◆ Diagnosis of uterine synechiae (p. 459).
- ◆ Incidental diagnosis of submucous fibroid or an uterine polyp or hydrosalpinx or nodular tube is an additional gain.
- ◆ To confirm the diagnosis of secondary abdominal pregnancy.

### STEPS

**The operation is done in the radiology department and without anesthesia.**

- Patient is to empty her bladder.
- She is placed in dorsal position with the buttocks on the edge.
- Internal examination is done.
- Posterior vaginal speculum is introduced; the anterior lip of the cervix is held by Allis forceps and an uterine sound is passed.
- Hysterosalpingographic cannula is fitted with a syringe containing radio-opaque dye—either water soluble contrast medium, meglumine diatrizoate (Renografin-60) or a low viscosity oil-based dye, ethiodized oil (Ethiodol). The dye is introduced slowly. About 5–10 mL of the solution is introduced. The passage of the dye into the interior may be observed by using a X-ray image intensifier and a video display unit.

- The speculum and the Allis forceps are removed but not the cannula.
- Two radiographic views are generally taken. The first one to show the filling of uterine cavity and the other at the completion of the procedure (after 10–15 minutes) showing tubal findings. The tubal patency is evidenced by peritoneal spillage (see Fig. 16.2).

### Advantages of watery medium over oil-based solution

- Permits rapid absorption.
- Eliminates granuloma formation.
- Negligible peritoneal irritation.
- No risk of embolism when extravasated.
- Better visualization of tubal mucosa.

### Advantages of oil-based medium over the watery contrast medium

- Better resolution of tubal architecture.
- Less uterine cramping pain.
- Higher subsequent pregnancy rate (better flushing of tubes).

### Advantages of HSG over D and I

- ◆ Lesser false-negative report (Cornual spasm can be overcome by prior IM injection of atropine sulfate 0.6 mg).
- ◆ Precise identification of the side and site of obstruction.
- ◆ Identification of uterine cavity abnormality.
- ◆ Flimsy intraluminal adhesions may be broken, as such chance of conception within 3–4 months is more.

**Timings:** HSG is done between D6 and D10 of the cycle. Antibiotic prophylaxis should be given. Doxycycline 100 mg PO twice daily is given, beginning the day before HSG and continuing for 5 days.

### COMPLICATIONS

Apart from the inherent complications of the uterine sound (uterine perforation) hemorrhage, HSG has got the following complications even with the use of watery solution.

- ◆ Peritoneal irritation and pelvic pain.
- ◆ Vasovagal attack.
- ◆ Intravasation of dye within the venous or lymphatic channels (common in tubercular endometritis) (see Fig. 10.6)
- ◆ Flaring up of pelvic infection (1–3%).

**Contraindications to HSG:** (i) Pelvic infection, (ii) Women known to have hydrosalpinges (Fig. 37.77), (iii) Presence of adnexal mass (PID), (iv) Pelvic tenderness on bimanual examination.

## CERVICAL BIOPSY

This is the common diagnostic procedure carried out both in the hospital and in the office.

### TYPES

- Surface (Ch. 9) • Punch • Wedge
- Ring • Cone

**Punch biopsy:** Punch biopsy is done in the outpatient or as an office procedure, without anesthesia.

Using Cosco's bivalve speculum, biopsy is taken from the suspected area or a four quadrant using punch biopsy forceps. Alternatively, the biopsy may be taken from the unstained area (white) when the cervix is painted with Schiller's iodine or colposcopic directed. Hemostasis is usually achieved by pressure with a gauze piece.

**Wedge biopsy:** This is done when a definite growth is visible. Necrotic area is to be avoided. **An area nearer the edge is the ideal site.**

- Posterior vaginal speculum is introduced.
- Anterior or posterior lip of the cervix is to be held by Allis forceps.
- With a scalpel, a wedge of tissue is cut from the edge of the lesion **including adjacent healthy tissue for comparative histologic study.**
- Hemostasis may be achieved by gauze packing or by sutures.

**Ring biopsy:** Whole of the squamocolumnar area of the cervix is excised with a special knife. The tissue is subjected to serial section to detect CIN or early invasive carcinoma. This is almost replaced by directed biopsy either Schiller or colposcopy.

**Cone biopsy (conization):** The operation involves removal of cone of the cervix which includes entire squamocolumnar junction, stroma with glands and endocervical mucous membrane.

**INDICATIONS:** Conization is done as **diagnostic and therapeutic purpose in CIN**. With the advent of colposcopy and identification of the extent of the lesion, a diagnostic conization can be effective for the therapeutic purpose as well. **Cases of CIN suitable for conization are** (see p. 326 — Table 22.3):

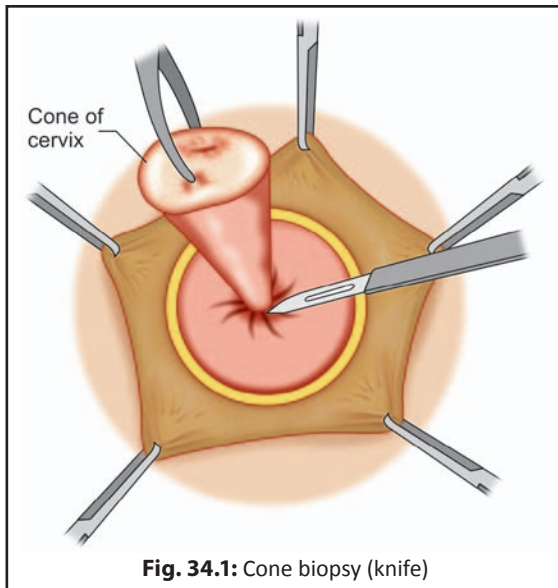
- ◆ Unsatisfactory colposcopic findings. The entire margins of the lesion are not visualized.
- ◆ Inconsistent findings—Colposcopic, cytology and directed biopsy.
- ◆ Positive endocervical curettage.
- ◆ When biopsy cannot rule out invasive cancer from CIS or microinvasion.

**PROCEDURES (FIG. 34.1):** The procedure is usually done with conventional knife (cold knife cone). Currently, it is being done with the help of CO<sub>2</sub> laser used as scalpel under colposcopic guidance with advantages.

**TABLE 34.1**

### ADVANTAGES OF LASER OVER COLD KNIFE CONIZATION

- ▶ Done in the outpatient under local anesthesia
- ▶ Less tissue damage and less blood loss.
- ▶ Postoperative pain and discharge (morbidity)—less
- ▶ Regeneration of epithelium occurs earlier (3–4 weeks).
- ▶ All types of CIN can be treated.
- ▶ Fertility and pregnancy outcome are not affected adversely.



**Fig. 34.1:** Cone biopsy (knife)

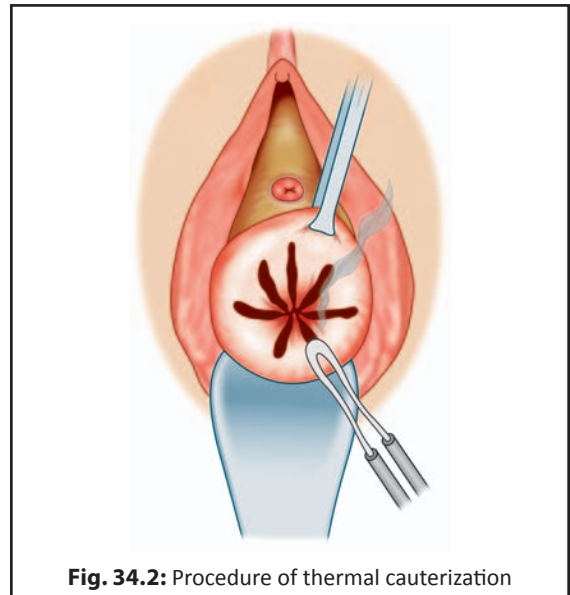
### **Principal steps (Cold Knife)**

- ◆ The operation is done under general anesthesia.
- ◆ Blood loss is minimized with prior hemostatic sutures at 3 and 9 O'Clock positions on the cervix by ligating the descending cervical branches.
- ◆ The cone is cut so as to keep the apex below the internal os (Fig. 34.1).
- ◆ After the cone is removed, a margin suture is placed at 12 O'Clock position for identification of the cone.
- ◆ Routine endocervical curette above the apex of the cone is performed and uterine curettage is done, if indicated (Table 34.1).
- ◆ Cone margins are repaired by hemostatic sutures. Sturmdorf hemostatic suture should not be used as it interferes with future colposcopic examination.

The excised cervical tissue is sent for histological examination (serial section—minimum 6). **If the margins of the cone are involved in neoplasia**, hysterectomy should be seriously considered either within 48 hours or at a later date (6 weeks) to avoid infection.

### **Complications**

- ◆ Secondary hemorrhage.
- ◆ Cervical stenosis leading to hematometra.
- ◆ Infertility.
- ◆ Diminished cervical mucus.
- ◆ Cervical incompetence leading to recurrent miscarriage.
- ◆ Midtrimester abortion or preterm labor.



**Fig. 34.2:** Procedure of thermal cauterization

## **THERMAL CAUTERIZATION**

This is an operation whereby the eroded area of the cervix is destroyed either by thermocoagulation or red hot cauterization.

**INDICATION:** Cervical ectopy with troublesome discharge. Prior cervical smear or biopsy if necessary, should be undertaken.

**PROCEDURES (Fig. 34.2):** While the superficial cauterization can be done without anesthesia as an outdoor procedure but where extensive cauterization is required, it should be done under general anesthesia.

- ◆ Lower part of the cervical canal is dilated by one or two small dilators.
- ◆ The whole eroded area is cauterized by cautery point (see Fig. 37.42) giving **linear radial strokes starting from inside the cervical canal to over the eroded area. The strokes should be made about 2 mm deep and at a distance of 1 cm.**
- ◆ The area is smeared with antibiotic ointment.

**Healing:** It takes about 2–3 weeks for sloughing of the burn area. Complete epithelialization by squamous epithelium occurs by 6–8 weeks.

**Patient information:** There may be serosanguineous or even blood stained discharge for about 2–3 weeks.

Local (cream) and systemic antibiotic need to be given, when infection is there.



## CRYOSURGERY

This is a procedure whereby destruction of the tissue is effective by freezing.

### INDICATIONS

- ◆ Cervical ectopy (p. 267).
- ◆ Benign cervical lesions—such as CIN, condyloma accuminata, leukoplakia, etc.
- ◆ Condyloma accuminata of vulva and VIN diagnosed colposcopically and not more than 2 cm in size.
- ◆ VAIN, condyloma accuminata or vault granulation tissue following hysterectomy.
- ◆ As a palliative measure to arrest bleeding in carcinoma cervix or large fungating recurrent vulval carcinoma.

**PRINCIPLE:** It consists of a ‘probe’, the tip of which is cooled to a temperature below freezing point ( $-60^{\circ}\text{C}$ ). **Freezing produces cellular dehydration by crystallization of intracellular water and ultimately death of cells.** This is effective by rapid expansion of gas which is passed through it. Carbon dioxide is widely used while nitrous oxide and liquid nitrogen are also used.

**PROCEDURES:** This is an outpatient procedure and is done without anesthesia. Commonly used technique is freeze-thaw-freeze.

A probe that adequately covers the lesion is selected. The probe tip is lightly covered with water-soluble jelly to provide good thermal contact with the cervix.

The appropriate cryosurgery probe is applied to the cervix and the freezing activated. When a good iceball extending 4–5 mm beyond the edge of the probe is obtained, the freezing is stopped; the probe thawed (to raise the temperature above freezing point) and removed. The probe which adhered to the tissue should not be pulled out until the temperature rises again. Usually 90 to 180 seconds are required to obtain a satisfactory freeze. If necessary, a second time freezing technique may be employed to get a good result.

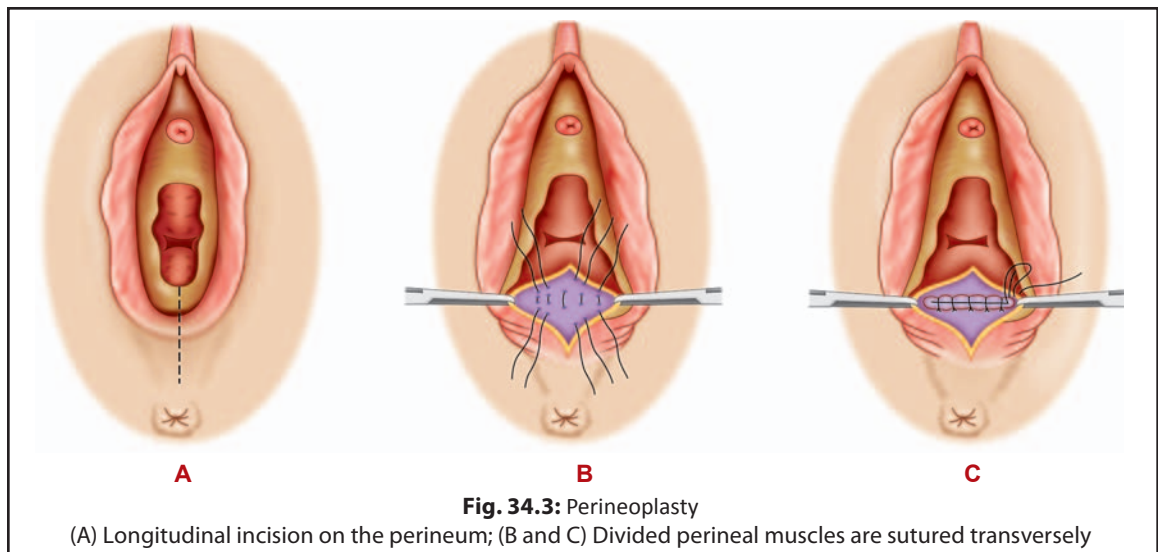
The application to the cervix freezes the tissue to a depth of about 3 mm.

### ADVANTAGES OVER THERMAL CAUTERY

- ◆ Anesthesia is not required.
- ◆ Precise destruction of tissue.
- ◆ There is no secondary hemorrhage.
- ◆ Cervical stenosis is rare.

**DRAWBACKS:** There is excessive discharge for about 2–3 weeks.

**Healing** is complete in 6 to 10 weeks.



## PERINEOPLASTY

Perineoplasty is the reconstruction of the narrow vaginal introitus to make it adequate for sexual function (Fig. 34.3).

### Indications are:

- a. Congenitally small introitus.
- b. Rigid perineal body.
- c. Rigid hymenal ring.
- d. Narrowed introitus following overzealous perineorrhaphy or episiotomy repair.

### Principal steps:

- A longitudinal incision is made in the mid-line from above (2 cm) the fourchette to the skin of the perineum below (2 cm) (See Fig. 34.3A).
- The incision is deepened through the vaginal mucosa, skin and the perineal body.
- Mobilization of the vaginal mucosa and perineal skin is done.
- Two gloves are worn on the left hand. Left index finger is passed into the rectum and it is hooked upwards and outwards, while the superficial perineal muscles are divided.
- Finally, the wound is sutured in layers transversely by using interrupted sutures (Fig. 34.3B and C).

[In **Fenton's method** a transverse incision is made along the fourchette].

**Repair of complete perineal tear** (see p. 433).

## AMPUTATION OF CERVIX

Amputation is an operative procedure whereby a part of the lower cervix is excised.

### INDICATIONS

- Congenital elongation.
- Chronic cervicitis with hypertrophied cervix not relieved by conventional therapy.
- As a component part of Fothergill's operation to rectify the supravaginal elongation.

### GUIDELINES

The following practical guidelines are formulated:

- Except in congenital elongation, prior exclusion of malignancy should be done (Pap Smear p. 110).
- High amputation is to be avoided in cases where future childbirth prospect is retained. High amputation may produce cervical incompetency.

### AMPUTATION OF CERVIX

**Principal steps:** Initial steps are same as that of cold knife cone biopsy (see p. 590).

- A circumferential incision is made around the cervix and vaginal mucosa is separated from the stroma of the cervix.
- A cone-shaped amputation is done and the cut margins are repaired with hemostatic mattress sutures.
- Raw surfaces of the cervix are covered by the Bonney-Sturmdorf suture using a cutting needle (see Fig. 15.18).

### COMPLICATIONS

#### Immediate complications include:

- Hemorrhage—both primary and secondary.
- Sepsis.

#### Remote complications include:

- Cervical stenosis leading to hematometra.
- Cervical incompetency leading to midtrimester abortion.
- Secondary cervical dystocia during labor.

## MAJOR SURGICAL OPERATIONS

Major surgical operations—vaginal or abdominal are in the domain of specialists conversant with gynecologic surgery. It is indeed difficult to make the students understand the techniques of the operations with language. As such, utmost attempt has been made to make them familiar with the **principal steps** of some such common operations with diagrams.

## ABDOMINAL HYSTERECTOMY

Hysterectomy is the operation of removal of uterus. When the uterus is removed abdominally, it is called **abdominal hysterectomy**.

**Types:** Depending upon the extent of removal of the uterus and adjacent structures, the following types are described:

- ▶ **Total hysterectomy**—Removal of the entire uterus.
- ▶ **Subtotal**—Removal of the body or corpus leaving behind the cervix.
- ▶ **Panhysterectomy**—Removal of the uterus along with removal of tubes and ovaries of both sides. **The term ‘hysterectomy with bilateral salpingo-oophorectomy’ is preferred.**
- ▶ **Extended hysterectomy**—Panhysterectomy with removal of cuff of vagina.
- ▶ **Radical hysterectomy**—Removal of the uterus, tubes and ovaries of both the sides, upper one-third of vagina, adjacent parametrium and the draining lymph nodes of the cervix (see p. 353, Table 23.11).

**Indications:** The indications are grouped as shown in the Tables 34.2 and 34.3.

TABLE 34.2	INDICATIONS OF ABDOMINAL HYSTERECTOMY
Benign lesions	<ul style="list-style-type: none"> <li>• Dysfunctional uterine bleeding</li> <li>• Fibroid uterus</li> <li>• Tubo-ovarian mass</li> <li>• Endometriosis</li> <li>• Adenomyosis</li> <li>• CIN</li> <li>• Endometrial hyperplasia</li> <li>• Benign ovarian tumor in perimenopausal age</li> </ul>
Malignancy	<ul style="list-style-type: none"> <li>• Carcinoma cervix</li> <li>• Carcinoma ovary</li> <li>• Carcinoma endometrium</li> <li>• Uterine sarcoma</li> <li>• Choriocarcinoma</li> </ul>
Traumatic	<ul style="list-style-type: none"> <li>• Uterine perforation</li> <li>• Cervical tear</li> <li>• Rupture uterus</li> </ul>
Obstetrical	<ul style="list-style-type: none"> <li>• Atonic PPH</li> <li>• Morbid adherent placenta</li> <li>• Hydatidiform mole &gt; 35 years</li> <li>• Septic abortion</li> </ul>

### Some Considerations of Hysterectomy (Benign Lesions)

**Age and parity:** An ideal condition is that the patient preferably be in the perimenopausal age group with family completed. However, the operation may have to be done under forced circumstances even in comparatively young age group or unmarried or nulliparous women (Example—Contemplating myomectomy).

**Total or subtotal:** The preferred surgery is always a total hysterectomy unless there is sufficient reason to leave behind the cervix. **The indications of subtotal (supracervical) hysterectomy are:**

- ◆ Difficult tubo-ovarian mass with obliteration of the anterior and posterior pouches.
- ◆ Pelvic endometriosis particularly involving the rectovaginal septum.
- ◆ Emergency hysterectomy (cesarean hysterectomy).

### Advantages of Subtotal (Supracervical) Hysterectomy

Controversy exists as regard the usefulness of subtotal hysterectomy. **The benefits mentioned are:** reduced operative and postoperative morbidity, reduced vaginal shortening and vault prolapse and increased sexual satisfaction. Hospital stay is shorter. Papanicolaou cervical smear must be normal before contemplating supracervical hysterectomy. It should be maintained as a routine follow up (see Table 9.1).

### The risks of the cervical stump left behind are:

- ✦ Cervicitis with abnormal vaginal discharge.
- ✦ Stump carcinoma may develop (1%).

**Preservation of ovaries:** Amidst controversy, it seems rational to preserve the ovaries in premenopausal women if they are found healthy. Some however, remove the ovaries beyond 45 years and preserve the same before that age, if found healthy.

### Special considerations for removal of ovaries

- If the ovaries are diseased in inflammatory process or involved in neoplastic conditions with the patient around the age of 40 or older.
- Hysterectomy done in a woman of any age who has a history of ovarian or breast cancer in first degree relative.
- Postmenopausal women as a routine.

BENEFITS AND RISKS OF OVARIAN CONSERVATION DURING HYSTERECTOMY	
Benefits	Risks
1. Ovarian function continues till the expected time of spontaneous menopause	1. Risks of developing ovarian neoplasms (Benign or malignant). Relative risk (RR) of ovarian cancer is 0.6 even 10 years after hysterectomy
2. Menopausal symptoms appear late and the severity is less	2. Residual ovarian syndrome occurs in 1–3 percent of cases due to multiple cystic follicles and/or periovarian adhesions (p. 578)
3. Decreased incidence of vasomotor symptoms, osteoporosis and atherosclerotic changes (see p. 61)	3. Chronic pelvic pain and dyspareunia.
	4. Risk of relaparotomy in 3–5 percent

Hormone replacement therapy is to be considered when ovaries are removed (see p. 61).

### Removal of fallopian tubes

The uterine tubes are removed:

- When the ovaries are removed (salpingo-oophorectomy).
- When the tubes are diseased but ovaries are conserved (salpingectomy) due to young age.

### STEPS OF OPERATION (BENIGN LESION)

#### Preoperative workup (see p. 581)

#### Actual steps (Fig. 34.4)

- Abdomen is opened either by a low transverse or infraumbilical paramedian or midline incision.
- The uterus is drawn out of the wound.
- Doyen's retractor is placed in position.
- The patient is placed in Trendelenburg position.
- The guts and omentum are packed off from the operative area.
- The pelvic organs are examined. The decision of preserving or removing the adnexae is made.
- The traction of the uterus is given by either using vulsellum or placing long artery forceps on either side of the uterine cornu (myoma screw is used in fibroid). The uterus is pulled to one side while clamps are placed on the contralateral side.
- **If the ovaries are to be removed**, paired clamps (two long straight artery forceps) are placed in the infundibulopelvic ligament [Fig. 34.4(1)].

The tissues in between are cut and replaced by transfixation sutures (Vicryl No. '0' or chromic catgut

No. '1'). **If the ovaries are to be preserved**, the paired clamps are placed near the cornu of the uterus to include Fallopian tube, mesosalpinx containing uterine vessels and ovarian ligament. The structures are cut in between the clamps and replaced by transfixation sutures (Vicryl No. '0' or chromic catgut No. '1'). [Fig. 34.4(2)]

- Paired clamps are placed on the round ligament, cut and replaced by sutures (Vicryl No. '0' or chromic catgut No. '1'). [Fig. 34.4(3)]
- Similar procedures up to this stage are followed on the other side.
- Loose peritoneum of the uterovesical fold [Figs 34.4 (4, 5, 13)] is cut and extended from one divided round ligament to the other. The bladder is pushed down and out with gauze added with scissors stripping till the anterior vaginal wall is reached. **This will minimize injury to the bladder and ureters in subsequent steps of operation** [Figs 34.4(4, 5)].
- Paired clamps are placed on the parametrium containing ascending branch of the uterine artery, close to the uterus at the level of internal os. The tissues in between are cut with the scalpel and replaced by ligature (Vicryl No. '0' or catgut No. '1'). Similar step is followed on the other side [Fig. 34.4(6)].
- The uterus is now pulled forwards to make the uterosacral ligaments prominent. Clamps are placed over the uterosacral ligaments as close to the cervix. The ligaments are cut. The peritoneum in between the ligaments is dissected down with scissors and finger. The clamps are replaced by sutures (same suture material) [Fig. 34.4(7)].
- Clamps are placed close to the cervix on the paracervical tissue (Mackenrodt's) containing

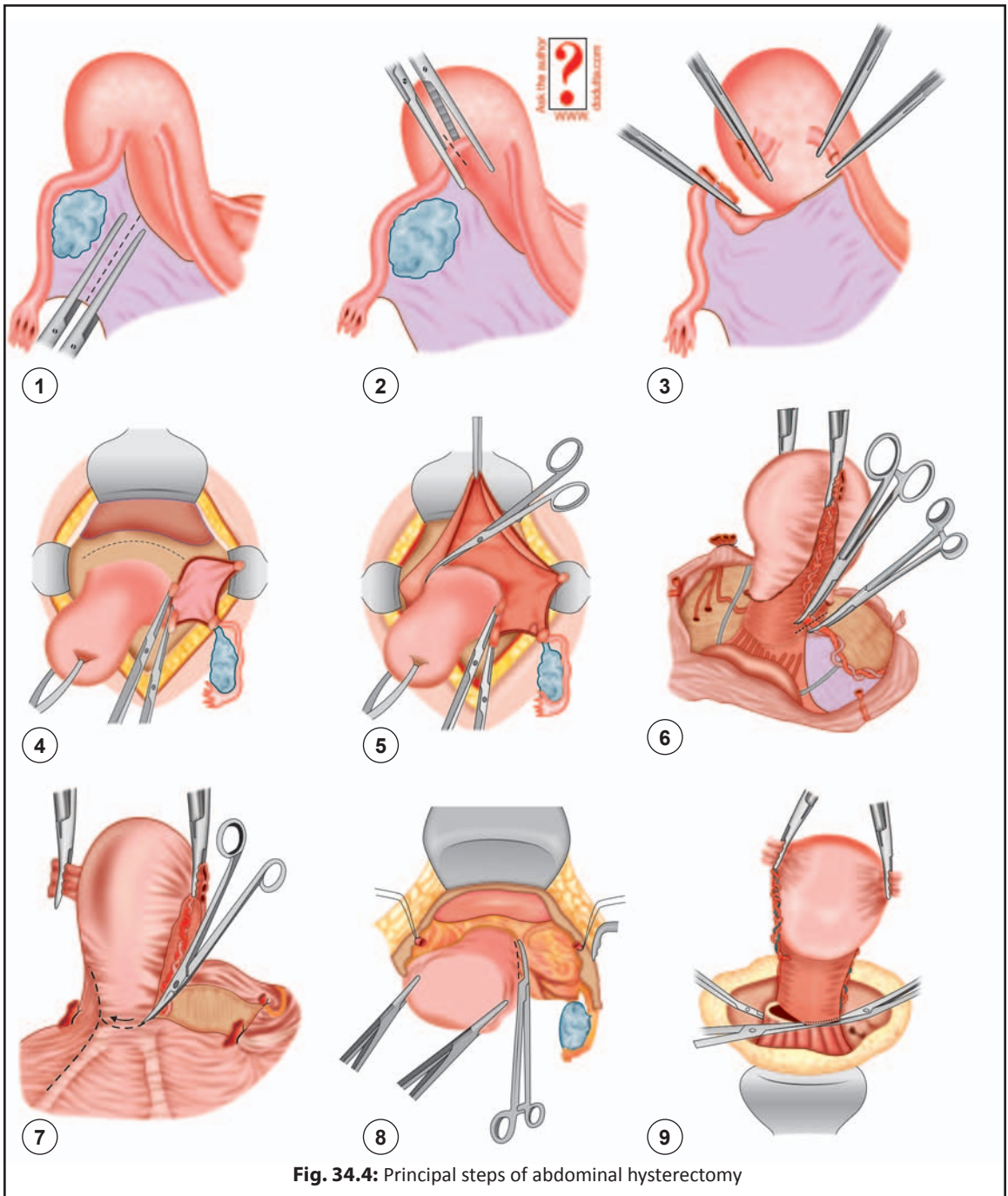


Fig. 34.4 (Contd...) next page

Fig. 34.4 (contd...) from previous page

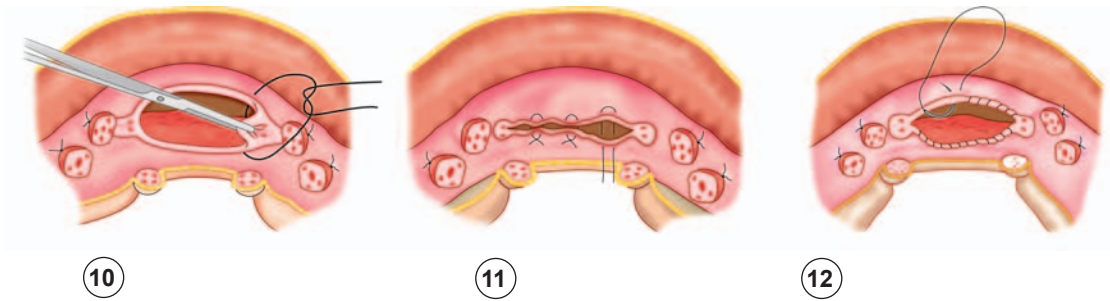
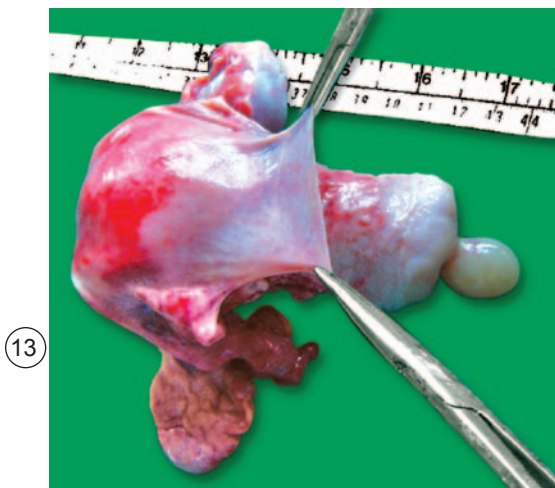


Fig. 34.4: Principal steps of abdominal hysterectomy



Uterovesical fold of peritoneum dissected out during hysterectomy

descending cervical artery, cut and replaced by ligature (same suture material). Similar step is followed to the other side [Fig. 34.4(8)].

- Vault of the vagina is opened by a stab incision with a scalpel at the cervicovaginal junction. The remaining vault of the vagina is cut while traction is given with a single toothed vulsellum on the cervix [Fig. 34.4(9)].
- The edges of the cut vaginal vault are grasped by Allis forceps [Fig. 34.4(10)].
- Lateral vaginal angles are closed by transfixation suture (Fig. 34.4(10)).
- Vault is closed by interrupted sutures [Fig. 34.4(11)] or the free vaginal margin is reefed with a continuous locking suture (Fig. 34.4(12)).

- Pelvic peritonization may be done (optional) by running sutures using catgut No. '0'.
- Abdominal packs are removed; peritoneal toileting is done.
- Abdomen is closed in layers.

TABLE 34.3

## COMMON INDICATIONS OF ABDOMINAL HYSTERECTOMY

<b>Total</b>	<ul style="list-style-type: none"> <li>• DUB</li> <li>• TO mass</li> <li>• Uterine fibroid</li> <li>• Endometriosis</li> </ul>
<b>Subtotal</b>	<ul style="list-style-type: none"> <li>• Difficult TO mass</li> <li>• Endometriosis (rectovaginal septum)</li> <li>• Obstetric causes</li> </ul>
<b>Pan hysterectomy</b>	<ul style="list-style-type: none"> <li>• Indications for total hysterectomy in perimenopausal age</li> </ul>
<b>Extended Radical</b>	<ul style="list-style-type: none"> <li>• Carcinoma endometrium</li> <li>• Carcinoma cervix-stage I and II</li> </ul>

## COMPLICATIONS OF HYSTERECTOMY

- **Intraoperative** (during operation)
- **Postoperative:** ♦ Immediate ♦ Late ♦ Remote
- **Intraoperative**
  - ♦ Hemorrhage
  - ♦ Visceral injury: Intestine, bladder or ureter
  - ♦ Anesthetic hazard: Atelectasis, pulmonary edema, embolism.
- **Postoperative:**
  - **Immediate:**
    - ♦ Hypovolemia (hemorrhagic) → shock.

◆ *Urinary:*

- Retention due to pain and spasm
- Cystitis
- Anuria may be due to inadequate fluid replacement (prerenal) or ureteric obstruction (postrenal) see p. 425.

I **Late**

◆ **Incontinence**

- **Overflow** due to prolonged over-distension of the bladder.
- **Stress** due to prolonged catheterization.
- **True**—If occurs immediately after operation, it is caused by injury to the bladder or ureter (p. 418). If occurs 7–14 days after operation, it is due to sloughing and necrosis either of the bladder or uretes (VVF or UVF p. 425).

◆ **Pyrexia**—fever may be due to:

- Cystitis (due to catheterization)
- Abdominal wound infection
- Vault cellulitis, hematoma
- Thrombophlebitis
- Pulmonary infection, atelectasis, pneumonia
- Peritonitis.

◆ **Hemorrhage**

- **Primary:** It is due to slipping of the ligature usually that of the vaginal angle. Hemostasis can be achieved by the vaginal route under general anesthesia. Care is to be taken to prevent bite of the ureter in the suture. If the procedure fails, laparotomy has to be done for hemostasis.
- **Secondary:** This type of hemorrhage occurs between 7–14 days after operation and is due to sepsis. Bleeding source may be from the vault or internally (rare) from the sloughing uterine or ovarian artery.

**If from the vault,** hemostasis can be achieved by interrupted or mattress suture using ‘Vicryl’ under general anesthesia. In cases of recurrences, one may have to tackle the situation through abdominal route as mentioned below.

**In cases of internal hemorrhage** which is fortunately rare, laparotomy has to be done along with resuscitative procedures. If the uterine artery is involved, anterior division of the internal iliac artery has to be tied to secure hemostasis.

*Hematomas*—In the pelvis or rectus sheath may cause low grade temperature. Large hematomas should be drained.

*Wound dehiscence* is seen commonly with vertical incision. Patients with infection, immune suppression and malignancy are at high risk.

Ileus	Obstruction
<b>Distension</b> — Present	Present
<b>Pain</b> —Mild due to distension	Progressively severe due to cramps
<b>Bowel sounds</b> — Absent	Peristaltic rushes
<b>Vomiting</b> — Present	Present
<b>Onset</b> — Within 48–72 hours of surgery	Delayed 5–7 days postoperative
<b>X-ray</b> — Loops of small and large bowel distended with gas	Distended bowel loops with air-fluid level
<b>Treatment</b> — Conservative: nasogastric suction, intravenous fluids, enemas, correction of electrolyte imbalance and control of infection	Initial conservative; may need surgical intervention

Class	Description
<b>Type I</b>	Simple hysterectomy
<b>Type II</b>	Modified radical hysterectomy. Paracervical tissues and upper vagina (1–2 cm) are removed after dissection of ureters at the point of entry to bladder. Uterine arteries are ligated at the site of crossing the ureters. The medial half of parametria and proximal uterosacral ligaments are resected
<b>Type III</b>	Radical hysterectomy, en-block removal of uterus with upper 1/3 of vagina with paravaginal and paracervical tissues. The uterine vessels are ligated at their origin. Removal of entire width of parametria and as much of uterosacral ligaments are done
<b>Type IV</b>	Extended radical hysterectomy with removal of upper 3/4th of vagina and paravaginal tissues are done
<b>Type V</b>	Partial exenteration (see p. 349)

**Type II–V** are completed with bilateral pelvic lymph adenectomy

*Paralytic ileus and intestinal obstruction*—Postoperative bowel dysfunction may be due to ileus or obstruction (Table 34.4).

*Necrotizing fasciitis* is a rare but life-threatening complication. Infection is in the superficial and subcutaneous tissues. There is extensive tissue necrosis. Supportive therapy, wide tissue excision and antibiotics are the management.

*Phlebitis*—Intravenous cannula related phlebitis causes pain, redness and fever. Venous cannula should be removed and antibiotic should be continued.

*Deep vein thrombosis (DVT)*—is not an uncommon problem. Calf veins are commonly affected. It is associated with low grade fever, pain and swelling of the affected cuff. B-mode ultrasound can detect an intramural clot.

Heparin is administered intravenously (30,000–40,000 units/24 hours) once the diagnosis is confirmed. Activated partial thromboplastin time (APTT) is maintained at 1.5–2.5 times the control. Heparin is replaced by warfarin orally after 5 days and it is continued for 4–6 weeks. Low molecular weight heparin (Fragmin) 2500U SC every 24 hours or low dose heparin 5000U SC every 12 hours, starting 1–2 hours before surgery, for 5–7 days is recommended as a preventive measure against venous thromboembolism.

*Pulmonary embolism* is a rare but fatal complication. Patient commonly presents with sudden onset of chest pain, dyspnea, tachycardia, tachypnea and hemoptysis. Arterial blood gas analysis, D-dimer level (negative) ventilation/perfusion scan and contrast pulmonary angiography, spiral CT are the diagnostic aids. Ventilation-perfusion scan reveals areas with decreased perfusion but adequate ventilation. Heparin is

**TABLE 34.6** ABDOMINAL HYSTERECTOMY

Advantages	Disadvantages
<ol style="list-style-type: none"> <li>1. Scope of wide exploration of the abdominal and pelvic organs (ovaries, appendix, gallbladder, etc.)</li> <li>2. Tubo-ovarian pathology can be tackled effectively and simultaneously</li> <li>3. Concurrent surgical procedures (appendicectomy) may be performed when needed</li> <li>4. Operation can be done by a relatively less experienced surgeon</li> </ol>	<ol style="list-style-type: none"> <li>1. Difficult to perform in too obese patients</li> <li>2. Postoperative complications are slightly high. There is increased incidence of peritonitis, fever, pulmonary and vascular complications</li> <li>3. More postoperative pain and more need of analgesia</li> <li>4. More hospital stay</li> <li>5. Delayed resumption in day-to-day activities</li> <li>6. Morbidity and mortality are more compared to a vaginal hysterectomy</li> <li>7. Presence of abdominal scar</li> </ol>

**TABLE 34.7** VAGINAL HYSTERECTOMY (See Ch. 15 P. 221)

Advantages	Disadvantages
<ol style="list-style-type: none"> <li>1. Can be effectively done in obese patients</li> <li>2. Postoperative complications are less</li> <li>3. Less morbidity and mortality</li> <li>4. Less postoperative pain and less need of analgesia</li> <li>5. Less hospital stay</li> <li>6. Early resumption of day-to-day activities</li> <li>7. No abdominal incision and scar</li> </ol>	<ol style="list-style-type: none"> <li>1. More skill and experience are needed on the part of the surgeon</li> <li>2. Exploration of abdominal and pelvic organs cannot be done</li> <li>3. Difficult in cases with restricted uterine mobility, limited vaginal space and associated adnexal pathology</li> <li>4. Limitation in cases with : uterus &gt;12 weeks of size, presence of pelvic adhesions or, previous history of laparotomy with adhesions</li> </ol>



the drug of choice. Thrombolytic therapy (recombinant human plasminogen activator) clear the emboli more rapidly when infused IV. Pulmonary artery embolectomy or inferior vena cava filter placement may have to be considered for massive pulmonary embolus. Warfarin should be started orally after 2–3 days of heparinization. Heparin is withdrawn once the therapeutic level of warfarin is obtained. Dose of warfarin is aimed to prolong the prothrombin time. International normalized ratio (INR) is maintained at 2.0 to 3.0.

### Remote Complications of Hysterectomy

- ◆ Vault granulation—It is more with catgut and less with Vicryl.
- ◆ Vault prolapse—less compared to vaginal.
- ◆ Incisional hernia—more with mid-line vertical incision than with low transverse one.
- ◆ Prolapse of the fallopian tube through the vault (rare).
- ◆ Depression, psychiatric symptoms.
- ◆ Sexual dysfunction.

**Comments:** Vaginal hysterectomy is the ideal method if not contraindicated. In the hands of an expert conversant with vaginal hysterectomy even in undescended uterus, vaginal hysterectomy is the method of choice. This route still offers benefits.

**Complications of Vaginal Hysterectomy:** See p. 222, 223.

**Laparoscopic assisted vaginal hysterectomy (LAVH)** (see p. 617), does have some superiority

over traditional vaginal hysterectomy even in an undescended uterus. Pelvic adhesions (endometriosis) can be dealt under vision with operative laparoscopy. The cost of the former is very high whereas perioperative morbidity is the same (for details see p. 617).

**Pelvic floor repair (PFR)**—see p. 216.

**Fothergill's or Manchester Operation**—see p. 217.

**Operations for vault prolapse**—see p. 220.

**Cervicopexy** (Sling or Purandare's Operation)—see p. 221.

**Complications of vaginal operations**—see p. 221.

## OPERATIONS ON THE OVARY

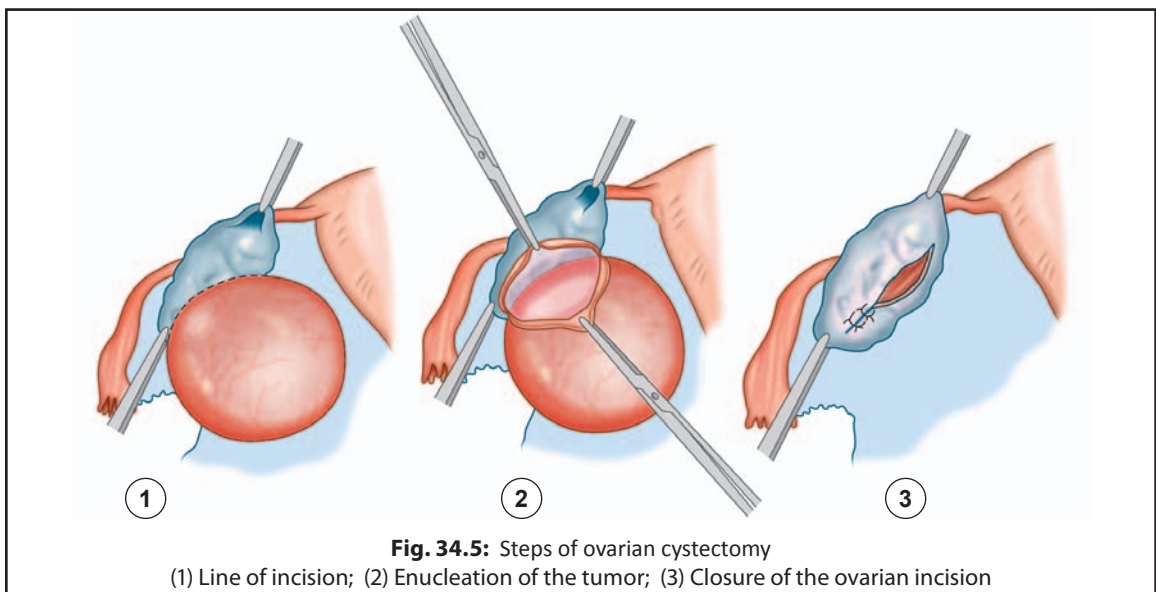
### OVARIAN CYSTECTOMY (FIG. 34.5)

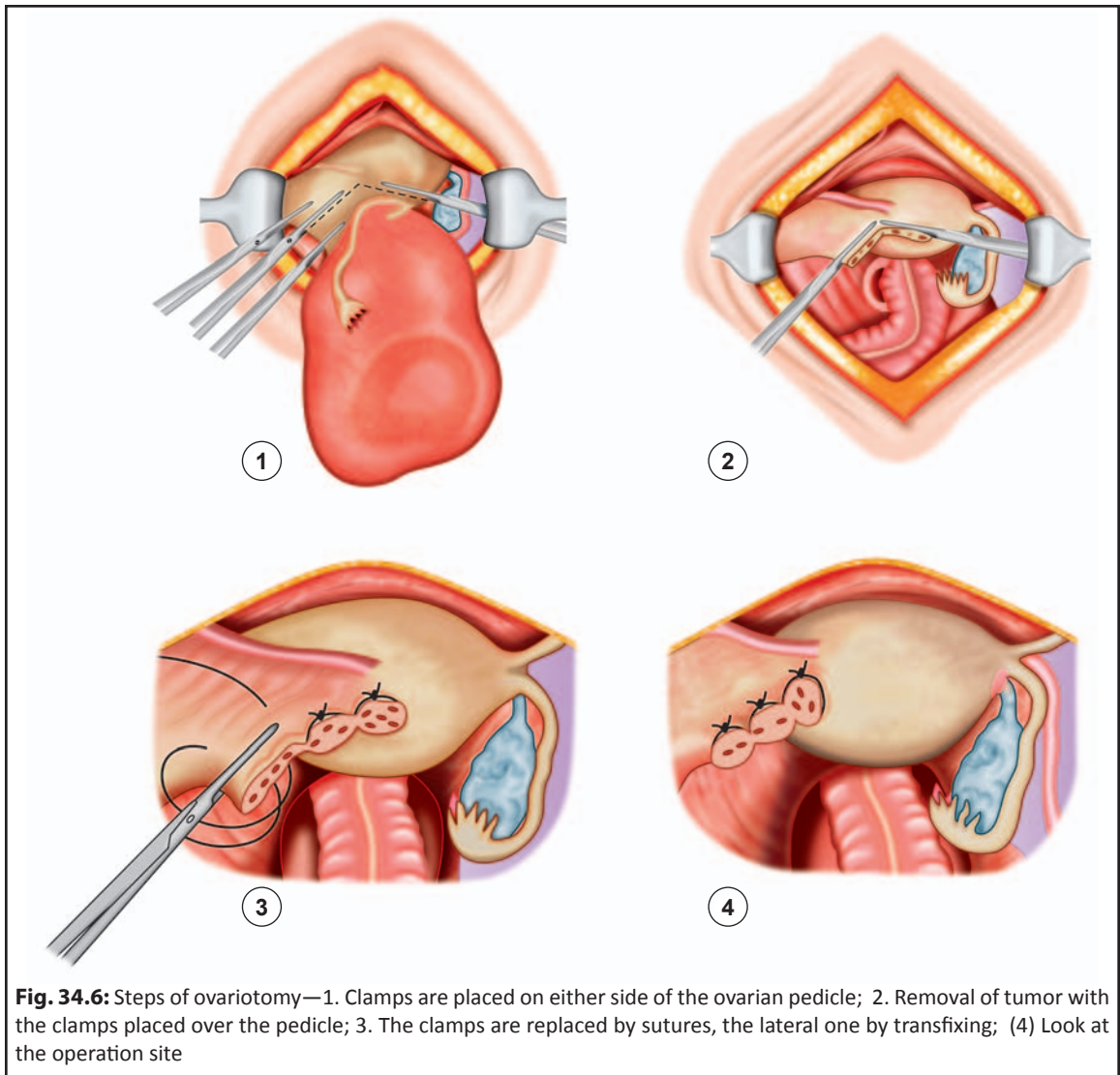
Removal of the ovarian tumor leaving behind the healthy ovarian tissue is called ovarian cystectomy.

It is the operation of choice especially when both the ovaries are involved with benign neoplasm in young women.

#### Principal steps

- Incision (elliptical) is made with a scalpel through the ovarian cortex at the base of the ovarian cyst [Fig. 34.5(1)].





- The cyst wall is separated gently, using the handle of the scalpel or by scissors and the cyst is shelled out without rupture [Fig. 34.5(2)].
- The dead space is obliterated using (4–0) absorbable sutures. Ovarian surface is approximated using very fine interrupted sutures [Fig. 34.5(3)].

**Ovariectomy (Fig. 34.6):** Removal of the tumor along with healthy ovarian tissue is called ovariectomy. The term is better replaced by oophorectomy. This is

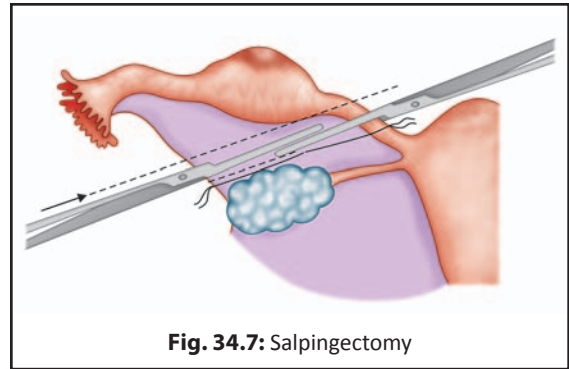
indicated when the tumor is big or complicated by torsion or hemorrhage and the other ovary is healthy.

#### Principal steps

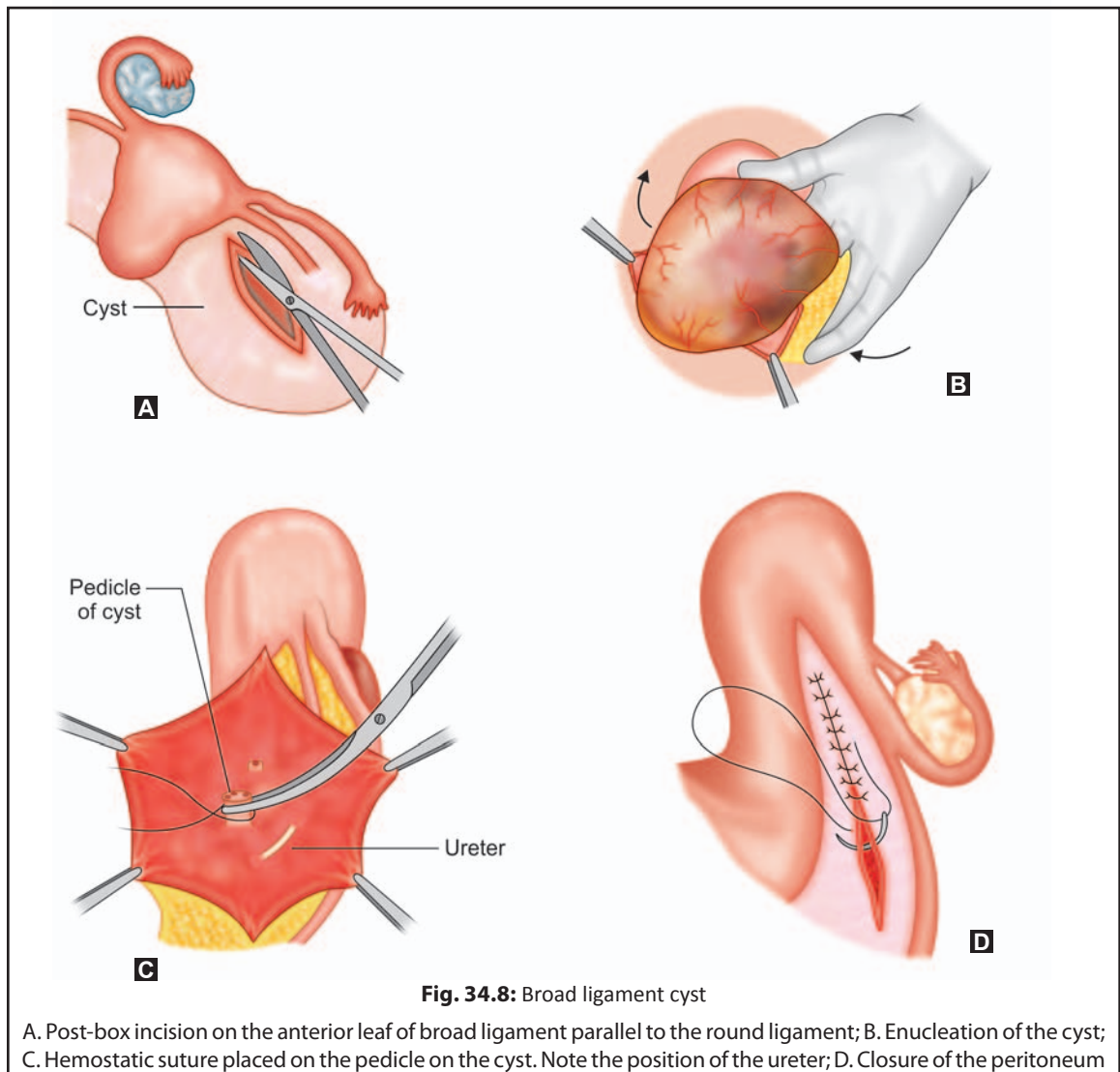
- ◆ Paired clamps are placed laterally over the infundibulopelvic fold of peritoneum with its contents. Medial pair of clamps are applied on the side of uterus to include the ovarian ligament and the Fallopian tube [Fig. 34.6(1)].

- ◆ Pedicles are cut in between and the tumor is removed [Fig. 34.6(2)].
- ◆ Clamps are replaced by transfixing ligatures [Fig. 34.6(3)].
- ◆ Pedicles are checked carefully for hemostasis [Fig. 34.6(4)].

**WEDGE RESECTION:** A wedge of ovarian tissue with the base on the surface and the apex extending to medulla is removed in PCOS when medical treatment fails to induce ovulation. About one-third of the ovarian tissue is removed by the wedge method. This operation is not commonly done these days.



**Fig. 34.7:** Salpingectomy



**Fig. 34.8:** Broad ligament cyst

A. Post-box incision on the anterior leaf of broad ligament parallel to the round ligament; B. Enucleation of the cyst; C. Hemostatic suture placed on the pedicle on the cyst. Note the position of the ureter; D. Closure of the peritoneum

**Laparoscopic ovarian drilling** is more commonly done than ovarian wedge resection (see p. 237). It can be done using a needle point monopolar cautery, or a bipolar cautery or by laser. Cortex is usually punctured up to a depth of 3–5 mm at 4–6 sites (see Fig. 35.6).

**Ovarian biopsy:** This is indicated to differentiate premature ovarian failure from resistant ovarian syndrome or for the problem of intersexuality.

### SALPINGECTOMY (FIG. 34.7)

One pair of long hemostatic forceps is placed on the medial end of the Fallopian tube including the mesosalpinx as close to the uterus. A second pair of clamp is placed from the lateral aspect on the mesosalpinx. The clamp tips are to be approximated. The tube is excised and the clamps are replaced by ligatures. **The excised tube is to be sent for histology.**

### BROAD LIGAMENT CYST OR LEIOMYOMA (FIG. 34.8)

- ◆ Post box incision is made with a knife on the anterior leaf of the broad ligament making parallel to the round ligament [Fig. 34.8(A)].
- ◆ Fingers are used to separate the tumor from the leaves of broad ligament up to the base [Fig. 34.8(B)].

In a case of fibroid, the capsule is incised and the myoma is enucleated from its bed by sharp and blunt dissection.

- ◆ Position of the ureter is checked and a clamp is placed on the tumor pedicle.
- ◆ The pedicle is cut and the clamp is replaced by a ligature [Fig. 34.8(C)].
- ◆ The leaves of broad ligament are closed with a continuous suture [Fig. 34.8(D)].

### OPERATIONS FOR INVERSION OF THE UTERUS

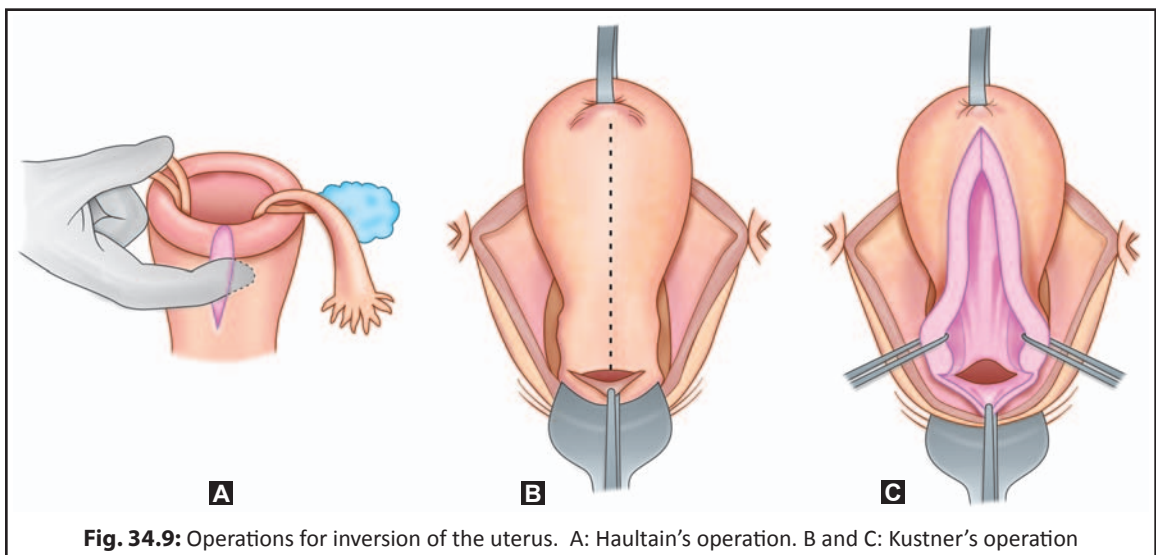
#### HAULTAIN'S OPERATION (FIG. 34.9A)

##### Principle of the operation

This is done abdominally. Correction of inversion is done after cutting the posterior rim of the cup-like depression (see Fig. 34.9A).

##### Actual steps

- ▶ Antiseptic cleaning of the vagina is done preoperatively.
- ▶ Abdomen is opened with the patient in Trendelenburg position.
- ▶ The ring of tissue is grasped by Allis forceps. A vertical incision is made on the midline at the posterior rim.



**Fig. 34.9:** Operations for inversion of the uterus. A: Haultain's operation. B and C: Kustner's operation

- ▶ A finger is passed through the incision and the inverted fundus is pushed up. An assistant may also push up inverted fundus through the vagina.
- ▶ Uterine incision is repaired with chromic catgut sutures in two layers.

### KUSTNER'S OPERATION (FIGS 34.9B AND C)

This is a vaginal procedure.

#### Actual steps

- ◆ Uterus is drawn upwards and forwards by a single tooth vulsellum holding at the fundus.
- ◆ Pouch of Douglas is opened by a transverse incision made on the posterior vaginal wall.
- ◆ Left index finger is introduced along the hollow of the inverted uterus. Posterior uterine wall is cut through by a scalpel from fundus to the external os (Fig. 34.9B).
- ◆ The inverted uterus is then turned inside out and inversion is corrected.
- ◆ Repair of the incised uterine wall is done with vicryl (1–0) or chromic catgut sutures in two layers.
- ◆ Repair of the pouch of Douglas and posterior vaginal wall is done.

**Spinelli's operation** is a vaginal procedure and principle is the same as that of Kustner. Here uterovesical pouch is opened and uterine incision is made on the anterior wall.

### VENTROSUSPENSION OPERATION

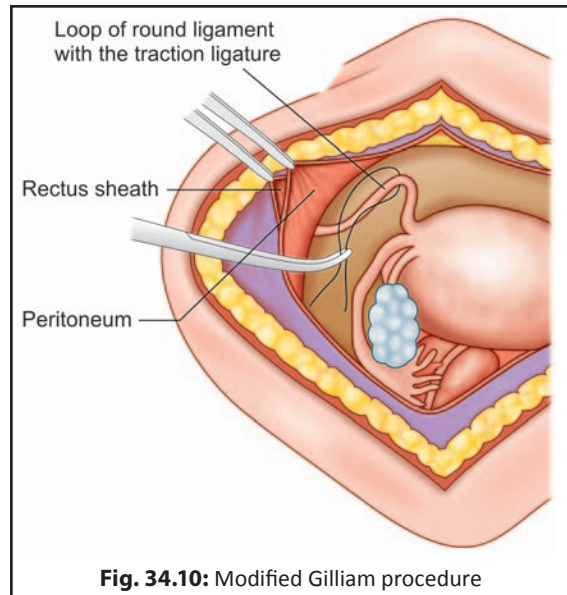
This operation is less commonly performed these days. Common indications of this operation in relation to retroversion of uterus have been mentioned before (see p. 199). Other indications are to prevent adhesions over the posterior uterine surface following: (i) myomectomy operation; (ii) operation for endometriosis, where the uterus is bulky.

It may be done by: (i) plication of the round ligaments; (ii) modified Gilliam procedure or by (iii) laparoscopic suspension operation.

**Actual steps:** Abdomen is opened by suprapubic transverse incision.

#### Plication of the round ligaments

Reefing suture is passed through the substance of the round ligaments extending from the internal abdominal ring up to the myometrium at the cornu of the uterus. Suture material



**Fig. 34.10:** Modified Gilliam procedure

used is either chromic catgut or Vicryl. The suture is tied firmly at the end. Similar procedure is done on the other side. The round ligaments are shortened and the uterus is thus anteverted.

### MODIFIED GILLIAM PROCEDURE

#### Principal steps (Fig. 34.10)

- ◆ Each round ligament is sutured with no. 1 chromic catgut about 3–4 cm from the cornu of the uterus. This is left untied and used for traction.
- ◆ A long curved clamp is introduced between the rectus sheath and the lateral border of the rectus muscle up to the internal inguinal ring. The peritoneum overlying the opened jaws of the clamp is incised.
- ◆ The traction ligature on the round ligament is now grasped by the clamp and the clamp is withdrawn gradually.
- ◆ The loop of round ligament, such withdrawn, is sutured to the rectus sheath by three interrupted delayed absorbable sutures (Vicryl 1–0).
- ◆ Similar procedure is repeated on the other side.
- ◆ Abdomen is closed in layers.

#### Complication of ventrosuspension operation

- ◆ Pain — when there is excessive stretching of the round ligaments.
- ◆ Avulsion of the round ligament and bleeding — rare.

## ABDOMINAL MYOMECTOMY

### Measures to control blood loss during myomectomy

- I Preoperative treatment with GnRH analogue reduces the vascularity of the tumor and thereby reduces operative blood loss (see p. 281).
  - I Use of vasoconstrictive agents—commonly used is vasopressin (Synthetic). 20 units of vasopressin diluted in 20 mL of normal saline is injected into the myometrium overlying the myoma.
  - I Use of Victor Bonney's specially designed clamp (see Fig. 37.22) to reduce uterine artery blood flow. This clamp is placed around the uterine vessels and the round ligament.
  - I Use of tourniquets—to occlude the uterine vessels and also the ovarian vessels at the infundibulopelvic ligament.
- A soft plastic tube (less traumatic) is passed through a small hole one on either side made in an avascular part of the broad ligament at the level of the uterine isthmus. This tourniquet is tightened just before making the incision for myomectomy.
- I Controlled hypotensive anesthesia (using sodium nitroprusside) to reduce venous tone and a moderate degree of Trendelenburg position (to enhance venous drainage) reduce operative blood loss.

#### Actual steps

- ◆ Uterine incision — a single incision (linear or elliptical) in the midline on the anterior wall of the uterus is preferred.

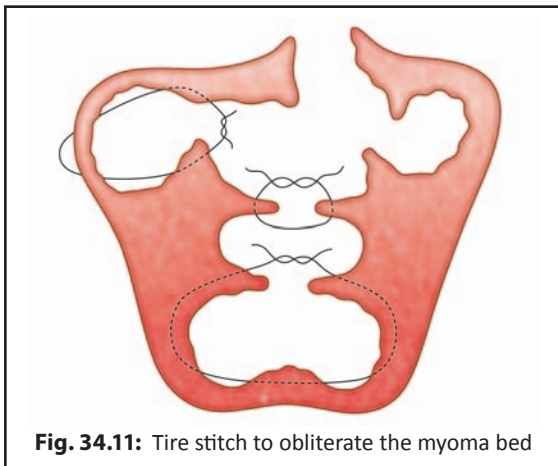


Fig. 34.11: Tire stitch to obliterate the myoma bed

This has the following advantages:

- Avoids any injury to the tube and ovary
- Lateral fibroids are removed by tunnelling without any additional scar on the uterine surface.
- Fibroids from the cavity or posterior wall can be removed by transcavity approach. This avoids scar on the posterior wall and adhesion formation.
- ◆ Incision is deepened through the myometrium and the (pseudo) capsule, till the myoma is reached.
- ◆ The myoma is grasped with a single toothed vulsellum and dissection is continued in the plane between the myoma and the capsule (to minimize blood loss). Myoma is enucleated (intracapsular) from its bed by sharp (scissors) and blunt (knife handle) dissection.
- ◆ The myoma bed (deep space) is obliterated by interrupted mattress or figure-of-eight sutures. Sometimes layers of sutures (tire stitch) may be required to approximate the myometrium (Fig. 34.11).
- ◆ **Bonney's hood operation** — is done to remove a large fundal myoma. A low transverse incision is made on the myoma over the anterior uterine surface. After enucleation of the myoma, the capsule is trimmed and is sewn over the anterior uterine wall. This minimizes adhesion formation (see Fig. 34.12).
- ◆ The serous coat of the uterus is approximated with a thin absorbable suture. To prevent adhesion over the incision site, interceed (oxidized cellulose) or Gore-text (surgical membrane) can be used.

### CERVICAL FIBROID

- ◆ *Anterior cervical myoma*—can be approached by making a transverse incision over the uterovesical

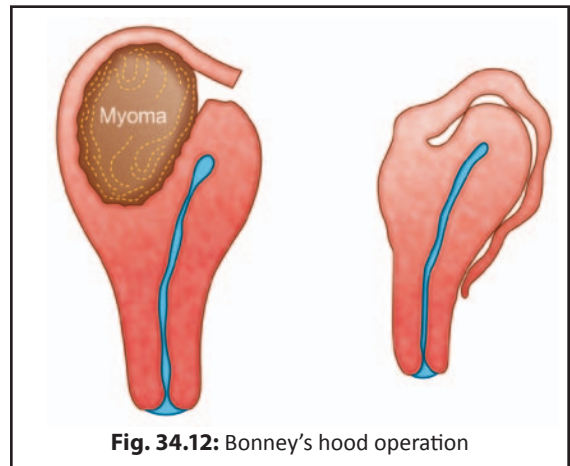


Fig. 34.12: Bonney's hood operation

peritoneum. Bladder is dissected down before the incision over the capsule of the fibroid is made. Fibroid is then enucleated (intracapsular).

- ◆ *Posterior cervical myoma*—approach is made by low posterior incision on the uterine surface through the pouch of Douglas.
- ◆ *Central cervical myoma*—The peritoneum of the uterovesical pouch is incised transversely and the bladder is dissected down. Hemisection of the uterus is done from above downwards to reach the myoma which is then enucleated (intracapsular). The dead space is obliterated without closure of the cervical canal. The bisected uterus is then repaired.

### Broad ligament myoma (see p. 602).

**Complications of Myomectomy:** General complications of any abdominal procedure has been discussed (see p. 596). The specific complications are:

#### Immediate

- ◆ Hemorrhage—intraperitoneal from the uterine wound. This may occur when hemostasis during operation is imperfect.
- ◆ Injury to bladder and ureter—specially with cervical and broad ligament myomas.
- ◆ Injury to the Fallopian tubes—interstitial portion is commonly damaged during incision and suturing.
- ◆ Injury to bowel.

- ◆ Febrile morbidity—due to tissue reaction or infection.

**Remote** — (see Ch. 19, Table 19.9).

## RADICAL HYSTERECTOMY (SEE P. 348)

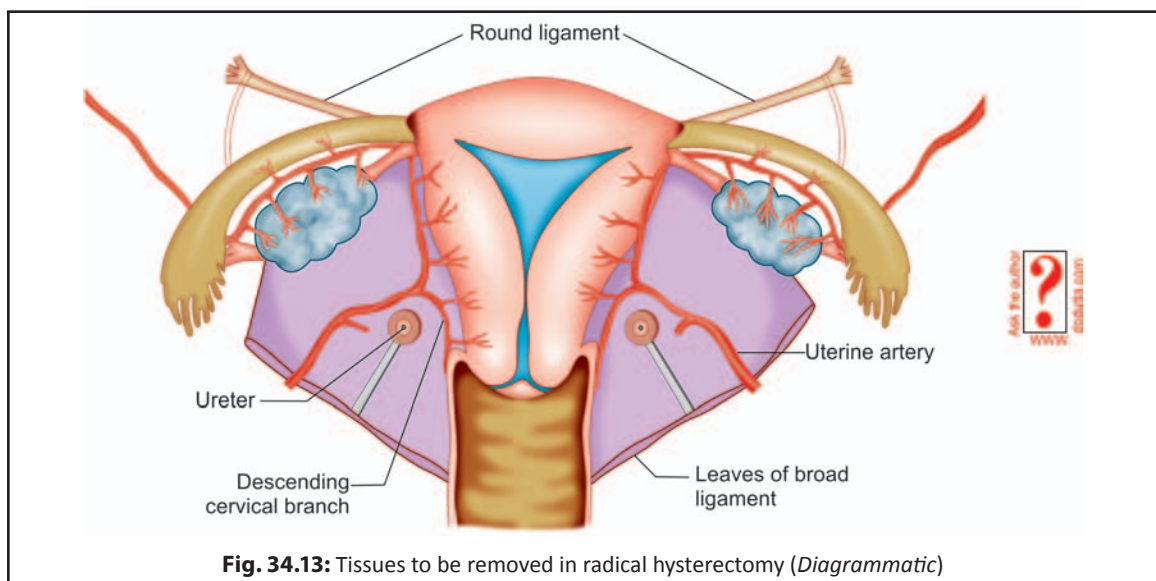
(**SYN: CLASS IV RADICAL HYSTERECTOMY**)

Wertheim's original operation was less extensive. With this procedure only a selective group of lymph nodes (e.g. enlarged and palpable) and only the medial half of the cardinal and uterosacral ligaments were removed.

The classic radical hysterectomy (Type IV) is performed in most centers these days. **Tissues removed in this operation** include wide resection of the parametrium, periureteral tissue, superior vesical artery, cardinal and uterosacral ligaments, upper three-fourth of vagina and thorough pelvic lymphadenectomy (see Fig. 34.13).

### INDICATIONS OF RADICAL HYSTERECTOMY

- A. Carcinoma cervix: Stage IA1 (lymphovascular space involvement): IA2, IB1, IB2, IIA (selected)
- B. Endometrial carcinoma: Stage IIB (see p. 357)
- C. Vaginal carcinoma: Stage I–II (Limited to upper one-third vagina)
- D. Recurrence of cervical cancer after radiotherapy: Growth limited to cervix and upper vagina



**Fig. 34.13:** Tissues to be removed in radical hysterectomy (*Diagrammatic*)

### Steps of operation

Preoperative work up (see p. 341, Table 23.7)

- Continuous bladder drainage by Foley catheter.
- Vaginal packing under anesthesia.

### Actual steps

- Abdomen is opened by low mid-line or transverse incision.
- Abdominal and pelvic exploration is done to detect any metastatic disease.
- Liver, under surface of the diaphragm, kidneys, para-aortic lymph nodes, stomach, omentum and ovaries are examined thoroughly.
- Traction of the uterus is given by long artery forceps, placed one on either side of the uterine cornu.
- The round ligament is clamped, cut and ligated near the pelvic side wall. The infundibulopelvic ligament is also clamped, cut and transfixed at this juncture (when ovaries are to be removed).

In some doubtful cases, opening up of the peritoneum of the **utero-vesical pouch is done first**. The cervix is then palpated for evidence of tumor extension. The operation is abandoned in favor of concurrent chemo and radiotherapy, if bladder is found involved with the tumor.

- ◆ The broad ligament leaves are opened up and the paravesical and pararectal spaces are explored.

**Paravesical space** is bounded anteriorly by the symphysis pubis, medially by the bladder, laterally by the obturator muscle and the pelvic side wall and posteriorly by the cardinal ligament.

**Pararectal space** is bounded anteriorly by the cardinal ligament, posteriorly by the sacrum, medially by the rectum and the uterosacral ligament and laterally by the hypogastric vessels.

- ◆ **The uterine artery** is identified and dissected out. It is then clamped cut and ligated at its origin from the anterior division of internal iliac artery. Some prefer to ligate the anterior division of internal iliac artery just distal to its posterior division.
- ◆ **On the medial flap of peritoneum, the ureter is identified** and is dissected free from the parametrial tissue. Great care is taken when the ureter is dissected from the tunnel of the cardinal ligament (base of broad ligament). Damage to the adventitia and the muscular coat of the ureter should be avoided. Ureter can be retracted, when required, with an umbilical tape.

- ◆ **Bladder** is reflected off the cervix and the upper vagina and the **vesicocervical** and **vesicovaginal space** is created.
- ◆ The peritoneum of the pouch of Douglas is incised to expose the uterosacral ligaments. The rectum is rolled free and the **rectovaginal space** is created by sharp and blunt dissection.
- ◆ **The uterosacral ligament** is clamped close to the sacrum, cut and ligated (with no.1 delayed absorbable suture). The cardinal ligament and paravaginal tissues are clamped close to the lateral pelvic wall, cut and ligated.
- ◆ **The vaginal pack** is pulled out. Long right angled clamps are applied one on either side of vagina, low down to remove upper 3 cm of the vagina. The specimen is removed by cutting below the clamps (to avoid tumor spillage). The edges of the vagina are grasped with long Allis forceps.
- ◆ **The vaginal margins** are sutured if it is left open for drainage. Some prefer to close the vagina by interrupted sutures, so that postoperative suction (vacuum) drainage can be used.
- ◆ **Thorough pelvic lymphadenectomy** is done (external iliac, internal iliac, common iliac, obturator). **Para-aortic lymph nodes** are evaluated and sampling is done in women with positive pelvic lymph nodes (frozen section).  
The sensitivity of sentinel lymph node for prediction of lymph node metastasis is 100%.
- ◆ Hemostasis is checked. Pelvic peritonization may be done. Abdominal packs are removed.
- ◆ Abdomen is closed in layers. Continuous bladder drainage is maintained for 7–10 days.

(Surgical steps are described for one side and similar steps are repeated on the other side).

**Laparoscopic Radical Hysterectomy** is currently being evaluated for the management of early stage cervical carcinoma. **The laparoscopic procedures used are:**

- Laparoscopic surgical staging only:** (i) Transperitoneally or (ii) Retroperitoneally.
- Laparoscopically Assisted Radical Vaginal Hysterectomy (LARVH) with pelvic and aortic lymphadenectomy.** The abdominal part of the procedure includes division of: (i) ovarian vessels, (ii) round ligaments, (iii) uterine artery by opening up of the pararectal and paravesical spaces and (iv) pelvic and aortic lymphadenectomy.



- C. **Laparoscopic Radical Hysterectomy with pelvic and aortic lymphadenectomy.**
- D. **Laparoscopically Assisted Radical Vaginal Trachelectomy (LARVT) with pelvic and aortic lymphadenectomy**—done in (i) selected young women (ii) early stage disease (stage IA<sub>2</sub> or IB<sub>1</sub> ≤ 2 cm) and (iii) to preserve the reproductive function. This procedure includes: (i) Laparoscopic pelvic and aortic lymph node dissection and (ii) vaginal radical trachelectomy if only there is no lymph node metastasis (see p. 352).

Involvement of para-aortic nodes without involvement of the pelvic nodes is extremely rare. If para-aortic nodes are found to be involved with metastatic tumor on frozen section biopsy in the beginning, the procedure of radical hysterectomy is abandoned. Concurrent chemotherapy and radiotherapy are then considered.

**Complications of radical hysterectomy** (see p. 348).

## OPERATIONS ON THE VULVA

### SIMPLE VULVECTOMY

Preoperative work up (see p. 582).

#### Actual steps

- Lithotomy position.
  - Outer incision—an elliptical incision is made commencing anteriorly on the mons pubis → encircling laterally along the medial side of labiocrural fold → posteriorly across the mid-line of perineum (Fig. 34.14).
  - Inner incision — passes around the introitus and anterior to urethra (see Fig. 34.14).
- Vulval skin (not deeper tissues) is removed. Bleeding vessels (branches of internal pudendal artery) are ligated separately.
- Apposition of the skin edges is done (interrupted sutures) without tension.
  - Continuous bladder drainage is maintained with a Foley's catheter for 3–4 days.

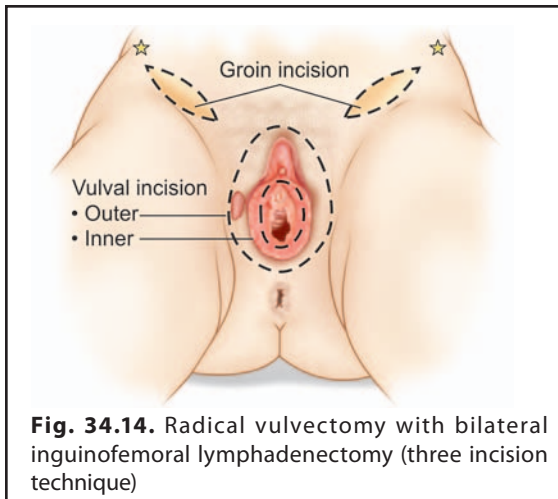
Tissues removed are—mons pubis, clitoris, labia majora and minora.

### RADICAL VULVECTOMY WITH BILATERAL INGUINOFEMORAL LYMPHADENECTOMY (FIGS 34.14 AND 34.15)

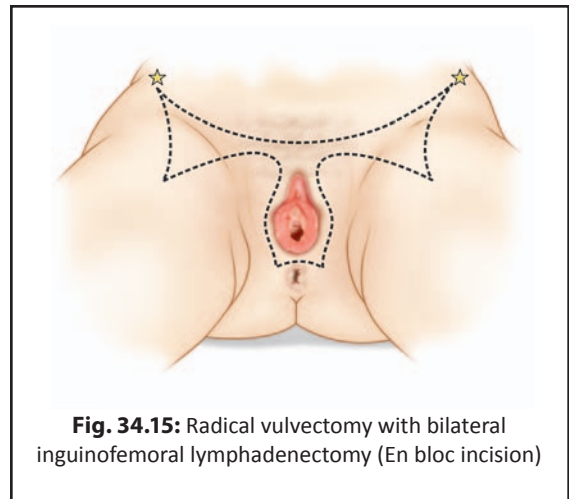
No single operation technique is standard. En bloc dissection of the groin nodes in continuity with vulvectomy is done only for large vulval lesion. **Three separate incisions have been currently used to reduce the considerable morbidity of en bloc procedure** (see p. 336, 337).

**Actual steps: Three incision technique is preferred** in most centers. These are—(i) Vulval incision, (ii) Groin incision one on either side (see Fig. 34.14).

- ◆ **Groin incision** is a crescent-shaped one, starting about 2–4 cm medial and about 2 cm below the anterior-superior iliac spine. The incision curves gradually downwards above the inguinal ligament medially to the superficial inguinal ring or about 2 cm below and 2 cm medial to the pubic tubercle. Mons pubis is spared. A strip of skin (2–4 cm) width is excised. This incision helps more complete dissection and reduces skin necrosis.
- ◆ Vulval incisions are same as described in simple vulvectomy. Special points to note are:
  - Wide tumor free margin (at least 1 cm) is essential. If the tumor is close to urethra or vagina, lower 2 cm of urethra and lower vagina may be sacrificed.
- ◆ Dissection must be done down to the deep fascia.
- **Inguinofemoral lymphadenectomy**
  - Dissection is carried out down to external oblique fascia and fascia overlying the sartorius muscle.
  - The lymph nodes and the fatty tissues around the superficial circumflex iliac and the superficial epigastric vessels are resected off. The vessels are ligated.
  - At the caudal end of femoral triangle—the long saphenous vein is dissected and doubly ligated with 2–0 silk.
  - The surrounding lymph nodes (Saphenofemoral junction) are dissected off the sartorius and the adductor fascia.
  - The lymph nodes, lateral and medial to femoral artery and vein are dissected out by sharp dissection.
  - Inguinal and femoral lymph nodes are removed and sent for frozen section biopsy. The **Cloquet**



**Fig. 34.14.** Radical vulvectomy with bilateral inguofemoral lymphadenectomy (three incision technique)



**Fig. 34.15:** Radical vulvectomy with bilateral inguofemoral lymphadenectomy (En bloc incision)

**node or node of Rosenmuller** at the femoral canal (medial to femoral vein) may be absent in more than 50 percent cases. If these nodes are positive, ipsilateral retroperitoneal pelvic lymphadenectomy is performed.

- **Lymphatic drainage** occurs in a stepwise fashion. The **sentinel lymph node** when negative for tumor metastasis, it is rare for the other nodes in the basin to be involved. Identification of the **sentinel lymph node** (Cloquet node) can therefore guide the extent of surgery and also the surgical lymph node dissection. This can reduce the risk of surgical morbidity and mortality.
- **Sentinel node biopsy** (p. 337) is done using either blue dye or radio colloid. Methylene blue dye is injected at the periphery of the tumor → the blue dyed lymphatics are followed → dyed nodes are then removed and subjected to frozen section biopsy. Otherwise **technetium-99m** is injected into the tumor and the radioactive tracer uptake in the regional lymph nodes is then identified by a hand-held gamma camera.
- However, radiation therapy is preferred to surgery for pelvic node dissection (see p. 337).
- Closed system suction drains are placed in the groin area. Groin incision is closed by interrupted sutures.

### Complications of Radical Vulvectomy

#### Early:

- Hemorrhage.
- Seroma collection.
- Fluid and electrolyte imbalance.
- Groin wound infection, necrosis and dehiscence.
- Urinary tract infection.
- Rectovaginal fistula.
- Deep vein thrombosis.
- Pulmonary embolism (see p. 599).
- Psychological—depression.

#### Late:

- Leg edema, leg cellulitis.
- Dyspareunia due to introital stenosis.
- Femoral or inguinal hernia.
- Osteitis pubis, osteomyelitis.
- Loss of body image.
- Recurrence (10%).

**Operations for urinary incontinence** (see p. 402).

**Repair of vesicovaginal fistula** (see p. 421).

**Repair of ureteric injuries** (see p. 425).

**Vaginal reconstruction operation (vaginoplasty)** (see p. 457).



## KEY POINTS

- Preoperative investigations should preferably be done prior to admission in hospital.
- In elective operations, the patient should be made fit for surgery prior-hand.
- Even in minor surgery, examination of the cardiovascular system, complete hemogram and complete urine examination should at least be done.
- Preoperative risk assessment is essential to minimize surgical morbidity and others (p. 580).
- For any operation, preoperative counseling and informed consent are essential (p. 580).
- Day care surgery has many benefits. Here the patients are admitted, operated and discharged on the same day (p. 580). Patients are screened before hand.
- Postoperative care should include record of vital signs, fluid replacement, output record, adequate pain control, antibiotic therapy and vigilance to the close system suction drains.
- Only dilatation of the cervix is indicated in—prior to amputation of the cervix, spasmodic dysmenorrhea, pyometra or hematometra.
- Common indications of D&C are infertility, DUB, incomplete abortion and endometrial pathology.  
Common complications of D&C are injury to the cervix, uterine perforation, injury to the gut and infection. Remote complications include cervical incompetence and uterine synechiae.
- D & I is indicated to note the patency of the tubes in cases of infertility or following tuboplasty operation.
- HSG is done in the radiology department without anesthesia (p. 588). Besides tubal patency test, it has many other benefits (p. 588). It is superior to D&I.
- Types of cervical biopsy include—surface, punch, wedge, ring and cone type (see p. 589).
- Destruction of the benign pathological cervical lesions (ectopy, CIN) can be done by thermal cauterization, cryosurgery or laser (see p. 590, 591).
- **Perineoplasty** is a simple reconstructive surgery for widening the narrow vaginal introitus for sexual function (p. 592).
- Complications of cervical conization or amputation include postoperative hemorrhage and cervical stenosis or cervical incompetence (see p. 223; Table 15.3).
- Common indications of total hysterectomy for benign lesions are DUB, fibroid, TO mass and endometriosis (see p. 593, Table 34.2).
- Common indications of subtotal hysterectomy are difficult TO mass, endometriosis of rectovaginal septum and sudden deterioration of the general health while contemplating total hysterectomy.  
Premenopausal ovaries are better to be preserved, if not pathological.
- Conization of the cervix is done either as a diagnostic or therapeutic procedure in CIN or in microinvasive carcinoma. Laser cone has got distinct advantages over the cold knife cone (see Table 34.1).
- Complications of abdominal hysterectomy are intraoperative, postoperative (immediate, late and remote) (see p. 596). Postoperative bowel dysfunction (ileus and obstruction) need to be differentiated (see Table 34.4).

*Contd...*

Contd...

- ▶ Hysterectomy can be abdominal, vaginal, laparoscopic or laparoscopic assisted vaginal. Each method has got advantages and disadvantages (see p. 593, 598). Each case needs to be individualized for any particular method. Hysterectomy may be classified into different types (p. 593).
  - ▶ Laparoscopic ovarian drilling is more commonly done compared to wedge resection in the management of PCOS cases (see p. 602).
  - ▶ Operations for chronic inversion of the uterus may be abdominal (Haultain) or vaginal (Kustner or Spinelli) (p. 602).
  - ▶ Ventrosuspension operations are less commonly done these days. Plication of the round ligaments, modified Gilliam procedure or laparoscopic suspension operation are the different methods (see p. 603).
  - ▶ Abdominal myomectomy could be done either by open surgery or laparoscopically. Control of operative blood loss is an important step (see p. 604). A single incision on the anterior wall is preferred. Hemorrhage is the single most important complication (p. 605).
  - ▶ Radical hysterectomy (Type IV) is the operation of choice for invasive carcinoma of the cervix (see p. 348 and p. 605). Extensive pelvic tissues are removed (p. 605). Complications of radical hysterectomy are other organ injury (bladder, ureter) besides the complications of simple hysterectomy (p. 348).
  - ▶ Laparoscopic radical hysterectomy is currently being done (p. 607). Laparoscopically assisted radical vaginal trachelectomy (LARVT) is a fertility sparing surgery, done for early stage (IA<sub>2</sub> or IB<sub>1</sub> ≤ 2 cm) diseases.
  - ▶ Radical vulvectomy with bilateral inguinofemoral lymphadenectomy could be done either by three incision technique (preferred) or by en bloc procedure (butterfly horned incision).
  - ▶ Node of Cloquet or Rosenmüller (deep femoral node) may be absent in more than 50 percent cases.
  - ▶ Pelvic node metastases are rare unless inguinofemoral nodes are involved. However, radiation therapy is preferred to surgery for pelvic node dissection (see p. 333).
- Complications of radical vulvectomy may be early or late (p. 608) and increase the morbidity.

# Endoscopic Surgery in Gynecology

## (Syn: Minimally invasive surgery, Minimal access surgery)

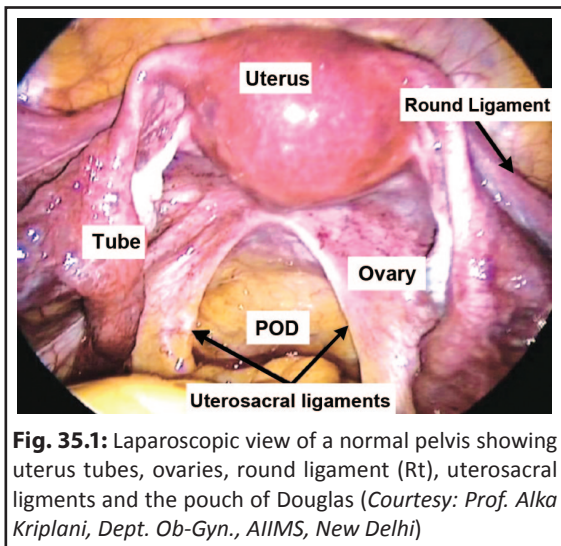
The range of surgical procedures in gynecology, performed with the use of either a laparoscope or a hysteroscope is designated as **endoscopic surgery**. With very fast technological advancement, as much as 80 percent of gynecological operations can be performed endoscopically.

**History:** First description of endoscopy is recorded by **Phillip Bozzini** in 1805. He used a simple tube and candle light to visualize the interior of the urethra. **Pantaleoni** of Ireland first used a cystoscope in 1869 as an hysteroscope to diagnose a case of irregular vaginal bleeding. **Jacobaeus** of Sweden in 1910 first introduced a cystoscope in the peritoneal cavity and coined the term laparoscopy. In 1938, **Veress** first reported the spring loaded needle for creating pneumothorax in patients with tuberculosis. In 1947, **Raoul Palmer** of France introduced the use of gaseous distension of the peritoneal cavity using gas and the lithotomy (Trendelenburg) position. Landmark progress of the use of “Coldlight” and fiberoptics were made by **Fourestier** and **others**. In 1967 **Steptoe** of England first published the monograph “Laparoscopy in Gynaecology” in english language. **Kurt Semm** of Germany is credited for his advanced operative laparoscopic procedures (myomectomy) in the 1970s. First laparoscopic hysterectomy was reported by **Reich et. al** in 1989.

### Advantages of Laparoscopic Surgery

- ◆ Rapid postoperative recovery.
- ◆ Less postoperative pain and reduced need of postoperative analgesia.
- ◆ Shorter hospital stay and reduced concomitant cost
- ◆ Quicker resumption of day-to-day activity
- ◆ Less adhesion formation
- ◆ Minimal abdominal scars (cosmetic value)
- ◆ Reduced blood loss

- ◆ No large incisions
- ◆ Less risk of incisional hernia
- ◆ Increased patient’s satisfaction.



**Fig. 35.1:** Laparoscopic view of a normal pelvis showing uterus tubes, ovaries, round ligament (Rt), uterosacral ligments and the pouch of Douglas (Courtesy: Prof. Alka Kriplani, Dept. Ob-Gyn., AIIMS, New Delhi)

### Disadvantages

Disadvantages are mainly related to case selection and experience of the surgeon:

- Operation time—may be longer
- Risk of iatrogenic complications (see p. 619)
- High initial expenditure
- Surgeon needs specialized training and expertise
- Long learning curve
- Instruments and equipments are sophisticated
- Complications are specific to laparoscopy and may be fatal.

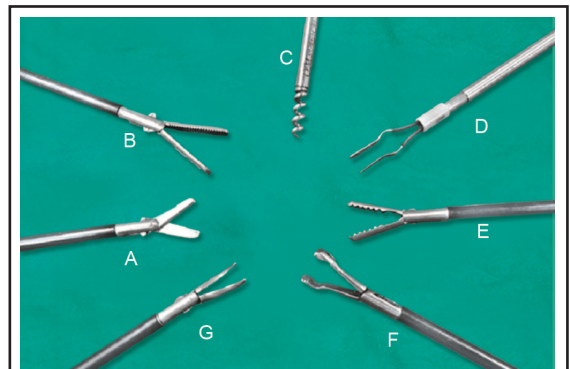
### BASIC INSTRUMENTS AND ELECTROSURGICAL UNITS FOR LAPAROSCOPIC SURGERY (FIG. 35.2)

- ◆ **Telescope**—Caliber varies from 4–12 mm with rod lens system. Angle of view may be either straight forward (0°) or fore oblique (30°).
- ◆ **Veress needle**—It is used for creating pneumoperitoneum by carbon dioxide. It is spring loaded to prevent visceral injury. The blunt tip point springs out when it enters the peritoneal cavity.
- ◆ **Trocar and cannula**—is inserted through the abdominal wall following pneumoperitoneum. The trocar is removed and the telescope is introduced through the cannula (sleeve). Disposable trocar and veress needles are available.
- ◆ **Light source**—High intensity light (xenon or halogen source) beam (cold light) is transmitted to the telescope for excellent visualization. Fiber optic cables are used to transmit the cold light from source to the telescope.
- ◆ **Imaging system** includes: Laparoscope, light source, fiber optic cord, camera unit and monitors.
- ◆ **Camera unit** includes: Camera head, cable and camera control. **The camera** head is attached to the eye piece of the laparoscope. The image resolution depends on the number of pixels (2,50,000 – 3,80,000) on the chip. High definition digital camera uses resolution up to 1,100 lines to produce more vivid picture.


- **Monitor:** High resolution color monitors with 700 lines provide optimal picture visualization.
- **Insufflator:** The rate of gas flow rate (L/min) and intra-abdominal pressure (mm of Hg) are displayed on the insufflator. It is used to create controlled pneumoperitoneum as there is some amount of gas (CO<sub>2</sub>) leak through the different ports. Either low flow rate (0.5–1 L/min) or high flow rate is used depending on the need.

### Accessory Instruments (Fig. 35.3)

- ◆ **Scissors** of different sizes and designs are used for dissection and to cut tissue.
- ◆ **Grasping forceps** of different designs with are used to hold tissues.



**Fig. 35.3:** Ancillary instruments: A. Scissors; B. Bowel grasper; C. Myoma screw; D. Bipolar coagulating forceps; E. Grasping forceps (alligator jaws); F. Grasper (Babcock); G. Dissecting and grasping forceps.



**Fig. 35.2:** Laparoscopic instruments: (A) Telescope (B) Trocar and cannula (C) Veress needle

- ◆ **Probes** Blunt probe is used for manipulation of viscera (e.g. intestines and ovaries) to visualize other structures.
- ◆ **Aspirator and irrigator** Blunt and sharp aspirators are used for aspiration of fluid from the peritoneal cavity or ovarian cysts. **Irrigation** is done for washing the peritoneal cavity with normal saline at the end of a surgical procedure.
- ◆ **Morcellator** is needed when a large piece of tissue (myoma) is morcellated into small pieces so as to be removed through the laparoscopic sleeve.
- ◆ **Uterine manipulator** is used for adequate visualization of the uterus and adnexae during operation.
- ◆ **L-hook** for cutting tissues using monopolar energy.
- ◆ **Myoma screw**—for myomectomy (laparoscopic modification (Fig. 35.3C)).
- ◆ **Specimen retrieval bag.**

### HEMOSTASIS DURING LAPAROSCOPIC SURGERY

Perfect hemostasis is mandatory at the end of any endoscopic surgery.

**Electrocoagulation:** Electrosurgical units are used for cutting and coagulation of biological tissues. **Cutting mode** provides uninterrupted low voltage to vaporize tissues (100°C). Lateral thermal spread is minimal. **Coagulation mode** creates peak voltage three times higher than of cutting mode. It causes rapid tissue desiccation and carbonization. In **blended mode** cutting and coagulation currents are combined creating alternate high and low voltage current.

**Monopolar Electrosurgery:** The current (electrons) is pushed from the generator through the active electrode to the contact tissue. The current returns back to generator through the neutral electrode after it has passed through the patient.

It is important to check the return electrode is in good contact with the patient. It should be broad enough to reduce the current density far below the level of tissue burning.

Depending upon the size of the electrodes (current density) and voltage used, unwanted burns may be produced due to stray current flow.

**Bipolar Electrosurgery:** Here the current flows from the generator between the two jaws of the forceps or scissors, holding the target tissue (Fig. 35.6). There is no need for ground plate. Bipolar energy is very effective for hemostasis. It works by conducting electrical current with high power density that is confined between the jaws of the forceps. It has limited lateral thermal spread, low contact temperature and high compressive effects. Damage to tissue is more precise compared to unipolar mode.

**Laser Coagulation** (see p. 123): Lasers used in gynecological surgery are CO<sub>2</sub>, KTP-532 and Nd:YAG lasers. For effective cutting, vaporization and coagulation of tissue, power density is an important factor. The depth of tissue penetration depends on the type of laser used, e.g. for CO<sub>2</sub> (most commonly used) 0.1 mm, KTP-532—0.4–0.8 mm and Nd:YAG is 0.6–4.2 mm (see p. 123).

**LigaSure** is a bipolar electrosurgical device used to cut, vaporize, coagulate and seal blood vessels. It delivers electrical energy as high current and low voltage output. The problem of sticking and charring to tissues are less. Lateral thermal spread is also less. It seals blood vessels, up to 7 mm in size.

**Enseal Vessel Fusion** is a bipolar system that deliver a locally regulated current. Tissue temperature remains within 120°C as there is generation of resistance in the plastic jaws of the instrument. The device has a mechanical blade that can be advanced gradually to desiccate and cut tissue bundles.

**Harmonic scalpel:** It is an ultrasound energy source to break hydrogen bonds in tissues. It uses vibration at the rate of 55,000 cycles per second. Harmonic Ace (Ethicon) has minimal lateral thermal injury. This is effective in cutting or coaptation (sealing) of vessels upto 4 mm diameter. There is no risk of electrical injury.

**Mechanical Clips and Staples:** Titanium clips and staples are used for hemostasis by securing blood vessels. Disposable stapling cartridge with a self-contained knife blade (Endo GIA 30) is used for laparoscopic hysterectomy producing quick cut and hemostasis.

**Sutures and Ligature:** Like an open surgery sutures can be used to ligate blood vessels and to secure vascular pedicles. Different methods of suturing and knot tying are used: (a) intra-corporeal knot tying,

(b) extra-corporeal knot tying or (c) endoloops pretied ligature (Roeder loops).

### INDICATIONS OF LAPAROSCOPIC SURGERY

Advances in electrosurgical units, optics, technology, instrumentation and video imaging have widened the area of endoscopic surgery day-by-day. The laparoscopic surgical procedures are graded according

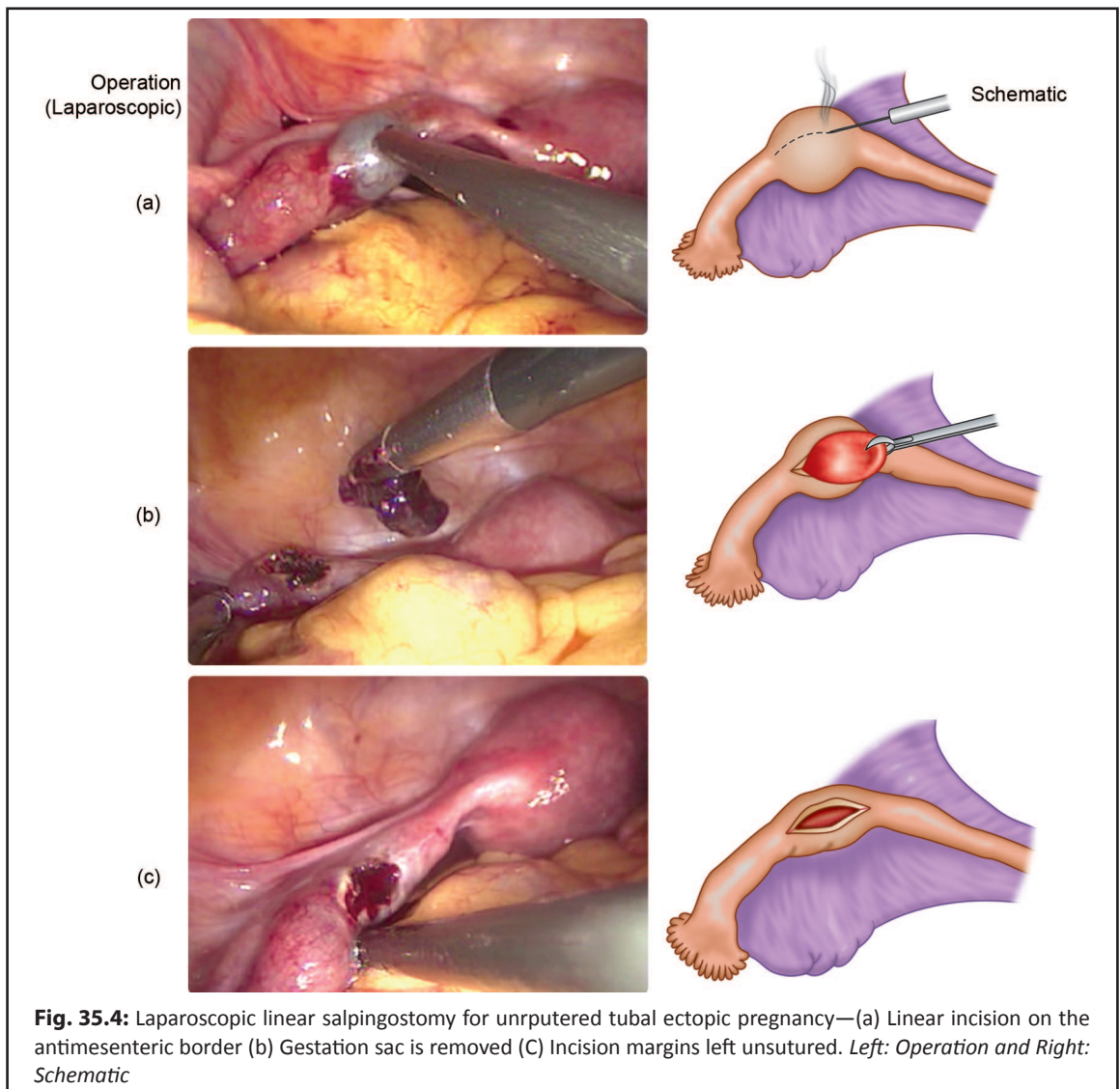
to the extent of surgery and also to the competence of the surgeon. They are labelled as follows:

A. Diagnostic laparoscopy (see p. 121)

B. Therapeutic (operative) laparoscopy

#### ■ **Minor procedures**

- ◆ Tubal sterilization (see p. 496, Fig. 35.8).
- ◆ Adhesiolysis (without bowel involvement) (Fig. 35.7)
- ◆ Aspiration of simple ovarian cysts.
- ◆ Ovarian biopsy.





### ■ **Moderate procedures (Fig. 35.4)**

Ectopic pregnancy:

- ◆ Salpingostomy—(Fig. 35.4)
- ◆ Segmental resection
- ◆ Salpingectomy
- ◆ Salpingo-oophorectomy

Endometriosis: Ablation by diathermy or laser.

*Ovary*

- ◆ Diathermy for PCOS (Fig. 35.6)
- ◆ Drainage of endometriomas
- ◆ Ovarian cystectomy
- ◆ Salpingo-ovariolysis (Fig. 35.7).

*Uterus*

- ◆ Myomectomy
- ◆ Laparoscopic assisted vaginal hysterectomy (LAVH)
- ◆ Adhesiolysis – including bowel involvement (Fig. 35.7)

### ■ **Extensive procedures**

- ◆ Major endometriosis
- ◆ Myomectomy
- ◆ Retroperitoneal lymphadenectomy
- ◆ Hysterectomy
- ◆ Urinary incontinence
- ◆ Sacrocolpopexy.

### **Contraindications (Table 35.1)**

One should be familiar with the contraindications to maximize the patient safety and minimize the procedure related morbidity.

**TABLE 35.1**

#### **CONTRAINDICATIONS OF LAPAROSCOPY**

- ◆ Severe cardiopulmonary disease
- ◆ Patient hemodynamically unstable
- ◆ Generalized peritonitis
- ◆ Significant hemoperitoneum
- ◆ Intestinal obstruction
- ◆ Extensive peritoneal adhesion
- ◆ Large pelvic tumor
- ◆ Pregnancy > 16 weeks
- ◆ Advanced malignancy
- ◆ Anticoagulation therapy.

### **OPERATIVE PROCEDURES FOR LAPAROSCOPY**

Preoperative screening is essential and contraindications are excluded (see Table 35.1). Informed consent is taken and it should include the permission for open surgery if necessity arises. **General anesthesia** is generally preferred. There is significant hemodynamic changes during laparoscopy due to—(a) raised intra-abdominal pressure (CO<sub>2</sub> insufflation), (b) head-down position, (c) lung compression due to pneumoperitoneum and bradycardia due to vagal stimulation (visceral manipulation). Cardiac output may fall by 10–30 percent. Procedures like sterilization could be performed under local anesthesia. The operating table should have the facilities for rotating at different angles. Low lithotomy position of the patient with buttocks protruding slightly from the edge of the table is used.

### **SURGICAL TECHNIQUES**

- ◆ Patient positioning
- ◆ Production of pneumoperitoneum
- ◆ Introduction of trocar and cannula
- ◆ Introduction of laparoscope
- ◆ Creation of accessory ports
- ◆ Surgical procedures to carry out
- ◆ Deflation of the peritoneal gas
- ◆ Closure of the parietal wound (ports).

**Position of patient:** The patient is placed in lithotomy position. The buttocks are at the edge or slightly over the table's edge. Sterrups should have ample padding to support the lower leg. Head end of the patient is lowered (Trendelenburg 15–30°) after insertion of the primary trocar. This is done to displace the bowel out of the pelvis. For good view and hand-eye coordination, both for the surgeon and the assistants, the video monitor is placed at the foot end of the table. The electrosurgical unit and the suction irrigator should be placed behind the surgeon or assistant. The bladder is emptied by a Foley's catheter. Pelvic examination is done methodically. An uterine manipulator is introduced through the cervical canal for manipulation to visualize the tubes and uterus at a later step.

**Pneumoperitoneum:** A small skin incision (1.25 cm) is made just below the umbilicus. The veress needle is introduced through the incision with 45° angulation into the peritoneal cavity. The abdomen is inflated with about 1L–4L of gas (carbon dioxide). But for diagnostic purposes nitrous oxide

or room air or oxygen can be used. Symmetrical distension of abdomen with loss of liver dullness is suggestive of proper pneumoperitoneum. Volume of gas varies from 1L-4L depending upon the patient. But in any case intra-abdominal pressure should not exceed 20 mm Hg. The flow rate of the gas is about one liter per minute with a pressure not exceeding 20 mm Hg. Otherwise this interferes with diaphragmatic excursion and venous return due to caval obstruction.

### Correct placement of veress needle is verified by:

- Hanging drop method**—a small amount of sterile saline is placed on the top of the veress needle. The saline drops in the peritoneal cavity while there is negative intra-peritoneal pressure.
- Syringe barrel test**—a 10 mL syringe with normal saline is attached to the veress needle. Aspiration is done to rule out blood or bowel contents. The saline is then pushed down and aspiration is again done. If the needle placement is correct, the fluid cannot be withdrawn as it goes in the peritoneal cavity.
- Intra-abdominal** pressure is low (<10 mm Hg) on correct placement and there is free flow of gas.
- Obliteration of liver dullness** (on percussion).

### Other possible sites of veress needle insertion:

- Left subcostal margin [3 cm below in midclavicular line—**Palmer's point**]. Stomach must be decompressed and splenomegaly to be ruled out.
- Transvaginal—through the pouch of Douglas.

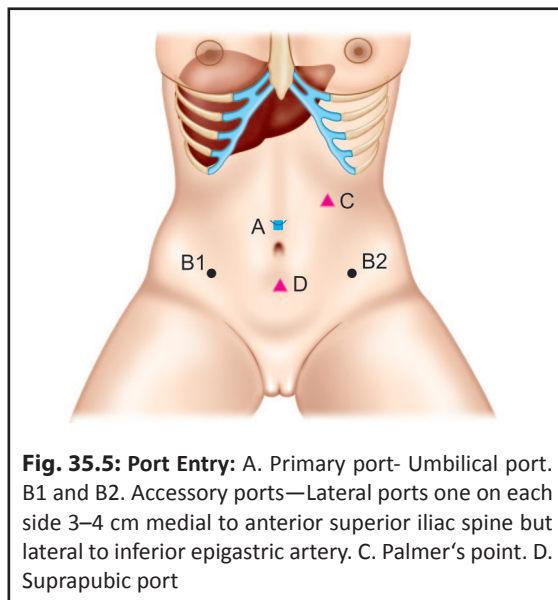
### Laparoscopic Insufflator

**Operative laparoscopic procedures** needs high flow. Automatic sensors of the **insufflator** shut off gas flow when the intra-abdominal pressure reaches 15 to 20 mm Hg.

**Port Entry (Fig. 35.5):** Peritoneal cavity is entered through three main sites: (i) At the umbilicus (most common). (ii) Suprapubic (2-4 cm above). (iii) **Palmer's point** (midclavicular line) on the left. In obese patients the needle is inserted more vertically.

### Introduction of Trocar and Cannula

The abdominal wall is elevated and the trocar with cannula is inserted through the same incision. The angle of insertion is similar to that of the veress needle, directing towards the hollow of the sacrum. There is escape of gas when the trocar is within the peritoneal cavity. The trocar is removed and the laparoscope is then introduced. **Open laparoscopy** was introduced (Hasson-1971) to reduce the risk of blind insertion of the veress needles and trocars.



**Fig. 35.5: Port Entry:** A. Primary port- Umbilical port. B1 and B2. Accessory ports—Lateral ports one on each side 3–4 cm medial to anterior superior iliac spine but lateral to inferior epigastric artery. C. Palmer's point. D. Suprapubic port

Peritoneal cavity is opened through a small incision (1 cm) at the umbilicus pneumoperitoneum is done through a special cannula inserted in the incision. The laparoscope is then introduced.

**Secondary trocar insertion** is needed for both the diagnostic and operative procedures (see Fig. 35.5). Sites selected are either on the flank (3–4 cm lateral to the medial umbilical ligament) or lateral to the lateral margin of rectus abdominis muscle or on the suprapubic region. This is done under direct vision with illumination to avoid trauma to abdominal organs and the inferior epigastric vessels.

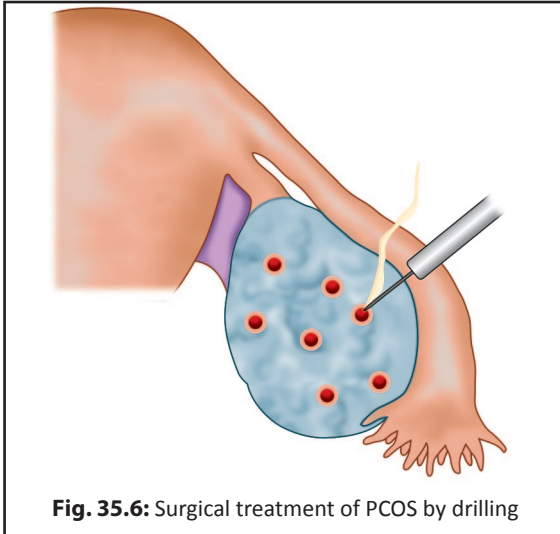
**Laparoscopic procedures of tissue dissection:** (i) Blunt dissection. (ii) Sharp dissection (using scissors). For control of bleeding, bipolar diathermy is used for hemostasis. (iii) Aquadissection with hydraulic pressure is used to create tissue planes. (iv) Electrodissection using unipolar or bipolar diathermy for dissection and coagulation. (v) Laser dissection (see p. 123). (vi) Harmonic scalpel.

**Methods of hemostasis** (see p. 613).

**Removal of specimens:** Large volume of tissues after laparoscope could be removed by any of these methods: (i) Morcellation. (ii) By enlarging any of the suprapubic trocar incision site. (iii) Through the colpotomy incision. The specimen is put in a EndoCatch bag and is taken out without spilling.

### Examination of the Pelvis

After introduction of the laparoscope, a systematic inspection of the pelvic and abdominal organs is done. The patient is put to Trendelenburg position for proper visualization of the pelvic organs.



**Fig. 35.6:** Surgical treatment of PCOS by drilling

**Visualization:** Diagnostic procedures may be performed with direct optical visualization. Operative procedures are carried out with video camera (Fig. 35.12).

## OPERATIVE LAPAROSCOPY

■ **Tubal sterilization with single puncture technique:** The various operative techniques of laparoscopic procedures are beyond the scope of the book. As the laparoscopic sterilization is commonly done, this procedure is described in p. 496 (Fig. 35.6).

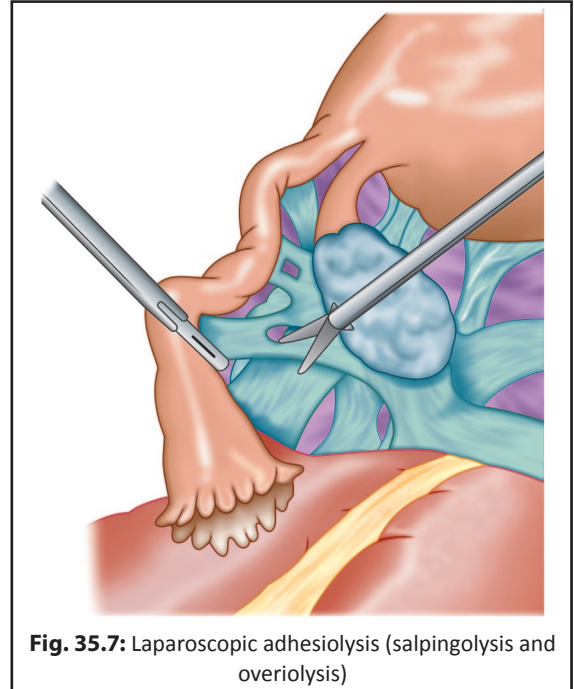
■ **Total Laparoscopic Hysterectomy (TLH)**

Uterus is freed of all its attachment laparoscopically. The uterus is removed either vaginally or abdominally following morcellation. Vagina is closed with sutures laparoscopically (details see below).

■ **Laparoscopic Assisted Vaginal Hysterectomy (LAVH): See below**

**Benefits of laparoscopy prior to vaginal hysterectomy are:** (i) Diagnosis of any other pelvic pathology. (ii) Adhesiolysis or excision of

endometriosis. (iii) Adnexae is freed laparoscopically. (iv) Dissection of bladder from uterus. (v) Desiccation and transection of uterine artery (vi) Entire uterus may be freed from its attachments.



**Fig. 35.7:** Laparoscopic adhesiolysis (salpingolysis and overiolysis)

## PROCEDURE OF LAPAROSCOPIC HYSTERECTOMY

Three or four puncture sites are made. One 10 mm umbilical port is used for the laparoscope, connected to the video camera. Three other secondary ports are made, each of 5 mm size (see p. 612). Two of them are placed on the ipsilateral side and the third on the opposite side. These are placed lateral to the inferior epigastric artery or in the mid-line above the bladder. The left lower puncture is the major portal for operative manipulation. The right is used for retraction with atraumatic grasping forceps.

**Bipolar coagulation** or **Harmonic Scalpel** are used to transect pelvic ligaments and to achieve hemostasis. Bipolar coagulation desiccates the blood vessels. Scissors are used to transect the pedicles following coagulation. The round ligament, infundibulopelvic ligament are similarly coagulated and transected. Sutures, staples or clips can also be

used. The leaves of the broad ligament are opened up with the scissors. The peritoneum of the vesicouterine pouch is dissected with the scissors. Hydrodissection may be used to develop the space.

**LAVH**, the laparoscopic procedure is stopped at this point. The rest of the operation is completed vaginally. Uterine vessel ligation is done from below. This is exactly the same as that of vaginal hysterectomy (see p. 220).

### Total Laparoscopic Hysterectomy (TLH)

Dissection is continued to expose the uterine vessels. After careful identification of the uterine vessels and the ureter, the uterine vessels are desiccated using bipolar diathermy and then cut. Harmonic Scalpel use causes coagulation and cutting simultaneously.

Uterus is then freed from the rest of attachment. The cardinal ligaments on each side are divided. Colpotomy device and vaginal occluding device (Colpotomizer system) help to detect the site of colpotomy and maintain pneumoperitoneum simultaneously. Wet laparotomy sponge may be placed in the vagina for this purpose. Vagina is transected using monopolar energy or by harmonic. Bipolar cautery is used for hemostasis. The specimen

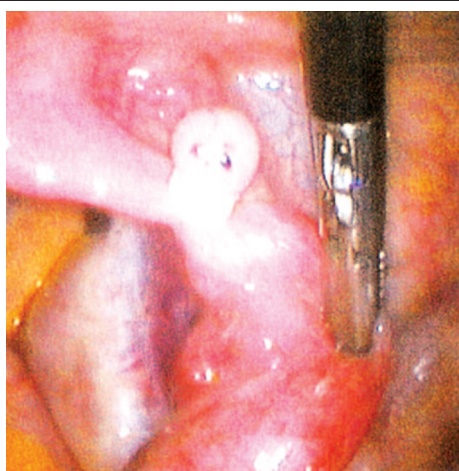
is removed (*see above*). Vaginal vault is closed. Extra corporeal sutures may be used.

After completion of the procedure, laparoscope is used to check the pelvis for hemostasis. Peritoneal cavity is irrigated with Ringer's lactate solution and suctioned until clear fluid is obtained. Bleeding vessels are coagulated. 500 mL of Ringer's solution are left in the peritoneal cavity. The laparoscopic instruments are then removed and the pneumoperitoneum is deflated. The trocar incisions (ports) are closed.

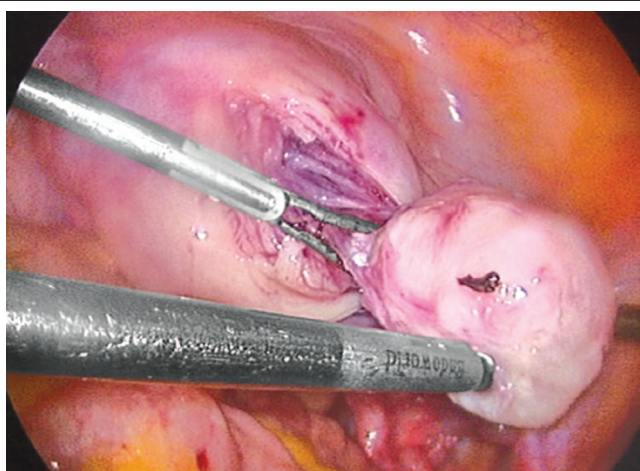
### Postoperative Care

General postoperative care is similar to any other major gynecological surgery. Care specific to laparoscopic hysterectomy are:

- Prophylactic antibiotics** are used in a case of hysterectomy (p. 584)
- Laparoscopic ports** should be kept clean and dry for next 7–10 days.
- Diet** may be started by next 12 hours.
- Discharge:** Patient may be discharged by next 48–72 hours.
- Daytoday physical activity** may be started by 10–12 days time.
- Intercourse should be** avoided for next 6 weeks.



**Fig. 35.8:** Laparoscopic view showing tubal sterilization with silastic (Fallope) rings



**Fig. 35.9:** Laparoscopic myometomy. Myoma screw (Fig. 35.3C) is used for traction of the myoma (Courtesy: Dr. Parul Kodtawala, Ahmedabad)

## COMPLICATIONS OF LAPAROSCOPY

Complications are grouped into: (i) specific to laparoscopy itself, (ii) due to anesthesia, (iii) common to any surgical procedures.

### ■ Complications due to laparoscopy itself:

- (1) Extraperitoneal insufflation
  - (a) Surgical emphysema
  - (b) Omental emphysema
  - (c) Cardiac arrhythmia
- (2) Injury to blood vessels—mesenteric, omental, injury to major pelvic or abdominal artery or vein. Inferior epigastric vessels may be injured during insertion of accessory trocars.
- (3) Injury to bowel—with veress needle or trocar especially when there is adhesions.
- (4) Injury to organs like bowel, bladder or ureter. Damage may be mechanical during dissection or thermal by electrical or laser energy.
- (5) Electrosurgical complications—causing thermal injury (electrode burns, insulation defects).
- (6) Gas (carbon dioxide) embolism—resulting in hypotension, cardiac arrhythmia.

### ■ Anesthetic complications peculiar to laparoscopy are:

- (1) Hypoventilation (pneumoperitoneum and Trendelenburg position lead to basal lung compression and reduced diaphragmatic excursion).
- (2) Hypercarbia and metabolic acidosis (when CO<sub>2</sub> is used for pneumoperitoneum).
- (3) Basal lung atelectasis.
- (4) Others—esophageal intubation, aspiration and cardiac arrest.

### ■ Complications common to any surgical procedure

- |                      |                       |
|----------------------|-----------------------|
| (1) Hemorrhage       | (2) Infection         |
| (3) Wound dehiscence | (4) Port site hernia. |

Death rate in diagnostic laparoscopy is about 5/100,000 procedures. With experience, the fatality is markedly reduced to even zero. **Causes of death are** cardiac arrest, gas embolism and consequences of intestinal injury.

**ROBOTICS:** Robotic surgical system allow the surgeon to operate from a distant station. Two robotic arms filled with instruments works inside patient's abdomen. These arms have 360° range of movement. It has the advantage of increased dexterity, minimum fatigue, tremors or incidental hand movement. It is expensive and needs training.

## HYSTEROSCOPY

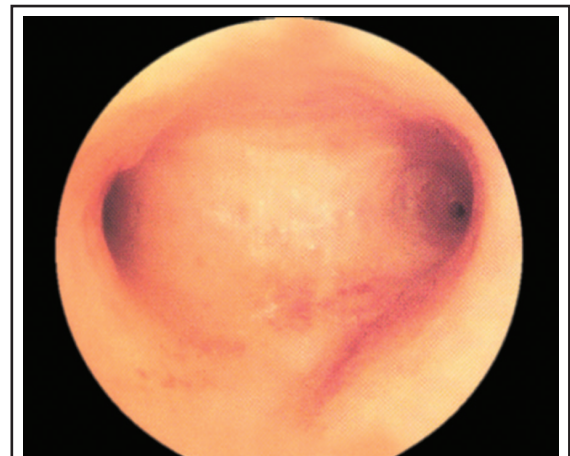Hysteroscopy is a procedure that allows direct visualization inside the uterus (Fig. 35.10). It can be used for diagnostic as well as therapeutic purposes (Fig. 35.12).

### Basic Instruments and Electrosurgical Units for Hysteroscopic Surgery (Fig. 35.11)


**Telescope**—Rigid telescopes are commonly used. The telescope may be either straight on (forward view) (0°) or fore oblique view 30°, 70° or 90°.

**Flexible telescopes**—The tip of the hysteroscope can bend up to 110°. It has the advantage of easy uterine entry through the angle between cervix and uterus. It helps easy aligning the catheter for tubal cannulation (Fig. 35.10).

**Microhysteroscope** acts as a high powered microscope by switching the lens to 150X. Light contact with the mucous membrane is needed.



**Fig. 35.10:** Panoramic view of the uterine cavity with a hysteroscope. Tubal ostium is seen one on either side



**A**  
**Fig. 35.11A:** (A) Hysteroscope

**B**  
**Fig. 35.11B:** Hysteroscope with working element for operative interventions (outer diameter: 8 mm)

**Telescope sheath**—A sheath is required to introduce the telescope. Sheath used for diagnostic purposes are smaller (5 mm) than that for operative sheath (7–10 mm). Operative instruments are introduced through the sheath. Operative hysteroscopy needs separate inflow and outflow sheaths. The inflow sheath carries the distension medium to the tip of the telescope, from where it is withdrawn via the outer sheath. This helps to maintain the clear view.

**Distending media**—The uterine cavity is distended with a media to separate the uterine walls and to have a panoramic view. The media used could be either a gas or a liquid.

**Carbon dioxide (CO<sub>2</sub>)**—is commonly used for diagnostic purposes. It is soluble in blood and is safe.


Hysteroflator provides gas flow rate of maximum 100 mL per minute and a maximum pressure of 100 mm Hg.

**Liquid media** is used for operative procedures.

**Normal saline** can be used but not suitable for monopolar electrosurgery. Constant flow is to be maintained to flush the operative area.

**Glycine 1.5 percent** is used in many centers for excellent visualization. It is hypoosmolar. Resectoscope (monopolar electrosurgery) can be used as it does not conduct electricity. Fluid can be pressurized via a roller pump or by a pressure infusion bag cuff system with a maximum flow rate of 100 mL/min and maximum pressure of 100 mm Hg.

**Mannitol (5%) and Glycine (2.2%)** are Iso-osmolar, so can be used safely. They can be used with electrosurgical devices also.



**C**  
**Fig. 35.11C:** Resectoscope (with an angled cutting loop)

While using liquid distension media, volume of fluid instilled, volume of return fluid and the fluid deficit must be calculated. Significant fluid deficit (Saline 1.5-2L) warns the surgeon to discontinue the procedure. Glycine: A fluid deficit of  $\geq 500$  ml, may cause hyponatremia and hypo-osmolar state.

**A fluid deficit of ( $\geq 500$  ml is alarming to prevent hyponatraemia and hypo-osmolality. Deficit of  $\geq 1L$ , require measurement of serum electrolytes and diuretic (frusemide) therapy.**

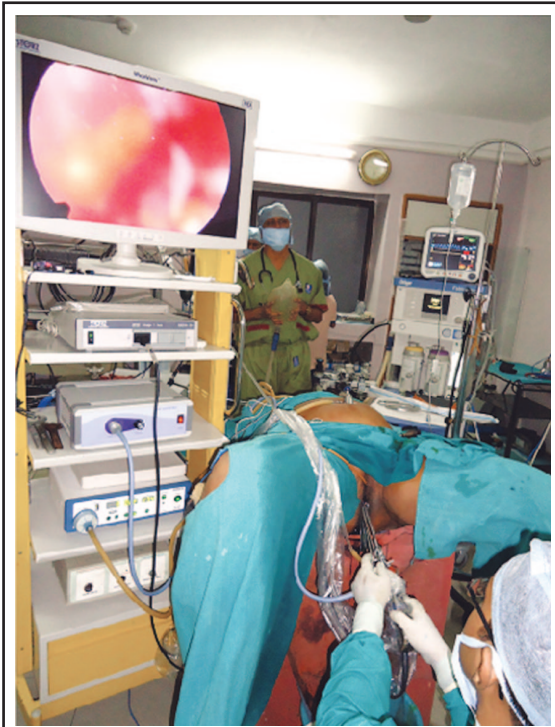A pressure of about 50-70 mm Hg is required for adequate distention of the uterine cavity. This pressure should not exceed the mean arterial pressure to avoid extravasation.

**Accessory instruments are:** scissors, forceps, grasping forceps (Fig 35.3) Monopolar and bipolar electrodes (a ball, needle or cutting loop) are used for operative hysteroscopy.

**Image-recorder**—recorded images are useful as teaching aids to the trainees. They can also be used as an evidence (in defense) for medicolegal purpose.

**Camera:** The hysteroscopic image is visualized on the monitor with the help of a camera. The camera used for laparoscopy can also be used. The monitor is checked before hand for visualization of appropriate image. A high resolution camera and color monitor is required for both the surgeon and the assistants.

**Light source:** Xenon or mercury halide can provide high intensity light sources for excellent illumination.



**Fig. 35.12:** Hysteroscopic procedures in progress

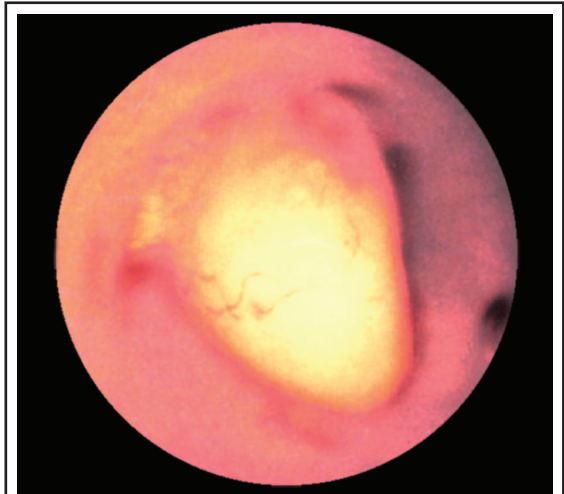
### Anesthesia and Procedures

**Diagnostic procedures**—are carried out as an outpatient under paracervical block with 1 percent xylocaine (10–15 mL). Initial steps are same as in dilatation and curettage p. 585. Telescope inserted within the diagnostic sheath, is gradually inserted through the cervical canal while the light is on. The distension media is flushed through the sheath. Uterine cavity is evaluated thoroughly with a closer view at fundus, lateral, anterior, posterior walls and the tubal ostia. Endocervical canal is seen while withdrawing the hysteroscope from the uterus.

**Operative procedures**—are carried out under general anesthesia or regional anesthesia (spinal or epidural).

#### INDICATIONS OF DIAGNOSTIC HYSTEROSCOPY

- (a) **Abnormal uterine bleeding:**
  - ◆ Menorrhagia (Fig. 35.13).
  - ◆ Postmenopausal bleeding (see p. 559).



**Fig. 35.13:** Hysteroscopic view of a submucous fibroid

- (b) **Infertility**—when associated with abnormal hysterosalpingogram (filling defect, synechiae).
- (c) **Müllerian anomalies** like arcuate, subseptate, septate, bicornate uterus or uterus didelphys can be diagnosed with hysteroscopy. The procedure is combined with laparoscopy for confirmation.
- (d) **Recurrent miscarriage:** Intrauterine pathology such as fibroids, polyps, Asherman's syndrome (see Fig. 37.73) can be diagnosed and treated.
- (e) **Misplaced IUD** (see Fig. 29.6).
- (f) **Chronic pelvic pain** due to obstructive uterine anomaly, fibroids, bicornuate uterus may be diagnosed. Laparoscopy is done to exclude other pelvic pathologies.
- (g) **Transformation zone** (p. 322) could be visualized with colpomicrohysteroscopy.
- (h) **Hemangioma** and arterio venous malformation—diagnosis.

#### INDICATIONS OF OPERATIVE HYSTEROSCOPY

- (a) **Polypectomy** and myomectomy.
- (b) **Lysis** of intrauterine adhesions (synechiolysis).
- (c) **Endometrial ablation** (laser or roller ball) for patients suffering from DUB (see p. 195).

- (d) **Endometrial resection**—where endometrium is excised using a resectoscope (Fig. 14.4) for patients with DUB (p. 195).
- (e) **Metroplasty** (resection of uterine septum) Fig. 35.14.
- (f) **Removal** of foreign body or IUD, when the thread is missing.
- (g) **Biopsy** of suspected endometrium under direct vision.
- (h) **Tubal cannulation**—under hysteroscopic guidance can release any proximal tubal obstruction (due to mucous plugs or spasm). A special catheter is passed through the tubal ostium up to the interstitial part of the tube.
- (i) **Sterilization**—by destroying the interstitial portion of the tubes using Nd:YAG laser or electrocoagulation or for insertion of Essure (p. 501).
- (j) **Laser coagulation** of endometrial hemangioma and arteriovenous malformation in cases with unresponsive bleeding.

#### Pretreatment Evaluation and Protocol

- ▶ It should preferably be done in the postmenstrual phase with normal sized uterus.
- ▶ Should be preceded by diagnostic hysteroscopy.
- ▶ Pretreatment with danazol, GnRH analogue or progestogen for 4-6 weeks to make the endometrium thin prior to endometrial ablation/resection.

#### LEVELS OF HYSTEROSCOPIC PROCEDURES (RCOG 1994)

##### ■ Level 1. (Diagnostic procedures)

- ◆ Diagnostic hysteroscopy plus target biopsy.
- ◆ Removal of simple polyp.
- ◆ Removal of IUCD.

##### ■ Level 2. (Minor operative procedures)

- ◆ Fallopian tube cannulation (proximal)
- ◆ Minor Asherman's syndrome
- ◆ Removal of pedunculated fibroid or large polyp.

##### ■ Level 3. (Complex operative procedures)

- ◆ Resection of uterine septum
- ◆ Major Asherman's Syndrome
- ◆ Transcervical resection of endometrium (TCRE)
- ◆ Resection of submucous leiomyoma

#### CONTRAINDICATIONS OF HYSTEROSCOPY

- ▶ **Pelvic infection:** Hysteroscopy can cause spread of infection. The distension media flowing through the tube spreads the infection in the peritoneal cavity.
- ▶ **Pregnancy:** However, hysteroscopy can be done to remove an IUCD when the threads are missing.
- ▶ **Cervical cancer:** Trauma to the friable cervix can cause excessive bleeding.
- ▶ **Cardiopulmonary disorders** are at higher risk of anesthesia as hysteroscopy carries its own risk of gas embolism, fluid overload and pulmonary oedema (see p. 619).
- ▶ **Cervical stenosis:** Can cause cervical trauma. PGE<sub>2</sub> gel inserted 2 hours before surgery, softens the cervix and help easy dilatation.

#### OPERATIVE HYSTEROSCOPY

**Transcervical resection of endometrium (TCRE) or laser ablation of endometrium (LAE)** is done as an alternative to hysterectomy for dysfunctional uterine bleeding.

**Principle** of this operation is to destroy the endometrium up to a depth of 3–5 mm. There would be no further regeneration of endometrium as the basal layer of endometrium as well as the basal and spiral arterioles are destroyed.

**Procedure:** Endometrial resection is done from cornu to cornu (fundus) and all the walls. Ablation is not needed below the level of the internal os. TCRE or LAE is completed by about 30 minutes time and patient can go home on the same day.

Total resection or ablation of endometrium should result in amenorrhea. **Selection of the patient** is very important. Presence of pelvic pain is a contraindication. Before TCRE or LAE endometrium



is suppressed using danazol or GnRH analogue for 4–6 weeks (see p. 534). Therapeutic response following TCRE or LAE has been observed in 80–85 percent of cases (see p. 196).

### HYSTEROSCOPIC MYOMECTOMY

It is done for submucous myomas as an alternative to hysterectomy or laparotomic myomectomy for a patient with intractable symptoms.

**Indications:** (i) Infertility (ii) Menorrhagia.

#### Classification of intrauterine myomas (European Society of Hysteroscopy)

**Grade (G):** Degree of intramural development of myoma.

**G0:** Myoma, limited to uterine cavity (pedunculated).

**G1:** Myoma, endocavitary component > 50%.

**G2:** Myoma, endocavitary component < 50%.

**Surgical technique:** Preoperative GnRH agonist therapy is used (p. 525). Resectoscope is normally used for myoma resection. Electro surgical working element with 90° cutting loop (Fig. 35.11) is usually used to shave off any submucous leiomyoma (Fig. 19.8). Myometrium is desiccated through contact coagulation for 30–40 seconds to control bleeding. Bleeding can also be controlled using roller ball coagulation. Uterine tamponade with the inflated bulb of a Foley Catheter is also effective.

**Common complications are:** Uterine perforation and hemorrhage (see below).

### COMPLICATIONS OF HYSTEROSCOPY

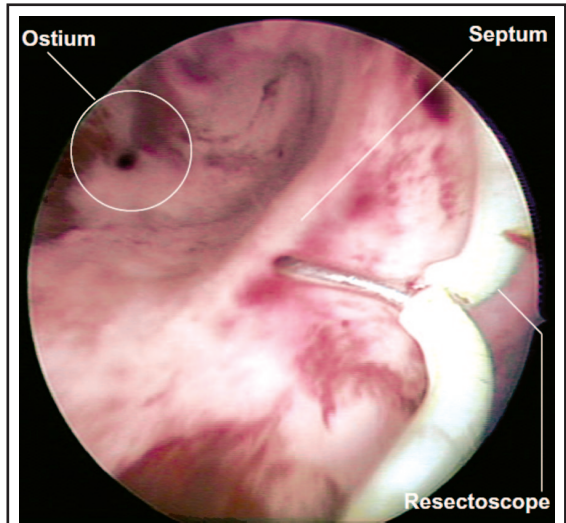
Complications may arise from any of these following:

- ◆ Peroperative
- ◆ Late

#### Peroperative Complications

##### (A) Distension media:

- ◆ Fluid overload.
- ◆ Pulmonary edema, cerebral edema.
- ◆ Hyponatraemia.



**Fig. 35.14:** Patient with complete septum. Resection of the septum is being done using the resectoscope

- ◆ Neurological symptoms.
- ◆ Ammonia toxicity due to excess glycine absorption.
- ◆ Embolism (CO<sub>2</sub>).

##### (B) Operative procedures

- ◆ Uterine perforation.
- ◆ Hemorrhage—intraoperative or postoperative.
- ◆ Injury to intra-abdominal organs.

##### (c) Electrosurgical—Thermal injury to intra-abdominal organs due to laser or electricity.

##### (d) Others—Infection, anesthetic complications and treatment failure.

#### Late Complications

1. **Abnormal uterine bleeding** due to failure of TCRE especially in the young age group.
2. **Hematometro and pyometers**—may occur due to infection after hysteroscopic surgery with cervical stenosis. Ablation near internal os level should not be done.
3. **Pregnancy**—may occur following TCRE (rare).

**KEY POINTS**

- ▶ Endoscopy is the procedure to visualize the interior of a viscus or space with the use of a telescope. In gynecology as much as 80 percent of operations can be performed endoscopically with the use of either a laparoscope or a hysteroscope.
- ▶ During laparoscopy, the magnification of the object depends upon the distance of the laparoscope from the object. With 'Storz' it is nearly 10 times when working distance is 3 mm and is 1 when the distance is 30 mm.
- ▶ Laparoscopic surgery could be diagnostic (see p. 121) or therapeutic (see p. 617). Before any procedure is undertaken, contraindications must be carefully excluded (Table 35.1). Informed consent should include the permission for open surgery if necessity arises.
- ▶ Hemostasis during laparoscopic surgery can be achieved using electrocoagulation (monopolar/bipolar), laser coagulation, ligatures, sutures(extracorporeal/intra-corporeal), enseal, harmonic scalpel or by stapler and clips. (p. 613)
- ▶ Thermal damage caused by electrosurgery or laser depends on the degree of heat applied to the tissues. Tissue damage with heat is as follows: 45°C = Tissue death; 70°C = Coagulation; ≥ 90°C = Desiccation; ≥ 100°C = Vaporization; ≥ 200°C = Carbonization (charring).
- ▶ Laparoscopic tubal sterilization is the commonest surgical procedure. In LAVH the uterine arteries are clamped and secured through vaginal route. In TLH (p. 617) entire procedure is done laparoscopically.
- ▶ Complications of laparoscopy may be due to the procedure itself or due to anesthesia (see p. 619).
- ▶ Hysteroscopy is superior to HSG . The distending media commonly used in hysteroscopy is normal saline or glycine (1.5 %).
- ▶ The contraindications (see p. 622) of hysteroscopy are pelvic infection, pregnancy and active uterine bleeding. Complications include fluid overload, pulmonary edema, and injury to genital or abdominal organs or electrosurgical injuries (see p. 623).
- ▶ Hysteroscopic surgery should be done in the postmenstrual phase. Pretreatment with danazol or GnRH analogue for 4-6 weeks facilitate endometrial ablation or resection.

# Current Topics in Gynecology

## STEM CELLS AND THERAPIES IN GYNECOLOGY

Reproductive tissues are the important source of stem cells (progenitor cells). Stem cells have the potential to be used in the field of regenerative medicine.

### Potentials for the Use of Stem Cells in Regenerative Medicine

1. Treatment of inherited genetic disorders.
2. Treatment of hematological diseases.

A stem cell has the ability to renew (reproduce) itself for long periods.

### Properties of Stem Cells

- a. Ability to self renew (undergoing numerous cell divisions) maintaining the undifferentiated state.
- b. Multipotency: Capacity to differentiate into a mature cell type.

**Totipotent Stem Cells** are produced by first few divisions of the fertilized egg cell. Totipotent stem cells (from the morula) can differentiate into embryonic and extraembryonic cell types. Totipotent cells can produce a complete and viable organism.

**Pleuriptent Stem Cells** are descendent of totipotent cells. These cells can differentiate on tissues derived from any of the three germ layers including fetal tissues (placenta, umbilical cord, amnion, amniotic fluid cells).

**Embryonic Stell Cells** are pluripotent. These cells are derived from the inner cell mass of a blastocyst.

**Multipotent Stem Cells** can differentiate into various tissues originating from a **single germ layer** (mesenchymal cells or hemopoietic stem cells that produce red blood cells, white blood cells, platelets).

**Unipotent cells** produce only their own cell type. They have greater self-renewal property than fully mature cells.

Theoretically, the more primitive or 'potent' stem cells are, the potential for uncontrolled cell division is more strong. Unfortunately the potential for oncogenesis is also high. It is the major concern about the oncogenic potential of pleuriptent stell cells (embryonic stem cells). Nonpleuriptent cells source are not inherently oncogenic.

**Embryonic Stem (ES) Cells** have the potentials to be used in regenerative medicine.

**Multipotent Stem Cells** can be obtained from several fetal tissues (following medical termination of pregnancy or at birth).

## USE OF EMBRYONIC STEM (ES) CELLS IN REGENERATIVE MEDICINE

### Gynecology:

#### ◆ Regeneration of urogenital tract tissues

##### ◆ Treatment of stress urinary incontinence (SUI)

Currently SUI is treated by mechanical support to the bladder (TOT) (See p. 404) Biomaterials (autologous stem or urethral tract progenitor cells) are injected into the utethral sphincter. This is aimed to restore and regenerate rhabdomyosphincter muscle content and function. These autologous cells commonly integrate into the sphincter complex. These cells then differentiate and ultimately lead to sphincter regeneration. This ongoing research might be of immense benefits in regenerative medicine.

##### ◆ Bladder reconstruction

- i. Acellular natural or synthetic biomaterials are used as an implant which becomes incorporated through ingrowth of cells from the adjacent native host cells of the bladder. The biomaterials used are: Small intestinal submucosa and bladder-derived acellular matrix.

- ii. Implantation of scaffolds (cell-seeded collagen-coated PGA scaffolds) pre-incubated with autologous cells (wrapped in omentum within a vascular bed). Reports are available indicating possibility of creating full thickness bladder wall.

◆ **Biomaterials** can be used for the use of pelvic organ prolapse (POP) and urinary incontinence. The purpose is to generate new muscles/tissues which can perform in an integrated manner with the existing tissues to provide mechanical support to the pelvic organs. Currently synthetic meshes are used for POP and SUI. Mesh erosion, infection are the known complications. Hybrid biomaterials (synthetic and naturally-derived polymers) may be fabricated to restore pelvic floor

function and cure of SUI. Biomaterials should have good biocompatibility and appropriate biomechanical and biochemical properties.

#### ◆ **Müllerian ducts reconstruction**

- ▶ Progenitor cells with ability of self repair (bone marrow stem cells) can be used for uterine malformations.
- ▶ Autologous cells (from vaginal biopsy) can be expanded and functional vagina can be reconstructed for a woman with vaginal agenesis.


However, till date it is essential to understand its known limitations, putative benefits and the unknown risks. Until there is sufficient evidence on the efficacy of therapy, each case should be considered on an individual basis.

# Practical Gynecology

- Instruments    ■ Specimens
- Imaging Studies  
(X-ray, USG, CT, MRI Plates)

## INSTRUMENTS

### ■ SPATULA AND CYTOBRUSH (FIG. 37.1)



**Fig. 37.1:** Spatula (top) and cytobrush (bottom)

Ayre's spatula (wooden or plastic) and the endocervical brush are used for collection of cells for cytology screening.

#### PROCEDURE

- ◆ **For cervical cells**—Projected end of the spatula goes within the external os. The spatula is rotated 360° to collect cells from the entire ectocervix [see Fig. 9.16(ii)].
- ◆ **For endocervical cells**—The cytobrush goes within the cervical canal and is rotated to collect cells [Fig. 9.16(iii)].
- ◆ **For cytochemical study (p. 110)**, the rounded end of the spatula is used [Fig. 9.16(i)].

**Self-assessment: Q. How do you prepare the slide?**

**Ans.** The material so collected is immediately spread over a slide. Fixative (95% ethyl alcohol) is spread over it. Once dried up, the slide is then stained (in the laboratory) either with Papanicolaou or Sorr's method. It is examined under the microscope by a cytopathologist.

**Q. Who are the women (at risk), that they need cervical cytology screening?**

- Ans.**
- Any sexually active women over 21 years and up to 70 years of age.
  - Others: (see p. 111).

**Q. What is the grading of Papanicolaou's smear?**

**Ans.** Grading is total five: Normal, infective, suspicious, few malignant cells and plenty of malignant cells (p. 112).

**Q. What is a dyskaryotic smear? What are the different types of dyskaryotic smear?**

**Ans.** Dyskaryosis is the morphological abnormalities of the nucleus. Abnormalities may be nuclear enlargement in size and shape, irregularity in outline, multinucleation and hyperchromasia. Dyskaryotic smear may be: (i) Mild, (ii) Moderate and, (iii) Severe (p. 111).

**Q. What is Koilocytosis?**

**Ans.** It is the nuclear abnormalities observed in HPV infection. The typical changes are: Perinuclear halo, nuclear irregularity, hyperchromasia and multinucleation (Fig. 22.4).

**Q. What is CIN? How do you diagnose CIN?**

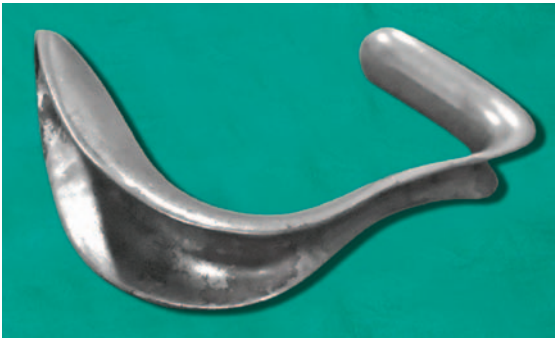**Ans.** It is the histological observation where part or whole of thickness of cervical squamous epithelium is replaced by cells with varying degree of atypia. Basement membrane remains intact. Diagnosis of CIN is made by: (i) Cytology, (ii) VIA, (iii) Colposcopy, (iv) Cervicography, (v) Biopsy and, (vi) Conization of cervix (p. 589).

**Q. How do you manage a case of CIN?**

**Ans.** (a) Local ablative methods. (b) Excisional methods (LLETZ) or by (c) Hysterectomy (scheme 3).

■ **SIMS' DOUBLE BLADED POSTERIOR VAGINAL SPECULUM (FIG. 37.2)**

The instrument was designed by Marion Sims. The blades are of unequal breadth. The use of one is dependent on the calibre of the vagina. It may be single bladed.



**Fig. 37.2:** Sims' speculum

■ **CUSCO'S BIVALVE SELF-RETAINING VAGINAL SPECULUM (FIG. 37.3)**



**Fig. 37.3:** Cusco's speculum

**Q. What is the Bethesda System classification for cervical cytology?**

**Ans.** See p. 113 (Table 9.3)

**Q. How to take cervical smear?**

**Ans.** Cervix is exposed with a Cusco's bivalve speculum without any lubricant. Prior bimanual examination should not be done. Rest see p. 110, 111.

**Q. How HPV infection and CIN are related and how it could be prevented?**

**Ans.** p. 323.

**Uses**

- ◆ It is commonly used in vaginal operations such as D + C, D + E, anterior colporrhaphy, vaginal hysterectomy, etc. to retract the posterior vaginal wall.
- ◆ To visualize the cervix and inspect the abnormalities in the anterior vaginal wall like cystocele, VVF or Gartner's cyst after placing the patient in Sims' position.
- ◆ To collect the materials from the vaginal pool for cytology or Gram stain and culture.

**Self-assessment**

- ◆ Sims' position (p. 103 Fig. 9.3A).
- ◆ Sims' triad (p. 423).
- ◆ Introduction of Sims' speculum (p. 104).
- ◆ Why the blades are of unequal sizes?
- ◆ Lesions in the anterior vaginal wall.
- ◆ Indications of D + C (p. 585).
- ◆ Steps of D + C (p. 586).

The valves are to retract the anterior and posterior vaginal wall so as to have a good look to the cervix. A light source from behind is essential. It is commonly used in the OPD.

**Uses**

- ◆ To visualize the cervix and vaginal fornices.
- ◆ To collect cervical smear for cytologic screening and vaginal pool materials (p. 105).
- ◆ To have cervicovaginal swabs for Gram stain and culture.
- ◆ To insert or to remove IUCD or to check the threads.
- ◆ To perform minor operations like punch biopsy, surface cauterization or snipping a small polyp.

**Self-assessment**

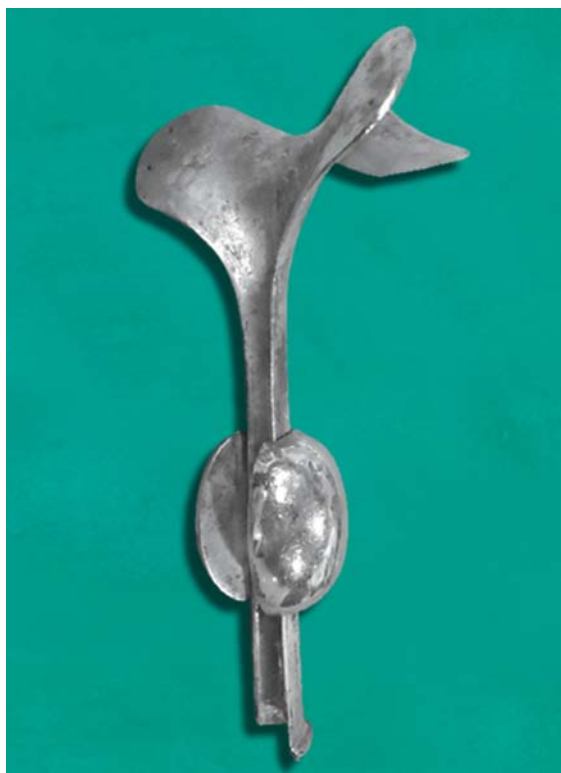- ◆ Use of two blades (see above).
- ◆ Lesions in the cervix (p. 167, 270, 323).
- ◆ Ectopy (erosion) cervix (p. 269)
- ◆ Pap's gradings (p. 112).
- ◆ Polyps (p. 272).

**Q. What is cervical ectopy?**

### ■ AUVARD'S SELF-RETAINING POSTERIOR VAGINAL SPECULUM (FIG. 37.4)

**Uses**

- ◆ It is used as posterior vaginal wall retractor in operations like anterior colporrhaphy, vaginal hysterectomy, etc.
- ◆ It should be used only when the operation is done under general or regional anesthesia as the instrument is heavy. It requires no assistant. (Prolonged use may cause perineal pain in the postoperative period).

**Fig. 37.4:** Auvard's speculum

**Ans.** It is the replacement of squamous epithelium of the ectocervix by columnar epithelium of endocervix by the process of metaplasia. (See p. 269).

**Q. What are the different types of polyps?**

**Ans.** Polyps may be Benign (Mucous, Fibroid or Placental) or Malignant. It may be sessile or pedunculated. See p. 272.

### ■ FEMALE RUBBER CATHETER (FIG. 37.5)

**Uses**

- ◆ To empty the bladder in retention of urine.
- ◆ To administer oxygen.
- ◆ To use as a tourniquet in myomectomy operation as an alternative to myomectomy clamp.

**Self-assessment**

- ◆ Causes of retention of urine (p. 410 Table 24.8).
- ◆ Procedure of catheterization (p. 109).

**Q. What are the causes of acute and chronic retention of urine?**

**Ans.** (i) Postoperative (common), (ii) Obstructive, (iii) Failure of detrusor contraction, (iv) External sphincter spasm and, (v) Others (see p. 410).

**Q. What are the different causes of urinary incontinence?**

**Ans.** See page 398/399.

**Q. What are the different menstrual abnormalities that can manifest with retention of urine? (See p. 410, Table 24.8).****Fig. 37.5:** Female rubber catheter

**Ans.**

- i. Primary amenorrhea (cryptomenorrhea) → Hematocolpos (see p. 450) → Retention.
- ii. Secondary amenorrhea → Retroverted gravid uterus (see p. 410) → Urinary retention.
- iii. Menorrhagia → Impacted uterine fibroid in the POD (see p. 280) → Urinary Retention.
- iv. Irregular bleeding and pain → Pelvic hemothecoele, pelvic abscess (see p. 178) → Retention.
- v. No menstrual abnormality → Impacted ovarian tumor, cervical fibroid or ovarian mass.

### ■ FEMALE METAL CATHETER (FIG. 37.6)

**Uses**

- ◆ To empty the bladder prior to major vaginal operations. Not only it facilitates the operation but minimizes the injury to the bladder.
- ◆ To confirm the diagnosis of Gartner's cyst from cystocele (see p. 200).
- ◆ It is not used in obstetrics to avoid trauma.

**Use in PFR (see p. 219)**

- ◆ To empty the bladder prior to the operation.
- ◆ To note the lower limit of the bladder before making the incision on the vagina.
- ◆ Prior to cutting the vesicocervical ligament.
- ◆ At the end of the operation to make sure about absence of any injury.

### ■ FOLEY'S CATHETER (FIG. 37.6A)

It is used in Gynecology for (A) **Continuous drainage of bladder**. Common indications of use are:

- ◆ Vaginal/abdominal hysterectomy.
- ◆ Pelvic floor repair.
- ◆ Repair of VVF
- ◆ Urinary retention due to pelvic tumor/retroverted gravid uterus.
- ◆ Radical hysterectomy.



**Fig. 37.6A:** Foley's catheter



**Fig. 37.6:** Female metal catheter

**Self-assessment**

- ◆ What is the Length of female urethra? (see p. 13).
- ◆ Differentiation of Gartner's cyst from cystocele (p. 200).
- ◆ Management of injury to bladder during operation: Bladder mucosa is apposed with 3-0 delayed absorbable suture (Vicryl) as a continuous layer. A second layer of (musculofascial) suture with the same material is used to reinforce the first layer. Continuous bladder drainage is maintained for 10 days.

(B) During hysterosalpingography, sonohysterosalpingography (SIS). The catheter is introduced into the uterocervical canal. The balloon is inflated to occlude the internal os. The media (dye/saline) is pushed (see p. 239).

(C) To assess the patency of the fallopian tube during laparotomy. The catheter is introduced in the uterocervical canal. The balloon is inflated to occlude the internal os. The dye is then pushed through the catheter.

**Self-assessment**

- ◆ What are the urinary complications following abdominal hysterectomy?
- ◆ Common urinary complications of vaginal hysterectomy.
- ◆ Mention the postoperative management following repair of VVF (p. 423).
- ◆ Common causes of retention of urine due to pelvic tumour or retroverted gravid uterus (p. 410).
- ◆ What is sonohysterosalpingography (SIS)? (p. 118)



### ■ CERVICAL DILATORS (FIGS 37.7 AND 37.8)

#### Varieties

- ◆ Hawkin-Ambler: There are 16 sets starting from 3/6 and ends with 18/21 (Fig. 37.7).
- ◆ Hegar's: There are 12 sets, the smallest one is of 1–2 mm. This is used mainly in gynecological operations.
- ◆ Das's dilator (named after Sir Kedarnath Das) (Fig. 37.8).

#### Uses

- ◆ To dilate the cervix to facilitate intrauterine introduction of instruments (curette) or devices (IUCD) or hysteroscope or radium.



**Fig. 37.7:** Hawkin–Ambler dilator

- ◆ To dilate the cervix to facilitate drainage of intrauterine collection — pyometra, hematometra or lochiometra (p. 169, 450).
- ◆ To confirm patency of cervical canal after amputation of the cervix.
- ◆ To dilate the urethra in urethral stricture.

#### Self-assessment

- ◆ Indications of dilatation of the cervix only (p. 585).
- ◆ Indications of amputation of cervix (p. 592).
- ◆ Causes of pyometra (p. 169).
- ◆ Complications of dilatation operation (p. 586).



**Fig. 37.8:** Das's dilator

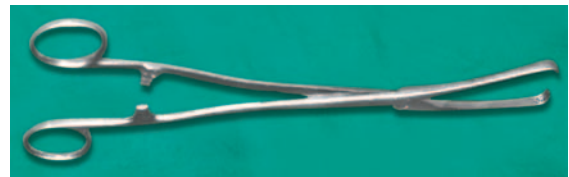### ■ MULTIPLE TOOTHED VULSELLUM (FIG. 37.9)

#### Uses

- ◆ To hold the parous cervical lip in operations like D + C, anterior colporrhaphy or vaginal hysterectomy. Its function is to make the cervix steady by traction.
- ◆ To remove a polyp by twisting as an alternative to Lane's tissue forceps
- ◆ To hold the fundus of the uterus and to give traction while the clamps are placed in operation of total abdominal hysterectomy for benign lesion.

#### When the posterior cervical lip is to be held ?

Usually the anterior lip is held but in some conditions, the posterior lip is to be held. Such conditions are:



**Fig. 37.9:** Multiple toothed vulsellum

- In amputation cervix or vaginal hysterectomy when the posterior cervicovaginal mucous membrane is cut (see p. 220, 586).
- Posterior colpotomy for drainage of pus (pelvic abscess) or vaginal ligation.
- When there is growth in the anterior lip (cancer cervix).
- Culdocentesis (p. 120).

### ■ SINGLE TOOTHED VULSELLUM (FIG. 37.10)

#### Uses

- ◆ To hold the cervix after opening the vault of vagina and to give traction while the remaining vault is being cut in total abdominal hysterectomy (p. 594).

- ◆ To hold the new cervical stump after amputation of the cervix and in Fothergill's operation (p. 210, 592).
- ◆ To hold the cervical stump left after subtotal hysterectomy (p. 593).
- ◆ Sometimes to hold the anterior lip of nulliparous cervix in operation of D + C (Allis' tissue forceps preferred).

**Self-assessment**

- ◆ What are the indications of amputation cervix? (p. 592).
- ◆ Indications of subtotal hysterectomy (p. 593).
- ◆ Mention common indications of abdominal hysterectomy (p. 593).
- ◆ Common indications of vaginal hysterectomy (p. 217).
- ◆ Indications of Fothergill's operation (p. 216).
- ◆ Principal steps of Fothergill's operation (p. 216).

### ■ ANTERIOR VAGINAL WALL RETRACTOR (FIG. 37.11)

**Use**

- ◆ To retract the sagging anterior vaginal wall to have a good look on the cervix while retracting the posterior vaginal wall by the Sims' speculum.

### ■ OLIVE POINTED MALLEABLE GRADUATED METALLIC UTERINE SOUND (FIG. 37.12)

**Uses**

- ◆ To confirm the position of the uterus.
- ◆ To note the length of the uterocervical canal.
- ◆ It acts as a first dilator.
- ◆ To sound the uterine cavity in a case of IUCD with missing threads.
- ◆ To differentiate a polyp from inversion.

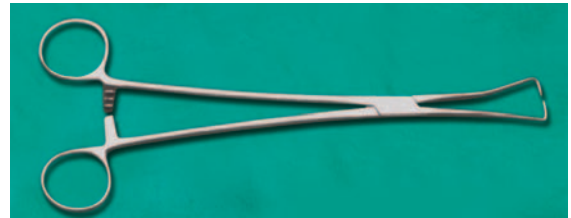**Self-assessment**

- ◆ Normal position of the uterus and length of the uterocervical canal (p. 7).
- ◆ Conditions where the length of the uterocervical canal is increased: **Ans.** Fibroid uterus, elongation of cervix, endometrial carcinoma.

### ■ UTERINE CURETTE (FIG. 37.13)

**Types**

- Sharp at one end, blunt at the other (Fig. 37.13A).
- Sharp or blunt at both ends.
- Handle with only sharp at one end.
- Flushing curette (blunt) (Fig. 37.13B).
- Sharman's curette (Fig. 37.13C).

**Fig. 37.10:** Single toothed vulsellum

- ◆ Complications of Fothergill's operation (p. 223, Table 15.5).

**Fig. 37.11:** Anterior vaginal wall retractor**Fig. 37.12:** Olive pointed malleable graduated metallic uterine sound

- ◆ Causes of elongation of the cervix (p. 273).
- Q. Common complications of using uterine sound?**

**Ans.** Uterine perforation and hemorrhage (p. 586).

**Q. How do you recognize uterine perforation?**

**Ans.** (a) Sudden loss of resistance (sense of giving a way). (b) Passage of the instrument more than the length of the uterine cavity. (c) Vaginal bleeding.

- ◆ Management of uterine perforation (p. 586).

**Fig. 37.13A:** Sharp at one end, blunt at the other end

**Uses: Sharp curette (Fig. 37.13A)**

- ◆ Infertility (p. 241).
- ◆ DUB (p. 190).
- ◆ TB endometritis (p. 138).

**Blunt curette**

- ◆ Suspected choriocarcinoma (p. 365).
- ◆ Suspected endometrial carcinoma (p. 359).

**Flushing curette (Fig. 37.13B)**

- ◆ Following D + E.

**Sharman's curette (Fig. 37.13C)**

- ◆ Infertility work up, where only a strip of endometrium is enough to study the hormonal reflection. It is done as an outpatient procedure and without anesthesia.

**Self-assessment**

**Q.** *What is the purpose of doing endometrial biopsy in a woman with infertility?*

**Ans.** To detect evidence of ovulation — by seeing the secretory changes in the endometrium (see p. 90).

**Q.** *Which day of the menstrual cycle endometrial biopsy is usually done?*

**Ans.** Biopsy should be done on D21–D23 when the cycle is regular. When the cycles are irregular, it is done within 24 hours of the mens.

**Q.** *In the endometrial biopsy, what is the earliest evidence of ovulation?*

**■ UTERINE DRESSING FORCEPS (FIG. 37.14)**

The instrument is often confused with laminaria tent introducing forceps. The blades are transversely serrated while in the latter, there is a groove on either blade.

**Uses**

- ◆ To swab the uterine cavity following D + E operation with a small gauze piece.
- ◆ To dilate the cervix in lochiometra or pyometra.
- ◆ To plug the uterine cavity with gauze twigs in continued bleeding after removal of polyp.

**■ SPONGE HOLDING FORCEPS (FIG. 37.15)****Uses**

- ◆ Antiseptic dressing before any abdominal or vaginal operation.
- ◆ To clean the vagina with gauze pieces before and after vaginal operations.
- ◆ To hold the cervix in circlage operation during pregnancy.

**Fig. 37.13B:** Flushing curette**Fig. 37.13C:** Sharman's curette**Fig. 37.13:** Uterine curettes

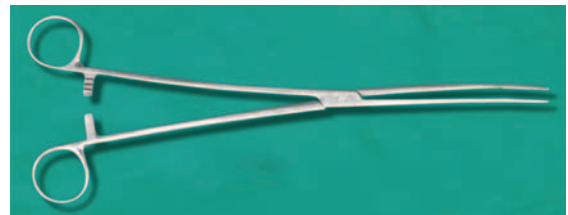**Ans.** **Subnuclear vacuolation** is the earliest evidence appearing within 36–48 hours of ovulation (see page 90).

**Q.** *What are the other methods of diagnosis of ovulation?*

**Ans.** BBT, cervical mucus study, vaginal cytology, serum progesterone, serum LH and estradiol, sonography and laparoscopy (see p. 239).

**Q.** *What are the ovarian causes of infertility?*  
*See p. 229.*

**Ans.** Anovulation, LPD and LUF (see p. 229).

**Fig. 37.14:** Uterine dressing forceps**Self-assessment**

- ◆ Causes of pyometra (p. 169).
- ◆ Management of polyps (p. 287).

**Fig. 37.15:** Sponge holding forceps

**Self-assessment**

**Q.** Name a few common abdominal operations.

**Ans.** Abdominal hysterectomy (p. 593), myomectomy (p. 604), ovariectomy (p. 600).

**Q.** Name a few common vaginal operations.

- Ans.**
- D&C (p. 585)
  - PFR (p. 216)
  - Vaginal hysterectomy (p. 218)
  - Fothergill's operation (p. 216).

### ■ OVUM FORCEPS (FIG. 37.16)

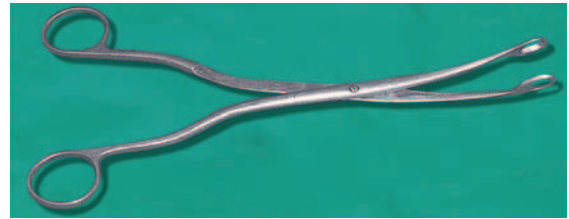It is often confused with sponge holding forceps but it has no catch. As such, it minimizes trauma to the uterine wall if accidentally caught and also it has got no crushing effect on the conceptus.

**Uses**

- ◆ To remove the products of conception in D and E after its separation partially or completely.
- ◆ To remove molar tissue in hydatidiform mole.
- ◆ To remove uterine polyp (small).

**Methods**

The cervical canal is dilated first. The instrument is introduced with the blades closed and opened inside the cavity. The products are caught and then with



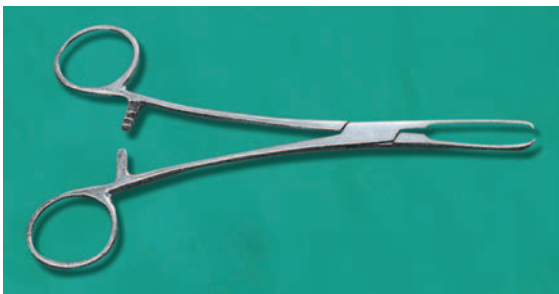**Fig. 37.16:** Ovum forceps

twisting movements and simultaneous traction, the products are removed.

**Complications**

It may produce injury to the uterine wall to the extent of even perforation. Not infrequently, a segment of intestine or omentum may even be pulled out through the rent.

### ■ ALLIS TISSUE FORCEPS (FIG. 37.17)



**Fig. 37.17:** Allis tissue forceps

**Uses**

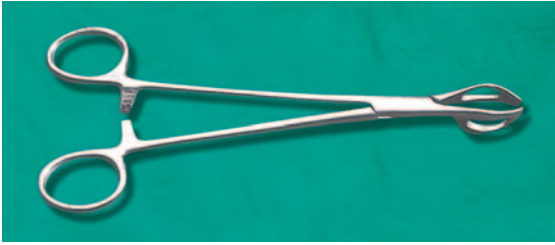- ◆ To hold the margins of the vaginal flaps in colporrhaphy operation (p. 215).
- ◆ To hold the peritoneum or rectus sheath during repair of the abdominal wall.

- ◆ To hold the margins of the vagina in abdominal hysterectomy (p. 594).
- ◆ To hold the anterior lip of the cervix in D and C operation (p. 586).
- ◆ To catch the torn ends of the sphincter ani externus in CPT repair (p. 433).
- ◆ To remove a small polyp.
- ◆ To take out the tissue in wedge biopsy (p. 589).

**Q.** What are the common symptoms associated with genital prolapse?

**Ans.** Woman may remain asymptomatic if the prolapse is mild. The common symptoms are: genital organs protruding out of the vaginal opening, difficulties in walking, sitting, urination or defecation. Prolapse may interfere with sexual intercourse or may cause vaginal bleeding due to ulceration of mucosa. It may cause incontinence of urine, pelvic pressure or backache (p. 207, 208).

### ■ LANES TISSUE FORCEPS (FIG. 37.18)



**Fig. 37.18:** Lanes tissue forceps

#### Uses

- ◆ To hold parietal wall (bulk of tough tissues) for retraction during abdominal operations with transverse incision (hysterectomy).
- ◆ To hold the polyp or fibroid in polypectomy or myomectomy operation.
- ◆ To hold the towel during draping.

### ■ CERVICAL OCCLUSION CLAMP (FIG. 37.20)

The blades are guarded with rubber tubes to avoid trauma to tissues.

**Uses:** Evaluation of tubal patency during laparotomy (following tuboplasty).

**Procedure:** Cervix is occluded with the instrument and methylene blue dye is injected into the uterine cavity through the fundus using a syringe and a needle.

#### Self-assessment

- ◆ Different methods to assess tubal patency (p. 240).

### ■ MYOMA SCREW (FIG. 37.21)

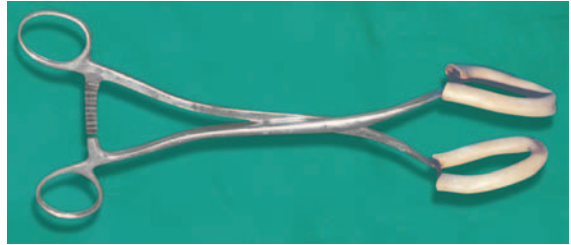
#### Uses

- ◆ To fix the myoma after the capsule is cut open and to give traction while the myoma is enucleated out of its bed (myomectomy).
- ◆ To give traction in a big uterus (multiple fibroid) requiring hysterectomy while the clamps are placed.

#### Self-assessment

- ◆ Indications of myomectomy (p. 282)
- ◆ Steps of myomectomy (p. 604)
- ◆ Complications of myomectomy (p. 605)

### ■ UTERUS HOLDING FORCEPS (FIG. 37.19)

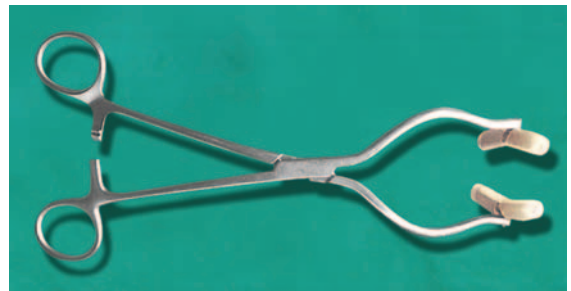

**Fig. 37.19:** Uterus holding forceps

The blades are protected with rubber tubes to minimize trauma to the uterus.

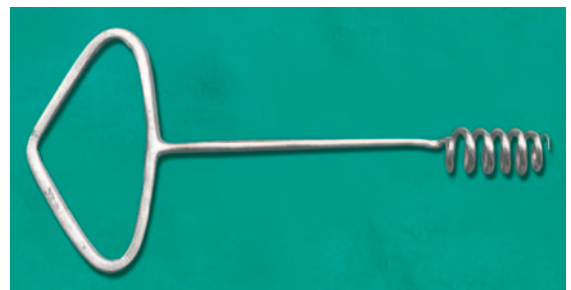
#### Uses

- ◆ To fix and steady the uterus when conservative surgery is done on the adnexae (tuboplasty: p. 252).
- ◆ What are the different surgical procedures for proximal and distal tubal disease? p. 251.



**Fig. 37.20:** Cervical occlusion clamp

- ◆ Different types of tubal reconstructive surgery (p. 251).



**Fig. 37.21:** Myoma screw

- ◆ Important considerations before myomectomy (p. 282).

### ■ BONNEY'S MYOMECTOMY CLAMP (FIG. 37.22)

#### Uses

- ◆ The clamp is used in myomectomy operation. It curtails the blood supply to the uterus temporarily, thereby minimizing the blood loss during operation. Simultaneous, bilateral clamping of the infundibulopelvic ligaments by rubber guarded sponge holding forceps may be employed.
- ◆ The instrument is placed at the level of internal os with the concavity fitting with the convexity of the symphysis pubis. The round ligaments of both sides are included inside the clamp to prevent slipping of the instrument and preventing the uterus from falling back. The clamp is removed after suturing the myoma bed but before closing the peritoneal layers.

- ◆ It is seldom used nowadays. alternative methods are: Preoperative use of GnRH analogue (p. 525), and/or intraoperative use of tourniquets, vasoconstrictive agents (vasopressin) and others.

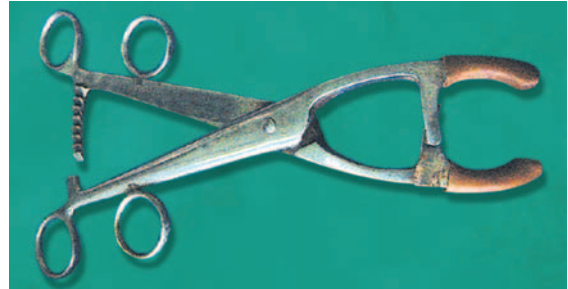

Fig. 37.22: Bonney's myomectomy clamp

### ■ HYSTEROSALPINGOGRAPHY CANNULA (LEECH WILKINSON VARIETY) (FIG. 37.23)

In HSG, a syringe is required to push the dye. Iodine containing radio-opaque dye (urograffin) is used. It is done in the radiology department without anesthesia.

#### Uses

- ◆ Hysterosalpingography (HSG) (p. 588).
- ◆ Also used for hydrotubation.

**Hydrotubation:** Medicated solution is pushed transcervically in conditions such as following tuboplasty operation or suspected flimsy fimbrial adhesions. The drugs instilled are dexamethasone 4 mg with gentamicin 80 mg in 10 mL normal saline. It should be instilled in the proliferative phase for at least 3 cycles.

#### Self-assessment

- ◆ What is HSG? (p. 588)
- ◆ Timing of HSG (p. 588).
- ◆ Advantages of HSG over laparoscopy (p. 238).

**Q. How do you compare the oil-based versus water-based media used in HSG?**

**Ans.** Water-based media is commonly used. It causes



Fig. 37.23: Hysterosalpingographic cannula

less cramping pain and discomfort. Oil-based media gives better image and has higher pregnancy rates. Granuloma is more with oil-based media. Embolization is minimal with either media (p. 588).

**Q. What are the indications of HSG?**

**Ans.** See p. 588.

**Q. Advantages of laparoscopy over HSG.**

**Ans.** See p. 238.

**Q. What are the complication of HSG?**

**Ans.** See p. 588 and 589.

**Q. What are the other alternatives to HSG?**

**Ans.** Diagnostic laparoscopy and dye test; sonohysterosalpingography and insufflation test (p. 237 and p. 238).

**Q. What is sonohysterosalpingography?**

**Ans.** See p. 238.

### ■ KOCHER'S ARTERY FORCEPS (FIG. 37.24)

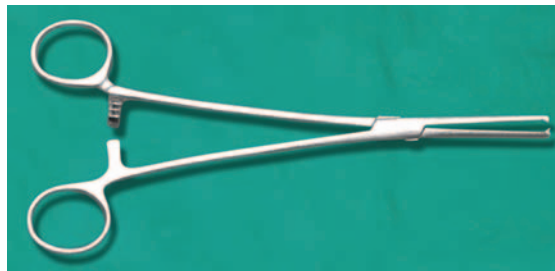#### Use

- ◆ To use as a clamp in hysterectomy operation.

#### Self-assessment

- ◆ What added advantage it has got?  
Due to the presence of tooth, it gives a firm grip to the pedicle hold.

- ◆ Indications abdominal of hysterectomy (p. 593).
- ◆ Mention the different sites where the clamps are placed in total abdominal hysterectomy (p. 594).
- ◆ Principal steps of Fothergill's operation (p. 216).
- ◆ Complications of Fothergill's operation (p. 223, Table 15.5).



**Fig. 37.24:** Kocher's artery forceps

### ■ LANDON'S BLADDER RETRACTOR (FIG. 37.25)

#### Uses

- ◆ In vaginal hysterectomy.
- ◆ To keep the bladder up, to facilitate opening of the uterovesical peritoneum (p. 216).
- ◆ To introduce it through the opening of the uterovesical pouch and to retract the bladder while the clamps are placed. This prevents injury to the bladder (p. 219).
- ◆ To inspect the suture lines after completion of vaginal plastic operations by retracting the anterior or posterior vaginal wall.
- ◆ Intravaginal plugging can be done under its guidance.
- ◆ To use as lateral vaginal wall retractor while the clamps are placed.

#### Self-assessment

**Q.** What are the non-surgical treatments of prolapse?



**Fig. 37.25:** Landon's retractor

**Ans.** Conservative treatments include: (i) To avoid aggravating factors (obesity, chronic cough, constipation). (ii) Pelvic floor exercise. (iii) Estrogen replacement therapy (postmenopausal women). (iv) Pessary in some cases (p. 215).

**Q.** Mention the different sites where the clamps are placed during vaginal hysterectomy (p. 219).

**Q.** Mention the important postoperative complications following vaginal hysterectomy with PFR (p. 225).

### ■ INSUFFLATION CANNULA (FIG. 37.26)

The instrument is not complete. It requires a 'Y' rubber tube. One end is attached to a bulb and the other end to a manometer.

#### Use

- ◆ To know the patency of the tube (Rubin's test) in infertility investigation or following tuboplasty.

#### Self-assessment

- ◆ Ideal time of operation in relation to menstrual cycle (p. 240).



**Fig. 37.26:** Insufflation cannula

- ◆ Complications of D and I (p. 587).
- ◆ Advantages of HSG over D and I (p. 588).

### ■ ABDOMINAL RETRACTORS (FIGS 37.27A TO C)

Retractors are used to retract tissues out of the operative field. This is needed for better exposure of the operative field during surgery. Retractors are held in place either by an assistant (manual retractor) or by counter pressure with some device (self-retaining retractor). Manual retractor can be used alone or in combination with a self-retaining retractor. Manual retractors can be placed according to need.

#### Doyen's retractor (Fig. 37.27A)

##### Use

- ◆ To retract the abdominal wall in abdominal pelvic surgery to expose the field of operation.
- ◆ As an alternative, self-retaining retractor may be used.

#### Balfour self-retaining retractor (Fig. 37.27B)

Two lateral blades and an additional (third) blade. All the blades are detachable and may be of different sizes.

##### Use

- ◆ To retract the abdominal wall all around.
- ◆ To expose the field of operation widely (no assistant is needed for manual retraction).

#### Deaver's retractor (Fig. 37.27C)

It is a manual retractor either used alone or in combination with a self-retaining one. It has got different sizes.

##### Uses

- ◆ It is used in abdominal operation to retract the viscera as and when required in order to facilitate the operative procedures like abdominal hysterectomy. For that purpose, it may also be used as a lateral retractor.
- ◆ To retract the parietal wall during abdominopelvic surgery (hysterectomy).
- ◆ To retract the bladder and intestines during the surgery.



Fig. 37.27A: Doyen's retractor

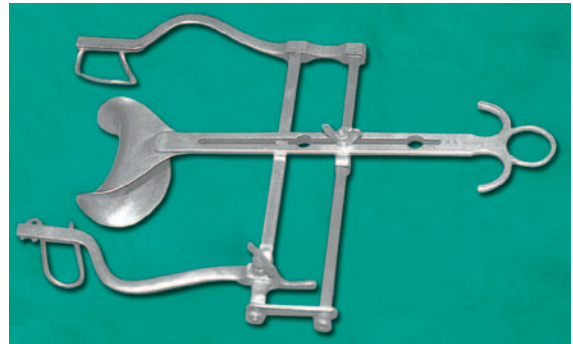


Fig. 37.27B: Balfour self-retaining retractor

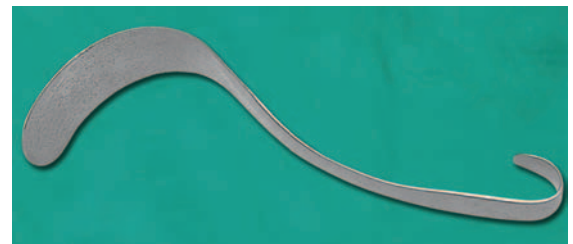

Fig. 37.27C: Deaver's retractor

### ■ LONG STRAIGHT HEMOSTATIC FORCEPS (SPENCER WELL'S) (FIG. 37.28)

##### Uses

- ◆ It is used as a clamp in (a) hysterectomy (b) salpingectomy or (c) salpingo-oophorectomy operation.
- ◆ To catch a bleeding vessel for hemostasis deep into the pelvis.



Fig. 37.28: Long straight hemostatic forceps

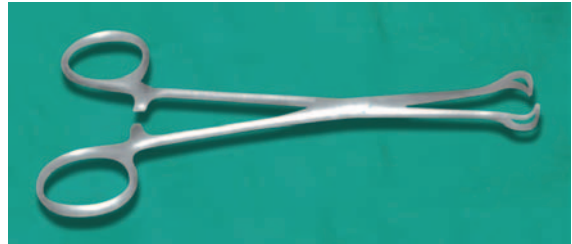

**Self-assessment**

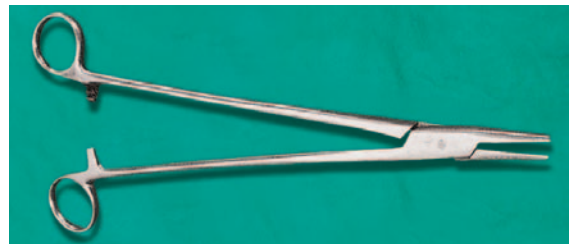- ▶ Pedicles hold in total abdominal hysterectomy (p. 594).
- ▶ Indications of salpingectomy (p. 598).
- ▶ Pedicles held in vaginal hysterectomy.
- ▶ Pedicles hold during salpingo-oophorectomy (p. 590). [Fig. 34.4(1), p. 591].
- ▶ Complications of abdominal hysterectomy during operation (p. 596).

**■ BABCOCK'S FORCEPS (FIG. 37.29)****Uses**

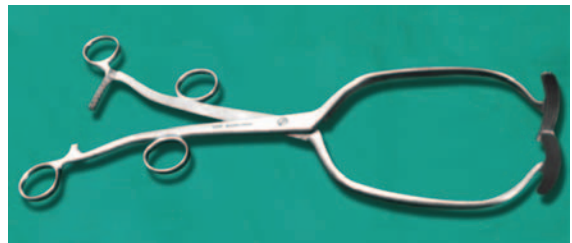- ◆ To hold the Fallopian tube in tuboplasty operation (see p. 251).
- ◆ To hold lymph nodes during dissection in radical hysterectomy (lymphadenectomy p. 594).
- ◆ To hold the appendix during appendicectomy.

**Fig. 37.29:** Babcock's forceps**■ NEEDLE HOLDER (FIG. 37.30)****Uses**

- ◆ It may be straight or curved.
- ◆ To catch-hold the needle, the needle should be caught at the junction of anterior 2/3rd and posterior 1/3rd.

**Fig. 37.30:** Needle holder**■ BARKELAY BONNEY VAGINAL CLAMP (FIG. 37.31)****Use**

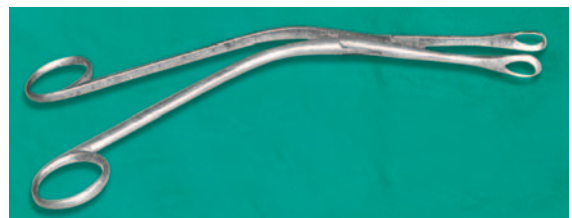- ◆ To occlude the vaginal canal prior to cutting the vagina in Wertheim's hysterectomy.

**Fig. 37.31:** Barkelay Bonney vaginal clamp**■ PUNCH BIOPSY FORCEPS (FIG. 37.32)****Uses**

- ◆ To take biopsy from the cervix.
- ◆ The biopsy is taken as an outdoor procedure without anesthesia. The site of biopsy is either from the suspected area or Schiller's iodine or colposcopically directed.

**Self-assessment**

- ▶ Mention the different types of cervical biopsy (p. 589).
- ▶ Procedure of sending the material for histology (p. 590).
- ▶ Schiller's test (p. 328).
- ▶ VIA (p. 327).
- ▶ Histology of carcinoma cervix (p. 340).
- ▶ Early diagnosis of carcinoma cervix (p. 344).
- ▶ Complications of cervical biopsy (p. 590).
- ▶ Complications of cone biopsy.

**Fig. 37.32:** Punch biopsy forceps

### ■ DISSECTING FORCEPS (FIGS 37.33 AND 37.34)

#### *Toothed*


#### Use

- ◆ To hold tough structures like rectus sheath, cut margins of vaginal vault following hysterectomy or margins of vaginal flaps in PFR or the skin margins during suturing.

#### *Plain or non-toothed*

#### Use

- ◆ To hold soft tissues like peritoneal margins during suturing.



**Fig. 37.33:** Toothed dissecting forceps




**Fig. 37.34:** Non-toothed dissecting forceps

### ■ SCALPEL (FIG. 37.35)

The instrument has a — handle and a blade

#### Uses

- ◆ To cut the abdominal wall — skin, subcutaneous tissue, rectus sheath and opening the peritoneum.
- ◆ To cut the mucous coat in vaginal plastic operation and to cut tissues during surgery.
- ◆ To cut pedicles during hysterectomy.



**Fig. 37.35:** A. Scalpel; B. Handle and blade

### ■ NEEDLES [FIG. 37.35(a)]

#### **Round bodied (curved)**

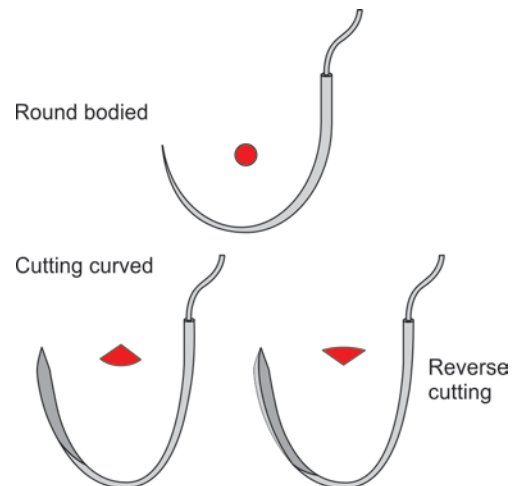
It is used while suturing soft structures like:

- ◆ Peritoneum, muscles.
- ◆ Suturing the pedicles in hysterectomy.
- ◆ Suturing the pubocervical fascia.
- ◆ Tubectomy or salpingectomy operation.

#### **Cutting (Curved)**

It is used while suturing tough structures like:

- ◆ Suturing the vaginal margins in PFR (p. 216).
- ◆ Closure of the vaginal vault following hysterectomy (p. 596).
- ◆ Repair of the rectus sheath. Suturing the skin.



**Fig. 37.35(a):** Curved needles. All the needles are swaged.

### ■ SCISSORS (FIGS 37.36 TO 37.39)

Scissors are used to dissect and cut tissues. It may be straight or curved variety.

#### **Mayo's Type — (Fig. 37.36)**

This is used in almost every operation requiring tissue dissection and excision. It is mainly used for cutting tough tissues.



**Fig. 37.36:** Scissors (Mayo's type)

**Bent on Flat (Bonney) Type — (Fig. 37.37)**

This is used conveniently in anterior colporrhaphy to dissect the vesicovaginal space and also for tissue dissection.

**Metzenbaum — (Fig. 37.38)**

This is used to dissect and cut tissue such as peritoneum and adhesions.

**Perineorrhaphy — (Fig. 37.39)**

It is comfortably used in perineorrhaphy operation; also used in episiotomy.

**Self-assessment**

- Indications of PFR (p. 217).
- Complications of PFR (p. 222).
- Principal steps of perineorrhaphy, PFR, CPT repair (p. 214).
- Complications in abdominal wound.

**Ans. What is wound dehiscence:** When the separation of the layers of abdominal wound is up to the peritoneum — it is called a complete dehiscence. If the intestines come out of the wound, it is called **evisceration or burst abdomen**.

**Burst abdomen** usually occurs between seven and ten days of the operation. Predisposing factors are malnutrition, infection, cough due to chronic lung disease or abdominal distension.

**Management:** In the operation theater, under general anesthesia, necrotic tissues and clots are removed. The bowel is cleansed thoroughly with warm normal saline and placed back in the abdominal cavity.

**■ TOWEL CLIPS (FIG. 37.40)****Use**

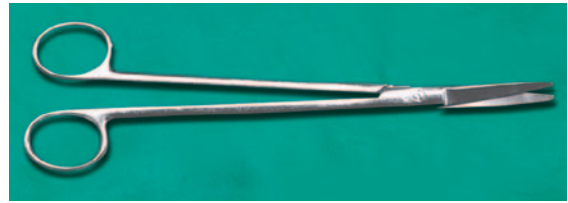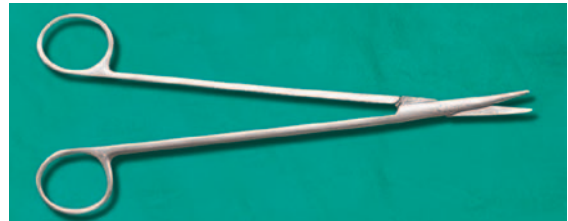
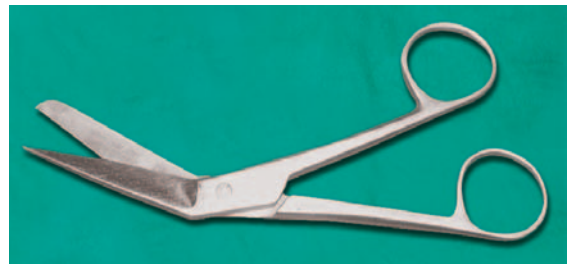- ◆ These are used in draping the operative area— abdominal or vaginal. The towels or sheets are fixed to the skin and to each other with these clips.

**Self-assessment**

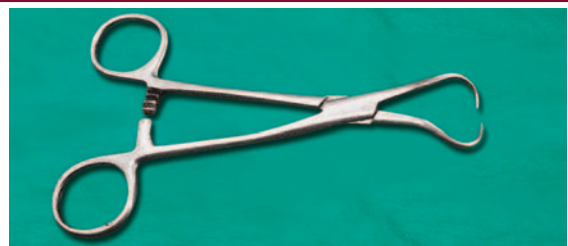- How the antiseptic cleaning in abdominal or vaginal operation is done in the operation table prior to draping (see p. 582).

**■ LOOP HOOK (FIG. 37.41)**

**Use:** To remove IUCD from the uterine cavity when the threads are missing (see p. 482).

**Fig. 37.37:** Scissors (Bonney) — bent on flat type**Fig. 37.38:** Scissors (Metzenbaum)**Fig. 37.39:** Scissors (perineorrhaphy)

Through and through nylon (No. 2) sutures are passed 2 cm apart and about 3 cm from the skin margins to close the wound. Sutures are left in place for three weeks. Antibiotic (broad spectrum) is started and modified according to the culture and sensitivity report. Predisposing factors are to be taken care of.

**Fig. 37.40:** Towel clip**Fig. 37.41:** Loop hook

**Method of use:** The cervical canal is dilated if needed (p. 585). The hook is introduced within the uterine cavity. The IUCD is felt and is grasped within the hook. It is then pulled out.

### ■ ELECTROCAUTERY (FIG. 37.42)

**Use:** Thermal cauterization of the cervix for cervical ectopy (p. 590).

#### Self-assessment

- ◆ Steps of thermal cauterization (p. 590).
- ◆ How tissue healing occurs? (p. 590).
- ◆ How the patient is counseled for the postoperative care? (p. 590).
- ◆ Complication of the procedure.

**Ans.** Excessive vaginal discharge, slight vaginal bleeding and pelvic pain.

### ■ CRYOPROBE (FIG. 37.42A)

**Use:** Tissue destruction is done by freezing (p. 591) at  $-90^{\circ}\text{C}$ .

#### Self-assessment

- ◆ What are the indications of cryotherapy?

**Ans.** (a) Cervical lesions: ectopy (erosion), CIN, VIN (p. 318), VAIN (p. 319).

- ◆ What is the principle of using cryotherapy?

**Ans.** The cryoprobe is held in contact with the tissue and the tip is cooled to  $-90^{\circ}\text{C}$  ( $\text{CO}_2$  is commonly used). Freezing produces cellular dehydration by crystallization of intracellular water and ultimately death of cells occur. Tissue damage occurs upto 5 mm depth.

### ■ LAPAROSCOPIC INSTRUMENTS (FIG. 37.43)

**A. Telescope (p. 612):** Commonly used are 5 mm or 10 mm diameter and viewing angle may be 0 or 30 degrees.


**B. Trocar and cannula (p. 612).**

**C. Veress needle (p. 612).**

The veress needle consists of a spring loaded blunt perforated trocar within a sharp cannula. Resistance allows the sharp cannula to protrude but when the resistance disappears, the blunt trocar protrudes out. This prevents injury to the viscera.

**Use:** It is used in laparoscopy operation to produce

**Precautions:** Location of the IUCD within the uterine cavity must be confirmed (p. 482). Trauma (perforation) to the uterus is to be avoided. Hysteroscopic removal can also be done.



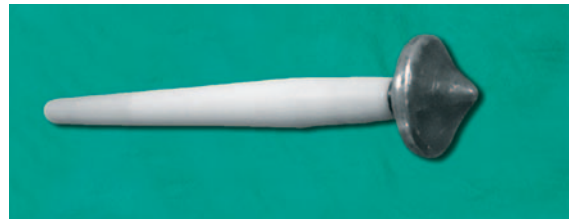**Fig. 37.42:** Electrocautery (inset — the cauterization probe)

- ◆ What are its advantages over thermal cautery ?

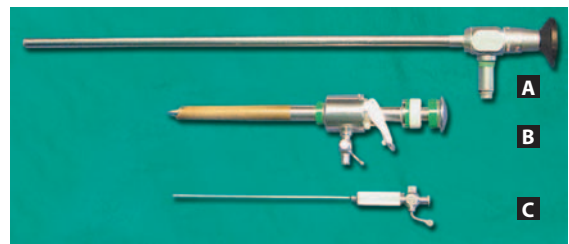
**Ans.** (a) No anesthesia is needed. (b) Precise tissue destruction. (c) No secondary hemorrhage.

- ◆ What are the disadvantages ?

**Ans.** Excessive vaginal discharge for about 10–14 days.



**Fig. 37.42A:** Cryoprobe



**Fig. 37.43:** Telescope 10 mm 0-degree, trocar and cannula and veress needle

pneumoperitoneum. The common site of puncture is through a small incision made in the lower rim of the umbilicus (see p. 615).


### ■ TROCAR AND CANNULA (FIG. 37.44)

The instrument is introduced through the same infraumbilical incision through which veress needle is passed at an angulation of 45° towards the pelvis.

After its introduction, trocar is withdrawn and the telescope is introduced. It is then attached to the cold light source (p. 616).

#### Self-assessment:

- I Indications of laparoscopy (p. 121 and 614).
- I Complications (p. 619).
- I Distension media used (p. 620).



**Fig. 37.44:** Cannula and trocar (pyramidal tip) — separated

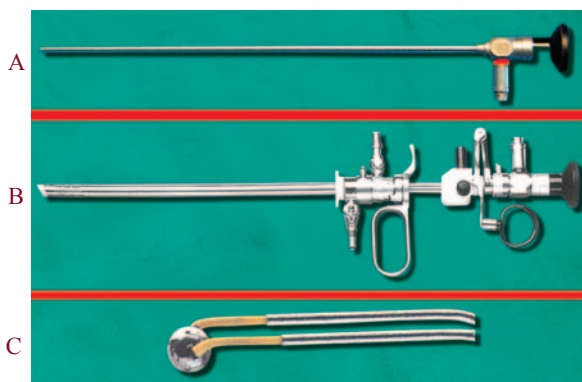
- I Advantages and disadvantages of laparoscopic sterilization operation over conventional methods (p. 494).

### ■ HYSTEROSCOPIC INSTRUMENTS (FIG. 37.45)

- A. Telescope (p. 619): 4 mm 0-degree.
- B. Telescope with working element (p. 619)
- C. Electrodes (coagulating roller ball electrode)

#### Self-assessment

- ▶ Indications of hysteroscopy (p. 621)
- ▶ Distension media used (p. 620)
- ▶ Complications (p. 623)
- ▶ Contraindication of hysteroscopy.



**Fig. 37.45:** Hysteroscopic instruments

### ■ HODGE-SMITH PESSARY (FIG. 37.46)

It is made up of silicone nite or ebonite. It is sterilized by immersing it in cidex for 12 hours.


**Indications of use:** See p. 201.

#### Contraindications of use

- Fixed RV uterus
- Presence of infection

**Self-assessment:** How pessary works? See p. 200.

**Method of insertion:** The patient lies in dorsal position with an empty bladder. The pessary is held collapsed or folded to make the insertion easy. A lubricant may be used. It is introduced inside the vagina



**Fig. 37.46:** Hodge-Smith pessary

and is pushed high. The broad end lies in the posterior fornix, the narrow end behind the symphysis pubis and the concavity is directed upwards.

#### Instructions to the patient

- I To have vaginal douche at least twice a week.
- I To check after 1 month.
- I To be removed or reintroduced after 3 months.

### ■ RING PESSARY (FIG. 37.47)

It is made up of silicon and rubber. It is sterilized by keeping in cidex for 12 hours.



**Fig. 37.47:** Ring pessary

**Indication of Uses:** See Chapter 15 (p. 214).

■ **Contraindications of use**

- ◆ Presence of sepsis.
- ◆ Gross relaxation of pelvic floor muscles.

**Measurements:** As in Hodge-Smith pessary.

**Instructions:** As in Hodge-Smith pessary.

**Self-assessment:**

- ◆ Mechanism of action (p. 200).
- ◆ How the patient is followed up and what symptoms are usually enquired ?

**Ans.** Pessary removal, examination, cleaning and reinsertion is done usually at an interval of 2–3 months. It is done initially by the doctor/nurse and later on by the patient herself once she is taught about the procedure. In every follow up visit, patient is asked about any symptoms like: vaginal bleeding, pain, offensive discharge and voiding difficulty.

- ◆ What are the complications of pessary use ?

**Ans.** Vaginal discharge, bad odor, vaginal erosion, ulceration, pessary incarceration, forgotten pessary rarely vaginal cancer (rare).

## PROCESSING OF INSTRUMENTS

**A. Disinfection:** It is done by any one of the methods: Immersing instruments in (i) boiling water for 20 minutes (ii) 2% glutaraldehyde (Cidex) solution for 20 minutes or (iii) 0.5% chlorine solution for 20 minutes (0.5% of chlorine solution is made by adding 3 teaspoons (15 g) of bleaching powder in one litre of water). **B. Cleaning:** Instruments are disassembled and washed on all surfaces in running (preferably warm) water. The cannulas should be flushed repeatedly. **C. Sterilization:** Either by —(i) Autoclaving at 121°C (250°F), under pressure of 15 lbs/in<sup>2</sup> (106 kPa) for 30 minutes or (ii) Immersing in 2% glutaraldehyde (Cidex) solution for 10 hours.

## STERILIZATION OF INSTRUMENTS

**BLUNT INSTRUMENTS:** All blunt instruments are sterilized either by boiling for half an hour or in an autoclave for 20 minutes with 20 lbs pressure at 120°C.

**SHARP INSTRUMENTS:** Sharp instruments like

knife, needle, etc. are sterilized by keeping in lysol for 24 hours.

## SUTURES

The suture materials used in a particular surgical step depend on the strength of the tissues to be sutured and the time required for the wound to regain its strength. Depending on diameter, sutures are categorized into no. 0, 1, 2, etc. Sutures when smaller than no. 0, are indicated as 1-0, 2-0 and so forth. Due considerations also to be given on tensile strength of the suture, the rate at which the suture material loses its strength *in vivo* and the interaction expected between suture and tissues.

**CLASSIFICATION:** The suture materials may be classified either as absorbable or nonabsorbable. Their biological origin or synthetic preparations are mentioned briefly.

- **Absorbable** ■ **Nonabsorbable**

**Absorbable:** • Biological • Synthetic

SUTURES		
Nature	Type	Tissue where used
<i>Absorbable</i>	<ul style="list-style-type: none"> <li>• Plain catgut</li> <li>• Chromic catgut</li> </ul>	<ul style="list-style-type: none"> <li>• Subcutaneous tissue</li> <li>• Pedicle, vaginal wall, rectus sheath, etc.</li> </ul>
<i>Delayed absorbable</i>	<ul style="list-style-type: none"> <li>• Dexon</li> <li>• Vicryl</li> <li>• PDS</li> </ul>	<ul style="list-style-type: none"> <li>• Subcuticular</li> <li>• Microsurgery</li> <li>• Fascial structure</li> <li>• Vaginal vault</li> <li>• Skin</li> <li>• Rectus sheath</li> </ul>
<i>Nonabsorbable</i>	<ul style="list-style-type: none"> <li>• Nylon</li> <li>• Prolene</li> <li>• Silk</li> <li>• Dacron</li> </ul>	<ul style="list-style-type: none"> <li>• Skin</li> <li>• Rectus sheath</li> <li>• Skin of the abdomen</li> </ul>

**Biological: • Catgut and Collagen**

**The catgut** (derived from the word *kitgut* — strings of a musical instrument known as kit) is obtained from the submucosa of sheep or ox intestines. Collagen is derived from ox Achilles tendon. Both are available in plain and chromic form. Treatment with chromic sulfate produces chromic catgut and the untreated material produces plain catgut. Chromic catgut is degraded by proteolytic enzymes of white blood cells (inflammatory cells) slowly. Chromic catgut loses half of its tensile strength by 10 days and maintains some strength upto 21 days. Plain catgut loses 70 percent of its tensile strength by 7 days.

**Synthetic**

- ◆ **Dexon:** Dexon (polyglycolic acid) is a copolymer of glycolic acid and is degraded by hydrolysis with minimal inflammation. It loses half of its tensile strength in 15 days and is absorbed in 4 months.
- ◆ **Vicryl (coated): Vicryl (polyglactin)** is a copolymer of lactide and glycolide. It loses its tensile strength in 30 days. It is absorbed by 70 days. It produces less tissue reaction than catgut.

**Vicryl rapide (coated):** It is also a polyglactin suture. It is similar to plain catgut. Absorption is rapid with minimal tissue inflammation. 70 percent of its tensile strength is lost by 7 days. It is used for repair of soft tissues, episiotomy repair and skin.

The tensile strength of the above sutures is much greater than that of catgut. But these sutures need more throws to secure knots compared to catgut.

- ◆ **Polydioxanone suture (PDS)** is a pliable mono-filament made of polydioxanone. It loses half of its tensile strength in 28 days. Tissue inflammation is minimal. Monofilament sutures have no interstices to lodge any

bacteria. So infections are rare. **Polyglyconate sutures** have got similar properties. These are used for fascial closure.

All the synthetic absorbable materials are sterilized by ethylene oxide.

**Nonabsorbable: • Biological • Synthetic Biological**

- ◆ **Silk** suture can be handled and tied easily. It has excellent knot security. It is sterilized by gamma radiation. It is a foreign protein and initiates strong inflammatory response and loses half of its tensile strength by 1 year. It should not be used in contaminated or infected tissue.
- ◆ **Cotton** is the weakest nonabsorbable suture. It loses 50 percent of the tensile strength by 6 months. Wet cotton is stronger (10%) than dry cotton. It is rarely used now.

**Synthetic**

- ◆ **Terelene or Dacron:** These are extruded from a homopolymer.
- ◆ **Polyamide (Nylon):** It is a man made monofilament or multifilament. It is very much nonreactive in tissues. Monofilament nylon has greater tensile strength, incites less tissue reaction and is less prone to infection than braided nylon.
- ◆ **Polypropylene (Prolene)** is a hydrocarbon polymer and is monofilament. It has least tissue reaction. Knot security is greater. It is sterilized by ethylene oxide.
- ◆ **Steel** suture is nonreactive and has highest tensile strength. It is not commonly used now.

**Nonabsorbable sutures** maintain their tensile strength for a long time. However, there may be suture related pain or rarely sinus formation.

**SPECIMENS**

**DESCRIPTION:** The description of a specimen includes:

- Identification of the organ/organs.
- To describe the pathology as seen on naked eye examination.

**Identification of the organ**

**Uterus:** *The uterus is identified by —*

- ◆ Pear-shaped structure ◆ Adnexal attachment
- ◆ Cervical opening
  - Circular in nulliparous
  - Transverse slit in parous

**Anterior surface is identified by:**

- ◆ Attachment of round ligament

- ◆ Loose attachment of uterovesical peritoneum [Fig. 34.4 (13)] p. 593.

**Posterior surface is identified by:**

- ◆ Attachment of ovarian ligament with or without ovary.
- ◆ Cut margin of the posterior peritoneum which is densely attached and placed at a lower level than the cut edge of the anterior peritoneum.

**Uterine tubes:** Tubular structures with abdominal ostium surrounded by fimbriae and mesosalpinx.

**Ovary:** Fallopian tube is usually attached to the ovarian specimen. If the uterine tube is not mounted, even then the specimen is likely to be ovarian as there is no other pelvic organs resembling it, exception being a parovarian cyst (Fig. 37.64).

## SPECIMEN — 1 AND 2

**DESCRIPTION (FIGS. 37.48 AND 37.49A AND B)**

This is a specimen of uterus with tubes and ovaries of both the sides (Fig. 37.48).

There is alteration in the size (enlarged) and shape (irregular) of the uterus due to multiple fibroids. The fibroids are of different sizes. Some are cut open to show whorled appearance (Fig. 37.49B). A capsule is seen (Fig. 37.48) surrounding the fibroid. Part of the tumor is covered by endometrium (submucous fibroid Fig. 37.49A) or a part is covered by serous coat (subserous fibroid Fig. 37.49B). One subserous fibroid has got a pedicle (Fig. 37.49B) — pedunculated.

The tubes and the ovaries are looking normal in all the specimens.

**Operation done:** Total hysterectomy with bilateral salpingo-oophorectomy.

**Diagnosis:** Multiple fibroids of the body of the uterus.

**Self-assessment**

- What are the different types of uterine fibroid (p. 273).
- Causes of menorrhagia (p. 276).
- Causes of infertility (p. 277).
- Causes of pelvic pain (p. 277).
- How to differentiate a fibroid from an ovarian tumor on clinical examination (p. 281).
- Place of medical management (p. 279).
- Different types of surgical management available (p. 268).

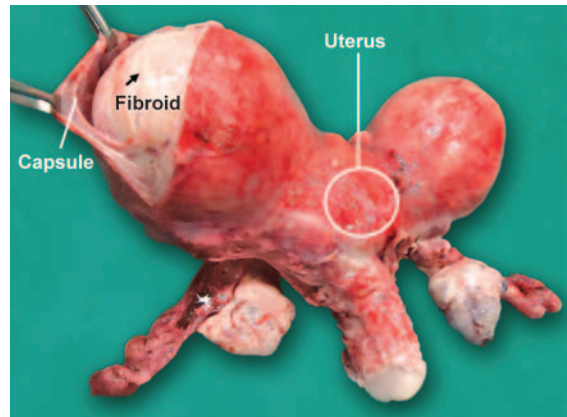
**Q. What could be the presentation of the woman in the clinic? P. 279.**

**N.B.** As with these specimens with total hysterectomy, the women are unlikely to suffer from infertility and as bilateral oophorectomy had been done, their probable age would be  $\geq 45$  years.

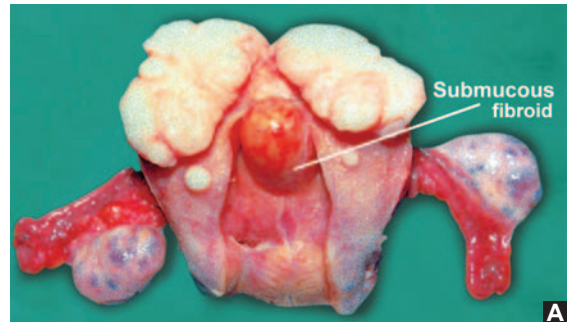
**Q. What are the indications, conditions to be fulfilled before myomectomy? What are the contraindications? Ans.** See p. 284.

**Q. What are the different treatment options available for fibroids? (p. 284, 285).**

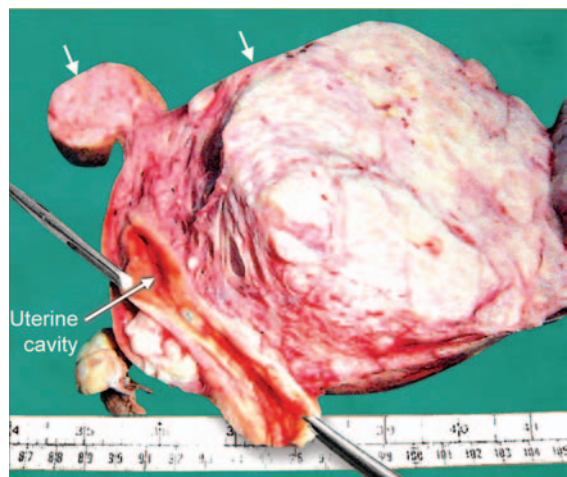
**Ans. A. Surgery** — (a) Hysterectomy, (b) Myomectomy. **Surgical procedures** may be: (i) Laparotomy, (ii) Laparoscopy, (iii) Hysteroscopy (see p. 284). (c) Myolysis.



**Fig. 37.48:** Multiple fibroid uterus, hysterectomy and bilateral salpingo-oophorectomy had been done. Tissue dissection had been done to show the capsule of the fibroid



**Figs. 37.49A and B:** Fibroid uterus — subserous, interstitial and, submucous variety. Specimen 37.49B has got a huge subserous (arrow) and also a pedunculated subserous variety of fibroid (arrow). Both the specimens are cut-opened to show the endometrial cavity. Both the cavities are increased and distorted



**B:** Uterine cavity is shown with Allis tissue forceps



B. Medical therapy (p. 266).

C. Interventional radiology — uterine artery embolization.

**Q.** How do you differentiate fibroid uterus from adenomyosis?

**Ans.** See p. 282.

### SPECIMEN—3

#### DESCRIPTION (FIG. 37.50)

This is a specimen of uterus, with tubes and ovaries of both the sides.

Anterior surface of the uterus is cut open to show a mass arising from the fundus protruding into the uterine cavity. Another mass is seen to come out of the uterus through the cervical canal with a long pedicle.

**Operation done:** Total hysterectomy with bilateral salpingo-oophorectomy.

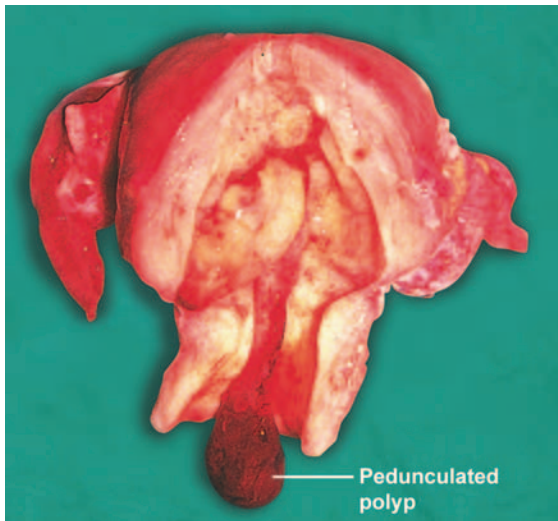
**Diagnosis:** Submucous fibroid polyps—Sessile and pedunculated.

#### Self-assessment

- ◆ Clinical presentation of such a case (p. 285, 287).
- ◆ Confirmation of diagnosis.

**Q.** When do myomas require to be removed (indications of myomectomy)?

**Ans.** (i) Any myoma growing during the follow up period. (ii) Menorrhagia not responding to medical therapy. (iii) Excessive pain or pressure symptoms.



**Fig. 37.50:** Submucous fibroid polyps (sessile and pedunculated). Patient suffered menorrhagia, metrorrhagia and dysmenorrhea

(iv) Woman with infertility or recurrent miscarriage when no cause other than fibroid is present (see text p. 285).

- ◆ What are secondary changes in a fibroid (p. 278).
- ◆ What are management alternative to hysterectomy (see p. 281).

### SPECIMEN—4

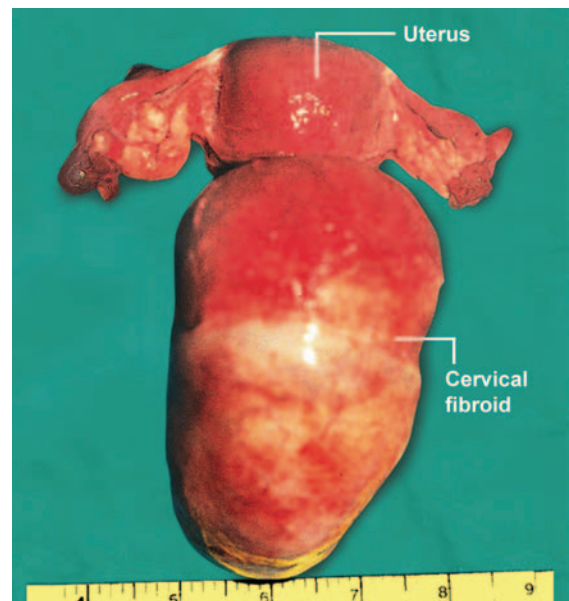
#### DESCRIPTION (FIGS 37.51A AND B)

This is a specimen of uterus (Fig. 37.51A) with tubes and ovaries of both the sides. There is a huge mass arising from the posterior cervical wall. The small uterus sits on the top of the huge mass. (*Lantern on dome of St. Paul's*).

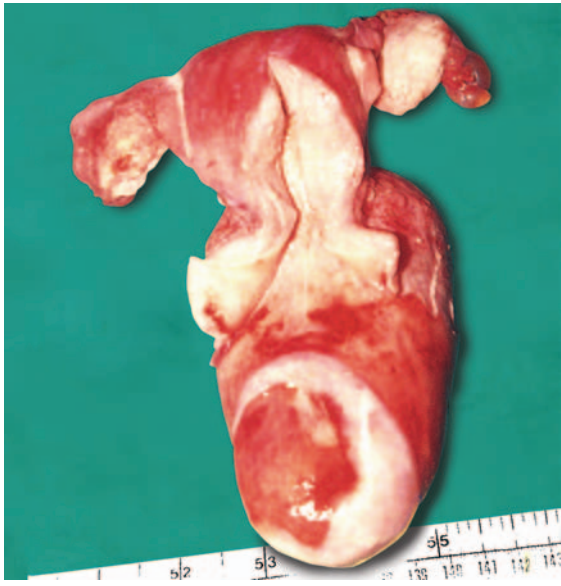The anterior surface of the uterus (Fig. 37.51B) is cut open to show the anterior cervical wall and the uterine cavity.

**Operation done:** Total hysterectomy with bilateral salpingo-oophorectomy with removal of the mass.

**Diagnosis:** Cervical fibroid (posterior).



**Fig. 37.51A:** A huge posterior cervical fibroid

**Self-assessment:**

- ◆ Types of cervical fibroid (p. 284).
- ◆ Modes of presentation in a case with cervical fibroid (p. 284).
- ◆ What are the surgical risks in such a case (p. 284)
- ◆ Approach for surgical removal of cervical myoma (p. 601).
- ◆ Displacements of the ureter and risks of ureteric injury (p. 425, 426).
- ◆ Common gynecological pathologies where ureteric injury is more likely (p. 425).

**Fig. 37.51B:** Same specimen as in 37.51A, is seen from the anterior surface

**SPECIMEN—5****DESCRIPTION (FIG. 37.52)**

This is a specimen of the uterus and the tubes and ovaries of both the sides. The uterus is enlarged and is cut open to show a diffuse growth located at one wall. The growth presents a striated appearance with scattered dark hemorrhagic spots. It has got no capsule. (c.f. — fibroid — whorled appearance and a capsule).

**Operation done**—Total hysterectomy with bilateral salpingo-oophorectomy.

**Diagnosis:** Adenomyosis.

**Self-assessment:**

- ◆ Describe the clinical presentation of pelvic endometriosis (p. 307).
- ◆ Causes of infertility in endometriosis (p. 231).
- ◆ Clinical features of adenomyosis (p. 315)
- ◆ Histological picture of adenomyosis (p. 314).
- ◆ Mention treatment options for pelvic endometriosis (p. 310).
- ◆ Treatment for adenomyosis (p. 315).

**SPECIMEN—6****DESCRIPTION (FIG. 37.53)**

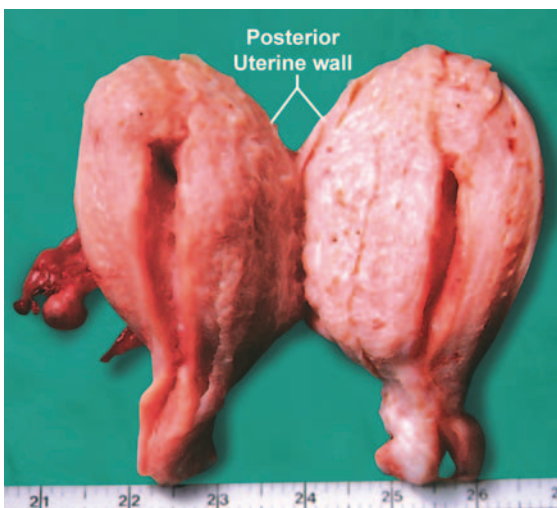
This is a specimen of the uterus with tubes and ovaries of both the sides. The ovaries are hugely enlarged, lobulated with a yellowish tinge. The uterus is also enlarged. Vesicular mass is seen protruding out through the incised uterus.

**Operation done:** Total hysterectomy with bilateral salpingo-oophorectomy.

**Diagnosis:** Hydatidiform mole with large theca lutein cysts of both the ovaries.

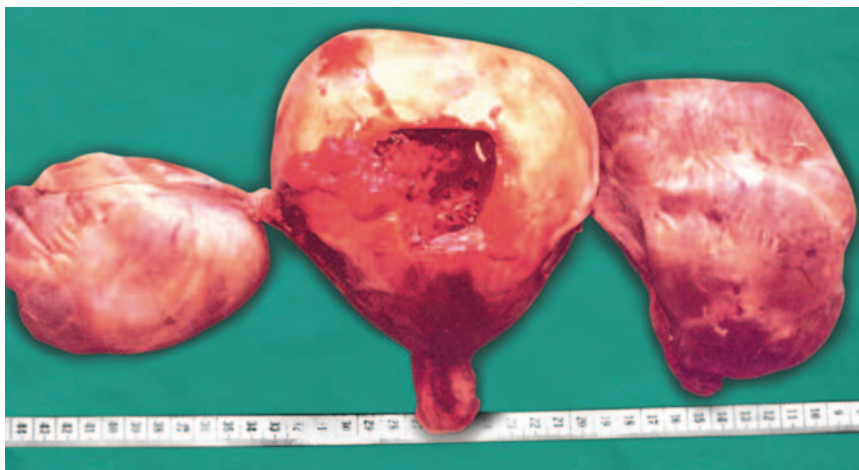**Self-assessment**

- ◆ High-risk factors for gestational trophoblastic neoplasia (GTN) (p. 363).



**Fig. 37.52:** Specimen of adenomyosis

- ◆ Clinical features of GTN (p. 362).
- ◆ Management of GTN (p. 365).
- ◆ Place of uterine curettage in GTN (p. 366).
- ◆ **Management of theca lutein cysts:** once hydatidiform mole or GTN is treated, there is spontaneous regression (within a few months) of the cysts. Rarely they are removed when complications like torsion or intracystic hemorrhage occur.



**Fig. 37.53:** Hydatidiform mole with bilateral large theca lutein cysts

### SPECIMEN—7

#### DESCRIPTION (FIG. 37.54)

This is the specimen of a uterus with the tubes and ovaries. The uterus is enlarged. The anterior surface of the uterus is cut open to show a purplish growth invading the myometrium. The tube and the ovary are looking healthy.

*This 37 years old parous lady was admitted with irregular bleeding P/V following a miscarriage. She underwent D/C thrice. Her serum  $\beta$  hCG level was 96,000 mIU/ml. Following courses of chemotherapy the serum hCG level remained persistently elevated.*

**Operation done:** Total hysterectomy with bilateral salpingo-oophorectomy. Histology confirmed choriocarcinoma.

**Diagnosis:** Choriocarcinoma of the uterus.

**Self-assessment:** *Q. How the selection of chemotherapy regimen is done?* **Ans.** See p. 365.

- ◆ Place of hysterectomy in GTN (p. 367).
- ◆ Prognosis of GTN following treatment and the risk of recurrence (p. 367).

*Q. What are the common sites of metastasis?*

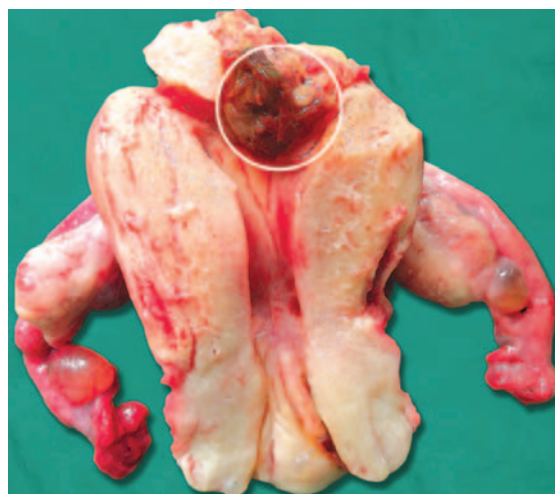
**Ans.** See p. 362.

*Q. What is the place of prophylactic chemotherapy and what are its limitations?* **Ans.** See p. 365.

*Q. WHO FIGO scoring system for risk assessment.*

**Ans.** See p. 364.

*Q. Reproductive behavior of women following treatment of GTN.* **Ans.** See p. 366.



**Fig. 37.54:** Choriocarcinoma resistant to chemotherapy. Lesion is seen to invade the myometrium

- ◆ Response to chemotherapy and subsequent reproductive behaviour (p. 367).
- ◆ Patient follow up following treatment (p. 367).

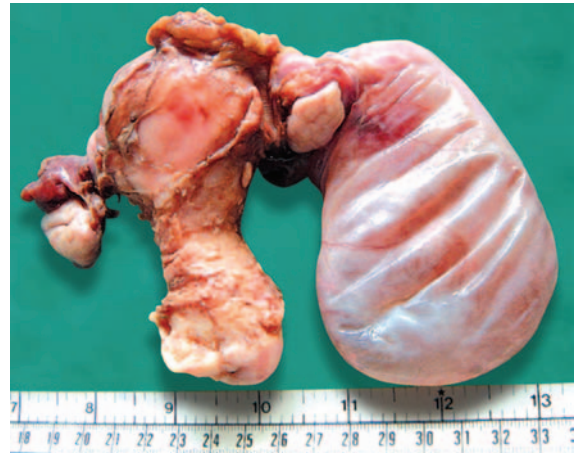
**SPECIMEN—8****DESCRIPTION (FIG. 37.55)**

This is a specimen of uterus, tubes and ovaries of both the sides. The left tube is markedly enlarged specially towards the outer half. The shape looks like a 'retort'. The inside fluid appears to be clear.

**Diagnosis:** Hydrosalpinx of the left tube.

**Self-assessment**

- ◆ Pathogenesis of hydrosalpinx (p. 171).
- ◆ Organisms involved in pathology (p. 171).
- ◆ Mode of affection in gonococcal infection (p. 127).
- ◆ Mechanism of the 'retort' shape (p. 171).
- ◆ Steps of salpingectomy (p. 588).



**Fig. 37.55:** Specimen of total hysterectomy with bilateral salpingo-oophorectomy showing a large hydrosalpinx (retort-shaped) of the left tube.

**SPECIMEN—9****DESCRIPTION (FIG. 37.56)**

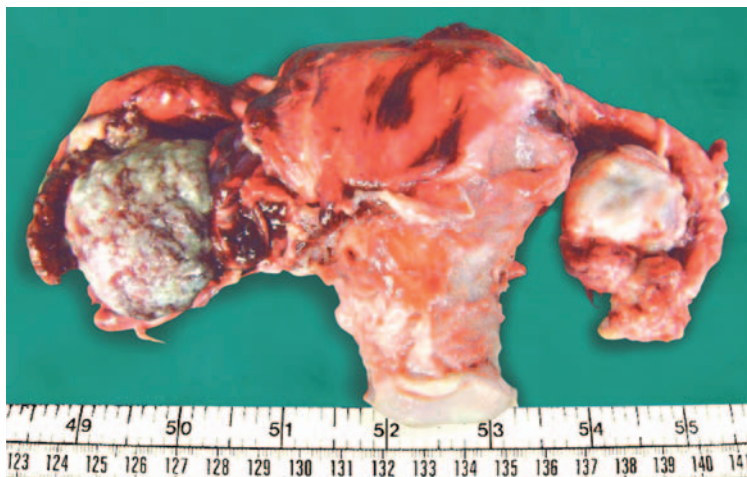This is a specimen of the uterus, tubes and ovaries of both the sides. The tubes of both sides are coiled, wall is thickened and matted with the ovaries. There are adhesions over the surfaces of the tubes and uterus. TAH & BSO had been done. Histology confirmed tuberculosis.

**Diagnosis:** Bilateral tubo-ovarian (TO) mass.

**Self-assessment**

- ◆ Mention the pathogenesis of TO mass (p. 174).

- ◆ Mention the clinical diagnostic criteria of PID (p. 130).
- ◆ What is the mode of spread of infection in tubercular, pyogenic and other infections (p. 127, 139).
- ◆ How infertility could be explained with genital tuberculosis? (p. 139).
- ◆ Mention the complications of acute PID and its late sequelae (p. 134).
- ◆ What are the characteristic changes on HSG of the tube when infected with tuberculosis? (p. 141).
- ◆ What are the contraindications and indications of surgery in a woman with pelvic tuberculosis? (p. 143).



**Fig. 37.56:** Specimen of uterus, tubes and ovaries showing bilateral tubo-ovarian mass due to genital tuberculosis

## SPECIMEN—10

**Description (Fig. 37.57)**

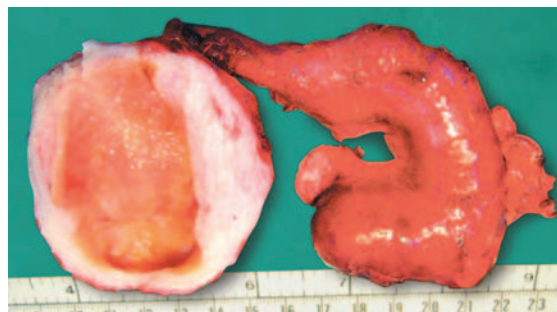
This is a specimen of a non-communicating horn of a bicornuate uterus (cut-opened) with the tube. The tube is elongated, sausage shaped and purplish in color. The cut-open uterus shows the cavity which was filled with blood. The tube is filled with blood.

**Operation done:** Excision of the non-communicating horn and salpingectomy.

**Diagnosis:** Rudimentary (non-communicating) horn of a bicornuate uterus with hematosalpinx.

**Self-assessment**

- ◆ **Causes of hematosalpinx:** Tubal ectopic pregnancy, endometriosis, cryptomenorrhea (p. 450) and rarely primary tubal carcinoma (0.3% of all genital malignancies).



**Fig. 37.57:** Hematosalpinx of the right tube

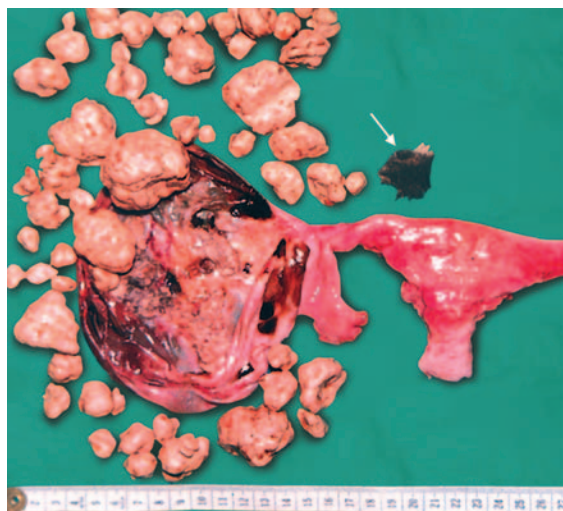- ◆ **Causes** of cryptomenorrhea (p. 450).
- ◆ **Clinical presentation** of a care with tubal carcinoma: triad of lower abdominal pain (colicky), profuse watery discharge (hydros tubae profluens) and vaginal bleeding (p. 370). Preoperative diagnosis is rare and often mistaken as an ovarian tumor (p. 369).

## SPECIMEN—11

**DESCRIPTION (FIGS 37.58A AND B)**

These are the specimens of the uterus with tube and ovary of the right side. The ovarian cysts (right) are cut open to show inspissated sebaceous material, hair and other mature (mesenchymal) tissues. Teeth is present in about a third (see Figs. 37.58A and B).

**Operation done:** Total hysterectomy with bilateral salpingo-oophorectomy.



**Fig. 37.58A:** Gross appearance of a dermoid cyst of the ovary showing hair, teeth (arrow) and butter balls (sebum aggregated to form spherules)

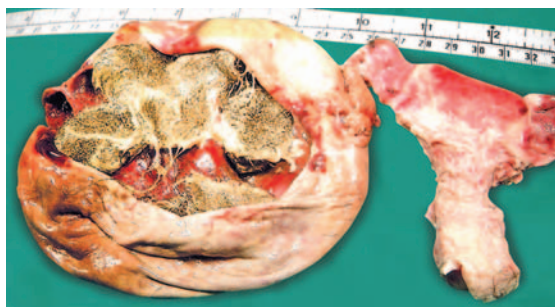
**Diagnosis:** Dermoid cyst of the right ovary.

**Self-assessment**

- ◆ Name the tissues arising from the three germ cell layers (p. 293).
- ◆ Frequency of bilaterality and association with pregnancy (p. 293).
- ◆ Common complications (p. 301).
- ◆ Management in a young patient (p. 301).
- ◆ Risk of malignant change (p. 298).
- ◆ What are strumal carcinoids? (p. 294).

**Q. How carcinoid tumors of the ovary are treated?**

**Ans.** Excision of the tumor (ovariotomy) causes rapid fall in the serum level of serotonin and disappearance of 5-hydroxy indole acetic acid in the urine. There is rapid remission of symptoms.



**Fig. 37.58B:** Gross appearance of dermoid cyst of the ovary with hair and sebaceous material (cut section)

## SPECIMEN—12

## DESCRIPTION (FIG. 37.59)

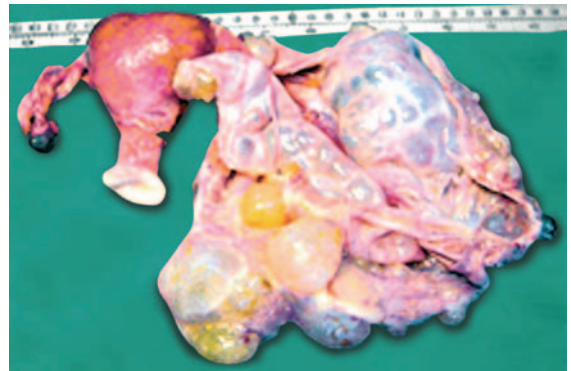This is a specimen of the uterus with tubes and ovaries of both the sides. The left sided ovarian cyst is cut open to show many septa. There are few smaller cysts projecting inside.

**Operation done:** Total hysterectomy with bilateral salpingo-oophorectomy.

**Diagnosis:** Mucinous cyst adenoma.

## Self-assessment

- ◆ Mention the common epithelial tumors of the ovary (p. 291).
- ◆ Discuss the differential diagnosis of a pelvic abdominal lump? (p. 300).
- ◆ Clinical presentation of a benign ovarian tumor (p. 295).
- ◆ Features of a functional cyst (p. 285).
- ◆ How a benign ovarian tumor could be differentiated from a malignant one clinically?



**Fig. 37.59:** Left sided mucinous cyst adenoma (gross appearance on cut specimen)

- ◆ How laparotomy findings could be helpful to differentiate a benign tumor from a malignant one? (p. 280).
- ◆ What are Psammoma bodies? (p. 293).
- ◆ What are the complications of a benign ovarian tumor? (p. 298).
- ◆ Management of a benign ovarian tumor (p. 300).
- ◆ Structures forming the ovarian pedicle (Table 20.3, p. 298).

## SPECIMEN—13

## DESCRIPTION (FIG. 37.60)

This is a specimen of uterus with tubes and ovaries of both the sides. The right ovary is hugely enlarged and cut opened to show its solid texture islands of yellow tissue separated by fibrous septa.

**Operation done:** Total hysterectomy with bilateral salpingo-oophorectomy.

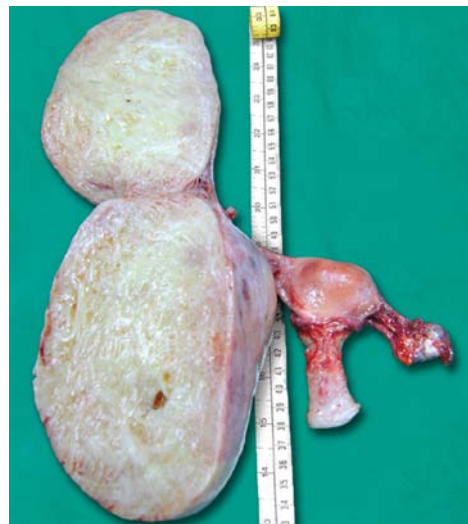**Diagnosis:** Solid ovarian tumor. theca cell tumor of the ovary was confirmed on histology.

## Self-assessment:

- *Mention the common solid tumors of the ovary.*  
*Benign:* Fibroma, thecoma, Brenner tumor (p. 278, 385).  
*Malignant:* Primary ovarian carcinoma, dysgerminoma, immature teratoma, mesonephroma (p. 370, 383).
- *What is Meig's syndrome (p. 296)?*

**Ans.** It is a triad of findings including ascites, pleural effusion and benign ovarian fibroma. The cause

is unknown. The ascites and pleural effusion resolve spontaneously when the ovarian tumor is removed.



**Fig. 37.60:** Gross appearance of a solid ovarian tumor (right)

- *What are the hormone producing tumors of the ovary?*

- Feminizing tumors: Granulosa cell and theca cell (p. 387).
- Masculinizing tumors: Sertoli-Leydig cell and Hilus cell (p. 388).
- Others: Struma ovarii (thyroid hormones) (Carcinoids are rare specialized germ cell ovarian tumors that secrete 5-HT (p. 294).
- What are the germ cell tumors of the ovary? (p. 383).

### SPECIMEN—14

#### DESCRIPTION (FIG. 37.61)

(A) This is a pathological specimen of the uterus and both the ovaries. The ovaries are enlarged lobulated with the walls irregular and shaggy. Cut section shows solid areas with hemorrhage and necrosis in places.

(B) Omentectomy done.

(C) Ascitic fluid (hemorrhagic) is collected.

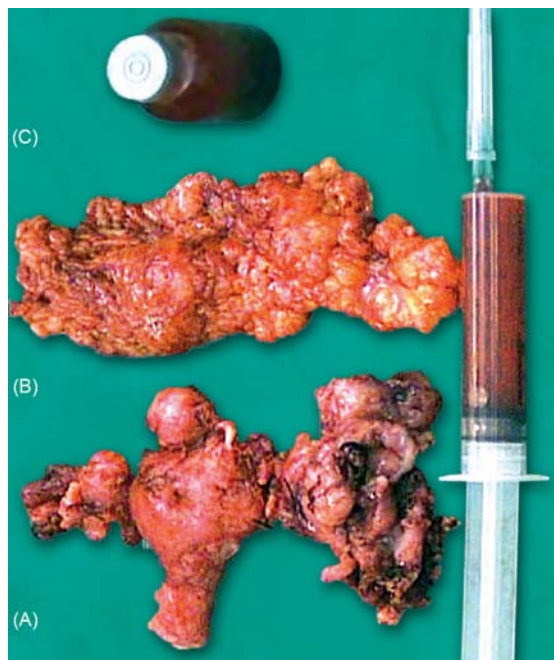
**Diagnosis:** Most likely malignant ovarian tumors (bilateral).

#### Self-assessment

- ◆ Clinical features of a malignant ovarian tumor (p. 364).
- ◆ What are the common malignant ovarian tumors? (page 366, Table 23.22).
- ◆ How omentectomy is helpful in the management of ovarian malignancies? (see p. 380).
- ◆ Is epithelial ovarian cancer hereditary?

**Ans.** About 5–10 percent of all epithelial ovarian cancers are familial. There are three different syndromes of hereditary ovarian cancer: (i) Breast/ovarian familial cancer (75–90%). (ii) Site specific ovarian cancer (5%) and (iii) Lynch II syndrome (2%) — see p. 365.

- ◆ Mention the high-risk factors as well as the protective factors for ovarian malignancy (p. 379).
- ◆ Principles of surgical approach (guidelines) in a malignant ovarian tumor (p. 380).
- ◆ What are the tissues removed in cytoreductive surgery? (p. 378).



**Fig. 37.61:** Specimen of bilateral serous cyst adenocarcinoma (confirmed on histology) — (A) total hysterectomy, bilateral salpingo-oophorectomy with (B) infracolic omentectomy and (C) Ascitic fluid (hemorrhagic) was collected for malignant cell cytology

#### ◆ How serum CA-125 measurement is helpful?

**Ans.** It is helpful with a known case of ovarian cancer: (i) To know the response of treatment. (ii) To know tumor resistance to chemotherapy. (iii) Early detection of tumour recurrence (p. 379).

### SPECIMEN—15

#### DESCRIPTION (FIG. 37.62)

This is a specimen of the uterus with tubes and ovaries of both the sides. The ovaries are enlarged with cap-sules ruptured. There is exophytic growth on the surface that infiltrates the surrounding organs. The cut surfaces show solid texture, extensive areas of hemorrhage and necrosis.

**Operation done:** Total hysterectomy with bilateral salpingo-oophorectomy and omentectomy.

**Diagnosis:** Bilateral ovarian carcinoma (mucinous cyst adenocarcinoma).

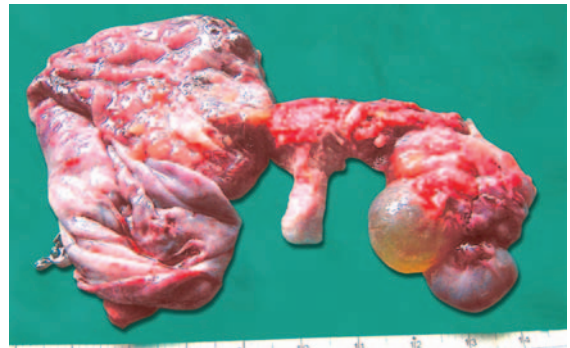#### Self-assessment

- ◆ What are the common sites of metastases?

**Ans.** See p. 378.

**Self-assessment**

- ◆ Methods of spread in a case of ovarian malignancy (p. 373).
- ◆ Place of neoadjuvant chemotherapy for ovarian malignancy (p. 379).
- ◆ What are the findings during laparotomy to differentiate a benign ovarian tumor from a malignant one. **Ans.** p. 294
- ◆ What are the treatment modalities in a case of ovarian malignancy? p. 376
- ◆ What is the place of prophylactic oophorectomy during hysterectomy (p. 376).



**Fig. 37.62:** Bilateral mucinous adenocarcinoma of the ovaries (gross appearance on cut specimen)

**SPECIMEN—16****DESCRIPTION (FIG. 37.63)**

This is a specimen of the uterus with tubes and ovaries of both the sides. The ovaries are found enlarged with lobulated appearance and are free of adhesions. The shape of the ovary is maintained. The color is pinkish with smooth surfaces. Uterus and tubes are found normal.

**Operation done:** Total hysterectomy with bilateral salpingo-oophorectomy.

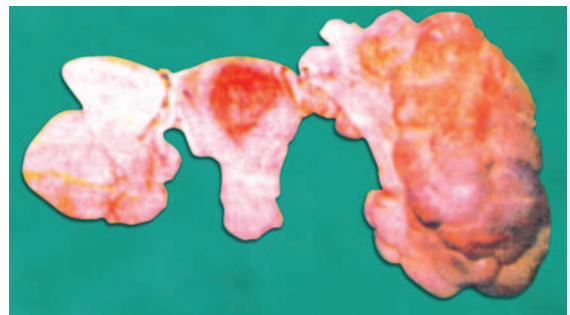
**Diagnosis:** Probably Krukenberg's tumor.

**Self-assessment**

- ◆ *What is a Krukenberg tumor?*

**Ans.** This is a metastatic adenocarcinoma of the ovary. Almost all metastasize from the stomach. Few arise in the breast, colon or biliary tract.

- ◆ Suggestive appearance for diagnosis (p. 388).



**Fig. 37.63:** Krukenberg tumor

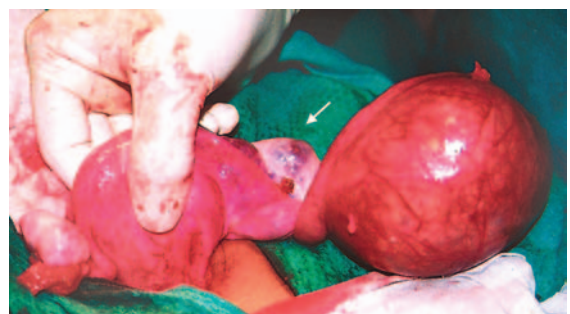- ◆ Primary sites (p. 388).
- ◆ Mode of spread to the ovaries (p. 388).
- ◆ Histological picture (p. 388).
- ◆ Prognosis (p. 388).
- ◆ What is the survival rate (p. 389).

**SPECIMEN—17****DESCRIPTION (FIG. 37.64)**

This is a specimen of the uterus with the tubes and ovaries. A hugely enlarged cyst is attached to the fimbrial end of the left tube which is stretched out. Left ovary is seen clearly (*see arrow*) behind the tube.

**Operation done:** Total hysterectomy with bilateral salpingo-oophorectomy with removal of the cyst is done.

**Diagnosis:** Parovarian cyst (Left).



**Fig. 37.64:** At a glance, it seems to be ovarian but careful inspection reveals the ovary is separated from the cyst



**Self-assessment**

- ◆ Diagnosis of a parovarian cyst (p. 305).
- ◆ Embryological origin of the cyst: From the remnant of the Wolffian body situated in the mesosalpinx.
- ◆ Usually the cyst is unilocular, has a thin wall and is filled with a clear fluid.
- ◆ Clinical features and management: Same as ovarian tumor (p. 297).
- ◆ Management: Excision of the cyst.
- ◆ Risk of malignancy — rare.

**SPECIMEN—18****DESCRIPTION (FIG. 37.65)**

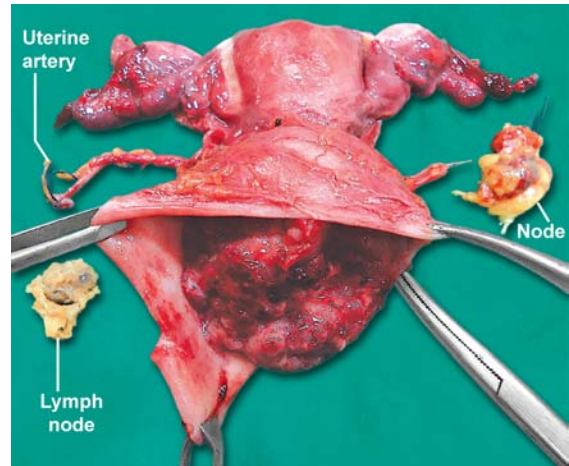
This is a pathological specimen of the uterus, tubes and ovaries of both the sides with upper vagina and the parametrium. The growth arising from the cervix is huge and exophytic.

**Operation done:** Radical hysterectomy for carcinoma cervix.

**Diagnosis:** Carcinoma cervix (invasive) (FIGO Stage IIA).

**Self-assessment**

- ◆ Histological types (p. 335).
- ◆ Diagnosis of early carcinoma (p. 337).
- ◆ Lymphatic drainage of the cervix (p. 30).
- ◆ Management of CIS, microinvasive and early stage carcinoma (p. 328).
- ◆ Advantages and disadvantages of radiotherapy (p. 341, 342).
- ◆ Principal steps of radical hysterectomy (p. 606).
- ◆ Tissues removed in radical hysterectomy (p. 606).
- ◆ Significance of sentinel node biopsy (p. 333).
- ◆ Staging procedures allowed by FIGO (p. 333).
- ◆ Complications of radical hysterectomy (p. 344).
- ◆ Preventive measures for carcinoma cervix — Primary and secondary prevention (p. 338).



**Fig. 37.65:** A specimen of carcinoma (squamous cell) of the cervix showing marked exophytic growth. Radical hysterectomy had been done. uterine arteries are ligated at their origin from the internal iliac artery. Both the ovaries and upper third of vagina had been removed. Pelvic lymph adenectomy done (one enlarged node on either side is seen)

- ◆ Mention the different treatment modalities for carcinoma cervix (p. 340).
- ◆ Causes of death in carcinoma cervix.
- ◆ Differential diagnosis of carcinoma cervix (p. 338).
- ◆ Place of laparoscopic assisted vaginal trachelectomy (p. 344).

**SPECIMEN—19****DESCRIPTION (FIG. 37.66)**

This is a specimen of the uterus with tubes and ovaries of both the sides. The uterus is uniformly enlarged. The anterior surface is cut open to show a fungating growth confined to the body. The tubes and ovaries are healthy.

**Operation done:** Total hysterectomy with bilateral salpingo-oophorectomy.

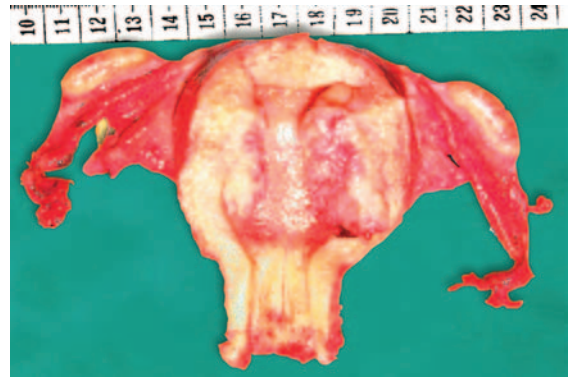
**Diagnosis:** Endometrial carcinoma.

**Self-assessment**

- ◆ Clinical presentation (p. 348).
- ◆ Discuss the methods of diagnosis (p. 348).

- ◆ Histological types of endometrial carcinoma (p. 347).
- ◆ Lymphatic drainage of body of the uterus (p. 29, 347).
- ◆ High-risk women (p. 352).
- ◆ Surgical procedures in the management (p. 350).
- ◆ Place of chemotherapy and radiotherapy (p. 351, 352).

**Fig. 37.66:** The uterus is cut open to show a diffuse and partly necrotic growth of adenocarcinoma filling the uterine cavity



## SPECIMEN—20

### DESCRIPTION (FIG. 37.67)

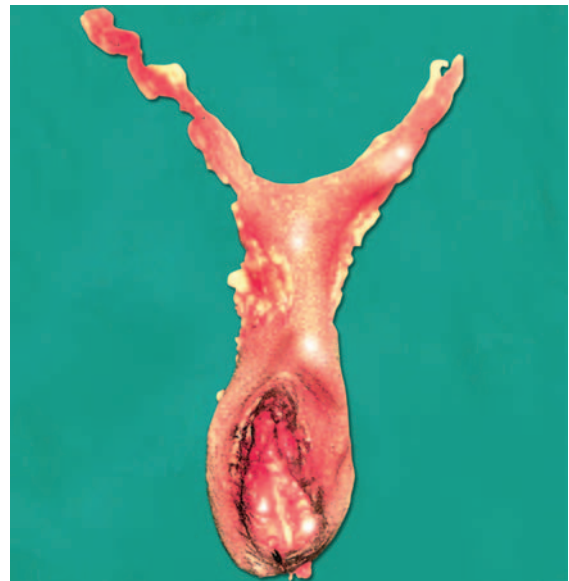This is a specimen of the vulva. The vulva shows a large exophytic growth and biopsy revealed squamous cell carcinoma.

**Operation done:** Radical vulvectomy. Vulvectomy specimen is obtained by the skin sparing “long horn” incisions. Tips of the horns rest on the anterior superior iliac spines. The upper margin of incision is interspinous, the lower margin is along the inguinal skin creases and the labiocrural folds. Three incision technique is currently used in most of the centres (p. 607).

**Diagnosis:** Carcinoma of the vulva.

### Self-assessment:

- ◆ Common sites of vulval malignancy (p. 328).
- ◆ Different histological types (p. 326).
- ◆ Lymphatic drainage of the vulva and its clinical significance (see p. 30, 327).
- ◆ Clinical presentation (p. 327).
- ◆ Types of vulvectomy (see p. 607).
- ◆ Advantages of three separate incisions (p. 607).
- ◆ Complications of radical vulvectomy (see p. 608).



**Fig. 37.67:** Carcinoma of the vulva — radical vulvectomy done using “long horn” incisions

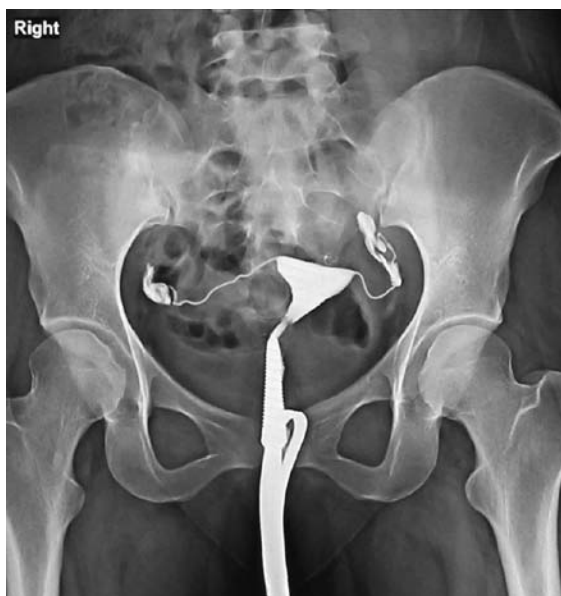- ◆ Significance of a sentinel node (p. 329).
- ◆ Prognostic factors for vulval carcinoma (see p. 329).

## IMAGING STUDIES IN GYNECOLOGY

## PLATES: SKIAGRAPHS, ULTRASONOGRAPHS, COMPUTED TOMOGRAPHS, AND MAGNETIC RESONANCE IMAGING

## HYSTEOSALPINGOGRAM (HSG)

## ONE (FIG. 37.68)



**Fig. 37.68:** Hysterosalpingogram with bilateral peritoneal spillage

## TWO (FIG. 37.69)

Hysterosalpingogram showing radio-opaque shadow demarcating the uterine cavity. No radio-opaque shadow is visible on either tube.

**Diagnosis:** Hysterosalpingogram showing bilateral cornual block.

**Self-assessment**

- ◆ Alternative investigations (p. 240).
- ◆ Management if tubes are damaged.
- ◆ Results of tuboplasty (p. 248).
- ◆ Different methods of ART (Table 16.13, p. 251).

**Management if tubes are normal:**

- ◆ To assess the male factors and ovarian factors for infertility.
- ◆ What other information can be obtained from HSG? p. 588.
- ◆ What are the causes of tubal block? (p. 229).

Hysterosalpingogram showing radio-opaque shadow demarcating the uterine cavity. The radio-opaque dye is visible in the lumen of both the tubes. There is peritoneal spillage on both sides.

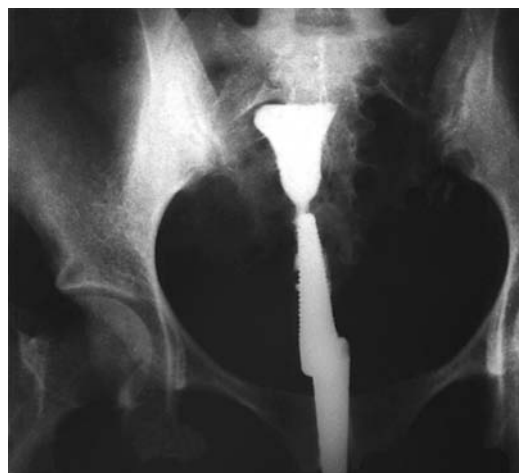**Diagnosis**

Normal hysterosalpingogram (normal cavity) with bilateral patent tubes (free peritoneal spill).

**Self-assessment**

- ◆ Indications and contraindications of HSG (p. 588)
- ◆ Timing of HSG in relation to the menstrual cycle (p. 588)
- ◆ Steps of the procedure (p. 588)
- ◆ Complications of HSG (p. 589)
- ◆ Prospect of fertility in this case: **Ans.** As the tubes are patent, the couple should be investigated to assess the ovulatory status and male factors for infertility (Ch. 16).
- ◆ Other methods for assessment of tubal patency (p. 240).

**Ans:** Salpingitis, salpingitis isthmica nodosa, benign polyps within the tubal lumen, tubal endometriosis, tubal spasm and intratubal mucous debris.



**Fig. 37.69:** Hysterosalpingogram showing bilateral cornual block. She had a history of MTP

**THREE (FIG. 37.70)**

Hysterosalpingogram showing radio-opaque shadow filling the uterine cavity. The tubes of both sides are distended with the radio-opaque dye. There is no evidence of peritoneal spillage.

**Diagnosis:** Bilateral hydrosalpinx (fimbrial block).

**Self-assessment**

- ◆ Causes of bilateral fimbrial block (p. 172).
- ◆ Is this woman a suitable case for HSG?

**Ans.** Ideally this woman suffering from hydrosalpinx (chronic PID) should not have undergone HSG, had this been diagnosed before hand. Infection may flare up following HSG.

- ◆ Management for distal and proximal tubal block (p. 247).
- ◆ *What is the appearance of the tube on HSG when infected with tuberculosis?* (p. 141).
- ◆ *What is the reproductive outcome in a woman with pelvic tuberculosis?* (p. 143).
- ◆ Indications of IVF–ET (p. 240).
- ◆ Does the presence of hydrosalpinx impair the result of IVF?

**FOUR (FIG. 37.71)**

Hysterosalpingogram showing a radio-opaque shadow filling both the horns of the uterus. The radio-opaque dye is visible within the tubes. There is peritoneal spillage on both the sides (Fig. 37.71).

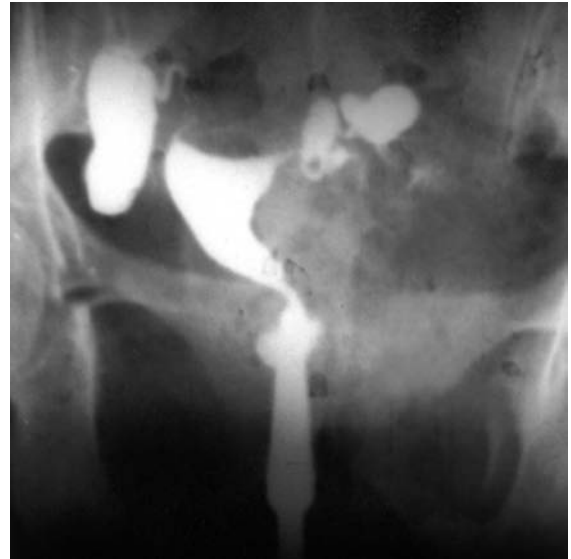**Diagnosis:** It seems to be a case of bicornuate uterus with bilateral patent tubes.

**Self-assessment**

- ◆ How one can differentiate bicornuate from septate uterus (p. 45).

**Ans.** When HSG or hysteroscopy is combined with laparoscopy, both the internal and external architecture of the uterus is clearly revealed. This is one of the way to confirm the diagnosis.

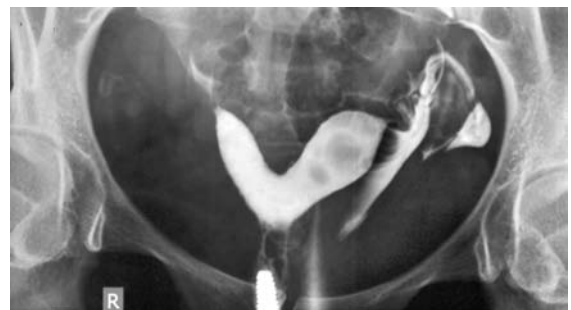- ◆ Management options of a patient with septate uterus (p. 47).
- ◆ **Gynecological symptoms** in bicornuate uterus (p. 45).



**Fig. 37.70:** Hysterosalpingogram showing bilateral hydrosalpinx (fimbrial block). Bilateral salpingostomy was done. Thereafter, she had an ectopic pregnancy

**Ans.** Hydrosalpinx reduces the pregnancy rates of IVF by about 50 percent. Endometrial receptivity is reduced resulting in implantation failure. Pretreatment (IVF), salpingectomy improves the outcome.

- ◆ **Management** of a bicornuate uterus is difficult. **Metroplasty** or unification (Strassman or Tompkins) operation has been recommended (p. 47).
- ◆ Reproductive behavior in a woman with uterine anomalies (p. 45).



**Fig. 37.71:** Hysterosalpingogram showing bicornuate uterus. Metroplasty was done for recurrent midtrimester miscarriage. Subsequently, she had a live birth at term, delivered by LSCS

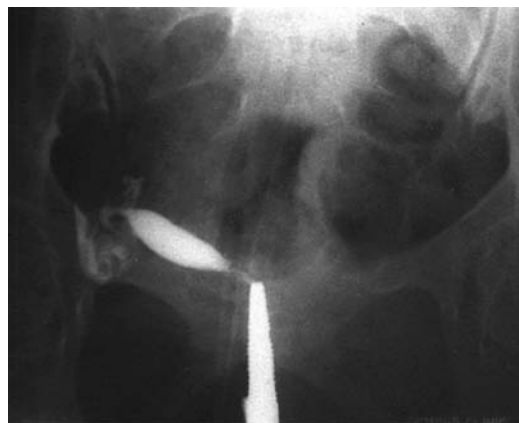**FIVE (FIG. 37.72)**

Hysterosalpingogram showing a radio-opaque shadow filling a single horn of the uterus. There is peritoneal spillage from the tube.

**Diagnosis:** It seems to be a case of unicornuate uterus with patent tube.

**Self-assessment**

- ◆ Confirmation of diagnosis (p. 45).
- ◆ Discuss the types of Müllerian anomalies (p. 44, 45).
- ◆ What is the reproductive outcome in a case with unicornuate uterus. **Ans.** Poor — due to reduced uterine capacity, less muscle mass and inability to expand (p. 45). Rupture may occur during pregnancy.



**Fig. 37.72:** Hysterosalpingogram showing a unicornuate uterus

**SIX (FIG. 37.73)**

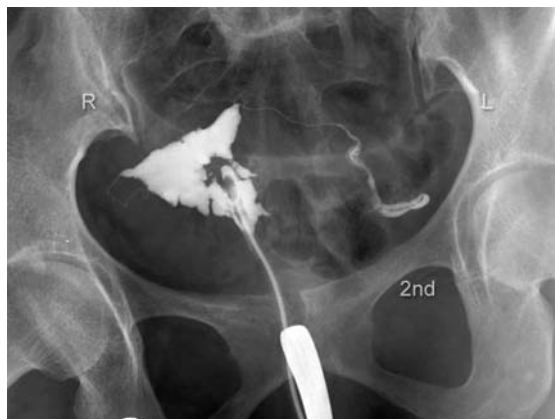Hysterosalpingogram showing irregular filling of radio-opaque dye.

**Diagnosis:** Uterine synechiae (Asherman's syndrome).

**Self-assessment**

- ◆ Common causes of uterine synechiae (p. 459).
- ◆ Other methods of diagnosis (p. 468, 469).
- ◆ Management of uterine synechiae (p. 472).
- ◆ Uterine causes of amenorrhea (p. 457).
- ◆ *In what conditions of amenorrhea karyotyping is needed?*

**Ans.** (i) Patients with uterus but no breasts and high FSH level—Gonadal failure (p. 452). (ii) Patients with no uterus but breasts present – Androgen insensitivity syndrome (p. 443). (iii) Premature ovarian failure if



**Fig. 37.73:** Hysterosalpingogram showing intrauterine adhesion. A case of tuberculous endometritis. [Courtesy by Dr H Roy, Patna]

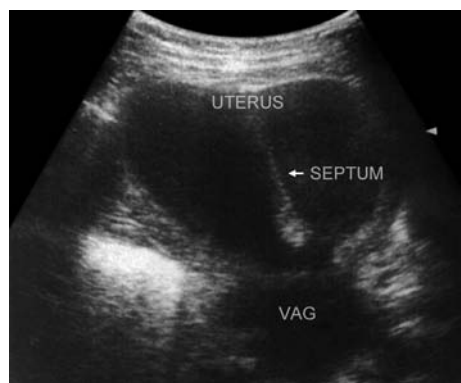< 30 years of age (p. 454). (iv) Short stature (<60") with Turner Stigmata – Turner's syndrome (p. 441).

**SEVEN (FIG. 37.74)**

Ultrasonographic view of a septate uterus.

**Self-assessment**

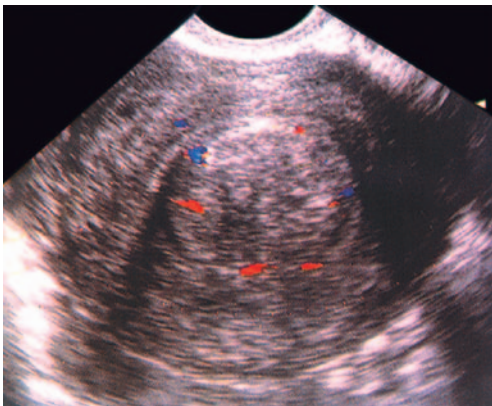
- ◆ What are the different types of uterine abnormalities? (p. 44).
- ◆ What may be the clinical presentation of such a case? (p. 45).
- ◆ What are the different obstetric complications? (p. 45).
- ◆ What are the different modes of diagnosis?(p. 47).
- ◆ What are the treatment options available? (p. 47).



**Fig. 37.74:** Ultrasonographic view of a septate uterus

**EIGHT (FIG. 37.75)****Self-assessment**

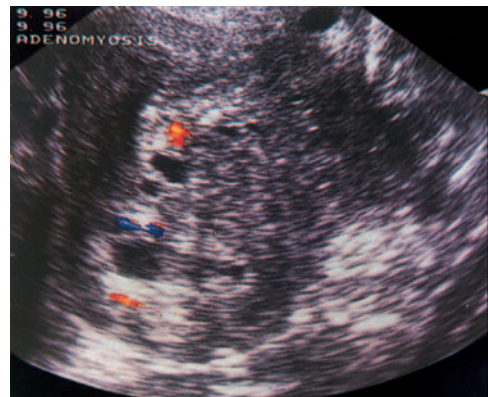
- ◆ What are the causes of symmetrical enlargement of the uterus? (p. 278, Table 19.5)
- ◆ How a couple should be counselled before proceeding to myomectomy? (p. 284).
- ◆ What are the principal steps of myomectomy? (p. 604).
- ◆ What are the measures that can be adopted to minimize blood loss in myomectomy operation? (p. 604).
- ◆ What are the different types of surgery for myomectomy? (p. 284).
- ◆ What are the common complications of myomectomy? (p. 605).
- ◆ What are the long-term results of myomectomy in respect of recurrence and others? (See page 284).



**Fig. 37.75:** Ultrasonographic (TV) view of a leiomyoma

**NINE (FIG. 37.76)****Self-assessment**

- ◆ Mention the different modalities of treatment options for pelvic endometriosis (p. 309).
- ◆ **What are the common sites of pelvic endometriosis?** (p. 305).
- ◆ Mention the indications and the different types of surgery that can be done for endometriosis (p. 312).
- ◆ How do you manage a case of chocolate cyst (ovarian endometrioma) of the ovary? (p. 306).
- ◆ What are the different hormones used in the management of endometriosis? (p. 310).
- ◆ Treatment of scar endometriosis (p. 313).
- ◆ How fibroid uterus could be differentiated from adenomyosis? (see Table below).



**Fig. 37.76:** Sonographic view of adenomyosis showing diffusely enlarged uterus with cystic spaces

#### DIFFERENTIATING FEATURES OF FIBROID UTERUS AND ADENOMYOSIS

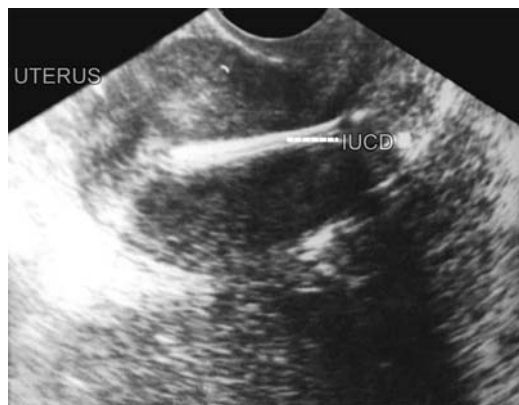	Fibroid uterus (Fig. 37.75)	Adenomyosis (Fig. 37.76)
<b>Age</b>	• Usually observed in the <b>reproductive age</b>	• Commonly seen in women <b>older than 40 years</b>
<b>Pathology</b>	• It is the benign neoplasia of the smooth muscle and fibrous tissue of the uterus	• It is due to the presence of functioning endometrium within the muscle layers of the uterus
<b>Uterus</b>	• Irregularly enlarged depending upon the site, size and number of myomas. It is firm and non-tender (unless degeneration)	• Diffusely enlarged due to myohyperplasia. Uterus is soft and tender
<b>Symptoms</b>	• Menorrhagia and dysmenorrhea — often present	• Menorrhagia—present. Dysmenorrhea often begins a week before and it continues even after the period is over
<b>Diagnosis</b>	<ul style="list-style-type: none"> <li>• <b>Sonography (TVS)</b> — homogeneous echogenic area over the fibroid</li> <li>• <b>Cut section:</b> Capsule present, smooth and whitish surface with whorled appearance</li> <li>• <b>Histology:</b> Proliferation of smooth muscle and fibrous tissue</li> </ul>	<ul style="list-style-type: none"> <li>• Cystic spaces within the myometrium</li> <li>• Absence of endometrial-myometrial junctional zone <b>on MRI</b> is diagnostic</li> <li>• <b>Capsule absent.</b> Diffuse trabeculated appearance, cystic spaces with hemorrhagic spots</li> <li>• Proliferation of endometrial glands and stroma. Phagocytic cells laden with hemosiderin pigment are present (p. 308, 317).</li> </ul>

**TEN (FIG. 37.77)**

Ultrasonographic view of Cu T inside the uterine cavity. Thread was missing in this case.

**Self-assessment**

- ◆ What are the possible causes of missing thread? (p. 484).
- ◆ How do you investigate such a case with missing thread? (p. 484).
- ◆ What are the indications of removal of IUDs? (p. 484).
- ◆ What are the complications of IUD use? (p. 482).
- ◆ What are the specific advantages of the third generation of IUDs over the others? (p. 483).



**Fig. 37.77:** Ultrasonographic view of a Cu T inside the uterine cavity, in a case of missing thread

**ELEVEN (FIG. 37.78)**

Hysterosalpingogram showing markedly dilated tube with retention of dye (right).

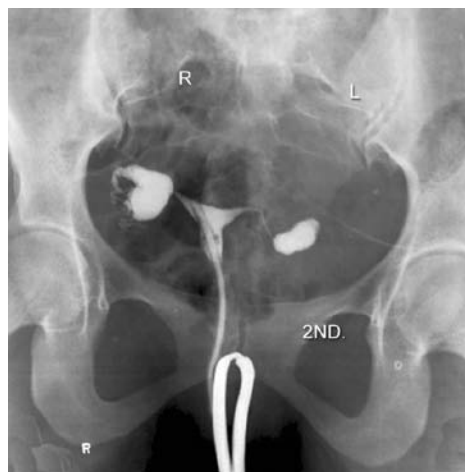**Diagnosis:** bilateral hydrosalpinges.

**Self-assessment:**

*What are the other methods of diagnosis?*

**Ans.** USG, laparoscopy.

- ◆ Dangers of HSG in such a case (p. 588).
- ◆ What are the common types of tubal reconstructive surgery? (p. 237).
- ◆ What factors are related to the success of tuboplasty? (p. 248).
- ◆ What are the guidelines for tubal surgery? (p. 248).



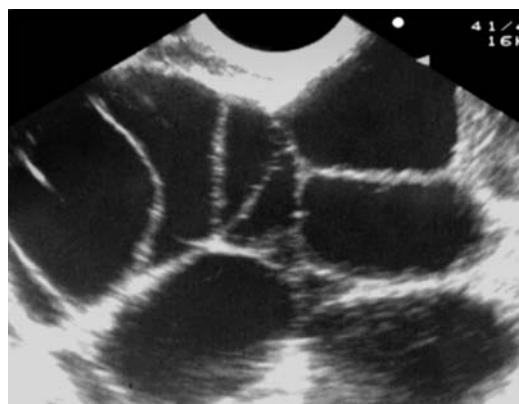**Fig. 37.78:** Hysterosalpingogram showing markedly dilated tube with retention of dye. Bilateral hydrosalpinges [Courtesy by: Dr H Roy, Patna]

**TWELVE (FIG. 37.79)**

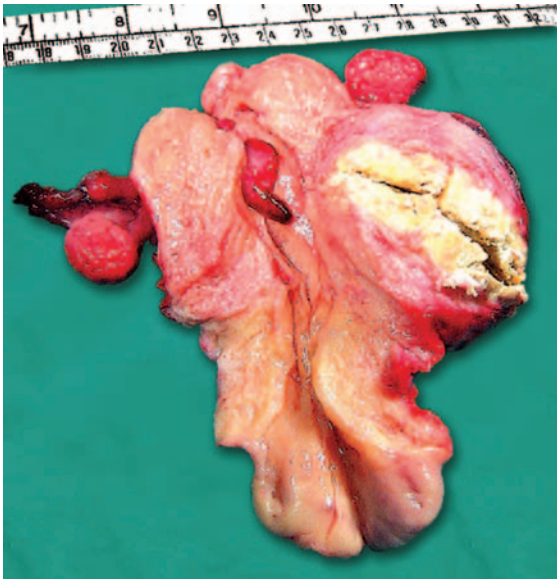Ultrasonographic view of the ovary following hyperstimulation syndrome (OHSS). Multiple follicles are seen.

**Self-assessment**

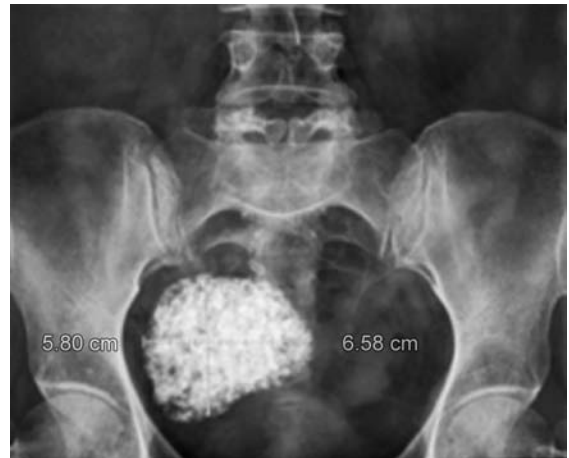- ◆ What are the different grades and the clinical features of OHSS? (p. 529).
- ◆ How could this problem be prevented? (p. 529).
- ◆ Indications of use of gonadotrophins in infertility (p. 527, 528).
- ◆ What is ovarian reserve? (p. 528).
- ◆ Who are the high responders? (p. 528).
- ◆ What is coasting? (p. 528).
- ◆ How do you manage a case of OHSS? (p. 529).



**Fig. 37.79:** Sonographic view of OHSS

**THIRTEEN (FIGS 37.80A AND B)**

**Fig. 37.80A:** Specimen of a uterus, tubes and ovaries cut opened to show multiple fibroids of the uterus. The uterine cavity is enlarged. The fibroid is cut to show the calcific degeneration (womb stone) within it



**Fig. 37.80B:** Plain X-ray of the pelvis and lower abdomen showing the calcific degeneration of a fibroid (popcorn appearance)

**Self-assessment**

- ◆ What are the secondary changes in a fibroid? (p. 275) ?
- ◆ What are the degenerations in fibroid? (p. 275)

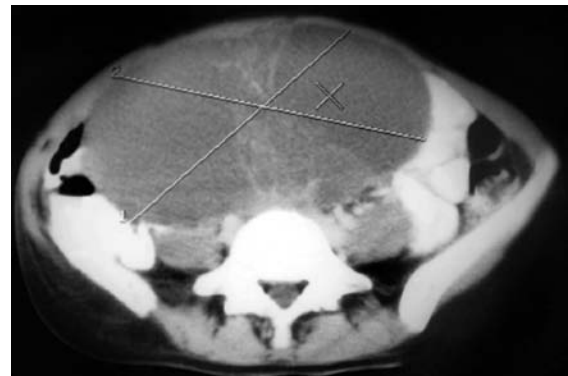**FOURTEEN (FIG. 37.81)**

Computed tomographic view of an ovarian tumor.

**Self-assessment**

- ◆ What special advantages CT has got in gynecology? (See p. 118).
- ◆ Place of sonography and positron emission tomography (PET) in the management of ovarian malignancy.
- ◆ As a diagnostic aid how magnetic resonance imaging (MRI) is useful in gynecology? (p. 119)
- ◆ *What is the value of CT in the evaluation of pelvic or periaortic lymph node metastasis?*

**Ans.** For most pelvic malignancies lymph nodes more than 8 mm in maximum short-axis dimension (MSAD) are regarded as abnormal. CT is helpful to



**Fig. 37.81:** Computed tomographic (CT) view of an ovarian tumor

detect retroperitoneal metastatic nodes. However, results may be false-negative due to micrometastasis or false-positive due to lymphadenitis or reactive hyperplasia.



**FIFTEEN (FIG. 37.82)**

CT of the brain in a patient with choriocarcinoma, showing metastasis.

**Self-assessment**

◆ *What are the common sites of metastasis in choriocarcinoma?*

**Ans.** • Lungs (80%); • Anterior vaginal wall (30%); • Brain (10%); • Liver (10%) and others.

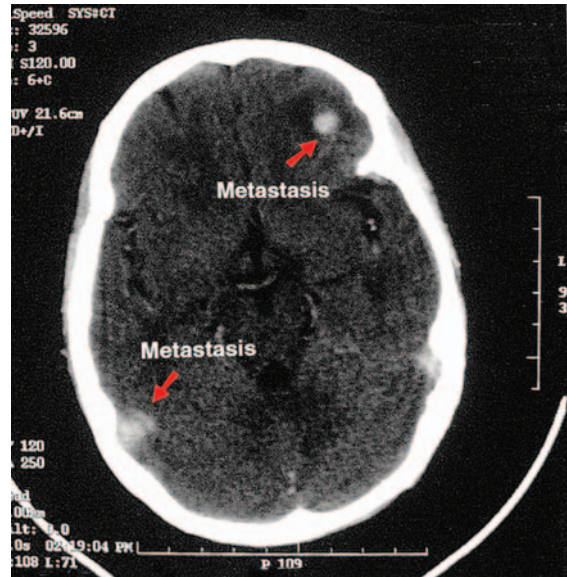
◆ *What is the significance of metastasis?*

**Ans.** (1) Site of metastasis is related to the prognosis of the disease (see p. 356), e.g. metastasis in lungs and pelvis is of low score, whereas brain metastasis puts the patient into high score disease.

(2) Number of metastasis is also prognostically related. More the number, higher the score. (WHO prognostic scoring, p. 356). Such patients need combination drug regimen, whole brain radiation therapy.

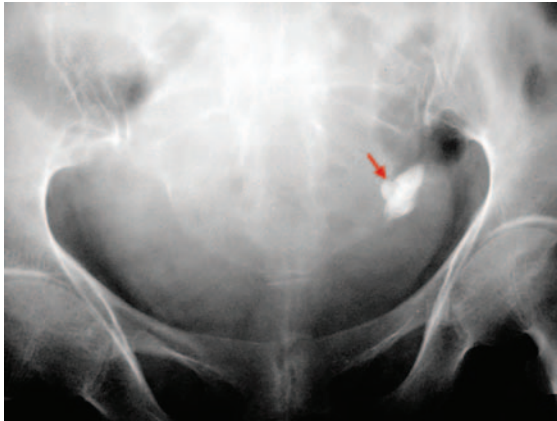
◆ *How do the patients usually present?*

**Ans.** Common symptoms are: III health, irregular vaginal bleeding. Symptoms due to metastases are: cough, breathlessness, haemoptysis (Lung); headache,



**Fig. 37.82:** CT view of the brain, in a patient with choriocarcinoma, showing metastasis (arrow)

convulsion, paralysis or coma for cerebral metastases and epigastric pain, jaundica for liver metastases.

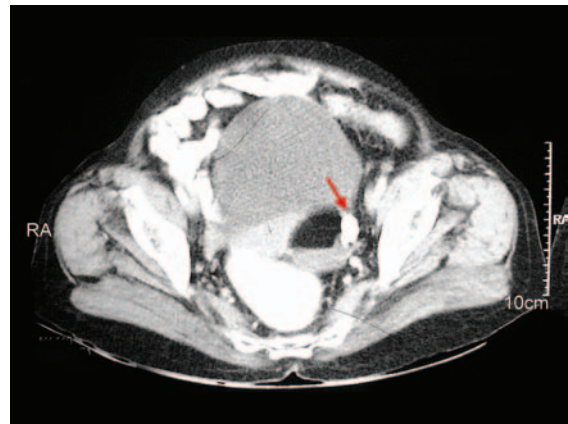
**SIXTEEN (FIGS. 37.83A AND B)**

**Fig. 37.83A:** Straight X-ray of the abdomen and pelvis with an ovarian tumor showing (arrow) the shadow of a tooth (Dermoid cyst)

**Self-assessment**

◆ Describe the cut section of an ovarian dermoid cyst (p. 293).

◆ Typical findings of an ovarian dermoid cyst in CT.



**Fig. 37.83B:** Computed tomographic view of the abdomen and pelvis of the same woman as in Figure 37.83A showing the tooth (Dermoid cyst of the ovary)

**Ans.** Characteristics of a dermoid cyst in CT include the mixture of low density areas due to fat, high density areas from dental elements or calcification (arrow) and a fat-fluid level.

◆ *What is the limitation of USG?*

**Ans.** Compared to CT or MRI, USG is not sufficient for accurate staging of any pelvic malignancy.

**SEVENTEEN (FIG. 37.84)****Self-assessment**

◆ *How normal endometrium and myometrium could be studied with MRI?*

**Ans.** With MRI endometrium is shown as the inner zone of high-signal-intensity stripe. The deeper myometrium is recognized as a very-low-signal intensity zone. The junctional zone demarcates the two (Fig. 37.83). The myometrium appears as the intermediate signal-intensity zone. In postmenopausal women, the contrast between the junctional zone and the myometrium decreases.

◆ *What special advantages MRI has got in gynecology?*

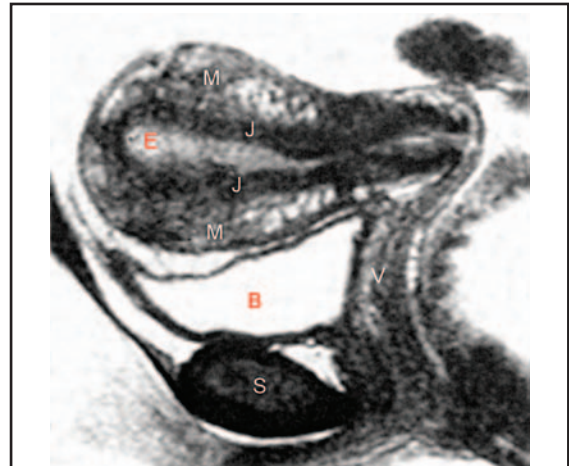
**Ans.** 1. MRI offers multiplaner images.

2. Gadolinium enhanced  $T_1$ -weighted images can determine.

- (i) Depth of myometrial invasion. (ii) Pelvic and periaortic (retroperitoneal) nodal metastasis in cervix endometrial carcinoma. (iii) Invasion of malignant process in the cervix accurately (p. 118, 119). (iv) It can detect recurrence of


pelvic tumor. (v) It is superior to CT in detecting metastatic nodes (p. 119).

3. MRI is safe in pregnancy

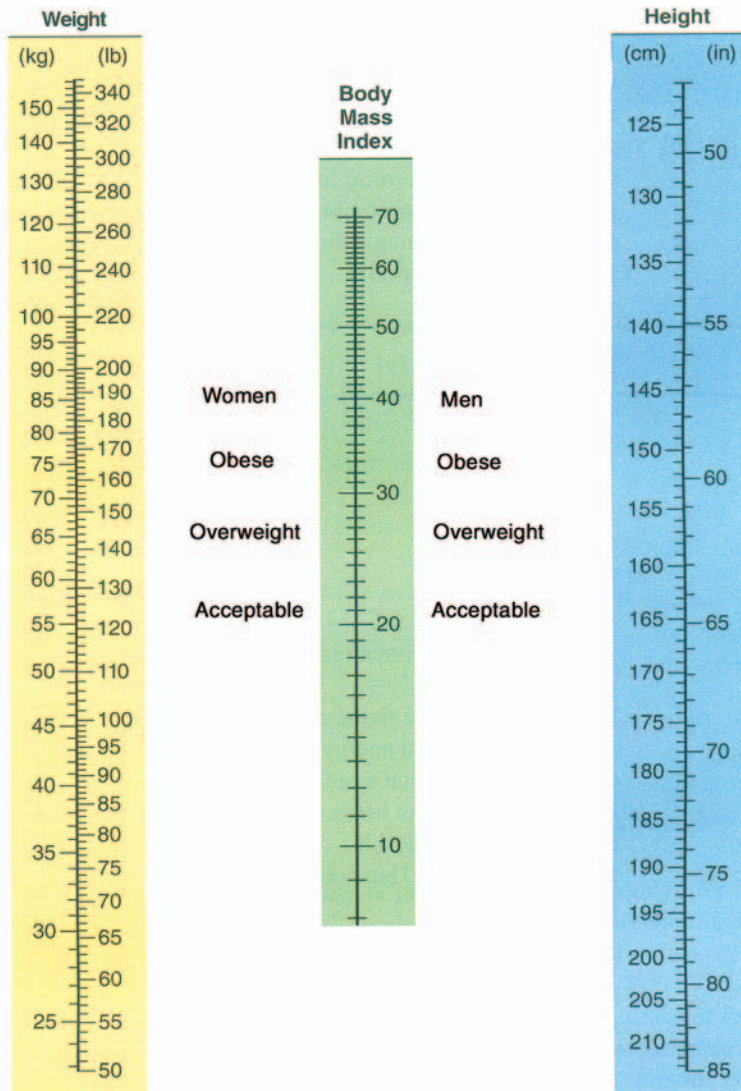


**Fig. 37.84:** MRI plate of a normal uterus on a sagittal  $T_2$ -weighted spin-echo image showing endometrium (E), the junctional zone (J), the myometrium (M), urinary bladder (B) and the vagina (V)

**TABLE 37.1: NOMOGRAM FOR CALCULATING BODY SURFACE AREA OF ADULTS**



**TABLE 37.2: NOMOGRAM FOR CALCULATING BODY MASS INDEX**



# Index

*Page number followed by t and f indicate table and figure respectively*

## ■ ■ A ■ ■

- 3 $\alpha$ -Androstenediol-glucuronide (3a AG), 572
- 5 $\alpha$  reductase, 439
- Abdominal examination, 100
- Abdominal pain, 307
  - cyclical, 557
  - differential diagnosis, 557, 558
  - in ectopic pregnancy, 557
  - in PID, 127
  - lump, 568
  - post-operative, 598, 611
- Abnormal menopause, 64
- Abortion,
  - anatomical factors, 45
  - recurrent spontaneous, 45
- Abscess,
  - pelvic, 170
  - tubo-ovarian, see Tubo-ovarian abscess, 129
- Acanthosis nigricans, 263, 459
- Acetowhite changes, cervix, 324, 325
- Acne, 527, 549
- Acquired immune deficiency syndrome (AIDS), 153
- Actinomycosis, 144
- Activins, 68, 76, 92
- Acyclovir, 153
- Adenoacanthoma endometrial, 309, 372
- Adenocarcinoma,
  - cervix, 339
  - clear cell (adeno) carcinoma, 339
  - endometrial, 354
  - ovary, 370
  - vulva, 333
- Adenocarcinoma-in-situ (AIS),
  - vulva (Paget's disease), 319
- Adenoma malignum, cervix, 340
- Adenoma pituitary, 464
- Adenomyosis, 314, 647, 648f, 660
- Adenosis, vaginal, 547
- Adenylate cyclase, 67
- Adhesions, chlamydial infections, 121f, 148
- Adiana, 502
- Adjuvant therapy, 244, 248, 386, 539
- Adnexal mass, 545
- Adolescents, 542, 546
  - menstrual disorders, 546
  - neoplasm, 547
  - obesity, 549
  - ovarian mass, 547
  - STDs, 549
- Adrenal cortex, 76
  - androgen, 75
  - androgen-secreting tumours, 441, 466
- Adrenal glands, 76
- Adrenal hyperplasia,
  - congenital, 440
  - late onset, 466
- Adrenarche, 49
- Adrenocortical hormones, 71, 538
- Adrenocorticotrophic hormone (ACTH), 71
- Adrenogenital syndrome, 440
- Age, gynecologic problems, 54, 542
- AIDS, 153
- Albright's syndrome, 51
- Alkylating agents, 513, 516
- Allis tissue forceps, 634
- Alopecia, 514
- Alzheimer's disease, 60
- Ambiguous genitalia, 444, 445

- Amenorrhoea, 449  
 causes, 450, 451, 457, 458t  
 classification, 449  
 exercise-related, 451  
 hyperprolactinaemic, 459, 461, 464  
 hypothalamic, 463  
 in hypothalamic pituitary disorders, 451, 458t  
 in ovary failure, 463  
 investigations, 467t, 468  
 lactational, 449  
 management, 469  
 pathological, 450  
 physiological, 449  
 post-pill, 466  
 primary, 450  
   definition, 450  
 secondary, 457  
 weight related, 463  
   anorexia nervosa, 464
- American Fertility Society Classification for Endometriosis, Revised, 309t
- Aminoglutethimide, 471
- Amnion vaginoplasty, 44
- Amputation cervix, 592
- Anemia, cytotoxic drug therapy, 515t
- Anal canal, 16
- Analgesia,  
   patient-controlled (PCA), 584  
   postoperative, 584
- Analgesics, in urinary tract, 409
- Analogues GnRH, 527
- Anastrozole, 310, 533
- Androblastoma, 386
- Androgen insensitivity syndrome, 443, 445
- Androgen(s), 58, 75, 537, 571, 575t  
   hirsutism/virilization, 571  
   therapy, 571  
   excess, 460
- Androstenedione, 571, 573
- Aneuploidy, 326t
- Anorexia nervosa, 464
- Anosmia, 464
- Anovular menstruation, 95
- Anteflexion of uterus, 7, 201
- Anterior colporrhaphy, 211
- Anteversion of uterus, 201
- Anti-androgens, 535  
   in hirsutism, 574
- Antibiotics,  
   in bacterial vaginosis, 152  
   in chlamydial infection, 150  
   in gonococcal infections, 148  
   in PID, 133, 135  
   in syphilis, 149  
   in urinary tract infections, 412  
   prophylactic preoperative use, 581
- Anticholinergic drugs, in incontinence, 406, 407
- Anticoagulants,  
   postoperative therapy, 583
- Antiemetic therapy, 515, 519
- Anti-gonadotrophin, 530
- Anti-mullerian hormone (AMH), 35, 76, 443, 529
- Anti-oestrogens, 533
- Anti-progesterone (RU 486), 537
- Antisperm antibodies, 240, 249  
   in cervical mucus tests, 249  
   management, 249
- Antituberculous chemotherapy, 142
- Apareunia, 568
- Aphthous ulcer, 262
- Arcuate arteries, 26
- Argon laser, 123
- Aromatase inhibitors, 245, 533
- Artificial insemination, 250
- Artificial urinary sphincter, 405
- Ascites,  
   ovarian tumours, 301, 373-374
- Asherman's syndrome, 138, 459, 659
- Assisted reproduction, 243
- Assisted reproductive techniques (ART), 203
- Asthenozoospermia, 232
- Asymptomatic bacteriuria, 411
- Autocrine, 524
- Autoimmunity,  
   in endometriosis, 306  
   ovarian failure, 463
- Auvard's speculum, 629f
- Azithromycin, 150, 151
- Azoospermia, 232
- AZT (zidovudine), 156
- B ■**
- Backache, 561
- Bacterial vaginosis, 152
- Bariatric surgery,  
   obesity, 249

- Barr body, 440
- Bartholin's gland  
abscess, 162  
anatomy, 2  
carcinoma, 337  
cyst, 162  
lymphatic drainage, 31
- Bartholinitis, 161, 162
- Basal body temperature, 235
- Basal cell carcinoma, vulva, 324
- Behcet's disease, 262
- Bethesda classification, 113, 320
- Bethesda system, 113, 306
- Bicornuate uterus, 658
- Bimanual examination (palpation), 106
- Biodegradable, contraceptives, 502
- Biopsy, cervix, 589
- Biphosphonates, 61
- Bladder injury, repair, 630
- Bladder, urinary, 14
- Blood supply,  
pelvic organs, 26
- Boari flap procedure, 427
- Body image, altered, 608
- Body mass index (BMI), 549, 574, 666  
obesity; weight, 464
- Body surface area, 665
- Bonney's hood operation, 604
- Bonney's myomectomy hood/clamp, 604, 636f
- Borderline epithelial tumours, ovary, 301
- Botryoides sarcoma, 369
- Brachytherapy, 506  
afterloading system, 506  
interstitial, 506  
in vaginal cancer, 339  
in vulval cancer, 338  
intracavitary, 506  
in cervical cancer, 350, 506, 510  
in endometrial cancer, 358
- BRCA1 gene, 371, 520, 565
- BRCA2 gene, 371, 520, 565
- Breakthrough bleeding (BTB), 489
- Breast cancer, 564  
aetiology / risk factors, 565  
breast imaging, 565  
familial genetics, 565  
risk after HRT, 62  
screening women at risk, 564  
staging, 566
- Breastfeeding,  
contraceptive effects, 477, 478  
in HIV infection, 154
- Breasts, 561  
abnormalities of development, 562, 563  
accessory, 563  
anatomy, 561  
asymmetry, 563  
at puberty, 50  
biopsy, 566  
examination, 100  
fibroadenoma, 564  
fibrocystic disease, 564  
hypertrophy, 563  
in menopause, 58  
nipple discharge, 566  
self examination, 565
- Brenner tumours, 293
- Broad ligament,  
anatomy, 21  
cyst, 602  
fibroid, 277, 602
- Bromocriptine, 471
- Brunschwig's operation, 349
- Burch colposuspension, 403
- Burning vulva syndrome, 265
- Burns, electrosurgery causing, 613, 619
- Burst abdomen, 641
- Buserelin, 525t  
for uterine fibroid, 281  
in endometriosis, 311, 526



- CA125, serum, 377, 514
- Cabergoline, 471
- Caesium, 506
- Caffeine consumption, 182
- Calcitonin, 61
- Calcium (Ca), 60, 69
- Call Exner's body, 384
- Caloric restriction, 574
- Canal of Nuck, cysts of, 263
- Cancer, gene therapy, 520
- Candida albicans*, 110, 164
- Cannula, 636f

- Capronor, 502
- Carbon dioxide, in laparoscopy, 612
- Carbon dioxide laser, 123, 327
- Carboplatin, 515t, 516t
- Carcinoid tumour, ovary, 294
- Carcinoma,
- cervix, 339, 655
  - endometrium, 354, 655
  - fallopian tube, 369
  - in-situ*, 320
  - ovary, 370, 653
  - stump, 354
  - vagina, 337
  - vulva, 333, 654
- Carcinosarcoma, uterine, 368
- Cardinal ligaments, 22
- Caruncle, urethral, 413
- Carunculae myrtiliformes, 2
- Catheter, 629, 630
- Catheterisation, 109
- CD4lymphocytes, HIV infection, 154
- Cell cycle, 511
- Cell kinetics, 511
- Cellular tissues, in pelvis, 22
- Colpoperineorrhaphy, 213
- Centchroman, 501
- Cervical carcinoma, 339
- CIN, 320, 628
  - FIGO staging, 342
  - screening, 324
  - treatment, 346
  - microinvasive disease, 351t
- Cervical cytology, 110, 627
- Cervical dilator, 631
- Cervical hostility, 250, 532
- Cervical mucus, 114
- Cervicitis, 167
- Cervicography, 325
- Cervicopexy (sling), 221
- Cervical intraepithelial neoplasia (CIN), 320
- Cervix,
- amputation, 592
  - anatomy, 8
  - biopsy, 589
  - cauterization, 590
  - cervical carcinoma, 339, 655
  - complications, 346
  - diagnosis, 344
  - differential diagnosis, 346
  - histology, 340
  - incidence, 339
  - in-situ*, 320
  - LARVT, 352
  - smear, 111
  - spread, 341
  - stages, 342
  - stump, 354
  - conisation, 589
  - cyst, 269
  - dilatation, 622
  - dysplasia, 320
  - ectopy, 267
  - ectropion, 269
  - elongation, 270
  - fibroid, 604
  - mucous, 114
  - tear, 269
  - tuberculosis, 143
- Chancroid, 150
- Chemotherapy, 511
- alkalating agents, 513, 515
  - alkaloids, 514, 517
  - antibiotics, 513, 517
  - antimetabolites, 513, 516
  - biological, 514, 516t
  - dosage, 516t
  - hormones, 513, 518t
  - multiple agent, 513
  - platinum, 513, 516t
  - single agent, 512
  - taxanes, 513, 517t
  - toxicity, 514
- Chlamydia, 131, 150, 166t
- Chlorambucil, 516t, 518t
- Chocolate cysts, ovarian, 312
- Chorioadenoma destruens, 361
- Choriocarcinoma, 362, 383, 649
- Chorion gonadotrophins, 245, 521, 528
- CIN, 112, 320, 628
- Cisplatin, 379, 512, 513, 516
- Clamp, 638
- Clear cell adenocarcinoma, 355
- Climacteric, 57
- Clitoris, 1



- Cloaca, 34  
Clomiphene, 244, 533  
Cloquet's lymph node, 31  
Clue cells, f 152  
Coasting, 528  
COH, 252  
Coitus,  
    injury, 434  
    interruptus, 478  
    vulval/vaginal trauma, 436  
Colles' fractures, 60  
Collimation, 123  
Colorectal cancer, 371  
    hereditary non-polyposis (HNPCC), 371  
Colour Doppler ultrasound, 117  
Colpocleisis, 211  
Colpomicrohysteroscope, 122, 619  
Colpopexy, 221  
Colporrhaphy,  
    anterior, 211  
    posterior, 213  
Colposcopy, 115  
    cervix, 325  
    method, 115  
    terminology, 116, 325  
    vagina, 319  
    vulva, 318  
Colposuspension, 403  
Colpotomy, posterior, 176  
Complete perineal tear, 430  
Computerized tomography (CT), 118, 663  
Condylomata acuminata, 157  
Cone biopsy, 589  
    knife, 589  
    laser, 589  
Congenital adrenal hyperplasia (CAH), 440, 466  
Congenital anomalies, genital organs, 41  
Consent, informed, 581  
Continence, 397  
    stress, mechanism of, 398  
Contraceptives, 475  
    barrier methods, 476  
    centchroman, 501  
    condom,  
        female 476; male 476  
    copper T, 479  
    diaphragm, 477  
    emergency contraception, 492  
    fertility awareness based, 478  
    IUCDs, 479  
    implanon, 492  
    injectable steroids, 491  
    LNG-IUS, 480  
    methods, 475  
    mini pill, 491  
    morning after pill, 492  
    multiloal, 480  
    natural, 478, 479  
    nestorone, 501  
    nor plant, 492  
    post-coital, 492  
    prescription, 500  
    progestasert, 480  
    progestin only pill, 491  
    saheli, 501  
    sponge (Today), 478  
    sterilisation, 494  
        laparoscopic, 498  
        no-scalpel, 494  
        tubectomy, 496  
        vasectomy, 494  
    steroidal, 485  
    triphasic, 490  
Controlled ovarian hyperstimulation, 252, 525  
    coasting, 528  
    protocols, 526  
    super ovulation, 526  
Cornification index, 114  
Corticotrophin-releasing hormone (CRH), 67  
Corona radiata, 86  
Coronary artery disease, 59, 463  
Corpus albicans, 87  
Corpus cancer syndrome, 354  
Corpus luteum, 87  
Corticosteroid therapy, 445, 471, 538  
Counselling, 150, 494, 500, 581  
Craniopharyngioma, 451, 458  
Crohn's disease, 261  
Cryopreservation, 255  
Cryosurgery, 591  
Cryotherapy, 591  
Cryptomenorrhoea, 41, 450  
Cryptorchidism, 228  
CT scan, 118

- CECT, 465  
 Culdocentesis, 120  
 Culdoplasty (McCall), 216, 211  
 Culdoscopy, 122  
 Curettage, uterine, 585  
 Cusco's bivalve speculum, 628f  
 Cushing's syndrome/disease, 466  
 Cycle,  
   endometrial, 90  
   ovarian, 84  
 Cyclofem, 501  
 Cyclophosphamide, 516, t 30.6 and 30.7  
 Cyproterone acetate (CPA), 535, 575  
 Cystic glandular hyperplasia, 188, 329  
 Cystitis, 412  
 Cystocele, 204, 209, 211, 213  
 Cystometry, 400  
 Cystoscopy, 122, 401  
 Cysts (see also individual organs)  
   atretic, 89  
   cervical, 269  
   chocolate, 312  
   dermoid, 293  
   follicular, 289  
   lutein, 289  
   Nabothian, 269  
   ovarian, 289  
   parovarian, 302  
   vaginal, 264  
   vulva, 263  
 Cytobrush, 627f  
 Cytology, cervical, vaginal, 110  
 Cytotoxic drugs (chemotherapy), 515
- ■ D ■ ■
- Danazol, 311, 530  
 Day surgery, 582  
 DDA VP (desmopressin), 406  
 Decubitus ulcer, 206  
 Deep inguinal lymph node, 29  
 Dehydroepiandrosterone (DHA), 571  
 Dehydroepiandrosterone sulphate (DHAS), 571  
 Delayed puberty, 54, 451  
 Dementia, 60  
 Depo-provera (depot medroxyprogesterone acetate), 491  
 Depression, 60, 489  
 Dermoid cyst, 293  
 Desogestrel, 491  
 Detrusor,  
   overactivity, 406  
   innervation, 394  
   instability, 407  
     drug therapy, 406  
     investigations, 407  
 Development,  
   female genital organs, 35  
 Dexamethasone suppression test, 466  
 Diabetes insipidus, 470  
 Diagnostic procedures, 108  
 Diaphragm, pelvic, 17  
 Diathermy, 613  
   bipolar, 613  
   monopolar, 613  
 Diethylstilboestrol (DES), 547  
 Dihydrotestosterone (DHT), 571  
 Dilatation, 585  
   cauterisation, 590  
   curettage, 585  
   DNA, HPV, 323  
   insufflation, 587  
 Dilators, cervical, 631  
 Discharge, vaginal, 551  
   abnormal, 553  
   normal, 552  
 Discus proligerus, 85  
 Distension media, 620  
 Docetaxel (Taxotere), 379, 518, (t 30.7)  
 Doderlein's bacillus, 7  
 Donor insemination, 250  
 Donovan bodies, 151  
 Dopamine,  
   agonists, 471  
   antagonists, 464  
 Doppler ultrasound, 117  
 Douglas, pouch of, 20  
 Doxorubicin (Adriamycin), 516, 517 (t30.6, 30.7)  
 Drappings, 582  
 Drospirenone, 485, 535  
 Drugs,  
   hirsutism-inducing, 573 (t33.13)  
   hyperprolactinaemia due to, 465  
   male infertility due to, 229

- masculinization of female fetus by, 441
  - resistance, 513
  - voiding disorders caused by, 409
  - DVT, 598
  - Dydrogesterone, 536
  - Dysfunctional uterine bleeding, 187
  - Dysgerminoma, 381
  - Dyskaryosis, 112, 627
  - Dysmenorrhoea, 178
    - aetiology, 178
    - congestive, 181
    - ovarian, 181
    - primary (spasmodic), 178
    - treatment, 179
    - unilateral, 181
  - Dyspareunia, 568
  - Dysplasia, cervical, 320
  - Dystrophies, vulval, 259
  - Dysuria, 413
- ■ E ■ ■**
- Ectopy, cervical, 267
  - Ectropion, cervix, 268
  - Ejaculation,
    - premature, 229
    - retrograde, 242
  - Electrocardiography, preoperative, 580
  - Electrocautery, cervix, 590
  - Electrolysis, 576
  - Elephantiasis vulvae, 576
  - Elongation, cervix, 270
  - EMA/CO regimen, 366
  - Embolism, carbon dioxide, 623
  - Embolization, postoperative, 596
  - Embolotherapy, 281
  - Embryo,
    - cryopreservation, 255
    - donation, 254
    - transfer, 254
  - Embryo or oocyte donation, 254
  - Embryoma, 291
  - Encephalitis, 51
  - Endodermal sinus tumour, 383
  - Endo GIA stapling devices, 613
  - Endometrial ablation, 193
    - complications, 596
    - endometrial preparation for, 622
    - indications, 193
    - microwave, 195
    - novasure, 195
    - rollerball technique, 195
    - thermal balloon, 193
  - Endometrial biopsy, 120
  - Endometrial carcinoma,
    - aetiology, 354
    - diagnosis/investigation, 356
    - familial, 355
    - management, 357, 655
    - surgery, 358
    - tamoxifen therapy, 355, 359, 534
  - Endometrial carcinoma, prognostic index for, 360
  - Endometrial sampling, 120
  - Endometriosis, 304
    - aetiology, 305
    - clinical features, 306
    - definition, 304
    - endocrinopathy, 309
    - endometriomas, 312
    - pathology, 306
    - scoring APS, 309
    - sites, 305
    - stromal, 316
    - treatment, 309
  - Endometritis, 168
    - acute, 168
    - chronic, 168
    - senile, 168
  - Endometrium, 8
    - biopsy, 120
    - carcinoma, 354
    - cyclic changes, 88
    - hyperplasia, 194, 329
    - polyp, 385
    - stromal sarcoma, 367
  - Endopelvic fascia, 23
  - Endorphins, 68
  - Endoscopy, in gynaecology, 611-624
  - Enterocoele, 205, 211, 213, 220, 221
  - Epidermal growth factor (EGF), 76, 272
  - Epidermidization of cervix, 322
  - Epimenorrhoea, 185
  - Epoophoron, 36

- Erosion cervix, 267
- Erythromycin, in pelvic infections, 150, 151
- Essure, 502
- Ethinyl oestradiol, 531
  - in emergency contraception, 486
  - in oral contraceptives, 486
- Etoposide, 517 (t 30.6)
- Examination of patient, 98
  - abdominal, 100
  - anaesthesia, under, 123
  - bimanual, 106
  - breasts, 100
  - clinical, 99
  - digital, 105
  - pelvic, 104
  - rectal, 107
  - rectovaginal, 108
  - speculum, 105
  - urine, 109
  - vaginal, 105
- Examination under anaesthesia, 123
  - cervical cancer, 340
  - fistulae, 419
- Exenteration, pelvic, 348
- External genitalia, 1
- ■ F ■ ■**
- 5-Fluorouracil, 516 (t 30.6), 518 (t 30.7)
- Fallopian tubes
  - anatomy, 10
  - carcinoma, 368
  - insufflation, 587
  - infection, 137, 147, 169
  - ligation, 494
- Fallopscopy, 239
- Falope ring, 498
- Familial breast/ovarian cancer
  - genetics, 371, 520, 564, 652
- Family planning
  - natural, 478
- Fascia
  - endopelvic, 22
  - pubocervical, 23
- Fecundity, 227
- Feminising tumours of the ovary, 384, 652
- Fenton's operation, 592
- Fern test, 115
- Fertility, awareness method, 478
- Fertilization, *in vitro*, 251
- Fibroid (fibromyoma, myoma), 272
  - broad ligament, 273
  - capsule, 274
  - cervical, 274, 284
  - complications, 276
  - clinical features, 276
  - degenerations, 275
  - diagnosis, 278, 660 t
  - histology, 275
  - incidence, 272
  - myomectomy, 281, 604, 623
  - polyps, 285
  - treatment, 279, 618
  - secondary changes, 275
  - types, 273
  - wandering, 273
- Fibroplant, 484
- FIGO staging
  - cervical cancer, 342
  - endometrial cancer, 357
  - gestational trophoblastic tumour, 357
  - ovarian cancer, 374
  - vaginal cancer, 338
  - vulval cancer, 336
- Filshie clip, 497
- Fimbrial cyst, 48
- Fimbrioplasty, 247
- Finasteride, in hirsutism, 538, 576
- Fine-needle aspiration cytology (FNAC), 566
- Fistulas
  - classification, 417
  - recto-vaginal, 427
  - surgical repair, 421, 422
  - urethro-vaginal, 424
  - uretero-vaginal, 424
  - vesico-vaginal, 417
- Fitz-Hugh-Curtis syndrome, 121 (f 9.24), 129-130
- Flora of vagina, 6
- Fluconazole, 165
- Fluoxetine, 183
- Flutamide, in hirsutism, 538, 576
- Follicle, ovarian
  - atresia, 89
  - dominant, 85
  - graafian, 85

growth, 82  
 ovulation, 86  
 recruitment, 84  
 selection and dominance, 85  
 structures, 86  
 Follicle-stimulating hormone (FSH), 70, 243  
   purified preparation, 243  
   recombinant human, 243  
 Follicular atresia, 89  
 Follicular cyst, 289  
 Forceps, 633, 634, 639, 640  
   dissecting, 640 f  
   ovum, 634 f  
   sponge holding, 633 f  
   uterine dressing, 633 f  
 Foreign bodies  
   uterus, 436  
   vagina, 436  
 Fothergill's operation, 216  
   complications, 223t  
 Fourchette, 1  
 Fractional curettage, 357  
 Frankenhauser's plexus, 32  
 Frequency of micturition, 407  
   treatment, 407  
 Frequency / volume chart, 400  
 Furunculosis, 160


■ G ■

Gabapentine, 61  
 Galactorrhea, 464  
 Gamete intrafallopian transfer (GIFT), 253  
 Gamma rays, 506  
 Gamma-aminobutyric acid, 182  
*Gardnerella vaginalis*, 152  
 Gartner's duct cyst of, 47, 210, 264  
 GAX collagen injections, periurethral, 402  
 Gene therapy, 521  
 Genetics, cancer, 371, 520  
 Genital crisis, 543  
 Genital organs, defense, 126  
 Genital prolapse, 201-223  
 Genital tubercle, 36  
 Genital tuberculosis, 137  
 Genitalia, external  
   ambiguous, 440, 547  
   development, 34


Germ cell tumour, ovary, 291, 381  
 Germ cells, 37, 82  
 Gestational trophoblastic disease (GTD), 361  
 Gestrinone, 531  
 Gilliam's operation, 201, 603  
 GnRH analogues, 252, 525  
   agonist, 525  
   antagonists, 246, 527  
   hazards, 527  
   uses, 525  
 Gompertzian growth, 512  
 Gonad, development, 37  
 Gonadal dysgenesis, 441  
 Gonadoblastoma, 383  
 Gonadotrophin-releasing hormone (GnRH), 66, 246, 525  
 Gonadotropins, 70, 245, 527  
 Gonorrhoea, 147  
 Goserelein, 525  
 Gossipol, 503  
 Graafian follicle, 85  
 Granuloma inguinale, 151  
 Granulosa cell tumour, 384  
 Granulosa cells, 72  
 Granulosa lutein cyst, 289  
 Grape like sarcoma, 369  
 Grays (Gy), 507  
 Growth factors,  
   uterine fibroids, 272  
 Growth hormone (GH), 245, 549  
 Guidelines, 248, 378, 571  
 Gynandroblastoma, 384  
 Gynefix, 502

■ H ■

11-Hydroxylase deficiency, 440, 466  
 21-Hydroxylase deficiency, 440, 466  
 HAART, 156  
 Hematocolpos, 42, 450  
 Hematoma, vulva, 436  
 Hematometra, 42, 450  
 Hematosalpinx, 450, 651  
 Hematuria, 401  
*Haemophilus vaginalis*, 152  
 Hemorrhage, postoperative  
   primary, 222, 597  
   secondary, 222, 597


- Hair growth, 571  
 genetic/ ethnic influences, 573  
 hormonal influences, 573  
 pubic, development, 49  
 removal, 576
- HAIR-AN syndrome, 459
- Haultain's operation, 602
- Heparin  
 thromboembolism prophylaxis, 582, 598
- Hepatitis B virus (HBV) screening, 581
- HER-2/neu, in ovarian cancer, 521t
- Hermaphrodite, 444
- Hernia, incisional, 599, 619
- Hernia, inguino labial, 263
- Herpes genitalis, 152
- Herpes zoster, 160
- Hirsutism, 547, 571
- History,  
 in gynaecology, 99  
 preoperative, 580
- HIV, 153
- Hormone replacement therapy (HRT), 61  
 monitoring, 62  
 preparations, 62  
 risks, 62
- Hormone therapy, in gynaecology, 513
- Hormones,  
 in gynaecology, 513  
 mechanisms of action, 69f, 73f  
 serum values, 79t  
 steroid, 72
- Hot flushes, 59
- HPV, *see* Human papilloma viruses, 323, 326
- H-Y antigen, 38, 439
- Hydatidiform mole, 361, 648
- Hydradenoma, 264
- Hydrocolpos, 544
- Hydrosalpinx, 170, 650
- Hymen, 2
- Hyperandrogenism, 573t
- Hyperinsulinaemia, 461  
 in hyperandrogenism, 571  
 in polycystic ovarian syndrome, 459
- Hyperprolactinaemia, 464, 471, 576
- Hyperthyroidism, menorrhagia, 185
- Hypertrichosis, 571
- Hypogastric artery ligation, 606
- Hypogonadism  
 hypergonadotrophic, 54, 451  
 causes, 54, 451
- Hypomenorrhoea, 187
- Hyponatraemia, 441
- Hypothalamic hormones, 67, 525
- Hypothalamo-pituitary-ovarian axis, 78f
- Hypothalamus, 66
- Hypothyroidism  
 amenorrhoea/oligomenorrhoea in, 187, 456
- Hysterectomy,  
 abdominal, 593  
 complications, 222, 596  
 indications, 593t  
 laparoscopic, 617  
 laparoscopic assisted vaginal, 617  
 subtotal, 593  
 total, 593  
 vaginal, 217, 599  
 Wertheim's (radical), 348, 579
- Hysteroflator, 620
- Hysterosalpingography, 238, 588, 636, 637
- Hysteroscopy, 122, 619  
 complications, 623  
 indications, 621
- 
- Identification of,  
 monilia, 111, 164  
*Trichomonas vaginalis*, 163
- Ifosfamide, 494t, 497t
- Imaging in gynecology, 116
- Imaging,  
 CT, 118, 663  
 HSG, 588, 657  
 MRI, 118, 664  
 PET, 119  
 X-ray, 116, 662  
 USG, 116, 660
- Imipramine, in incontinence, 406t
- Immotile cilia syndrome (Kartagener), 228t
- Immunotherapy, 519
- Implanon, 492
- Implant, biodegradable, 508
- Impotency, 228t, 243

- Incisions, 583  
 Cherney, 583  
 Maylard, 583  
 Pfannenstiel, 583  
 Vertical, 583
- Incontinence of,  
 feces, 431  
 urine, 398
- Index, body mass, 574, 666
- Induction of ovulation, 243, 533
- Infants, 542
- Infections, genital organs, 126  
 organisms concerned, 127, 137  
 postabortal and puerperal, 133  
 sexually transmitted, 146  
 tubercular, 137
- Infertility, 227  
 causes, 227  
 female factors, 229 (Scheme-1)  
 immunological, 240  
 investigations, 231  
 LUF, 230, 247  
 luteal phase defect, 229, 247  
 male factors, 228 t  
 prognosis, 255  
 secondary, 227  
 treatment, 240  
 unexplained, 227, 249
- Infundibulo pelvic ligament, 21
- Inhibins, 76
- Injury, bladder, 418, 630  
 perineal, 430  
 ureter, 425
- Innervation of genital organs, 31
- Insemination  
 intrauterine (IUI), 250  
 subzonal (SUZI), 251
- Instruments,  
 hysteroscopic, 620, 643  
 laparoscopic, 612, 643
- Insufflation cannula, 637
- Insulin resistance, 460, 470
- Insulin sensitiser, 244, 470
- Insulin-like growth factor 1 (IGF-I), 76, 92, 461
- Integrins, 306
- Interception, 492
- Interferons, 519
- Interleukin, 306
- Intermenstrual bleeding, 186 t
- Internal genital organs, 3
- Intersexuality, 439
- Intertigo, vulva, 161
- Intracytoplasmic sperm injection (ICSI), 254
- Intrauterine contraceptive devices (IUCD), 479, 502
- Intravenous urogram (IVU), 401
- Intravesical pressure, 400 t
- Invasive mole, 361
- Inverse square law, 506
- Inversion uterus, 223, 602
- In-Vitro* fertilization, 251  
 Doppler ultrasound, 117
- Irving method, 496 f
- Isoflavones, 61
- IUI, 250
- ■ K ■ ■**
- 17-Ketosteroid, 574
- Kallmann's syndrome, 228t, 451, 464
- Kartagener syndrome, 228t
- Karyotype, 441
- Karyotyping, 229, 233, 441
- Kelly sutures, 402
- Ketoconazole, in hirsutism, 538, 576
- Klinefelter's syndrome, 444
- Kobelt's tubule, 47
- Kocher's artery forceps, 636
- Koilocytosis, 112, 323f
- Krukenberg's tumour, 387, 654
- KTP (potassium titanylphosphate) laser, 123t
- Kustner's operation, 603
- ■ L ■ ■**
- Labia majora, 1
- Labial fusion, 440, 543
- Lactational amenorrhoea, 449
- Lamivudine, 156
- Landon's retractor, 637
- Laparoscopic hysterectomy (TLH), 617
- Laparoscopy, 121, 614  
 aspirator irrigator, 613  
 cameras, 612  
 chromopertubation, 238

- c lips, 613
  - complications, 619
  - contraindications, 615t
  - diagnostic, 121
  - electro cautery,
    - bipolar, 613
    - monopolar, 613
  - instruments, 612
  - insufflator, 612
  - morcellator, 613
  - operative, 617
  - ovarian drilling, 471
  - port, 616
  - procedures, 615
  - staples, 613
  - sterilization, 498
  - sutures, 613, 644
  - trocarr and cannula, 612
  - Veress needle, 612
  - Large loop excision (LLETZ), 328
  - Lasers, 123
    - common laser systems, 123
    - controlled area (LCA), 123
    - hazards, 124
    - physics, 123
    - uses, 123
  - Laurence-Moon-Biedl syndrome, 453
  - LAVH, 617
  - Lazko method of repair, 423
  - LeFort's operation, 221
  - Leiomyoma, 272
  - Leiomyomatosis
    - intravenous, 367
    - peritonealis disseminata, 368
  - Leiomyosarcoma, 367
  - Letrozole, 245, 533
  - Leukorrhea, 551
  - Leuprorelin, 525
  - Levator ani muscle, 17
  - Levator plate, 203
  - Levonorgestrel, 486
  - Leydig cells, 228
  - Libido, 62, 489
  - Lichen sclerosis, 261
  - Ligament,
    - broad, 21
    - cardinal, 22
    - infundibulo pelvic, 21
    - ovarian, 24
    - round, 23
    - uterosacral, 23
  - Lipshutz ulcer, 262
  - Liquid based cytology, 113
  - LLEP, 328
  - Lump, abdomino-pelvic, 568
  - Luteal follicular shift, 93
  - Luteal phase, inadequate, 237, 247, 253, 536
  - Luteal-placental shift, 89
  - Luteal support, 253
  - Luteinized unruptured follicle (LUF) syndrome, 237, 248
  - Luteinizing hormone, 71
  - Luteinizing hormone-releasing hormone, 67
  - Lymphadenectomy
    - laparoscopic, 349
    - pelvic, 348
    - vulval cancer, 607
  - Lymphatic drainage, 28-31
    - bladder, urethra, 31
    - cervix, 30
    - corpus, 29
    - ovarian, 30
    - vaginal, 30
    - vulval, 30, 335
  - Lymphogranuloma venerum, 151
  - Lynch I and II syndrome, 371
- 
- 6-Mercaptopurine (6MP), 513
  - MaCall culdoplasty, 216, 225
  - Mackenrodt's ligament, 22
  - Macrophage colony-stimulating factor (M-CSF), 515
  - Macrophages, peritoneal, in endometriosis, 306
  - Madlener's technique, 496f
  - Magnetic resonance imaging (MRI), 118
  - Mala N, 486t
  - Maldevelopment of genital organs, 41-48
  - Male,
    - contraception, 476, 503
    - infertility, 228-231, 242, 251
  - Mammography, 563
  - Manchester,
    - operation for prolapse, 216
    - technique of irradiation, 348
  - Marshall-Marchetti-Kranz operation, 404



- Marsupialization, Bartholin's cyst, 162  
 Martius graft, 423  
 Mastalgia, 95, 182, 489  
 Mc Cune-Albright syndrome, 51  
 Medroxyprogesterone acetate, 311t, 360, 471  
 Mefenamic acid, 179t, 192  
 Meig's syndrome, 296, 652  
 Melanoma  
   MSH, 71  
   vaginal, 338  
   vulval, 334  
 Melphalan, 516t  
 Menarche, 49  
 Menopause, 57  
   bone metabolism, 58  
   definition, 57  
   delayed, 64  
   endocrinology, 57  
   premature, 64, 463, 471  
   surgical, 64  
   symptoms, 59  
   treatment, 60  
 Menorrhagia, 185  
 Menstruation,  
   anatomic aspect, 82  
   anovular, 95, 188  
   cervical cycle, 96  
   definition, 82  
   endometrial cycle, 90  
   hormone in relation, 91  
   hygiene, 95  
   mechanism of bleeding, 91  
   ovarian cycle, 84  
   postponement, 95, 536  
   symptoms, 93  
   total blood loss, 82  
   vaginal cycle, 96  
 MESA, 515 (t 30.5)  
 Mesigyna, 501  
 Mesna, 516  
 Meso-ovarium, 21  
 Mesosalpinx, 21  
 Metal catheter, female, 630  
 Metformin, 243, 470  
 Methotrexate, 513, 516  
 Metritis, 168  
 Metronidazole, 152, 164  
 Metrophthia haemorrhagica, 188  
 Metroplasty, 47  
   abdominal (Tompkin's), 47  
   hysteroscopic, 47  
 Metrorrhagia, 186  
 Micromanipulation, 254  
 Micro-surgery, 243  
 Micturition  
   continence of urination, 397  
   incontinence of urine, 398  
   physiology, 395  
 Mifepristone (RU486), 492, 537  
 Minimally invasive surgery, 611  
 Minipill, 491  
 Mirena, 480, 484  
 Mitotane, 471  
 Mittelschmerz, 181  
 Mixed mesodermal tumour, 367  
 Molluscum contagiosum, 157  
 Monilial vaginitis, 146  
 Monoclonal antibodies, radiolabelled, 520  
 Morning after pill, 492  
 Mucinous cystadenom, ovary, 291, 295  
 Mucocolpos, 542  
 Müllerian duct, 35  
 Müllerian eminence, 36  
 Müllerian tubercle, 36  
 Müllerian-inhibiting factor (MIF), 39, 514, 529  
 Myelosuppression, cytotoxic, 516 (t30.6)  
 Myolysis, laparoscopic, 283  
 Myoma (see fibroid), 604, 272  
 Myoma screw, 635 f  
 Myomectomy, 281, 604  
   complication, 605  
   hysteroscopic, 283  
   laparoscopic, 623  
   results, 282  
 Myometrium, 8
- ■ N ■ ■**
- Nabothian cyst (follicle), 268  
 Nafarelin, 525 (t31.1)  
 Naproxen, 179, 191  
 Needlestick injuries, 156  
 Neisseria gonorrhoea (gonococcus), 147  
 Neoadjuvant therapy, 380  
 Neonates, 542

- Neovagina, methods of creation, 456
- Nestorone, 501
- Nestronone, 535
- Neurotransmitters, 67
- Nevirapine, 156
- Nickerson's medium, 110, 165
- Nipples,  
     accessory, 563  
     discharge, 566
- Nipples, discharge, 567 (t 33.11)
- Nocturia, 406
- Nomegestrol, 502
- Non-steroidal anti-inflammatory agents, 179, 192
- Norethisterone, 491, 534
- Norgestrel, 486, 534
- Norplant, 492
- Nuvaring, 501
- Nystatin, 165
- 
- Obesity, adolescent, 462, 464, 546, 573
- Oestrogen(s), 57, 72, 531  
     contraindication, 532  
     therapy, 31
- OHSS, 529
- Oligomenorrhoea, 186
- Oligospermia, 232
- Omentectomy, 378, 653
- Oncogenes, 520
- Oocyte, 82
- Oocyte donation, 254
- Oophoritis, 173
- Operations,  
     gynaecology, 585
- Opioids  
     endogenous, 68  
     in cancer, 353
- Oral contraceptives combined (COC), 485
- Orchidometer, 232
- Osteitis pubis, 404, 608
- Osteoporosis, 59
- Ovarian,  
     biopsy, 599  
     drilling, laparoscopic, 471, 602  
     remnant syndrome, 559  
     residual syndrome, 559  
     wedge resection, 601
- Ovarian agenesis, 441
- Ovarian cystectomy, 301, 599
- Ovarian cysts-non-neoplastic, 289
- Ovarian failure (POF), 452, 549
- Ovarian follicles, 83
- Ovarian fossa, 12
- Ovarian hyperstimulation syndrome (OHSS), 529
- Ovarian ligaments, 24
- Ovarian, pedicle, 298 (t 20.3)  
     androgens, 75, 460  
     cycle, 84  
     peptides, 76  
     torsion, 298 (t 20.4)
- Ovarian reserve, 528
- Ovarian tumour (Benign), 289  
     adolescence, in, 547  
     borderline, 301  
     Brenner, 293  
     childhood, in, 547  
     classification, 291  
     clinical features, 295  
     complications, 298  
     cystic, 291  
     diagnosis, of, 295  
     malignant, 370  
     management, 300
- Ovarian tumours, 291  
     epithelial  
         benign, 290  
         borderline, 301  
         malignant, 370, 653  
     feminising, 384, 652  
     germ cell, 381  
     masculinising, 386  
     sex cord stromal, 384  
     solid, 652
- Ovariolysis, 587
- Ovariotomy, 301, 600
- Ovary, 11  
     development, 37  
     endometriomas, 312  
     steroidogenesis, 71
- Overactive bladder, 406
- Overflow incontinence, 398
- Ovotestes, 444
- Ovulation, 92  
     diagnosis, 235

- failure of, 229
  - incessant, 371
  - induction of, 243
  - tests for, 240
  - Oxybutynin, 406
- P ■**
- Paclitaxel (Taxol), 380, 517 (t 30.6)
  - Pad tests, 400
  - Paget's diseases, vulva, 319
  - Pain,
    - biology, 555
    - bladder, 408
    - cervical cancer, 353
    - pelvic, 555
    - vulval, 264
  - Palliative care, 353
  - Panhysterectomy, 593
  - Papanicolaou grading, 112 (t 9.2)
  - Papanicolaou stain, 111
  - Papillary serous carcinoma, 371/372
  - Paracentesis, 376
  - Paracrine, 524
  - Paralytic ileus, 598
  - Para mesonephric ducts, 36
  - Parametritis, 173
  - Parametrium, 22
  - Paravaginal repair, 213
  - Paroophoron, 36
  - Parovarian cyst, 48, 302, 654
  - PCA, 584
  - Pediculosis pubis, 157
  - Pelvic abscess, 175
  - Pelvic cellular tissue, 21
  - Pelvic congestion syndrome, 181, 557
  - Pelvic diaphragm, 17
  - Pelvic examination, 104
  - Pelvic fascia, 21
  - Pelvic floor, 17
    - repair, 216
  - Pelvic inflammatory disease (PID), 127
  - Pelvic lymphatics, 28
  - Pelvic nerves, 31
  - Pelvic organ prolapse, 201
  - Pelvic pain, 555
    - acute, 555 (t 33.4)
    - chronic, 557 (t 33.6)
  - Pelvic veins, 28
  - Peptides, 76
  - Perforation uterus, 586
  - Pericervical ring, 23
  - Perihepatitis, chlamydial, 150
  - Perineal body, 20, 204
  - Perineal tear, 430
  - Perineoplasty, 592
  - Perineorrhaphy, 213
  - Perineum, 19
  - Peritoneal carcinoma, 381
  - Peritoneal fluid, 306
  - Peritonei, pseudomyxoma, 300
  - Pessary,
    - HodgeSmith, 201, 643
    - ring, 201, 643
    - test, 201, 643
  - Pfannenstiel incision, 583
  - PFR, 211, 216
  - Pineal gland, 51
  - Pipelle sampler, 120, 560
  - Pituitary gland, 69, 70
  - Pituitary gonadotrophin, 527
  - Pituitary hormones, 69
  - Placental site trophoblastic tumor, 361
  - Pneumoperitoneum, laparoscopy, 615
  - Podophyllotoxin, 517
  - Polycystic ovarian disease, 459, 469, 573, 601, 617
  - Polymenorrhoea, 185
  - Polyps, 285
    - cervical, 286
    - endometrial, 285
    - fibroid, 286
    - management, 287
    - placental, 287
  - POMB/ ACE regimen, 383, 519
  - Pomeroy's technique, 496
  - POP-Q system, 226
  - Positron emission tomography, 119
  - Postcoital test, 115, 239
  - Postmenopausal bleeding, 559
  - Postoperative care, 583
  - Postoperative complications, 596
  - Postpartum necrosis (Sheehan syndrome), 458, 465
  - Post-pill amenorrhoea, 489
  - Pouch of Douglas, 20
  - Power density (PD), 123

- Premalignant disease, 318-331
- Premenarcheal, 544
- Premature ovarian failure, 463
- Premenstrual syndrome, 182
- Preoperative preparations, 580
- Presacral neurectomy, 180
- Primary peritoneal adenocarcinoma, 381
- Primordial follicle, 83
- Procidentia, 206
- Proctoscopy, 123
- Progesterone, 75, t 535
  - activity grades, 535
  - challenge test, 469, 534
  - classification, 535
  - therapeutic, 534
- Progesterone only pill, 491
- Prognostic factors,
  - cervical cancer, 342
  - endometrial cancer, 360
  - in trophoblastic disease, 367
  - ovarian cancer, 381
  - vulvar cancer, 337
- Prolactin, 71, 461, 464, 576
- Prolactinoma, 456, 464, 577
- Prolapse, 201
  - aetiology, 204
  - degree, 205, 206
  - diagnosis, 208
  - preventive, 210
  - stage, 206
  - supports of uterus, 201
  - symptoms, 208
  - treatment, 210
  - types, 204, 205
  - vault, 220
- Prophylactic antibiotics, 582
- Prostaglandin synthetase inhibitors, 185
- Prostaglandins,
  - dysmenorrhoea, 179
  - endometriosis, 306
  - in menorrhagia, 192
  - in menstruation, 92
- Protein kinase C, 69
- Protein kinase, 69
- Pruritus vulvae, 553
- Psammoma bodies, 293
- Pseudo-Meig's syndrome, 296
- Pseudomyxoma peritonei, 300
- Psoas hitch procedure, 427
- Psoriasis, 261
- Psychosexual problems, 567
- Puberty, 49-55
  - constitutional, 51
  - delayed, 54
  - endocrinology, 49
  - menorrhagia, 54
  - precocious, 51
  - pubic hair, development, 49
  - somatic changes, 49
  - stages tanner, 50
- Pubocervical fascia, 23
- Pulmonary embolism, 598
- Pulmonary oedema, hysteroscopy, 624
- Punch biopsy, 589
- Purandare's operation, 221
- Pyometra, 168
- Pyosalpinx, 171, 650
- Pyouria, 412
- Pyridoxine, in PMS, 182

■ ■ Q ■ ■

- Q-tip test, 399
- Quantitative gradings, 206
- Quiescent (Go) cells, 511
- Quinacrine, 502

■ ■ R ■ ■

- Radiation dose, 508
  - biological effects, 508
  - Gray, 507
- Radiation reaction, 508
- Radical,
  - complications, 349
  - hysterectomy, 593, 605
  - laparoscopic, 349, 606
  - LARVH, 606
  - vaginal trachelectomy, 607
  - vulvectomy, 607
- Radio curability, 509
- Radio potentiators, 510
  - carcinoma cervix, 510
  - carcinoma' ovarian, 510

- computerised dosimetry, 509
  - intensity modulated (IMRT), 510
  - 3D CRT, 510
  - Radio sensitivity, 509
  - Radioisotopes, 506
  - Radiotherapy, 505
  - Radium, 506
  - Rape, 434
  - Rape, forensic considerations, 434
  - Rectocele, 204
  - Rectovaginal examination, 108
  - Rectovaginal fistula, 427
  - Recto-vaginal septum, endometriosis, 307
  - Rectum, 16
  - Red degeneration, fibroid, 275
  - Relaxed perineum, 204
  - Relaxin, 76
  - Resistant ovary syndrome, 452, 457
  - Retention urine, 409
  - Retractors,
    - Balfour self retaining, 638
    - Deaver's, 638
    - Doyen, 638
    - Landon's, 637
    - vaginal wall, 632
  - Retractors, abdominal, 638
  - Retroflexion, uterine, 198
  - Retroversion, uterine, 198
  - Rifampicin, 142, 487
  - RMI, 377, 548, 570
  - Rokitansky's protuberance, 293
  - Rokitansky-Kuster-Mayer syndrome, 453 (t 28.1)
  - Rollerball endometrial ablation, 195
  - Rosiglitazone, 470
  - Round ligaments, 23
  - RU486 (mifepristone), 192, 537
- ■ S ■ ■**
- S. Phase, 511
  - Sacral colpopexy, 220
  - Sacrospinous colpopexy, 221
  - Safe period, 478
  - Solifenacin, 406
  - Saline infusion sonography, 239, 560
  - Salpingectomy, 602
  - Salpingitis isthmica nodosa, 138, 172
  - Salpingitis, 169-173
  - Salpingography,
    - hysterosalpingography, 238, 588, 621
    - ultrasound, 116, 240
  - Salpingolysis, 248, 614
  - Salpingo-oophorectomy, 602
  - Salpingo-oophoritis, 176
  - Salpingoscopy, 122, 238
  - Salpingostomy, 248
  - Salvage procedure, 405
  - Sarcoma,
    - botryoides, 369
    - uterine, 276, 367
  - Savage's syndrome, 457
  - Scabies, 158
  - Schiller's test, 325
  - Scissors, laparoscopic, 612f
  - Screening,
    - breast cancer, 564
    - cervical cancer, 111, 324
    - endometrial cancer, 358
    - ovarian cancer, 377
  - Sebaceous cysts, vulva, 263
  - Second look, 380
  - Secondary surgery, 380
  - Semen, analysis, 232
  - Seminiferous tubules, 228, 444
  - Senile endometritis, 168
  - SERMS, 61
  - Serotonin, 68
    - in gonadotrophin release, 67
    - in PMS, 182
  - Serous adenocarcinoma ovary, 372
  - Serous cyst adenoma, ovary, 292
  - Sertoli cell-only syndrome, 229
  - Sertoli cells, 228
  - Sertoli Leydig cell tumours, 386
  - Sex cord stromal tumours, 384
  - Sex-determining region of Y (SRY) gene, 39
  - Sex differentiation, 39
  - Sex hormone-binding globulin (SHBG), 460, 470, 573
  - Sexually transmitted diseases, 146-159
  - Sheehan's syndrome, 465
  - Shock,
    - bacteraemic endotoxic, 134
    - TSS, 166
  - Short stature, 441
  - Sims' position, 103

- Sims' speculum, 628  
 Sims' triad, 423  
 Sinovaginal bulbs, 37  
 Sling operation, 221  
 Sling procedures, suburethral, 405  
 Smear cervical, 110  
 Smear dyskaryotic — mild, moderate, severe, 112 f  
 Soft sore, 150  
 Solifenacin, 406  
 Sonography, 117  
 Sonohysterosalpingography, 239  
 Sound, uterine, 632  
 Space,  
     pararectal, 606  
     paravesical, 606  
 Spatula, 627  
 Specimens, 645-656  
 Sperm antibodies, 234, 240, 242, 250  
 Sperm-cervical mucus contact test (SCMC), 239  
 Sperm count, 232  
 Spinnbarkeit, 115  
 Spironolactone, 538, 575  
 SRY gene, 39, 446  
 SSRI, 183  
 Stamey procedure, 404  
 Stein-Leventhal syndrome, 459  
 Sterilization, 494  
     laparoscopic, 498  
     mini laparotomy, 497  
     tubectomy, 496  
     vasectomy, 494  
 Steroid hormones, 71, 531  
 Strassman's procedure, 47  
 Stress, amenorrhoea related to, 463  
 Stress incontinence, urinary, 398  
 Stromal endometriosis, 316  
 Struma ovarii, 294  
 Strumal carcinoids, 294  
 Subzonal insemination (SUZI), 251  
 Superovulation for assisted conception, 251  
 Supports of genital organs, 201  
 Surface area, body, 665  
 Surrogacy, 243  
 Suture materials, 644  
 Swim-up test, 250  
 Swyer's syndrome, 446  
 Syndrome,  
     Fitz-Hugh-Curtis, 121, 150  
     Meig, 296, 652  
 Synechiae uterine, 459  
 Syphilis, 148
- ■ T ■ ■
- Tall girls, 453, 549  
 Tamoxifen, 533  
 Tanner staging, 50  
 Taxol, see Paclitaxel, 380, 514, 517  
 Telescope, 612  
 Teletherapy, see Radiotherapy, 507  
 Temperature,  
     basal body (BBT), 235  
 Teratoma immature, 383  
 Teratoma solid, 383, 651  
 Teratozoospermia, 232  
 Terminal care, 353  
 Testicular determining factor (TDF), 38  
 Testicular failure, 233  
 Testicular feminisation, 424  
 Testis, biopsy, 232  
 Testosterone (T), 572  
     antagonists, 575  
 Theca cell tumours, 385  
 Theca cells, 72  
 Theca externa and interna, 72, 85  
 Threadworm infestations, 553  
 Three swab test, 420  
 Thromboembolism, 598  
 Thrombophlebitis, 598  
 Thyroid hormones, 76, 540  
 Thyroid-stimulating hormone (TSH), 71  
 Thyrotrophin-releasing hormone (TRH), 67  
 TNM staging, breast cancer, 566  
 Tolterodine, 406  
 TOT, 404  
 Toxic shock syndrome, 166  
 Trachelectomy, 352, 607  
 Trachelectomy, radical, 352  
 Tranexamic acid, 192  
 Transformation zone, cervix, 321  
 Transforming growth factor (TGF), 272  
 Transvaginal sonography, 117  
 Treponema pallidum, 148

- Trichomonas vaginitis, 110  
 Trigone, bladder, 34, 394  
 Trocars, 612  
 Trophoblastic tumour, 361  
 True hermaphrodite, 444  
 Tubal insufflation, 238, 587  
 Tubal ligation, 495  
 Tubal surgery,  
   guidelines, 248  
   laparoscopic, 614  
   methods, 248  
   microsurgical, 248  
 Tuberculosis, genital, 137  
 Tubo-ovarian abscess, cyst, 129  
 Tuboplasty, 248  
 Tumour markers, 377, 521  
 Tumour necrosis factor- $\alpha$ , 306  
 Tumour suppressor genes, 520  
 Tunica albuginea, 11  
 Turner's syndrome, 441, 446, t 27.2 and 28.1  
 TVT, 404  
 Two-cell, two-gonadotrophin theory, 72
- U**
- Uchida technique, 497  
 Ulcer, Vulva, 262  
 Ultrasound in gynaecology, 117  
   TAS, 117  
   TVS, 117  
 Unicomuate uterus, 659  
 Uniplant, 502  
 Ureter(s),  
   anatomical relations, 15  
   fistulae, 427  
   surgical injury, 425  
 Urethra,  
   anatomy, 13, 394  
   caruncle, 413  
   prolapse, 413  
 Urethral sphincter incompetence, 394  
 Urethral syndrome, 412  
 Urethrocele, 204  
 Urethrovaginal fistulae, 424  
 Urge incontinence, 398, 405, 408  
 Urgency of micturition, 408t  
 Urinary bladder, 14  
 Urinary diary, 400  
 Urinary diversion, 405  
 Urinary fistula, 417  
 Urinary retention, 409  
 Urinary tract infections (UTI), 410  
 Urine examination, 109  
 Urodynamic investigations, 400  
 Uroflowmetry, 400  
 Urogenital sinus, 34  
 Uterine,  
   curettes, 632f, 633f  
   dressing forceps, 633f  
   sound, 632f  
 Uterine bleeding, abnormal (DUB), 190, 559  
 Uterine malformations, 44  
 Uterosacral ligaments, 23  
 Uterovaginal canal, 36  
 Uterus, 7, 36
- V**
- VAC regimen, 519t  
 Vaccine, HPV, 326  
 Vagina,  
   adenosis, 339, 547  
   agenesis, 43, 451f, 453t  
   anatomy, 4  
   carcinoma, 337  
   coital injury, 439  
   cyst, 264  
   cytology, 114, 627  
   development, 36  
   examination, 104  
   flora, 6  
   malformation, 42  
 Vaginal creams, oestrogen-containing, 63, 531  
 Vaginal discharge, 110, 551  
 Vaginal examination, 104  
 Vaginal intraepithelial neoplasia (VAIN), 319  
 Vaginal ring, (LNG), 501  
 Vaginectomy radical, 339  
 Vaginismus, 567  
 Vaginitis, 163 (t 12.1)  
   chlamydial, 150, 166  
   gonococcal, 147  
   monilial, 164  
   senile, 165  
   trichomonas, 163  
 Vaginoplasty, 456

Vaginitis, bacterial (anaerobic), 152  
 Varicosities, Vulva, 264  
 Vascular endothelial growth factor (VEGF), 529  
 Vasectomy, 494  
     no scalpel, 494  
 Vault prolapse, 220  
 Vault suspension, 221  
 Vento suspension, 200, 603  
 Veress needle, 612  
 Vesicovaginal fistula, 417  
 Vestibulitis, vulval, 265  
 VIA, 325  
 Videocystourethrography (VCU), 401  
 VIN, 318  
 Violin string adhesion, 130  
 Virilism, 571  
 Voiding disorders, 409  
 Vulsellum, 631, 632f  
 Vulva, anatomy, 1  
     burning, 264  
 Vulva, epithelial disorders, 259  
 Vulval pain, 264  
 Vulval tumours, 264  
 Vulval ulcer, 262  
 Vulval dermatosis, 259  
 Vulvectomy,  
     complications, 608  
     radical, 607  
     separate groin incisions, 607  
     simple, 607  
 Vulvitis, 160  
 Vulvodynia, 265  
 Vulvo-vaginitis, 544

## ■ ■ W ■ ■

Ward-Mayo's operation, 217, 599  
 Warfarin, 599  
 Wedge resection, ovary, 247  
 Weight,  
     amenorrhoea, weight loss-related, 458, 463  
     in hirsutism, 574  
 Wertheim's (radical) hysterectomy, 605  
 Witch's milk, 543  
 Wolffian duct, remnants, 47  
 Womb stone, 275, 662  
 Wound dehiscence, 641

## ■ ■ X ■ ■

X-chromosome, 39  
 X-rays, 116, 506, 580, 657  
 XX gonadal dysgenesis, 442  
 XXY female, 443  
 XXY (Klinefelter's) syndrome, 444  
 XY females, 444

## ■ ■ Y ■ ■

Yasmin, 486  
 Y-chromosome, 38, 39, 446  
 Yolk sac tumour of the ovary, 383  
 Young's syndrome, 229

## ■ ■ Z ■ ■

Zidovudine, 156  
 Zona pellucida, 84, 254  
 Zygote intrafallopian transfer, 254





Copyright © Harcourt  
**D C DUTTA'S**  
**TEXTBOOK OF**  
**GYNECOLOGY**

**SALIENT FEATURES**

- ❖ Presentation is simple, lucid and concise
- ❖ Core knowledge (must know area) is highlighted
- ❖ Enriched with flow-charts, boxes, photographs, sketches and drawings
- ❖ Consistent and uniform standard of information in all the chapters
- ❖ Information is up-to-date and evidence based
- ❖ Key points are for easy and quick revision
- ❖ Self assessment questionnaire for clinical and viva-voce examination (chapter 37)
- ❖ Different color codes are for the readers' convenience of quick reference
- ❖ Online access through [www.dcdutta.com](http://www.dcdutta.com) for 'more information' & 'ask the author'
- ❖ Video clips are incorporated for learning common operations
- ❖ Indispensable for different post graduate entrance examinations in India and abroad
- ❖ Essential for the practising gynecologist, trainee residents, general practitioners and nurses.

Available at all medical book stores  
or buy directly from Jaypee Brothers through online shopping  
at [www.jaypeebrothers.com](http://www.jaypeebrothers.com)



**JAYPEE BROTHERS**  
**Medical Publishers (P) Ltd.**  
[www.jaypeebrothers.com](http://www.jaypeebrothers.com)

Shelving  
Recommendation  
**OBSTETRICS &  
GYNECOLOGY**

